3rd EDITION

CONCISE TEXT BOOK OF SURGERY

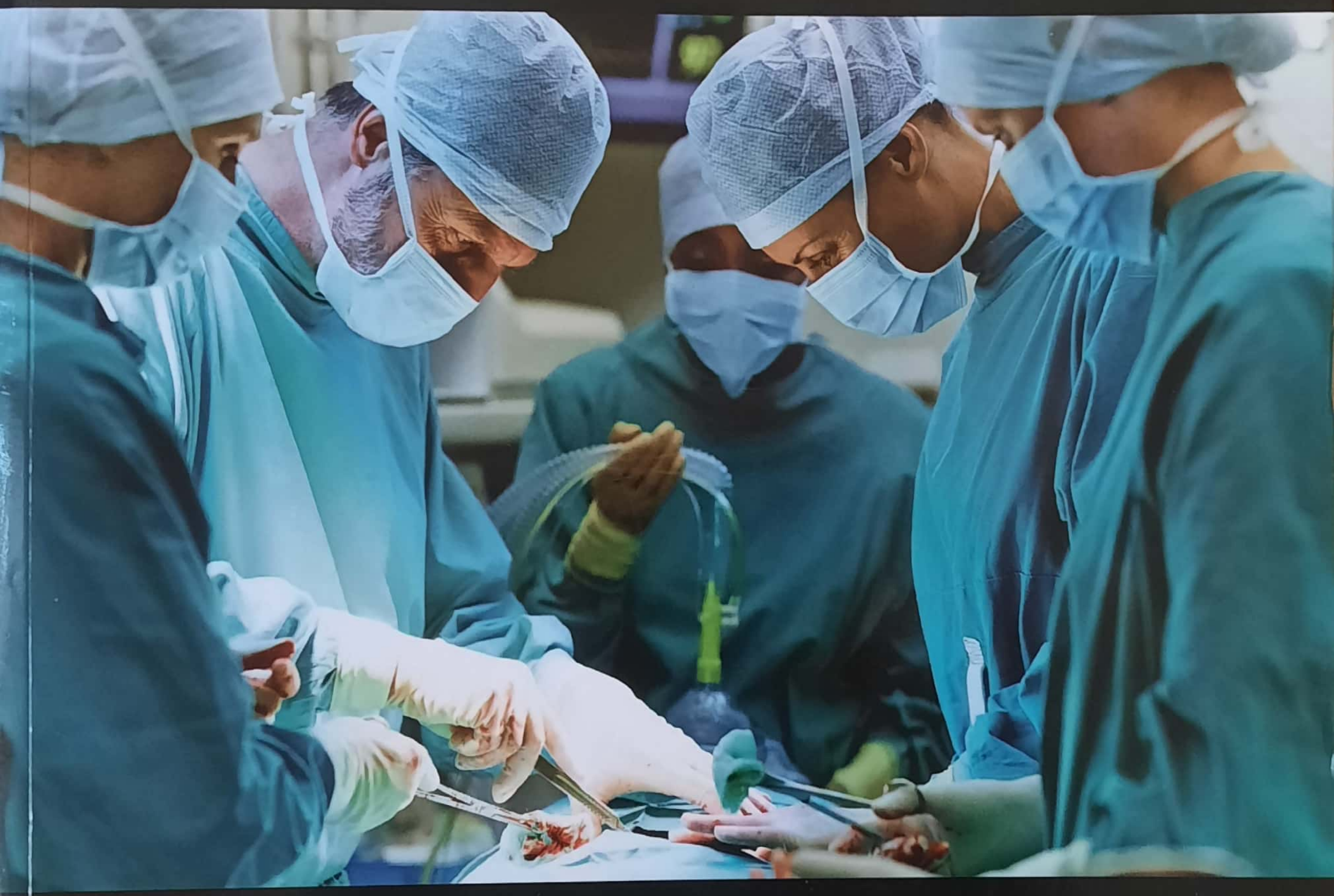

Arif Naseem

Pulse Publications

A MUST BUY FOR UNDERGRADUATE STUDENTS PREPARING FOR FINAL YEAR EXAMINATIONS AND PGMEE/NEET

CONCISE TEXT BOOK OF

SURGERY

Salient features

- A Text Book with Marked PGMEE/NEET Questions in Text
- Text Written In Easy and Flowing Language
- All in one book on undergraduate Surgery
- Topics which have been repeatedly asked in final Prof. Examinations & PGMEE/NEET are dealt in Detail
- Large number of easy to grasp mnemonics given along with Text
- In order to keep the book concise and limit text volume, unnecessary details have been kept away with
- At the end of each chapter, important final professional Examination questions are given in a box

ISBN 978-93-92448-04-1

9 789392 448041

₹1400.00

Arif Naseem

pulsepublications
PulsePublicat
pulsepublications.org

Buy books online
http:// www.pulsepublications.org

Pulse Publications

Pulse Hospital, Chhatrasangh Chauraha,
34, Kasia Road, Gorakhpur (U.P.) 273 001
Tel : +91 551 2203 494
Mobile : +91 92353 92282

Preface To Third Edition

The gestation of this book has been longer than initially envisaged; however, I take immense pleasure to release third edition after a gap of seven years since second edition.

In light of an over-whelming response and feedback that have been received to the previous editions from dear students with warmth, culminating into its success, a new updated edition became imminent on my part to keep you abreast with latest trend, albeit it was bit challenging due to professional commitments.

The emphasis in this edition is to put subject matter simple like previous edition, however keeping pace with the ever-evolving environment, all the chapters have been specifically revised without tweaking basic concept and fluidity of the text for the benefit of the students on undergraduate text of surgery.

The new edition has been supplemented with about 250 photographs, 80 key boxes and numerous flow charts for student's easy understanding and comprehension, with following highlights:

- Text has been kept concise and precise in "point" form to impart required information in minimum words, fit for undergraduate level.
- The length of the chapters is optimum to retain the learning interest, thus keeping you focussed.
- The text is comprehensive with a view that student grasps the subject easily and thereby successfully writes the exam.
- The text has been tailored in a such way that it is useful in preparation of final professional exam as well as for NEET.
- It is for the first time that PGMEE/NEET questions from various exams have been boldly marked in the text, which will help student preparing for NEET surely.

It has been my humble endeavour to keep the content to the point and correct, however there might be some untoward mistakes/human errors, please do write to me on my email to that effect, enabling me to ratify the same.

I, sincerely, express my gratitude to everyone who helped me and to Dr. Amit Tripathi of Pulse Publication, without whom this work would not have been possible.

At last, I admit that I may have many limitations and shortcomings as an author, however I have envisioned and endeavoured to provide the undergraduates with a book, which will make major final prof. subject, simple and easy for their academic and professional excellence.

Wishing you all the best and hope this new edition meets your expectations.

Arif Naseem
Gorakhpur 2nd January 2022

arif_naseem2008@yahoo.com

Preface To First Edition

The problem with currently available books on surgery is that they don't exactly match the requirements of under- graduates, namely to be able to pass the final year exams with good marks; and at the same time to prepare for the PG entrance exams. This book is a humble attempt at the same. The surgical literature offers many good and standard books, reading whome i have grown up, however hardly any book provides precise systematic text to the undergraduate students.

It is for the first time that PGMEE questions asked in various exams have been boldly marked in the text , which will definitely help students while preparing for PGMEE.

I remember my difficulties as a undergraduate, when i was in a constant dilemma as whether i would be able to reca- pitulate all the paoints mentioned in the standard text books, when required in exams. Before writing this text book i asked many present day MBBS students, which were facing the same problem.

The text volume (content) of present day standard text books are increasing day by day, however the cranial capacity of human being remaining same, it is becoming increasingly difficult in preparing surgery. I decided to write this book with a specific aim to simplify the language and at the same time providing almost all the necessary information for an undergraduate.

At the outset, I must admit that, I have nothing much to add in the original matter, except for making the language easy, simple, less time consuming and at the same time more retainable, because knowledge which is not retained and produced; at the time when needed is like indigestion occurring after having a good meal. More over, a good book should be **both informative and well as <u>student oriented</u>**, which I have tried to make at my level best.

However this book does not claim to be a comprehensive text book of surgery, the basic motto of this book is to present the subject of undergraduate surgery in a manner that;

1. It is easy to understand for those great majority of students who find the regular text book available a bit difficult to understand.
2. To provide text which is most useful for preparing for Final professional examination, as well as for preparing for PG exams even during the first reading, which will definitely help you next year, in internship while preparing for PGME.

I have aimed to make this book as easy to study as I believe is possible for an undergraduate text book of surgery to be. I have paid special attention to the following features that facilitate achievement of these objectives:

- The length of chapters are short enought to be retained in a resonable length of time.
- The test is concise. I have provided the text in "point" form and tried my best to use minimum number of words to impart the necessary informations at undergraduate level.
- The text is comprehensive and I strongly hope that it will satisfy most of you in both understanding the subject and passing the examinations.

Outstanding features of this book are

1. Being written in an very easy to understand language, So make this book as first book of surgery, and once the basic concept is clear then read other standard text books.
2. The questions asked in various PG exams have been specifically marked at the site of text, so that students can pay more attention to them, even during first reading during Final professional.
3. Illustrated diagrams accompany the text where ever required. they present the text in concise form and allow quick review at a glance. however unnecessary and confusing photographs have been kept away with.
4. Large numbers of easy to grasp Mnemonic.
5. The topics which have been repeatedly asked in entrance exams, are dealt with a greater detail.
6. In an endeavour to keep the book "concise and to the point", unnecessary and confusing details have been kept away.
7. At the end of each chapter, important Final professional questions are given in a box; which will be helpful while preparing for the Final year examinations.

I sincerely admit that I have my limitation and deficiencies as an author, though I have made an attempt to provide the undergraduates with a book which will make a major Final prof. subject simple, methodical and easy.

I hope this book, which is simple enough for undergraduates will be appreciated by most of the students and also welcomed by the postgraduates and honourable teachers, who rely on systematic study.

Lastly, It is quite possible, that there may be errors in spelling, typing, and grammar as most of DTP job (computer setting) work has been done by me itself, however these will hardly make any difference in understanding the text. I shall be highly grateful to the readers for their valuable suggestions.

I take this opportunity to extend my best wishes to all the readers

See the invisible

Touch the intangible

Achieve the impossible

Arif Naseem

Feb 14, 2008

Contents

1. Wound, Wound Healing and Scar — 1-15

- Classification of Wound
- Surgical Wound Classification
- Types of Wound
- Wound Closure
- Phase of Wound Healing
- Factors affecting wound healing
- Some Chronic Wounds
- Abnormal Wound Healing
  - Hypertrophic scar
  - Keloid

2. Shock — 16–22

- Stages of shock
- Types of shock
- Management of shock

3. Basics of I.V. Fluid Therapy — 23–32

- Indication of fluid therapy
- Disadvantage
- Contraindication
- Types of I.V. fluid
  - Crystalloid
  - Colloid

4. Hemorrhage and Blood Transfusion — 33–40

- Classification
- Physiological effect
- Methods of determining blood loss
- Blood transfusion
- Massive blood transfusion
- Blood products
- Red blood cell subsititute

5. Nutrition in a Surgical Patient — 41–52

- Nutritional assessment
- Administration of nutrition
- Enteral nutrition
- Parenteral nutrition
- Nutritional support in special situations

6. Surgical Infections — 53–58

- Boils (Furuncle)
- Abscess
- Carbuncle
- Cellulitis
- Erysipelas
- Hidradenitis suppurativa
- Necrotizing fascitis

7. Ulcer, Sinus and Fistula 59–68

- Stage of Ulcer
- Anatomy of an ulcer
- Classification of ulcer
- Causes of non healing of an ulcer
- Sinus
- Fistula

8. Principle of Laparoscopic Surgery 69–75

- Introduction
- Instruments
- Diagnostic Laparoscopy
- Technique
- Steps in Laparoscopy

9. Burn and Post Burn Contracture 76–91

- Pathophysiology
- Depth of burn
- Extent of burn
- Burn severity
- Management of a burn patient
- Electric burn
- Post-burn contracture
- Chemical burn

10. Plastic and Reconstructive Surgery, Skin Grafting 92–98

- Skin grafts
- Flaps

11. Tetanus and Gas Gangrene 99–105

- Tetanus
- Gas gangrene

12. Infection of The Hand and Foot 106–118

- Anatomy of hand
- Types of Hand Infection
- Miscellaneous conditions of hand
- Ganglion
- Surgical incision of hand
- Diseases of Foot
  - Plantar fascitis
  - Ingrowing toe nail
  - Diabetic foot
  - Madura foot

13. Skin Lesions and Skin tumour 119–145

- Function of Skin
- Benign skin Lesion
  - Dermoid cyst
  - Sebaceous cyst
  - Lipoma
  - Corn
  - Callosity
- Neurofibroma
- Moles
- Premalignant lesions of the skin
- Hemangioma
  - Capillary hemangioma
    a. Strawberry anigoma
    b. Portwine stain
    c. Salmon patch
  - Cavernous hemangioma
  - Arterial or plexiform hemangioma
- Malignant tumours of skin
  - Basal cell carcinoma (Rodent ulcer)
  - Squamous cell carcinoma (epidermoid carcinoma)
  - Malignant melanoma

14. Scalp, Skull, Brain and SpinalCord 146–164

- The scalp
- The skull
- Fracture
- Brain injury
- Supra cranial hematoma
  - Extradural (epidural) hematoma
  - Subdural hematoma
  - Subarachnoid hemorrhage
- Traumatic brain edema
- Assessment of head injury
- Neural tube defects
- Tumor's of CNS

15. Mouth, Cheek and Toungue 165–179

- Stomatitis
- Oral candidiasis
- Bacterial infection
  - Vincent stomatitis
  - Cancrum oris
- Oral Ulceration
  - Apthous ulceration
  - Herpes ulcer
  - Traumatic ulcer
  - Syphilitic ulcer
  - Tubercular ulcer
  - Ulcers due to agranulocytosis
  - Carcinomatous ulcer
- Oral cysts
  - Mucus retention cyst
  - Ranula
  - Dermoid Cyst
- Cheek
  - Tumours of cheek
  - Carcinoma of the cheek
- Lip
  - Carcinoma of lip
- Tongue
  - Tongue tie
  - Macroglossia
  - Hyperkeratosis
  - Leukoplakia
  - Erythroplakia
  - Oral submucous fibrosis
  - Carcinoma of tongue

16. Cleft Lip and Palate 180–183

- Cleft lip
  - Classification
- Cleft Palate
  - Classification
- Treatment of cleft lip and palate
- omplication due to cleft lip and palate

17. The Gums and Jaws 184–192

- Epulis
- Alveolar abscess
- Osteomyelitis of jaw
- Jaw Tumours
  - Malignant ameloblastoma
  - Giant cell reparative granuloma
  - Giant cell tumour (osteoclastoma)
  - Bone cyst
- Aneurysmal
- Dental cyst
  - Complication due to cleft lip and palate
  - Dentigerous cyst
  - Primordial cyst
  - Adamantinoma
- Simple
  - Chondroma
  - Torus
  - Fibrous dysplasia

18. The Salivary Gland — 193–204

- Composition of saliva
- Function of saliva
- Surgical anatomy
  - Parotid gland
  - Sub mandibular gland
  - Lingual nerve
- Acute parotitis
- Acute suppurative parotitis
- Mumps parotitis
- Salivary gland neoplasm
  - Pleomorphic adenoma
  - Warthin's tumours
  - Carcinoma
- Frey's syndrome

19. The Neck — 205–223

- Surgical anatomy
- Swelling of neck
  - Thyroglossal cyst
  - Thyroglossal fistula
  - Sub hyroid bursal cyst
  - Branchial cyst
  - Branchial fistula
- Cystic hygroma
- Carotid body tumour
- Sternomastoid tumour u Cervical rib
- Cervical lymph node
- Cervical lymph node dissection

20. The Thyroid Gland — 224–257

- Surgical anatomy
- Physiology of thyroid hormone
  - Investigation of thyroid disorder
  - Imagine technique
  - Test of function of thyroid
  - Specific test for thyroid
- Goiter
- Disease of thyroid
  - Development and congenital disease
    - Developmental anomalies of shape
    - Development anomalies of position
    - Remnant of thyroglossal duct
  - Disease related to release of thyroid hormone
    - Hyperthyroidism
    - Hypothyroidism
- Immunological disease of the thyroid
  - Grave's disease
  - Hashimoto's thyroiditis
- Inflammatory thyroid disease
  - Subacute thyroiditis: De-Quer-vain's thyroiditis
  - Riedel's thyroiditis
  - Acute (suppurative) thyroiditis
- Thyroid Neoplasm
- Benign
  - Solitary thyroid nodule (95% are benign)
  - Follicular Adenoma
- Malignant
  - Anaplastic carcinoma
  - Medullary carcinoma
- Thyroidectomy
- Solitary thyroid nodule

21. Parathyroid and Adrenals 258–268

- Para Thyroid Gland
  - Surgical anatomy
  - Hyperparathyroidism
  - Hyperthyroidism
- Adrenal Gland
  - Cushing syndrome
  - Primary hyper aldosteronism (conn's syndrome)
  - Secondary hyperaldosteronism
  - Neoplasm of adrenal

22. Chest Wall, Pleura and Lungs 269–284

- Disease of chest wall
  - Pectus excavatum
  - Pectus carinatum
  - Tietze's disease
  - Cold abscess of chest wall
  - Empyema Necessitans
- Disease of pleura and lung
  - Pneumothorax
  - Hemothorax
  - Empyema thoracis
  - Lung abscess
  - Lung tumors
- Chest trauma
  - Rib fracture
  - Stove in chest
  - Flial chest
  - Traumatic pneumathorax
  - Traumatic hemothorax
  - Surgical emphysema

23. Arterial Disorder 285–312

- Peripheral vascular disease
  - Atherosclerotic obstructions
  - Buerger's disease
- Acute thromboembolism
- Vasospastic disorders
- Raynaud's phenomenon
- Gangrene
- Amputation
- Arterial aneurysm
- Arterio-venous fistula
- Subclavian steal syndrome
- Thoracic outlet syndrome

24. Venous Disorder and Lymphedema 313–330

- Varicose vein
- Venous thrombosis
- Pulmonary embolism
- Lymphedema

25. The Breast 331–369

- Congenital abnormalities of breast
- Surgical anatomy
- Manifestation of breast disease
- Investigation of breast disease
- Mastalgia
- ANDI
- Inflammatory and related lesions of breast
- Benign neoplasm of breast
  - Fibro adenoma
  - Phylloid tumour
  - Duct papilloma
- Malignant neoplasm of breast
- Breast reconstruction
- Gynecomastia

26. The Esophagus 370–398

- Surgical anatomy
- Esophageal perforation
- Corrosive stricture of esophagus
- Achalasia cardia (cardio-spasm)
- Plummer-Vinson syndrome
- Mallory- weiss syndrome
- Dysphagia lusoria
- Schatzki's ring
- Gastro-esophageal reflux disease
- Hiatus hernia
- Neoplasm of esophagus
- Esophageal diverticula

27. The Diaphragm 399–402

- Diaphragmatic Hernia
  - Hiatus Hernia
  - Para sternal hernia
  - Bochdalek hernia
  - Traumatic diaphragmatic hernia
- Eventration of diaphragm

28. The Stomach and Duodenum 403–455

- Surgical anatomy
- Physiology
- Investigation
- Hypertrophic pyloric stenosis of infancy
- Duodenal atresia and stenosis
- Acute erosive gastropathy
- Chronic gastritis
- Menetrier's disease (Hypertrophic gastritis)
- Eosinophilic gastritis
- Peptic ulcer
  - Gastric ulcer
  - Duodenal ulcer
- Carcinoma of stomach Other Gastric tumours
  - Gastric stromal tumours
  - Gastric carcinoid
  - Gastric lymphoma
- Duodenal tumour
- Acute gastric dilatation
- Volvulus of stomach
- Dieulafoy's disease
- Gastric diverticula
- Hypertrophic pyloric stenosis of adult
- Bariatric surgery

29. The Liver 456–493

- Surgical anatomy
- Investigation of Liver disease
- Liver trauma
- Hemobila
- Liver abscess
- Cyst of liver
- Neoplasm
- Benign
  - Liver cell adenoma
  - Focal nodular hyperplasia
  - Hemangioma
- Malignant
  - Hepatocellular carcinoma
  - Metastatic tumour
- Portal hypertension
- Budd-chiari syndrome

30. The Gail Baldder and Bile Duct — 494–527

- Surgical anatomy
- Investigation of biliary tract
- Congenital conditions of the biliary tree
- Choledocholithiasis
- Cholangitis
- Obstructive jaundice
- Sclerosing cholangitis
- Bile duct stricture
- Extra hepatic biliary atresia
- Choledochal cyst
- Gall stone disease
- Parasitic infection of the bile duct
- Carcinoma of gall bladder
- Cholangiocarcinoma
- Klatskin's tumours

31. The Pancreas — 528–557

- Embryology
- Congenital abnormalities
  - Pancreatic divisum
  - Annular pancreas
  - Ectopic pancreas
  - Pancreatic hypoplasia
- Surgical anatomy
- Injury to pancreas
- Acute pancreatitis
- Chronic pancreatitis
- Neoplasm of exocrine pancreas
- Endocrine tumours of pancreas

32. The Spleen — 558–570

- Surgical anatomy
- Physiology
- Functions of spleen
- Rupture of spleen
- Blood disorder treatable by splenectomy
- Splenomegaly and hypersplenism
- Splenectomy
- Tropical splenomegaly
- Splenic abscess

33. Peritoneum, Omentum, Mesentery and Retroperitoneum — 571–589

- Peritoneal fold
- Peritonitis
  - Primary
  - Secondary
  - Tertiary Peritonitis
- Special forms of peritonitis
  - Meconium Peritonitis
  - Biliary peritonitis
  - Tuberculous peritonitis Chylous Ascites
- Intra peritoneal peritonitis
  - Pelvic abscess
  - Subphrenic abscess
- Neoplasm of peritoneum
- Mesenteric tear
- Mesenteric cysts
- Non specific mesenteric lymph adenitis
- Tuberculosis of mesenteric lymph node
- Retroperitoneal fibrosis
- Retroperitoneal trauma

34. The Small and Large Intestine 590–636

- Peritoneal fold
- Surgical anatomy
- Hirschsprung's disease (Congenital megacolon
- Idiopathic megacolon (chronic functional constipation
- Diverticular disease
- Meckel's diverticula
- Colonic diverticulitis
- Ulcetative colitis
- Chron's disease
- Tuberculosis of the intestine
  - Hyper plastic ileocecal tuberculosis
  - Ulcerative tuberculosis
- Short bowel syndrome
- Ischemic colitis
- Tumours of the small intestine
- Tumours of the large intestine
  - Non neoplastic epithelial tumours
  - Benign neoplasm
  - Malignant neoplasm
- Fecal fistula (entero-cutaneous fistula)
- Ileostomy and colostomy

35. Intestinal Obstruction 637–661

- Classification
- Dynamic (mechanical) intestinal obstruction
- Closed loop obstruction
- Important causes of intestinal obstruction
  - Volvulus
  - Volvulus neonatorum
  - Volvulus of the small intestine
  - Cecal volvulus
  - Volvulus of sigmoid
  - Intussusception
  - Adhesive intestinal obstruction
  - Band causing intestinal obstruction
- Acute intestinal obstruction of new born
  - Congenital atresia
    - Duodenal atresia
    - Jejuno-ileal obstruction
    - Arrested rotation with band
    - Meconium ileus
    - Meconium - plug syndrome
- Adynamic obstruction
- Pseudo obstruction
- Mesenteric vascular disease
  - Acute mesenteric ischemia
  - Chronic mesenteric ischemia
  - Mesenteric venous thrombosis

36. The Vermiform Appendix 662–676

- Surgical anatomy
- Acute appendicitis
- Appendicular lump
- Recurrent appendicitis
- Tumour of appendix

37. The Rectum 677–691

- Surgical anatomy
- Proctitis
- Prolapse of rectum
- Solitary rectal ulcer
- Benign tumours of the rectum
- Carcinoma of rectum
- Bleeding per rectum

38. The Anus and Anal Canal — 692–716

- Surgical anatomy
- Pilonidal sinus
- Anal fissure
- Hemorrhoid
- Fistula in ano
- Anorectal abscesses
- Perianal abscess
- Proctalgia fugax
- Pruritus ani
- Carcinoma of anal canal
- Perianal paget disease

39. Trauma, Assessment and Management — 717–730

- Death following trauma
- Mechanism of injury
- Triage
- Scoring system of injury severity
- Management of trauma patient

40. Abdominal Trauma — 731–745

- Mechanism of injury
- Diagnosis of abdominal injury
- Abdominal compartment syndrome
- Blunt abdominal trauma
- Penetrating abdominal trauma

41. Abdominal Wall and Umbilicus — 746–757

- Abdominal wall layers
- Burst abdomen
- Incisional hernia
- Diverication of recti
- Neoplasm of abdominal wall
- Abdominal incision
- Diseases of umbilicus
  - Omphalitis
  - Umbilical granuloma
  - Umbilical calculus (umbolith)
  - Umbilical fistula
  - Patent urachus
  - Neoplasm of umbilicus

42. Hernia — 758–786

- Incidence
- Etiology
- Classification of hernia
- Inguinal hernia
  - Indirect inguinal hernia
  - Direct inguinal hernia
- Obstructed and strangulated inguinal hernia
- Rare varieties of inguinal hernia
- Femoral hernia
- Umbilical hernia
  - Exomphalos
  - Umbilical hernia of infant
  - Paraumbilical hernia of adult
- Epigastric hernia
- Rare external hernia
  - Spigelian hernia
  - Sciatic hernia
  - Gluteal hernia
  - Lumbar hernia
  - Obturator hernia
  - Perineal hernia
  - Peterson hernia

43. Investigations of Urinary Tract 787–794

- Surgical anatomy
- Methods of evaluating renal structure and function

44. The Kidney and Ureter 795–830

- Congenital abnormalities of kidney
- Injuries to kidney
- Hydronephrosis
- Renal stone
- Ureteric stone
- Kidney infections
  - Acute pyelonephritis
  - Emphysematous pyelonephritis
  - Chronic pyelonephritis
- Xanthogranulomatous pyelonephritis
- Renal abscess (Renal carbuncle)
- Infected hydronephrosis and pyonephrosis
- Perinephric abscess u Renal tuberculosis
- Wilm's tumour
- Renal cell carcinoma (Hypernephroma)
- Papillary transitional cell tumours of renal pelvis and ureters.
- Squamous cell carcinoma of pelvis

45. The Urinary Bladder 831–847

- Surgical anatomy
- Ectopia vesicae
- Rupture of bladder
- Retention of urine
- Cystitis
- Bilharzial cystitis
- Bladder stone
- Carcinoma of the bladder
- Hematuris
- Urinary incontinence

46. The Prostate 848–868

- Surgical Anatomy
- Benign Prostatic Hyperplasia
- Carcinoma of prostate
- Bladder out flow obstruction due to bladder neck disease
- Acute Prostatitis
- Chronic Prostatitis
- Prostatic calculi
- Chronic pelvic pain syndrome (CPPS)
- Retention of urine

47. The Urethra 869–880

- Surgical Anatomy
- Meatal stenosis
- Congenital valve of posterior Urethra
- Hypospadias
- Epispadias
- Injury to male urethra
- Urethritis
- Urethral stricture
- Male urethral carcinoma
- Foley's catheter

48. The Penis 881–888

- Surgical Anatomy
- Phimosis
- Paraphimosis
- Balano posthitis
- Peyronie's disease
- Priapism
- Carcinoma of penis

49. The Testis and Scrotum — 889–914

- Surgical Anatomy
- Idiopathic scrotal gangrene (Fournier's gangrene)
- Filarial scrotum
- Sebaceous cyst of scrotum
- Carcinoma of the scrotum
- Imperfect descent of testis
- Retractile testis
- Testicular torsion
- Varicoele
- Hydrocele
- Chylocele
- Hematocele
- Pyocele
- Epididymal cyst
- Spermatocele
- Epididymo-orchitis
- Tumour of Testis
- Extra gonadal germ cell tumours
- Male infertility

50. Day Surgery — 915–919

- Introduction
- Definition
- Benefits of day surgery
- Day surgery units
- Suitable day surgery procedures
- Extended day surgery
- Hospital hotels

51. Oncology Cancer Chemotherapy and Radiotherapy — 920–935

- Oncogene
- Tumour suppressor genes
- Tumour markers
- Oncogenesis
- Chemotherapy
- Hormone therapy
- Immunotherapy
- Chemotherapeutic regime

52. Principles of Laser Surgery — 936–942

- Introduction
- Laser Light
- Pulsed laser
- Continuous wave laser
- Laser/atom connection
- Types of LASER
- LASER surgery
- Advantage of LASER surgery
- LASIK LASER

53. Surgical Conditions in Neonates, Infants and Children — 943–971

- Gastrointestinal condition
  - Duodenal atresia
  - Jejunoileal atresia
  - Malrotation and volvulus neonatorum
  - Meconium ileus
  - Meconium plug syndrome
  - Anorectal malformation
  - Hirschsprung's disease
  - Acute scrotum
  - Testicular torsion
  - Undescended testis
- Tumours
  - Wilm's tumour
  - Neuroblastoma
  - Rhabdomyosarcoma
- Skin lesions
  - Capillary hemangioma

- Colonic atresia
- Infantile pyloric stenosis
- Intussusception
- Appendicitis
- Mesenteric adenitis
- Exomphalos
- Gastroschisis
- Prune belly syndrome
- Congenital hernia/hydrocele
- Other common conditions
  - Umbilical hernia
  - Diaphragmatic hernia
- Strawberry angioma
- Portwine angioma
- Portwine stain
- Salmon patch
- Venous/Cavernous hemangioma
- Arterial/Plexiform hemangioma
- Head & neck disorders
  - Neural tube defect
  - Sacrococcygeal teratoma

54. Organ Transplantation 972–991

- Types of donor
- Immunology
- Rejection
- Immunosuppression
- Principles of transplantation
- Donor
- Kidney Transplantation
- Liver transplantation
- Pancreas transplantation
- Small bowel transplantation
- Heart transplantation
- Lung transplantation
- Pancreas transplantation
- Small bowel transplantation

55. Diagnostic Modalities 992–1002

- X-ray
- Contrast enhance X-ray
  - Ba swallow
  - Ba meal
  - Ba meal follow through (BMFT)
  - Ba enema
- Ultrasonography
- CT Scan
- MRI Scan
- Magnetic resonance spectrography
- Radionuclide scanning(Isotope scintigraphy)
- PET scan

INDEX 1003–1032

1 Wound, Wound Healing and Scar

Contents

- Classification of Wound
- Surgical Wound Classification
- Types of Wound
- Wound Closure
- Phase of Wound Healing
- Some Chronic Wounds
- Abnormal Wound Healing

WOUND

A wound is breach in continuity of the skin or surface epithelium. Wound is called simple when only skin and subcutaneous tissue is involved, and is termed as complex when it involves underlying nerves, vessels, tendons with devitalized tissue.

Classification of Wound

It can be classified as:

A. **Closed wounds**-Bruise/Contusion, Hematoma
B. **Open wounds**-Puncture wounds, Abrasion, Laceration.
C. **Complex wounds**-Crush/Avulsion, Gunshot wound, Blast wound.

(a) Closed Wound

These are as result of blunt trauma and usual causes are fall, sport's injury or assault with blunt weapon.

1. Bruise (Contusion)

Bruise is visible infiltration of blood in tissue, following rupture of capillaries as a result of application of blunt force. Usually it is subcutaneous and there is **no breach in continuity of skin.** A superficial bruise is slightly raised above the surface of skin, due to infiltration of blood in subcutaneous tissue. It must however be remembered that bruise may not always be present at the site of impact, but appear at entirely different area. Appearance of bruise depends on force of violence and some other factors like:

- Site more marked on parts over lying bones.
- Bruise occurs easily on lax tissue like face, around genitalia and around eyes.
- Greater the vascularity of part the greater is bruising
- Children and old people tend to bruise easily.
- Bruising is more evident in fair colour person.
- Bruise disappear by itself in extremely variable period, except in some individual and at some site where discolouration may persist for longer period.

2. Hematoma

Hematoma is described as localized collection of blood in tissue following blunt trauma. Initially the collection is fluid; but it does clot within minutes or hour. Later, after

few days the hematoma will again liquefy.

Treatment

- Most of the time hematoma resolve spontaneously in variable period without scarring, but on occasion there may be persistent tethering of skin.
- There is chances of secondary infection and development of abscess. If it happen, incision and drainage should be done.
- Hematoma causing pressure effect, should be evacuated by open surgery.
- Hematoma on cosmetically sensitive site should be aspirated by wide bore needle, with antiseptic precaution.

(b) Open wound

Open wound is as result of penetrating trauma. There is **clear cut breach in continuity** of skin. They are classified as:

1. Incised wound

This is a wound caused by sharp instrument like knife, blade or glass. These are ***tidy wounds*** (NEET) that has no bruising or gaping between the wound margins.

Treatment

If wound is simple, non contaminated and presents in ***less than 6 hours*** after injury, *primary suturing* is ideal and on healing, scar is linear and least deforming. This period is known as ***Golden period*** (AI 91) of primary repair.

2. Puncture (stab) Wound

Puncture wound is open injury caused by a more or less pointed weapon, when it is driven through the skin and depth is the greatest dimension. *This wound is deeper than its length.* There is always risk of foreign material carried deeply into underlying tissue. External examination of stab wound gives no indication of its depth, direction or the internal injuries, hence it is wise to ruled out visceral organ injury by thorough physical examination and appropriate investigations. See figure 1.0

Treatment

It should be done in following order:

- First make sure that there is no underlying visceral injuries.
- Wound should be irrigated.

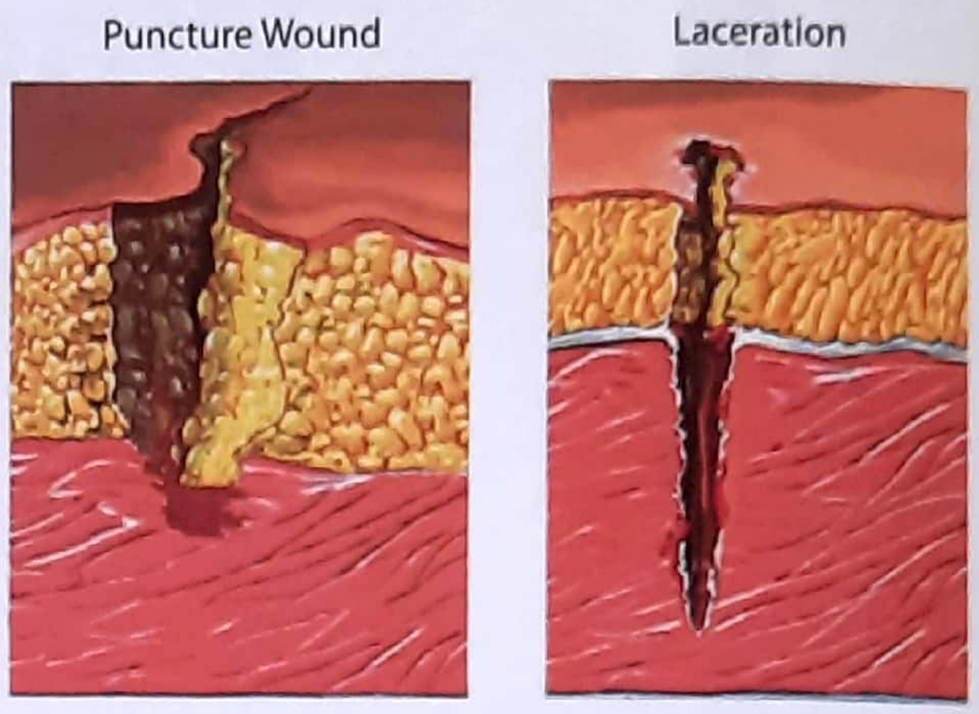

Figure 1.0: Types of wound

- Antibiotics and tetanus prophylaxis should be started.
- Foreign body should be remove by forceps. Small invisible foreign bodies can be detected radiologically and removed.

3. Abrasions

Abrasion is shearing injury of skin due to tangential force, in which surface is rubbed away causing loss of surface epithelium. It bleeds profusely and heals rapidly in few days. Depending on the manner in which they are caused, abrasions are classified into following:

- Scratches
- Grazes
- Imprint, pressure or contact abrasion.

Treatment

Most of superficial abrasions heal by epithelialization. In few cases, where full thickness skin loss is present, skin grafting is required. Abrasion may be dirt ingrained, and if this dirt is not removed at the time of primary treatment permanent tattooing of skin will result.

4. Lacerations

These are wounds, in which the skin and underlying tissues are torn frequently; as a result of road traffic accidents. Once the dermis has cut, there is less resistance in subcutaneous tissue and cut may penetrate to deeper tissue, jeopardizing the integrity of muscles, tendons and vessels. The clinical examination must therefore access the integrity of all three structures.

Treatment

The ideal form of lacerated wound treatment includes surgical inspection, cleaning and closure. The wound must be thoroughly inspected to ensure that there is no damage to underlaying deeper structure. If they are encountered, they must be repaired. If all structures are identified then these are repaired individually by appropriate technique. Hemostasis must be secured throughout the exploration. Muscles can be opposed my mattress suture where as fascia and subcutaneous tissue should be opposed by interrupted absorbable suture. Skin closure should be done in such way that skin margins do not invert.

(c) Complex wound

1. Traction and avulsion

These are open injuries, where there has been severe degree of tissue damage with displacement of tissues from their normal anatomical alignment. Such injuries occur when hands or limb are trapped in moving machinery, such as rollers, producing a degloving injury. *Degloving injury* (KERELA 2000) is caused by shearing forces that separate tissue planes rupturing their vascular interconnection and causing tissue ischemia. (Figure 1.1 and 1.2)

These can be open or closed. They can occur only in the single subcutaneous plane, but when present hi multiple planes, such as between muscles and fascia and between muscle and bone are an indication of severe high energy injury with limited potential for primary healing. The danger of degloving or avulsion injuries is that; there is devascularization; and tissue and skin necrosis may become apparent in the next few days.

Treatment

If there is closed degloving injury, then area of devitalized skin is identified and removed, followed by full thickness skin grafting. In case of open injury, the wound is cleaned and prepared for skin grafting or flap cover.

2. Crush Injury

Crush injuries are a further variant of blunt injury, and are often accompanied by degloving and compartment 'syndrome. Injury to tissue within a closed fascial compartment leads to bleeding, exudation and swelling of these tissues result in an increased interstitial pressure. As the interstitial pressure rises above capillary perfusion pressure, the blood supply to the viable tissues is reduced, resulting in further ischemic tissue injury and swelling, and causes ***compartment syndrome.***

- This process should be identified early. The most reliable clinical sign of compartment syndrome is pain, worsened by passive stretching of effective muscles.
- Features of Crush syndrome → ↑ K^+, ↓ Ca^{+2}, ↑ PO_4^{-3}, ↑ Uric acid, Myoglobinuria, ↑ BUN & Creatinine, Lactic acidosis.
- The loss of peripheral pulses is not an indication of compartment syndrome.

Figure 1.1: Degloving injury

Figure 1.2: Degloving injury

- Where compartment syndrome (>30 mmHg) is suspected and confirmed, immediate **fasciotomy (up to deep fascia) is advised.** Longitudinal incision (release incision) are made through deep fascia and it may also be necessary to make extensive longitudinal releases in the skin.

3. Gun Shot Injury

These injuries are associated with different severities of tissue damage depending on whether the injury is of low or high velocity fire arm. Such injuries are often associated with severe tissue contamination from clothing, dirt of other foreign material.

- Superficial gun shot wounds require careful surgical excision and should be left open. Following high velocity injuries, fasciotomy of all the fascial compartment of limb should be under taken.
- Perforating and penetrating wounds are special type of gun shot wounds; which are caused by high velocity bullet, that may lodge in or pass through the tissue.
- A perforating wound usually has both an entry and exit wounds, while a penetrating wound has only entry wound and has no exit wound.

Treatment

If gun shot wound is localized to subcutaneous tissue & deep fascia and is associated with extensive damage, they should be managed by extensive debridement and achievement of hemostasis.

****

SURGICAL WOUND CLASSIFICATION ACCORDING TO CONTAMINATION

1. Clean (Class I)

Uninfected operative wound in which *no inflammation is encountered and hollow organ system is not entered.* Surgical wound following blunt trauma should be included in this category, if they meet the criteria. Other example is hernia surgery.

Surgical site infection (SSI) rate : 1-2% (1-2% before prophylaxis).

2. Clean Contaminated (Class II)

Operative wound in which **the respiratory, alimentary, genital or urinary tract are entered, under controlled condition and without unusual contamination. For example; Cholecystectomy, Gastrojejunostomy.** *(NEET, APPG 06)*

SSI Rate - 3% (6-9%)

3. Contaminated (Class III)

Open fresh accidental wound, or operations with major breaks in sterile technique or gross spillage from the GI tract during operative procedure and incision in which acute/non purulent inflammations is encountered.

SSI Rate - 6% (13-20%)

4. Dirty (Class IV)

Old traumatic wound with retained devitalized tissue and those that involve existing clinical infection or perforated viscera, i.e.; Organisms causing post operative infection were present in operative field before operation. Example is drainage of cervical abcess, other abscess.

SSI Rate - 7% (20-40%)

****

Scoring system for severity of wound infection.

ASEPSIS Wound Score

A - Additionla treatment
(antibiotics, Drainage, Debridement)

S - Serous Discharge

E - Erythema

P - Purulent exudate

S - Separation of Deep tissue

I - Isolation of bacteria

S - Stay as inpatient prolonged over 14 days as result of wound infection

Southampton wound grading system *(NEET 20)*

0 → Normal Healing

I → Normal Healing with mild browsing or erythema.

II → Erythema plus other signs of inflammation.

III → Clear or Haemoserous discharge.

Major complication

IV → Pus.

V → Deep or severe wound infection.

TYPE OF WOUND

1. Acute Wounds

Acute wounds usually occurs in a normal, healthy person resulting from transient, externally induced damage to the tissue and is closed either primarily or allowed to close by secondary intension. Acute wound proceed in an orderly & timely reparative process to achieve sustained restoration of structure and function.

2. Chronic Wounds

These wounds have *failed* to proceed through the orderly process that produces satisfactory anatomical and functional integrity, or that wounds have proceeded through the *repair process without producing any adequate result.*

- The majority of wounds that have not healed in 3 months are considered chronic.
- Skin ulcers, which usually occur in traumatized or vascularly compromised soft tissue are also considered chronic in nature.

KEY-BOX 1.1
Muscle viability is detected by '4C' (NEET)
(a) **Colour:** dead muscle has dark colour & has lost it's sheen.
(b) **Contractility:** dead/unhealthy muscles does not twitch when held by forceps.
(c) **Consistency:** dead muscles has lost its turgor and is mushy in consistency
(d) **Capillary bleeding:** dead muscle does not. bleed at cut ends.

- Repeated trauma, poor perfusion or oxygenation and/ or excessive inflammation contribute to the causation and the perpetuation of the chronicity of wounds.
- Any wound that does not heal for a prolonged period of time (eg; Marjolin's ulcer) is prone to malignant transformation, so biopsy of chronic wound from wound edges should be taken to rule out malignancy. (PGME)

KEY-BOX 1.2

Management of acute wounds

1. Examination
a) Depth?
Underlying structures injured
b) Configuration?
c) Nonviable tisue?

2. Preparation
a) Anesthetic
- Lidocaine with or without epinephrine
b) Exploration
- Underlying structures injured
c) Cleansing
- Pulsed irrigation, saline only
d) Hemostasis
e) Debride nonviable tissue
f) Betadine on surrounding skin
g) Antibiotics (rare)
h) Tetanus

3. Approximation
a) Deep layers
- Fascial layers only
- Absorbable suture
b) Superficial layers
- Meticulous alignment
- Nonabsorbable sutures in skin
- Staples
- Monofilament
- Dermal glues

4. Follow-up
a) Cellulitis/drainage?
b) Suture removal
- 4-5 days for face
- 7-10 days other skin

KEY-BOX 1.3
Desired characteristics of wound dressings
Promote wound healing (maintain moist environment)
Conformability
Pain control
Odor control
Nonallergenic and nonirritating
Permeability to gas
Safety
Nontraumatic removal
Cost-effectiveness
Convenience

Treatment of Wounds

1. Local care

- Management of acute wound begins with careful history and detail clinical examination. Examination of wound may require irrigation and debridement of wound edges.
- Antibiotics and tetanus prophylaxis is needed.
- High pressure wound irrigation with normal saline is effective in achieving complete debridement of foreign material and non-viable tissue.
- Wound edges should be debrided, for fresh edge, and re-approximation is done by minimum possible suturing.

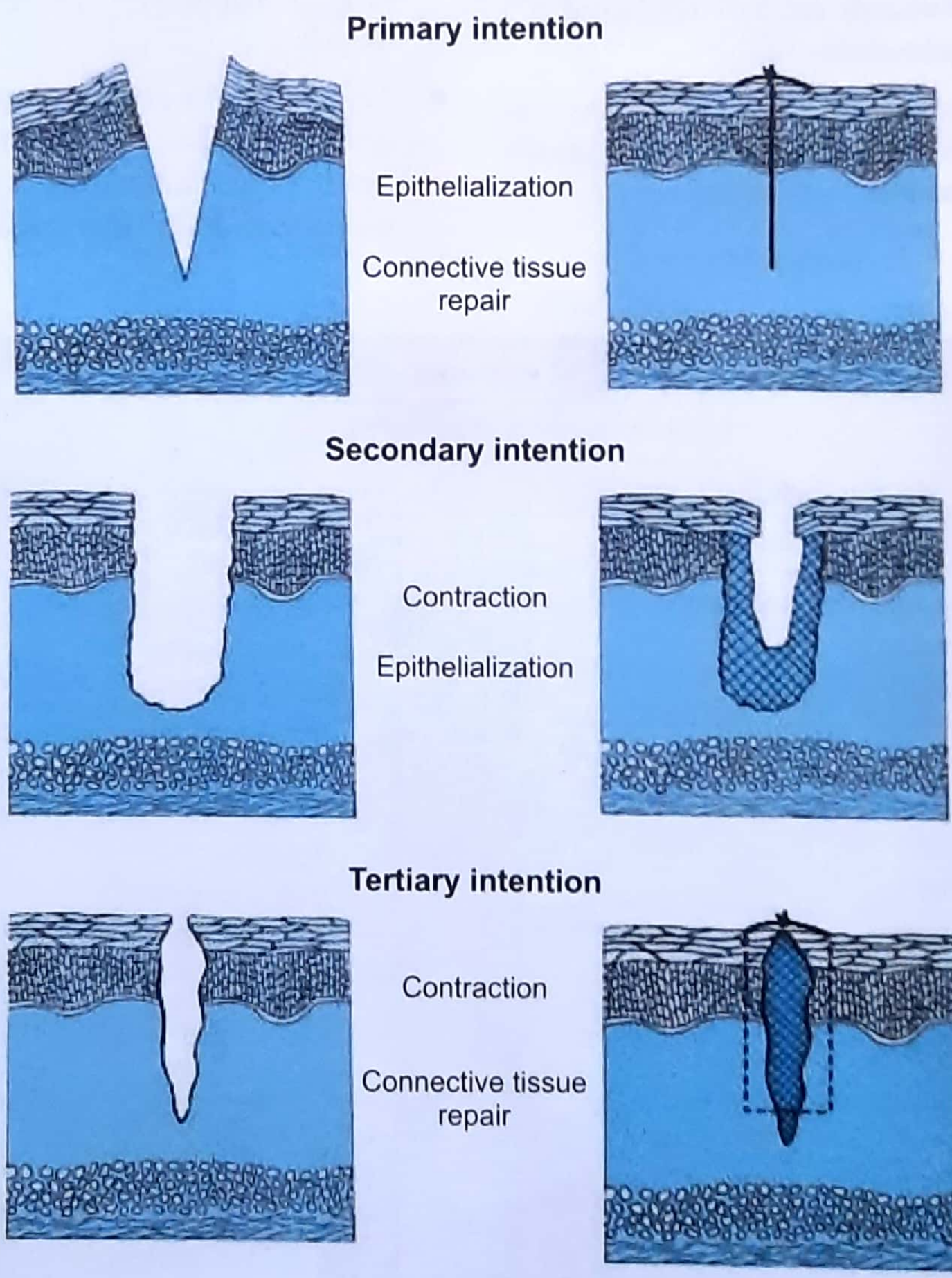

Figure 1.3: Different clinical approaches to the closure and healing of acute wounds.

- All non viable tissue should be debrided. The viability of a tissue can be assessed by 4 'C'. (Please see key box 1.1)

2. **Antibiotics** are used if wound is infected.
3. **Dressing:** The main purpose of dressing in to provide the ideal environment for wound healing. Tissue suturing glue contains cyanoacrylate.

Please read keybox 1.2 and 1.3.

****

TYPES OF WOUND CLOSURE

1. Primary or I[st] Intention Closures (NEET)

In primary closure; wounds are *immediately sealed after injury* with simple suturing or clips or adhesive materials or skin graft placement. Primary closure of wound should be done with in 6-9 hours of injury. (KERELA 87)

2. Spontaneous or Secondary Intention Closures

Here, *no active intent to seal (close) the wound is done*. Generally this type of closure is represented by highly contaminated wound, which will close by reepithelialization and contraction of wound by itself over a period of time. This occurs when there is sufficient loss of tissue and wound edges are apart, viz; deep burn, bed sore, chronic ulcer. After more granulation tissue & fibrosis is seen.

3. Delayed primary or Tertiary intention Closures

Here, a **contaminated wound is initially treated with repeated debridement (means unleast or cut open)** (NEET) **and dressings with topical or even systemic antibiotics for several days to control infection.** (NEET) Once it is assessed that wound is healthy and is ready for closure, surgical intervention such as suturing, skin grafting or flap design is performed.

Please see figure 1.3

****

PHASES OF WOUND HEALING

Normal wound follows a predictable pattern that can be divided into overlapping phases as-

1. Inflammatory (or reactive) phase
2. Proliferative (or regenerative or reparative) phase

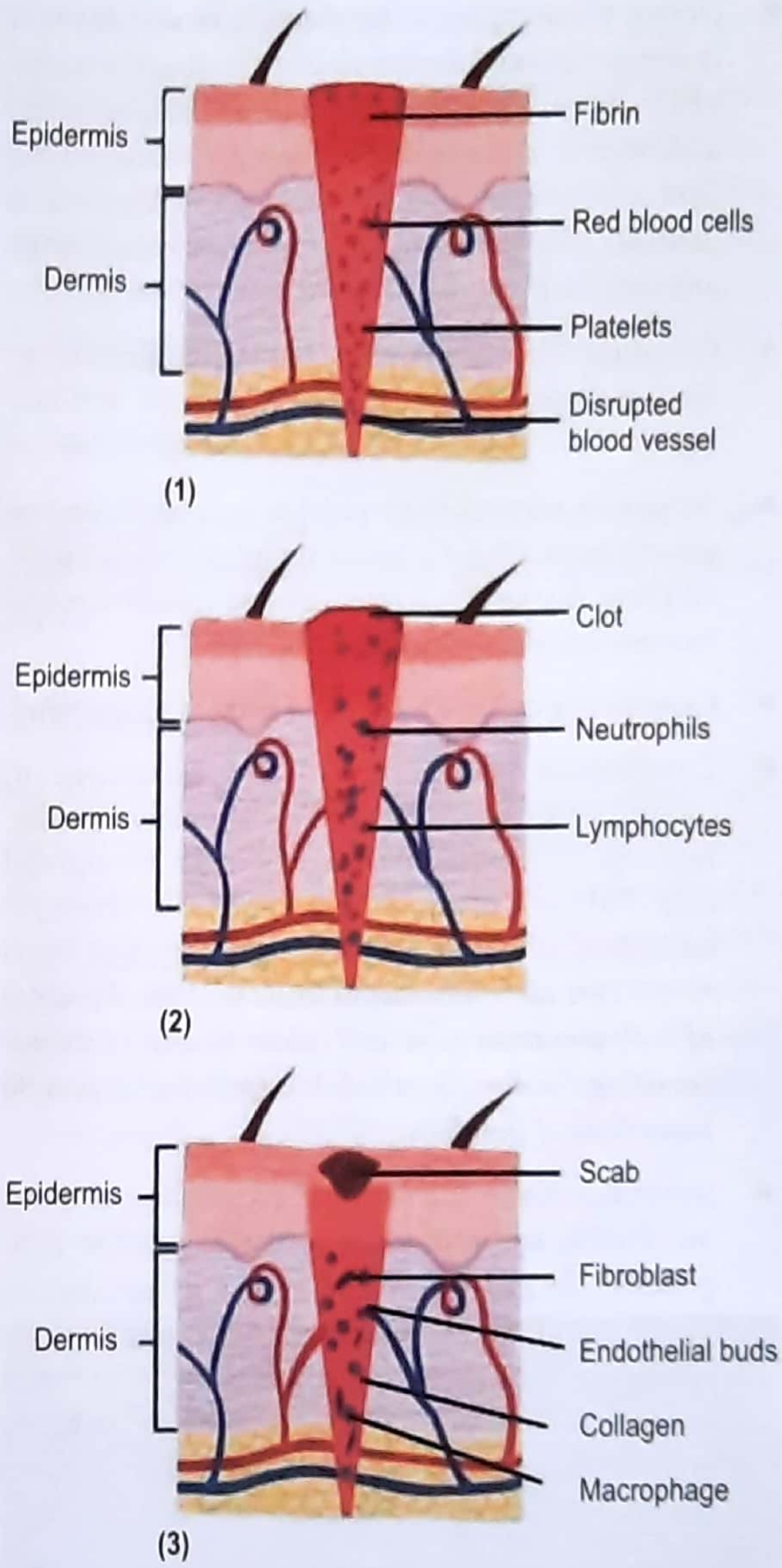

Figure 1.4: The phases of wound healing viewed histologically

3. Maturational (or remodelling) phase

1. Inflammatory (or reactive) Phase

- This is immediate response to injury and is aimed to limit the amount of damage and in preventing further injury. During this phase, hemostasis and inflammation occurs. This phase is characterized by increase vascular permeability, migration of cells into the wound by chemotaxis, secretion of cytokines and growth factors into the wound and activation of the migrating cells.

- During tissue injury, damage to blood vessels result in direct exposure of subendothelial collagen to platelets, leading to platelet aggregation, degranulation and activation of the coagulation pathway. *Initial Intense local vasoconstriction of arterioles and capillaries (due to release of catecholamines) is followed by vasodilation and increased vascular permeability.* (VERY IMP. POINT)
- Cessation of hemorrhage is aided by plugging of capillary endothelium (as exposed to type IV & V collagen)
- Substances released from platelets eg; platelet derived growth factor (PDGF), transforming growth factor (TGF) beta, fibronectin, serotonin cause vasodilation and increase vascular permeability, (IMP. POINT)
- Coagulating cascade form a clot and seals the wound.
- Complement factors eg; C_{5a}, and leukotriene b_4 cause chemotaxis along with inflammatory mediators (eg; IL-1, TNF-alfa) derived from endothelial cells (PMN) or neutrophils to migrate in extracellular matrix, with in few hours *peaking at 24-48 hours* (PGME). ***This all combination leads to clinical finding of inflammation that is:- rubor (redness), tumor (swelling), color (heat), dolar (pain) and functio laesa (loss of function)*** IMP POINT
- Integrin molecules; a family of cell surface receptors on PMNs, are responsible for cell migration (diapedesis). As *PMNs*, do not survive longer than 24 hours, so after 24-48 hours predominance of cells in wound shift to mononuclear cells* (MANY PGME). So PMNs are not essential in wound healing, on the contrary neutrophil factors have been implicated in delaying the epithelial closure of wound.

  (*PMN= Polymorphonuclear cells = Neutrophils)
- **Macrophages are the cell that is truly central to wound healing**(MANY PGME). Activated integrin expression in monocytes transform them in wound macrophages, which achieve significant numbers in the wound by *48 to 96 hour* post injury and remain present until wound healing is complete. Macrophages secretes numerous cytokines (eg; IL-1, TNF) Growth factors (eg; Fibroblast growth factors), Proteinases (eg; matrix metalloproteinase MMP) and have their role in angiogenesis and matrix deposition.
- T-lymphocyte, another population of inflammatory cells appears in wound at around 5th day with peak around 7th day of post injury and bridge the transition from inflammatory to the proliferative phase of healing.

(B-lymphocyte appear to have no role in wound healing)(MANY PGME)

- Lymphocytes exert most of their effects on fibroblasts by producing stimulatory cytokines (eg; IL-2), and depletion of most wound T-lymphocytes decreases wound strength and it's collagen content.

2. Proliferative Phase

It is IInd phase of wound healing, roughly spans from 4-12 day. This stage is characterized by the formation of granulation tissue. In this phase, repair of wound occurs by angiogenesis, fibroplasia and epithelization.

(i) Angiogenesis

This is new blood vessel formation due to migration and proliferation of endothelial cells promoted by cytokines and growth factors (eg. Fibroblast growth factor, PDGF, TGF- beta, TNF alfa), and especially by vascular endothelial cell growth factor (VEGF) from keratinocytes.

(ii) Fibroplasia

After injury, the normally quienscent and sparse fibroblast are chemoattracted to the inflammatory site, where they divide and becomes activated to carry out their primary function of matrix synthesis in form of collagen deposition and remodeling (mediated mainly by cytokines and growth factors). *Collagen synthesis rate declines after 4 weeks* (PGI 81) eventually balancing the rate of collagen destruction by collagenase. At this point the wound enters a phase of collagen maturation, which continues for months to even years.

(iii) Epithelization

This begins within hours after injury. Initially by clot sealing and then by epithelial cell migration across the defect. This is by keratinocytes located at the basal layer of residual epidermis by migration, proliferation, differentiation and stratification.

3. Maturational Phase

- This begins during fibroplastic phase and is characterized by recognitions of previously synthesized collagen. So net wound collagen content is the result

of a balance between collagenolysis (by MMP) and collagen synthesis, with net shift toward collagen synthesis and eventually reestablishment of *extra cellular matrix composed of relatively acellular collagen rich scar.

- The deposition of matrix at wound site follows a characteristics pattern: *Fibronectin and collagen type III make early matrix* (MANY PGME), Glycosaminoglycans (G-AG) and proteogylcans represent the next significant matrix component; and *collagen type I* is the *final matrix* (MANY PGME).
- *This scar remodelling continue for many months (6-12 months) post injury* (PGME), gradually resulting in a mature, avascular and acellular scar, but **mechanical strength of the scar is *never* achieved to that of normal tissue**. (NEET, PGI 88) (Figure 1.4)

Extracellular Matrix

Made up of collagen and proteoglycans which form "gel like" ground substance that make up granulation tissue along with elastin fibres.

****

FACTORS AFFECTING WOUND HEALING

(PGME MANY TIMES)

1. Aging

Elderly patients are more likely to have surgical wound rupture and delayed healing compared with young. With aging collagen undergoes depressed synthesis due to upregulation of MMP_2, decreased reepithelization and angiogenesis with decrease levels of multiple growth factors. Due to decreased collagen synthesis in *old people, they have best scar among all age group* (PGI).

NOTE: Scarring is primarily due to collagen content in wound.

2. Infection

Probably *most common cause of healing delay is wound infection*. If the bacterial count in the wound exceeds 10^5 organisms per gram of tissue or if beta-hemolytic streptococci are present, the wound will not heal by any means including flap closure, skin graft or primary suture. *Bacteria prolong the inflammatory phase* and interfere with epithelization, contraction and collagen deposition. (PGME)

3. Hypoxia and anemia

Molecular oxygen is essential for collagen synthesis, Ischemia can be caused by atherosclerosis, cardiac failure or simple wound tension preventing localized perfusion. Mild to moderate anemia does not appear to adversely affect wound oxygen tension and collagen synthesis, unless the hematocrit falls below 15%. (Normal = 35-45%)

4. Ionizing radiation

Ionizing radiation causes endothelial cell injury with endarteritis resulting in atrophy, fibrosis & delayed tissue repair.

5. Diabetes

Diabetes mellitus *impairs wound healing at all stages*. These patients with associated neuropathy and atherosclerosis are prone to develop tissue ischemia and infection. Careful pre-operative correction of blood sugar levels improves the outcome of wounds in diabetic patients. Increasing inspired O_2 tension, proper antibiotics and correction of other coexisting metabolic abnormalities can result in improved wound healing.

KEY BOX 1.4

Factors that affect Wound Healing in Surgical Practice

Local	General	
• Blood supply	• Old age	• Malnutrition
• Denervation	• Anemia	• Obesity
• Hematoma	• Anti inflammatory drugs	• Temperature
• Infection	• Cytotoxic drugs	• Trauma
• Mechanical stress	• Hormones	• Vitamin, mineral deficiency
• Surgical	• Systemic infection (Diabetes)	
• Suture material	• Jaundice	• Uremia
• Type of tissue	• Malignancy	• Hypovolemia

6. Malnutrition *(AI 93)*

Protein catabolism can result in delay in wound healing, (esp. Arginine deficiency). Vitamin deficiencies affect wound healing mainly due to their effect as cofactors. Delayed healing can occur in as few as 3 months of vitamin C deprivation. Deficiency of vitamin A, impedes monocyte activation and cellular adhesion. Vitamin A increases the inflammatory response in wound healing and it directly increases collagen production and epidermal growth factor receptors. *Vitamin K deficiency causes decrease synthesis of prothrombin and factors VII, IX and X.* ***(MANY PGME)***.

In minerals, *Zinc deficiency results in delayed wound healing*, though it is rare except in large burns, severe multiple trauma, hepatic cirrhosis. *Zinc is a necessary cofactor for RNA polymerase and DNA polymerase* ***(MANY PGME)***

7. Drugs

Large doses or chronic use or glucocorticoids impair *fibroblasts phase* of wound healing. Steroid used after the first 3 to 4 days post injury do no affect wound healing, as severely as when they are used in the immediate post operative period.

All chemotherapeutic antimetabolite drugs adversely affect wound healing by inhibiting early cell proliferation and wound DNA and protein synthesis, all of which are critical to successful tissue repair.

****

Figure 1.5: NPWT

Negative Pressure Wound Therapy/Vaccum Assisted Closure (NPWT)

NPWT promotes wound healing by applying a vaccum through special sealed dressing. The continued vaccum draws out fluid from the wound & increases blood flow to area. Dressing is changed 2 to 3 times per week. The pressure applied is -125 mmHg. (Figure 1.5)

Contraindication to NPWT

- Malignancy in wound
- Untreated osteomyelitis
- Non enteric or unexplored fistula fistula
- Necrotic tissue with eschar

****

SOME CHRONIC WOUNDS

Venous Stasis Ulcer (Varicose Ulcer)

These are due to venous stasis and back pressure. Venous stasis occurs due to incompetence of either superficial or deep venous system. Chronic venous ulcers are usually due to incompetence of deep venous system and are commonly painless. Static ulcer tend to occur at the sites of incompetent perforators, the most common being ***above the medial malleolus*** ***(NEET, PGME)***. It is due to adherence of neutrophils to capillary endothelium causing plugging with decrease dermal blood flow. It leads to venous hypertension and capillary damage with extravasation of hemoglobin, which results in *pigmentation (brownish) of skin combined with loss of subcutaneous fats*. See figure 1.6

The wound is *usually shallow with Irregular margin and pigmented surrounding skin* ***(MANY PGME)***. The main treatment is compression therapy usually with rigid, zinc oxide impregnated non-elastic bandage, along with local wound care.

Pressure or Decubitus Ulcer

It is trophic ulcer.*(NEET)* These are chronic wounds following tissue necrosis from pressure. They occur over bony prominences, and arise when there is unrelieved pressure in soft tissues overlying bone; such that the external pressure exceeds capillary perfusion pressure and ischemic necrosis occurs. It's formation is accelerated in presence of friction, shearing forces and moisture.

Other contributory factors include hypotension, peripheral vascular disease, immobility, altered mental status, chronic conditions and altered nutritional status as occur in paraplegic patients. (See figure 1.6)

Prevention is better than cure, but when sore develops, identification of cause is important and if cause is removed, the ulcer will heal by secondary intension. Care of ulcer include debridement of all necrotic tissue, relieve of pressure, nutritional support, maintenance of favorable wound environment.

Pressure ulcer staging -

Stage I: Erythema of intact skin.

State II: Loss of epidermis & dermis.

State III: Loss of structures from epidermis through SC tissue & into fascia.

State IV: Full thickness less involving muscle & bone.

Management of pressure ulcer.

The basic components of pressure ulcer management are reducing or relieving pressure on the skin, debriding necrotic tissue, cleansing the wound, managing bacterial load and colonization, and selecting a wound dressing.

The pressure-reducing devices used in preventive care also apply to treatment. Static devices are useful in a patient who can change positions independently. A low–air-loss or air-fluidized bed may be necessary for patients with multiple large ulcers or a nonhealing ulcer, after flap surgeries, or when static devices are not effective. No one device is preferred.

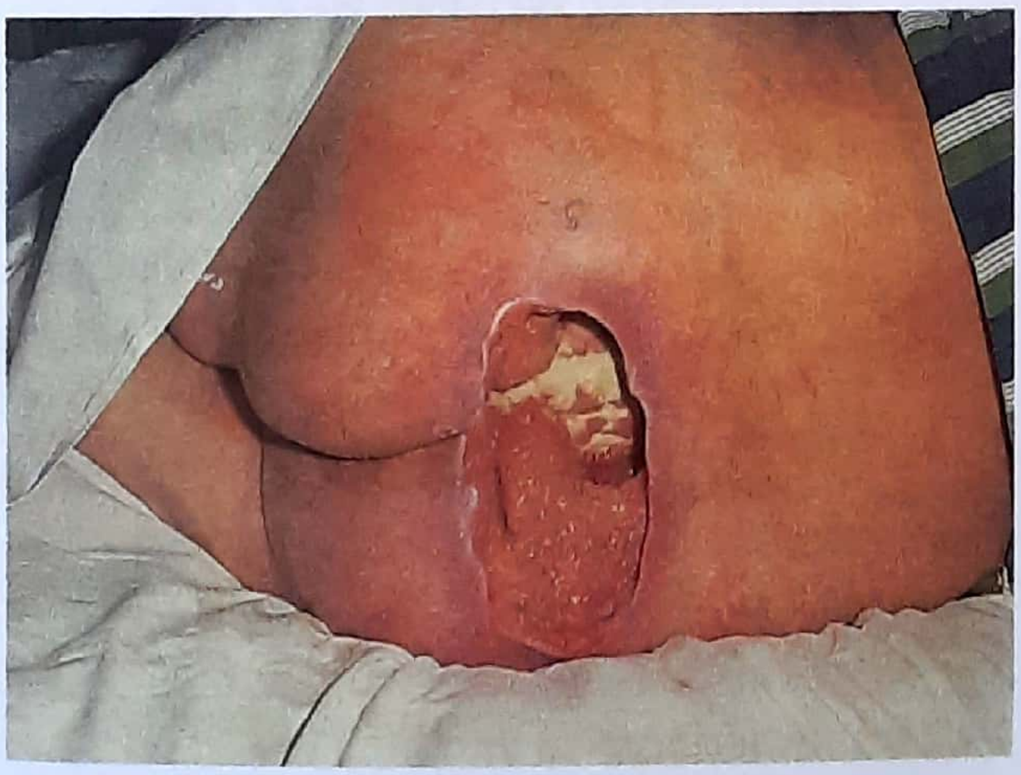

Figure 1.6: Decubitus ulcer

Pain assessment should be completed, especially during repositioning, dressing changes, and debridement. Patients at the highest risk of pressure ulcers may not have full sensation or may require alternate pain assessment tools to aid in communication. The goal is to eliminate pain by covering the wound, adjusting pressure-reducing surfaces, repositioning the patient, and providing topical or systemic analgesia. Small randomized controlled trials show that topical opioid (diamorphine gel; not available in the United States) and nonopioid (lidocaine/prilocaine [EMLA]) preparations reduce pain during dressing changes and debridement.

Necrotic tissue promotes bacterial growth and impairs wound healing, and it should be debrided until eschar is removed and granulation tissue is present. Debridement, however, is not recommended for heal ulcers that have stable, dry eschar without edema, erythema, fluctuance, or drainage. Debridement methods include sharp, mechanical, enzymatic, and autolytic. Sharp debridement using a sterile scalpel or scissors may be performed at bedside, although more extensive debridement should be performed in the operating room. Sharp debridement is needed if infection occurs or to remove thick and extensive eschar. Healing after sharp debridement requires adequate vascularization; thus, vascular assessment for lower extremity ulcers is recommended. Anticoagulation is a relative contraindication for sharp debridement.

Mechanical debridement includes wet-to-dry dressings, hydrotherapy, wound irrigation, and whirlpool bath debridement. Wet-to-dry dressings adhere to devitalized tissue, which is removed with dressing changes (dry dressings should not be moistened before removal). However, viable tissue may also be removed and the process may be painful. Hydrotherapy via whirlpool bath debridement or irrigation may loosen debris. Enzymatic debridement is useful in the long-term care of patients who cannot tolerate sharp debridement; however, it takes longer to be effective and should not be used when infection is present.

Wounds should be cleansed initially and with each dressing change. Use of a 35-mL syringe and 19-gauge angiocatheter provides a degree of force that is effective yet safe; use of normal saline is preferred. Wound cleansing with antiseptic agents (e.g., povidone-iodine [Betadine], hydrogen peroxide, acetic acid) should be avoided because they destroy granulation tissue.

KEY BOX 1.5

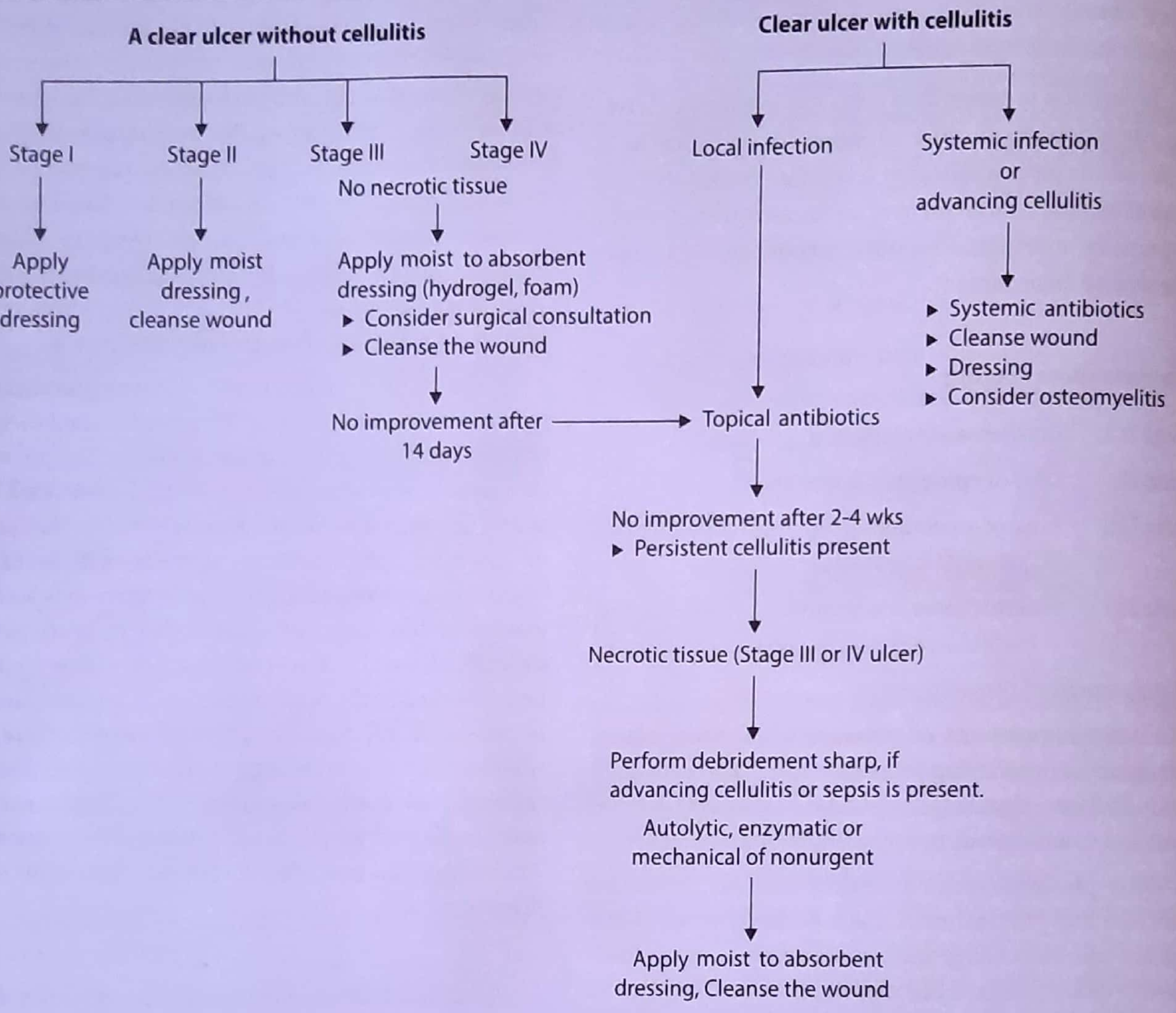

→ **Cordinal rule for dressing of pressure ulcer is keep ulcer tissue most and surrounding intact tissue dry.**

Dressings that maintain a moist wound environment facilitate healing and can be used for autolytic debridement.28 Synthetic dressings reduce caregiver time, cause less discomfort, and potentially provide more consistent moisture. These dressings include transparent films, hydrogels, alginates, foams, and hydrocolloids. Transparent films effectively retain moisture, and may be used alone for partial-thickness ulcers or combined with hydrogels or hydrocolloids for full-thickness wounds. Hydrogels can be used for deep wounds with light exudate. Alginates and foams are highly absorbent and are useful for wounds with moderate to heavy exudate. Hydrocolloids retain moisture and are useful for promoting autolytic debridement.

****

ABNORMAL WOUND HEALING

If wound insult is greater, (ie; amount of lost tissue, amount of foreign material or bacterial inoculation), longer is the reparative process; and greater will be the amount of residual scar of the healed wound.

Hypertrophic Scar and Keloids

These are **example of proliferative scar**. These are characterized by excessive collagen deposition versus collagen degradation.

Now lets discuss them one by one:

Figure 1.7: Hypertrophic lkaparotmy scar

Figure 1.8: Keloid scar

NOTE: Presternal area is most common site

Hypertrophic Scar

These are raised, more cellular, more vascular scars that ***remains within the confines of the original wound*** *(MANY PGME)* and **frequently regress spontaneously with time.** (See figure 1.7 and 1.8)

- Clinically they are red, raised, itchy and tender, more common in children and where skin tension is high eg.; at tip of shoulder.
- The risk of developing a hypertrophic scar can be minimized by ensuring quite primary healing. Massage of the scar with moisturizing cream or application of pressure to the remodelling scar can accelerate the natural process of maturation and avoid hypertrophic scarring.
- These scar *usually develop within 4 weeks to 3 months after trauma,* *(IMP. POINT)*

Histologically

Both demonstrate increased thickness of epidermis with an abundance of collagen and glycoprotein deposition

Keloids

These are the scars that ***grow <u>beyond</u> the borders of the original wounds*** and *<u>tend to occur 3 months to years after the initial insult</u>,* *(IMP. POINT)*

- Even minor injury can result in large keloid lesios. These scars *<u>rarely regress with time</u>*. The *<u>most common site for keloid formation are **presternal area** shoulder and back</u>* *(AIIMS 93)*. (Please see Figure 1.7; 1.8, 1.9, 1.10 and 1.11)

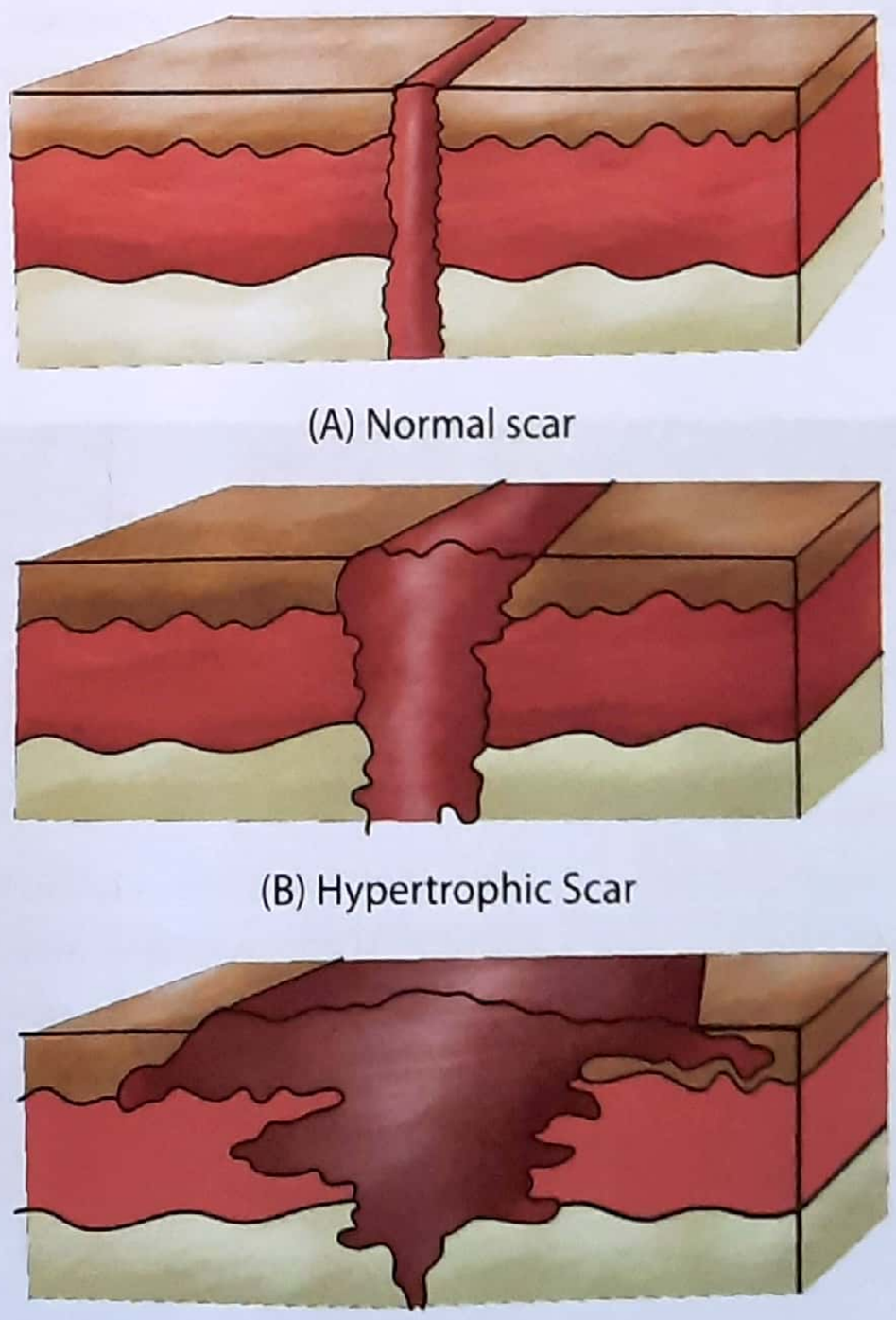

(A) Normal scar

(B) Hypertrophic Scar

(C) Keloid

Figure 1.9: Hypertrophic laparotomy scar

Figure 1.10: Hypertrophic scar on thigh

Figure 1.11: Extensive Keloid

(PGME) Keloid and hypertrophic scars have stretched collagen bundles aligned in the **same plane as the epidermis**, as opposed to *normal scar tissue where the collagen bundles are randomly arrayed and relaxed.*

Treatment

Treatment goal include restoration of function to the area, relief of symptoms and prevention of recurrence. **Excision alone of keloid** (NEET) lead to high recurrence rate (45-100%) (PGME). There are fewer recurrences, when **surgical excision** (NEET) is combined with other modalities such as **1st line treatment intralesional corticosteroid injection**, (NEET) topical application of silicone sheet or pressure garment. Surgery is only recommended for debulking large lesion or as second line therapy when other modalities fail.

Surgical excision is planned in a such way that incision line does not extend beyond the margins of Keloid scar.

KEY BOX 1.6

Characteristics of keloids and hypertrophic scars

	KELOID	HYPERTROPHIC SCAR
Incidence	Rare	Frequent
Ethnic groups	African American, Asian, Hispanic	No predilection
Prior injury	Yes	Yes
Site predilection	Neck, chest, ear lobes, shoulders, upper back	Anywhere
Genetics	Autosomal dominant with incomplete penetration	No
Timing	Symptom-free interval; may appear years after injury	4-6 weeks post injury
Symptoms	Pain, pruritus, hyperesthesia, growth beyond wound margins	Raised, some pruritus, respects wound confines
Regression	No	Frequent spontaneous
Contracture	Rare	Frequent
Histology	Hypocellular, thick, wavy collagen fibers in random orientation	Parallel orientation of collagen fibers

Role of Intra lesional steroid (Triamcinolone) (AIIMS 94)

It decreases fibroblasts proliferation, collagen and GAG synthesis and inflammatory process. It is recommended as 1st line treatment for keloid and 2nd line treatment for hypertrophic scar, if topical therapies fail. Steroid may soften, flatten and give symptomatic relief to keloid but they cannot make lesion disappear. **External compression** is used to treat hypertrophic scar especially after burn. Topical **retinoids** are also used in both type of scar treatment, with reported response rate of 50% to 100%.

Before concluding this topic kindly go through key box 1.6.

****

Sample Questions for Prof Examination

1. What is "healing by primary intention"? List the factors affecting would healing.
2. Write short notes on hypertrophic scar. How will differentiate it with Keloid.

2 SHOCK

Contents

- Stages of shock
- Types of shock
- Management of shock

Shock is defined as <u>poor tissue perfusion</u>* with inadequate delivery of oxygen and nutrients to maintain normal tissue and cellular function, leading to impaired cellular metabolism, irrespective of cause. *(UP 99)*

* **Perfusion is** supply to an organ or tissue, with nutrients and oxygen, through blood. The **basis of shock** is **poor tissue perfusion**

The cellular injury caused by inadequate delivery also include the production and release of inflammatory mediators, that further compromise perfusion though various change within microvasculature causing maldistribution of blood flow. This lead to a vicious cycle and ultimately causes multiple organ failure; and if this progression is not interrupted, may leads to the death of the patients.

KEY POINT: Simply, the shock is imbalance between substrate delivery (supply) and cellular substrate requirements (demand).

The magnitude of the physiological response is proportional to both the degree and the duration of the shock. While the quantitative nature of the physiologic response, in shock will vary with the etiology of shock, the qualitative nature of the response to shock is similar with common pathways in all types of shock. The initial insult, whether hemorrhage, injury or infection initiates both; neuroendocrine and inflammatory mediator response.

****

STAGES OF SHOCK

Shock is a progressive disorder, and if uncorrected leads to death. Unless the insult is massive and rapidly lethal (e.g. massive hemorrhage from a ruptured aortic aneurysm, pelvic bone fracture) shock tends to evolve through three general phase with sequential pathophysiological and clinical events in progression. These are:

STAGE I

Initial Non Progressive or Compensated phase of Shock

Here, **reflex compensatory mechanism through Neuroendocrine response are activated by release of Norepinephrine**, and perfusion of vital organs are maintained. The *goal here is to maintain perfusion to vital organs eg: heart, brain at the expense of other tissue; especially muscle, skin and GIT.* *(VERY IMP. POINT)*

STAGE II

Progressive Stage or Decompensation Phase of Shock

This is associated with continuous hypoperfusion and onset of worsening circulatory and metabolic imbalances, including acidosis.

STAGE III

Irreversible stage of shock

This stage sets in after the body has incurred cellular and tissue injury; so severe that even if the hemodynamic defects are corrected, survival is not possible.

****

TYPES OF SHOCK

1. **Hypovolemic Shock**
2. **Traumatic Shock**
3. **Cardiogenic Shock**
4. **Septic Shock**
5. **Neurogenic Shock**
6. **Hypoadrenal Shock**
7. **Obstructive Shock**
8. **Anaphylactic Shock**
9. **Vasovagal Shock**

Now let us discuss them one by one:-

1. Hypovolemic Shock

This is **most common type of shock (in surgical pracctice as well)**. This is due to loss of intra vascular fluid volume by hemorrhage, dehydration, vomiting and diarrhea. ***Mild Hypovolemia*** (< 20% of blood volume loss) only generates mild tachycardia. Physiological responses maintain systemic arterial pressure (hence compensated shock). In ***moderate hypovolemia*** (~20%-40% of blood volume loss); the patients becomes increasingly anxious and tachycardia is present, although normal B.P. may be maintained in supine position however postural hypotension and tachycardia may be significant (decompensated progressive shock). In ***Severe hypovolemia*** (> 40% of blood volume loss) all the classical signs of shock appear, but perfusion to the central nervous system (brain) is well maintained until shock becomes irreversible. Hence decrease mental status or agitation is an ominous (very bad) clinical sign. This progression can be insidious or extremely rapid, ultimately causing cardiovascular collapse. So a very narrow time frame separates the derangements found in severe shock that can be reversed with aggressive resuscitation from those of progressive decompensation and irreversible cell death.

- Most patients who loose <25% of blood volume → systolic B.P. is > 110 mmHg, Whose Blood loss of 25-33% of blood volume → systolic B.P. is approximately 100 mmHg.
- When loss > 33% of blood volume → systolic BP < 100 mm Hg.
- Clinical shock is usually accompanied by hypotension (ie; a mean arterial pressure <60 mm Hg) in previously normotensive person.
- *Tachycardia is not a reliable indicator of significant hemorrhage* (PGME).
- Please see key boxes 2-1 & 2-2.

2. Traumatic Shock

This is primarily due to hypovolemia due to bleeding, either externally (open wounds), Internally (in body cavities) or ruptured organs (eg; liver, spleen) or bone fractures. But even when hemorrhage has been controlled, patients can continue to suffer loss of plasma volume in interstitium of injured tissue, as this is caused by injury induced inflammatory responses with secondary mi-

KEY BOX 2.1

Mild (20% Blood volume loss)	Moderate (20-40% Blood volume loss)	Severe (>40% Blood volume loss)
• Cool extremities	• Same, Plus	• Same, Plus
• Increased capillary refill time	• Tachycardia	• Hemodynamic instability
• Diaphoresis (Profuse sweating)	• Tachypnea	• Marked tachycardia
• Collapsed Veins	• Oliguria	• Hypotension
• Anxiety	• Postural changes of blood pressure	• Mental states deterioration (Coma)

KEY BOX: 2.2				
CLINICAL ASSESSMENT OF HEMORRHAGE				
PARAMETERS	**I**	**II**	**III**	**IV**
Blood loss (mL)	Up to 750	750-1500	1500-2000	>2000
Blood loss (% blood volume)	Up to 15	15-30	30-40	>40
Pulse rate (per minute)	<100	100-120	120-140	>140
Blood pressure	Normal	Normal	Decreased	Decreased
Pulse pressure (mm Hg)	Normal or increased	Decreased	Decreased	Decreased
Respiratory rate (per minute)	14-20	20-30	30-40	>35
Urine output (ml/hour)	>30	20-30	5-15	Negligible
Central nervous system/mental status	Slightly anxious	Mildly anxious	Anxious, confused	Confused, lethargic

crocirculation injury. This differentiate traumatic shock from ordinary hypovolemic shock. Trauma to heart may itself cause pump failure, leading to shock.

3. Cardiogenic Shock

Cardiogenic Shock is defined clinically as circulatory pump failure leading to diminished forward flow of blood from heart and subsequent tissue hypoxia, *in the setting of adequate intravascular volume.*

- Most common cause is acute extensive myocardial infaraction (when >50% of the wall of left ventricle is damaged)
- Mortality rate for cardiogenic shock is 50-80%.
- Cardiogenic shock complicates 5-10% of acute MI.
- Pathophysiology involves vicious cycle of myocardial Ischemia → Myocardial dysfunction → more ischemia of ventricles → pump failure & decrease stroke volume
- *Hemodynamic criteria*
  - Systemic BP < 90 mm Hg for at least 30 minutes.
  - Decrease Cardiac index (<2.2 lt/min/m^2)
  - Increase Pulmonary artery wedge pressure (>15 mm Hg). [normal value; 4-8 mm Hg]
- Cardiac shock can be caused by direct injury to heart including profound myocardial contusion, blunt cardiac valvular injury or direct myocardial damage.

4. Vasodilatory Shock (Septic Shock)

Vasodilatory shock is characterized by both peripheral vasodilation with resultant hypotension and resistance to treatment with vasopressors. Plasma catecholamine levels are increased, renin angiotensin system is activated in Vasodilatory shock.

Causes of Vasodialatory shock

1. Septic shock (most common)
2. Hypoxic lactic acidosis
3. Carbon monoxide poisoning
4. Decompensated and irreversible hemorrhagic shock
5. Terminal cardiogenic shock.

- Vasodilatory shock presents final pathway for profound and prolonged shock of any etiology.
- The mortality for severe septic shock is 50-70%, chiefly as a result of profound and prolonged hypotension, refractory to catecholamines therapy.
- Gram positive cocci, gram negative bacilli, fungal infection can produce septic shock, as this shock is by product of the body's response to these type of invasive and severe localized infection.

Pathophysiology

The systemic infection and released toxins (eg. endotoxins & exotoxin), which tend to stimulate immune system and different type of cells viz; endothelial cells and platelets, this whole cascade causes;

- Increased inflammatory mediators (eg; IL, TNF, cytokines) leading to systemic inflammatory response.
- There occurs increase in procoagulant activity.
- Increase microvascular blood flow by increase NO synthesis (increase arteriolar vasodilatations)
- Increased capillary permeability with fluid loss of intravascular compartment.
- When this response is overly exuberant or becomes systemic rather than localized, manifestations of sepsis become evident, *(IMP. POINT)*
- The hemodynamic changes in septic shock passes through *two characteristics phases;*

(i) Early or hyperdynamic (warm) shock

In this, patient has normal or increased cardiac output with tachycardia. Systemic vascular resistance is reduced while pulmonary vascular resistance is elevated. The extremities are usually warm & dry.

(ii) Late or Hypodynamic (cold) Shock

As sepsis progresses, generalized capillary leakage and other fluid losses lead to severe hypovolemia with reduced cardiac output, tachycardia and vasoconstriction.

The systemic infection induces cardiac depression, pulmonary hypertension → edema and hypoxia.

Patient becomes cold, clammy*, drowsy, tachypneic, febrile and diaphoretic*. Renal failure and hypothermia develops with much increase in serum lactate.

Clammy, means wet and damp. Diaphoretic = Profuse sweating.

5. Neurogenic Shock

Neurogenic shock refers to diminished tissue perfusion as a result of loss of vasomotor tone by sympathetic nervous system to peripheral arterial beds; producing dilatation of resistance arterioles and capacitance vein (leading to relative hypovolemia and hypotension). It is usually secondary to spinal cord injury (traumatic), from vertebral body fracture of cervical or high thoracic region or pharmacological blockage of sympathetic inputs (spinal anesthesia). Patient presents with decrease in blood pressure associated with normal or decreased pulse rate and warm, dry extremities.

6. Hypoadrenal Shock

Hypoadrenal shock occurs in cases, in which unrecognized adrenal insufficiency (eg; prolonged high dose of steroid use, T.B.) major surgery or trauma complicates the host response to the stress. This type of shock is characterized by reduction in systemic vascular resistance, hypovolemia and reduced cardiac output.

7. Obstructive Shock

Obstructive shock occurs in tension pneumothorax or in cardiac tamponade, in which *mechanical obstruction* causes decreased compliance of heart. Tension pneumothorax obstructs venous return and cardiac tamponade obstructs blood flow to ventricles. The diagnosis is made on clinical examination for these conditions.

8. Anaphylactic Shock

Causes of anaphylactic shock are penicillin administration, serum injection, stings, bite, dextran etc. The antigen combines with IgE; on the mast cells and basophils, releasing large amounts of histamine and slow release substance of anaphylaxis. This causes bronchospasm, laryngeal edema, respiratory distress with hypoxia, massive vasodilatation, hypotension and shock. The mortality is around 10%.

9. Vasovagal Shock

This is **as a response to sudden fear or severe pain,** and the **effect varies from slight fainting fit to death.** This type of shock is known as vasovagal shock or psychogenic shock. There is sudden *pooling of blood* in the large reservoirs of vascular compartment in limb muscles and splanchnic arteriolar bed. This causes hypoxia of vital centres.

- There is a history of emotional stress, or pain of a sudden nature.
- Bradycardia and pallor, (mind bradycardia)
- Tachypnea.
- Fainting.
- Reflexes are usually intact.

Management of vasovagal shock

1. Place the patient flat or in head low position.
2. Ensure patency of airway.
3. I.V. Atropine may be needed for persistent or increasing bradycardia.

CLINICAL PRESENTATION (of shock)

- This varies with the previous level of organ function, compensatory mechanisms, severity of organ dysfunctions and the cause of shock .
- Tachycardia, tachypnea and oliguria are the hallmark. *(NIM HANS 86)*
- Cool extremities are seen in hypodynamic shock.
- With progression, blood pressure falls and frank hypotension (MAP* < 60-65 mmHg) ensues. With further progression, anuria, mottled dusky extremities and altered sensorium occurs.

  * MAP- mean arterial pressure

- Shock Index = $\frac{\text{Heart rate (HR)}}{\text{Systolic blood pressure (SBP)}}$
- **Modified shock index =** $\frac{\textbf{Heart rate (HR)}}{\textbf{Mean blood pressure (MBP)}}$ *(AIIMS Nov 17)*

Recap : Mean blood pressure = Diastolic blood pressure + 1/3 (Systolic blood pressure (SBP) - Diastolic blood pressure (DBP)

LABORATORY STUDIES

- Initial laboratory test should include complete chemistry profile with serum electotytes, creatinine, blood urea nitrogen (BUN), liver function test, calcium, magnesium and phosphate levels, prothrombin and activated partial tromboplastin time.
- Hemoglobin level varies with the type of shock. Stress of circulatory shock increase platelet count initially, but with progression thrombocytopenia occurs.
- BUN* and creatinine rarely change after the acute onset of shock, even if renal injury is present.

  (* BUN: Blood urea nitrogen).

- ABG* determines the adequacy of oxygenation and acid base status.

  (* ABG = Arterial blood gas analyzer)

- Serial serum lactate levels are used in the assessment of prognosis and levels of > $2meqL^{-1}$ represent tissue ischemia.
- A 12 lead ECG is critical for diagnosis of ischemic injury either as a primary cause of cardiogenic shock or secondary to hypotension associated with other shock. Chest radiograph is also a must. Other studies should be considered in specific conditions which may include blood, sputum and urine examination and cultures in a cases of suspected sepsis.

Invasive Hemodynamic monitoring (Central venous pressure: CVP)

- Arterial pressure catheter is a must for all patients suspected of having circulatory shock. Marked peripheral vasoconstriction may make the assessment of blood pressure by manual sphygmomanometry inaccurate. Also continuous monitoring of the rapidly changing hemodynamic status of unstable patients and access for ABG* sample is available with arterial catheter in place.
- *Central venous pressure* monitoring is not an accurate means of monitoring volume resuscitation and should be used only as a rough guide. An initially low CVP (i.e; less than 5 mm Hg) may indicate hypovolemia. So CVP monitoring is inadequate for the hemodynamic assessment of critically ill patients and also it does not accurately estimate left ventricular preload in critically ill patients.
- *Pulmonary artery wedge pressure* (PAWP)/It is an accurate reflection of left ventricular function *(PGME)* and can be used to monitor cardiac output and pulmonary edema, however both CVP and PAWP do not accurately assess tissue perfusion *(UPSC 95)*.

  * ABG-Arterial blood gas analyzer

KEY POINT: Shock is clinically best assessed by urine output *(PGI 97)* Urine output should be more than 0.5 ml/kg/hour. *(AIIMS 94, 95)*

MANAGEMENT AND THERAPY

Patients in shock should be managed in ICU with continuous ECG monitoring and close nursing support. Management of shock can be divided into specific therapy for triggering injury and general therapy of the shock syndrome.

Aims *(DELHI 09)*

The basic goal of circulatory shock therapy is the restoration of effective perfusion to vital organs and tissue before the onset of cellular injury. End points of this treatment include restoration of mental acuity, production of an adequate urine output; decrease of any signs of myocardial ischemia; and attempt at normalizing monitoring parameters including arterial blood pressure, pulmonary capillary wedge pressure, cardiac output, venous oxygen saturation and oxygen consumption. The severity, duration and underlying cause of the shock must be assessed. Prognosis is related to whether the shock state is reversible or irreversible.

A. Resuscitation

1. Airway management and mechanical ventilation

A critical first step in the treatment of shock is to ensure adequate alveolar ventilation and oxygenation. Most patients with the fully developed shock syndrome require tracheal intubation and mechanical ventilatory support, even if acute respiratory failure has not yet occurred. Improvement may occur for several reasons. Mechanical ventilation allows blood flow to be redistributed, tends to reverse lactic acidosis and supports the patient until other therapeutic measures can be effective. Tracheal intubation is also indicated, if mental status changes make airway unprotected or for inadequate respiratory compensation for metabolic acidosis. Positive pressure ventilation and PEEP may produce further hemodynamic compromise, if volume status of the patient is not maintained. PEEP may also be desirable in patient with ARDS or pulmonary edema to ensure adequate oxygenation.

2. Acid base Balance

Metabolic acidosis of the plasma may be protective is shock states and that bicarbonate administration may transiently decrease intracellular and cerebrospinal fluid P_H. The mechanism being production of CO_2 as a product of the bicarbonate buffering of hydrogen ion and the rapid diffusion of this non ionized CO_2 across cellular membranes. This paradoxical intracellular acidosis hinders brain and cardiac functions. Thus; the optimal approach in the management of lactic acidosis is to improve organ and systemic perfusion so that anaerobic metabolism is limited and the liver as well as kidney can clear the accumulated lactate.

KEY BOX 2.3	
Therapeutic Goals of shock Resuscitation	
Mean arterial pressure (MAP)	> 84 mm Hg
Central venous pressure (CVP)	>3cm H_2O
Hemoglobin (Hb)	>8g/dl
Pulmonary capillary wedge pressure (PCWP)	>9 mmHg
Cardiac index (CI)	> 4.5 1/min/m^2
Heart rate (HR)	<100 beats/minute
Temperature (T)	98-101°F
Mixed venous oxygen tension	>35 mm Hg

3. Fluids

Common to all etiologies of hemodynamic instability and shock, fluid is needed to provide optimal intravascular volume to ensure adequacy of preload. Thus, it is appropriate to begin fluid administration in all. Substantial controversy exists regarding the appropriate use of crystalloid and colloid fluids for resuscitation. **Crystalloid treatment appears to be equal or more favorable to colloid with respect to mortality when shock accompanies trauma,** (NEET) where as colloid prove more favorable in nontrauma shock and neither solution is better for treatment of adult respiratory distress syndrome (ARDS) and sepsis; under these circumstances, in fact colloid is deleterious. In any event, fluid therapy forms one of the cornerstones of the resuscitation and treatment of most forms of shock, the *exception* being cardiogenic shock, where vasopressors, & anti-dysrhythmics are required to increase cardiac output.

(a) Crystalloid solution therapy

Crystalloid solutions are cheap, easy to administer and replace deficiencies from total extracellular space losses. Massive volumes of isotonic salt solutions are necessary before severe changes in plasma oncotic pressure occur. Crystalloids preserve renal function if normal hemodynamics are maintained. Myocardial efficiency may be improved after lactated ringer's solution (RL) is utilized in the treatment of hemorrhagic shock.

Disadvantages

One of the major disadvantages of the use of crystalloids for shock treatment is the large volume that must be used versus colloid solutions to enact the same effect. This is because crystalloid solutions rapidly equilibrate with the extravascular space. There also occurs a drop in the serum concentration of protein.

The use of crystalloids is also associated with a decrease in the osmotic pressure. Hematocrit also decreases.

(b) Colloid Administration

The advantages of colloid solutions versus crystalloid include an increase in total protein and serum albumin levels. This result in an increased colloid osmotic pressure. Colloid is capable of larger acute and transient increases in plasma volume per unit volume versus balanced salt solution.

Disadvantages

Colloids are costly. Their value is transient because in severe shock, there occurs an associated generalized disruption of the microvascular endothelium, hence colloids leak out of the vascular space into the interstitium, within one to two hours of their administration.

- Colloids may prolong an impending renal insult by preferentially maintaining intravascular volume at the expense of a depleted interstitial volume.

B. Specific Therapy

In Hypovolemic Shock

(a) Quick restoration of circulating volume is achieved.

(b) For this ***Crystalloid solutions*** **(Ringer's lactate) are ideal,** (NEET) where water and sodium loss is predominant and will also serve as initial treatment in hemorrhagic shock.

(c) *Colloid solutions*, for example; dextran and gelatins (Hamaccel), remain in the circulation for longer time and draw extracellular fluid in to the circulation by osmotic pressure and increased blood pressure.

(d) *Blood transfusion:* Blood, plasma or plasma substitutes should be given as indicated, as soon as they become available.

In Cardiogenic shock

The aim of treatment is to improve cardiac output.

- Intubation and mechanical ventilation is often required
- Complete bed rest
- Pain relief with morphine injection
- Thrombolytic therapy should be started, if patient has had a myocardial infarction
- Electrolyte abnormalities commonly hypokalemia and hypomagnesemia should be corrected. Significant dysrhythmias should be treated with antiarrhythmic drugs, pacing or cardioversion if necessary.
- When profound cardiac dysfunction exists, inotropic drugs (eg. dopamine, dobutamine) may be indicated to improve cardiac contractility and cardiac output.

Septic Shock

After *first line therapy of the septic patient with broad spectrum antibiotics*, intravenous fluids, and intubation (if necessary), vasopressors may be necessary to treat patients with septic shock. *Catecholamine are the vasopressors that are used more often* (PGME)

Intravenous hydrocortisone has been advocated in the treatment of septic shock, but it's benefits are debatable.

Anaphylactic shock

- Treatment is started with infusion of intravenous fluid.
- Subcutaneous administration of *adrenaline to improve cardiac output* and induce vasoconstriction. Anti-histaminics are given to block the histamine receptors. (UP 99)
- Hydrocortisone is given to prevent the release of histamine from the mast cells.
- Specific treatment, such as penicillinase is used if the anaphylactic reaction is due to penicillin.

Complication of shock

The following complication could take place:-

- Acute respiratory failure.
- Acute renal failure (ARF)
- Disseminated intravascular coagulation (DIG).
- Stress ulceration (Cushing's ulcer)
- Severely ill patients may develop systemic inflammatory response syndrome (SIRS).
- Multiple organ dysfunction syndrome (MODS) and MOF (Multiple organ failure)
- Death.

Sample Questions for Prof Examination

1. Define and classify shock. Give causes, pathophysiology and management of Septic shock.
2. Discuss the type of shock and the management of a case of hypovolemic shock.
3. Write short notes on septic shock.
4. Write short notes on anaphylactic shock.

3 Basics of I.V. Fluid Therapy

Contents

- Indication of fluid therapy
- Disadvantage
- Contraindication
- Types of I.V. fluid
  - Crystalloid
  - Colloid

FLUID THERAPY

As a principle, oral route is always preferred over I.V. route, but I.V. fluid therapy has great importance in various clinical problems with advantage of accurate, controlled and predictable way of administration with immediate response due to direct infusion in intravascular compartment. It also promptly corrects the serious fluid and electrolyte disturbances.

Indications for Fluid Therapy

1. Conditions where oral intake is not possible eg; Coma, anesthesia, surgery.
2. In case of severe vomiting and diarrhea
3. Moderate to severe dehydration and shock, where urgent and rapid fluid replacement is needed.
4. As a vehicle for various IV drug administration eg; Antibiotics, chemotherapeutic agents, vasopressor agents.
5. Total parental nutrition (TPN)
6. Hypoglycemia, where 25% dextrose is life saving.
7. Treatment of critical problems like shock, anaphylaxis, severe asthma, cardiac arrest and forced diuresis in urinary stones, poisoning etc.

Disadvantages of Fluid Therapy

1. More expensive, requires strict asepsis.
2. Possible only in hospitalized patients under skilled supervision.
3. Improper selection of type of fluid, can lead to serious problems.
4. Improper volume and rate of infusion of fluid can be life threatening, especially in infants and children.
5. Improper techniques of administration can lead to severe complication.

Contraindications of Fluid Therapy

1. I.V. fluid should be avoided, if patient is able to take oral fluid.

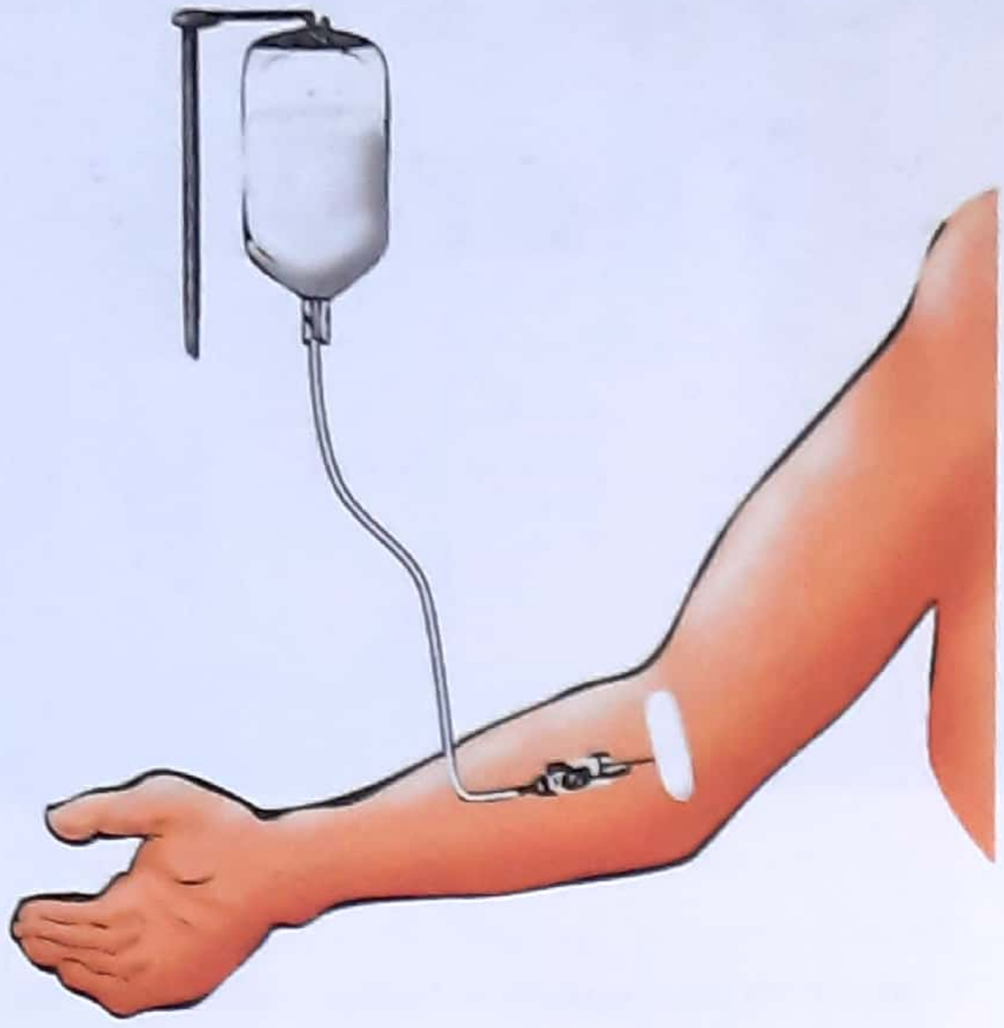

Figure 3.1: Patient on I.V. fluid therapy

2. It is preferable to avoid I.V. fluid in patient with congestive heart failure or volume overload.

Complication of IV Fluid Therapy

1. *Local*
   a. Infusion phlebitis (ie; inflammation of vein in use)
   b. Infiltration
   c. Hematoma formation

2. *Systemic*
   a. Circulation over load:- with rapid or large volume infusion especially in patients with cardiac problems.
   b. Rigors
   c. Air embolism
   d. Septicemia

3. *Other*
   a. Fluid contamination
   b. Fungus in I.V. fluid
   c. Mixing of incompatible drugs
   d. Improper technique of infusion
   e. IV set or IV catheter related problems
   f. Human error related problems

.....

TYPES OF IV FLUID

I.V. fluid can be broadly divided in (A) Crystalloids and (B) Colloids.

A. VARIOUS CRYSTALLOIDS

Isotonic crystalloids infusion, distribute uniformly throughout the extracellular compartment, so that after 1 hour, only 25% of total volume infused remains in the intra-vascular space. Various types of crystalloids are discussed below:

1. 5% Dextrose (D-5%)

Composition

One litre of fluid contains: 50 grams of Glucose

Pharmacological Basis

5%-dextrose (D-5%) corrects dehydration and supplies energy. After consumption of glucose, remaining water is distributed in all compartments of body proportionately, therefore D-5% is the best agent to correct intercellular dehydration. D-5% is selected when there is need of water but not electrolytes. It is isotonic while 0-10% is hypertonic. D-5% solution provides 170 Kcal/1.

Indications

Widely used fluid for prevention & treatment of dehydration due to inadequate water intake or excessive loss.

- Cheapest fluid to provide adequate calories to body.
- For pre and postoperative fluid replacement.
- As a vehicle for IV administration of various drugs.
- Adequate D-5% glucose infusion protects the liver against toxic substances.
- Correction of hypernatremia due to pure water loss (eg; diabetes insipidus, hypernatremia due to salt poisoning or excessive use of electrolyte solution needs infusion of 5% dextrose with fursemide to promote Na^+ excretion and correction of hypernatremia)

Contraindication

- *Cerebral edema:* Because of its hypotonic nature, D-5% dextrose aggravates cerebral edema.
- *Neurosurgical procedures:* as 5%-dextrose increases intracranial pressure, it can cause damage during neurosurgery, and must be avoided.
- *Acute ischemic stroke:* Glucose containing fluid should not be used after acute ischemic stroke, as hyperglycemia aggravates cerebral ischemic brain damage.
- *Hypovolemic shock:* 5%- dextrose is not the right fluid to select, because it does not substantially increase intravascular volume. Moreover, fast replacement by large volume of D-5% can lead to hyperglycemia which in turn cause osmotic diuresis, leading to increases urine output, so correction of dehydration will be delayed.
- *Hyponatremia and water intoxication:* By providing electrolyte free water, 5%-dextrose worsens both conditions.
- *Hypernatremia:* Fast infusion of 5%-dextrose rapidly corrects severe hypernatremia, but this correction occurs slowly in brain cells, so swelling of hypertonic brain cells occur. This may lead to serious or permanent neurological damage. Moreover, rapid infusion of dextrose induces osmotic diuresis, which may further aggravate hypernatremia. So correction of hypernatremia should be done gradually with other D-5% or with low Na^+ (sodium) containing fluids.
- *Blood transfusion:* Dextrose solution and whole blood should not be administered through the same IV line as hemolysis and clumping can occur.
- Uncontrolled *diabetes* and severe hyperglycemia.

KEY BOX 3.1

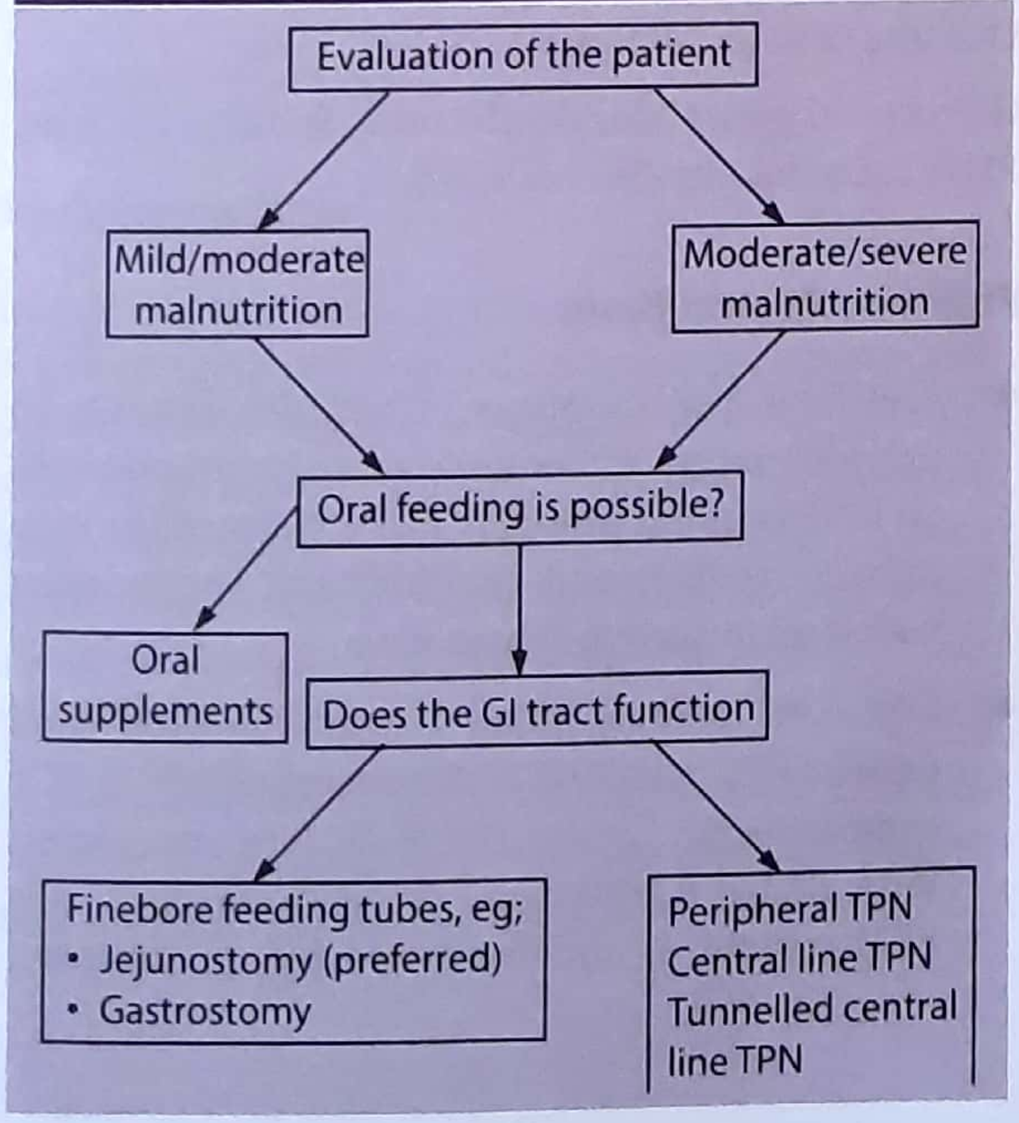

Precautions

- I.V. administration of dextrose solution (especially hypertonic) may cause local pain, vein irritation and thrombophlebitis.
- Prolonged I.V. administration of 5 %-dextrose can cause hypokalemia, hypomagnesemia and hypophosphatemia.

2. Isotonic saline (0.9% NaCl: Normal Saline NS)

Composition *(PGI 88, many PGME)*

One liter of fluid contains:

Sodium	154.0 mEq
Chloride	154.0 mEq

Pharmacological Basis

- Sodium chloride is present chiefly in extracellular fluid maintaining osmolality of ECF; so isotonic saline is used to provide major extracellular electrolytes.
- As isotonic saline increases the intravascular volume substantially, therefore isotonic saline is a very useful I.V. fluid to raise blood pressure in the patient with hypovolemic shock.

Indications

- Water and salt depletion as in diarrhea, vomiting, excessive diuresis or excessive perspiration.
- Treatment of hypovolemic shock.
- Treatment of alkalosis (eg; in vomiting) with dehydration, (because of rich chloride content in Normal Saline)
- In severe salt depletion or hyponatremia, when rapid correction of sodium is necessary.

Miscellaneous

- Initial fluid therapy in diabetic ketoacidosis.
- Treatment of hypercalcemia.
- Fluid challenge in prerenal ARE
- Irrigation for washing of body fluids.
- As a vehicle for certain drugs. It can be given safely with blood.
- In patients with renal failure, as it contain no potassium.
- Brain injury.

Contraindication

- Cautious use or avoid in hypertensive or preeclamptic patients and in patients with edema due to salt retaining conditions.
- Careful administration to very young or elderly patients.
- *Dehydration with severe hypokalemia:* with severe hypokalemia there is deficit of even ICF potassium. Infusion of isotonic saline, without additional potassium supplementation will aggravate electrolyte imbalance of ICF.
- In early post operative period, sodium should be restricted as sodium retention usually occurs.
- When infused in large volume, it may result in mild hyperchloremia.

Hypertonic saline (3% NaCl)

It is used in treatment of hyponatremia due to SIADH or water intoxication (along with furosemide), as it provides greater sodium in lesser fluid volume (Na concentration 513 mEq/13%; versus 154 mEq/1 in 0.9% NaCl).

3. Dextrose with half strength saline (0.45% DNS) (5% dextrose with half strength saline; 0.45% NaCl Solution)

Composition

One litre of fluid contains:

Sodium 77.0 mEq; Glucose 50 gm; Chloride 77.0 mEq

Pharmacological Basis

As this fluid contains 50% salt as compared to NS or DNS, it is used when there is need for calories, more water and lesser salt replacement. Requirement of water is greater in pediatric group as compared to adults. However, salt requirement is same in both groups. In pediatric group ratio of requirement of water : NaCl is about double as compared to adult group, so this is a suitable replacement fluid in pediatric patient.

Indications

1. Fluid therapy in pediatric patients.
2. Treatment of severe hypernatremia : as it corrects hypernatremia gently, it avoids cerebral edema and is therefore safe.
3. As maintenance fluid therapy.
4. Early postoperative period.

Contraindications

- Hyponatremia.
- Severe dehydration due to diarrhea and vomiting, where there is need for larger salt replacement.

4. Dextrose with Normal Saline (DNS) (5% Dextrose with 0.9 NaCl solution)

Composition

One litre of fluid contains:

Glucose- 50 gms, Chloride-154 mEq, Sodium-154 mEq, PH-4.2, Osmolarity-585 mOsm/lt.

Pharmacological Basis

- This fluid has advantages of both 5% dextrose (to provide energy) and isotonic saline (to provide salt). So DNS is useful to supply major extracellular electrolytes (sodium and chloride) and energy along with fluid to correct dehydration.
- Like 0.9% isotonic saline it rapidly corrects NaCl deficit of ECF, as DNS is distributed chiefly in ECF compartment. Unlike D-5% it does not correct intracellular dehydration. As DNS increases only ECF volume, it can be considered in treatment

of dehydration with hypovolemic shock, but like D-5%, faster infusion of large volume of DNS will lead to large glucose load (>25 gm/hr), leading to hyperglycemia induced osmotic diuresis.

Indication

- Correction of salt depletion and hypovolemia with supply of energy.
- Correction of vomiting or nasogastric aspiration induced alkalosis and hypochloremia along with supply of calories.
- Fluid compatible with blood transfusion.

Contraindications

1. *Anasarca:* Cautious use in anasarca due to cardiac, and renal disease.
2. *Hypovolemic shock:* Not preferred in severe hypovolemic shock, when rapid replacement with larger volume of fluid is required.

5. Ringer's Lactate (RL) (Hartman's solution or balanced salt solution)

Composition

One litre of fluid contains: *(TN 99, Ranchi 07)*

Sodium *(NEET)*	**130 mEq,** *(NEET)*	Potassium	4 mEq
Chloride	109 mEq	Calcium	3mEq
Bicarbonate	28mEq		

Physiological Basis

Because of high sodium concentration (130 mEq/L), Ringer's lactate rapidly expands intravascular volume, and hence it is very effective in treatment of severe hypovolemia. Ringer's lactate is a commonly used physiological fluid, *as its electrolyte content (ie. Na, K and Ca) is nearly similar to the concentration in plasma,* so even larger amount of RL can be infused rapidly without risk of electrolyte imbalance.

Sodium lactate in Ringer's lactate is metabolized in liver to bicarbonate. As RL provides bicarbonate, it is *useful in correction of metabolic acidosis.* *(Imp. point)*

Because Ringer's lactate not only supplies almost all electrolytes but also provides bicarbonate, it is very useful in many surgical conditions.

Indications

- Correction of severe hypovolemia rapidly with large fluid volume.
- For replacing fluid in *postoperative patients, burns, fractures, fluid loss due to diarrhea.* *(AI 94, pgme many times)*
- Diarrhea induced hypovolemia with hypokalemic metabolic acidosis is effectively treated with RL. RL is the fluid of choice for initial treatment of diarrhea induced dehydration even in pediatric practice.
- In diabetic ketoacidosis, RL provides glucose free water, so corrects metabolic acidosis with added advantage of supplying potassium.
- For maintaining normal ECF fluid and electrolyte balance during and after surgery.

Contraindications

- In liver diseases, severe hypoxia and shock, lactate metabolism is severely impaired. Ringer's lactate infusion can lead to lactic acidosis in such patients.
- In severe CHF lactic acidosis takes place, which is more in heart tissues. Lactate given cannot be utilized, so it may worsen the problem.
- Severe metabolic acidosis, where conversion of lactate to bicarbonate is impaired, Ringer's lactate may worsen metabolic acidosis.
- In vomiting or continuous nasogastric aspiration: Here hypovolemia is associated with metabolic alkalosis. As RL provides bicarbonate, it will worsen metabolic alkalosis and therefore is not preferred.
- *Along with blood transfusion:* Calcium in RL binds with the citrate anticoagulant in blood transfusion. This can inactivate the anticoagulant and promote the formation of clots in donor blood. *For this reason simultaneous infusion of RL and blood product in one I.V. line is contraindicated.* *(PGME)*
- The calcium in RL binds with certain drugs (ie; amphotericin, thiopental, ampicillin, doxycycline etc), and reduces their bioavailability and efficiency.

KEY BOX 3.2

Composition of common I.V. Fluids (in mEq/L)

Fluid	Na	K	Cl	Acet	Lact.	NH_4C_1	Ca	Mg	HPO_4	Citr.	MOsm/L	Dext.
ECF	142	4	103	-	27	-	5	3	-	-	280-310	-
D-5%	-	-	-	-	-	-.	-	-	-	-	278	50
0.9 NS	154	-	154	-	-	-	-	-	-	-	308	50
.045% DNS	77	-	77	-	-	-	-	-	-	-	432	-
DNS	154	-	154	-	-	-	-	-	-	-	586	50
RL	130	4	109	-	28	-	3	-	-	-	274	
Iso-G	63	17	150	-	-	70	-	-	-	-	580	50
Iso-M	40	35	40-	20	-	-	-	-	15	-	410	50
Iso-P	25	20	22	23	-	-	-	-	3	3	368	50
Iso-E	140	10	103	47	-	-	5	3		8	595	50
Dextrose saline (4% dextrose in 0.18% saline)	30	30										
Gelo-fusine	150	150										
Haemacel	145	5.1	145				<1					

6. Isolyte-'G' ('G'astric replacement fluid)

Composition

One litre of fluid contains:

Glucose	50 gms
Sodium	63 mEq
Ammonium	69 mEq
Chloride	130 mEq
Potassium	17 mEq

Physiological Basis

During vomiting or continuous nasogastric aspiration there occurs loss of gastric juice. Gastric juice contains 60 mEq/L of sodium, 17 mEq/L of potassium and 130 mEq/L of chloride along with acidic content. So *vomiting or continuous nasogastric aspiration will lead to hypochloremic hypokalemic metabolic alkalosis.* (PGME-many times)

Isolyte-G is gastric replacement solution. It provides all electrolytes lost by gastric juice, corrects alkalosis and provides calories. Ammonium ions in Isolyte-G are converted into urea and hydrogen ion by liver. Hydrogen ion thus produced is used to neutralize the alkalosis.

7. Isolyte'M' ('M'aintenance solution with 5% Dextrose)

Composition

One litre of fluid contains:

Glucose	50 gms	Chloride	38 mEq
Sodium	40 mEq	Phosphate	15 mEq
Potassium	35 mEq	Acetate	20 mEq

Pharmacological Basis

Isolyte-M is the richest source of potassium (35 mEq/L), *hence very useful to treat hypokalemia* (many PGME). However, always ensure good urine output or normal renal status before its infusion.

Proportion of electrolytes in Isolyte-M is almost similar to the maintenance requirements of the body. Additionally, it corrects acidosis and supplies energy. So this fluid fulfills the needs of body electrolytes, pH maintenance, caloric supply and water replacement, so it is ideal fluid for **M**aintenance fluid therapy & therefore, named Isolyte-**M**.

As concentration of sodium is low (40 mEq/L) in Isolyte-M, it should be avoided in hyponatremia.

Indications

1. For parenteral fluid therapy, it is ideal *maintenance fluid.*
2. To correct hypokalemia secondary to diarrhea, bilious vomiting, prolonged infusion of potassium free IV. fluids

8. Isolyte-P (mainly used in Pediatric age group)

Composition

One litre of fluid contains:

Glucose	50 gram	Chloride	22 mEq
Magnesium	3 mEq	Acetate	23 mEq
Sodium	25 mEq	Potassium	20 mEq

Pharmacological Basis

Isolyte-**P** is designed to suit maintenance fluid requirement of children (**P**ediatric age group). It provides electrolytes, maintains pH, supplies calories and replaces water deficit. As *compared to adults, children need more water but same electrolytes.* So Isolyte-P provides almost double water but same electrolytes as Isolyte-M. Isolyte-P can be used in adults, when there is chiefly water loss and only small loss of electrolytes eg; hypernatremia.

Indications

1. Chiefly used as maintenance fluid in infants and children to provide daily water and electrolytes.
2. Excessive water loss or inability to concentrate urine (ie; diabetes insipidus).

Contraindications

- *Hyponatremia:* Among all sodium containing I.V. fluids, Isolyte-P has least concentration of sodium (20 mEq/1), so it will aggravate hyponatremia in a patient with hyponatremia.
- *Renal failure:* cautiously used in renal failure due to high concentration of potassium (20 mEq/1)
- Hypovolemic shock: Isolyte-P is not suitable I.V. fluid to correct hypovolemic shock (as with diarrhea or vomiting) due to following reasons:
  (a) Because of low Na^+ concentration, ability of Isolyte P to correct intravascular volume and hypotension is poor.
  (b) In oliguric child, high K^+ concentration (20 mEq/ L) is not safe.
  (c) Rapid infusion of large volume of Isolyte-P can cause hyperglycemia and osmotic diuresis, even in child with fluid deficit, which is not desirable in a hypovolemic child.

8. Isolyte-'E' ('E'xtracellular Replacement Solution)

Composition

One litre of fluid contains:

Glucose	50 gms	Chloride	103 mEq
Sodium	140 mEq	Calcium	5 mEq
Potassium	10 mEq	Magnesium	47 mEq
Acetate	3 mEq	Citrate	8 mEq

Pharmacological Basis

Isolyte-E is Extracellular replacement solution. Isolyte-E has electrolytes similar to ECF, except that *it has double the concentration of potassium and acetate* (which will get converted into bicarbonate). Patients on long term fluid therapy may develop magnesium deficiency. Isolyte-E provides all ECF electrolytes, additional potassium and acetate to correct metabolic acidosis, supplies energy and replaces water deficit.

Contraindications

1. Vomiting or continuous nasogastric aspiration.
2. Metabolic alkalosis due to diuretics or sodium bicarbonate.

Recap: *Till now we were discussing various crystalloid solutions, now we will discuss various colloid solution*

B. COLLOID SOLUTIONS (OR PLASMA EXPENDERS OR PLASMA SUBSTITUTE)

Colloids are large molecules, with high molecular substances with size 1-20 micron, and when infused into the vascular space, they are retained within the vascular system for longer time unlike crystalloids. So colloids are more effective than crystalloids as plasma volume expander. ***Colloids are about three times more potent than crystalloid fluids for increasing vascular volume*** and supporting the cardiac output, so in patient with hemorrhagic shock, when plasma or blood is not available immediately, infusion of colloids to correct circulatory fluid volume is vital and often life saving. However, to maintain adequate capacity to carry oxygen, blood transfusion is required subsequently; as soon as available.

Properties or an ideal plasma expanders

1. Exerts oncotic pressure comparable to plasma.
2. Should remain in circulation long enough to maintain a normal blood volume and not leak out in tissue (for at least 4-6 hours)
3. Should be pharmacodynamically inert.
4. Should not be antigenic or pyrogenic.
5. Should not interfere with blood grouping.
6. Should be stable, easily sterilizable and cheap.
7. Should be pharmacodynamically non toxic.

VARIOUS COLLOID SOLUTIONS

1. Albumin

Albumin is a physiological plasma protein. Chief function of albumin is to maintain plasma oncotic pressure (responsible for 75% of the oncotic pressure of plasma), Other function of albumin is binding and transport of low molecular weight substances like bilirubin, hormones, certain drugs etc.

Heat treated preparation of human serum albumin is commercially available in a 5% solution (50 gm/L) and a 25% solution (250 gm/L).

(a) 5% albumin solution (50 gm/1 or 5 gm/dl) has a colloid osmotic pressure of 20 mm of Hg (which is similar to that of plasma), and expands the plasma volume to roughly the same as volume infused. Approximately half of the infused volume of 5% albumin stays in the vascular space. The oncotic effects of albumin last 12 to 18 hours.

(b) 25 % albumin solution has a colloid osmotic pressure of 70 mm of Hg and expands the plasma volume by 4 to 5 times the volume infused. This plasma volume expansion occurs at the expense of the interstitial fluid volume (fluid shifts from extravascular to intravascular compartment), so 25% albumin should not be used for volume resuscitation in patients with fluid deficit (hypovolemia)

These solutions are chosen, where crystalloid fail to sustain plasma volume for more than few minutes due to low colloid osmotic pressure.

Indications

(a) *Plasma volume expansion:* when rapid volume expansion is required, as in acute hypovolemic shock, burns and severe acute albumin loss, albumin is an ideal solution for replacement.

(b) Correction of *hypoproteinemia.*

(c) As an *exchange fluid:* In therapeutic plasmapheresis.

Adverse effects

Adverse effects are rare and include nausea, vomiting, febrile reaction and allergic reactions, including anaphylactic shock. Infusion of albumin solution is contraindicated in patient with severe anemia or cardiac failure.

For adults an initial infusion of 25 gm of albumin is suggested, (eg; 500 ml of a 5% solution or 100 ml of a 25%

KEY BOX 3.3		
FLUID	**EFFECTIVE PLASMA VOLUME EXPANSION**	**DURATION OF EXPANSION**
5% Albumin	70-130 ml	16 hrs
25% Albumin	400-500 ml	16 hrs
6% Hetastarch	100-130 ml	24 hrs
10% Pentastach	150ml	8 hrs
10% Dextran	100-150 ml	6 hrs
6% Dextran	80 ml	12 hrs

solution). A suggested rate is 1 to 2 ml per minute (5% albumin) or 1 ml per minute (25% albumin) although high rates may be needed in the treatment of shock .

2. Dextran

The Dextran are glucose polymers produced by bacteria incubated in a sucrose medium. Dextran is available in two forms, (i) with a molecular weight of 70,000 (dextran 70) and (ii) with a molecular weight of 40,000 (low molecular weight dextran, dextran 40). They are ultimately degraded enzymatically to glucose. They are cheap and can be stored for very long time, so they are the most commonly used plasma expander.

Pharmacological basis

- Both forms effectively expand intravascular volume, but dextran is not a substitute for whole blood, because it has no oxygen carrying property.
- Dextran-40 as 10% solution produces greater expansion of plasma volume than dextran 70 as 6% solution but comparative duration of expansion with dextran 40% is shorter due to its rapid renal excretion.
- *It is useful in improvement of microcirculation and prevention of thromboembolism.* (imp. point)

Indications

1. Correction of hypovolemia: for short term rapid expansion of plasma volume in conditions such as shock or impending shock from burns, surgery, hemorrhage or trauma.
2. Prophylaxis of deep vein thrombosis and postoperative and post traumatic thromboembolism; because it is useful in improvement of microcirculation & prevention of thromboembolism.
3. To improve blood flow and microcirculation in threatened vascular gangrene, (imp. point)

Side effects

- Acute renal failure
- Hypersensitivity reaction: as dextran is a potent antigen, sensitivity reactions are known to occur, but with better manufacturing techniques incidences have decreased (less than 10%).
- Dextran may interfere with blood grouping and cross matching, (due to rouleaux formation)
- Causes **decrease platelets adhesiveness** and hence increase bleeding time. (AIIMS 81, PGI81)

3. Gelatin Polymers (Haemaccel)

Haemaccel (500 ml plastic bottle pack 3.5% solution).

It is a sterile, pyrogen free, colloidal plasma volume substitute, which contains a ***polymer of the degraded gelatin with electrolytes.*** (PGI81, AIIM84).

Each litre contains; Polymer from degraded gelatin 35 gm (Molecular weight 30000-35000)

Sodium	145 mEq,	Calcium	12.5 mEq,
Chloride	145 mEq,	Potassium	5.1 mEq

Indications

1. For rapid expansion of intravascular volume and correction of hypotension in shock, burn, trauma, and intra or postoperative blood loss
2. For priming of heart lung machine.

Advantage

1. No interference with coagulation, blood grouping and cross matching.
2. It remains in blood for 4-5 hours & expands plasma volume by about 50% of infused volume.

Side effects

Hypersensitivity reaction (flushing, urticaria, rigor, bronchospasm and fall in blood pressure) because it causes histamine release.

4. Hetastarch (Hydroxyethyl Starch)

Hetastarch is a synthetic colloid available, as 6% solution in isotonic saline. Hetastarch is a starch that is composed of more than 90% esterified amylopectin.

Pharmacological basis

After I.V. hetastarch infusion, molecules with lower molecular weight (about 40% of dose) are readily excreted in urine in 24 hours. Larger molecular weight fractions are metabolized and eliminated slowly. Hetastarch is slightly more potent than 5% albumin as colloid. The expanded plasma volume may last for 24 hours.

Advantage

1. Nonantigenic: fewer antigenic properties as compared to dextran.
2. Hetastarch does not interface with blood grouping or cross matching
3. Hetastarch is less expensive than albumin.
4. Plasma volume expansion greater than 5% albumin.
5. Expands plasma volume for a longer period, effect lasts for about 24 hours

Disadvantage

1. *Increase in serum amylase concentration* during and 3-5 days after discontinuation of hetastarch. So serum amylase concentration can not be used to diagnose acute pancreatitis during this period.
2. Like other colloids, it has no oxygen carrying capacity, so one should not allow hematocrit to fall below 30% after an infusion

Administration

The dose of hetastarch depends on the patient's need. The usual adult dose of hetastarch 6% solution is 500 ml to 1 liter. The total daily dose should not exceed 20 ml/kg.

5. Pentastarch

Pentastarch is a low molecular weight derivative of hetastarch, that is available as 3%, 6% and 10% solution in isotonic saline. Pentastarch differs from hetastarch in having a lower degree of esterification. As pentastarch contains smaller but more numerous starch molecules, it has a higher colloidal osmotic pressure, so it is more effective as a volume expander than hetastarch. 10% pentastarch can increase plasma volume 1.5 times of the infused volume.

Also know -

1. Needle Gauge (Thickness)

- The higher the gauge, the thinner the needle.
- It indicates external diameter.
- Lower gauge needle have higher blood flow.

Gauge	Color
14	Orange
16	Grey
18	Green
20	Pink
22	Blue
24	Yellow
26	Purple
17	White

2. French Scale

- French scale used to measure size of catheter, is a measure of external diameter of catheter. If French size is 9, external diameter is 3 mm (i.e. divided by 3).
- Higher French number indicated thicker catheter.

3. If IV access can't be made in a shock patient, intraosseous cannulation should be done next (PGME).

******

4 Hemorrhage and Blood Transfusion

Contents

- Classification
- Physiological effect
- Methods of determining blood loss
- Blood transfusion
- Massive blood transfusion
- Blood products
- Red blood cell subsititute

Hemorrhage means loss of circulating blood from vascular system, resulting in decreased total blood volume. This can be classified in various ways depending on the source, timing and nature.

CLASSIFICATION

On the basis of

A. Source of Hemorrhage

1. Arterial Hemorrhage

Arterial Hemorrhage is usually bright red in colour, blood spurts as a jet which rises and falls in time, with the heart beat. In case of pulmonary artery hemorrhage; the blood is dark red in colour.

2. Venous Hemorrhage

Venous Hemorrhage is usually dark red in colour and has a steady, continuous flow. In case of pulmonary vein hemorrhage; the blood is bright red and has a high pressure.

3. Capillary hemorrhage

Capillary hemorrhage is usually bright red in colour and the hemorrhage is often rapid and oozing.

On the basis of

B. Time of Hemorrhage

1. **Primary:** At the time of operation or injury.

2. **Reactionary** (DELHI 09)

Usually occurs 4-6 hours after operation but can occur within 24 hours. (UP 2001, 2006) . This may occur due to:

(a) Due to slipping of a ligature, **dislodgment of a clot** (NEET), cessation of reflex vasospasm.

(b) Precipitating factors being : rise of BP and refilling of the venous system on recovery from shock; coughing and vomiting which can raise venous pressure.

3. Secondary hemorrhage

It *occurs usually 7-14 days after operation* and is due to infection and sloughing of a part of the wall of an artery.

On the basis of

C. Type of hemorrhage

1. External hemorrhage

In this, source of hemorrhage is always visible (revealed).

2. Internal hemorrhage

(a) Concealed

When bleeding is invisible (ie. sealed); eg; rupture of spleen and liver, fracture of femur, ruptured ectopic pregnancy.

(b) Revealed

Concealed internal bleeding may become revealed as in hematemesis in peptic ulcer disease and hematuria due to renal trauma.

SIGNS OF HEMORRHAGE

In case of increasing blood loss there is increasing pallor, rising pulse rate, restlessness, fall in blood pressure, dyspnea, cold and clammy* skin. [* *Clammy= damp and sticky].*

****

PHYSIOLOGICAL EFFECTS OF HEMORRHAGE

- If the amount of blood loss is less than 10-15%; there is no clinical effect, mainly as a result of compensation by vasoconstriction.
- If the blood loss is more than 10-30%, venous return is decreased. The sequence of event is as following.

↓Venous return

↓

↓Cardiac output

↓

↓Blood pressure

↓

↓Tissue perfusion

↓

Cause sympathetic over activity

↓

Compensation by increase in heart rate (tachycardia) and vasoconstriction

****

METHODS OF DETERMINING BLOOD LOSS

The hemorrhage can be assessed on the basis of following *(MANY PGME)*

1. Signs of hemorrhage: Discussed earlier.
2. Hemoglobin level: No immediate change is detected, but falls after a few hours.
3. Hematocrit reading: Fall in hematocrit is observed.
4. *Measurement of blood loss*
   - (a) ***Blood clot:*** *The size of the clenched fist is roughly equal to 500 ml of blood* *(PGI 88)*. Closed fracture of long bone roughly equals to 500-2000 ml.
   - (b) ***Swab weighing*** before and after operation: 1 g = 1 ml + blood collected in the suction bottles, depending on the duration and extent of surgery multiplied by a factor of 1.5. *(JUNE 99)*

MANAGEMENT *(PLEASE SEE BOX 4.1)*

A. Stopping Blood Loss: This is done By 3 'P's
Kindly go through key box 4.1

(i) Pressure and Packing

Pressure and packing should be applied as soon as possible. Packing with a wide gauge or sponges are done, as in ruptured liver. Pressure by a tourniquet around thigh or limbs can be applied in case of bleeding from them.

(ii) Position and rest

The position of the bleeding part is kept in such a way, that gravity affect is least, eg. limb elevation, when bleeding is from limbs.

KEY BOX 4.1

MANAGEMENT

There are two basic principles of management; stop the blood loss, and restore blood volume.

(A) Stop the blood toss	(B) Restoring blood volume
(3 Ps) • **Pressure and Packing** *(MOST IMPORTANT)* • **P**osition and rest • **P**rocedure (operative) eg; ligation, repair	• Blood transfusion and • Blood products • Plasma expanders

(iii) Operative Procedure

- Artery forceps and clips are mechanical means of controlling bleeding. The clamped vessels can be ligated with catgut, cotton threads, or silk, or it can be coagulated with diathermy.
- Repair can be done with patches of vein or dacron graft for vascular defects.
- The whole or a part of bleeding organ may require excision, for example; splenectomy or partial hepatectomy, for splenic and hepatic rupture.

B. Restoring Blood Volume

The best way to restore blood volume is, **fresh blood transfusion,** which is discussed below.

****

BLOOD TRANSFUSION

Indications

1. The commonest indication of blood transfusion is acute hemorrhage, be it external (revealed) or internal (concealed).
2. Blood loss during surgery.
3. Severe burn
4. Anemia
5. In post operative cases blood transfusion is required when the patient has become considerably anemic and debilitated, either due to excessive bleeding during operation, or as a result of infection or septicemia.
6. To increase coagulability.
7. Hypoproteinemia and malnutrition.

Collection of Blood for Transfusion

- Before, collecting blood from an individual or donor, one has to be sure, that he is not suffering from any disease; which may be transmitted through blood, particularly hepatitis and AIDS.
- Blood is collected into a commercially prepared sterile plastic bag.
- The donor lies down on bed. Sphygmomanometer cuff is applied to the either of upper arm (from which the blood is to be collected) and is inflated to a pressure of 70-80 mm Hg.
- After injecting 0.5 ml of local anesthetic (xylocain), a wide bore needle (usually 15 Gauge) is introduced into the median cubital vein.
- The needle is connected to a plastic tube, which is attached to the sterile plastic bag, which already contains 75 ml of anticoagulant solution.
- During collection, blood is constantly mixed with anticoagulant solution to prevent clotting. About 350 ml of blood is taken in a single bag.
- Two types of **anticoagulant solutions** are usually used to mix with the donor blood. These are:

(i) CPD solution

Citrate + **P**hosphate + **D**extrose solution. This has *storage life of about 3 weeks.*

(ii) CPD**A** solution

When with the above solution **A**denosine is added it is called as CPD**A** solution, and *storage life is increased to 5 weeks*. Adenosine is added to increase storage life of blood. *(JLP 93)*

Blood Storage

- All blood for transfusion must be stored in special blood bank refrigerators controlled at 4°C. If blood is allowed to stand at higher temperature for more than 2 hours, it increases the risk of transmitting infection.
- During storage of blood, the red blood cells or erythrocytes, which constitute the major component, lose their ability to release oxygen to the tissue of the recipient with in 7 days, so **it is best to transfuse the blood within 7 days after collection.**
- White blood cells are rapidly destroyed in stored blood (usually within 48 hours). *(PGME)*
- Platelets are also destroyed considerably at 4°C. Only few are functionally useful after 48-72 hours.
- Like platelets, clotting factors VIII and V are also destroyed quickly.

PACKED RED CELLS

Packed red cells are advisable in patients with chronic anemia, in elderly individuals, in infants or young children, and in those patients whose cardiac reserve is low and may suffer from cardiac failure, if whole blood is transfused.

****

COMPLICATION OF BLOOD TRANSFUSION

- The *most common cause of mismatched blood transfusion is human error (blood bank clerk error, or other medical staff error)* (PGME MANY TIMES)
- There are various complication of blood transfusion, which can be broadly divided into two groups. These are:

(a) transfusion reactions and

(b) transmission of disease.

Complications

(A) Transfusion reaction	(B) Transmission of Infection
(a) Hemolytic reaction	1. Hepatitis
1. Incompatibility	2. AIDS
(b) Non-Hemolytic reaction	3. Bacterial infection (box 4-2)
2. Pyrogenic (febrile) reaction	4. Septic shock.
3. Hypersensitivity (allergic) reaction	5. Malaria
4. Sensitization to leukocytes and platelets	

Now lets discuss them one by one

(A). TRANSFUSION REACTION

The following are the various transfusion reaction which may be seen as complication of blood transfusion, of these; **incompatibility is most serious** and should be avoided at all costs. Transfusion reaction may be divided as following:

(a) Hemolytic Reaction

1. Incompatibility

There are 3 main causes of incompatibility

(i) Human error: (M/C causes) mismatched blood due to clerical mistake and other medical staff error, (MANY PGME)

(ii) Transfusion of blood, which is already hemolyzed by warming or freezing.

(iii) Transfusion of blood after expiry date.

Clinical feature

- Pain at the infusion site and along the vein used for transfusion.
- Fever with chills and rigor.
- Headache.
- Chest and loin pain (a very important feature, occurs due to blockage of renal tubules).
- Flushing of face.
- Sweating.

Other signs include oliguria, hemoglobinuria, hypotension, nausea, vomiting and hypothermia.

Treatment

- Stop the transfusion immediately.
- Patient's and donor's bloods are retested for ABO and Rh factor.
- Foley's catheter is passed & urine output recorded.
- Initiate diuresis by maintaining adequate hydration with IV infusion of crystalloids (isotonic saline), large doses of fursemide (150 mg) is given intravenously to provoke diuresis.
- If diuresis is obtained, a high output urine is maintained at the rate of 100 ml/hour.
- If oliguria or anuria occurs, the fluid intake and potassium intake are restricted and the patient is treated as a case of renal shut down.
- Other supportive measures are 100 mg IV hydrocortisone and vasopressors. Anti-histaminic may also be useful.

(b) Non-Hemolytic reaction

2. Pyrogenic (Febrile) reaction

- Febrile reaction is defined as an increase in temperature of at least 1°C during or within few hours after transfusion.
- This may be due to bacterial contamination or due to alloimmunisation to leucocyte and platelet antigens in patients, requiring repeated blood transfusion or following previous pregnancy.

Clinical feature

Fever with chills and rigors, tachycardia, headache, restlessness, nausea and vomiting.

Treatment

- These reactions are rarely serious and resolve either spontaneously or after discontinuation of blood transfusion.
- Administration of antipyretic and antihistaminics provide symptomatic relief.

3. Hypersensitivity (Allergic) reaction

These are usually mild and associated with itching and urtricaria. They are commonly attributed to unidentified foreign proteins in donor blood. These reactions are usually not serious.

Treatment

Stop the transfusion, give antihistaminics, adrenaline or hydrocortisone.

4. Sensitization of leukocytes and platelets

This is occasionally seen where many blood transfusion to patient have been given in the recent past. The patient develops antibodies against the white cells or platelets of the donated blood, which causes reaction. *Treatment* is symptomatic.

(B). TRANSMISSION OF INFECTION

Following infection may be transmitted through blood transfusion. Please see key box 4.2

1. Serum Hepatitis virus

Hepatitis may be transmitted from donor, and usually results in severe hepatitis, arising approximately 3 months after the transfusion.

2. HIV

HIV can be transmitted by blood and blood products. Although AIDS has received considerable attention, it ranks far behind hepatitis as a cause of death resulting from blood transfusion *(IMP. POINT)*

3. Bacterial infection

Transmission of bacterial infection through blood is not uncommon and mainly as a result of faulty storage technique. The donor's blood; when left in a warm room for some hours before transfusion, bacterial proliferation may take place. See box 4.2

KEY BOX 4.2

INFECTIONS Transmitted Through Blood Transfusion
(PGME MANY TIMES)

1. Bacterial: Brucellosis, Syphilis
2. Helminthiasis: Filariasis
3. Protozoan: Malaria, Toxoplasmosis, Chaga's disease, Trypanosomiasis.
4. Rickettsial: Relapsing fever, Rocky mountain fever
5. Viral: CMV, Ebsteinbarr virus, HBV, HIV, Yellow fever virus'.

NOTE: Viral hepatitis is the most common and fatal complication of blood transfusion. *(PGMB MANY TIMES)*

4. Malaria

Can be transmitted by blood transfusion in areas where the disease is endemic.

Other Complications

1. Thrombophlebitis
2. Air Embolism
3. DIC (Disseminated intravascular coagulation)
4. Hypothermia (if too cold blood is transfused)
5. TRALI (Transfusion Related Acute Lung Injury)

****

MASSIVE BLOOD TRANSFUSION

Massive transfusion is defined as that which is equivalent to or exceeds the patients own blood volume with in 24 hours (i.e; more than 10 units) *(NEET)*.

*NOTE. ONE UNIT OR POINT BLOOD IS EQUAL TO 350 ml OF BLOOD

There are quite a few hazards of massive blood transfusion and should be kept in mind.

Complications due to Massive Blood Transfusion

- Metabolic alkalosis *(AIIMS NOV 19)*
- **Hyperkalemia** / Hypokalemia

- Citrate toxicity
- Hypothermia
- Failure of coagulation
- **DIC**
- Thrombocytopenia
- **Hypocalcemia** *(AIIMS JUNE 20)*
- Hyper ammonemia
- ARDS
- Congestive cardiac failure (due to volume overload).

****

BLOOD PRODUCTS

Packed Red Blood Cells

- This component is indicated for most patients with a symptomatic deficit of oxygen carrying capacity, especially in those who may not tolerate an increase in blood volume, as in elderly or those with heart failure.
- One unit contains 300 ml with hematocrit about 70%.
- One unit should raise an adult recipient's hemoglobin by 1.0 gram *(AI 03)*.
- Average life span of transfused RBC is 35 days (maximum-50 days).

Platelet Concentrates

- Platelets stored at room temperature, can be used for 5 days after collection.
- If stored at 4°C, it should not be used after 48 hours after collection *(PGI 81,88, AIIMS 86)*
- One platelet concentrate produce an increase of 7000 to 10,000 platelet/cu mm, one hour after transfusion to 70 kg adult.
- In a patient with thrombocytopenia, target platelet count after plate transfusion to perform on invasive procedure is 50,000/μL *(AIIMS MAY 15)*.
- *Indications:* thrombocytopenia of <20,000/cu mm or clinical signs of bleeding.

KEY BOX 4.3

Components	Storage	Transport	Expiry	Indications
Whole blood	In a blood bank refrigerator at 2°C to 6°C	Can be transported for the next 24 hr if maintained at 1°C to 10°C during transport	35 days in a closed system, 24 hr in an open system	Acute blood loss Exchange transfusion Massive transfusion
Packed red cells	In a blood bank refrigerator at 2°C to 6°C	Can be transported for the next 24 hr if maintained at 1°C to 10°C during transport	35 days in a closed system, 24 hr in an open system	Chronic, symptomatic anemia Acute blood loss
Fresh frozen plasma	In a plasma freezer at below - 30°C	Transported in frozen state	1 year	Multiple factor deficiencies Severe liver disease Warfarin reversal
Platelet concentrate	In a platelet incubator with agitator at 20°C to 24°C with continuous gentle agitation	20°C to 24°C	5 days in a closed system, 4 hr in an open system	Bleeding due to low platelet count or impaired function
Cryoprecipitate	In a freezer at below - 30°C	Below - 30°C	1 year	Fibrinogen deficiency Dysfibrinogenemia Trauma Disseminated intravascular

Fresh Frozen Plasma (F.F.P)

- Frozen at –18° C or Cooler.
- Contains plasma proteins, especially factor V & VIII.
- Indications -
  - Replacement of isolated factor deficiency.
  - Antithrombin III deficiency
- Dosage – 12 to 15 ml/kg.

Cryoprecipitate

- If the frozen plasma is allowed to cool at 4°C, it will be divided into a white glutinous precipitate and a supernatant plasma. *This glutinous precipitate is known as cryoprecipitate.* It is usually stored at minus 40°C. *(UPSC 06)*
- It is a very rich source of factor VIII and fibrinogen *(PGI 79, AIIMS 85).*
- *Indication:*
  - Factor VIII deficiency (Hemophilia).
  - Fibrinogen deficiency (Hypofibrinogenemia)

NOTE. Please read Key box 4.3

****

RED BLOOD CELL SUBSTITUTES (ARTIFICIAL BLOOD)

These are called as artificial blood because, like RBCs they have Oxygen carrying capacity. Please see box 4.3. The red blood cell (RBC) substitutes commercially available are:

1. Perfluorocarbon Based Oxygen Carriers (FBOC)

- These are hydrocarbons; with fluoride substitution of the H radicals. They dissolve large amounts of gases.
- Amount of dissolved oxygen is proportional to ambient oxygen tension in blood (up to 50 ml oxygen/100 ml of FBOC).
- They have to be emulsified as they are oil like. They can release 1.3 ml of oxygen/100 ml of FBOC.
- It has to be transported in a frozen state. Anaphylactic reactions can occur.

Examples of FBOC are:

- Perfluoro decalin (**Fluosol DA**) *(MANY PGME)*
- Perfluoro octyl bromide emulsion (Oxygent)

2. Hemoglobin Based Oxygen Carriers (HBOC)

- Developed from 'cell free' hemoglobin (SFH Stroma free hemoglobin) from human and animal blood after lysis and centrifugation.
- They have more affinity for oxygen due to lack of 2, 3 DPG.
- They have short half life.
- They are nephrotoxic an important side effect.
- It is a leuko-reduction filter which prevents transfusion related reactions.

KEY BOX 4.4
Characteristics of an Ideal Blood Substitute
1. Effective in physiological conditions
2. Safety:
• From disease transmission
• From toxic reaction
• Should be Non immunogenic.
3. Prolonged life and universal acceptability.

- It is theorized that transfusions that contain white blood cells may cause adverse effects through multiple mechanisms. White blood cells may themselves harbor infectious disease and some pathogens will be more concentrated in white blood cells than the rest of the blood product. It is also theorized that the donor white blood cells may suppress the recipient's immune system by interacting with it.
- Leukoreduction is the removal of white blood cells (or leukocytes) from the blood or blood components supplied for blood transfusion.

Examples of HBOC are:

- Stabilized Hb
- Polymerized Hb
- Conjugated Hb
- Encapsulated/embedded Hb
- Recombinant human hemoglobin from *E. Coli.*

****

Sample Questions for Prof Examination

1. Enumerate the indication of blood transfusion.
2. What are the complications of blood transfusion.
3. How are they diagnosed and treat.
4. Complications and treatment of blood transfusion.
5. Write short notes on blood transfusion reaction.
6. Write short notes on complications of massive blood transfusion.

5 Nutrition in a Surgical Patient

Contents

- Nutritional assessment
- Administration of nutrition
- Enteral nutrition
  - Enteral nutrition
  - Parenteral nutrition
- Nutritional support in special situations
- Red blood cell substitute

Nutritional support in a surgical patient remains an essential component of perioperative care. Approximately one half of all hospitalized patients experience or are at risk for malnourishment, with severe protein calorie malnutrition (PCM) evident in one in ten patients. Malnourished surgical patients have increased mortality rate and are two or three times more likely to incur complications.

Many studies have found that appropriate nutritional intervention can improve postoperative outcomes and decrease costs. Most patients who undergo surgical procedures, have adequate fuel reserves to tolerate a short period of starvation and catabolism; however, some patients may require nutritional support; in particular those who have developed complications of major surgery, trauma, or sepsis, as well as those with cancer related cachexia. Adequate nutrition sustains basal metabolism, wound healing and immune response, all of which are essential for timely recovery.

The interaction of metabolism and endocrine responses resulting from major operation, trauma, or sepsis can be divided into ***three phase:***

1. Catabolic Phase

After major injury, there is a dramatic increase in the metabolic demand, as reflected in a significant rise in the urinary excretion of nitrogen (beyond that seen in simple starvation). After a major surgical procedure, protein depletion occurs inevitably because patients are commonly prevented from eating; instead of having an elevated basal metabolic rate.

2. The early anabolic Phase

Also called the corticoid withdrawal phase. Depending on the severity of stress, the body shifts from catabolism to anabolism. The timing of the event is variable, ranging from several days to several weeks. This phase is marked by a positive nitrogen balance and there is a rapid and progressive gain in weight and muscular strength. The total amount of nitrogen gained is equivalent to the amount lost in the catabolic phase; however the rate of repletion is much slower.

3. The late anabolic phase

This is the final phase of recovery and may last from several weeks to months. Adipose stores are replenished gradually, and nitrogen balance equilibrates.

****

NUTRITIONAL ASSESSMENT

Nutritional assessment is essential in identifying patients at risk for developing complication related to significant PCM*. Preoperative nutritional support can significantly reduce perioperative morbidity and mortality in patients with severe PCM. In addition, the incidence of postoperative morbidities, such as intra-abdominal abscess, anastomotic leakage, ileus may all be decreased by the use of preoperative enteral or parenteral hyperalimentation in patients with severe PCM.

* PCM = *protein calorie malnutrition*

KEY BOX 5.1

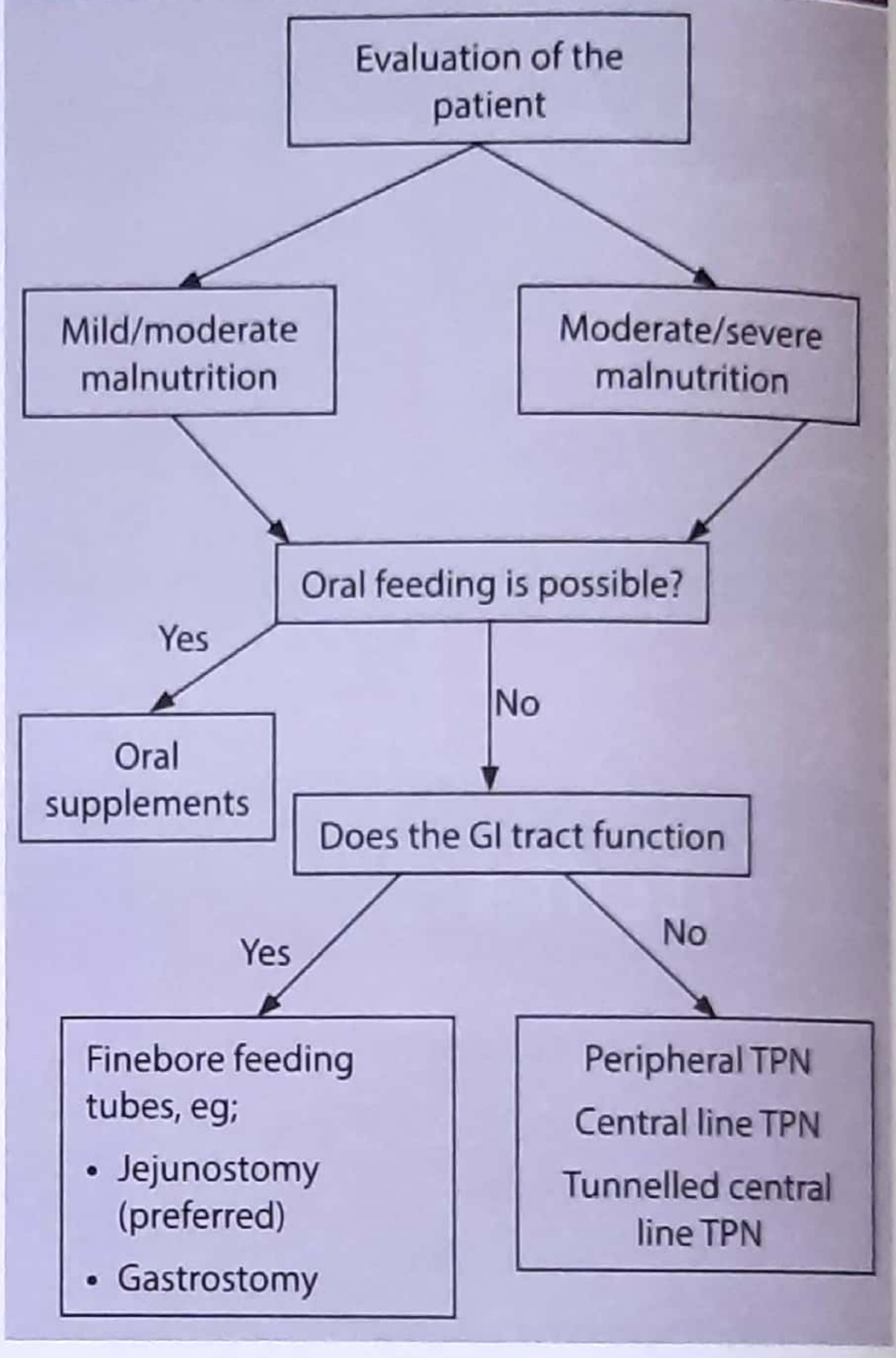

TYPES OF MALNUTRITION

Two forms of malnutrition have been identified

1. Marasmus

This is malnutrition that is caused typically by illness induced anorexia without catabolism. It is a *chronic nutritional deficiency marked by loss in weight, body fat, and skeletal muscle mass* (as identified by anthropometric measurements).

Visceral protein stores remain normal. Patients with marasmus may lose substantial body weight but are able to resist infection and respond appropriately to minor to moderate stress.

2. Kwashiorkor

This may be due to an extension of marasmus in some patients. This form of malnutrition develops, when the period of starvation is prolonged or if the stress is severe. Increased visceral protein loss and metabolic stress leads to hypoalbuminemia, edema and anergy. Even in a well nourished patient, a severe stress (eg. major burn or prolonged sepsis) may rapidly lead to the depletion of visceral protein stores and impairment in immune function.

EVALUATION OF PREEXISTING DEFICITS

A dietary history, physical examination (including anthropometric measurements), and relevant laboratory data are the appropriate tools needed to make an accurate evaluation of a patient's preoperative nutritional status:

1. **A history** of weight fluctuation or a change in dietary habits is particularly relevant. Recent weight loss (5%in the last month or 10% over 6 months) or a current body weight of 80-85% (or less) of ideal body weight strongly suggests the possibility of significant malnutrition.
2. **Physical examination** may identify muscle wasting (especially thenar and temporal muscles), loose or flabby skin, and peripheral edema (as a result of hypoproteinemia). More subtle findings of nutritional deficiency include skin rashes, pallor, glossitis, gingival lesions, hair changes, hepatomegaly, neuropathy and dementia.
3. **Anthropometric measurements** such as ***triceps skin fold thickness*** **and** ***mid arm (mid humeral) muscle circumference are a reflection of body fat stores and skeletal muscle mass, respectively*** (NEET, UPSC 95). These values are standardized for gender and height, & they should be reported as a percentage of the predicted value.

4. **Laboratory tests** that suggests malnutrition and have a direct correlation with preoperative morbidity include :
   (a) Serum albumin of less than 2.8 g/dl in a stable, hydrated patient. (Normal= 3.8-5.0 g/dl)
   (b) Anergy to injected skin recall antigens (eg; Candida, mumps).
   (c) Transferrin level of less than 200 mg/dl (Normal = 230-390 mg/dl).
   (d) Total lymphocyte count of less than 1,200 /mm^3.
5. **Nutritional indices:** A number of nutritional & biological indices have been developed to predict the risk of perioperative complications & mortality; such as:-
   (a) Prognostic Nutritional Index (PNI)
   (b) Catabolic Index (CI)
   (c) Creatinine Height Index (CHI)

ESTIMATION OF CALORIE AND PROTEIN REQUIREMENT

It is necessary to provide adequate substrates for healing and tissue repair. Failure to provide both adequate calories and protein leads to further depletion of lean body mass.

KEY BOX 5.2

Clinical Condition	Stress Factor
• Starvation	0.8-1.0
• Elective operation	1.0-1.1
• Peritonitis or other infections	1.05-1.25
• Adult respiratory distress syndrome or sepsis	1.30-1.35
• Bone marrow transplantation	1.2-1.35
• Cardiopulmonary disease without sepsis, dialysis or surgery	0.8-1.0
• Cardiopulmonary disease with major surgery	1.30-1.55
• Acute renal failure	1.30
• Liver failure	1.30-1.55
• Liver transplantation	1.20-1.50
• Pancreatitis	1.30-1.80

1. Basal energy expenditure (BEE)

It can be predicted using the **Harris-Benedict's equation:**

- BEE in kcal per day formen = 66.4 + (13.7 × weight in kg) + (5.0 × height in cm) (6.8 × age in year).
- BEE in K cal per day for women = 655 + (9.6 × weight in kg) + (1.7 × height in cm) – (4.7 × age in years).
- These equations provide a reliable estimate of the energy requirements in approximately 80% of hospitalized patients. *For ill patients*, these values may be multiplied by a factor that adjusts the estimate energy expenditure for the specific addition of the patient. The energy requirements is then increase by 25 % as an attempt to provide sufficient energy to maximize the anabolic process of the patient. Thus total energy (TEE) expenditure is estimated by multiplying BEE to stress factor*.
- **TEE = Estimated BEE × stress factor** (see key box 5.2 for stress factors)
- The energy needs in most hypercatabolic patients can be estimated at approximately 25-40 K cal/kg/day.
- Disease specific stress factor is used in calculation of total energy expenditure (TEE).

2. Estimates of protein requirements

The appropriate calorie to nitrogen ratio is approximately 150:1 in the absence of severe renal or hepatic dysfunction, *approximately 1.0 g protein per kg or body weight should be provided daily* (PGI 85, MANY PGME).

Estimated protein requirements in various disease state

Clinical condition	Protein requirement
Mild metabolic	1.0-1.1/kg
Moderate metabolic stress	1.2-1.4/kg
Severe metabolic stress	1.5-2.5/kg

Recap

Till now we were discussion: assessment of nutritional status, evaluation of nutritional deficit (BBE, TEE). Now we will discuss, how to give nutrition to a patient: Adminstration of nutrition.

****

ADMINISTRATION OF NUTRITION

Before going into details please see this flow chart:

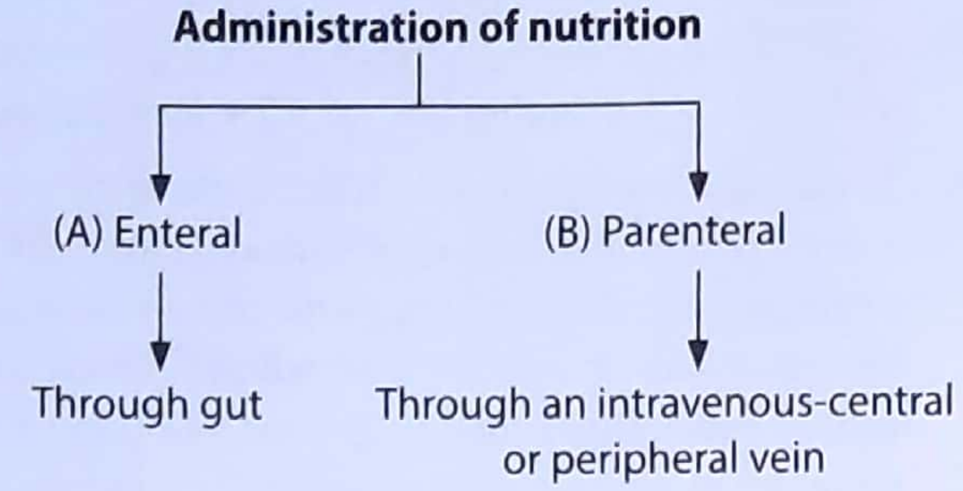

Nutritional requirements for surgical patients can be administrated either through the gut or parentally; through a central or peripheral vein; ie; through an intravenous drip. Before proceeding further please read Key box 5.1 carefully.

A. ENTERAL NUTRITION

In general, the **enteral route (intestinal route) is preferred over the parenteral route** (AI 02). Enteral feeding is simple, physiologic, relatively inexpensive and well tolerated by most patients. Enteral feeding maintains the GI tract cytoarchitecture and mucosal integrity, through trophic effects, absorptive function and normal microbial flora. This results in less bacterial translocation and exotoxin release from the intestinal lumen to the bloodstream. Enteral feeding is **indicated** for patients who have a functional GI tract, but are unable to take an adequate oral diet.

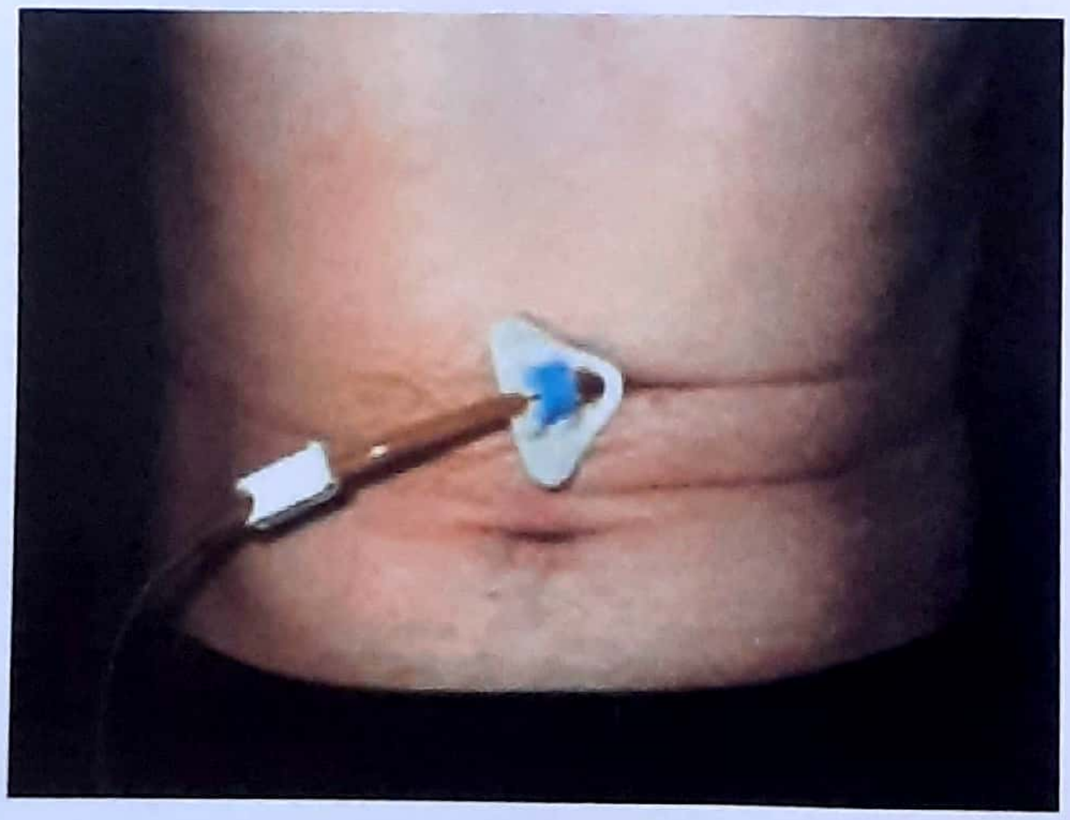

Figure 5.1 : Percutaneous endoscopic gastrostomy tube

Enteral feeding is **Contraindicated** in the patient with an intestinal obstruction, ileus, GI bleeding, severe diarrhea, vomiting, enterocolitis or a high output entero-cutaneous fistula (fecal fistula).

Feeding Tubes

Nasogastric, nasojejunal, gastrostomy and jejunal tubes area available for the administration of enteral feeding products. Gastrostomy tubes can be placed using minimally invasive techniques, such as by endoscopic or laparoscopic insertion. **Jejunal tubes are preferred for long term access** (PGME) and require a continuous infusion rather than bolus administration. See Fig 5.1 & 5.2.

Through feeding tube; fruit juices, soups, pulses, *khichris* can be flushed in the intestinal lumen. Oral medication can also be given through feeding tubes.

Nasogastric tube length is measured by nose to ear to xiphoid process.

Enteral Feeding Protocols

1. *Bolus feeding*

In general, bolus feedings are used in patients with nasogastric or gastrostomy feeding tubes. Tracheobronchial aspiration is a potentially serious complication; and to prevent this patient's head should be elevated to 30-45 degrees during feeding and for 1-2 hours after each feeding.

2. *Continuous injection*

Administration of food by a pump, is generally required for nasojejunal, or jejunal feeding tubes. The feeding jejunostomy tube should be flushed with approximately 30 ml of water every 4 hours.

3. *Conversion to oral feeding*

When indicated an oral diet is resumed gradually. In an effort to stimulate/increase appetite, enteral feeding can be modified by the following measures:

(a) Providing fewer feedings

(b) Holding daytime feedings

(c) Decreasing the volume of feedings. When oral intake provides approximately 75% of the required calories, tube feedings may be discontinued.

Administration of medications

Many oral medications can be administrated through feeding tubes. Medications that are not suitable for administration through a feeding tube include the following:

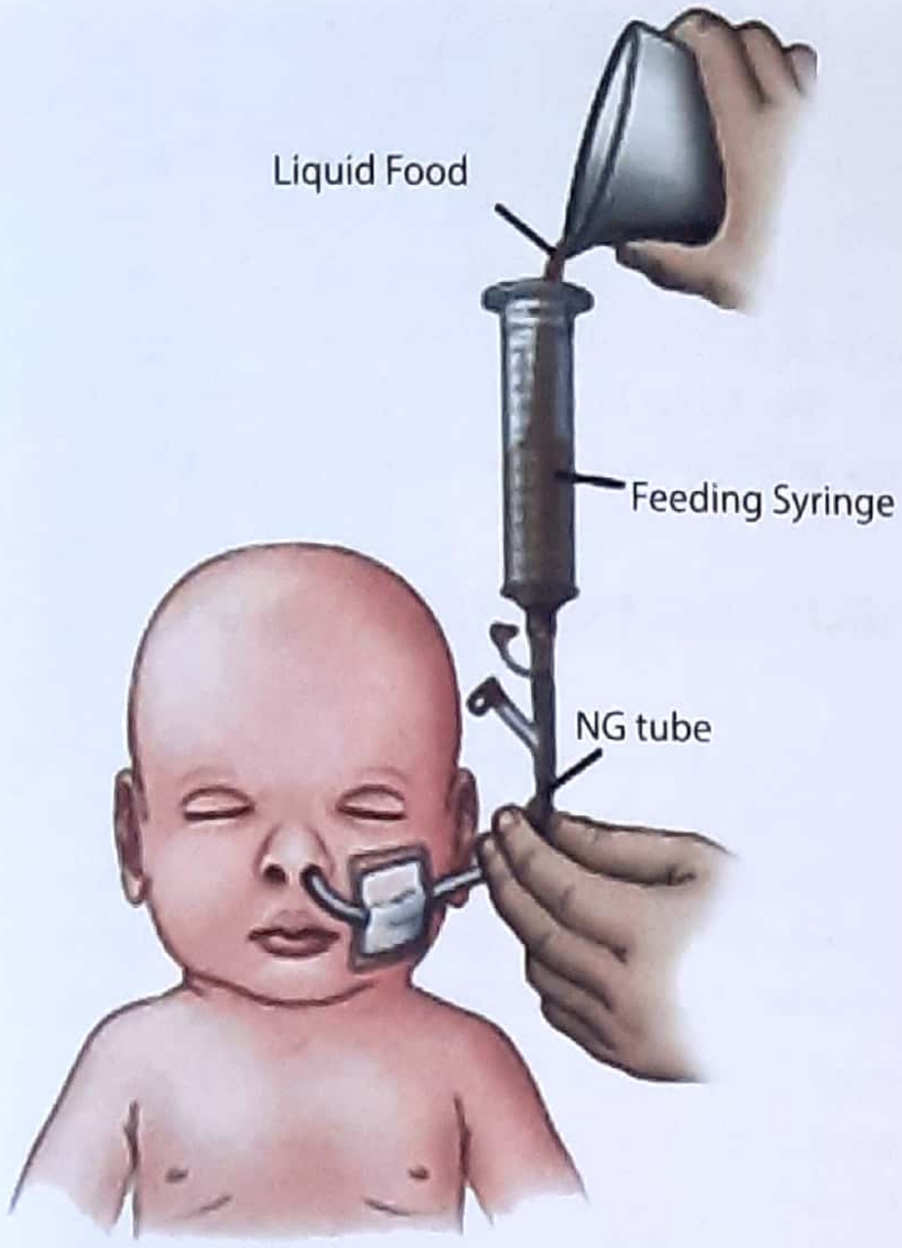

Figure 5.2: Ryle's tube (NG tube) feeding in a child

1. Enteric coated medications
2. Drugs in gelatinous capsules
3. Medications designed for sublingual use
4. Most sustained release medications

Complication of Enteral Feeding *(SEE KEY BOX 5.3)*

Abnormalities of serum electrolytes

Abnormalities in calcium, magnesium and phosphorus can occur and can be minimized through vigilant monitoring.

Hyperglycemia

This may occur in any patient, but is particularly common in patients with preexisting diabetes and/or sepsis. The serum glucose level should be determined frequently and regular insulin should be administrated accordingly.

Clogging

Clogging of the tube can be prevented by careful attention to routine flushing of the feeding tube with water.

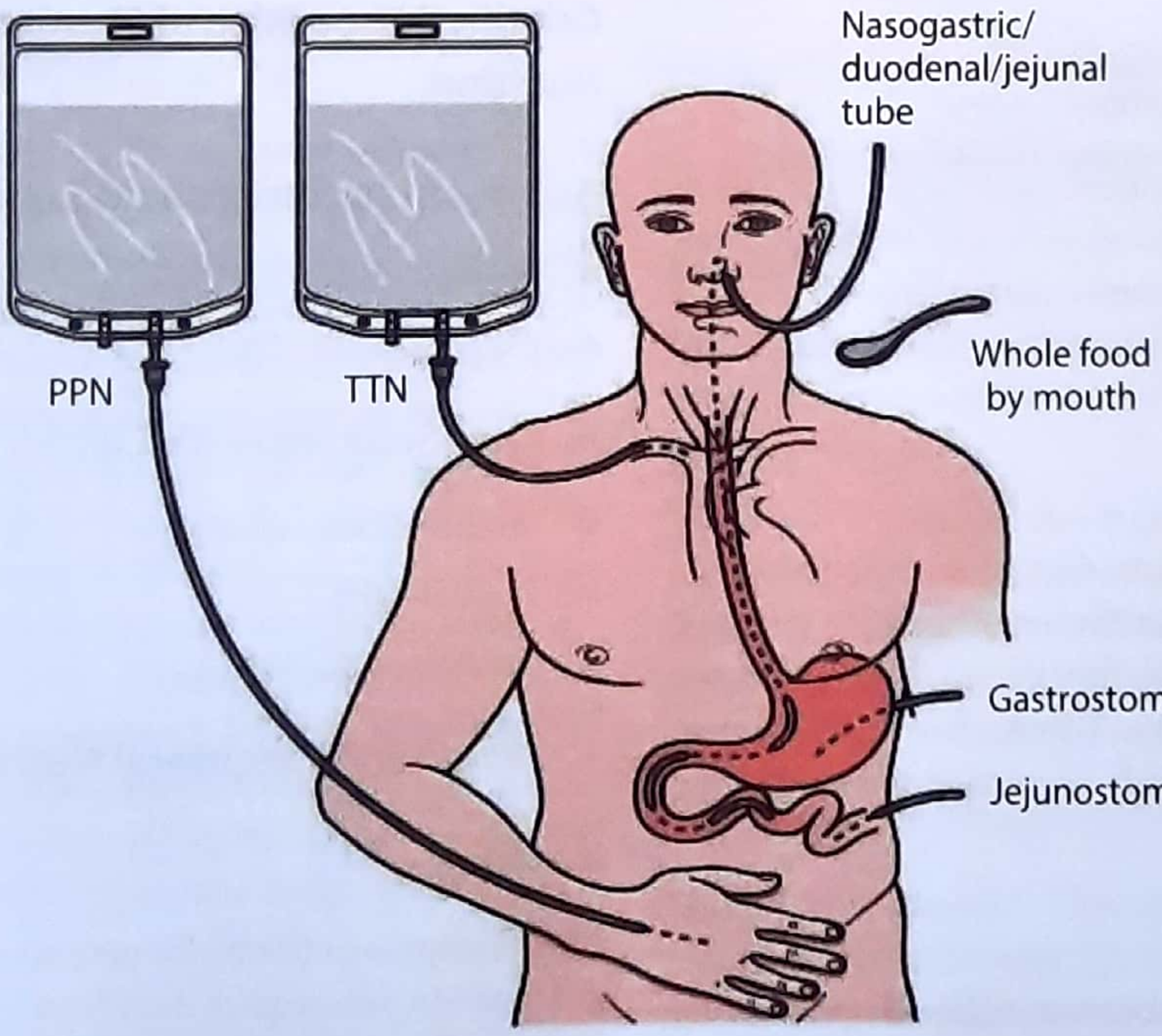

Figure 5.3 : Techniques used for adjuvant nutritional support. PPN, Partial parenteral nutrition; TPN, total parenteral nutrition,

KEY BOX 5.3

Complications of enteral nutrition

- Tube-related
  - Malposition
  - Displacement
  - Blockage
  - Breakage/leakage
  - Local complications (e.g. erosion of skin/ mucosa)
- Gastrointestinal
  - Diarrhoea
  - Bloating, nausea, vomiting
  - Abdominal cramps
  - Aspiration
  - Constipation
- Metabolic/biochemical
  - Electrolyte disorders
  - Vitamin, mineral, trace element deficiencies
  - Drug interactions
- Infective
  - Exogenous (handling contamination)
  - Endogenous (patient)

Tracheo-bronchial aspiration

This may occur with patients fed into the stomach or proximal small intestine and may lead to the development of pneumonia. Patients particularly at risk; are those with central nervous system abnormalities and those who are sedated.

High gastric residuals

High gastric residuals of tube feeding as a result of gastric outlet obstruction, dysmotility, intestinal ileus or bowel obstruction may limit the usefulness of nasogastric or gastrostomy feeding tubes. Treatment of this problem should be directed towards correcting the underlying cause.

Diarrhea

It is a potential consequence of enteral feeding, occurring in 10-20% of patients; however, other causes of diarrhea (e.g. *Clostridium difficile* or other infective colitis) should be considered.

Diarrhea may result from numerous causes: eg; too rapid feeding, an increase in the volume of hyperosmolar tube feedings, some medications (eg; metaclopramide), a diet high in fat content or by the presence of components not tolerated by the patient (eg; lactose). If other cause of diarrhea can be excluded, the volume or strength of tube feedings should be diminished. If there is no improvements, a different formula feed should be started.

B. PARENTERAL NUTRITIONAL THERAPY

When the gastrointestinal tract cannot be used, nutrients must be given parenterally (through venous line). Since parenteral nutrition is more expensive; and is associated with more technical, metabolic, septic complications and requires more expertise than enteral nutrition; it should only be used when the gut can not be used for nutrition.

Parental formulas deliver 75-150 nonprotein carbohydrate calories per gram of nitrogen infused, a ratio that maximizes carbohydrate and protein assimilation and minimizes metabolic complications (amino acid urea, hyperglycemia, and hepatic glycogenesis).

There are two methods:

(i) Peripheral parenteral nutrition (PPN) and

(ii) Total parenteral nutrition (TPN).

Calorific Composition of Standard Parenteral Nutrition.

A. 2 in 1 Solution (without Lipids):

- Amino Acids—20-25%
- Dextrose—75-80%

B. 3 in 1 Solution (with Lipids)

- Amino Acids—20-25%
- Lipids—20%
- Dextrose—55-60%.

1. Peripheral Parenteral Nutrition (PPN)

Indications

PPN therapy is indicated for patients with compromised gut function who require short term (<10 days) nutrition because they are unable to ingest adequate nutrients. It is contraindicated for patients who can be nourished via the gut.

KEY BOX 5.4	
Monitoring feeding regimes	
Daily	Body weight Fluid balance Full blood count, urea and electrolytes Blood glucose Electrolyte content and volume of urine and/or urine and intestinal losses Temperature
Weekly (or more frequently if clinically indicated)	Urine and plasma osmolality Calcium, magnesium, zinc and phosphate Plasma proteins including albumin Liver function tests including clotting factors Thiamine Acid- base status Triglycerides
Fortnightly	Serum vitamin B12 Folate Iron Lactate Trace elements (zinc, copper, manganese)

PPN Solution Formulation

One litre of standard PPN solution contains $D_{20}W$ 500mL; 10% amino acids; 500 ml, plus electrolytes, vitamins, minerals and trace metals. $D_{20}W$ contains 20 grams of glucose/100mL. The metabolism of 1L of $D_{20}W$ produces 340 nonprotein Kcal. One liter of standard PPN solution provides 50 grams of protein or the equilent of 8 grams of nitrogen. The ratio of non-protein carbohydrate calories to grams of nitrogen in 1 L of standard PPN solution is approximately 43 : 1. Since 1 L of standard PPN solution contains adequate nitrogen but inadequate calories, the daily PPN regimen should also include 500 mL of 20% fat emulsion (2 kcal/ml) by giving PPN solution at 125 ml/h and supplementing it with 500 ml of 20% fat emulsion daily, PPN provides about 2200 kcal and 150 grams protein (24 gams nitrogen) daily.

Administration

PPN is infused via an 18-gauge intravenous cannula in a peripheral vein. A 16-gauge single lumen central venous catheter (SLCVC) positioned in the superior vena cava via the subclavian or internal jugular vein may also be used.

2. Total parenteral nutrition (TPN)

Indications

TPN is indicated for patients who cannot be nourished enterically and need more than 10 days of (Intravenous) nutritional support.

Peripheral venous catheter is prefferred who need short term (<14 days) parenteral nutrition. Subclavian central venous line is recommended for long term use. Chlorhexidine is disinfected recommended for all catheter placement procedures.

TPN Solution formulation (AI 2011)

One liter of standard TPN solution contains D-50W 500ml, 8.5% amino acid 500 ml, plus electrolytes, vitamins, minerals and trace metals. 1 liter of standard TPN solution provides approximately 1000 kcal and 6.8 grams of nitrogen; and the ratio of nonprotein carbohydrate calories to grams of nitrogen is approximately 125:1.

KEY BOX 5.5

Complications of Parenteral Nutritional Therapy (AIIMS 87, 08)

Technical	Metabolic complications
Air embolus	**Glucose**
Arterial laceration	Postinfusion hypoglycemia
Branchial plexus injury	Hyperglycemia
Arteriovenous fistula	Hyperosmolar syndrome
Cardiac perforation	**Acid & base**
Catheter embolism	**Metabolic acidosis increased anion gap** (NEET)
Catheter malposition	Metabolic alkalosis
Pneumothorax	Respiratory acidosis
Subclavian vein thrombosis	**Lipids**
Thoracic duct laceration	Essential fatty acid deficiency
Venous laceration	Hypertriglyceridemia
Infections	**Nitrogen**
Insertion site contamination	Hyperammonemia
Catheter contamination	Increased serum urea
Secondary contamination	Negative nitrogen balance
• Septicemia-bacterial or fungal	**Water and minerals**
• Septic emboli	Overhydration/dehydration
• Osteomyelitis of clavicle	Hypo/hypernatremia
• Septic arthritis	Hypo/hyperkalemia
• Endocarditis	Hypo/hyperphosphatemia
Miscellaneous	Hypo/hypermagnesemia
Biliary cholestasis	Hypo/hypercalcemia
Fatty metamorphosis of the liver	**Trace element deficiency**
Hypercapnia secondary to large carbon load	Aluminium, Zinc, Iron, Copper
	Vitamins Hypervitaminosis A or D
	Deficiency of vitamins D or K
	Deficiency of the vitamin B and
	Vitamin C and folic acid

Patients receiving TPN should also receive 20-30% of their daily caloric requirement as fat in order to prevent a fatty acid deficiency. This is accomplished by giving 500 ml of 20% fat emulsion (2 kcal/ml) intravenously over 6-8 hours at least three times per week.

TPN solutions generally are administrated as a 3 in 1 admixture of protein as amino acids, carbohydrate as dextrose and fat as a lipid emulsion of soybean or safflower oils. Alternatively, the lipid emulsion can be administrated as a separate intravenous *"Piggy back"* infusion.

Administration

The TPN catheter is inserted either into the superior vena cava via the internal jugular or subclavian vein or into the inferior vena cava via the femoral vein. The solution is initially infused at a rate of 30- 40 ml/hour via a constant infusion pump. The rate should be at 40 ml/hour on the first day, 40ml/hour on the second day, and 100-125 ml/hour on the third day. The final rate is achieved within 72 hours, depends on the patients's daily caloric and protein requirements, age and cardiovascular status.

****

SPECIAL TPN SOLUTION

1. Concentrated

The TPN solution must be more concentrated for patients who require fluid restriction (eg; those with pulmonary and cardiac failure). One liter of concentrated TPN solution usually contains a combination of $D_{60}W$ or $D_{70}W$ and 10% to 15% amino acids 500 ml, plus additives.

2. Renal Failure

Patients in renal failure (serum creatinine >2 mg/dl) who cannot be dialyzed, and who require fluid restriction should receive a special renal failure TPN solution. Each litre of solution contains a combination $D_{80}W$ 500ml and renal failure amino acids (essential amino acids only) 500 ml plus limited amounts of sodium, potassium, magnesium and phosphate.

Patients in renal failure who can undergo dialysis should receive a TPN solution that contains $D_{60}W$ or $D_{70}W$ and 8.5% standard amino acids (essential and non-essential) 500 ml plus additives, with limited amounts of sodium, potassium, magnesium and phosphate.

KEY BOX 5.6

Biochemical Complication During Parenteral Nutrition and Their Correction

Complication	Clinical presentation	Correction
Hyponatremia	Confusion, Apathy	Reduce water intake increase Na^+ Intake
Hypokalemia	Apathy, cardiac irregularly	Increase K^+ intake
Hypomagnesemia *(AL 2000)*	Weakness, vertigo, convulsions	Increase Mg^{2+} intake
Hypophosphatemia	Apathy, confusion, paresthesia, red blood cell (RBC) oxygen dissociation	Increase PO_4 intake
Azotemia	Apathy	Increase water intake, increase energy: nitrogen ratio to 185 : 1
Hyperammonemia	Apathy, seizures, coma	Reduce infusion rate or stop altogether
Hyperglycemia	Increased blood sugar	Treat underlying cause and reduce infusion rate
Hypoglycemia	Lethargy, Vasoconstriction	Give dextrose
Hyperosmolar dehydration	Hyperglycemia Dehydration serum sodium and osmolality, apathy, coma	Correct hyperglycemia and give half-strength saline

Patients receiving TPN should also receive 20-30% of their daily caloric requirement as fat in order to prevent a fatty acid deficiency. This is accomplished by giving 500 ml of 20% fat emulsion (2 kcal/ml) intravenously over 6-8 hours at least three times per week.

TPN solutions generally are administrated as a 3 in 1 admixture of protein as amino acids, carbohydrate as dextrose and fat as a lipid emulsion of soybean or safflower oils. Alternatively, the lipid emulsion can be administrated as a separate intravenous *"Piggy back"* infusion.

Administration

The TPN catheter is inserted either into the superior vena cava via the internal jugular or subclavian vein or into the inferior vena cava via the femoral vein. The solution is initially infused at a rate of 30- 40 ml/hour via a constant infusion pump. The rate should be at 40 ml/hour on the first day, 40ml/hour on the second day, and 100-125 ml/hour on the third day. The final rate is achieved within 72 hours, depends on the patients's daily caloric and protein requirements, age and cardiovascular status.

****

SPECIAL TPN SOLUTION

1. Concentrated

The TPN solution must be more concentrated for patients who require fluid restriction (eg; those with pulmonary and cardiac failure). One liter of concentrated TPN solution usually contains a combination of $D_{60}W$ or $D_{70}W$ and 10% to 15% amino acids 500 ml, plus additives.

2. Renal Failure

Patients in renal failure (serum creatinine >2 mg/dl) who cannot be dialyzed, and who require fluid restriction should receive a special renal failure TPN solution. Each litre of solution contains a combination $D_{80}W$ 500ml and renal failure amino acids (essential amino acids only) 500 ml plus limited amounts of sodium, potassium, magnesium and phosphate.

Patients in renal failure who can undergo dialysis should receive a TPN solution that contains $D_{60}W$ or $D_{70}W$ and 8.5% standard amino acids (essential and non-essential) 500 ml plus additives, with limited amounts of sodium, potassium, magnesium and phosphate.

KEY BOX 5.6

Biochemical Complication During Parenteral Nutrition and Their Correction

Complication	Clinical presentation	Correction
Hyponatremia	Confusion, Apathy	Reduce water intake increase Na^+ Intake
Hypokalemia	Apathy, cardiac irregularly	Increase K^+ intake
Hypomagnesemia *(AL 2000)*	Weakness, vertigo, convulsions	Increase Mg^{2+} intake
Hypophosphatemia	Apathy, confusion, paresthesia, red blood cell (RBC) oxygen dissociation	Increase PO_4 intake
Azotemia	Apathy	Increase water intake, increase energy: nitrogen ratio to 185 : 1
Hyperammonemia	Apathy, seizures, coma	Reduce infusion rate or stop altogether
Hyperglycemia	Increased blood sugar	Treat underlying cause and reduce infusion rate
Hypoglycemia	Lethargy, Vasoconstriction	Give dextrose
Hyperosmolar dehydration	Hyperglycemia Dehydration serum sodium and osmolality, apathy, coma	Correct hyperglycemia and give half-strength saline

3 Hepatic Failure

Patients with hepatic encephalopathy should receive a hepatic failure TPN solution that contains a combination of $D_{30}W$ or $D_{40}W$ 500 ml and a special hepatic failure amino acid solution (branched chain amino acid) 500 mL plus additives, with the exception of limited amounts of sodium (<40meq/l).

Discontinuation of TPN should take place when the patient can satisfy 75% of his or her caloric & proteins needs with oral intake or enteral feeding.

****

MANAGEMENT OF COMPLICATIONS OF PARENTERAL NUTRITION

1. Treatment of air embolism

Involves placing the patient with left side down, head down, and feet elevated (Durant position) and aspirating blood and air through the subclavian catheter.

2. Catheter site infection

This is characterized by mild fever (37.5-38°C), pus around the catheter tract, and erythema and tenderness of the surrounding skin. Late changes include induration of the skin and systemic sepsis. Because catheter infections are twice as common (10% versus 5%) with triple lumen than with single lumen catheters, the later are much preferred. The principal findings are (1) unexplained hyperglycemia (serum glucose > 160 mg/dl). (2) fever (38-38.5°C [100.4-101.3°F]) for 12-24 hours. (3) leukocytosis (>10.000/µl), and (4) positive blood cultures from a remote vein as well as from the suspect catheter. Skin changes are rare.

Patients with a suspected catheter infection who have negative blood cultures and no cardiovascular compromise should have the catheter exchanged over a guidewire and the tip send for bacterial and fungal culture. If the fever resolves and subsequent cultures are negative (colony count < 15), no further therapy is necessary. If the patient remains febrile even after the catheter is change or continues to have positive blood or catheter cultures, a new central catheter should be inserted at another site.

3. Metabolic complications

Hyperglycemia and hyperosmolarity may lead to coma or death. In addition, hyperglycemia may be the first indication of occult infection. Patients with a serum glucose level of 200-400 mg/dl should have subcutaneous regular insulin. Patients with serum glucose level exceeding 400 mg/dl should have intravenous infusions of regular insulin. Conversely, hypoglycemia may occur on discontinuation of TPN.

The refeeding syndrome may occur when TPN is administered to a severely malnourished patient, resulting in a dramatic shift of extracellular ions into the intracellular space. Additional supplementation of K, Mg and PO_4 may be needed. A large parenteral sodium load in a severely malnourished patient may precipitate congestive heart failure.

4. Hepatic dysfunction

This is a common manifestation of long term TPN support. Steatosis is associated with mild elevations of the transaminases, alkaline phosphate, and bilirubin.

Cholecystitis, particularly the *acalculous Cholecystitis* is common in patients receiving TPN for extended periods *(IMP. POINT)*. Cholecystostomy or cholecystectomy is indicated for symptomatic patient.

HOME PARENTERAL NUTRITION

Patients who do not require a hospital environment for management of their primary disease, yet can not tolerate adequate enteral or oral feeding; may be candidates for home parenteral nutrition.

Patients with terminal illnesses, lack of self care ability, or lack of a supportive home environment are candidates for this method. Inflammatory bowel disease, motility disorders and ischemic bowel infraction are also indications. A period of in patient training is necessary to acquaint the patient with appropriate methods of solution preparation and delivery.

****

NUTRITIONAL SUPPORT IN SPECIAL SITUATIONS

Modifications of the standard adult formula are required for the treatment of patients with congestive cardiac failure, hepatic failure and renal failure. It is essential to recognize that no single intravenous nutrient solution can be ideal in all situations.

A. Neurosurgical Patient

Three cautions should be remembered when TPN is being considered for the brain injured patient.

1. Severe head injury is associated with hyperglycemia; and administration of large amounts of glucose could worsen this abnormality.
2. Free water administration is usually restricted after brain trauma to prevent severe hyponatremia.
3. The greatest hazard of TPN is sepsis. This risk should not be underestimated in critically ill patients bearing numerous catheters and multiple possible foci for infection.

B. Renal Failure

The principle that endogenous urea can be converted to nonessential amino acids, if an adequate amount of carbohydrate is provided, underlies one nutritional approach to patients with acute renal failure.

Patients with acute tubular necrosis are treated by parenteral nutrition with essential amino acids and hyper-tonic dextrose.

Because urinary glucose is notoriously unreliable in renal failure, the blood glucose level should be checked at least twice daily when therapy is started. Insulin is added to the solution if necessary; according to blood glucose levels.

Hypokalemia, hypomagnesemia and hypophosphatemia occur regularly, sometimes as soon as 8 hours after the initiation of renal failure fluid infusion.

C. Hepatic Failure

If the gut can be used, enteral supplementation is best. In the absence of hepatic encephalopathy, standard nutritional support is adequate for patients having liver failure. Patients with hepatic encephalopathy usually have an increase in methionine and aromatic amino acids and subnormal levels of branched chain amino acids. Therefore, special enteral and parenteral formulations have been used to correct this imbalance and reverse encephalopathy.

D. Enterocutaneous Fistula (Fecal Fistula)

Malnutrition is recognized as one of the major causes of morbidity in patients with fistulas. It should be said that the hypermetabolism due to uncontrolled sepsis is the most important factor leading to malnutrition in these patients. While some patients can receive some or all of their support through the enteral route, factors such as diarrhea, high fistula output, obstruction and intraabdominal sepsis with ileus may preclude the use of the gastrointestinal tract. In addition to better fistula closure rates, patients given TPN instead of enteral nutrition have their nutritional needs met earlier and are better repleted.

E. Sepsis

The nutritional support of septic patients is designed to reduce glucose administrations, because plasma glucose levels are high and peripheral tissue cannot use glucose. Lipid emulsions are used to provide calories because fatty acids and ketone bodies are preferred fuel for many organs during sepsis. Amino acid mixtures are enriched with branched chain amino acids to provide non-glucose fuel source for skeletal muscle and to prevent muscle auto-catabolism. Marked improvement of indexes of nutritional competence has been demonstrated in stressed patients in surgical intensive care units; who were given branched chain amino acid enriched mixture.

F. Short Bowel Syndrome

Mesenteric vascular thrombosis or embolus, midgut volvulus, internal herniation with infarction, massive abdominal trauma, multiple bowel resections for inflammatory bowel disease, malignancy or radiation enteritis, all can lead to short bowel syndrome. While most patients with short bowel syndrome are eventually managed entirely with enteral nutrition, the inability of the bowel to adequately absorb nutrients early in the course of the disease makes TPN a life saving measure. The goal is to eventually wean the patient from parenteral nutrition as the gut adapts.

kindly read small bowel syndrome in chapter small and large intestine (chapter 34, page no 503)

G. Acute Pancreatitis

Uncomplicated acute pancreatitis rarely requires any form of nutritional support because of its self limited nature. When complication of pancreatitis such as pseudocyst, fistulas, prolonged phlegmons or a fulminant course arise; nutritional support will be required. Enteral feedings should be attempted first. If enteral feedings exacerbate pain, produce ascites or cause serum amylase or lipase to rise; TPN should be initiated. In the absence of endogenous hypertrigylceridemia, a standard lipid emulsion may be used with care, provided that serum lipid profiles are monitored and verifying that triglycerides remain less than 400 mg/dl.

H. Critical Care

Because of the metabolic response to trauma, burns or sepsis, critically ill patients are prone to the rapid development of malnutrition. Such insults induce hypermetabolism, which leads to muscle wasting, insulin resistance and increases in counter regulatory hormones. Early nutritional intervention for these patients is vital, because protein calorie malnutrition increase mortality rates.

I. Pregnancy

In pregnancy patients receiving TPN, serum glucose should be monitored closely to prevent hyperglycemia, which is associated with increased risk for fetal complications such as macrosomia, poor pulmonary development and late fetal death.

With a normal liver, most patients receiving TPN in pregnancy can adjust the amino acid pattern of the administrated formula so that the amino acid pattern to which the placenta is exposed is normal. In the event, however that hepatic impairment is associated with pregnancy, care must be given to provide an amino acid profile that results in a normal amino acid profile to the placenta.

J. Pediatric Patients

In neonates, some of the hepatic .enzymes responsible for maintaining the normal levels of amino acid patterns are not fully developed. Consequently, greater attention must be paid to the constituents of the amino acid profile of nutritional support solutions in neonates and very young infants. The use of lipids is distinctly different than in adults, since up to 4 g/kg of lipids may be administrated for 24 hours in neonates, as opposed to the 2 g/kg limit in adults. In the pediatric patient on TPN, metabolic and volume problems can develop very rapidly. For this reason, serum electrolytes and the patient's volume status must be checked more frequently than in the adult. Also in contrast to the adult, pediatric patients can have hepatobiliary dysfunction development, in the form of cholestasis with conjugated hyperbilirubinemia. If this develops and other causes of hyperbilirubinemia have been excluded, TPN should be discontinued and enteral feeding started, since this is curative. If enteral nutrition cannot be started, reducing the amount of protein and the calorie to nitrogen ratio may be of benefit.

K. Diabetes

Diabetes often complicates nutritional management. Complications associated with TPN administration (e.g; catheter related sepsis) are more common with prolonged hyperglycemia. The goal in glucose intolerant patients is to maintain the serum glucose level at around 100-200 mg/dl. Hypoglycemia can result in shock, seizures or vascular instability. This can be prevented by adjusting the insulin dosing, with the understanding that insulin requirements will decrease as the patient recovers from the initial stress associated with the illness.

****

Sample Questions for Prof Examination

1. Write short notes on total parenteral nutrition.

6 Surgical Infections

Contents

- Boils (Furuncle)
- Abscess
- Carbuncle
- Cellulitis
- Erysipelas
- Hidradenitis suppurativa
- Necrotizing fascitis

BOIL (FURUNCLE)

Boil or furuncle is defined as an acute *Staphylococcal* infection of hair follicle with suppuration.

- Boils are common on back, neck and thigh.
- It is a extremely painful condition and patient presents with painful gradually increasing swelling.
- A short course of antibiotic with removal of affected hair is all that is required.

ABSCESS

An abscess is defined as collection of pus in a cavity. It can be superficial (such as pyogenic abscess, pyemic abscess, cold abscess) or deep (such as intra-abdominal abscess, liver abscess, intra-cerebral abscess, renal abscess)

1. Pyogenic abscess

This is commonest variety of abscess. Organism gain entry to form abscess by any one of the following method:

(a) Directly from outside

(b) Lymphatic spread

(c) Hematogenous spread

Abscess starts as a focal inflammation in a closed space followed by liquefaction necrosis of the native cells of the tissue in the center. See Fig. 6.1.

Figure 6.1: Pyogenic abscess

Clinical feature

- Patient presents with fever and pain.
- There are **five classical features:**

Rubor	Redness
Dolor	Pain
Color	Heat
Tumour	Swelling
Functio lesia	Loss of function

2. Pyemic Abscess

Pyemic abscesses are generally multiple; and all of them generally occur spontaneously and lodge in different parts of the body.

3. Cold Abscess

These are called as 'cold' abscess, because as most of other abscesses are warm (on palpation) and show signs of acute inflammation, a cold abscess doesn't have local warmth, no edema or tenderness. Tuberculosis of lymph node leads to cold abscess formation. Common sites are neck, axilla or groin.

Treatment of abscess

When fluctuation test is positive, an abscess should be treated with incision and drainage (I & D).

- Always send the pus, for culture and sensitivity and start antibiotic depending upon the sensitivity report.
- If the pus is not drained and only antibiotics are given, the inflammation will continue and may form a hard lump. This is called as **antibioma.**

****

CARBUNCLE

- Carbuncle is an *infective gangrene of the subcutaneous tissue, due to staphylococcal infection,* (IMP. POINT)
- Carbuncle are *mostly seen on back, in the nape of neck,* where the skin is coarse and the blood supply is relatively compromised. (PGME)
- Carbuncle is more common in a middle aged (>40 years) diabetic male.
- Stiffness of neck and tenderness are the earliest signs, the subcutaneous tissue becomes partially indurated and the overlying skin becomes rod and edematous.

Figure 6.2: Carbuncle; nape of neck

- Later the swelling and edema progresses in all direction and involves quite large area.
- After a few days an area of softness occurs in the central part which forms pustules and ruptures, allowing pus to discharge, giving a sieve like or cribriform appearance of the skin, which is pathognomonic of this condition (IMP. POINT). See Fig. 6.2.
- If the condition is not treated adequately, it may lead to septicemia, pyemia, toxemia or osteomyelitis.

Treatment

- Wide debridement* of the involved area.
- All necrotic (dead) tissue is excised and pus is sent for culture and sensitivity (to antibiotic) to pathologist.
- Appropriate antibiotics is started once the culture and sensitivity report arrives.
- In diabetic patients; diabetes must be controlled.

Debridement: surgical removal of dead and necrotic tissue.

****

CELLULITIS

- Cellulitis is the spreading inflammation of **subcutaneous tissue and fascial planes** caused by *Streptococcus pyogenes,* which usually enters through minor cuts and abrasions.
- Cellulitis can occur any where in the body but most commonly seen in the scalp, face, forearm or abdominal wall. (Figure 6.3 and 6.4; next page)

Figure 6.3: Cellulitis of hand

Figure 6.4: Cellulitis left leg

Clinical feature

Clinical features depends upon the virulence of the organism and extent of infection.

- The affected region appears swollen and feels tender, red and edematous. Edges are ill defined (cf. erysipelas)
- The constitutional features may vary from slight malaise to high fever.

Treatment

- Elevation of effected limb to reduce edema.
- Rest to the part involved.
- Appropriate antibiotics.
- Anti inflammatory drugs.
- Extensive involvement of the tissue will require debridement*.

Debridement: surgical removal of dead & necrotic tissue.

KEY BOX 6.1

Differentiation of Cellulitis and Erysipelas

Features	Cellulitis	Erysipelas
Tissue involved	Subcutaneous tissue and facial plane	Skin, Lymphatics
Rash	Absent	Typical rose pink rashes
Vesicles	Absent	Present
Edge	Ill defined	Well defined
When face is involved		
Edema of conjunctiva	Present	Absent
Involvement of pinna	Absent	Present *(Milian's ear sign*

****

ERYSIPELAS

Erysipelas is diffused *inflammation of the lymphatics of the epidermis,* caused by *Streptococcus pyogenes.* The infection is usually caused after a skin abrasion. (Fig. 6.5)

Clinical feature

Patient may have marked constitutional symptoms such as fever and malaise. The conditions which predispose this disease are debilitating state and poor health of the patient.

Figure 6.5: Erysipelas

Figure 6.6: Pyogenic granuloma

The condition appears as spreading inflammation with clearly defined margins, giving rise to ***rose pink rashes*** which extends to adjacent skin, (Fig. 6.5) Later vesicles may form; which contains fluid rich in bacteria. Erysipelas has well defined edges.

Treatment

The treatment consists of antibiotics, which usually completely control infection. Rarely, sloughing and gangrene formation may occur in very elderly, debilitated or diabetic patients, which may occasionally require debridement.

Before concluding this topic, kindly go through key box 6.1.

Pyogenic Granuloma

Pyogenic granulomas are common acquired, reactive proliferative vascular lesion of the skin & mucous membrane, usually following minor trauma. The lesion looks like hemangioma and tend to bleed. It is usually 0.5-2.0 cm in size, red in colour, soft in consistency, more or less pedunculated nodule. Most commonly it is seen on the face, finger and toes. (Figure 6.6)

Treatment of choice is excision of the lesion.

****

HIDRADENITIS SUPPURATIVA

- This is a chronic *suppurative disease of the apocrine sweat gland* bearing skin and its subcutaneous tissue. (Figure 6.1 and 6.8) *(PGI 09)*
- The chief factors responsible are poor personal hygiene and obesity. The associated factors are diabetes mellitus, abnormal steroid metabolism, cushing's syndrome.
- The whole process is progressive with subsequent fibrosis.

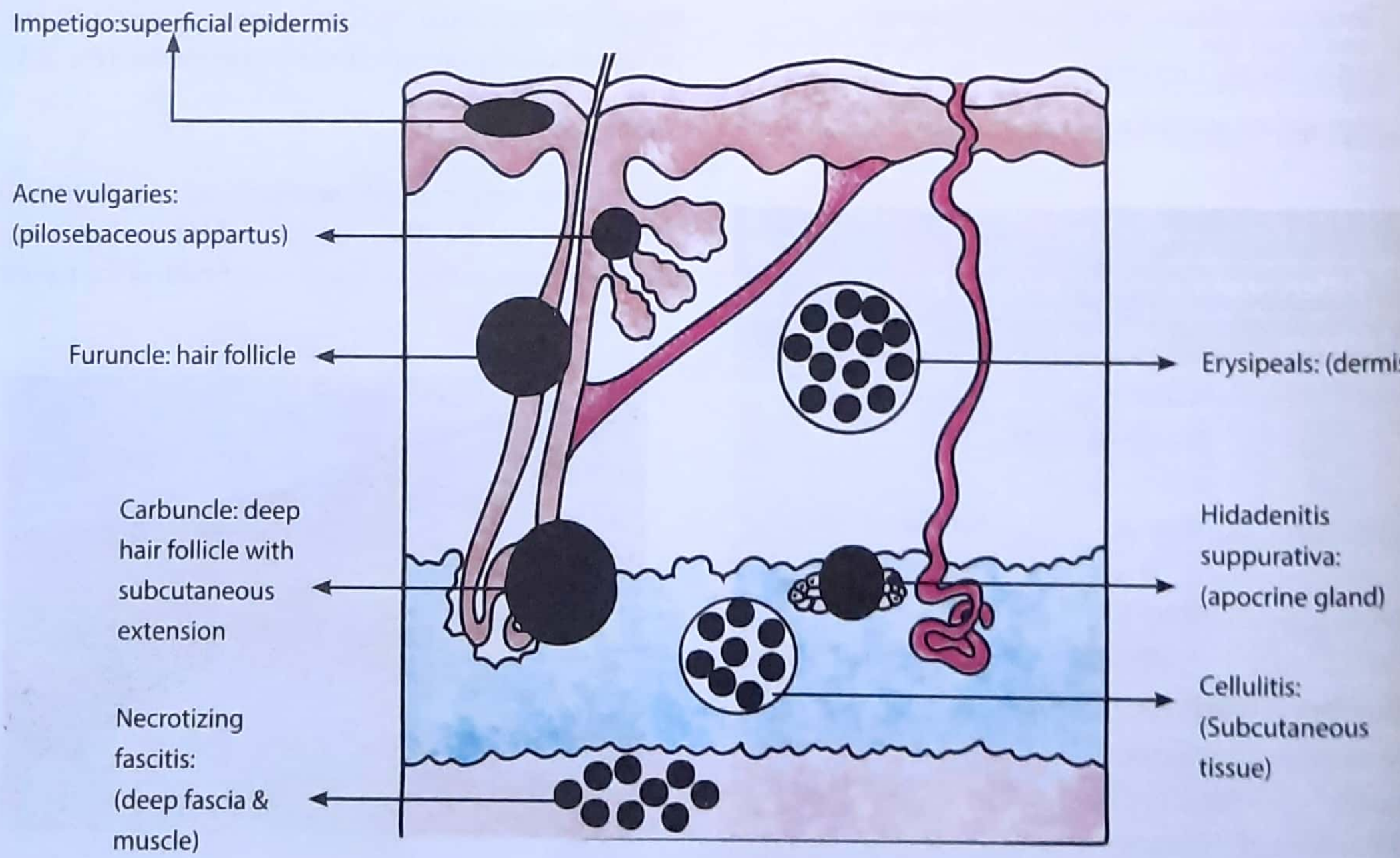

Figure 6.7: Various types and their sites of skin infections

Figure 6.8: Hidradenitis suppurativa

- Axilla is a common site, and extensive fibrosis can some time lead to restriction of shoulder movement.

Treatment

Local cleansing of affected area should be encouraged. In the early stage, incision and drainage with antibiotics may cure the condition. In chronic stage, there is widespread skin damage with scarring with sinus formation, and then radical surgery is the only satisfactory treatment.

****

NECROTIZING FASCITIS

- Necrotizing fascitis is a destructive, invasive and infective condition involving skin, subcutaneous tissue and deep fascia. *Muscles are usually spared. Figure* 6.9)
- Necrotizing fascitis of lower anterior abdominal wall is called as ***meleney's gangrene.***
- The infection may be a polymicrobial or a monomicrobial. The former is a synergistic combination of anaerobes and facultative organisms like coliforms or non-group A streptococci. Mono-microbial infection is due to group A beta-hemolytic streptococci.
- This condition is specially prone to occur in immunocompromise, malnutrition and obesity and in those persons who use corticosteroid drugs. Often any history of injury may not be available.
- Common sites are lower abdomen, genitalia and groin (AI 09). Other sites; less commonly involved are dorsum of hand, thorax. However any part of body may be involved.

Clinical feature

- Sudden pain in affected area with gross swelling and edema of part.
- Necrotic patches of skin and areas of subcutaneous induration and erythema appear. Associated systemic manifestations like fever, malaise develop. When gas forming organisms are involved, surgical emphysema develops.
- When the skin sloughs out, a burrowing ulcer with undermined edge develops.
- There is profuse; foul smelling discharge.

Treatment

- Early treatment include hospitalization, correction of dehydration and starting I.V. antibiotic therapy.
- Surgery involves wide debridement followed by daily dressing. Once the infection is controlled after few days or weeks, skin grafting can be done.
- Mortality is higher, if surgery is delayed or is inadequate.

****

Figure 6.9: Necrotizing fascitis of left leg

KEY BOX 6.2

Some Common Important Terms

Infection: It is the invasion of body by pathogenic microorganism

Bacteremia: Presence of viable microbes in the blood stream without proliferation and toxin production.

Septicemia: Presence of pathogenic microbes along with then-toxins caused by absorption of septic products viable microbes in the blood stream with multiplication and toxin production.

Pyemia: Circulation of Pyemic emboli in the blood forming multiple pyemic abscesses all over the body.

Toxemia: Circulation of toxin in the blood.

Sepsis, SIRS: (Systemic inflammatory response syndrome)-Two or more of following criteria should be present for SIRS:

1. Oral temperature >38°C or < 36°C
2. Tachypnea >24 breaths per minute.
3. Tachycardia > 90 beats per minutes
4. Leucocytosis > 12,000 permicro liter or leucopenia < 4000 per microliter.

Sequential Organ Failure Assessment (SOFA) *(NEET NOV. 20)*

Uses 3 criteria :-

I. Low BP (SBP < 100 mmHg)
II. High RR (≥ 22 breaths per min)
III. Altered mental status

SOFA Score is based on six different scores one each for :-

1.	Cardiovascular/Circulation	-	SBP (Systolic blood pressure)
2.	Respiration	-	PaO_2 & need for mechanical ventilation
3.	Mentation	-	GCS
4.	Hepatic function	-	Bilirubin
5.	Renal function	-	Creatinine
6.	Coagulation	-	Platelet count

Sample Questions for Prof Examination

1. Write short note on cellulitis.
2. Write short note on erysipelas.
3. Write short note on necrotizing fascitis.

7 Ulcer, Sinus and Fistula

Contents

- Stage of Ulcer
- Anatomy of an ulcer
- Classification of ulcer
- Causes of non healing of an ulcer
- Sinus
- Fistula

An **ulcer is *a break in the continuity of the covering epithelium,*** ie; skin or mucous membrane, either following molecular death of the surface epithelium or its traumatic injury.

****

STAGES OF ULCER

The stages of healing of an ulcer are as following :

Stage I: Extension Stage

In this stage of ulcer, the floor of ulcer is covered with exudate and slough,** while the base is *indurated* and the surrounding skin is inflamed. The discharge is purulent and may be even blood stained, (note: *indurated* = hardened)

Stage II: Transition stage (or healing stage)

The floor becomes cleaner, the slough separates and the induration of the base is less. Reddish granulation tissue appears on the floor and discharge becomes serous.

Stage III: Repair state

In this stage there occurs transformation of granulation tissue to fibrous tissue, which gradually contracts to form scar. When an ulcer does not show any tendency towards healing, it changes into a non healing (callous) ulcer. The floor has unhealthy pale granulation tissue* and it's base is indurated. The margins are thickened and indurated. The surrounding area is edematous and hyperpigmented.

**** Granulation tissue***

It is highly cellular and vascular tissue formed by the body to control infection due to its marked cellularity. It contains collagen, blood vessels, fibroblasts, inflammatory cells and macrophages.

Healthy granulation tissue is pink and covered with red granulation with serous discharge. It bleeds on touch (due to the large number of newly formed capillaries) and is non-tender.

Unhealthy granulation tissue is pale with flat or exuberant granulation or may be covered with slough. It is tender and produces a purulent and sometimes foul smelling discharge due to infection.

***** Slough***

Slough is dead soft tissue; that has not yet separated from the living tissue. It is seen before the infection is fully controlled and before granulation tissue forms.

****

KEY BOX 7.0

Classification

Ulcer

Clinical
- Spreading
- Healing
- Non healing (chronic)

Pathological

Non-Specific

Specific
- Tuberculous
- Syphilitic
- Soft sore

Maligant
- Epithelioma (SCC) (Marjolin ulcer)
- Rodent ulcer (BCC)
- Other Malignant ulcer

Traumatic	Arterial	Venous (varicose)	Tropical	Trophic	Miscellaneous
•Mechanical • Electric burn • Thermal burn • Chemical burn	•Athero sclerotic • Buerger's disease • Raynaud's disease				Associated with disease like • Gout • Anemia • Avitaminosis • Rheumatoid arthritis • Hypertension *(Martorell's ulcer)*

SEVEN

ANATOMY OF AN ULCER

Ulcer has edge, margin, floor and base: (Figure 7.1)

Margin

Margin is the junction between the normal epithelium and ulcer. (See figure 7.1)

Edge

Edge is the area, between the margin and the floor of ulcer. See box 7.1 and figure 7.1 & 7.2.

Floor

It is exposed surface of ulcer which can be seen, its appearance depends on the particular type of ulcer.

Base

It is the area on which the ulcer rests.

****

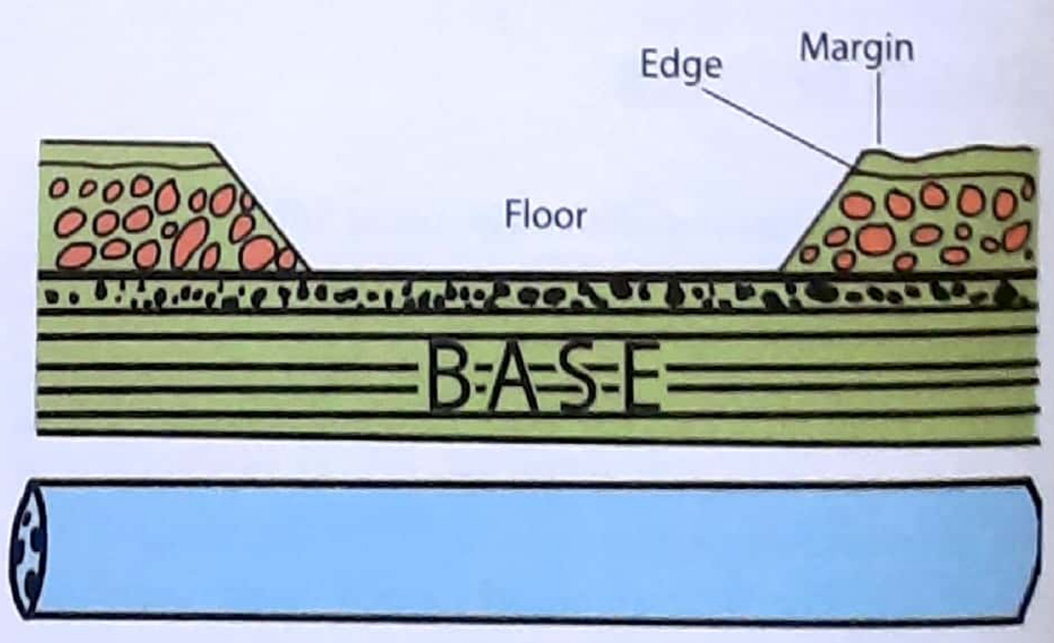

Figure 7.1: Anatomy of an Ulcer

CLASSIFICATION OF ULCER

Please See Classification in Key Box 7.0

1. CLINICALLY

A. Spreading (Acute) Ulcer

Pain, fever and impairment of functions are markedly present. Signs of local tissue destruction are evident with hardly any signs of regeneration (cf. healing ulcer). Floor is covered with profuse, offensive discharge and slough without any evidence of granulation tissue. The edge is ragged, inflamed and edematous due to continued process of tissue destruction. It is very tender. Surrounding area is hot, red and edematous. Regional lymph nodes may be enlarged and tender. They may even suppurate and form an abscess, if the treatment is delayed.

B. Healing Ulcer

Signs of tissue regeneration are marked. Floor is covered with firm, pinkish red, healthy granulation tissue with scanty serous discharge. The margin is **sloping** in character. It is covered with three distinct zones.

(i) The inner; **reddish zone** of healthy granulation tissue, which is covered with single layer of epithelium,

(ii) Middle; **bluish zone** of developing granulation tissue, which is covered with few layers of epithelium.

(iii) The outer most; **white zone** of developing fibrosis. The edge is neither inflamed nor edematous. Surrounding area is normal apart from slight degree of hyperemia. Base is neither indurated nor fixed to the deeper structures (cf. Spreading ulcer).

C. Chronic or Non Healing or Callus Ulcer

Signs of tissue destruction are more than those of regeneration (cf. healing ulcer). The floor is covered by pale granulation tissue and may show slough. Discharge is usually minimum or absent. However sometimes superadded infection may lead to profuse and purulent discharge. Induration is marked at the edge and base. The surrounding skin also becomes indurated and pigmented. The base is markedly indurated and fixed to the deeper structures in case of a malignant ulcer. The regional lymph nodes are enlarged and may be tender or non-tender.

KEY BOX 7.1	
Appearance of margin of various ulcers	
Ulcer	**Appearance of edges**
Healing	Sloping
Varicose	Sloping
Tuberculous	Undermined
Gummatous	Punched out
Perforating	Deeply punched
Epithelioma *(NEET)*	**Raised and everted** *(NEET)*
Rodent ulcer	Raised and beaded

Sloping edge

Punched-out edge

Undermined edge

Rolled edge



Everted Edge

Figure 7.2: Edges in various ulcers

KEY BOX 7.2
Causes of Delay/Non Healing of An Ulcer
1. Local/Causes: (i) Absence of rest to the part where ulcer is situated, (ii) Presence of foreign body in ulcer, (iii) Repeated trauma as in bed sore, (iv) Presence of pus (v) When ulcer base is formed by bone or fibrous tissue.
2. General Causes: (i) Old age (ii) Chronic debilitating disease e.g. Diabetes, Anemia, Leukemia, Tuberculosis (iii) Malnutrition (iv) Avitaminosis eg; lack of vitamin A, B, C. (v) Drug therapy e.g. chronic steroid intake, anti-metabolites or cancer chemotherapy.

Causes of non healing (delayed healing) of an ulcer is given in key box 7.2 and difference between healing and nonhealing ulcer is given in key box 7.3.

2. PATHOLOGICALLY

It can be classified as (Revise key box 7-0 once again)

A. Non specific ulcer

(a) Traumatic

Mechanical ulcer: This is due to trauma, shoe bite, direct trauma etc.

Electric burn: due to electrocution.

Chemical bum: due to application of caustic & acid.

Thermal bum: due to burns

(b) Arterial Ulcer

- This type of ulcer usually develop due to inadequate blood supply.
- These ulcers are mostly due to peripheral arterial disease and poor peripheral circulation.
- Atherosclerosis of the peripheral arteries is the commonest cause of this conditions. Buerger's disease, Raynaud's disease and diabetes may also result in this condition.
- Arterial ulcers are more common in old age due to atherosclerosis.

KEY BOX 7.3

Differentiation of healing and chronic ulcer

Features	Healing Ulcer	Chronic ulcer
HISTORY		
Ulcer		
Duration	Short (weeks)	Long (months)
Progression	Regressing	Stationary
Pain	Absent	Slight
Loss of function	Very little	Variable
Foul smell	Absent	May be present
PHYSICAL		
SIGNS		
Inspection		
Shape	Regular	Variable
Floor		
Discharge	Thin, serous	Seropurulent
Granulation	Bright red	Unhealthy, pale
Slough	Absent	May be present
Margin	Sloping	Variable
Surrounding skin	Normal	Pigmented
Palpation		
Tenderness	Absent	Slight
Bleeding-on touch	Occurs	Occurs only if malignant
Edge	Normal, thin	Indurated, thick
Fixity and infiltration	Absent	Present
Regional lymph nodes	Not palpable	May be palpable

KEY BOX 7.2
Causes of Delay/Non Healing of An Ulcer
1. Local/Causes: (i) Absence of rest to the part where ulcer is situated, (ii) Presence of foreign body in ulcer, (iii) Repeated trauma as in bed sore, (iv) Presence of pus (v) When ulcer base is formed by bone or fibrous tissue.
2. General Causes: (i) Old age (ii) Chronic debilitating disease e.g. Diabetes, Anemia, Leukemia, Tuberculosis (iii) Malnutrition (iv) Avitaminosis eg; lack of vitamin A, B, C. (v) Drug therapy e.g. chronic steroid intake, anti-metabolites or cancer chemotherapy.

Causes of non healing (delayed healing) of an ulcer is given in key box 7.2 and difference between healing and nonhealing ulcer is given in key box 7.3.

2. PATHOLOGICALLY

It can be classified as (Revise key box 7-0 once again)

A. Non specific ulcer

(a) Traumatic

Mechanical ulcer: This is due to trauma, shoe bite, direct trauma etc.

Electric burn: due to electrocution.

Chemical bum: due to application of caustic & acid.

Thermal bum: due to burns

(b) Arterial Ulcer

- This type of ulcer usually develop due to inadequate blood supply.
- These ulcers are mostly due to peripheral arterial disease and poor peripheral circulation.
- Atherosclerosis of the peripheral arteries is the commonest cause of this conditions. Buerger's disease, Raynaud's disease and diabetes may also result in this condition.
- Arterial ulcers are more common in old age due to atherosclerosis.

KEY BOX 7.3

Differentiation of healing and chronic ulcer

Features	Healing Ulcer	Chronic ulcer
HISTORY		
Ulcer		
Duration	Short (weeks)	Long (months)
Progression	Regressing	Stationary
Pain	Absent	Slight
Loss of function	Very little	Variable
Foul smell	Absent	May be present
PHYSICAL		
SIGNS		
Inspection		
Shape	Regular	Variable
Floor		
Discharge	Thin, serous	Seropurulent
Granulation	Bright red	Unhealthy, pale
Slough	Absent	May be present
Margin	Sloping	Variable
Surrounding skin	Normal	Pigmented
Palpation		
Tenderness	Absent	Slight
Bleeding-on touch	Occurs	Occurs only if malignant
Edge	Normal, thin	Indurated, thick
Fixity and infiltration	Absent	Present
Regional lymph nodes	Not palpable	May be palpable

Figure 7.3: Non-Healing Ulcer

Figure 7.4: Venous Ulcer

- Arterial ulcers occur in those parts of the limb, which are subjected to repeated pressure and trauma.
- Repeated episodes of trauma and super added infections cause destruction of the poorly vascularized skin, which fails to heal because of poor arterial supply.
- Arterial ulcer usually occur on the anterior and lateral aspect of the leg, on the toes, dorsum of foot or on the heel, (cf; venous ulcer on medial aspect of leg)
- Pain is the chief complaint.
- These ulcers tends to be punched out and destroy the whole skin & deep fascia and may expose the tendons or even bone in the floor of ulcer.
- The peripheral arterial pulses will be felt diminished or absent. The ischemic limb feels cold than the opposite limb.
- Elevation of the affected leg, above the heart level causes a marked pallor of leg with in 2-3 minutes and the patient experiences severe pain in the affected leg.

(c) Venous ulcer

- This is common ulcer of the leg. The basic cause of venous ulcer is abnormal venous hypertension in the lower third of the leg, ankle and dorsum of the foot.
- A venous ulcer is typically situated on the medial side of lower 1/3 of the leg; just above the medial malleolus. See figure 7.4.
- A venous ulcer is usually a painless non healing ulcer.
- A *venous ulcer is vertically oval in shape with sloping edge. It never penetrates deep fascia.* (IMP. POINT)
- A venous ulcer is characterized by *hyper pigmentation and eczema of the skin around the ulcer.* (IMP. POINT)
- *Presence of varicose veins* in the upper part of the leg or thigh clinches the diagnosis.
- See key box 7.4 for differentiating arterial ulcer and venous ulcer on next page.
- **Bisgaard regimen is for treatment** (AIIMS)**. This include 4 'E'**

  Education, Elevation, Exercise, Elastic compression Evaluation and antibiotics.

(d) Trophic Ulcer (Neurogenic or perforating ulcer) (INICET NOV. 20)

- The mechanism of formation of such ulcer is ***repeated injury or pressure in an area which has lost pain sensation.***
- The neurological conditions, which predispose to trophic ulcer are diabetes, alcoholic peripheral neuritis, tabes dorsalis, leprosy, paraplegia and syringomyelia.

KEY BOX 7.4	
Comparison of Arterial and Venous Ulcer	
Arterial Ulcer	**Venous Ulcer**
• Due to inadequate blood supply	• As a result of varicose ie; poor veins (abnormal venous tissue perfusion, hypertension)
• Usually occurs on, anterior or lateral aspect of leg or on the toes or dorsum of foot	• Usually occurs on lower 1/3 of medial aspect of leg
• Irregular in shape, punched out edge	• Vertically oval in shape, slopping edge.
• Painful ulcer	• Usually painless ulcer (if not infected)
• Always *penetrates deep fascia*	• *Does not penetrate deep* fascia
• Peripheral pulses are either weak or abscent	• Peripheral pulses are normal
• Affected limb feels cold	• Hyper pigmentation and eczema of skin may be present around the ulcer

- Common sites are heel and ball of the foot if the patient is ambulatory and gluteal region (bed sore) if the patient is bed ridden.

The **progression** is as follows Callosity

↓

Suppuration

↓

Discharge of pus

↓

Breakdown of skin

↓

Formation of ulcer

↓

Gradual burrowing deep into the muscle, tendon and even up to bone

↓

Perforates deep and hence ulcer also called as perforating ulcer

- The surrounding skin of a trophic ulcer is anesthetic, which is one of the diagnostic feature of the ulcer.

Note: Bed sore

A trophic ulcer may develop in a bed ridden patient in the gluteal region due to constant pressure and is called as **bed sore or pressure sore or decubitus ulcer** (Figure 7.3).

(e) Tropical ulcer

It is an acute ulcerative skin disease seen in tropical countries like India and Africa.

- The majority of tropical ulcers are situated on the leg. Majority of patients are malnourished, anemic and deficient in vitamins.
- Infection by Vincent's organism *(fusobacterium fusiformis in symbiosis with Borrelia vincenti)* gets entry following minor trauma or insect bite.
- This follows by acute onset of pain and acute lymphadenitis. Gradually, pustules develop and burst to form ulcers, whose edges are undermined and raised the floor is covered with copious seropurulent discharge. See figure 7.6.
- If left untreated, ulcer enlarges in size and could become quite large. Gradually the swelling may subside and ulcer either heals spontaneously or becomes chronic.

Figure 7.5 (a) : Pressure sore (decubitus ulcer)

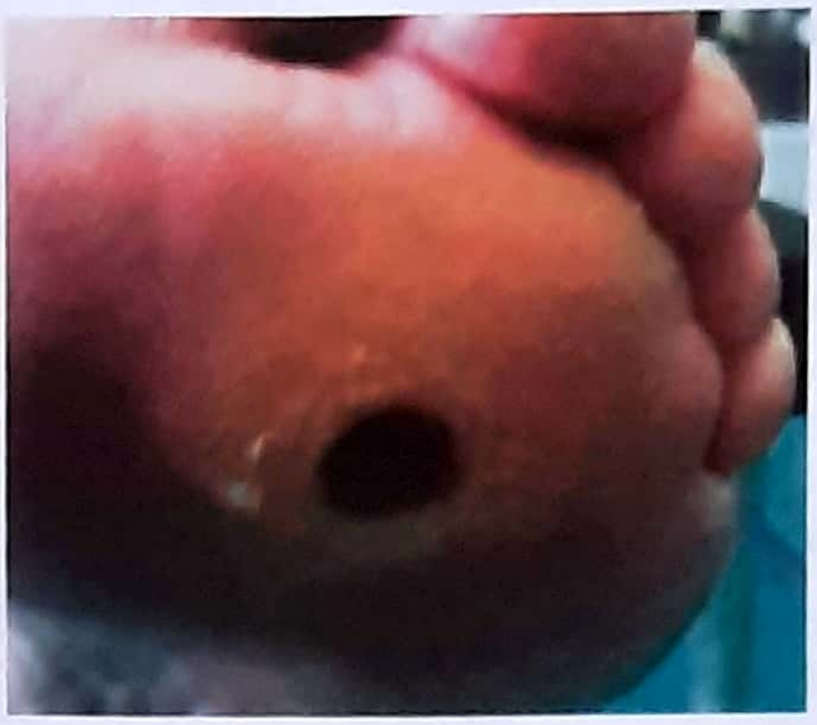

Figure 7.5 (b) : Trophic ulcer

(f) Miscellaneous ulcers

Ulceration of the legs may be associated with various disease like

(i) Anemia
(ii) Polycythemia
(iii) Rheumatoid arthritis
(iv) Leukemia
(v) Ulcerative colitis
(vi) Chronic lymphedema
(vii) Diabetes.
(viii) Hypertensive (Mortorells) ulcers

Figure 7.6: Tropical ulcer

I have described some common ulcers below:

Diabetic Ulcers

It develops due to diabetic neuropathy and arterial disease. Neuropathy is due to metabolic disturbance and not due to ischemia. Atherosclerotic changes of arteries are associated with microangiopathy characterized by thickening of the basement membrane of vessels and capillaries. (PGME)

- The ulcer is usually painless and occurs on the toes or heel of the foot. It is a deep, penetrating ulcer and attains chronicity due to constant reinfection.
- The edge is inflamed and slightly indurated. The floor may contain slough with seropurulent discharge and the base may be fixed to the deeper tissues. The surrounding skin is relatively healthy and pigmented.
- Muscular involvement is accompanied by loss of reflexes and deformities of limb in long standing cases. Presence of sugar in urine and high blood sugar level will confirm the diagnosis.

Benzin's Ulcer (Erythrocynoid ulcer)

It usually occurs in lower limbs especially in the calves of the adolescent girls. It is supposed to be due to localized areas of fat necrosis. It begins with symmetrical distribution or erythematous, purplish nodules on the calves which immediately break down to form an indolent ulcer.

Martorell's Ulcer (Hypertensive ulcer)

It commonly occurs in hypertensive patients. Though named as hypertensive; it is usually not associated with peripheral arterial disease such as atherosclerosis. It affects the lower limbs and appears as a localized patch of spontaneous skin necrosis. It is a progressive yet reversible lesion.

Cryopathic Ulcer

It occurs as a result of exposure to severe cold (chilblains or frostbite) which damages the vessel walls. Severe burning pain and waxy looking edema occur due to transudation in the affected part. Blisters and ulceration precede the onset of gangrene.

Delhi Boil (Oriental Sore)

It is due to infection by *Leishmania tropica*. An indurated papule appears on face or any exposed part of body and may progress to form an indolent ulcer, which heals with an ugly pigmented scar.

B. Specific Ulcers

(Please revise flow chart once again given earlier in this chapter on page 60)

1. Tuberculous ulcers

- Tuberculous ulcers are multiple painless ulcers. *The only tuberculous ulcer which is painful is a tuberculous ulcer present on tongue* (PGME).
- The tuberculous ulcer usually develops due to bursting of a cold abscess and is usually situated in the neck, axilla and groin.
- It is irregular in shape and a **typical undermined edge.** The floor is covered with pale granulation tissue with serosanguineous discharge.
- The regional lymph nodes are enlarged, non tender, firm and matted.

Lupus Vulgaris (Lupus means wolf); Lupus vulgaris is a form of tuberculosis of skin that occurs commonly in the face and hand occurring mostly in child and young adult. It begins as a single or multiple cutaneous nodule, later they may form multiple cutaneous nodule and form multiple superficial ulceration of skin. The peculiarity of this ulcer is that it heals at the centre and remains active at the periphery and thus gradually spreads like a wolf, hence named as lupus vulgaris. *Squamous cell carcinoma may occur in a lupus scar.*

2. Syphilitic ulcer

It is caused by *Treponema pallidum*. This is now a rare disease and I have not discussed the disease in detail as it is very unlikely that you will get question on it. However ulcers, which are clinically seen depending on the stage of the disease are listed below:

1st stage : Hard (Hunterian) chancre

2nd stage : Mucous patch and condylomata

3rd stage: Gummatous ulcer (typical punched out edges)

3. Soft Sore (Chancroid)

It usually occurs on the genitalia with in 3-5 days following exposure to *Hemophilus ducreyi.*

- Patient usually presents with multiple painful ulcers on the genitalia.
- On examination, margin is undermined and edges are ***Ulcer, sinus and fistula*** edematous. Floor shows typical yellow slough and purulent discharge. It bleeds easily on touch.
- The regional lymph nodes are palpable, hard & tender. Suppuration may follow; leading to formation of an inguinal soft swelling known as 'BUBO'.

C. Malignant Ulcer

The malignant ulcers are of following types :

1. Squamous cell carcinoma (including Marjolins ulcer)
2. Basal cell carcinoma (Rodent ulcer)
3. Malignant melanoma

These have been discussed in detail else where in this book.

Treatment of Ulcer

A. Conservative

1. Elevation of limb at rest.
2. Daily cleaning and dressing with antibiotic ointment or EUSOL*.
3. Antibiotic therapy with appropriate antibiotics.
4. Treatment of underlying cause eg; Tuberculosis, Syphilis, Diabetes etc.
5. Control of blood sugar in case of diabetic ulcer.
6. Removal of foreign body, if present in ulcer.

EUSOL - **E**dinberg **U**niversity **SOL**ution. It is formed by dissolving 12.5 grams of Boric acid and 12.5 grams of bleaching powder in 1 litre of lukewarm water.

Figure 7.7 : Typical appearance of the malignant transformation of a long-standing chronic wound.

B. Surgical

- Debridement* of all dead and necrotic tissue.
- Subfacial ligation of Dodd and cockett for varicose ulcer and Skin grafting.

Debridement is surgical removal of all dead and necrotic tissue with the help if scissors, blade and forceps.

****

DIFFERENTIAL DIAGNOSIS OF LEG ULCER

This is a important topic, you can get a short case in your final year professional examination.

1. Traumatic ulcer
2. Venous ulcer (M/C cause of chronic leg ulcer)
3. Arterial ulcers
4. Marjolin's ulcer
5. Tubercular ulcer
6. Trophic ulcer
7. Diabetic ulcer
8. Rare causes of ulcer: Ulceration of leg may be associated with various disease like.

(i) Anemia (ii) Polycythemia (iii) Rheumatoid arthritis (iv) Leukemia (v) Ulcerative colitis

Figure 7.8: Note : healing of ulcer over a period of time

****

SINUS

A sinus is a ***tract*** lined with granulation tissue, ***connecting an abnormal cavity to an epithelial surface.*** The cavity usually commences as an abscess in which the normal healing process is impaired. The granulation may be exuberant and protrude through the opening. A number of factors can lead to delayed healing and sinus formation.

These include:

- In adequately drained abscess
- Chronic inflammatory condition eg; tuberculosis, syphilis, leprosy.
- Foreign body in an abscess cavity.
- A sinus can give symptoms through recurrent discharge and recurrent bouts of acute infection of abscess cavity.
- A sinus is likely to persist until removal of causative factors.
- Malignant disease in a cavity wall can prevent healing and precipitate sinus formation.
- A sinus can give symptoms through recurrent discharge and recurrent bouts of acute infection of the abscess cavity; they are likely to persist until removal of the causative factors listed above.

****

FISTULA

A fistula is an abnormal tract between two epithelial surfaces. It is usually produced when an abscess cavity breaks into two adjacent epithelial surfaces; the etiological factors that prevent the closure of the tract and normal healing include those listed under sinus formation. Examples are; fistulae between adjacent loops of the gut in Crohn's disease and between the gut and the bladder in diverticulitis or malignant disease of either of the organs.

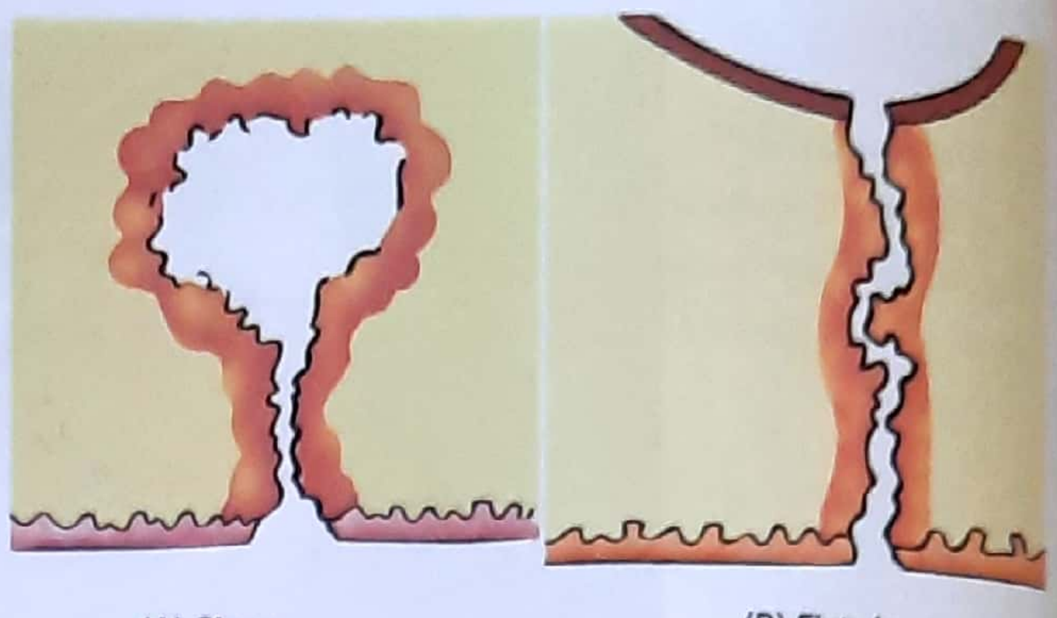

(A) Sinus (B) Fistula

Figure 7.9: Sinus & fistula

Perianal abscesses may communicate with the rectum and the anal canal and called as fistula-in ano, in these cases, inadequate surgical drainage produces a fistula that may persist with continued discharge. Foul smelling pus suggests fecal organisms and the likely presence of a fistulous connection. Diseased gut may perforate and 'discharge it's contents on to the abdominal wall (fecal fistula). There may be foul smelling discharge and the presence of gas bubbles is confirmation of the alimentary connection.

Tracheobronchial fistulae are usually congenital anomalies presenting soon after birth; but may follow malignant invasion of the adjacent organs in later life. Please see figure 7.9.

****

Sample Questions for Prof Examination

1. Write short notes on Trophic Ulcer.
2. Give the differential diagnosis of chronic ulcer of leg.

8 Principle of Laparoscopic Surgery

Contents

- Introduction
- Instruments
- Diagnostic Laparoscopy
- Technique
- Steps in Laparoscopy

INTRODUCTION

Surgery owes a tremendous debt to instrument manufactures and industry from the rod lens telescope invented by Herald Hopkins and first introduced by Karl Storz. **Laparoscopic cholecystectomy was first performed in France by Philip Mouret in** 1987 *(PGME)*.

Laparoscopic surgery is ideally a harmonious blend of advanced videoscopic technology, carefully planned with precisely engineered instruments and the skills of the surgeon.

Far less pain, far less medication, far shorter hospitalization, early return to family and work, better cosmosis, less complication are ample reasons to make laparoscopic surgery strongly patient generated.

Last three decades have gripped the interest and fired the imagination of the surgical community greatly for the laparoscopic technique. Laparoscopic cholecystectomy may well be the spring board for new endeavors in minimal invasive and minimal access surgery.

It is imperative for surgeons in developing countries to evaluate laparoscopic procedures and decide which of them gives real benefit to their patients as compared to the open procedure in terms of safety, efficacy, applicability and cost effectiveness: in other words to decide what is truly beneficial surgery for the patient.

****

INSTRUMENTS

Light Source

Laparoscopic surgery, requires higher intensity of light from a ***Xenon*** light source.

Video Camera

Video Cameras are of two types:

(i) Single chip, and

(ii) Three chip.

The single chip camera gives a resolution of 450 lines, while a three chip cameras give the resolution of about 700 lines.

Monitor

If a three chip camera is used it requires a monitor with at least 700 line resolution.

Laparoscope

Laparoscope is an endoscope to permit visualization of abdominal cavity. Laparoscopes come in three sizes: 10 mm, 7mm and 5 mm. Telescope's tips fog in peritoneal cavity due to temperature differences between outside and inside the patient. This is further aggravated by the cold CO_2 used for creating pneumoperitoneum. To avoid this, warming of the telescope in warm water, before use should be done.

Instruments for Exposure and Manipulation

Insufflator

Laparoscopic surgery demands uniform abdominal distension; maintained at certain preset safe limits of intra-abdominal pressure (12-14 mm Hg). Electronically controlled insufflators are available which are capable of delivering flow rates of at 6 liters/minute, **CO_2 is the gas in common use due to its advantage of being readily available,** (NEET) and it's capacity to rapidly dissolve in the blood system, minimizing the risk of gas embolism.

The electronic insufflator has a digital display which continuously monitors :-

1. Pressure at the tip of the Veress needle during insufflation.
2. The flow rate of CO_2 in liters/minute.
3. The volume of gas insufflated.
4. The intra-abdominal pressure.

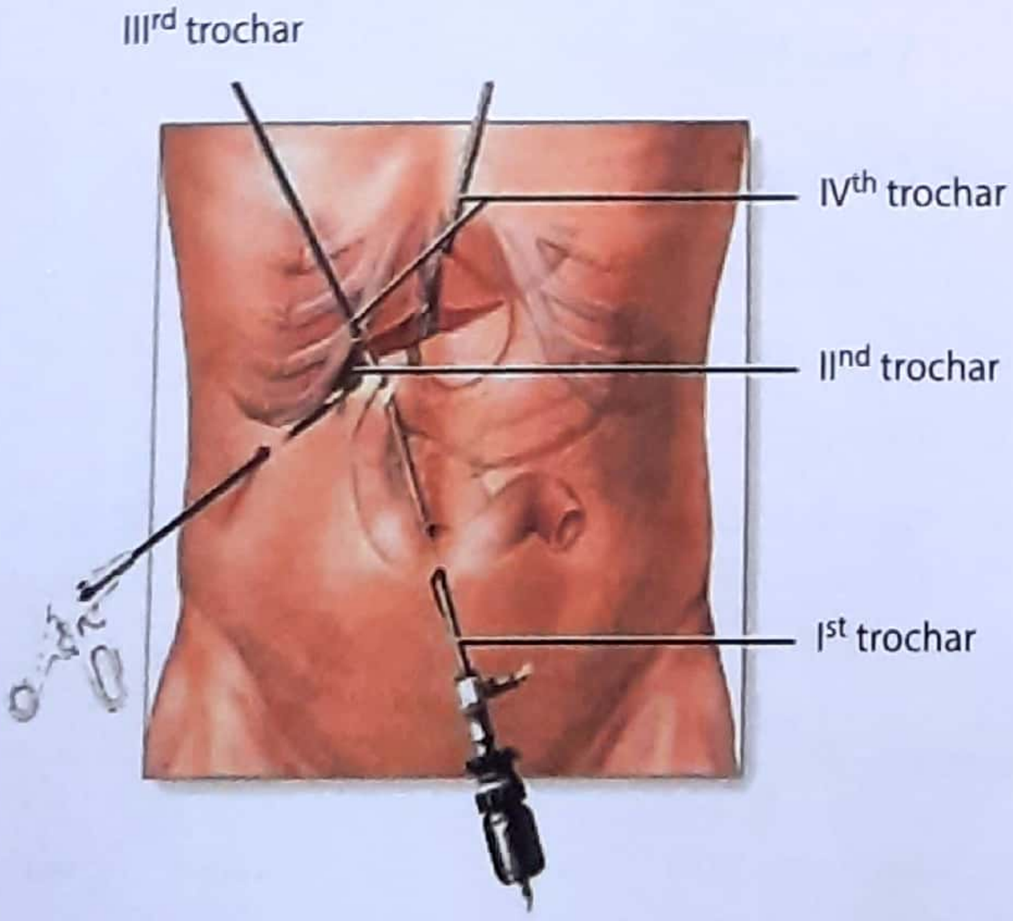

Figure 8.1: Laparoscopic cholecysectomy

The insufflator also has a adjustment, which controls and maintains the maximum intraabdominal pressure at a preset level, which is kept at around 12 mm Hg. Any inadvertent rise of intraabdominal pressure triggers a visual and audio alarm.

Puncture Instruments

1. The **Verres needle** is used to create the pneumoperitoneum. This needle has a spring loaded safety mechanism, whereby; an obturator projects beyond the sharp tip avoiding injury to intraperitoneal structures. Insufflation through the Verres needle should commence only after the correct placement of the tip in the free peritoneal cavity has been established.
2. **Trocars:** It is for introduction of the telescope and instruments and are of two sizes:
   (i) 11 mm trocars for the 10 mm instruments, and
   (ii) 5.5 mm trocars for the 5 mm instruments. The trocar consists of metal tube with a sharp conical tipped or pyramidal tipped obturator.

The outer end of the trocar has a gasket or "washer" which tightly grips any instrument passing through the trocar to minimize gas leak. All trocars have stopcocks through which CO_2 can be insufflated or evacuated.

Frequently a 5 mm instrument needs to be inserted through a 10 mm trocar. This can be done by inserting a "reducer" tube of 10 mm outer diameter, whose external end has a gasket of "washer" which fits the 5 mm instrument snugly, preventing gas escape.

Hasson Cannula

The Hasson cannula is specifically designed for use in the open technique. Depending on the thickness of the abdominal wall, the conical flange can be moved on the cannula. Tie holders on either side of the cannula keep the Hasson cannula firmly fixed to the abdominal wall.

Hand Instruments

Grasping and dissecting Instruments

Grasping and dissecting instruments can be flat, round-tipped, atraumatic for grasping, Curved fine tipped graspers are useful for dissecting tubular structures. Flat rounded graspers with teeth are of use in grasping and retracting thick walled structures or extracting the gallbladder or appendix from the abdomen.

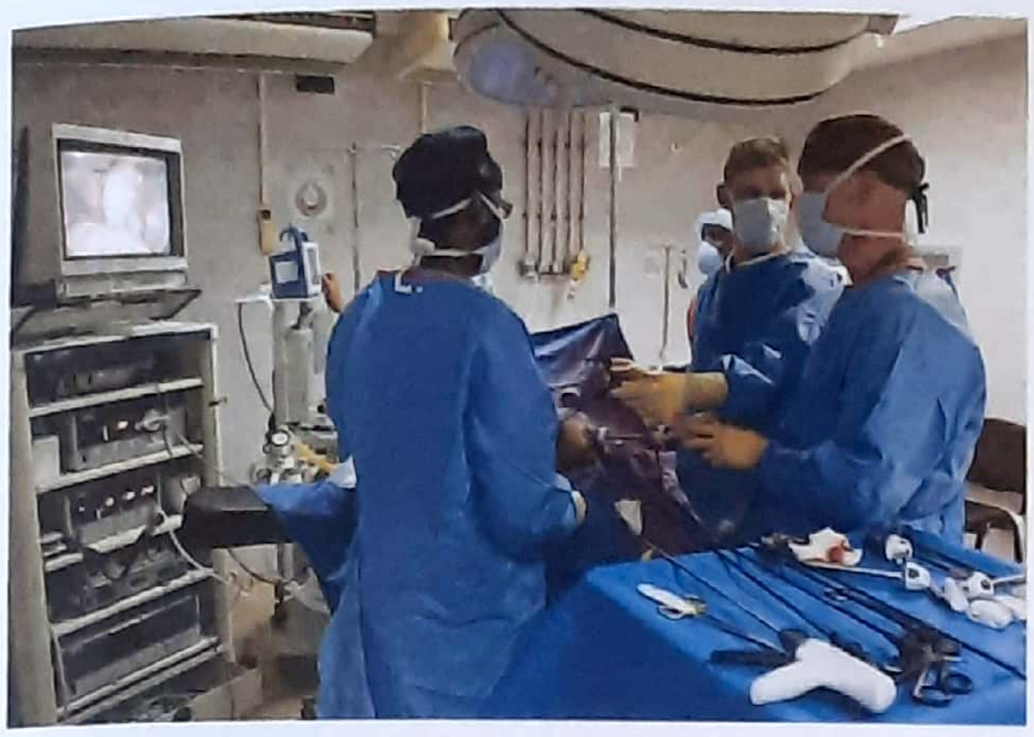

Figure 8.2: Laparoscopic cholecystectomy

A hook dissector helps to skeletonize tubular structures and also move them to permit clear vision, below and behind the structures. The diathermy hook dissector and diathermy spatula dissector are useful dissectors.

Retractors

The probe makes and adequate and safe retractor for most structures.

Scissors

Curved scissor come in 5 and 10 mm sizes. The 5 mm size gives more precision in the fine dissection and dividing.

Instruments for Occlusion. Ligation and Suturing Occlusion Clip-Applicators

Clip applicators come in three sizes; medium, medium large and large. The medium clip is ideal for thin structures like the cystic artery, the medium large for structures up to 5 mm in size like cystic duct.

Ligating Instruments

Extracorporeal knotting for ligatures can be done by a Roeder slip knot or by sliding multiple slip knots with pusher. Intracorporeal suturing and knotting requires Szabo-Berci needle driver set.

Maintaining Equipment

All hand instruments are immersed for 10 minutes in Povidone-iodine and H_2O_2 solution. The cleansing agent is washed with water and all the cleansed instruments are then immersed in Glutaraldehyde (Cidex) for 30 minutes.

Sterilization

All metal instruments are autoclaved, and all hand instruments and optical instruments are gas sterilized.

****

DIAGNOSTIC LAPAROSCOPY (DL)

Diagnostic laparoscopy allows perfect visual examination of the peritoneal cavity and further makes possible histological diagnosis of target biopsy under vision. Diagnostic laparoscopy must always be a sequel to careful clinical and laboratory examination and its greatest value in a diagnostic problem is in judicious conjunction with other diagnostic aids. Diagnostic laparoscopy is an invaluable help to surgeons in planning surgery or avoiding surgery after a complete diagnosis has been established.

Normal intra abdominal during laproscopy is set between 10-15 mmHg (8-12 mmHg in children).

Objectives of Diagnostic Laparoscopy

Diagnostic laparoscopy in the current era of minimal invasive surgery serves three essential purposes.

1. It is a valuable diagnostic aid for abdominal pathology, with diagnosis firmly established on biopsy.
2. It is an incomparable training modality. Diagnostic laparoscopy involves various steps like; creation of pneumoperitoneum and insertion of trocars, biopsies with the punch forceps and needles, adhesionolysis etc.
3. Acute abdomen is a very important indication for diagnostic laparoscopy for surgeons who routinely perform laparoscopic surgery. Diagnostic laparoscopy in acute abdomen is always done under general anesthesia, and in many situations diagnostic laparoscopy can be converted as therapeutic laparoscopic surgery.

Contraindication to Diagnostic Laparoscopy

Severe cardiac or respiratory insufficiency and large diaphragmatic hernias make the procedure dangerous due to raised intraperitoneal pressure by creation of pneumoperitoneum during diagnostic laparoscopy. Previous surgery, obesity, adhesions make the procedure much more difficult, but are not absolute contraindication.

Coagulopathy is an absolute contraindication to laproscopy.

****

TECHNIQUE OF DIAGNOSTIC LAPAROSCOPY

There are two types of laparoscopy:

(i) Single puncture, and

(ii) The double puncture instrument. The single puncture instrument has a diameter of 11 mm. Visualization, gas insufflation and translaparoscopic procedures are all carried out through the same cannula. The double puncture instrument has a main cannula of 5 or 7mm diameter for visualization and for insufflation, and a second cannula of 3 or 5mm diameter for instrumentation. We at all times used the double puncture instrument because:

1. The narrower 5 or 7 mm cannula of the double puncture instrument has a shorter trocar, making injury to intra-abdominal structures during introduction less likely.
2. Ascitic leak, omental prolapse, incisional hernia are unlikely after the use of the narrower cannula.
3. The second puncture is made safely under laparoscopic vision and can be suitably sited depending on the intra-abdominal pathology, as seen through the laparoscope, introduced through first cannula.
4. The double puncture provides a better sense of depth and distance, permits use of both hands and greatly increases versatility of translaparoscopic procedures.
5. Moving and palpating organs with a probe, biopsies under vision, suction, coagulation of bleeding areas, aspiration of cysts and abscesses done through the double puncture instrument make it eminently suitable for surgical practice.

Anesthesia

Local anesthesia is safer, faster and more suitable for diagnostic laparoscopy. Local anesthesia permits examination in high risk cases. A conscious and cooperative patient greatly facilitates the examination. All laparoscopies in children and for the traumatic or acute abdomen are done under general anesthesia.

****

STEPS OF LAPAROSCOPY

1. Pneumoperitoneum (Pneumo + Peritoneum ie; air in peritoneal cavity)

The skin and subcutaneous tissue are infiltrated with 2 percent lignocaine at the left McBurney's point but the preperitoneal tissue is not infiltrated with local anesthesia. Continuing firm pressure is maintained on the needle while the patient is asked to cough. The tip of the Veress needle is placed correctly in the free peritoneal cavity must be very carefully confirmed. It should be established that the tip of the Veress needle is in the free peritoneal cavity by:

(i) Unrestricted movement through 360°,

(ii) Injecting saline without resistance and failing to aspirate any return

(iii) When pneumoperitoneum is being established, it can be confirmed by resonant percussion note, confirming a generalized pneumoperitoneum. The purpose of creating the pneumoperitoneum is:

(a) To ensure that the main trocar puncture can be carried out with safety in an air cushion, which separates the anterior abdominal wall from the abdominal viscera, and

(b) To provide a medium in which the examination of the peritoneal viscera can be carried out.

2. Main Trocar Insertion

Only after free movement of the Veress needle, one confirms that an adequate pneumoperitoneum air cushion has been created then the main trocar is inserted. Trocar cannula is invariably inserted in the infraumbilical midline. Tissues are infiltrated with 2 percent lignocaine. A vertical or transverse infraumbilical incision is made with a stab knife in the skin and subcutaneous tissue.

The direction of entry is always caudal, in the midline towards the pelvis, ensuring that the trocar enters the abdominal cavity caudal to the bifurcation of the major vessels and in the area, where maximum air cushion is present. The safe entry of the trocar is confirmed by the 'hiss' sound of the escaping pneumoperitoneum. The trocar is removed leaving the trocar sheath in the peritoneal cavity. Now a telescope is introduced in abdominal cavity through trocar sheath.

Open Trocar Entry

In patients where previous surgery or the needle probe method suggest adhesions, a vertical 1.5 cm infraumbilical incision is deepened to sheath which is incised vertically. The two sides of the divided sheath are held up with sutures. The peritoneum is picked up and carefully incised ensuring that there is no adherent bowel underneath. A Hasson cannula is inserted and fixed in place with the stay sutures on the sheath. This is certainly a far safer method in the presence of adhesions.

3. Examination

Examination begins as soon as the telescope enters the sheath. The abdomen is examined in a systematic and sequential manner. With the patient in the left lateral position, the left lobe of the liver, the diaphragm and the spleen are examined; the greater curvature of the stomach, the anterior and the inferior surfaces of the right lobe of the liver and gallbladder are seen with the patient supine.

The midabdomen, omentum, transverse colon, small bowel and parietal peritoneum are the visualized. The telescope sweeps caudal end and with appropriate left or right side tilts the small bowel, descending and ascending colon and appendix are examined. Through a window in the omentum or mesocolon the telescope could enter the lesser sac for visualization of the pancreas.

4. The Second Puncture

When the adhesions, omentum or bowel obscure the view, or where pathology (which must be biopsied) is detected, it is necessary to insert the second trocar. The second puncture is usually made at the left McBurney's point for upper or mid-abdominal pathology, and at the right McBurney's point for lower abdominal pathology, the Veress needle skin incision is enlarged to permit entry of the 3 mm or 5mm trocar & the second puncture is made under laparoscopic guidance. Through the second cannula various endoscopic procedures can be carried out.

5. Exit

At the end of the laparoscopic procedure, it is necessary to ensure that there is no intraperitoneal or retroperitoneal bleeding, and then to remove all the gas from the peritoneal cavity, after which the cannula is slowly withdrawn. The two skin incisions are sutured.

Complication of Diagnostic Laparoscopy

(Discussed here; step by step)

1. Insertion of (verres needle)/Creation of pneumoperitoneum

malpositioning of tip of needle	Consequence
a. Pre-peritoneum	Emphysema
b. Hollow viscus	Perforation/distension
c. Localized adhesion	Localized-pneumoperitoneum
d. Omentum	Omental emphysema
e. Blood vessel	Bleeding, air embolism

Figure 8.3: Lap. cholecystectomy Vs open cholecystectomy

2. Pneumoperitoneum

(a) Cardiorespiratory embarrassment due to elevation of diaphragm, compression of inferior vena cava, hypercarbia.

(b) Air embolism, if needle is wrongly placed, in blood vessel

3. Main trocar insertion

(a) Hollow viscus perforation (stomach, bowel, bladder)

(b) Solid viscus injury (liver/spleen)

(c) Blood vessel injury (in abdominal wall, epigastric vessels, in peritoneal cavity mesenteric vessels, in retroperitoneum - aorta vena cava, iliac vessels).

4. Examination: Injury with telescope

5. Transperitoneoscopic procedures

(a) Bleeding after biopsy

(b) Biliary leak

(c) Bleeding/perforation while breaking adhesions.

6. Release of pneumoperitoneum

Pain if large volume of gas left behind.

Shoulder tip pain due to subdiaphragmatic migration of gas treated by oral PCM for 2-3 days.

Value Of Diagnostic Laparoscopy

The value of diagnostic laparoscopy in clinical surgery is summarized below.

- **Elective**
  - Hepatomegaly
  - Ascites
  - Abdominal Tuberculosis
  - Abdominal mass
  - Chronic abdominal pain
- **Emergency**
  - Traumatic abdomen
  - Acute abdomen

Diagnostic Laparoscopy and The Liver

The laparoscope has always been considered the "mirror image of the liver" and is of great value in three aspects of liver pathology.

1. Hepatomegaly
2. Malignancy
3. Cirrhosis and Portal hypertension

1. Hepatomegaly

Where hepatomegaly is clinically present, a visual and histological diagnosis is final and unequivocal. While cirrhosis and malignancy constitute the major cause of hepatomegaly an appreciable number is caused by abscesses, hydatid cysts, tuberculoma. Failure rate of laparoscopy in hepatomegaly is 4-5%.

Laparoscopy avoids unnecessary surgery in advanced malignancy, and in several disease processes. In addition to liver examination, the laparoscope also permits evaluation of related pathology in hepatomegaly, for example, disseminated malignancy or to look for the primary site in liver metastasis.

2. Malignancy

The most vital role of laparoscopy in malignancy is to avoid unnecessary surgery in disseminated disease. Perhaps the happiest role of the laparoscopy is in patients diagnosed as suffering from malignancy, when the laparoscope histologically excludes the diagnosis of malignancy made clinically or by non-invasive diagnostic aids.

Primary intra-abdominal tumours: In view which tumours of the gastrointestinal tract metastasize or invade adjacent viscera, laparoscopy can help to avoid unnecessary laparotomy in many cases. It is useful for tumours of the liver gallbladder, stomach, large intestine and pancreas.

Primary extra-abdominal tumours: Cancer of breast, lung, esophagus have a marked tendency to metastasize to the abdominal organs; particularly to the liver. All these tumours are often treated by radical surgery, surgery for the primary lesion does not involve a laparotomy. Laparoscopy is of value; because 90% of all liver metastases are on the surface and readily visible on laparoscopy.

Role of laparoscopy in systemic tumours: An exact idea of spread to the abdomen is an essential part of the staging and management of all lymphomas.

2. Abdominal Tuberculosis

Radiological examination is of no definitive diagnostic aid in these cases and ultimately the diagnosis is on exploration or laparoscopy. Abdominal .tuberculosis is a medical condition and surgery is indicated essentially as a result

of delayed diagnosis eg; strictures, adhesions or caseation, making surgery mandatory. When surgery is indicated, the mode of surgery employed today is conservative. If possible a "stricturoplasty" is greatly facilitated by previous antituberculosis therapy for a few weeks, which reduces the friability of the bowel adjacent to the stricture, permitting safe, one-layer suturing of bowel at the site of the stricture. Laparoscopy provides a "preview" of abdominal pathology, enabling specific preoperative treatment.

On visual examination at laparoscopy, tuberculosis can some time mimic malignancy, and the diagnosis has to be confirmed on biopsy.

3. Emergency Laparoscopy

The examination is always done by an experienced laparos-copist under general anesthesia and with full operation to carry on, as a formal laparotomy or operative laparoscopy as indicated.

4. Abdominal Trauma

Laparoscopy has made very little impact in the management of abdominal trauma. Superficial liver laceration constitute over 50 percent of all liver injuries and stop bleeding spontaneously, requiring no treatment.

Most significant value is in cases of multiple injuries associated with hip and pelvic fractures, since a retroperitoneal hematoma can mimic intraperitoneal injury, avoiding unnecessary surgery in these cases.

5. Acute Abdomen

Acute abdominal pain constitute one of the commonest surgical emergencies. The main value of laparoscopy is in lower abdominal and pelvic pain in female patients to exclude gynecological causes, the most important of which is the early detection of a ectopic pregnancy or to confirm acute appendicitis, when the diagnostic procedure continues as therapeutic laparoscopic surgery.

Advantages of Minimal Access Surgery & Limitation

Advantages of minimal access surgery	Limitation of minimal access surgery
• Decrease in wound size • Reduction in wound infection, dehiscence, bleeding, herniation and nerve entrapment • Decrease in wound pain • Improved mobility • Decreased wound trauma • Decreased heat loss • Improved vision	• Reliance on remote vision and operating • Loss of tactile feedback • Dependence on hand-eye coordination • Difficulty with haemostasis • Reliane on new techniques • Extraction of large specimens

****

9 Burn and Post Burn Contracture

Contents

- Pathophysiology
- Depth of burn
- Extent of burn
- Burn severity
- Management of a burn patient
- Electric burn
- Post-burn contracture
- Chemical burn (Acid & Alkali Burn)

Burn classifications

Causes of Injury

Flame-damage from superheated oxidized air by convection and radiation

Scald-damage from contact with hot liquids

Contact-damage from contact with hot or cold solids

Chemical-contact with noxious chemicals

Electrical-conduction of electrical current through tissues

Depth of Injury

Superficial-injury confined to the epidermis

Superficial partial-thickness-injury to the epidermis and papillary dermis

Deep partial-thickness-injury to the epidermis and reticular dermis

Full-thickness- injury extending through the epidermis and dermis into subcutaneous fat

A human burn is a **coagulative destruction** of the surface layers of the body. The majority of burns are caused by dry heat, while scald burns are produced by moist heat, eg; hot liquids or stream. Electrical burn occurs at the point of the entry and exit of the current. Chemical burns are caused by acids and alkalies.

An electric burn causes minimal destruction of skin but more damage to deeper tissues.

****

PATHOPHYSIOLOGY OF BURN

Epidermis is outer most layer of skin and is constantly replaced from the basal layer. The dermis is the underlying layer and is richly supplied by blood vessels. It has adnexal structures ie; hair follicles, sebaceous glands and sweat glands.

The adnexal structures contain epithelial cells, that can proliferate and heal a partial thickness wound by epithelization. The skin is one of the most vascular tissue in the body. The small vessels dilate due to direct burn injury to vessel wall, and liberate local histamine and produces vasodilatation. There also occurs increased permeability through the injured vessels, so that there is a continuous leakage of plasma; rich in low molecular weight protein and leads to hypovolemic shock. The **volume loss is greatest in the first eight hours.**

Zones of Injury in Burns

1. Zone of coagulation—Centres of wound— most severe injury inversible damage—Necrosis.

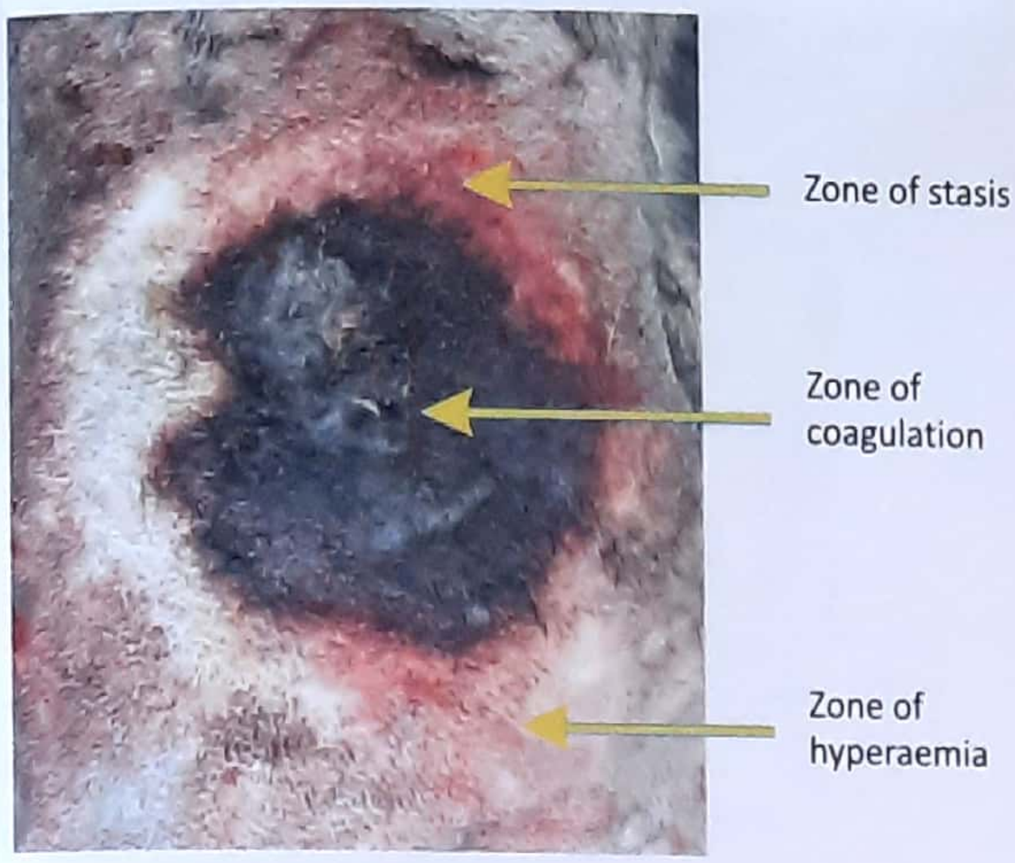

Figure 9.1 (a) : Pathophysiology of burn

2. Zone of Stasis–Ischemic but salvagable–vascular damage and leakage–can survive if infection is prevented.
3. Zone of hyperemia–minimal Cell injury–Vasodilation healing process begins here.

Because of the loss of electrolyte and protein from the circulation into extravascular compartment, the osmotic gradient is altered, and further increases the loss of fluid from the intravascular compartment.

- The hypovolemia causes splanchnic vasoconstriction and this contributes to the paralytic ileus. Acute gastric dilatation may also occur. Acute gastric erosion or ulcer may cause bleeding and gastric wall perforation.
- *Stress ulcers (curling ulcer) are seen in stomach of burn patient, and are thought due to decrease in mucosal defence (and not due to increased HCl).* (PGI 2000)
- *As with other major injuries, there occurs increased secretions of catecholamines, cortisol, glucagon, ADH and aldosterone.* (PGME)
- A profound hypermetabolism occurs in the post burn period, with raised basal metabolic rate (BMR).
- The persistently elevated levels of catecholamines an exaggerated degree of gluconeogenesis and protein break down, leading to protein catabolism, glucose intolerance (hyperglycemia) and marked total body weight loss.
- Burn causes global depression in immune function. There is depressed cellular function in all parts of the immune system, including activation and function of neutrophils, macrophages, T & B lymphocytes. Thus a burn patients are at great risk for a number of infection.

****

SYSTEMIC EFFECTS OF A SEVERE BURN

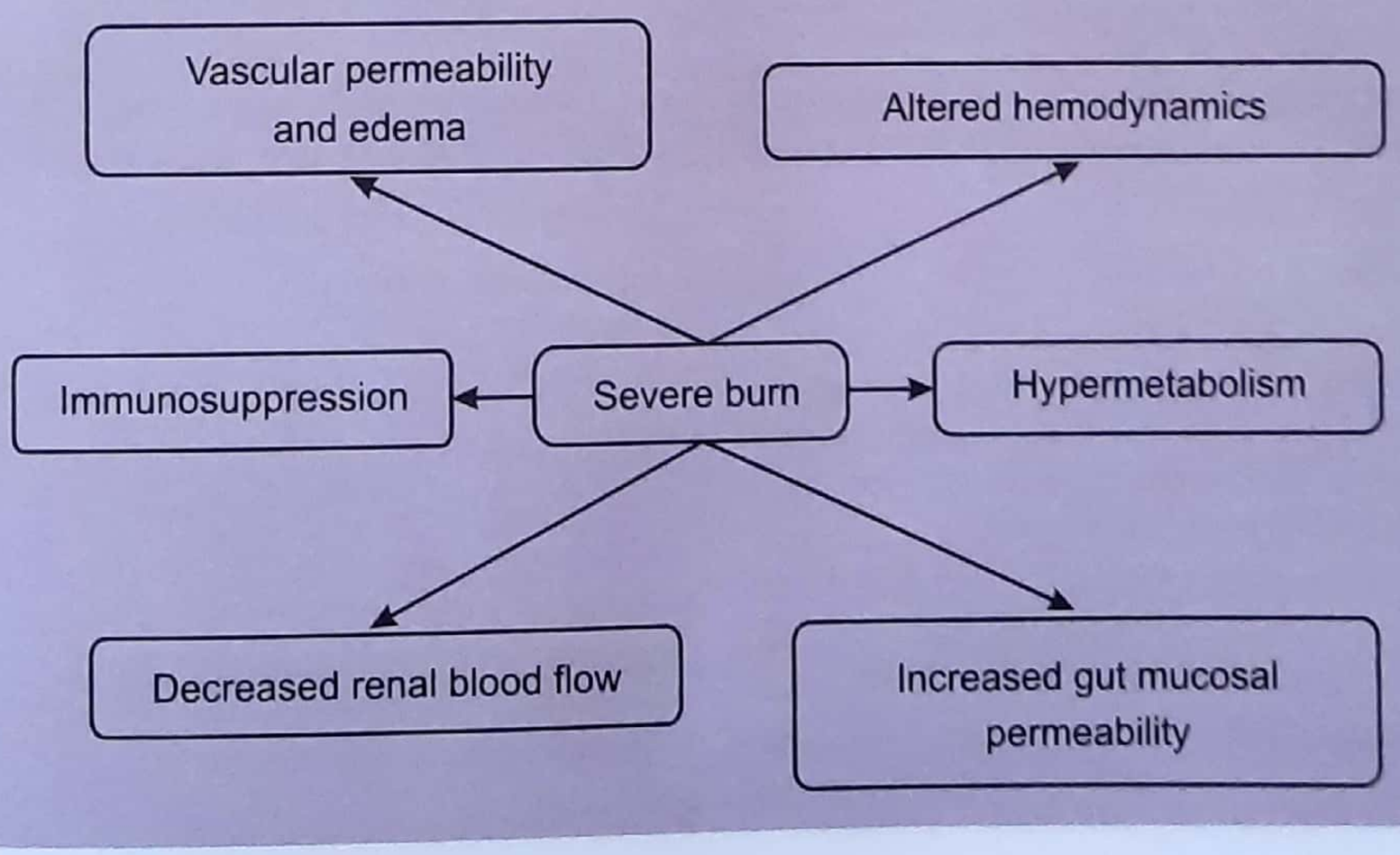

DEPTH OF BURN

Superficial or First Degree Burn

The superficial or first degree burn involves only the epidermis and is characterized by erythema (redness). Pain is the chief symptom and usually resolves in 2-3 days. Healing takes place uneventfully *without scarring*.

Second Degree Burn (Partial Thickness Burn)

Second degree burn is divided into:-

1. Superficial partial thickness
2. Deep partial thickness

The *Superficial partial thickness burn* is characterized by *blister formation. Since the deeper layers of the skin are not destroyed, regeneration is prompt, and these burn heal in 12-15 days; if infection does not occur.

The *Deep partial thickness bum* is more severe and extends into the reticular layers of the dermis, but entire dermis is not involved. Blister formation may take place and wound surface is usually mottled pink and white coloured. Capillary refilling is absent or occurs slowly. Pain is usually minimal or absent, but *scarring may occur when such injuries heal.* Healing takes place in 4-6 weeks. A deep partial thickness burn may get converted to a full thickness burn, if infection takes place. (Please see Key box 9.1, 9.2 & figure 9.1 (a & b) & for layers of skin; figure 13.1 on page 120)

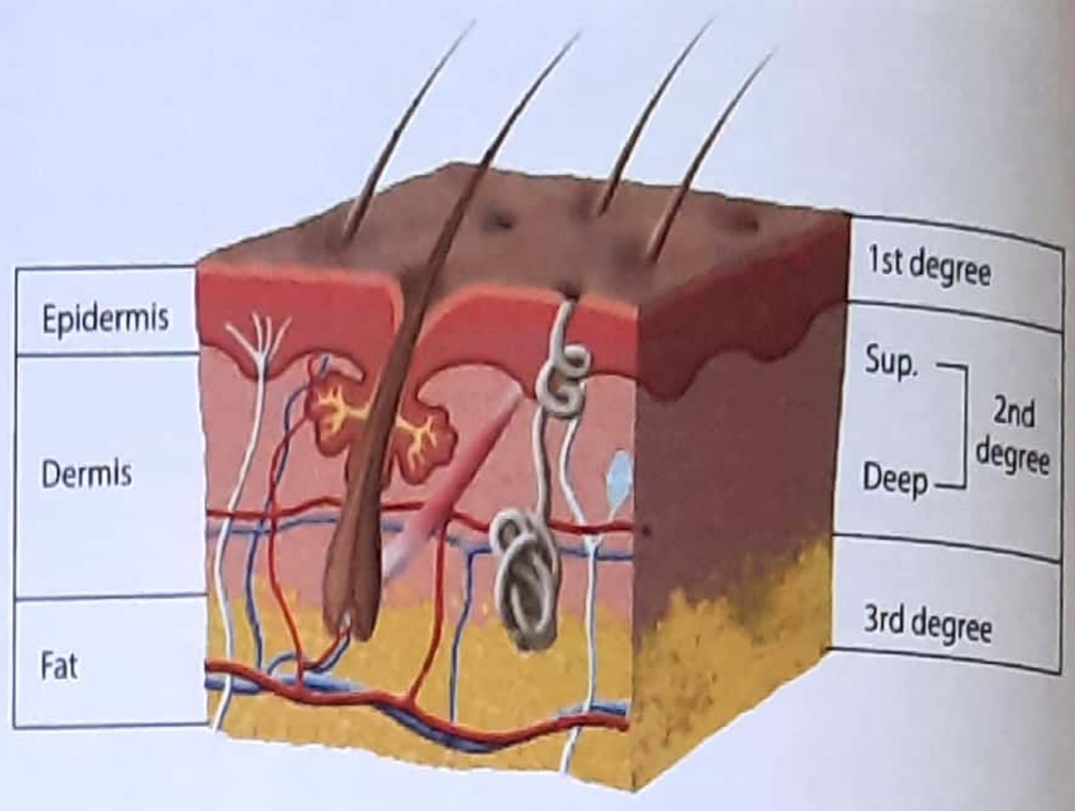

Figure 9.1 (b) : Degree of burn

NOTE: Blister is accumulation of fluid exudate in the layers of epidermis. Fluid is composed of plasma protein rich fluid and electrolyte, especially chloride *(PGME)*

Third Degree Burn (Full Thickness Burn)

A full thickness burn involves all layers of the skin (whole epidermis and dermis is involved), and is characterized by a hard, leathery eschar that is *painless* *(UP 04)* black or cherry red. There is no capillary refilling and pin-prick sensation is lost due to destruction of cutaneous nerves. A full thickness burn does not heal by itself, and an skin grafting is required.

KEY BOX 9.1

Comparison of partial and Full Thickness Burn

Partial Thickness	Full Thickness
1. Usually accidental	1. Usually homicidal or suicidal
2. Blister* formation is common *"**Blisters:** Accumulation of fluid exudate in the layers of epidermis leads to blister formation and is characteristic of partial thickness burn. The fluid is composed of plasma protein rich fluid and electrolytes (Cl^-). [Blister (for hindispeakers-phaphola)]	2. Blisters are not formed
3. Painful	3. Painless
4. Blanching on pressure present	4. Blanching on pressure absent
5. Pin - prick test positive	5. Pin prick test - negative
6. No eschar formation	6. Eschar *(burnt, block foil thickness skin)* present

KEY BOX 9.2 *(PGI Dec 07, 08)*

Degree	Depth	Features	Types of Healing
First Degree	Epidermis only	• Only erythema • Minimal tissue damage • Minimal skin edema • Usually no systemic side effect • Pain is the chief symptom	• 7-14 days • Uneventful healing
Second Degree *(NEET)* (i) Superficial dermal burn	Epidermis and part of dermis (papillary layer) *(AIIMS NOV 17)*	• **Blister formation** *(NEET)* • Very painful	• **2-3 weeks** *(NEET)* • **Usually heals with out scarring, unless infected**
(ii) Deep dermal *(PGI 93, AIIMS99)*	Epidermis, papillary dermis and part of reticular layer	• Waxy white appearance, with partial of dermis damage to hair follicles and other factors responsible for epithelial regeneration. • Minimal pain or even may be painless, liable to get infected by bacteria and become a full thickness burn	• 4-6 weeks, Usually heals with scarring
Third degree	Entire thickness of skin	• Lack of capillary refill • Leathery texture of skin *(AIIMS 93)* • Looks like parchment • All epithelial elements are destroyed • No potential for reepithelialization • Painless due to destruction of nerve endings *(UP 04)*	• No spontaneous healing, so requires skin grafting
Fourth degree	**Involves all underlying subcutaneous tissue, tendon or bone** *(NEET)*	• Variable	• No spontaneous healing • Patient usually does not survive

Fourth Degree Burn

It involves not only all the layers of the skin, but also subcutaneous fat and deeper structures, like muscles and bone.

Note: In reality, most burns are a mixture of different depths. The assessment of depth is important in planning because more superficial bums will tend to heal spontaneously; while deeper burn will require surgical intervention. It must be remembered that a burn is a dynamic wound and depth will change depending on the success of resuscitation; hence initial estimates need to be reviewed time to time.

****

EXTENT OF BURN [THE RULE OF NINE]

The palm of the patient's hand represent one percent of his own body surface area. The extent of the body surface burn involved in the adult is most commonly estimated by ***rule of nines*** *which was devised by tenison of palaski in 1949 and was later modified by WALLACE in 1951.* *(AIIMS84)*

In Adults

- Each upper extremity accounts for 9% TBS A*.
- Each lower extremity accounts for (9×2) 18% of TBSA
- Anterior trunk accounts for (9×2) 18% of TBSA
- Posterior trunk accounts for (9×2) 18% of TBSA
- **Head and neck accounts for 9% of TBSA** *(NEET, UP 04)*
- Perineum (External genitalia) account for 1% of TB SA

NOTE: TBSA-Total body surface area. See figure 9.2

This rule of nines does not apply strictly to infant and children, as their body surface area relative to body weight is much greater.

In Children (Less than 6 years)

Surface area of head is more than limbs. So ***rule of 5*** is followed in infants and young children:

Head	:	20%
Anterior aspect of trunk	:	20%
Posterior part of trunk	:	20%
Each limb	:	10% (4 × 10 = 40%)

Older Children (More than 6 years)

Head	:	15%
Lower limbs	:	2 × 15 = 30%
Upper limbs	:	2 × 10 = 20%
Posterior trunk	:	15%
Anterior trunk	:	20%

The modified *lund and browder chart* provides fair help for calculating burn percentage. The percentage of burn is depicted against each area in different age group. Please see key box 9.3, next page.

It is most accurate method.

Palm is approximately 1% (of total body surface area.).

****

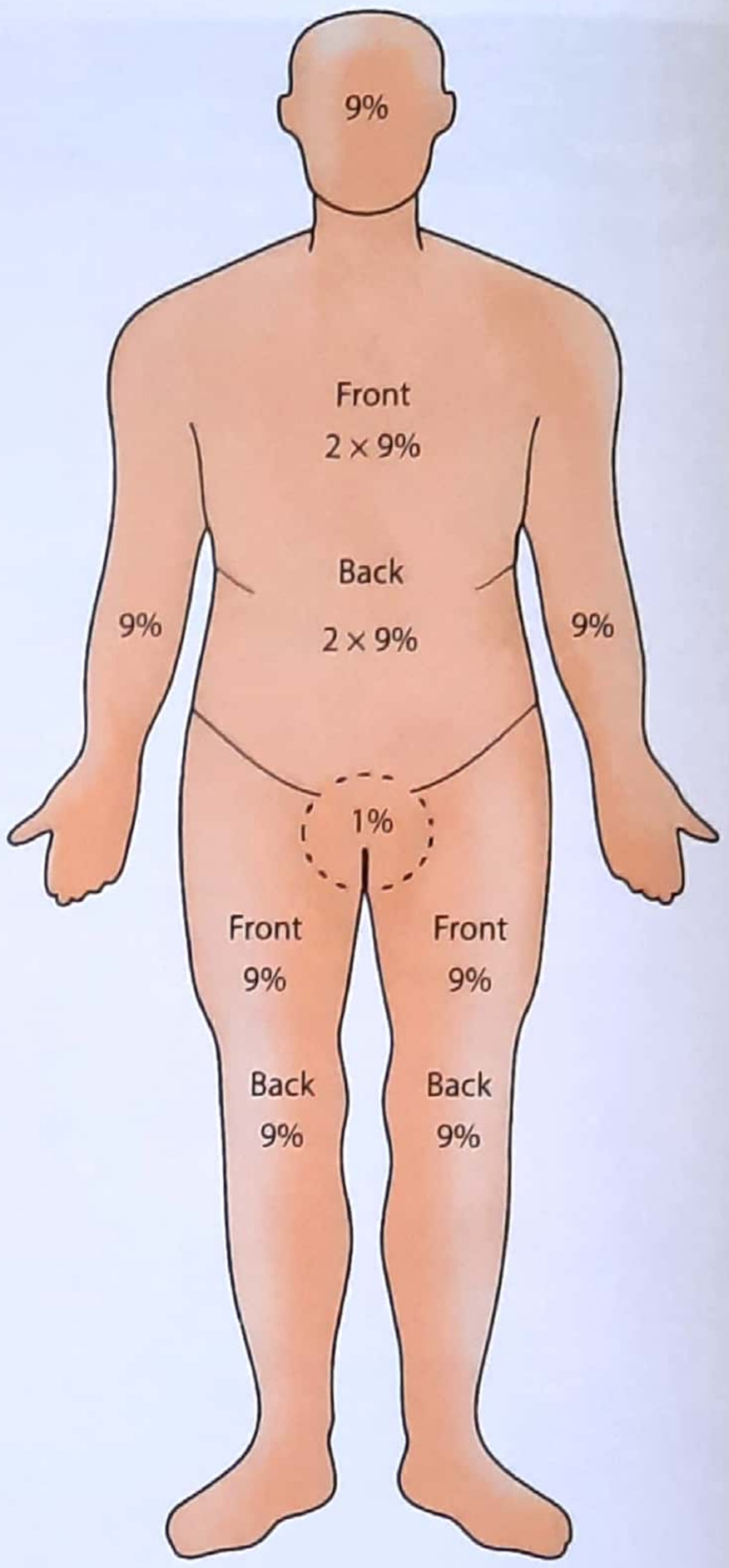

Figure 9.2: Rule of nine (See text for details)

BURN SEVERITY

The criteria for outdoor or indoor treatment are based on the severity of the burn. The following classification establishes the criteria *(IMP. POINT)*

(a) Major burn injury

- Second degree burn of >25 % body surface area in adults
- Second degree bum of >25 % body surface area in children.
- Third degree burn of > 10% body surface area.
- Most burn involving hands, face, eyes, ears, feet or perineum.
- Most patients with the following:

KEY BOX 9.3

Modified Lund-Browder chart for assessing percent total body surface area burn in children and adults

Area*	Birth to 1 year	1 to 4 years	5 to 9 years	10 to 14 years	Adult
Head	**9.5**	**8.5**	**6.5**	**5.5**	**4.5**
Neck	1	1	1	1	1
Trunk	13	13	13	13	13
Upper arm	2	2	2	2	2
Forearm	1.5	1.5	1.5	1.5	1.5
Hand	1.25	1.25	1.25	1.25	1.25
Thigh	**2.75**	**3.25**	**4**	**4.25**	**4.5**
Leg	**2.5**	**2.5**	**2.5**	**3**	**3.25**
Foot	1.75	1.75	1.75	1.75	1.75
Buttock	2.5	2.5	2.5	2.5	2.5
Genitalia	1	1	1	1	1

* Values listed are for one surface area and each individual extremity. Anterior and posterior surface area values are equivalent in estimating TBSA. For circumferential burns, multiply surface area burned by two.

- Inhalation injury
- Electrical injury
- Burn injury complicated by other major trauma
- Poor risk patients with burn

(b) Moderate uncomplicated burn injury

- Second-degree burn of 15-25% body surface area in adults
- Second-degree burn of 10-20% body surface area in children
- Third-degree burn of < 10% body surface area

(c) Minor burn injury

- Second-degree bum of <15% body surface area in adults
- Second-degree burn of <10% body surface area in children.
- Third-degree burn of < 2% body surface area.

****

MANAGEMENT OF A BURN PATIENT

The burn patient should be assessed and treated as any patient with major trauma.

Immediate Care & Resuscitation

At the scene of the injury; the first responder should remove the patient from the source of heat extinguish burning clothing, remove the patient form electrical contact without making contact with the current, dilute with large amount of water, any chemical agent causing tissue injury except phenol burns (where water accelerates the absorption, so polyethylene glycol should be used). Remove all clothing including footwear and gloves, contaminated by a chemical agent. The first priority is to ensure an adequate airway. Endotracheal intubation is indicated if the patient is semicomatose or has deep burns to the face and neck or is otherwise critically injured. Intubation should be done early in all doubtful cases, because delayed intubation will be difficult to be achieved in cases associated with laryngeal edema or upper airway injury,

and an emergency tracheostomy may then become necessary under difficult circumstances.

NOTE: *Succinylcholine should not be used as an anesthetic agent during intubation of a burn patient (PGME)*

Cardiopulmonary function must be maintained as in any other trauma patient. Early post injury cardiorespiratory arrest and the resulting need for cardiopulmonary resuscitation are uncommon in burn patient except those who have sustained high voltage electrical injury.

The application of cold water soaks at around 15° C is effective in decreasing pain in areas of second degree burn and should be used for analgesic effect, if the burns involves less than 25% of the total body surface (UPSC 02). Cold application may help reduce tissue heat content, and thus thermal injury from severe burns if applied with in 10 minutes, from time of burning, but exert little effect beyond that time. Cold soaks or ice should be used only for the length of time necessary to relieve pain, and subsequent systemic hypothermia should be avoided. Following cooling procedures, the burnt area should be covered with a clean sheet, over which a blanket should be placed to conserve heat loss. In case of an extensive burn, the patient should be transported to the speciality hospital as soon as possible. A clean sheet of cotton is used to cover the burnt patient during transportation to the hospital. A patient with a major burn, being transported to a burn center many kilometers away, a proper IV drip should be started, as timely administration of fluids would prevent hypovolemic shock.

Treatment of Minor Burns

Minor burns are generally superficial which do not exceed 10 to 15% of total body surface area, **rarely require hospitalization.** Wound should be cleaned with a mild antiseptic solution. A layer of one percent silver sulfadiazine cream is spread all over the wound. An antibiotic with better soft tissue penetration should be started.

Selection of Burn Patient for Hospitalization

The following categories of ***burns should be hospitalized and are needed to be referred to a burn unit*** *(NEET, MANY PGME)*

1. The partial or full thickness burns involving *more than* ***10 per cent of the total body surface area (BSA) in children*** *(NEET) and old people, and 15 percent in adults (PGI 04, AI91).*
2. *The burn of face, hands, feet and genitalia, which are difficult to manage at home (PGI 04).*
3. The burn associated with injury to *respiratory passage and fractures.*
4. Chronic preexisting disease, eg; diabetes, chronic obstructive pulmonary disease or deranged renal function.
5. Deep burns over joints and subcutaneous bones.
6. Electrical and Chemical burn.

NOTE: In an electrical burn, even if the skin wound is slight; damage to deeper tissues, blood vessels and muscles may later become apparent.

MANAGEMENT IN THE HOSPITAL (upon arrival)

Outcome depends on extent of burn.

Up on arrival in hospital, the patient is managed as following:

A. PATENCY OF AIRWAY

- Injury to the respiratory tract is one of the major cause of death due to burns.
- Mild bronchospasm may be relieved by IV aminophylline given slowly. If respiratory difficulty persist, it is wise to undertake endotracheal intubation prophylactically, rather than delaying until laryngeal edema makes this impossible.
- Tracheostomy should be avoided, if possible as it always imposes an increased hazard of sepsis, which may prove fatal.
- The major cause of death after burns is injury or complications in the respiratory tract. The problem includes inhalation injury, aspiration in unconscious patients, bacterial pneumonia, pulmonary embolism and post traumatic pulmonary insufficiency.
- Respiratory tract injury which predispose to other complications are divided into three categories.
  1. Direct thermal injury
  2. Carbon monoxide poisoning
  3. Inhalation injury
- **Indication of inhibation in burn patient -**
  - Persistent cough, stridor, wheezing
  - Hoarseness
  - Singed nasal loss
  - Respiratory distress, hypoxia or hyperapnea

KEY BOX 9.4

Guidelines for referral to a burn center

Partial-thickness burns greater than 10% total body surface area (TBSA)
Burns involving the face, hands, feet, genitalia, perineum, or major joints
Third-degree burns in any age group
Electrical burns, including lightning injury
Chemical burns
Inhalation injury
Burn injury in patients with complicated preexisting medical disorders
Patients with burns and concomitant trauma in which the burn is the greatest risk. If the trauma is the greater immediate risk, the patient may be stabilized in a trauma center before transfer to a burn center.
Burned children in hospitals without qualified personnel for the care of children
Burn injury in patients who will require special social, emotional, or rehabilitative intervention

- Increased CO level or CN level
- Carbonaceons sputum in mouth or nose
- Deep facial or neck burn
- Blustering or edema of oropharynix

B. INTRAVENOUS FLUID THERAPY

- It should be initiated as soon as possible after injury in all patients with burn of 15% or more. **The ideal fluid for infusion in first 24 hours is Ringer Lactate (RL)** (NEET). Fluid resuscitation should be initiated by infusing balanced salt solution through a large caliber intravenous (I/V) cannula placed in order of preference:-
  1. In a peripheral vein underlying unburned skin
  2. In a peripheral vein underlying burned would.
  3. In a central vein

RL = Hartmann solution

Calculation of IV fluid (to be given)

Fluid requirement is based on percentage of body surface burnt, which is determined by rule of nines, as discussed earlier.

PARKLAND FORMULA (PGME MANY TIME)

- Most frequently used formula for fluid calculation.
- Fluid resuscitation begins with an isotonic crystalloid solution *Ringer's lactate solution (RL) is the preferred solution* (PGME AI 91, UPPGME).

NOTE: *Normal saline should be avoided as large volumes required/or resuscitation may lead to hyperchloremic metabolic acidosis and hypernatremia.* (AIIMS 94)

- *RL is preferred solution for fluid resuscitation in a buRn patient* (MANY PGME).

(i) Fluid calculation for 1st 24 hours

- The quantity of crystalloid needed for adequate resuscitation is determined i.e; **2-4 ML/ Kg% OF TOTAL BODY SURFACE AREA BURNT** (NEET). *Half of this calculated fluid is given in first 8 hours, and half in next 16 hours depending on severity of burn.* (PGI 03)

For Example:

A patient of 60 kg with 70% burn will require: 2 ml × 60 × 70 = 8400 ml. ie; 8.4 liters of RL for first 24 hours. Of this 8.4 liters; half, i.e.; 4.2 liter should be given in first 8 hours, and other 4.2 liter over next 16 hours.

In children; fluid is required in addition, calculated by weight as:

4mL/kg for 0-10 kg + 2 mL/kg for 10-20kg + 1 mL/kg over 20 kg = rate in mL/hour. *For example* a child of 26kg will require= 10 × 4 + 10 × 2 + 6 × 1 = 66ml/h as maintenance fluid.

Please read key box - 9.5.

(ii) Fluid calculation for second 24 hours

Colloid is begun at a rate of 0.5 mL × percentage of total surface area burnt × weight and maintenance crystalloid (DNS) is continued at a rate of 1.5 mL × TBSA × weight in Kg.

Place of Oral fluid therapy

In borderline burn between 15-25%TBSA, lost fluids can be given orally. The commercial electrolyte preparations (electral) dissolved in water can be given to the burnt patient as frequently as possible. The Safdarjung hospital formula is popular: it contains 8 grams of table salt and 10 grams of sodium bicarbonate, dissolved in 1 litre of water, and sugar and lemon are added for taste.

KEY BOX 9.5			
BURN RESUSCITATION FLUID RATES AND TARGET URINE OUTPUT BY BURN TYPE AND AGE			
CATEGORY OF BURN	**AGE AND WEIGHT**	**ADJUSTED FLUID RATES**	**URINE OUTPUT**
Flame or Scald	Adults and older children (≥14 years old)	2 ml LR x kg x % TBSA	0.5 mL/kg/hr 30-50 mL/hr
	Children (<14 years old)	3 ml LR x kg x % TBSA	1 mL/kg/hr
	Infants and young children (≤30 kg)	3 ml LR x kg x % TBSA Plus a sugar-containing solution at maintenance rate	1 mL/kg/hr
Electrical injury	All ages	4 ml LR x kg x % TBSA until urine clears	1-1.5 mL/kg/hr until urine clears
Source : ALTS - Student manual - 2018 edition			

Monitoring of fluid resuscitation

Fluids should be administered during first and second post burn days in such an amount to maintain vital .signs, *satisfactory general condition and* ***urine output of 30-50 ml/hr*** *in adults and in children less than 30 kg, it should be 1 ml/kg/hr* (KAR 04).

Anxiety and restlessness may be early signs of hypovolemia and hypoxemia (KAR 95). Sphygmomanometer reading of blood pressure are not reliable because of increasing edema.

If repeated arterial blood sampling is needed, as in inhalational injuries, arterial cannula should be placed.

Central venous pressure monitoring should be reserved for those patients, who do not respond to the usual manners of resuscitation. In these patients a *swan ganz catheter* should be placed to measure pulmonary capillary wedge pressure in order to assess myocardial function and intra-vascular volume.

The lung appears to be reasonably well protected from early edema process, and pulmonary edema is uncommon during the resuscitation period, unless there is superimposed inhalation injury.

Oliguria during the resuscitation period (first 24 hours after injury) is commonly due to inadequate resuscitation, and is almost never due to ARF, so it should be treated by increased fluid administration and not by fluid restriction or/and administration of diuretics. There are *only four categories of bum patients in whom diuretic therapy may be necessary:*

1. Those with high voltage electric injury.
2. Those with associated mechanical soft tissue injury.
3. Those with particularly deep burns involving muscles.
4. Those with extensive burn, who remain oliguric despite receiving fluid volumes in excess of estimated needs.

KEY BOX 9.6		
Formulas to predict calorie needs in severely burned children		
AGE GROUP	**MAINTENANCE NEEDS**	**BURN WOUND NEEDS**
Infants (0-12 months)	2100 kcal/% TBSA burned/24 hours	1000 kcal/% TBSA burned/24 hours
Children (1-12 years)	1800 kcal/% TBSA burned/24hours	1300 kcal/% TBSA burned/24 hours
Adolescents (12-18 years)	1500 kcal/% TBSA burned/24hours	1500 kcal/% TBSA burned/24 hours

First three categories characteristically have heavy loads of pigments (hemochromogens) in their urine and are prone to develop ARF, unless a brisk urinary output is maintained, until the pigment concentration is reduced to insignificant levels. Fluid should be infused in these patients at the rate needed to achieve an hourly urinary output of 75-100 ml, but if the patient does not respond, a diuretic should be given. One ampoule (12.5gms) of mannitol is added to each liter of I/V fluid until the desired output is achieved and pigment clears.

Recap

Friends; till now we have taken care of (A) airway and (B) fluid loss due to burn, now we will discuss, burn wound and it's care

C. CARE OF BURN WOUND

- The local problem in burn wound is infection and the patient should be kept separately in a separate burn unit.
- A partial thickness burn is an open wound because the injured surface has lost it protective covering and hence exposed to infection.
- A full thickness burn can be considered a 'closed wound' because the covering skin, although coagulated, is present and is known as "Eschar" and forms a protective covering.

1. Local wound care of a partial thickness burn wound

The basic aim of burn wound management is to prevent, or limit infection and to avoid further skin damage. Following are the guidelines of management of burn wound after controlling shock :-

1. Clean the burn and surrounding skin under aseptic condition and sedation, with normal saline; preferably cooled or chilled (to reduce the progress of tissue effects of thermal injury).
2. Keep the affected part dry, cool and elevated (to limit edema).

The ideal local condition, **to minimize infection is "dryness"** and this is achieved by one of the following **two methods:**

(a) Exposure technique

The burnt surface is *left exposed to the air of room temperature* at 60-70° F and protected by a bed cradle and covered with sterile sheets. Elevation of affected part limits edema and a crust forms in 48 to 60 hours which separates in 2 weeks in a case of partial thickness burn, and in 3-4 weeks in deep dermal burns.

Modified exposure technique

The risk of infection in cases of extensive burns treated by the conventional exposure method is fairly high, in spite of careful nursing, the crust or eschar begins to crack. To minimize this risk, the burnt wound is covered with a thin layer of silver sulfadiazine cream or povidone iodine ointment with the gloved hand. Every day, discharge and excess cream or ointment are removed with the gloved hand and the burnt surface covered freshly with antiseptic cream or ointment.

After the first few days, the patient of less than 25 % surface area burn is taken to a clean bathroom and washed with soap and warm water using a hand shower. The burnt area is dried with sterile gauze and covered with an antiseptic cream or ointment. Exposure treatment of burns is difficult, when burns are circumferential, as some part (usually back) of the burnt surface remains in contract with the bed at any given time.

(b) Closed Technique (Absorptive dressings)

A suitable absorptive evaporative dressing consists of:

1. An innermost layer of vaseline gauze with or without an antibacterial agent
2. A layer of cotton gauze
3. A layer of cotton wool, and
4. An outermost layer of bandage.

The dressing protects the burnt area from contamination. It may need to be changed on alternate days, however, it there is no visible soakage the dressing can left undisturbed until healing is likely to be complete, (which is about ten days). If soakage* occurs, gauze, wool, and bandage should be removed and replaced. If there are unhealed areas, when the dressing is removed, a further small dressing can be applied.

NOTE: *Soakage: when dressing becomes wet due to serous/ sew sanguinous discharge from wound.*

In case of hand burns, the hand is immobilized in the position of function, ie; wrist slightly extended, metacarpophalangeal joints flexed and interphalangeal joints extended. (Glass holding manner)

Topical agents for Dressing

Silver sulfadiazine *(AIIMS MAY 17)* **cream is the most commonly used surface antibiotic for burn wounds**. Other agents used are:-

- Mofenide acetate
- Silver nitrate solution
- Polymyxin B sulphate cream/powder
- Betadine solution

Please read key box 9.7.

Biological dressing

Amniotic membrane or collagen sheets are used as an alternative to topical agent for partial thickness bum. An immediate application prevent fluid loss, protect against infection and relieves pain.

2. Local wound care of a full thickness burn (deep burn)

In deep burn, a dry cover formed as a result of burnt skin itself, which covers the tissue beneath is called as Eschar*, and therefore requires no additional dressings. The Eschar remains effective for 7 to 10 days and after 14 to 16 days it separates from the underlying living tissues through a process of enzymatic digestion. It is at this stage, that infection is very likely to occur and lead to toxemia, which must be prevented at any cost.

Because the skin has been completely destroyed, healing by first intention is impossible except by surgical aid. At any time between 10 to 14 days, the Eschar is removed by excision and the wound is closed by skin grafts, if possible by autograft.

KEY BOX 9.7

Burn wound dressings

DRESSING	ADVANTAGES AND DISADVANTAGES
Salves	
Silver sulfadiazine Mafenide acetate 11%	Broad-spectrum, painful daily dressing changes, does not penetrate eschar, inhibition of epithelialization. Broad-spectrum, penetrates eschar, painful application to partial-thickness burns, painful daily dressing changes, potential for metabolic acidosis, inhibition of epithelialization.
Bacitracin Neomycin Bactroban Polymyxin B Nystatin	Gram-positive coverage, painful daily dressing changes Gram-positive coverage, painful daily dressing changes Gram-positive coverage, painful daily dressing changes Gram-negative coverage, painful daily dressing changes Fungal coverage, connot be used in combination with mafenide acetate
Solutions	
Silver nitrate 0.5% 5% Mafenide acetate	Effective against all microbes, stains contacted areas, associated with methemoglobinemia. Broad-spectrum, penetrates eschar, painful application to partial-thickness burns, painful daily dressing changes, potential for metabolic acidosis, inhibition of epithelialization.
Dakin's solution Domboro's solution	0.5% sodium hypochlorite with buffers, effective against all microbes, inhibits epithelialization 0.25% acetic acid with buffers, effective against most microbes particularly *Pseudomonas*, inhibits biofilm formation
Antimicrobial Dressings	
Silver containing dressings	Broad-spectrum, long-term use minimizing painful wound care, does not penetrate eschar, difficult to assess the wound

Eschar: A full thickness burn can be considered as a closed wound, because the covering skin (though burnt) is present, and forms a protective covering, this full thickness burnt skin is called as Eschar.

Burn wound excision

Surgical management of burn wound has now become much more aggressive, with operative debridement** beginning within the first few days postburn, rather than after eschar has sloughed. More rapid closure after excision of burn wound clearly decreases the rate of sepsis and in full thickness burn injuries in excess of 60% of body surface significantly decreases the death rate.

Burn wound excision should be done as soon as possible but not within the first 24 hour, because it increase anesthetic rest and operative stress associated with massive blood loss, when excisions of more than 20% of the total body surface is done as a single procedure. Other adverse effects include the susceptibility of the excised wound to infection. Because of increased fibrosis and greater chances of hypertrophic scaring associated with healing after 2nd week, a two week period can be allowed for spontaneous healing. If it is anticipated that healing will not occur within two weeks, excision is not scheduled.

Debridement: Surgical removal of dead & necrotic tissue with the help of surgical blade and scissor.

How is excision done?

Excision can be done with scalpel, electrocautery & laser. Laser does minimum blood loss, but the equipment is costly and time required for excision is longer. Skin graft take-up is similar, following use of any one of these methods. Blood loss can be reduced by topical application of gauze sponges moistened with a warm solution of thrombin with or without epinephrine or by intravenous infusion or subescharal infiltration of vasopressin. In case of a limb a tourniquet can be used to minimize blood loss.

Burn wound sepsis

Microbial factors that influence the natural history of the burn wound and the likelihood of the sepsis or systemic infection include density of organisms (invasion is uncommon unless the number of bacteria equals or exceeds 10^5 per gram of tissue) and a variety of strain specific factors. *Relatively few organisms can be recovered form burn surface immediately after burn injury, and those that are present are predominantly gram positive* (PGME).

The type and density of organisms present in the untreated burn wound change with time, so that by the *5th post burn day gram negative organisms can be recovered from 60% of the patients*. By the middle of the 2nd post burn week, the burn wound or organisms are predominantly gram negative. The most common organisms complicating the burn injury are:

- Staph aureus
- Pseudomonas
- Enterococcus specie
- Enterobacteriaceae
- Group A Streptococci
- Candida albicans & E-coli

Without topical therapy, the organisms penetrate the eschar by migration along hair follicles and sweat glands and extend down to the viable nonviable interface (subescharal space). At this site, further microbial proliferation commonly occurs and promotes lysis of denatured collagen and results in spontaneous sloughing of the eschar. In those patients with inadequate host defence capacity or those in whom topical therapy is ineffective, the subescharal organism invade the underlying unburned tissue and may spread systemically. Strain specific factors which are important include exotoxins, endotoxins and a variety of enzymes such as collagenase, protease, elastase, esterase, lipase hemolysin and nucleases. Bacterial motility and antibiotic resistance also appear to be important in the development of invasive infection.

The incidence of burn wound sepsis is related to burn depth, burn size and patient's age. Invasive infection is uncommon in second degree burns. The incidence of burn wound sepsis is low in patients with burns less than 30% and rises as burn size increase above that level. Burn wound sepsis has been most common in children, less common in elderly and least common in young adults. **At the present time, even in patients with massive burns, the cause of death is seldom burn wound sepsis, but is commonly infection (sepsis) at another site in the *body*.** (UP 04)

Following topical agents are in wide clinical use, and each has specific advantages and limitation. The agent should be used selectively to meet the individual patient's wound care needs:

1. Silver sulfadiazine
2. Mafenide acetate
3. Silver nitrate solution
4. Acticoat
5. Povidine Iodine
6. Polymyxin-B sulfate

OTHER CONSIDERATION IN BURN PATIENT CARE

1. Ryle's tube Aspiration

Kyle's tube aspiration is indicated for any patient with nausea or vomiting; for most patients with burns covering 25% or more of the BSA, because it leads to paralytic ileus.

2. Analgesia

Should be confined to conservative use of intravenous narcotics in small, frequent dose.

3. Systemic antibiotics

These are usually not indicated. However, some situations, particularly in the early treatment of patients with partial-thickness burns, prophylaxis against beta hemolytic steptococci is warranted.

4. Tetanus toxoid with or without human globulin should be give.

5. Chemical burns

(a) Alkali burns are generally deeper and more serious than acid burns.

(b) All chemical burns should be treated by flushing with neutral solutions.

(i) Immediate drenching in a shower or with a hose is helpful.

(ii) Burns of the eye require extensive flushing over an 8 hour period.

Cause of Death in burns - Shock hypothermia, sepsis, ARDS, multiple organ failure (MOF).

****

ELECTRICAL BURNS

Electric burns are usually deeper and more severe than indicated by the surface appearance. It may lead to:

(a) Muscle and soft tissue Injury

Electrical energy is converted to heat as it traverses the body along the path of least resistance (ie; blood vessels and nerves). Thus muscles closet to bone, which has a high resistance therefore, generates the most heat; incur the most damage.

(i) **Muscle Involvement** may be markedly under estimated by attention to the surface wounds alone (fluid requirements are about 50% higher than estimated by surface wounds)

1. Brawny edema is characteristic
2. Early escharotomy, fasciotomy, and debridement are often necessary and repeated explorations at 24-48 hours may be needed.

(ii) Serious soft tissue injury results from high voltage electrical burns (generally more than 1000 volts): Low voltage electrical burns (household outlets) cause less soft tissue injury but may cause asystole and apnea.

(b) Surface burns

Occur at both the entrance and exit points of the current. Unsuspected exit sites including the scalp, feet or perineum should be sought.

(c) Oliguria

Oliguria is common as is acidosis

(i) Urine output should be maintained at high levels at least 50-100 ml/hr in adults. Mannitol administration is usually needed to maintain this level and is mandatory in the presence of **myoglobinuria** (NEET) (due to destruction of muscles by electric current).

(ii) Arterial blood pH should be monitored and maintained with intravenous bicarbonate, given as 50 mEq every half hour until the pH reaches normal levels.

(d) Myocardial infarction

Immediate or delayed MI is well described post-injury, thus making continuous cardiac monitoring essential in all patient with electrical burns.

(e) Transverse myelitis and cataracts

These are long term sequelae.

(f) ARF and Hyperkalemia

At the points of electric contact, the skin is severely injured and charred. When this occurs, resistance increases sharply with limitation of further passage of current and limitation of tissue heating, if the voltage is 1000V or less. At higher voltage reduction of current flow does not occur and tissue injury continues.

When current flow stops, a deeper tissue cool more slowly than the superficial ones, hence deeper tissues

Figure 9.3: Electric Burn

are more liable to severe injury, as a consequence of these characteristics of electric injury, misleading small cutaneous lesion may overlie extensive areas of devitalized muscle, which may liberate significant quantities of myoglobin and cause ARF, if an adequate urinary output is not maintained. Fluid estimates based on the limited cutaneous injury cause under resuscitation and further predispose the patient to ARF.

Hyperkalemia may develop as a consequence of extensive tissue necrosis and require treatment based on its severity (AIIMS 94). ECG should be obtained as electric burn, may lead to cardiac dysfunction.

COMPLICATION DUE TO BURN (PGI 99.2000)

1. **Hypovolemic shock (MC cause of death in early period)** (NEET)
2. Oliguria and renal failure (due to ATN)
3. Respiratory distress syndrome
4. Multi Organ System Failure (MOSF)
5. Curling's ulcer (UP 04)
6. Ischemic enterocolitis
7. Acute Pancreatitis and Cholecystitis.
8. Psychic trauma
9. Bronchopneumonia
10. Infection and **sepsis responsible for late death due to burn** (NEET)
11. Anemia and hypoproteinemia
12. Hormone disturbance

    (Excess secretion of Adrenaline, Glucagon-leads to Pseudodiabetes)
13. Acalculous Cholecystitis
14. Marjolins Ulcer (Sq.cell carcinoma) (PGI 03)

****

POST BURN CONTRACTURE

You may get a short case on it; in final prof viva examination.

Severe contracture following burn is common in developing countries, like India, due to inadequate primary treatment. Causes of contracture following burns are as following:-

Causes

1. Full thickness burn, that has not been treated by skin grafting.
2. Dermal fibrosis, secondary to deep partial thickness burn
3. Ectropion of the eyelids and lips.
4. Prolonged malpositioning of joints, especially in the flexed position.
5. Damage of deeper structure, like muscles, fascia, tendons.

Prevention of Burn Contracture

- With advanced management of burn patients, the mortality rate has been greatly reduced, however the morbidity due to post burn deformities remains high.
- Post burn deformities can be prevented more effectively by knowing, *that the position of comfort is likely the position of contracture*. The prevention of post burn deformities begins with the early management of burn injuries. A strict program of proper joint positioning, splintage, pressure garments, and physiotherapy must be put in place as soon as possible and should be carried on until full maturation of the burn scar, in order to avoid the crippling post burn contracture.
- Every precaution must be taken to prevent infection as a partial thickness burn can get converted to full thickness, if the wound gets infected.
- All burn wounds that do not heal even after 4 weeks following burn, should be closed by skin grafting.
- Care should be taken in cases of facial burns to protect the eyes. Early intervention in the form of tarsorrhaphy and split skin grafting should be done, when required to prevent complication such as corneal ulcers and ectropion of the eyelids.

Figure 9.4: Post burn contracture of right elbow

Figure 9.5: Post burn contracture of neck

Treatment

Surgical intervention is usually necessary to correct post burn deformation. In the active phase of burn wound healing, when the scar is hypertrophic, correction may be obtained by sustained traction forces, through active and passive means, rather than by surgical intervention. Serial splinting gives good results in flexion contracture of elbows and knees.

The surgical treatment of an established contracture consists of excision of scar and skin grafting. Narrow bands of contracture should be released by Y-V plasty.

Where as large contracture are excised, the raw areas (exposed area) should be covered with skin graft. In this *thick split-skin graft are preferred to thin split-skin grafts, as the* secondary *contracture is less common with them* [AI-IMS91]. The use of 'Z' plasty is recommended in small skin bands causing linear contracture.

Read skin grafting in next chapter.

****

CHEMICAL BURNS (ACID & ALKALI BURN)

Chemical burns are injuries to the skin, eyes, mouth, or internal organs caused by contact with a corrosive substance. They may also be called caustic burns.

Types of Chemical Burns

Chemical burns are classified like other burns based on the amount of damage done:

- **Superficial or first-degree burns** only affect the outer layer of skin, called the epidermis. The area will be red and painful, but there usually is no permanent damage.
- **Partial thickness or second-degree burns** extend into the second layer of skin called the dermis. Patient may have blisters and swelling, and it may leave scars.
- **Full thickness or third-degree burns** go through the skin and may damage tissue underneath. The area may look black or white. Because nerves are destroyed, Patient may not feel pain.

Chemical Burn Causes and Risk Factors

Most chemicals that cause burns are either strong acids or bases. A glance at the medical information on the labels of dangerous chemicals confirms the expected toxicity. Common sense precautions and consumer education can reduce risk of injury. A variety of household products can cause chemical burns, including : Ammonia, Battery acid, Bleach, Concrete mix, Drain or toilet bowl cleaners, Metal cleaners, Pool chlorinators, Tooth-whitening products.

Signs and symptoms of chemical burns include the following :

- Redness, irritation, or burning at the site of contact
- Pain or numbness at the site of contact
- Formation of blisters or black dead skin at the contact site
- Vision changes if the chemical gets into your eyes
- Cough or shortness of breath

Tissue damage from chemicat burns depends on several things, including :

- The strength or concentration of the chemical
- The site of contact (eye, skin, mucous membrane)
- Whether it's swallowed or inhaled
- Whether or not skin is intact
- How much of the chemicat you came into contact with
- Duration of exposure
- How the chemical works

Treatment

First aid

- Remove yourself or the person with the burn from the accident area.
- Remove any contaminated clothing.
- Wash the injured area to dilute or remove the substance, using large volumes of water. Wash for at least 20 minutes, taking care not to allow runoff to contact unaffected parts of your body. Gently brush away any solid materials, again avoiding unaffected body surfaces.
- Especialy wash away any chemical in eye. Sometimes the best way to get large amounts of water to your eye is to step into the shower.

Medical treatment

- IV fluids may be needed to normalize blood pressure and heart rate.
- The IV access may also be used for any medications needed to treat pain or protect against infection.
- Decontamination will begin (likely water irrigation).
- Patient may be given any antidote to counteract the chemical, if appropriate.
- Antibiotics often are not needed for minor chemical burns.
- Wounds will be cleaned and bandaged with medicated creams and sterile wraps as needed.
- Consultation with other medical specialists may be done.
- Pain from a burn can often be severe. Adequate pain control should be addressed.
- If there is any indication of breathing problems, a breathing tube may be placed in your airway to help
- If needed, a tetanus booster will be given.
- Itching as a burn heals can be a serious problem. Patient may need special medication to soothe it.
- For severe burns, you may need surgery. In a process called skin grafting, a piece of heathy skin from somewhere else on body or from a donor can be transplanted to reptace the damaged skin. Please read box below.

****

TREATMENT OF ACID AND ALKALI BURNS

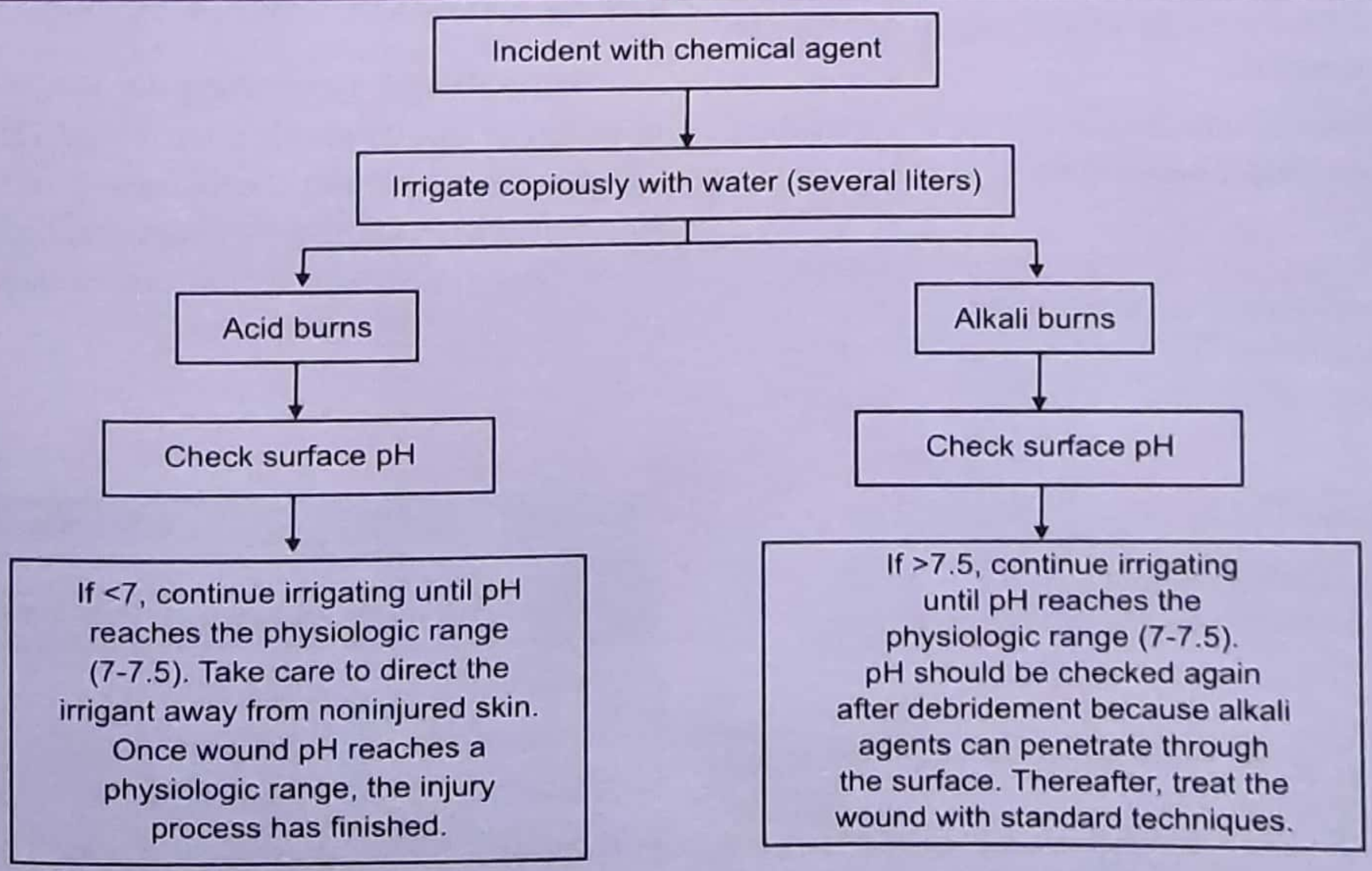

10 Plastic and Reconstructive Surgery, Skin Grafting

Contents

- Skin grafts
- Flaps

Plastic surgery is an art and science, which deals with the reconstruction of body parts altered by trauma, postburn contracture or birth defect. It is one of the oldest fields of surgery, having first been described in 700 B.C., in India. In 1818, Von Grief used the term 'Plastic' in his article on nasal reconstruction.

Three properties of skin are essential for reconstruction: elasticity, extensibility, and resilience.

1. Elasticity

Elasticity keeps skin in constant tension, owing to underlying collagen fibers. The function of elasticity becomes apparent when facial wrinkles form in it's absence as in old age.

2. Extensibility

Extensibility refers to the skin's ability to stretch, which can be seen on abdominal skin during pregnancy.

3. Resilience

This is noted by the skin's resistance to infection and puncture.

****

SKIN GRAFTS

Skin grafts are segment of epidermis and dermis that have been detached from their native blood supply, to be transplanted to another area of the body. A skin graft may be an **autograft** (ie; from the same person), an **allograft** (ie; from a genetically dissimilar individual of the same species, usually a cadaver), or a **xenograft** (ie; from a different species, usually pigs).

Cultured skin can be grown from human epidermal cells; this skin is most useful for extensively burned patients, because more surface area can be covered; however, the cultured skin tends to be very thin.

Skin grafting is transplanting skin to cover raw areas or to replace scar tissue that is interfering with function. The skin used for transplanting consists of segment of epidermis and dermis that have been detached from their native blood supply, to be transplanted to another area of the body.

KEY BOX 10.1	
Factors Influencing Reconstruction	
Patient Factor	**Defect Factor**
• Motivation • General health • Smoking • Nutrition	• Size of defect • Anatomy • Tissue lost • Availability of local tissue

Indication

Since the skin is the best possible dressing (PGI 88) for a raw surface, skin transplant is done in several situations.

1. In Burns

(a) When a large area has been lost, or when healing by the normal process of epithelialization may be unduly prolonged and may lead to excessive scarring.

(b) In deep burns, immediate excision of the burnt area with skin grafting could prevent/alleviate disability and suffering.

(c) Contracted scars, following burns in the neighbourhood of joints should be treated by excision and skin grafting; because it interferes with function.

2. Loss of skin

When there is loss of skin due to:

(i) Trauma or

(ii) Raw areas from operations for removal of malignant growths.

TYPES OF SKIN GRAFT

Skin grafts are classified according to thickness. Please see figure 10.1 (a & b) & key box 10.2.

1. Split thickness skin grafts (Thiersch grafts)

Split *thickness skin grafts contain the epidermis and a portion of the dermis* (AI 2000). They are further divided into thin, medium, and thick based on the amount of dermis included in the graft (0.010-0.025 inch). *The abdominal wall, buttocks and thighs are common donor sites* from where skin is taken (detached) for skin grafting (UPSC 07).

Advantage of split thickness skin graft include

(a) A large supply of donor areas

(b) Ease of harvesting

(c) Availability of donor site for reuse in 10-14 days

(d) Decrease primary contracture (PGME)

(e) *Coverage of large surface areas* (AI 2000)

(f) Ability to be stored for later use

Disadvantage of split thickness skin grafts include (PGME)

(a) Cosmetic inferiority to full thickness skin grafts.

(b) Decreased durability.

(c) Hyperpigmentation.

(d) Increased secondary contracture.

2. Full thickness skin grafts (Wolfe grafts) (NEET)

Full-thickness skin grafts contain the epidermis and the full thickness of dermis with out subcutaneous fat (AIIMS97,AI 2000). They are most useful for covering defects on the face or hand that are not amenable to cover with a skin flap.

A good match of skin colour can be obtained from donor sites in the post auricular or supraclavicular areas. Preauricular grafts provide the best colour match for the face (AIIMS92, AI97). The forearm and groin can also serve as donor sites for defects below the clavicle. Please see key box 10.2 and figure 10.1 (a & b).

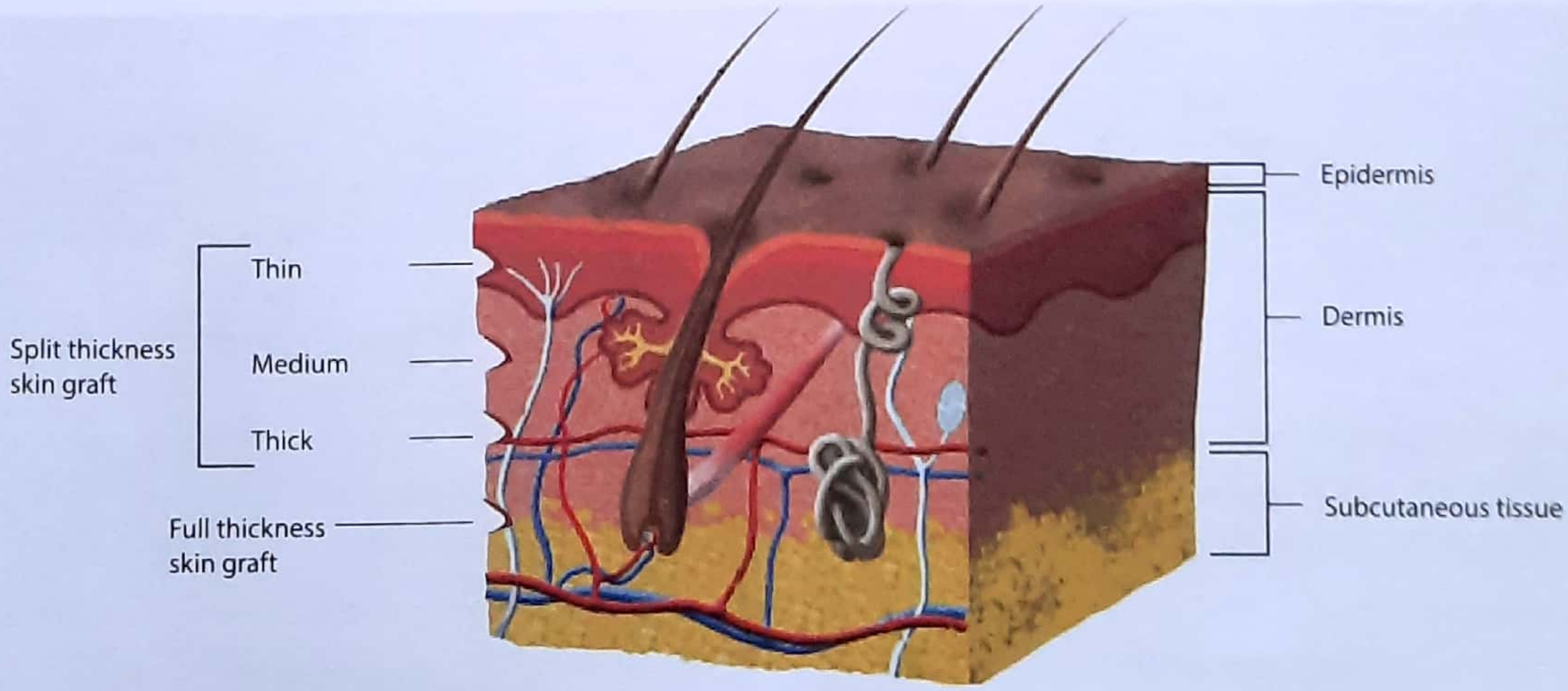

Figure 10.1 (a) : Thickness of skin grafts relative to thickness of skin

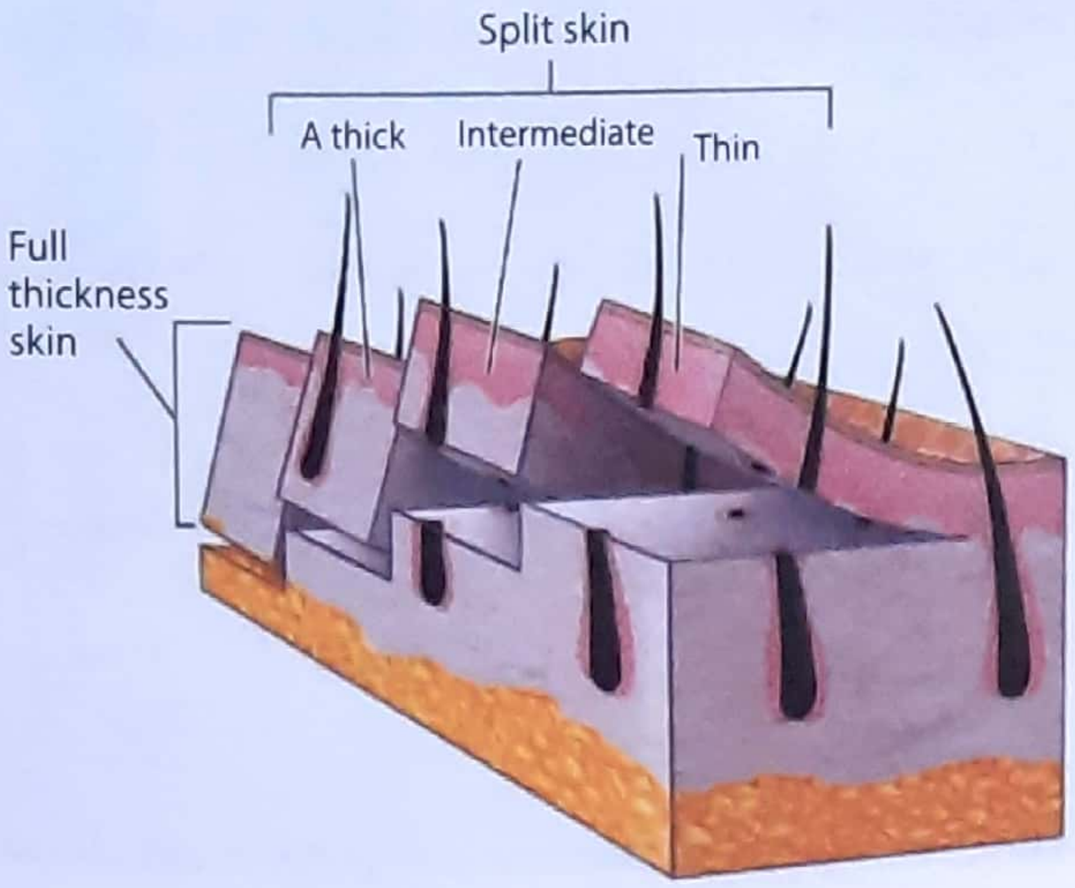

Figure 10.1 (b) : Skin grafts categorized based on thickness

Donor Sites for Full thickness graft

- Eyelids
- Postauricular Skin
- Supraclavicular area
- Antecubital region
- Inguinal/Genital/region
- Submammary/Subglutcal region

Advantage of full thickness graft

Advantages of full-thickness skin grafts include:

(a) *Cosmetic superiority to split thickness skin graft* (PGME)

(b) Decreased secondary contractures

(c) Increased durability

Disadvantage of full thickness skin graft

Disadvantages of full thickness skin grafts include:

(a) Limited donor sites

(b) Increased primary contracture

3. Composite Grafts

Composite grafts are those that are formed of multiple tissue (e.g; a fingertip containing skin, subcutaneous fat, and bone or a segment of ear containing skin and cartilage). These grafts may be effective in young patients, or in situations where the distal portion of the graft is less than 1 cm from the blood supply.

- Split thickness skin grafts are best obtained by specially designed instruments rather than taken free hand. The most common instrument used these days is Humby's knife. Please see figure 10.2 & 10.3.
- Full thickness skin graft are "harvested" with a free-hand technique using a No. 10 or No. 15 knife blade. A portion of subcutaneous fat is also harvested and must be excised carefully before grafting.

KEY BOX 10.2

Comparison of Split–Thickness Skin Graft and Full Thickness Graft

Split Skin Graft	Full Thickness Graft
• **Large donor area available**	• Small area available
• Donor site heal spontaneously	• Donor site does not heal spontaneouslt and hence most be closed
• Base of harvesting	• Relatively difficult
• **Donor site reusable in 10-14 days** (NEET)	• Increased durability, ability to be stored for later use
• **More reliable "take" (see below)**	• Less reliable "Take"
• Cosmetic interiorly to full thickness grafts	• Cosmetic superiority to split thickness skin graft
• Hyperpigmentation	• Less so
• **Increased secondary contracture**	• Decreased secondary contracture

Note: "TAKE" means taking up of graft by recipient site by its revascularization. (AIIMS JUNE 07)

KEY BOX 10.3			
	STSG (thin)	STSG (thick)	FTSG
Dermal content	+	++	+++
1° contraction	+	++	+++
2° contraction	+++	++	+
Engraftment	+++	++	+
Durability	+	++	+++
Pigmentation	+++	++	+
Resist desiccation	+	++	+++
Recipient bed	+	++	+++
Appearance	+	++	+++
STSG - Split thickness skin graft FTSG - Full thickness skin graft			

SURVIVAL OF SKIN GRAFT

Depends on three factors

1. Vascular recipient bed

These are necessary to provide nourishment for the transplant tissues.

(i) Imbibitions of plasma supports during the first 48 hours *(AIIMS99,2000)*. Fibrin is laid down and helps to hold the graft in place.

(ii) *Inosculation* (vascular budding) occurs, and the graft is usually supported by a true circulation by the fourth to seventh day. Generally, a graft begins to turn pink at this time. Lymphatic connections are formed by the fifth day.

(iii) **Revascularization & angiogenesis seen after 5 days of procedure.** *(NEET)*

2. Contact of the skin graft to underlying tissue

It is essential for inosculation to take place. Factors that can lead to loss of contact include,

(i) Tension on the graft

(ii) Fluid (e.g; blood, serum/pus) underneath the graft

(iii) Movement between the graft and its bed.

3. Preparation of wound to be grafted

(i) *Bone denuded of periosteum, cartilage denuded of perichondrium and exposed tendon do not support skin grafts; these areas require a flap procedure* *(AIIMS 98, AIIMS 99)*.

(ii) Infected wounds do not support skin grafts. The critical bacterial concentration appears to be 105 organisms/ gram of tissue and quantitative bacterial counts are useful when determining a wound's suitability for grafting. Mechanical debridement with a scalpel and scissors is necessary to remove necrotic tissue. Beta hemolytic *Steptococci and* upto some extent *Pseudomonas* produce proteases,

Figure 10.2: Humby's knife (Grafting knife)

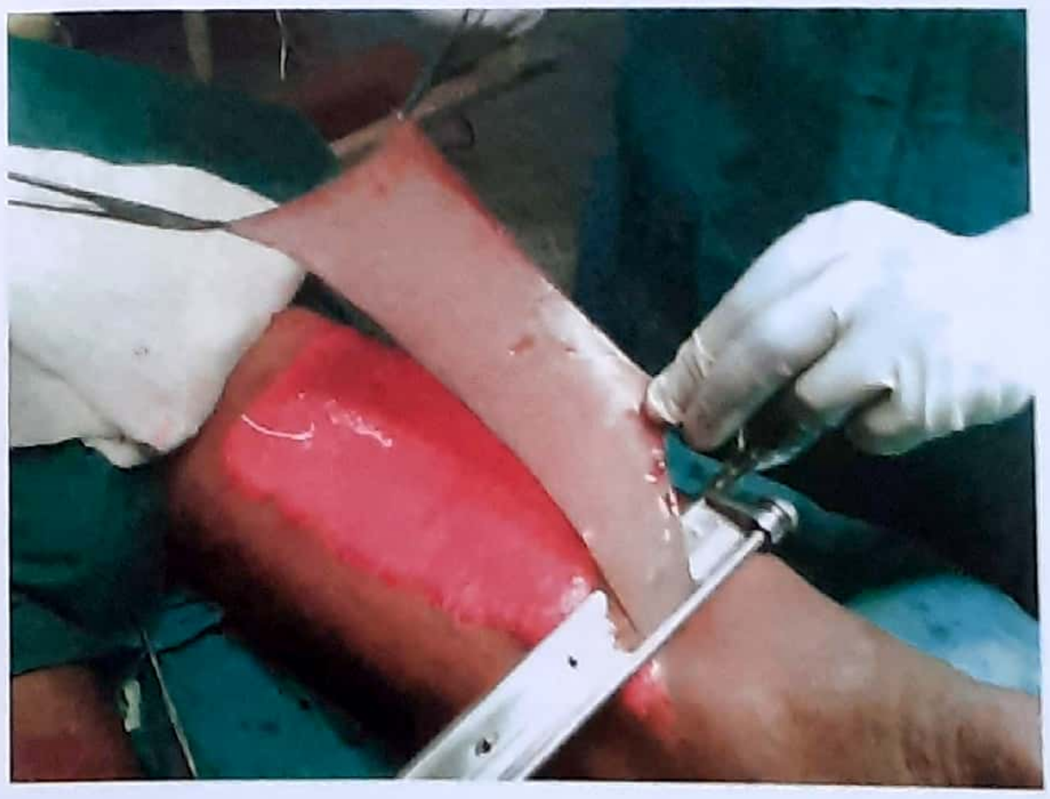

Figure 10.3: A 'skin graft' being taken

which prevent skin graft to "take". In this catagory *streptococci* are most notorious. (UP 2002)

****

FLAPS

Flaps are segments of skin and subcutaneous tissue that are moved (note; not removed) from one part of the body to another, either retaining or transplanting their vascular supply. Because of their intrinsic blood supply, flaps are useful for healing and for covering defects that require padding.

1. Local flaps

Flaps from the skin bordering the defects are mobilized, and moved into position either by advancement or by rotation or by a combination of the two.

e.g. Abbe-Estlander Flap for Lip (AI 08)

Advantages

(a) As *they are not detached* from the original site, nutrition does not suffer and blood supply is intact.

(b) The defects can be closed without tension.

Disadvantage

(a) Larger defects cannot be closed without tension, so this method cannot be used, for them.

(b) Cannot be used on face, as it causes flattening of contours and may cause disfigurement.

Methods

(a) Simple undercutting: ideal for moderate sized defects.

(b) V-Y advancement
- Bilobed - For tip of nose
- Pedicled flap - eyelid reconstruction

(c) Rotation flaps: Best for slightly larger defects, especially as these can be converted into triangular shapes.

(d) Excision of contracted linear scar and Z-plasty (use in hand surgery): used if the scar is in the neck and axillary fold, where it may cause interference with movement.

2. Pedicle flaps

Flaps are segments of skin and subcutaneous tissues that are moved from one part of the body to another, either retaining or transplanting their vascular supply, which is through a segmental artery. Because of the intrinsic blood supply, flaps are useful for promoting healing and for covering defects that require padding.

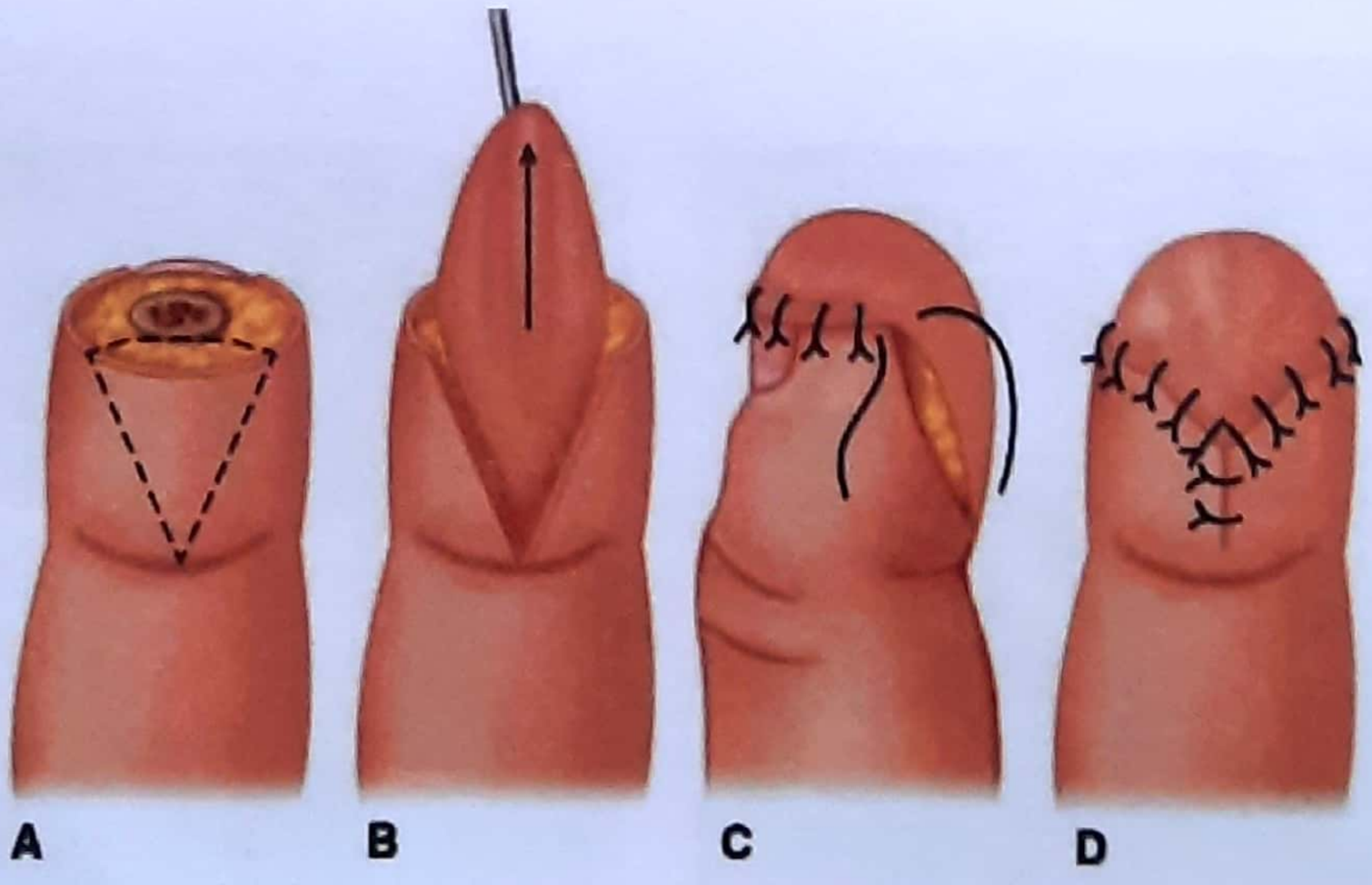

Figure 10.4 : V-Y flap closure

Figure 10.5 : Pectoralis major flap

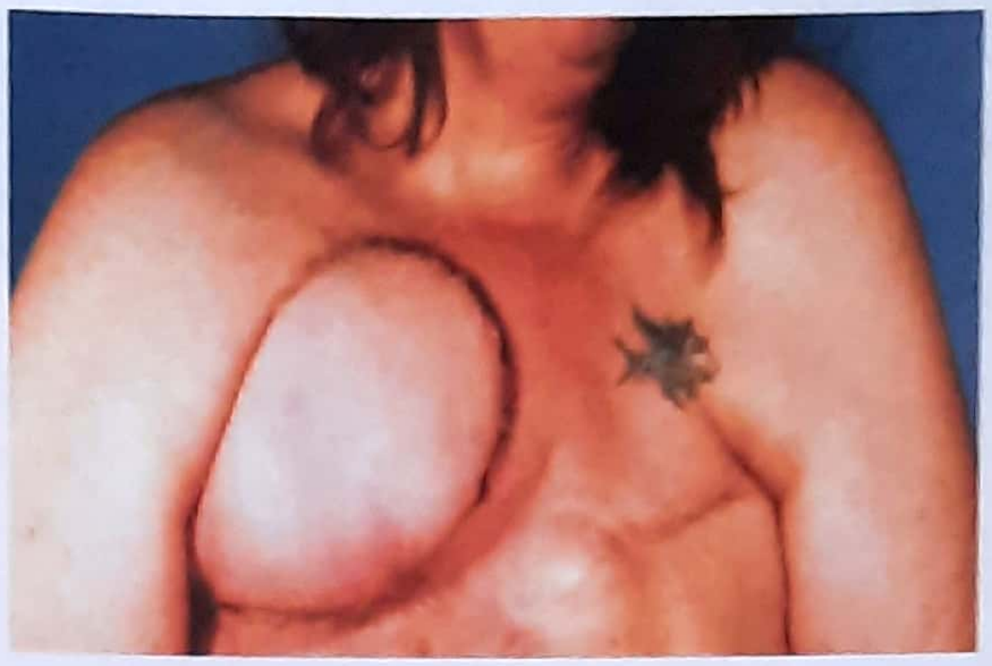

Figure 10.7 : Latissimus dorsi flap

Advantages

(a) *It can be done on cartilage, open joints, bare cortical bone or bare tendon etc* (AIIMS99, 98).

(b) It will take even if the recipient area is affected by irradiation or scarring.

(c) It is ideal, if the defect involves a cavity (like cheek).

(d) It is also employed for areas like the face, where good cosmetic results are required. It is also used for the hands and feet (decubitus ulcers), where the skin has adequate resistances to trauma. This type of graft has strength, stability and good cosmetic value.

Disadvantages

It requires careful planning and the surgeon should have adequate experience. It must be carried out in several stages, during which time the patient is usually confined to bed.

Figure 10.6 : Rectus abdominis flap

VARIOUS TYPES OF PEDICLE FLAPS

(i) Direct pedicle flap (approximation flap)

This type of pedicle flap is applied when the donor area and the recipient area can be brought into close proximity with each other, for example; from the trunk to the upper limb, from one lower limb to the other lower limb (cross leg flap), or from one finger to the other (cross finger flap).

(ii) Bridge flap (a variant of direct flap)

This is a form of approximation flap; it is left attached to the donor area at both ends, so that it will have double blood supply.

(iii) Indirect pedicle flap/tubed pedicle flap (Gillies flap)

This type of pedicle flap is used, when the donor area and the recipient area cannot be approximated, and it is necessary to bridge the distance between them.

The advantages of these three types of flaps are that they can be used, when the donor area and the recipient area can not be brought together. It is useful especially in plastic surgery of the face. As a result of tubing, no 'raw area' remains; and the risks of infection are greatly diminished. Also much less mobilization is required as compared to other types of graft. However, technically; it is a difficult procedure and has to be done in stages and by experienced plastic surgeons.

KEY BOX 10.4		
Mathes-Nahai classification of muscular flaps		
CLASSIFICATION	**VASCULAR SUPPLY**	**EXAMPLE**
Type I	One vascular pedicle	Gastroenemius
Type II	Dominant and minor pedicles (the flap cannot survive based only on the minor pedicles)	Gracilis
Type III	Two dominant pedicles	Rectus abdominis
Type IV	Segmental pedicles	Sartorius
Type V	One dominant pedicle with secondary segmental pedicles (the flap can survive based only on the secondary pedicles)	Pectoralis major

(iv) Muscle flaps

Provide increased blood supply to an area. Generally, they are used to cover exposed bone & are usually skin grafted. When the overlying skin and subcutaneous tissue are included, they are called **myocutaneous (musculocutaneous) flaps**.

1. The blood supply is predictable, and the flaps can be outlined anatomically. The flaps contain muscle with a named artery, which must be identified and preserved.
2. Muscle flaps have been most useful in reconstruction of the lower extremity and in area of poor vascularity. Myocutaneous flaps have been useful for reconstruction of tissue that has been injured by radiation.
3. **Most common used myocutaneous pedicle flap for pelvis surgeries is rectus abdominis flap** *(NEET)*. Fig. 10.6

(v) Fasciocutaneous flaps

These flaps involve the transfer of skin, subcutaneous tissue, and the underlying fascia with an anatomically distinct artery. Because there is no mobilization of underlying muscle, there is less functional debilitation. The donor site must be skin grafted. These flaps are cosmetically inferior to muscle flaps.

Uses of flaps include

1. Wound closure in areas of poor vascularity (e.g; wound overlying bare bone, cartilage, nerves, or tendons; radiation injured tissue)
2. Facial reconstruction (e.g; the nose or lips)
3. Areas over bone where padding is needed (e.g; the ischial tuberosity in a patient with pressure-sore)

*****

Sample Questions for Prof Examination

1. A middle aged man of Wt. 70 kg is admitted with burns of 30% of body surface. Discuss the management of the case.
2. Write short notes on Rule of nine.
3. Write short notes on partial thickness and full thickness grafts.

11 Tetanus and Gas Gangrene

Contents

- Tetanus
- Gas gangrene

Tetanus is acute neurological disease characterized by increased muscle tone which persists through out illness, associated with painful paroxysmal spasms of voluntary muscles; that is caused by "Tetanospasmin", a powerful protein toxin secreted by *"Clostridium- Tetani"*. Please see key box 11.1

Etiological agent

- The causative agent of Tetanus is *Clostridium tetani,* a gram positive; anaerobic motile rod that forms an oval terminal spore and thus assumes a spore* resembling a 'Tennis racket" or "Drum stick".
- The organism is found in soil, animal feces and occasionally in human feces.
- Spores are highly resistant to boiling, phenol, cresol, and autoclaving for 15 minutes at 120°c. The spores are best destroyed by steam under pressure at 120°c for 20 minutes or by gamma irradiations.

KEY BOX 11.1	
Tetanospasmin	
Tetanospasmin is a simple protein of single polypeptide chain. On autolysis it is broken down into:	
1. Heavy chain (100 Kda)	**2. Light chain (50 Kda)**
Mediates binding to nerve cell receptors	Block neurotransmitter

Spore

Some bacteria, particularly members of clostridia has ability to form a *highly resistant, resting stage* called as spore.

Toxin

Tetanus bacilli produces soluble exotoxins.

- **Tetanospasmin a neurotoxin**
- **Tetanolysin - a hemolysin**
- Tetanospasmin is responsible for clinical manifestation of tetanus. This is oxygen stable, but relatively heat labile. (PGME) Key box 11.1.
- The role of Tetanolysin is uncertain in disease process.

Incubation Period

Usually incubation period of tetanus is **6-10 days** (MANY PGME), but it may be as short as one day or as long as several months. Prolong incubation period is due to prophylaxis or due to spores lying dormant in wound.

KEY POINT: "A shorter incubation period is associated with greater mortality".

Period of Onset

This is the time interval between onset of first symptom and onset of first spasm (MANY PGME). In new born (tetanus neonatorum) the first symptom is usually persistent cry or inability to suck. In children and adults, it is usually "Trismus". *Period of onset is most reliable index for prognostic point.*

A shorter period of onset is associated with worse prognosis. (IMP. POINT)

Pathophysiology

- *Cl. tetani* has little invasive power. The spores implanted in a wound can germinate and multiply only if the conditions are anaerobic such as devitalized tissue or presence of foreign bodies or active infections.
- Toxin released in the wound binds to peripheral motor neuron terminals, enters the axon and is transported to nerve cell body in the brain stem and spinal cord by retrograde intra-axonal transport. The toxin then migrates across the synapse to presynaptic terminals, where **it blocks release of inhibitory neurotransmitters Glycine and Gamma Amino Butyric Acid (GAB A).**
- With diminished inhibition, the resting firing rate of motor neuron increases, producing rigidity.
- With lessened activity of reflexes, that limit polysynaptic spread of impulses, agonist and antagonist muscles may be recruited simultaneously rather than inhibited, producing spasms.
- Loss of inhibition may also affect preganglionic sympathetic neurons in the lateral gray matter of the spinal cord and produces sympathetic over activity and high circulating catecholamines levels.
- **In *local tetanus*,** only the nerve supplying the effected muscles are involved, where as ***Generalize tetanus*** occurs when toxin released in wound enters the lymphatics and blood stream and is spread widely to distant nerve terminals and CNS. In such condition toxin first enters motor nuclei and travels through shortest neural pathway to muscle of face, imparting the **typical features of trismus (lockjaw) and risus sardonicus,** when the toxin enters the CNS by longer pathway; it produces **opisthotonos and generalized rigidity.**
- The toxin spreads by neural pathway with a definite rate of 75 to 255 mm/day depending on muscle activity and quantity of muscle.

Effect of Tetanus Toxin

(i) On Motor system

- Muscle rigidity, spasm and generalized convulsions are produced.
- Muscle rigidity is due to disturbance in inhibitory process leads to increase resting firing rate of motor neurons.
- Spasm is due to simultaneous contraction of agonist and antagonist group of muscles, in absence of reciprocal inhibition.

(ii) On Autonomic Nervous system

Loss of inhibition at lateral gray matter of spinal cord causes sympathetic over activity, which results in. tachycardia, increase BMR, changes in arterial pressure, intense perspiration, hypothermia and dysrhythmia. Periods of bradycardia and hypotension may also be present. Sudden cardiac arrest may sometime occur.

(iii) On Endocrine system

Tetanus affects hypothalamo-hypophysial system and leads to water and electrolyte imbalance. The catecholamine level in hypothalamus increases.

(iv) Visceral changes

(a) Pulmonary system

Pulmonary complications in tetanus are one of the most common cause of death. There are structural and microcirculatory changes in lung causing extensive pulmonary congestion. Pulmonary complications also result from coagulation changes in pulmonary vessels and disturbance in pulmonary resistance.

(b) Myocardial changes

There is vacuole dystrophy, inhibition of activity of oxidative restorative ferments, disturbance in microcirculation, intra vascular thrombosis, perivascular hemorrhage and disturbance of lymphatic circulation.

GRADING OF SEVERITY OF TETANUS

Two methods mainly used are:

1. Patel and Jong Method

Tetanus patient may present with any or all of the following five criteria.

(i) Presence of lock jaw/inability to suck (in neonate)
(ii) Presence of spasm
(iii) Incubation period of seven days or less,
(iv) Period of onset 48 hours or less
(v) Fever on admission >99°C (axillary temperature) or within 24 hours of admission.

- The cases having one of the five criteria as grade I, two as grade II, and so on.

2. **Black Method:** Described in key box 11.2

Clinical Forms of Tetanus

Tetanus may be of 4 clinical types:

1. Localized Tetanus

This is due to localized involvement of a group of muscle, resulting in pain and spasm of muscle in proximity to site of injury. Localize rigidity is caused by dysfunction of the interneurons, which inhibits the alpha motor neurons of the affected muscle, without further CNS involvement.

2. Generalized Tetanus

This results due to generalized tonic rigidity and reflex convulsion. *Trismus (Lock jaw) is the first indication of rigidity and usually the first symptom* (MANY PGME). *Spasm of the masseter leads to lock jaw, and that of facial muscle causes risus sardonicus* (MANY PGME), tonic contraction of abdominal and spinal muscles causes ***opisthotonos*** *(upward bowing of body).* Moderate to severe cases of tetanus are complicated by intermittent reflex spasm that occurs in response to multiple stimuli. Acute respiratory failure may result from sustained generalized spasm with secondary diaphragmatic spasm or paralysis, or from laryngeal spasm. Severe spasm may result in vertebral fracture, long bone fractures and detachment of tendons from their insertion.

KEY BOX 11.3

Nerves Involved in Tetanus	
V	Trismus
VII	Risus sardonicus
VIII	Hyperacusis
X, XII	Dysphagia

3. Cephalic Tetanus

This usually follows head injuries or otitis media, though it can be occurs in cases with injury to other parts and also without any apparent injury. Single or multiple cranial nerves

4. Neonatal Tetanus (Tetanus neonatorum)

It usually occurs as generalized form and is usually fatal. It develops in children born to inadequately immunized mothers, frequently after unsterilized treatment of umbilical cord stump. It's onset generally comes during the first two weeks of life. Poor feeding, rigidity and spasm are typical features of neonatal tetanus.

KEY BOX 11.2

(Black Method of severity of tetanus)

Severity (Black method)	Incubation Period	Period of onset (in days)	Associated findings
Mild	>10 days	4-7 days	• Local rigidity • Mild trismus
Moderate	7-10 day	3-4 days	• Severe trismus • Dysphagia • Spasm
Severe	< 7 days	< days	• Severe spasm • Diffused rigidity • Autonomic dysfunction

Differential Diagnosis of Tetanus

(i) Meningitis

There is high fever, signs of meningeal irritation, absence of trismus. On investigation TLC is raised, CSF examination is characteristic. (In Tetanus CSF examination is normal).

(ii) Epilepsy

There may be loss of consciousness, even momentary during convulsions, history of similar episodes with completely symptom free intervals.

(iii) Strychnine Poisoning

- H/O ingestion of broken seeds of Nux vomica.
- Onset is sudden
- Between spasms muscles are completely relaxed.
- Chemical analysis reveals poison.

Strychnine acts on poSt-synaptic part, while teta-nospasmin on pre-synaptic part (MANY PGME)

(iv) Hypocalcemia and Hypomagnesemia

There may be seizures, tremors and laryngospasm but generalized rigidity and trismus are absent, blood level of Ca^{++} and Mg^{++} is diagnostic.

(v) Neonatal Hypoglycemic Convulsions

Newborn presents with coarse tremors, twitching, convulsions, refusal to feed, apathy and coma. Blood glucose level is diagnostic and disappearance of symptom on administration of intravenous glucose solution.

(vii) Intracranial hemorrhage and Kernicterus

Trismus is absent. An altered sensorium is present in these conditions, where as in tetanus, patient is alert. CSF findings and serum bilirubin level is diagnostic.

(viii) Phenothiazine and Metoclopramide Toxicity

Patient presents with features of extra pyramidal rigidity, manifested by spasm of muscles of back & neck, trismus and dysphagia.

****

MANAGEMENT OF TETANUS

Investigation

- No specific investigation is present to rule out or diagnose tetanus, but presence of serum antitoxin level greater than 0.0 IU/ml in usually protective and making the diagnosis less likely. However **at most of the time diagnosis is made on clinical grounds.**
- Microscopic examination of pus or necrotic material may reveals bacilli with spores in some cases.

Treatment

The **goals** in treatment of tetanus is:

(a) Eliminate the source of toxin

(b) Neutralize unbound toxin

(c) Prevent convulsion, rigidity and spasm

(d) Maintenance of adequate airway and ventilation

(e) Symptomatic treatment

(f) Treatment of complication

(g) Prevention of future recurrence

Now lets discuss them one by one:

(a) Eliminate the source of Toxin

- If wound toilet is properly performed within six hours of injury, it will destroy the spores. Proper wound debridement, use of local antibiotic and cleaning the wound with hydrogen peroxide is needed. There is significant improvement in mortality when wound undergoes aggressive debridement (with at least 2cm of normal viable tissue around wound margin), or amputation. Systemic antibiotic therapy should be administered to eradicate vegetative cells.
- *Drug of choice is penicillin (1.0-1.5 lac IU/Kg), though recently the trend is changing towards metronidazole.*
- In penicillin sensitive patients clindamycin, erythromycin or kanamycin may be given.

(b) Neutralization of Toxin (Use of Antitoxin)

- The antitoxin only neutralize circulating toxin and unbound toxin, but have no effect on toxin bounded to neural tissue. The first dose of antitoxin may be best administered before manipulating the wound.

Two types of antitoxins are available

(i) Human tetanus immunoglobulin (Tet-Glob)

(ii) Equine anti-tetanus serum (ATS)

- The human anti-tetanus immunoglobulin has advantage over equine anti-tetanus serum due to:-
  - No risk of hypersensitivity reactions Antibody levels for longer duration (20-40 days) than equine antiserum (7-14 days).
  - Not interface with patients antibody production
  - Does not require sensitivity test.
  - Devoid of any preservative.
- *Role of intrathecal antitoxin injection:* The initial spasms are due to free tetanus toxin circulating in the CSF, which is not yet fixed to anterior horn cells, thus free toxins are available for neutralization; which is nutralized by intrathecal injection of Tetglob. But after 48 hours of 1st convulsion, toxin is presumed to be fixed to nervous tissue, then intrathecal antitoxin is not of much value.

(c) Prevention of Convulsion, rigidity & spasm

- Centrally acting muscle relaxants like, methacarbamol, mephenesin, meprobamate or peripheral muscle relaxant like d-TC, succinylcholine can be used.
- *Methocarbomol* is ideal drug, having greater potency and long acting and does not suppress respiration. The *chief side effect is severe gastritis & hemorrhagic cystitis.* (IMP. POINT)
- Meprobamate is one of most potent muscle relaxant, but causes thrombosis, hemolysis and renal damage on prolong use.
- Mephenesin causes hypotension and hemoglobinuria.
- Diazepam, in addition to hypnotic is a potent muscle relaxant; it acts by depressing the ascending reticular activating system and internuncial neurons.
- A combination of muscle relaxant is more effective than massive use of any single drug.

(d) Maintenance of Airway

Maintenance of clean airway and ventilation is most important. In severe tetanus complete relaxation by peripheral muscle relaxant and tracheostomy with IPPV is mainstay of therapy.

(e) Symptomatic Treatment

- Beta blockers are used for sympathetic over activity like hypertension and profuse sweating. Usually labetalol, esmolol or clonidine is used.
- Hypotension & bradycardia requires volume expansion and vasopressor agents.
- Use of steroids, especially betamethasone reduces peri cellular edema around motor nerves and ganglion, and have an antitoxemic effect and support falling suprarenal functions.
- Use of pralidoxine at doses of 40mg/kg/day, by intramuscular route has beneficial effect, because tetanus toxin has some anticholynesterase effect.
- Use of hyperbaric oxygen causes, active regression of symptoms, progression of disease process is arrested and/or even reversed.

(f) Prevention of complication

- Adequate hydration status should be maintained.
- Adequate parenteral nutrition should be maintained.
- Physiotherapy is given to prevent contracture.
- Thromboembolic events should be prevented by heparin administration.
- 3Bs ie; (i) Bladder, (ii) Bowel and (iii) Back care, to be done.

(g) Prevention of recurrence

Patient recovering from tetanus should be actively immunized, because immunity is not induced by small amount of toxin that produces the disease.

Prognostic Factor in Tetanus

1. **Age**-Extremes of age-worse prognosis
2. **Sex**-Higher mortality in males.
3. **Incubation period**-Longer incubation period is associated with lesser mortality and vise-versa.
4. **Period of onset**-Shorter period of onset is associated with increase mortality.
5. **Severity of convulsion**-Severe convulsions are associated with increased mortality.
6. **Fever**-It is a bad prognostic factor.

Complication of Tetanus

(a) Over-sedation

(b) Respiratory complications: Aspiration pneumonitis and pulmonary edema, (most common cause of death)

(c) Hyperpyrexia

(d) Constipation

(c) Thrombophlebitis

(f) Electrolyte imbalance

(g) Bed sores

(h) Septicemia

(i) Compression fracture of vertebra

Cause of Death

Respiratory spasms with apneic spells is most common cause of death (IMP. POINT). Death can also occur due to hyperpyrexia, laryngeal spasm, pulmonary edema and electrolyte imbalance.

****

GAS GANGRENE

- Gas gangrene is a highly fatal, anaerobic gas producing infection of muscle and subcutaneous tissue.

Etiology

- The disease is caused by *Clostridium perfringens (clostridium welchi)* in about 80%, other organisms responsible are C. *septicum, C. edematiens (clostridium novi)* and *C. histolyticum.* (MANY PGME)

Pathogenesis

- Gas gangrene develops in wounds, where there is gross contamination with dirt and soil foreign body or feces. Other causes are war wounds, septic abortion, post operative wound and penetrating injury to colon or rectum.
- Gas gangrene commonly develops following road traffic accident. Endogenous infection from patients own feces may cause gas gangrene, when stump of amputated lower limb get infected.
- Clostridia are anaerobes, requiring a low redox potential to grow. Tissue redox potential is diminished by impaired blood supply, severe local edema, foreign bodies or oxygen consuming organism in wound.
- After gaining entry into tissue, organism produces powerful exotoxin, which include saccharolytic and hemolytic enzymes such as lecithinase, collagenase, hyaluronidase, protease, lipase, hemolysin and alpha toxin. Which further causes tissue damage. They cause:
  - (i) *Tissue destruction :* The ferments diffuse and cause destruction of tissue.
  - (ii) *Proteolysis:* They also break down proteins.
  - (iii) *Saccharolysis.* They break down sugars with formation of gas bubbles, which gives the condition it's name.
  - (iv) *Destruction of local microcirculation:* They prepare the way for the invasion of other organisms by destroying local microcirculation by thrombosis of small and medium arteries.
  - (v) *Fragmentation of collagen:* The hyaluronidase destroys the intercellular cement, facilitating the spread of infection.
- There occurs wide spread necrosis of muscle bundle which lose contractility and becomes dull, red, green and black.
- When the disease involves liver; gas is produced in liver a condition known as "foamy liver" classically seen at autopsy.

Clinical feature

- Patient is ill and restless, mild fever is often present.
- Tachycardia and hypotension is usual.
- Mental condition may remain normal till very late.

Local signs

- Increasing pain in the wound.
- Limb becomes edematous and tense.
- Palpation of the affected part reveals crepitus, which is a pathognomonic sign.
- Gangrenous patches in skin with vesicle formation.
- Skin near the wound becomes black.

Treatment

Prevention

Gas gangrene can be prevented by an early debridement of the dead tissue. Any wound which has occurred outdoor and contaminated with soil, feces, road traffic injury, and any wound in which tissue has been extensively injured is highly suspicious. The wound is carefully ex-

amined and all nonviable tissues are debrided. The minimum criteria for tissue viability are; bleeding from the wounds edges when cut, and contraction of muscle when gently pinched.

- Antitoxin should be given to all patients having wound contaminated with soil. AGGS (Anti gas gangrene serum) should be given intramuscularly.
- Prophylactic intravenous penicillin.

Treatment of established case

- 3 ampoules of AGGS I.V. 4 hourly.
- **Large doses of penicillin.** (NEET) Metronidazole/ clindamycin can be a good choice.
- Wide debridement of involved part is best treatment. (NEET)
- If infection is widespread emergency amputation is necessary to prevent spread of infection & septicemia.
- Hyperbaric oxygen: exposing the patient to 3 atmosphere of oxygen, reduces the toxin production.

****

Sample Questions for Prof Examination

1. Discuss the clinical features, differential diagnosis and management of tetanus.
2. Describe the signs, symptoms and treatment of tetanus. Write short note on: prophylaxis of tetanus.
3. Describe the clinical features of tetanus. How would you manage a case of tetanus?
4. Describe the etiology, clinical features and treatment of tetanus.
5. Discuss the etiopathology of gas gangrene.
6. Discuss the diagnosis and treatment of a case of gas gangrene.
7. Write short notes on prophylaxis of gas gangrene.

12 Infection of The Hand and Foot

Contents

- Anatomy of hand
- Types of Hand Infection
- Miscellaneous conditions of hand
- Diseases of Foot
  - Plantar fascitis
  - Ingrowing toe nail
  - Diabetic foot
  - Madura foot

SURGICAL ANATOMY

The Spaces of the Hand

A. Palmar spaces

- The pulp spaces of fingers
- The digital synovial sheaths
- The ulnar bursa
- The radial bursa
- The midpalmar space
- The thenar space

B. Dorsal spaces

- Dorsal subcutaneous space.
- Dorsal subaponeurotic space.

C The forearm space of Parona

Please see figure 12.1(a) & 12.1(b)

The lymphatic field of the hand

The rich network of lymphatics in the subcutaneous tissues of the dorsum receives efferent vessels from the palm, and because the skin covering the back of the hand is loose and elastic, **edema is often most evident on the dorsum of hand,** *irrespective of the site of the infection.*

After the local involvement, there is involvement of supratrochlear lymph node and the axillary lymph nodes on the side of the lesion.

INFECTION OF THE HAND

As our major prehensile organ, the hand is constantly in use and at risk of injury and infection. Abundant vascular supply promotes normal healing, following superficial hand infections or injury. Acute bacterial infections are common. In some anatomical spaces and compartments, infections can become established and without prompt treatment these can rapidly become limb or even life threatening.

Etiology and Incidence

Common causes of hand infection

- Trauma (60%)
- Human bites (25%)

KEY BOX 12.1

Pyogenic hand infections-causative organisms and empirical antibiotic treatment

Clinical situation/type of infection	Causative organisms	Empirical antibiotic treatment	
		First Choice	Second Choice
• Simple laceration (no contamination, crush or delay in treatment		None required with prompt appropriate surgical treatment	
• Cellulitis • Wound infections	Straphylococcus aureus, Streptococci	Flucloxacillin + penicillin	Cephalosporin (e.g. cerfuroxime)
• Septic arthritis • Acute osteomyelitis • Moderate open, lightly contaminated wound	Staph aureus, Steptococci + /– others	Cephalosporin	Vancomycin + gentamicin
• Severe local or systemic infection • Immunocompromised patient, diabetes mellitus, malignancy, HIV • Bite wounds, major open grossly contaminated wound	Straph aureus, Streptococci, Gram-negative bacilli, anaerobes	Cephalosporin + gentamicin + metronidazole	Vancomycin + gentamicin
• Suspected infection with resistant organisms (severely immunocompromised patient)	Methicillin-resistant Staph, aureus Streptococci	Vancomycin + gentamicin + metronidazole	

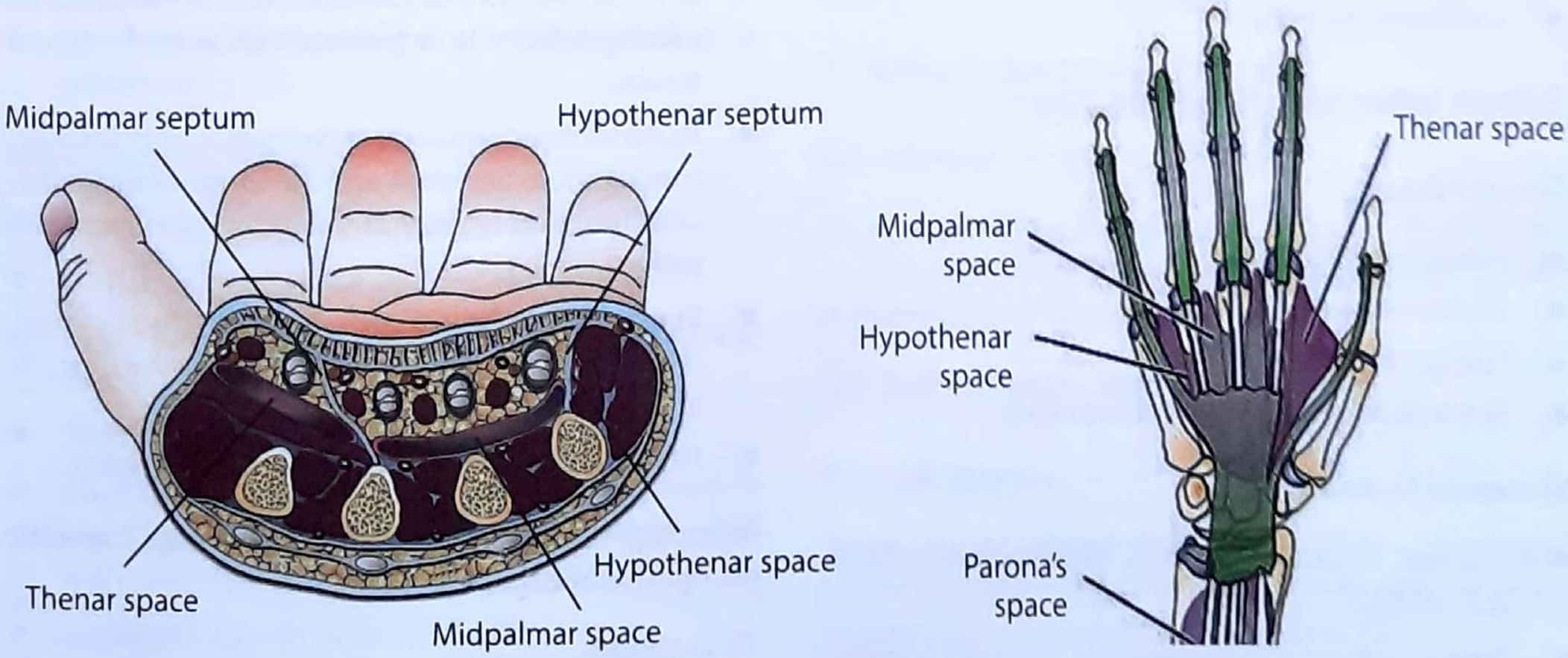

Figure 12.1(a): Hand spaces

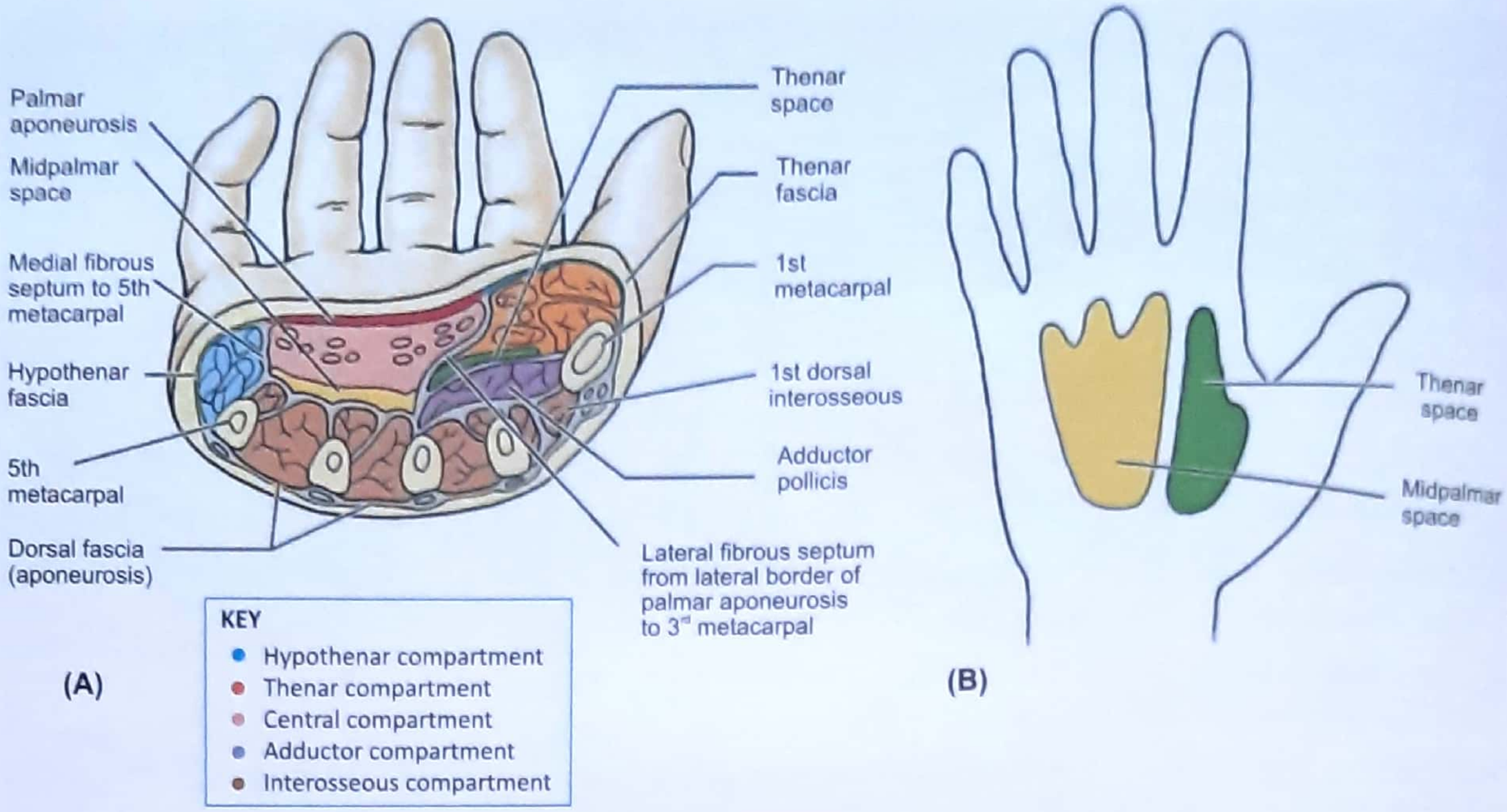

Figure 12.1(b): Hand spaces

- Animal bites (10%)
- Other causes (5%)

Common types of hand infection

- Cellulitis (35%)
- Paronychia/eponychia (35%)
- Felons (15%)
- Tenosynovitis (10%)
- Deep space abscess (2%)
- Osteomyelitis (1%)

Factors Influencing Hand infections

Local Factors

- Pathogen virulence
- Tissue disruption
- Foreign mater
- Previous injury (impaired circulation).

Systemic factors

- Systemic diseases (Diabetes, Rheumatoid arthritis, SLE, HIV)
- Drug treatment (Corticosteroids, Immuno suppressant)

Causative Organism

- The causative organism can be predicted from the initiating injury, the location and course of infection and the status of the host.
- *S. aureus* is the most common organism, isolated in 35% all hand infections.
- Hemolytic *Streptococci* commonly causes cellulitis whereas *S. aureus* and *Streptococci* causes septic arthritis and osteomyelitis. Gram negative bacilli such as *E.coli, proteus and pseudomonas* are notorious for causing infections in patients with altered immune status.
- Bacterial strains resistant to multiple antibiotic are becoming more prevalent and the threat of uncontrollable infection is worst in the immunocompromised patient.
- Fungi or mycobacterium may cause chronic infections. Gonococcal infection is a rare cause of septic arthritis or tenosynovitis.
- Herpes simplex virus causes a herpetic whitlow.

Infecting organisms acquired through specific occupational exposure

This includes

- *Herpes simplex* in dentists and health workers.

- *Pox virus* (orf, cow pox) in animal handlers.
- *Mycobacterium maximum* in fish keepers.
- *Candida albicans* in dish washers.
- *Sporothrix schenckii* in gardeners.

Management

This must help us to answer the important question. "Does this hand infection need an operative intervention"?

History and physical examination

Important features to be noted from history & physical examination include:-

- The initiating event, duration of symptoms, host status, tetanus immunization status.
- Signs of systemic sepsis (pyrexia, tachycardia, hypotension).
- The location and spread of the infection (degree of swelling, warmth, tenderness, lymphadenitis, joint involvement.)
- Abscess formation (throbbing pain, sleep disturbances).
- Fluctuation of the dorsum of the hand, which may be caused by an abscess, local edema or a palmar abscess (lymphatics in the hand drain to the dorsum).

Initial Investigation include

- Complete blood count, ESR, C reactive protein, blood Culture.
- Radiographs of hand for bone involvement.
- Fluid/tissue specimens for microscopy, culture & sensitivity.

Initial treatment-include

- Immunization against tetanus.
- Incision, drainage and washout of abscesses.
- Tight wound packing or continuous wound irrigation.
- Multiple surgical debridement.
- High dose intravenous antibiotics initially and then empirical antibiotics subsequently according to pus culture and sensitivities.
- Complete rest with a hand support.
- Limb elevation to reduce edema of the effected part.
- Early active mobilization of limb, as soon as the condition improves.
- Change from IV antibiotics to oral antibiotics when the condition allows.

****

TYPES OF HAND INFECTION

A. Poorly localized subcutaneous infection

1. Cellulitis
2. Lymphangitis

These are usually due to the *Streptococcal* infection and are spreading infections that usually do not localize. As there is no local collection of pus, drainage is not needed. The treatment is by rest, elevation and antibiotics. (The above two condition have been discussed in detail elsewhere in this book.)

B. Well localized Infection

1. Intra-cutaneous

(a) Intra-cuticular

(b) Subcuticular

2. Subcutaneous

3. Collar-stud abscess occurs when the epidermal component is connected to the dermal component.

Lets discuss them one by one:

1. Intra-cutaneous infection

(a) Intra-cuticular

An abscess with in the epidermis is usually referred to as an intra-cuticular abscess. An infected traumatic blister is an example of such an infection.

(b) Subcuticular infection are

(i) Septic blisters

These are common on the palmar surface of the fingers and in the finger webs. The epidermis becomes elevated by collection of pus with in the layers of skin.

(ii) Acute Paronychia

- It is common infection of the hand (35%). It is encountered in every walk of life, in both sexes and from infancy to old age.
- The infection arises from a hang nail, careless nail paring or a manicurist's unsterile instrument.
- The inflammation commences into the soft tissue fold to one side of the finger nail. Usually suppuration follows after minor trauma. See figure 12.2.
- In case the infection involves the eponychium (note : the lateral fold it is called eponychium) a 'run around' abscess forms, if the infection extends to the opposite side of the nail.
- The diagnosis can be made by inspection alone. If pus is present, light pressure on the inflamed area, or on the nail itself, evokes severe pain.
- The pus is release by incision on the nail fold and excision of that quarter of the nail.

(iii) Chronic Paronychia

- It may be due to inadequately treated acute paronychia, however in *most of the cases, it is due to fungal infection (Candida albicans)*.
- The onset is insidious with a history dating back months rather than days. The lesions are often multiple.
- There is little tenderness. The eponychium is glazes and becomes faintly pink without the redness of acute paronychia or frank pus.
- The nail itself may be affected, being cross ridged and sometimes pigmented brown.

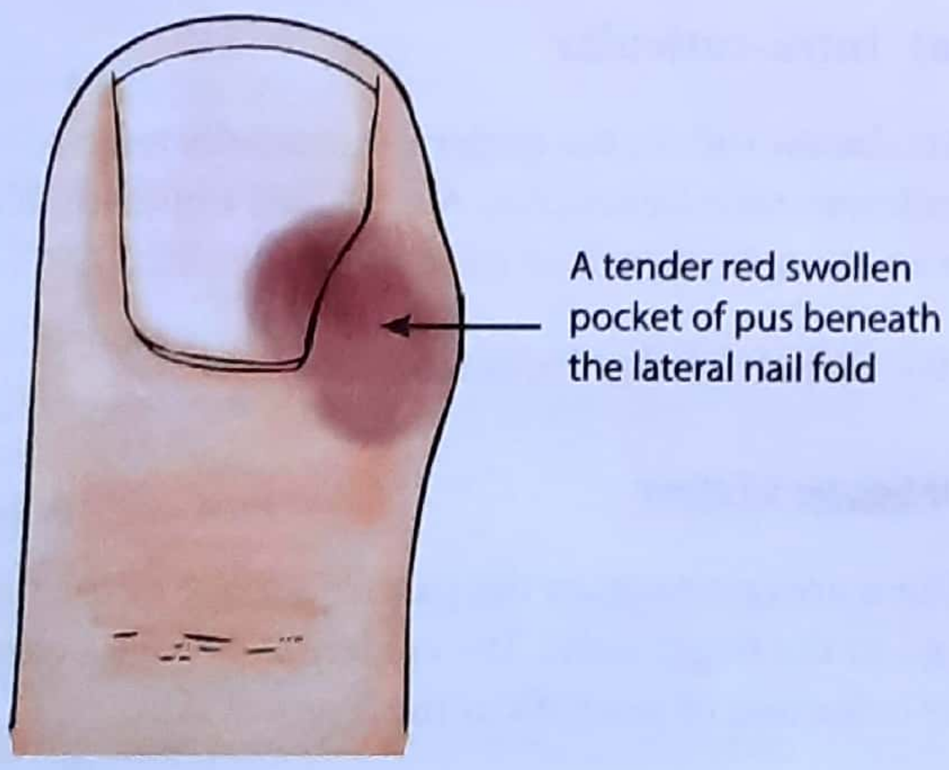

Figure 12.2: Acute paronychia

- Common in women who wash cloths and utensils, resulting in constant wetting of fingers.
- It may resolve if the hands are kept dry and the nail fold is regularly dressed with antifungal ointment and patient is given antifungal drugs. If this fails, the nail fold in laid open.

(iv) Carbuncles in the hand

This is *Staphylococcal* infection of hair follicles on the dorsum of hand or the proximal segments of the fingers. They respond well to antibiotic treatment and surgical intervention should be restricted to the removal of any sloughing tissue.

2. SUBCUTANEOUS infection

They include:

Pulp Space infections

The three pulp spaces on the flexor aspect of the fingers are separated by the flexor creases where the skin is attached to the underlying fibrous flexor sheath. The fatty tissue in the terminal space in subdivided into 15-20 compartments by fibrous septa between the skin and the periosteum of the terminal phalanx. Infection in the terminal pulp space therefore does not spread down the finger, but causes a rapid build up of pressure which may be associated with sloughing of the overlying skin and osteomyelitis of the terminal phalanx.

Infections that may affect a digit

(a) Tendon sheath infection

(b) Septic arthritis

(c) Paronychia

(d) Subcuticular abscess with subcutaneous 'collar stud'.

(e) Subcuticular abscess

(f) Osteomyelitis.

(g) Pulp space infection (discussed above).

(h) Apical pulp space infection - white spot

(i) Felon (NEET)

- Infection of the **terminal pulp space is known as 'Felon',** (NEET) which is common & potentially serious.
- Dull pain and swelling are the first symptoms, and if untreated, by the third day there are severe noctur-

nal exacerbations of throbbing pain, interfering with sleep.

- Light pressure over the affected pulp increases the pain.
- In the early acute phase antibiotic treatment is often successful.
- If localization of the pus has occured, which is indicated by persistent pain, localized tenderness, then it should be drained by a **lateral incision** which opens all compartments and avoids damage to the tactile tissue in front of the finger.
- If neglected, it may lead to necrosis **of distal 4/5 of** the terminal phalanx due to occlusion of the vessels by tension. The proximal 1/5 (epiphysis) escapes because its artery does not transverse the fibrous septa.

(ii) Apical abscess

It is a special type of pulp space infection. The infection is confined at first to the space between the distal quarter of the subungual epithelium and the periosteum. Frequently the pus bursts through the subungual epithelium to lie beneath the distal portion of the nail. Although very painful; there is comparatively little swelling. Tenderness is greatest at or just proximal to the free edge of the nail.

Treatment consist of evacuating the pus through a small incision over the most tender point. If there is much pus under the nail a triangular segment of nail should be removed.

Infection of The Middle Volar Pulp Space

In this instance also, the infection follows direct implantation of organisms by a prick. The finger is held in semiflexion in about 1/3 of cases an attempt to straighten it is painful. There is tender induration over the space.

In early cases, it is difficult to distinguish infection of the middle volar pulp space from infection of the underlying flexor tendon sheath; however, in the former, some relatively pain free movement of finger is possible.

In late cases, due to tracking of pus, frequently a purulent bleed appears in the distal flexor crease.

Infection of Proximal Volar Pulp Space

While this space is well partitioned from the middle space distally, proximally it communicates freely with the web space. Once localization has occurred, infection of this space is comparatively easy to diagnose. There is tender induration in this segment of the digit and frequently a web becomes involved also.

Web Space Infection

- The space between the bases of the fingers communicates, with the dorsum of the hand & proximal pulp spaces of the fingers via loose connective tissue at the side of fingers. Infection in these areas can spread to web spaces, or the spaces may become infected directly from an abrasion on the overlying skin.
- Constitutional symptoms are usually severe and patients are often seen before localization of the infection has occurred. At this stage there is gross edema on the back of the hand. Later; once localization has occurred the involved fingers are separated by the swollen web, which bulges out both palm wards and dorsally and adjacent web spaces may also become involved. The maximum tenderness is found on the volar (palmar) surface of the web and at the base of one or other of the adjacent fingers.
- In the early stages the infection is in the nature of a diffuse cellulitis, which may resolve with antibiotic therapy. Once localization has occurred, then the abscess should be drained by a short transverse incision on the palmar surface about 1 cm proximal to the web margin.

OTHER SERIOUS HAND INFECTION

1. Tendon Sheath Infection (Acute Suppurative Tenosynovitis)

The synovial sheaths surround the flexor tendons within the fibrous flexor sheaths; those of the index, middle and ring fingers end proximally at about the level of the metacarpophalangeal joints, but the sheath of thumb is continuous with radial bursa, and that of the little finger with the ulnar bursa.

In 11% of cases, sheath of either the index, middle or ring finger, or combinations of these communicates with the ulnar bursa. Also a point to remember is that the radial and ulnar bursae are communicated in over 80% of cases.

Infection is usually by the prick of a sharp pointed object such as a needle, a thorn, or the dorsal fin of a fish. The whole sheath is rapidly involved. In an established untreated tendon sheath infection there is severe throb-

bing pain and swelling of the finger; which takes up a slightly flexed position. Passive movements cause severe pain.

2. Ulnar and radial bursa infection Signs of involvement of the ulnar bursa

1. Flexion of finger's (usually little finger)
2. Fullness of the palm.
3. Fullness immediately proximal to the flexor retinaculum on the ulnar side.
4. A point of maximum tenderness over the level of transverse palmar crease ***(Kanavel's sign)***

Signs of involvement of the radial bursa

1. Flexion of the thumb.
2. Tenderness over the flexor pollicis longus sheath.
3. Swelling just proximal to the flexor retinaculum on the radial side.

Treatment

- Surgical exploration is indicated for any tendon sheath infection that has not settled completely after 48 hours of adequate antibiotic treatment. The fibrous sheath is exposed through volar incision placed at the entrance of the sheath and the distal skin crease of the finger. The hand is splinted in the position of immobilization in a boxing glove dressing, and antibiotics are given systemically.
- If the ulnar bursa is infected it should be explored through a longitudinal incision on the volar aspect of the wrist, care being taken not to cross the wrist at a right angle.
- The radial bursa is approached through an incision on the ulnar border of the tendon of flexor carpi radialis. In both the approaches, care is taken not to injure the median nerve, while opening the bursa.

INFECTIONS OF THE PALMAR SPACES

1. Deep Palmar Abscess (Mid Palmar Space infection)

- Mid palmar space lies deep to the flexor tendons and lumbrical muscles encircled by ulnar bursa and superficial to the three medial metacarpal bones with intervening interossei. It is separated from the thenar space by an oblique septum attached deep to the 3rd metacarpal and superficially to the middle finger profundus tendon.
- Usually the infection follows a penetrating injury, but it can result from the bursting of an undrained infection of the index, middle or ring fingers.
- Swelling of the back of the hand is extreme.
- *Obliteration of the concavity of the palm with even slight bulging is pathognomonic.* Passive movements of the fingers are limited and are extremely painful.
- Localization of pus usually becomes evident by tracking to the surface of the palm or one of the webs.
- The mid-palmar space is drained through one of the appropriate lumbrical canals.

2. Thenar Space Infection

- This space lies deep to the thenar muscles and superficial to the adductor pollicis. It is separated from the mid palmar space by a septum which.
- Infection of this space gives rise to the typical ballooning of the thenar eminence, which is quite characteristic. The flexion of the distal phalanx is pronounced.
- It is drained via the lumbrical canal on the radial border of the index finger.

3. Palmar subaponeurotic space (Superficial middle palmar space)

- It lies deep to the palmar aponeurosis and superficial to the flexor tendons. It contains the superficial palmar arch and the digital branches of the median and ulnar nerves.
- Infections of this space is usually secondary to an abrasion or penetrating wound of the palm. When pus is localized in the palm, it must be drained and a careful search made for any connection with another deeper collection, since collar stud abscesses are often found in this region.

INFECTIONS OF THE DORSAL SPACES

(A) Dorsal subcutaneous space

(B) Dorsal subaponeurotic space

- The subcutaneous space is deep to skin and the subaponeurotic space deep to extensor tendons. The most frequent causes of dorsal space infection are a boil of the overlying skin and a penetrating wound.

- The space can be drained by incision along the margins of the hand.

INFECTION OF THE PARONA'S SPACE

This space lies in the lower part of forearm anteriorly lying deep to the flexor tendons and superficially to the pronator quadratus may be infected by proximal extension of the infection from mid-palmar space and the thenar space and suppurative tenosynovitis. Deep seated abscess may develop, and fluctuation is difficult to elicit. Induration that pits on pressure suggests abscess formation, drainage is obtained by longitudinal incision.

****

MISCELLANEOUS CONDITION OF HAND

1. Whitlow

Better known as Herpetic Whitlow. It is a differential diagnosis of felon or pulp space infection. *This is caused by herpes simplex virus and may be found, in dental workers.*

Small vesicles appear, which may become crusty.

Severe throbbing pain, swelling and erythema over the distal phalanx of a single digit occurs. History of exposure to HSV, small vesicles surrounded by wheals, absence of pus and a soft pulp space help to distinguish it from a felon. Acyclovir can relieve the pain.

2. Bites

All wounds sustained from contact with teeth are potentially serious, because of risk of infection. Serious infection and subsequent loss of function can result from animal or human bites. Organisms in **human bite include *Staph aureus*** (M/C) (PGME). *Step, pyogenes, Eikenella corridens; staph epidermidis,* anaerobic organism, bacteroids. Animal bite organism include Pasteurella multicodens. *Strep, pyogens, Step, viridence, Bacteroids, Staphylococci* are common in both. Exploration and debridement should be done under adequate anesthesia.

3. Compound Palmar Ganglion

An old term signifying *tuberculous tenosynovitis* of the ulnar bursa. In long standing cases the fingers are partially flexed and there is an hour glass shaped swelling, with swelling above and below the flexor retinaculum.

Characteristics feature is the soft crepitant sensation derived from the movement of the melon seed bodies within the bursa.

4. Barber's Pilonidal Sinus

It is due to the clipped hairs which penetrate the skin of the web of the hands of barbers and cause a cyst with recurrent infection. In the uninflamed state the lesion is characterized by a small black dot situated towards the dorsum of the affected cleft. Excision of the cyst is treatment.

5. Orf

It is transmitted by sheep. The virus causes red papules which becomes reddish blue and then grey nodules. The vesicles are less painful than Herpetic whitlow. The condition resolves after a few weeks.

6. Implantation Dermoid

It is a painless, soft cystic swelling under the skin Of hand which is neither attached to the skin nor to the deeper structures. The most accepted reason is that at some previous time a fragment of epidermis was driven beneath the dermis and continued to proliferate.

7. Sporotrichosis (Sporothrix Schenckii)

Usually result from puncture wounds. A papule develops at the injury and then metastatic infection spread to the lymph channels. Synovitis is common. Treatment is debridement and Amphotericin B.

****

GANGLION

A ganglion is a localized tense, cystic swelling arising in connection with the joint capsule or tendon sheath (PGME). The exact etiology of ganglion is not known, but is supposed due to myxomatous or mucoid degeneration of fibrous tissue of joint capsule or tendon sheath.

Common sites

- Dorsum of the wrist (Commonest site: fig 12.3)
- Front of wrist
- Dorsum of foot
- Palm of hand

A ganglion usually presents as a painless, cystic swelling in young adult. Sometimes pain and discomfort on movement of wrist (or affected joint) may be present.

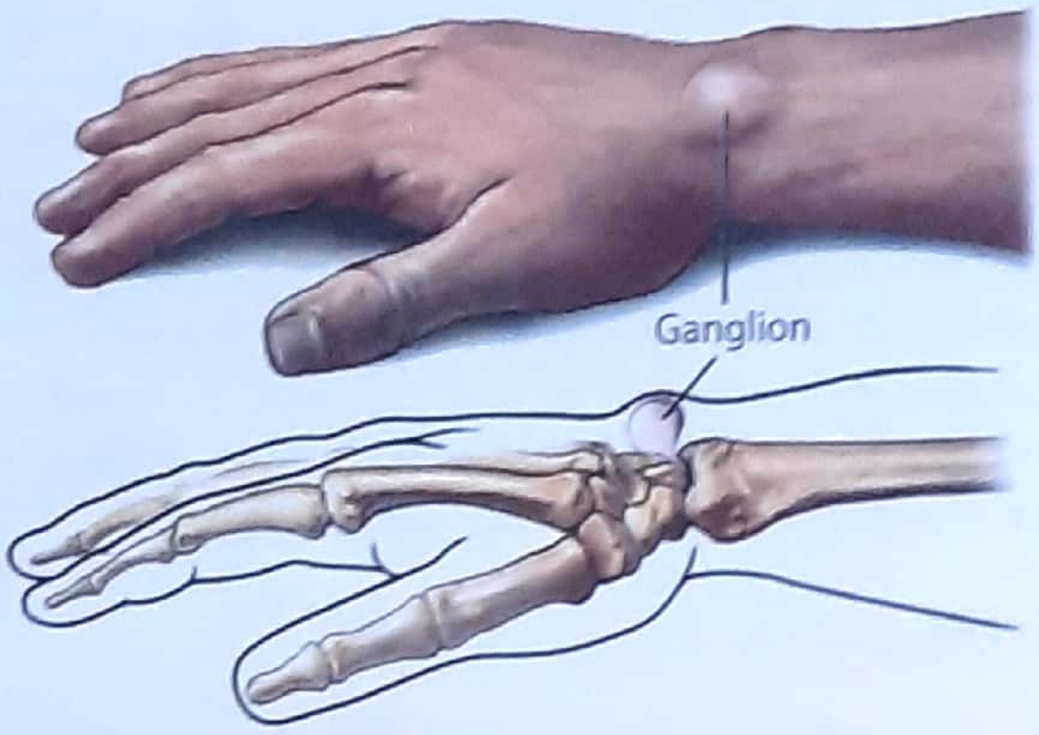

Figure 12.3: Ganglion on wrist joint

Treatment

Conservative treatment is as following:-

1. Local compression
2. Aspiration of the cyst and injection of sclerosing agent (3% sodium morrhuate or 5% phenol in almond oil) or hydrocortisone.
3. Multiple puncturing.

Operative Treatment

Complete excision of the ganglion is the best treatment, however recurrence is very common.

.....

THE SURGICAL INCISIONS OF THE HAND

Certain principles are applicable to all incisions of the hand

1. An incision in the palm of the hand should be longer than and incision on the dorsum of the hand, because the palmar skin lacks mobility.
2. The incision should be of adequate length to avoid necessary retraction, (See fig 12.4)
3. Incision should be parallel to major skin creases of the hand as far as possible.
4. An incision should not cross a skin creases at a right angle
5. A mid lateral incision must be dorsal to the ends of the flexor creases in the digits.

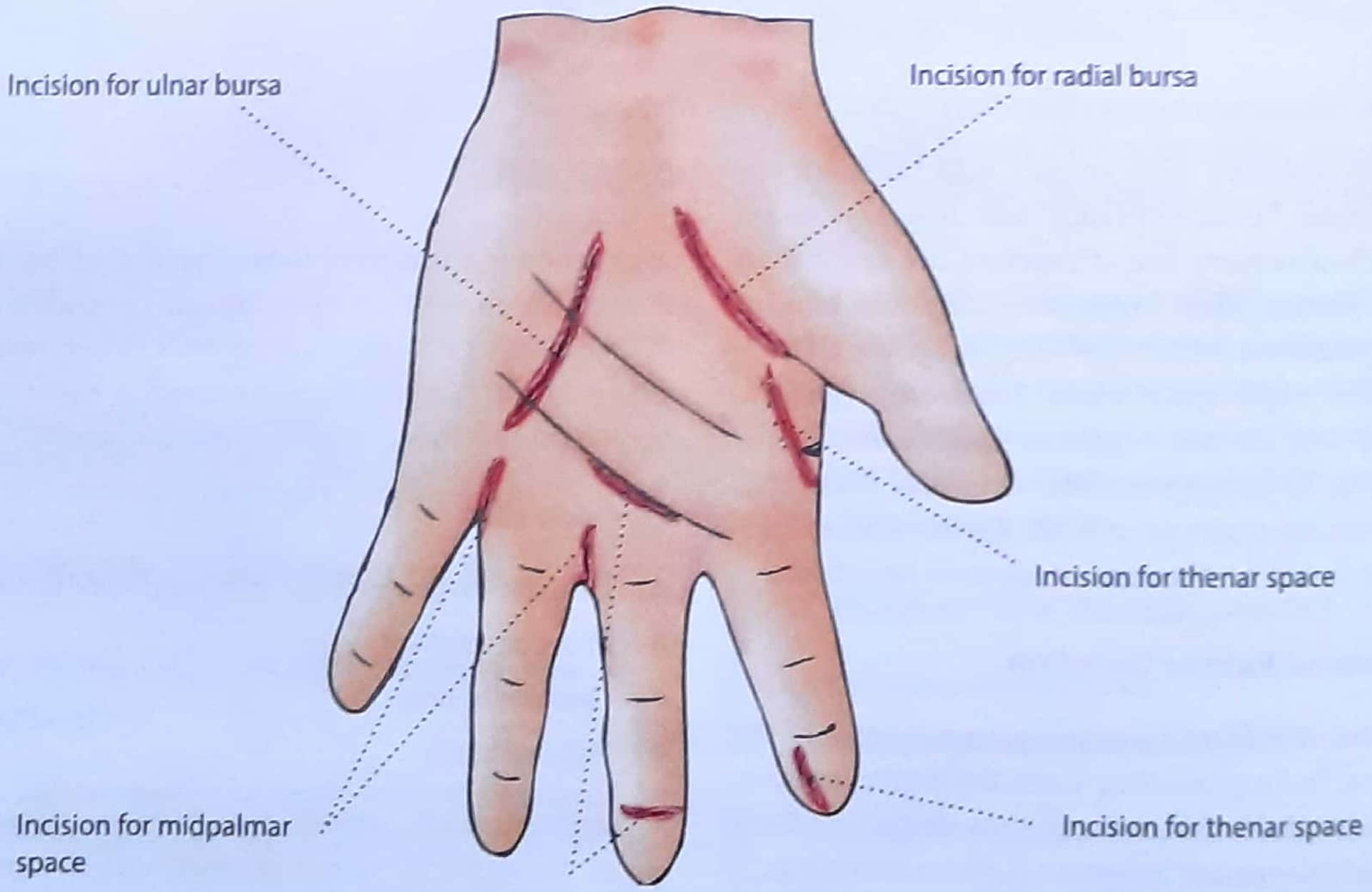

Figure 12.4: Various incisions for hand infections

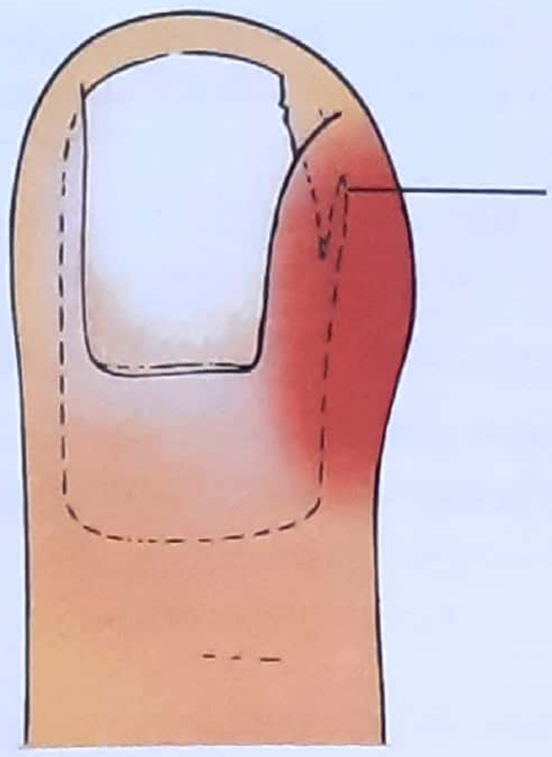

Figure 12-5: Ingrowing toe nail

The general principles of management of hand infections are quite straight forward and comprise:

1. Rest in the position of immobilization
2. Elevation to minimize edema
3. Appropriate antibiotic treatment
4. Surgical drainage of localized pus
5. Rehabilitation; once the infection in under control

****

DISEASES OF FOOT

PLANTAR FASCITIS

This is uncommon cause of hind foot pain, it starts from the plantar aspect of the heel. On examination, there is an area of tenderness on the heel. X-ray examination of foot may show a calcaneal spur.

Treatment consist of changing of footwear, wearing soft footwear, local injection of steroid or local anesthetic. If these measures fail a surgical release incision is made on the plantar fascia. Recently role of physiotherapy has been found very helpful.

INGROWING TOE NAIL

- In growing toe nail is described as an **excessive lateral growth of the nail into the nail fold, and** most commonly involves great toe. In most of the case the cause is idiopathic, while in some cases it may result from wearing of tight shoe, along with imperfect paring of nails. (Nail paring = Nail cutting). Fig 12.5.
- It is caused by the lateral edge of the toe nail cutting and growing into the adjacent soft tissue of the nail fold. Later superimposed infection (bacterial or fungal) causes inflammation and granulation tissue formation. It is a very painful condition.

Management

(a) Conservative

1. Keep the feet clean and dry
2. Avoidance of tight shoes
3. Proper nail cutting

(b) Operative Treatment

For long standing cases, total excision of the germinal matrix with the nail is required.

****

DIABETIC FOOT

"Give diabetes one inch, it will take your foot or even leg"

Figure 12.6(a): Diabetic Foot

Figure 12.6(b): Diabetic foot

Overview

- Diabetic foot is a clinical syndrome involving pain, deformity, inflammation, infection, ulceration and tissue loss of the foot in a diabetic patient. The greatest fears in a diabetic patient, is loss of eye sight and amputation.
- Due to mistaken belief and relative simplicity of diabetic foot, to it's more glamorous cousins like retinopathy and nephropathy, this problem has not been given, due respect in scientific publications.
- *It would be useful to impress upon the reader that incidence of diabetic foot as a diabetic complication is more than combined incidence of retinopathy, nephropathy, MI and stroke.* (IMP. POINT)
- Among people with diabetes 15% will have a foot ulcer in their life time and about 15-25% of them will require an amputation.
- In developed country like USA the annual incidence of lower extremity leg and foot ulcer is 200,000 and 56,000 major amputation are done for them. This is greater than all the complications of diabetes including coronary artery disease 10100, stroke 27000, blindness 6900 and renal failure 5900. In India, the prevalence of diabetes mellitus is adults was found to be 2.4% in rural population and 4-11% in urban population. Person with diabetes are at significantly high risk of lower extremity amputation.
- A person with diabetes is 15 times more likely to have a lower extremity amputation, than a non-diabetic individual.
- Experts from national diabetes data group and world health organization gave the criteria for diagnosing diabetes mellitus as:-
  - Symptoms of, diabetes + random blood glucose concentration > 200 mg/dl (11.1 mmol/L)
  - Fasting plasma glucose > 126 mg/dL (7 mmol/L)
  - Two hour plasma glucose > 200 mg/dL (11.1 mmol/ L) during an oral glucose tolerance test.

Pathophysiology

In the majority of patients diabetic peripheral neuropathy play a central role in up to 50% of patient with type II diabetes, but in developing countries like. India, infections and ischemia plays a major role in diabetic foot. In a diabetic patient recurrent plantar web space infection leads to superficial ulcerations and deep abscesses in fascial planes. The microangiopathy and polymicrobial infections in a hyperglycemia patient leads to foot sepsis involving deep plantar spaces and the foot ulcerations.

The diabetic foot results due to:

1. Neuropathy,
2. Vasculopathy and
3. Infection.

1. Peripheral neuropathy (Neuropathic foot)

This involves all the system ie; Motor, Sensory and Autonomic.

(a) Motor

Paralysis of intrinsic muscles of the foot and unopposed action of the calf muscle resulting in distortion of morphology, viz; alteration of weight bearing points of foot, subluxation of metacarpophalangeal (MP) joint leading to **Charcot foot *(rocker bottom foot)***, and unusual pressure points and ulcers. This lead to prominence of metatarsal heads.

(b) Sensory

Sensory loss leads to impairment of pain, deep pressure & temperature sensations and neuropathic ulcers develops

(c) Autonomic

Disruption of vasomotor control leads to reduced sweating and cracked dry skin, vulnerable to infection.

2. Microangiopathy (Neuro-ischemic foot)

The diabetics commonly develop micro angiopathy with thickening of the basal membrane of capillaries and arterioles. This may be associated with subintimal proliferation. This can cause significant peripheral ischemia and may be one of the cause of neuropathy.

A Neuro-ischemic foot is cool, pulse less foot with poor perfusion, however intermittent claudication and rest pain may be absent because of coexisting neuropathy, resulting in sensory loss.

3. Infected foot

Infected foot is a hallmark is Indian patients. Major factors complicating the issue are:

- Bare foot walking
- Lack of education
- Surgical attempts at home
- Use of unsterile topical application
- Late reporting to the higher centre:- by the time patient reports to a specialized centre, infection is already deep seated.

The Integral Part of A Classical Diabetic Foot

The foot is often massively swollen, foul smelling and the patient is toxic with signs of septicemia. Such an infected foot is limb threatening, requiring urgent amputation and is at time even life threatening.

The most common organism are *S. aureus,* anaerobic infections, *Bacteroids, Proteus* and *Enterococci.* It has been seen that degree of hyperglycemia is directly related to infection.

Clinical Feature

The natural history and clinical feature of diabetic foot can be divided into six groups:

1. The **foot is normal** and not at risk. The patients does not have the risk factors that renders him vulnerable to foot ulcer. These are neuropathy, ischemia, deformity, callus and edema.
2. **High risk foot** The patient developed one or more of the risk factors for ulceration of the foot.
3. **Foot with ulcer** Ulceration is on the plantar surface in the neuropathic foot and on the margin in the neuroischemic foot.
4. **Foot with cellulitis** The ulcer has developed infection with the presence of cellulitis which can complicate both the neuropathic and neuro-ischemic foot.
5. **Foot with Gangrene** In the neuropathic foot infection is usually the cause: In the neuro-ischemic foot infection is still the most common reason, although severe ischemia can directly lead to necrosis.
6. If the foot cannot be saved, it will need a major amputation.

Treatment

A. Prophylaxis: includes the following

- Control of diabetes
- Proper care of the feet by patient (keep the feet clean and dry)
- Stop smoking
- For minor injuries proper first aid treatment is essential
- Wearing comfortable shoes.

B. Treatment of ulceration, cellulitis & edema of foot

- Bed rest and appropriate antibiotics
- Twice daily dressing with antibiotic ointments.
- Debridement of superficial necrotic tissue an drainage of pus, if present.

C. Treatment of suppuration with marked cellulitis and Gangrene

- If suppuration and marked cellulitis is present; figure 12.6(b) then extensive debridement is done.
- All dead tissue should be excised and gangrenous part should be amputated.

****

MADURA FOOT

- Madura foot was first recognized as a clinical entity in madurai (south India) in 1860 for the first time, its fungal etiology was demonstrated and was called mycetoma.
- It is localized chronic progressive granulomatous inflammatory lesion and is characterized by gradually increasing painless tumour like swelling, with discharge of pus and granules through multiple sinuses.
- In great majority of cases, infection is introduced by a thorn prick.
- Firm painless nodule develop on the foot. These nodule increase in size and vesicle on the surface of

Figure 12.7: Madura foot with discharging sinuses

the nodule burst and a sinus develops which **starts discharging black, purulent material containing characteristic granules** *(PGME MANY TIMES)*, later on secondary infection takes place. See figure 12.7.

- The causative organism are true fungi (Eumycetes which causes maduromycoses) or bacteria or nocardia.

Clinical Features

It is characterized by 3 S;

- Swelling,
- Sinuses,
- Serosanguineous discharge, with granules.

Management

It is important to differentiate between the true fungal and pseudo fungal (nocardia) infection. Nocardia mycetoma can be treated successfully by dapsone (100 mg BD) along with broad spectrum antibiotic to deal with secondary infection. True fungal mycetoma (madura- mycetoma) does not respond to any drug and surgical excision remains the mainstay of treatment.

****

Sample Questions for Prof Examination

Write short notes on the following:

1. Diabetic foot.
2. Madura foot.

13 Skin Lesions and Skin tumour

Contents

- Function of Skin
- Benign skin Lesion
  - Dermoid cyst
  - Sebaceous cyst
  - Lipoma
  - Corn
  - Callosity
  - Hemangioma
    - Capillary hemangioma
      - a. Strawberry anigoma
      - b. Portwine stain
      - c. Salmon patch
    - Cavernous hemangioma
    - Arterial or plexiform hemangioma
- Neurofibroma
- Moles
- Premalignant lesions of the skin
- Malignant tumours of skin
  - Basal cell carcinoma (Rodent ulcer)
  - Squamous cell carcinoma (epidermoid carcinoma)
  - Malignant melanoma
  - Other skin malignancies

FUNCTION OF SKIN

Skin is the largest and most complex organ in the human body. The surface area is 10,000 sq cm to 18,000 sq cms and the total bulk of the skin and subcutis is about 15 percent of the body weight. It serves **various function, such as:**

1. Protective Function

It is primarily the protective barrier from

(i) Chemicals, by impermeability of epidermis,

(ii) Physical agents like solar radiation, by pigmentation.

(iii) Infective microbial, by immunosurveillance.

(iv) Deformation of deeper tissues.

2. Other function are

(i) Thermoregulation

(ii) Maintenance of fluid and electrolyte balance

(iii) Maintenance of acid base balance

(iv) Crude and fine perception from external world; and last but not the least

(v) Sexual stimulation.

Structurally, the skin has three different layers: epidermis, dermis and subcutis. Histologically; **epidermis** is composed of several layers viz; stratum corneum (horny layer), stratum granulosum, stratum spinosum, stratum basale, and the basement membrane. Please see figure 13.1 on next page.

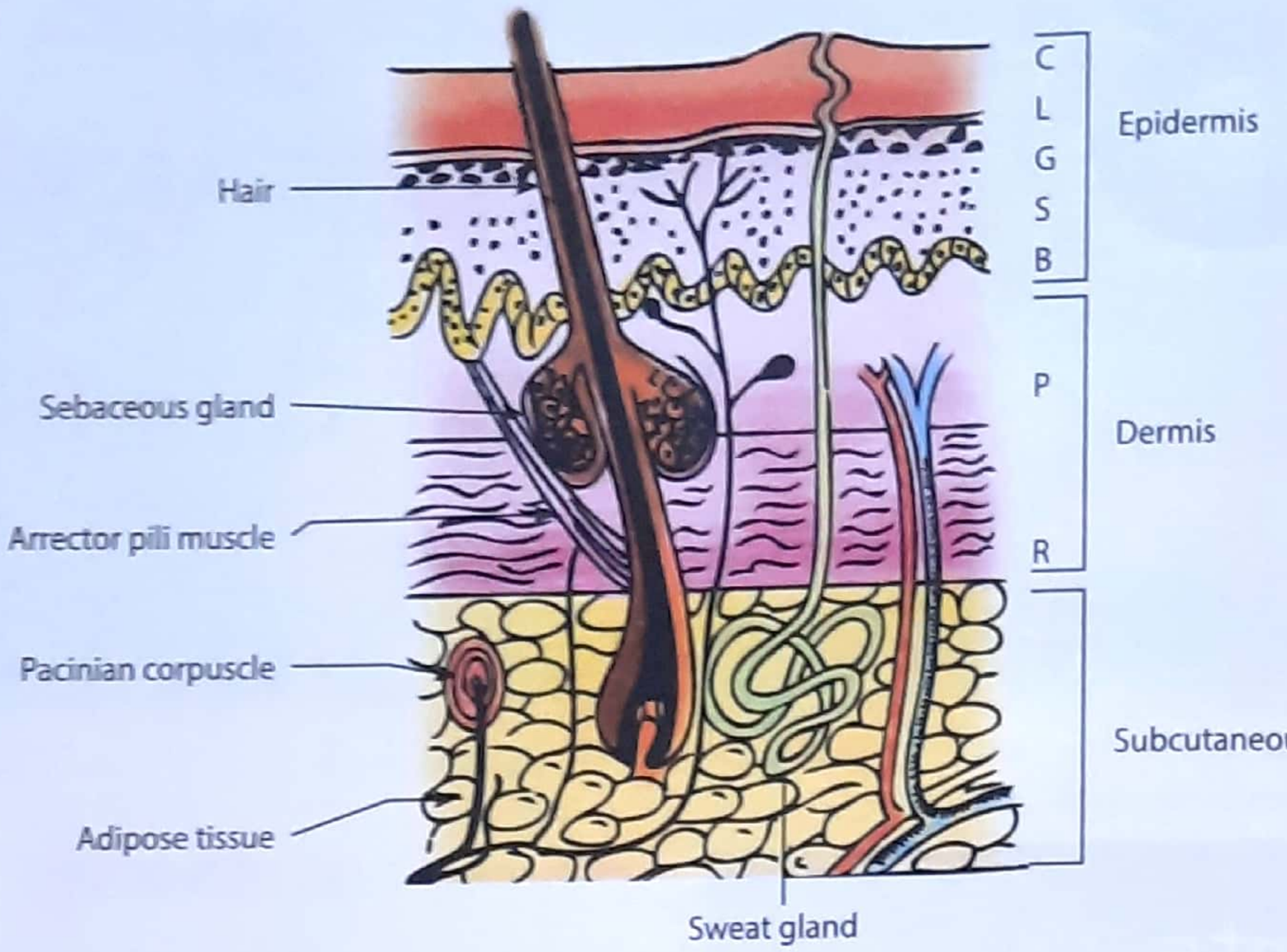

Figure 13.1(a): C = stratum Corneum, L = stratum Lucidium, G = stratum Granulosum, S = stratum Spinosum, B = stratum Basale **(of epidermis).** P - superficial Papillary layer *(of dermis)* R = deep Reticular layer **(of dermis)**

- Basically, there are *three types of cells.* Viz; keratinocytes, melanocytes and langerhan's cells.
- *Langerhan's cells are antigen presenting cells* (MANY PGME). They migrate to regional lymph nodes and communicate with immune system.

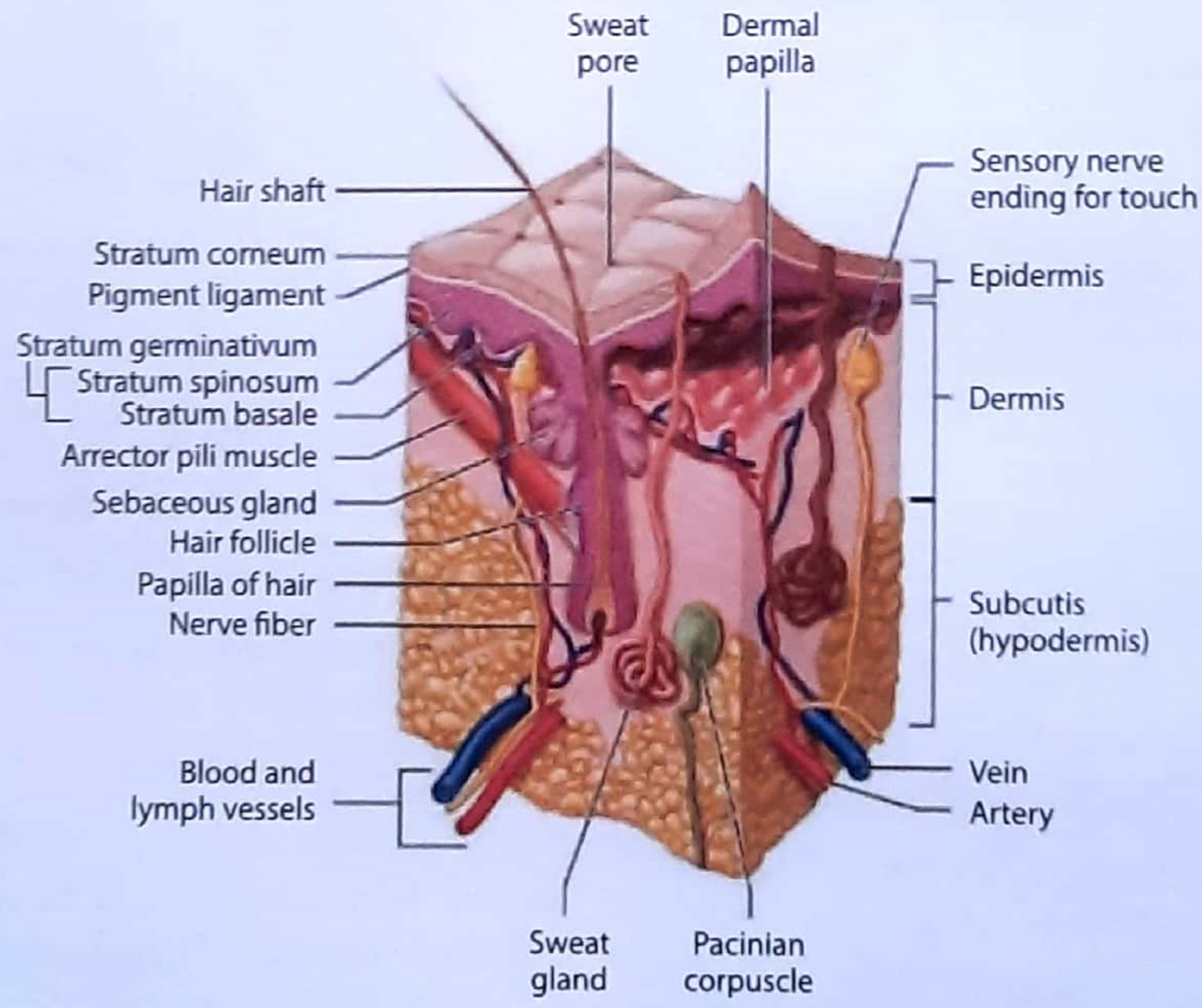

Figure 13.1(b): Schematic representation of the skin and its appendages. Note that the root of the hair follicle may extend beneath the dermis into the subcutis

- Keratinocytes have important role in maintaining homeostasis in skin by secreting a number of cytokines.
- **The dermis** comprises of (i) **papillary dermis** and (ii) **reticular dermis.** It contains sweat glands, sebaceous glands and hair follicles. It also contains the blood vessels in fine plexuses, intricate network of nerve fibres and sensory nerve endings for pain, touch and temperature. *The collagen deposition in dermis is mainly of type I and type II.* (PGME MANY TIMES)
- The skin has three main adnexal structures viz; the sweat glands, the hair follicles with their germinal centres and the sebaceous glands, together, these structures constitute a *pilosebaceous unit.* The apocrine glands are located in axilla and anogenital regions. The sebaceous glands secrete sebum, which keeps skin soft and oily. The ducts open at the hair follicles or on the skin surface.
- Before going into further details of diseases of skin, I will strongly advise you to go through figure 13.1 (a & b), and know the layers of skin, it will definitely help in understanding (and locating) various diseases.

****

BENIGN SKIN LESIONS

Dermoid Cyst (Epidermal Cyst)

- A dermoid cyst (also know as *epidermal cyst)* lies deep to the skin and is lined by skin, but is not directly attached to it.
- It is lined by squamous epithelium, and contains pultaceous or tooth paste like material which contains desquamated epithelial cells, sebum and sweat.

Clinical Types

There are four types of dermoid cyst:

1. Sequestration dermoid
2. Implantation dermoid
3. Tubulo-dermoid
4. Teratomatous dermoid

1. Sequestration dermoid

This is a congenital variety of dermoid cyst, which is formed by inclusion of epithelial 'nests' at the line of embryonic fusion. So these are found along the line of fusion of the two embryonic segments; eg:

Common Sites

1. Midline of the body (specially neck)
2. External angular (Just above the outer canthus of the eye) Figure 13.2.
3. Post auricular region
4. Anterior triangle of neck (branchial cyst)
5. Root of nose
6. At the site of fusion of the skull bones.

Pathology

This is a congenital condition. During closure of epidermal clefts and sinuses by skin fusion, dermal cells or epithelium may get buried along the line of closure. Then they liquefy together with sebum and sweat, forming a sequestration dermoid cyst. That is why these cysts lie deep to skin.

Clinical Feature

- A painless, slowly enlarging swelling is the main symptom and cosmetic disfigurement is the main complaint.
- The cyst may be present at birth, but is usually seen a few years later.
- The sites where these cysts usually occur are:- midline, external angular region (just above the outer can-thus of the eye, see figure 13.2), at root of nose (median nasal), behind the ear (posterior auricular) and on the skull at the site of fusion of the skull bones and anterior triangle of neck (branchial cyst).

Figure 13.2: External angular dermoid

- It usually presents as a pea sized swelling under the skin, and is usually fixed to the underlying bone.
- Dermoid cyst is not attached to skin, so *the skin can be lifted off the cyst easily.* (IMP. POINT)
- Cyst is soft and cystic and may indent (yield) on pressure, as the contents in the cyst is pultaceous.
- Transillumination test is negative.
- The cyst is neither compressible nor reducible.

Complication

- Infection
- Suppuration
- Ulceration
- Pressure symptoms

Treatment

Complete excision of the cyst is the treatment of choice, which is usually done under general anesthesia, as the cyst may require dissection from the sensitive pericranium, because it may have intracranial extension.

2. Implantation dermoid

It is an acquired cystic lesion, which develops following a puncture injury, in which **epithelial cells are implanted into the sub cutaneous tissue,** due to needle prick or thorn prick injury. See figure 13.3.

Common sites

These dermoids are more common jn gardeners, women and tailors. Common sites are:

- Palm of the hand
- Any part of finger
- Pulp or tip of finger
- Sole of foot
- Rarely on buttocks and knees

Clinical Features

- A history of puncture injury is usually available, however many patient may have forgotten any injury.
- A swelling in the finger or the palm is usually the presenting feature.
- The cyst may be slightly painful and tensely cystic, or even feel hard, (though not actually hard)

Figure 13.3: Implantation dermoid

Treatment

Consist of complete excision of the cyst.

3. Tubulo-dermoid

It is a type of epidermal cyst, developing from an unobliterated portion of congenital ectodermal duct or tube. It is formed by accumulation of secretion of the lining ectodermal cells of the unobliterated portion of an embryonic duct.

Examples of tubulo-dermoid cysts

(a) Thyroglossal cyst

Develops from the thyroglossal duct and is the commonest example of tubulodermoid cyst. (Discussed later)

(b) Post anal dermoid

- Develops from the remnant of neuroenteric canal or post anal gut and is now considered as a simple form of teratoma.
- It is usually seen in the space in front of the lower part of the sacrum and coccyx.
- It usually remains symptomless until adult life; when it is prone to become infected and cause pressure symptoms.
- Exceptionally, they may enlarge to very large size, and gives rise to difficulty in defecation due to compression on rectum.
- The cyst is easily palpable as a bulge on rectal examination.

- ***Treatment*** is complete excision of the cyst and sinus if present. In the case of large cyst, it is necessary to remove the coccyx in order to gain access.

(c) Ependymal cyst in the brain

They originate from the sequestration of cells derived from the infolding neuroectoderm.

4. Teratomatous dermoid

This is a cystic swelling developing from totipotent cells with ectodermal predominance.

Pathology

It usually contains mesodermal elements like bone and cartilage. The contents are usually bone, cartilage, tooth, hair and cheesy material. Hairs are almost always present in such cyst.

Common sites of occurrence are

(i) Ovary: Ovarian teratoma

(ii) Mediastinal cyst: they are always situated in the anterior mediastinum, and may be cystic or solid,

(iii) Retroperitoneum.

(iv) Post anal dermoid

Treatment is by complete excision of cyst

SEBACEOUS CYST (EPIDERMOID CYST/WEN)

- Sebaceous glands are present in skin, and secrete sebum which keeps skin soft and oily. Sebaceous cyst develops as a result of obstruction at the opening of a sebaceous gland, so **it is a retention cyst** *(NEET)* (retension of sebum) and is more accurately called as epidermoid cyst.
- The cyst lies *under the epidermis* and is free from it except at the place, where the mouth of the duct would open on the skin. This fixation of the cyst is usually seen as a black spot and is called **'Punctum'.**

Common sites

A sebaceous cyst can be seen any where is the body but most commonly seen in those parts where there are abundant sebaceous glands. Most common sites are:

1. Scalp
2. Scrotum
3. **Back** (figure 13.4)
4. Shoulder
5. Chest

- The sebaceous cysts of scrotum are often multiple & when well formed may feel solid due to calcification.
- ***Sebaceous cysts*** **does not occur in the palm or sole** *(NEET, PGI 88)*, because there are no sebaceous glands in the palm and sole. *(MANY PGME)*.

Clinical Features

- It can occur at any age from young to old, but are rare among children.
- These are typically a cystic swelling, which are spherical in shape and about 1-5 cm in size.
- The overlying skin is smooth and there is a blackish spot or 'punctum', which indicates the blocked opening of the duct.
- Sebaceous cyst is always fixed to skin, so the overlying skin cannot be pinched off the swelling.

In Case of dermoid cyst and a lipoma overlying skin can be pinched off from the swelling (IMP. POINT)

- Transillumination test is almost always negative.
- Tenderness on palpation, indicates infection in the cysts.

Treatment

- Total excision of the cyst is the treatment of choice.
- If the cyst has become infected, preliminary antibiotic therapy should be given and the excision is carried out when the infection has subsided.

Figure 13.4: Multiple sebaceous cyst on scalp, note they can occur any where in the body ***except*** palm and sole.

Figure 13.5: Sebaceous horn

Complication

1. **Infection:** This is most common complication of sebaceous cyst.
3. **Sebaceous horn:** Slow discharge of sebum from a wide punctum may taken shape of horn; a condition called as sebaceous horn. (Figure 13.5. Very rare).
3. **Ulceration and cock's peculiar tumour** very occasionally an infected sebaceous cyst ruptures leaving a persistent ulcer. When present in the scalp, it may resemble an epithelioma (squamous cell carcinoma), and is then called as cock's peculiar tumour (UP, AIIMS04, OTHERS).
4. **Calcification:** Sebaceous cyst of scrotum may calcify sometime and appear hard on palpation.

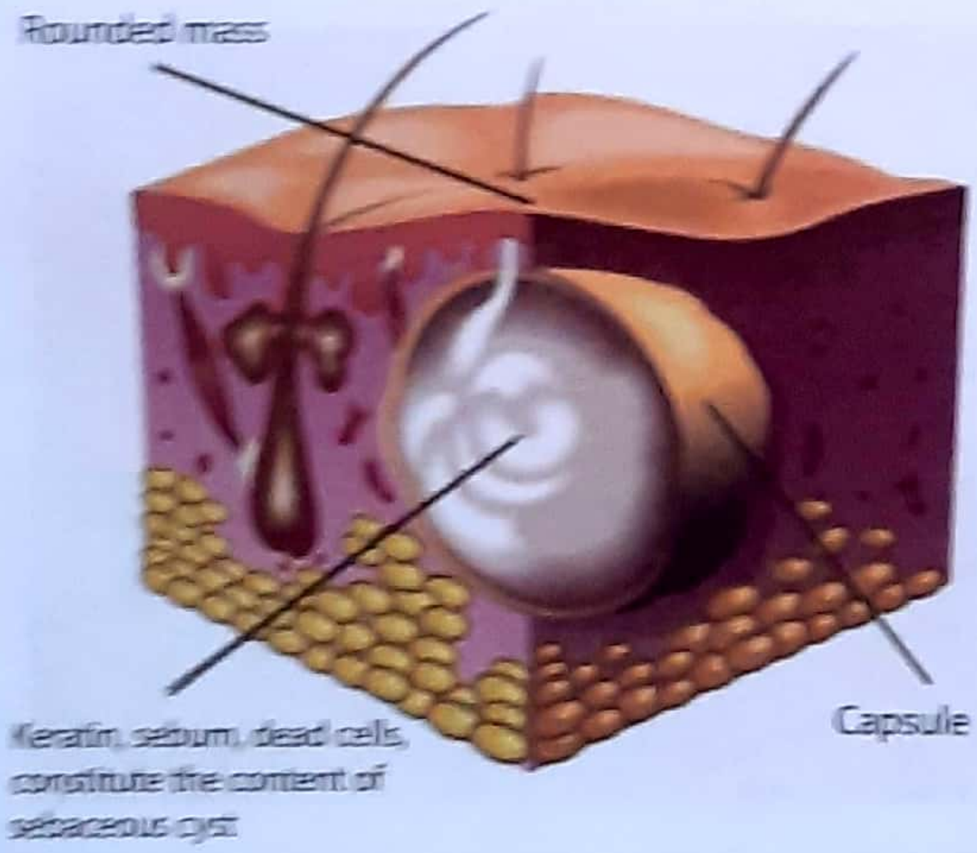

Figure 13.6: Diagnostic presentation of sebaceous cyst

LIPOMA

(Lipos = fat, Oma = tumour)

A lipoma is *commonest benign tumour* (Universal tumor) (PGMEE MANY TIMES). It is a slow growing benign tumour, composed of adult type cells and are found in any area of the body, where fat is normally found, that is why it is often called as 'universal tumour' or ubiquitous tumour (PGI 08). However the most common sites are the subcutaneous tissue of :

- Trunk
- Neck
- Shoulders
- Neck

Clinical types

1. *Encapsulated:* This is commonest variety and has well defined capsule.
2. *Diffuse:* This is a rare variety: it is also called a pseudolipoma.
   - It is a typical tumour of fat but has *no capsule.*
   - It is commonly seen in the subcutaneous and inter-muscular tissue of the neck.
   - It causes disfigurement of the region involved
   - It is often found in persons taking excessive alcohol.
3. *Multiple lipomas*
   - These are fairly common and are often referred to as lipomatoses.
   - The tumours are multiple, small to moderate in size, and are sometimes painful, in which case the condition is probably ***neurolipomatoses***, also called as ***Dercum's disease (adiposa dolorosa)*** (PGI 80, AIIMS 84), characterized by multiple tender deposits of fat especially on the trunk.
4. *Other types:* A few lipomas may contain other tissues and are named accordingly:

Figure 13.7: Lipoma of neck

(a) *Neurolipoma:* A lipoma containing nerve tissue; it is often painful due to pressure on involved nerve.

(b) *Fibrolipoma:* A lipoma containing excessive fibrous tissue.

Clinical feature

- It usually presents as a painless swelling and most common complaint is cosmetic disfigurement.
- Lipoma can occur anywhere in the body, but more common on upper limb, around shoulder, and in the neck or back.
- It is usually lobulated, compressible and often slips away from the examining finger. This is called as **slip sign**. The tumour itself feels typically soft, but does not fluctuate (but as fat at body temperature may be liquid, ***pseudo-fluctuation*** may be present)
- A lipoma is freely mobile over the deeper structures
- TRANSILLUMINATION test may some time be POSITIVE. This is only one condition which may transilluminate even through it is not a cyst.

Treatment

A lipoma should always be *excised*. Mostly the patient wants it for cosmetic reason, but even if there is no complaint, it should be excised due to its various complications.

Complication

1. Pressure effects due to enlarging large lipoma.
2. Degenerative changes:
   (i) Myxomatous.
   (ii) Saponification
   (iii) Calcification
3. Superficial fat necrosis, may occur as a result of injury.
4. Sarcomatous change (Liposarcoma) are seen particularly in retroperitoneal region, gluteal region and occasionally shoulder region.

CALLOSITY

- This is a localized, thickening or hardening of a part of skin caused by friction or pressure in that area, as a protective measure.
- It is usually a painless condition, and is characterized by thinking of the epidermis particularly the stratum corneum and the granular layer.
- On examination, callosity is a localized thickened area of skin which has no central core as seen with corn. (Figure 13.9(a))
- There is no need for treatment, although paring may be necessary and should be carried out by trained chiropodist. (Figure 13.9).

CORN

- **A corn is a localized hyper keratosis of the skin** *(PGME)*. Histologically a corn is composed of keratin masse with *intact basal layer.*
- It usually occurs at the sites of frictional pressure on the sole, foot and toes. This often occurs due to ill fitting or tight shoes.
- It consists of circumscribed, horny thickenings, which is cone shaped, with the apex pointing inwards, and the base on the surface. (Figure 13.8 & 13.9(b))
- Corn is thicker than callosity and causes more concern to the patient.
- It presents as yellow nodules over palm.

Treatment

- Corn may spontaneously disappear when the etiological factor is removed.
- Some times, **corn cap** may be beneficial.

Figure 13.8: Corn

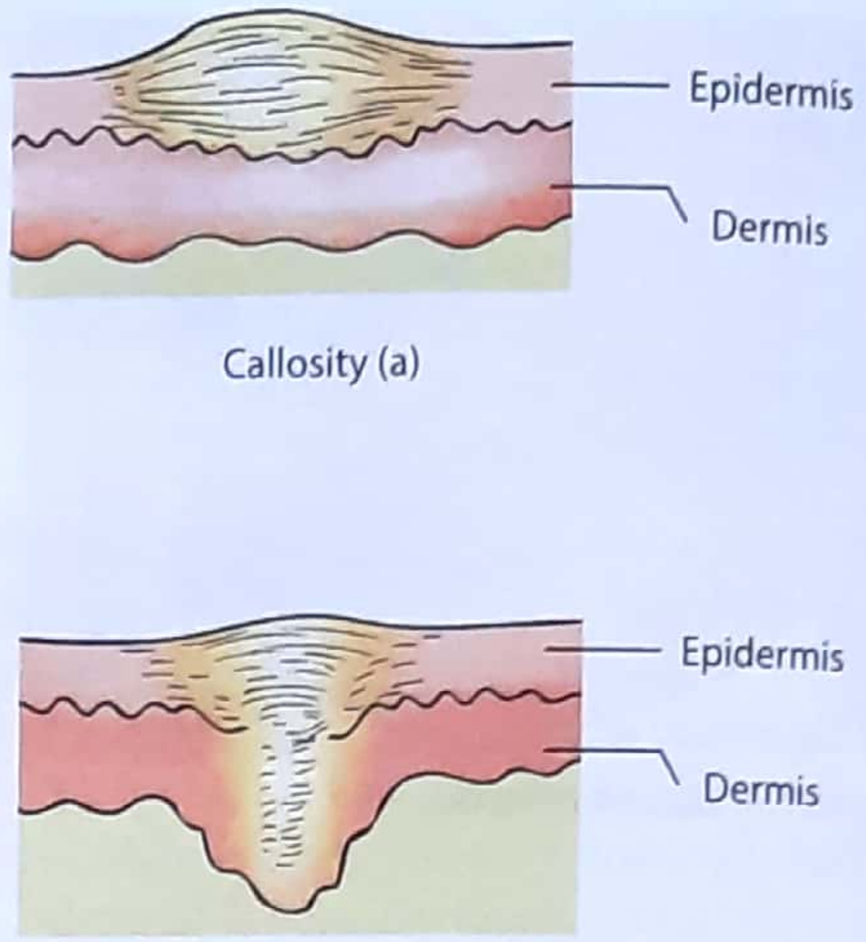

Figure 13.9: Note corn bores deep in dermis, while callosity is limited to epidermis

- If these measures fail and corn is painful, it should be excised with deep root of central core. This will prevent recurrence.

AINHUM

- It is a condition seen in childhood who run barefoot.
- A fissure appears at interphalangeal joint of toe - usually the fifth. *(NEET)*
- This fissure becomes a fibrous band, encircle the digit little toe & cause necrosis. *(NEET)*

WART

A wart is a patch of over growth of skin with hyperkeratosis. Virus is thought to be causative agent. Most common virus being human papilloma virus (HPV). *(PGME)* The disease can be transmitted by direct or intimate contact and can occur in all age, though commonly found in children, adolescent and young adults. The main complaint is of disfigurement.

Treatment

Most of the wart disappear spontaneously, but some may require treatment.

Important fact remains that there is no complete cure. Application of podophyllin and salicylic acid or silver nitrate may be helpful. Excision is done with diathermy Cryosurgery

Surgical removal is contraindicated as it may lead to scarring and recurrences rate is high.

Now lets move to another important topic

HEMANGIOMA

Hemangioma is a developmental malformation of blood vessels and are not typical tumour. About 70% are present at birth, which suggest that they may be hamartoma* rather than true tumour. Any organ may be involved but skin, liver and brain are common sites.

Hamartoma: A tumour resulting from over growth of normal tissue

Types of Hemangioma

There are mainly three types of Hemangioma

1. **Capillary Hemangioma:** Arising from capillaries.
2. **Venous or cavernous hemangioma:** Arising from the vein.
3. **Arterial or plexiform Hemangioma:** Arising from arteries.

Now lets discuss them one by one:

1. Capillary Hemangioma

There are three varieties of capillary hemangioma: strawberry angioma, port wine stain and salmon patch.

(a) Strawberry Angioma *(VERY IMPORTANT TOR PGME)*

- This is a bright or dark red in colour, protruding slightly from the skin surface. The surface is irregular and may be covered with areas of ulceration and scab formation. Please see figure 13.10.
- It is not pulsatile, but is compressible.
- The layers underneath the skin is often involved, and in severe cases the muscle may be affected.
- *The newborn is normal at birth* *(MANY PGME)* *and at the use of 1-3 weeks after birth, a red mark is noticed. This red mark gradually increases in size and takes a typical strawberry or raspberry like swelling.*
- *After the first birth day the angioma gradually regresses in size and involution may be complete by the age to 8 years* *(MANY PGME)*.
- Strawberry angioma is soft, **compressible** *(NEET)* and is not pulsatile. On pressure, most of the blood from angioma empties, leaving it collapsed. As soon as the pressure is released, refilling occurs quickly.

Treatment

- ***Wait and watch policy*** *should be adopted as majority of strawberry angioma (more than 90%) disappear on their own.* *(MANY PGME)*
- If the lesion exist even after 8 year, and the child and his parent insist on treatment for cosmetic reason, the following may be tried:
  - (i) Excision of the lesion with skin grafting
  - (ii) Intra-lesional and oral steroid have been demonstrated to produce involution of-these lesions,
  - (iii) Injection of hot water or hypertonic saline or sclerosing agent (Asklerol) has be tried with success,
  - (iv) Radiation therapy carries a high risk of complication and is dangerous and should not be tried.
  - (v) Photocoagulation

(b) Port win stain *(NEET)*

- It is *usually present since birth and* **does not regress** for rest of the life. *(AIIMS NOV 01,UP 92, AL 93),*
- It is an intradermal capillary malformation, please see figure 13.11(a) and 13.11(b).
- It is commonly found at face, shoulder, neck & gluteal region *(PGME)*.
- There is no definite swelling, but is a diffuse vascular deformity.
- Treatment is aimed at improving cosmetic appearance.
- ***Treatment*** **of choice for these lesion is LASER** *(NEET, PGME)*.

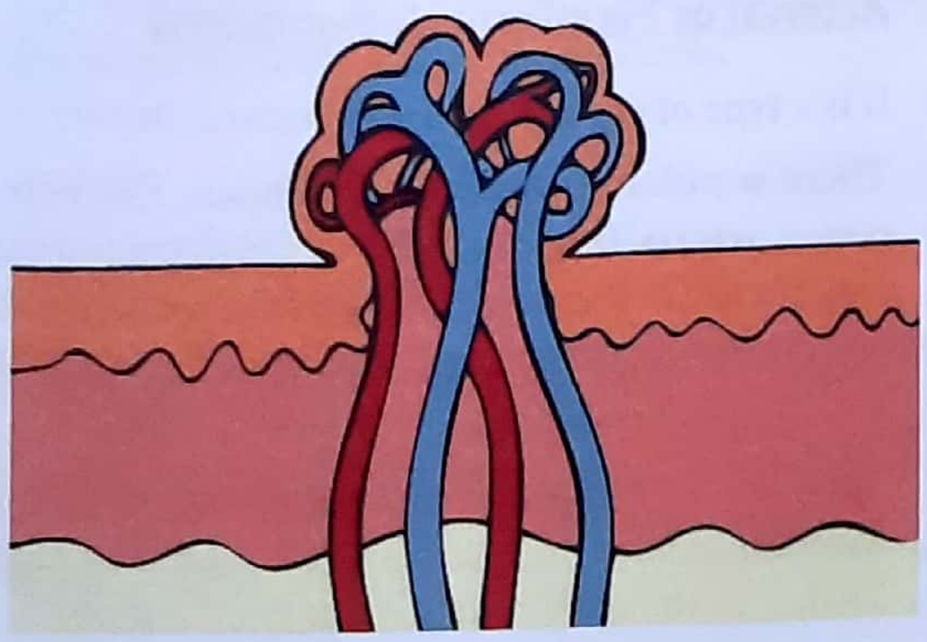

Figure 13.10: A strawberry naevus is an intradermal and subdermal collection of dilated blood vessels

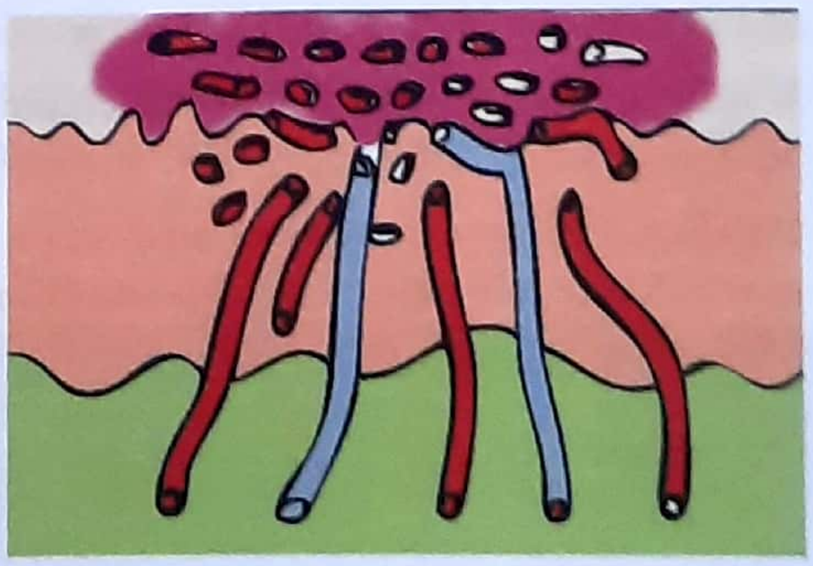

Figure 13.11 (a): A port-wine stain is a collection of dilated venules and capillaries just below the epidermis

Figure 13.11(b) Port wine stain

Figure 13.11(c) : Cavernous Hemangioma

(c) Salmon Patch (APPG 08)

- It is also *present since birth* (MANY PGME)
- It usually *disappears before the first birthday* (MANY PGME) *and is an involuting type hemangioma.*
- It is mostly seen over the middle of the forehead, or occiput or *anywhere in the midline.* (PGME)
- *Treatment: majority of these lesions disappear on their own and requires no treatment* (MANY PGME).

2. Venous or Cavernous Hemangioma

- It consist of multiple dilated venous channels, and is relatively uncommon. (Figure 13.11(c))
- It is a spongy swelling and usually present at birth, or may manifest in early childhood.
- It has no tendency to involute, and may become larger and more troublesome as time goes on.
- It may occur anywhere, but is more common in head, neck and limbs
- Occasionally they may be associated with a lipoma, in which case it is called a nevolipoma ***(Von Hippel Lindau Syndrome)***.

Clinical feature

It is felt like a soft, spongy mass (like a bag of worms).

- Overlying skin is bluish or atrophic.
- Sign of emptying is present (Compressibility)
- It is nonpulsatile, if pulsation is present it should be from associated A-V malformation
- It may produce ***local gigantism*** (hypertrophy of organs) (PGME).

Treatment

Generally conservative treatment is required like;

- Injecting a sclerosing agent into the lesion.
- Diathermy coagulation can be tried
- It the swelling is small and localized, surgery is the best treatment. The whole lesion is excised, after ligating the feeding vessels.

****

3. Arterial or Plexiform Hemangioma

- If is a type of congenital arteriovenous fistula.
- There is pulsatile swelling of arteries. The vein becomes **arterialized** due to flow of high pressure arterial blood in veins, which becomes tortuous, thick walled and pulsatile (arterialization); and feels like a bag of pulsating worm.
- This is often called **cirsoid aneurysm,** and is commonly seen on the forehead (figure 23.16 page 310) or in the scalp over the temporal region.
- The swelling is pulsatile and is also compressible.

Treatment

- An angiography is required to show the distribution of the lesion and anatomy of arterial system. Treatment options are:-

(i) Ligation of feeding vessels.

(ii) Therapeutic embolization of the feeding artery.

(iii) Complete excision, following ligation of all bleeding vessels.

****

NEUROFIBROMA

A neurofibroma is a tumour arising from the connective tissue of the nerve sheath. This is a developmental disorder and is often considered as hamartoma and not a typical tumour.

Clinical types *(SEE KEY BOX 13.1)*

Broadly it can be divided in-

1. Local or solitary neurofibroma
2. Generalized neurofibromatosis: This is also called as Von-Reckling Hausen's disease.

1. Local or Solitary Neurofibroma

- A solitary neurofibroma is found in the subcutaneous tissue and usually *arises from the sheath of a peripheral nerve,* eg; median nerve, ulnar nerve or a cranial nerve (where; it is called ***acoustic neuroma***).

Clinical feature

- Swelling is the main presenting feature.
- Pain or hyperaesthesia along the course of the nerve due to compression on the nerve fibres.
- Neurofibroma is a smooth, firm swelling along the course of the nerve and has well defined margins.
- It can be moved sideways, but not longitudinally along the long axis of the nerve. They may be tender.
- A neurofibroma may undergo cystic degeneration or sarcomatous changes.

Treatment

Excision of the tumour is treatment of this condition.

2. Generalized Neurofibromatosis (VonRecklinghausen's disease)

- Neurofibromatosis is the *commonest hereditary neurocutaneous syndrome,* with an estimated prevalence of 1:3000 in the USA.
- *Two heritable forms of neurofibromatosis, both* **autosomal dominant** *(MANY PGME)* are recognized:

(a) Neurofibromatosis 1 *(INICET NOV. 20)*

This is the classic form of the disease, characterized by numerous neurofibromas in the skin and peripheral nerves, associated with pigmented patches in the skin known as ***café au lait spots.***

- It results from an abnormal gene carried on **chromosome** 17 *(PGME)*. Diffuse proliferation of nerve elements may cause massive enlargement of tissues ("elephantiasis neurofibromatosa" or "Elephant man disease").
- Malignant transformation of neurofibromas occurs in 5-10% of cases *(PGME)*.

(b) Neurofibromatosis 2

This is relatively rare form, the gene of which is carried on **chromosome** 22 and is characterized by bilateral acoustic neuromas.

- In both types of neurofibromatosis, other neoplasms of the nervous system such as optic nerve glioma, meningioma and astrocytoma may occur *(PGME)*.

KEY BOX 13.1			
Heredity neurocutaneous syndrome			
Disorder	**Chromosome**	**Features**	**Tumours**
Neurofibromatosis- 1	17	Neurofibroma, cafe aulait spots	Cutaneous and peripheral nerve neurofibromas, other CNS neoplasms
Neurofibromatosis - 2	22	Bilateral acoustic neuromas	Acoustic neuromas, other CNS neoplasms

Figure 13.12: Multiple neuro-fibromatosis

Figure 13.13: Hairy mole

Treatment

This swelling is numerous and excision of all the neurofibroma is impossible. When an individual swelling is enlarged excessively & cause symptoms, then it should be excised.

****

MOLES (SYN: NEVUS, BENIGN MELANOMA)

- The most common benign lesion is a 'nevus' or a 'mole' (For Hindi speaker's Til).
- Most of them are present at birth.
- These lesions are composed of melanocytes of neuroectoderm. The melanocytes increases in number, to form moles in different layers of skin.
- These may be congenital or acquired type.

Types

1. Hairy Mole

This is a common variety. It is slightly raised above the level of skin, and has hairs growing from its surface. Figure 13.13.

2. Non-hairy or Smooth mole

This is also very common. The surface is not elevated and there is no hair growing from its surface.

3. Blue Nevus

It is uncommon, smooth hairless lesion measuring less than 1 cm in diameter. They arise deep in the dermis. The thick overlying layers of the dermis and epidermis mask the colour of the black melanin and make it *look blue*. It is commonly seen on the face, dorsum of the hand, feet and buttocks of babies called as **mongolian spot.** Malignant degeneration in these lesion are rare.

4. Junctional Nevus

These are dark, flat smooth lesions, which ranges generally from 1-2 cm is diameter. They are occasionally hairy and develop around the Junctional or basal layer of the epidermis.

Junctional moles are immature and unstable and can turn malignant and in fact most common lesion to turn into malignant melanoma. (PGME MANY TIMES)

5. Compound Nevus

These are brown to black in colour, and usually 1-cm in diameter. They may be elevated and are frequently hairy, arising from the epidermo-dermal interface and from with in the dermis. Malignant transformation is rare.

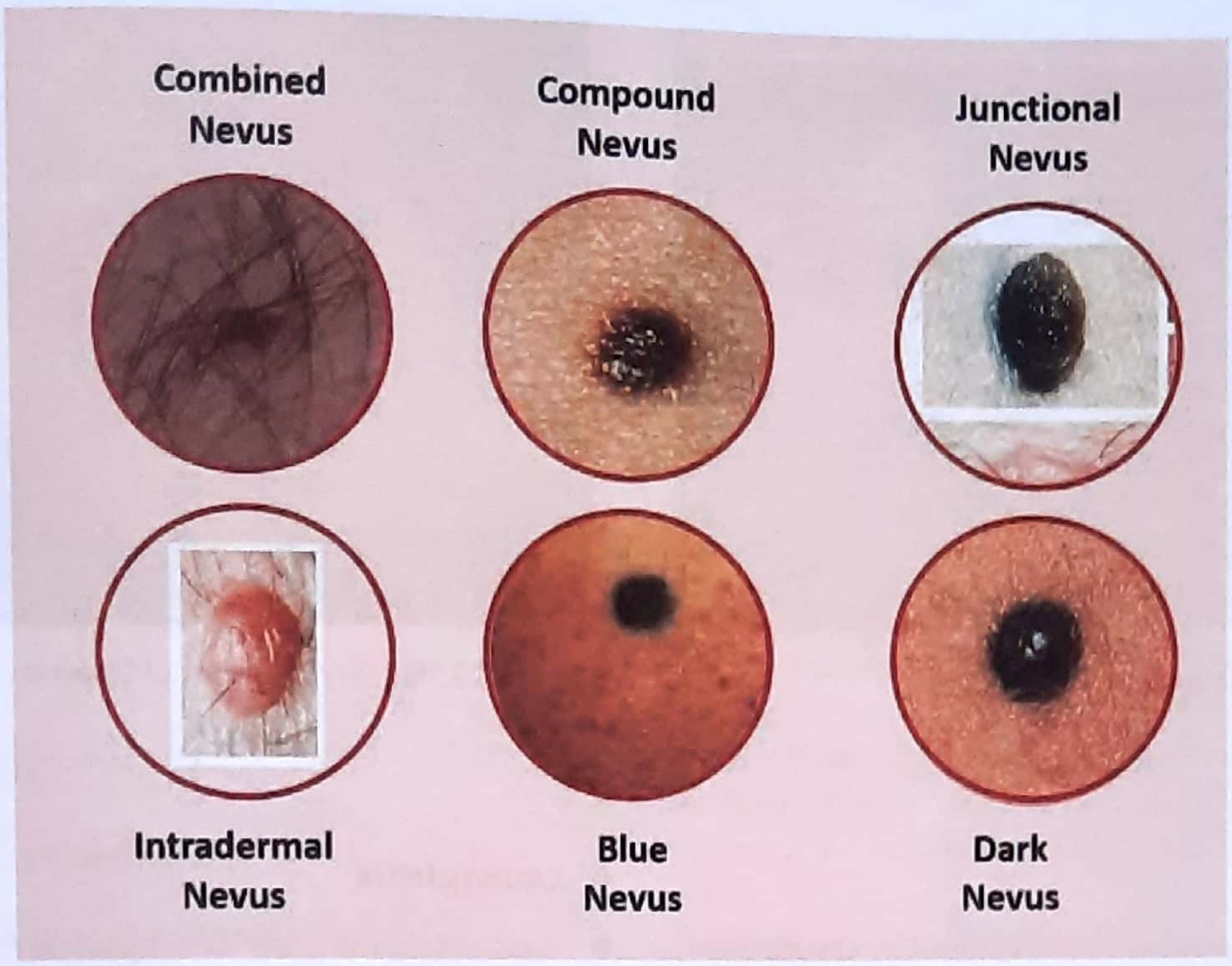

Figure 13.14: Moles

6. Benign Juvenile melanomas (spitz nevus)

These are smooth, round, pink to black lesions measuring 1-2 cm in diameter. It is usually found in young children and the face being the commonest site. Malignant degeneration is rare.

7. Giant Pigmented hairy nevus

These brown to black hairy lesions, and have an irregular nodular surface. They frequently involve more than 1 feet of body surface and arise from the dermis and Junctional areas. Malignant degeneration has been estimated at approximately 10%.

Treatment

1. *Treatment is indicated for functional and giant pigmented nevus, because of their malignant potential.* (IMPORTANT POINT)
2. Indication, for excision of any pigmented lesion include:
   - Changes in colour, size, shape, or consistency.
   - Pain.
   - Satellite nodules.
   - Regional lymphadenopathy.
3. Except for large lesions, excisional biopsy, with a margin of normal skin, should be performed. Further therapy may be indicated, depending on the histological diagnosis and location of the lesion.
4. For large lesions, a full thickness wedge biopsy, including a small area of normal skin, should be taken.

****

PREMALIGNANT CONDITIONS OF THE SKIN

1. Solar (actinic) keratosis

- This is the *most common premalignant condition* and is also called as **senile keratosis** (PGME)
- It occurs as a multiple scaly or warty lesions.
- It appears as red/yellow or brown multiple scaly or warty lesions. (Figure 13.15)
- Exposure to sun rays is the most important predisposing factor and the most effective wavelength for carcinogenesis is UVB (290-320 nm) of solar spectrum.
- About 15-20% of lesions become malignant, with invasion of dermis.

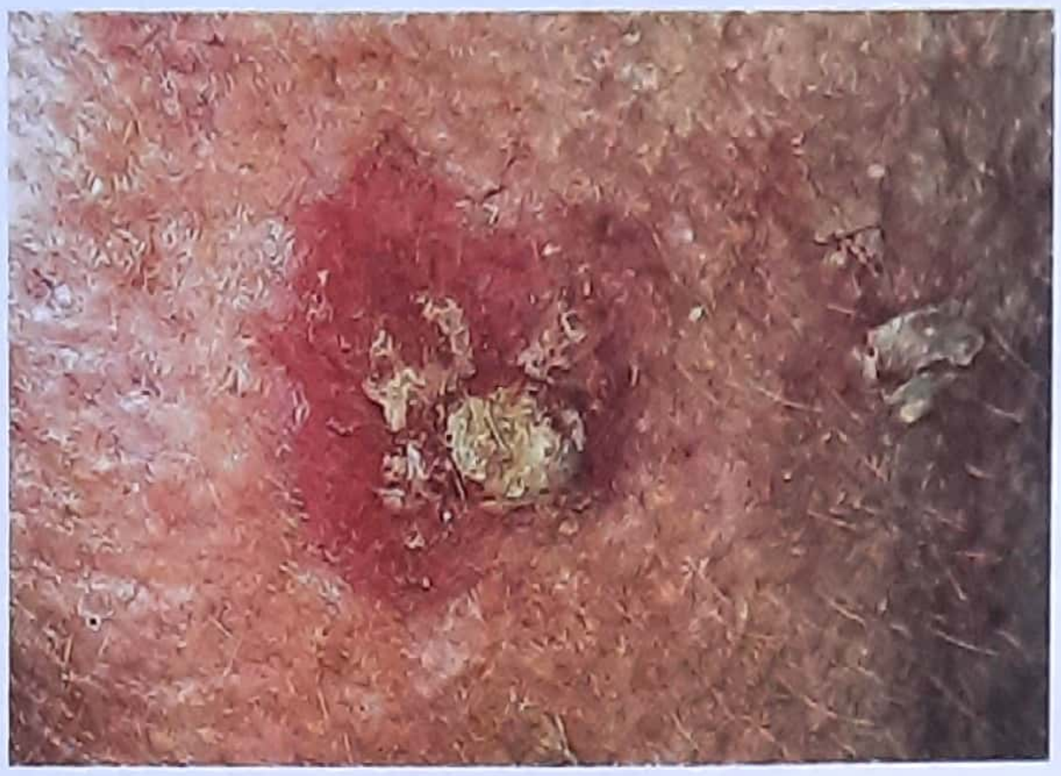

Figure 13.15: Solar (actinic) keratosis

Figure 13.16: Erythroplasia of Queyrat

Treatment

- Superficial lesions are best removed by **cryotherapy,** with carbon dioxide or liquid nitrogen.
- Indurated lesion are best excised.
- Multiple lesions may be treated by application of tropical 5- fluorouracil (5-FU).

2. Bowen's disease

- It presents as a single or multiple raised thickened plaque like lesions, *(plaque = patch like)*
- It can occur on any part of body but particularly on trunk of an elderly.
- It is caused by solar radiation or found in those with arsenic ingestion.
- It is considered as carcinoma-in situ, and carcinoma may arise after 15-20 years.

Treatment

Cryotherapy* or **cauterization** to destroy the lesion is treatment of choice. (Cryotherapy*: See index)

3. Erythroplasia of Queyrat

- Bowen's disease of the glans penis and the vulvae is called Erythroplasia of Queyrat. (Figure 13.16)
- The lesion appears as red, velvety, irregular, raised plaque. **Treatment** is by wide local excision.

4. Leukoplakia

- Leukoplakia is seen as a hyper keratotic, smooth, white patch which is dry and rough to touch.
- Factors responsible for leukoplakia to develop is **"6S"** and Candidiasis *(MANY PGME)*. 6s are:
- Smoking
- Sepsis
- Sharp tooth
- Syphilis
- Spirits (alcohol)
- Spicy food

Treatment is by radiotherapy.

5. Radiation dermatitis

Due to excessive exposure to X-ray radiation; the superficial layer of skin is damaged.

- In early stages there is erythema which progresses to desquamation and hyperpigmentation
- On prolonged and greater exposure atrophy, irregular hyper pigmentation, telangiectasia and hair loss occurs.
- *The Squamous call carcinoma may develop.(PGME).*

6. Keratoacanthoma

It is a locally destructive skin lesion that is found most commonly on head, neck and upper extremities.

Please see figure 13.17

Figure 13.17: Keratoacanthoma

7. Uncommon Conditions

- Kraurosis Vulvae (Breisky's disease)
- Lupus vulgaris
- Long standing chronic ulcer
- Prolonged chemical irritation
- **Xerosis pigmentosum obliterans** (NEET)
- Long standing warts.

****

MALIGNANT TUMOURS OF SKIN

Basal cell carcinoma (Rodent Ulcer)

- ***Basal cell carcinoma are most common cancer of skin and accounts for 60% of all skin cancers.*** (PGME)
- Most common malignant neoplasm of eyelid.
- ***To remember:***

Just to remember: *Though the name is BASEal cell carcinoma, it is on the TOP in the list of malignant skin tumour, ie;* M/C *malignant skin cancer,* (MANY PGME). base=road, it is also called as rodent ulcer.

Etiology

- Exposure of ultraviolet rays of the sun (solar keratosis); hence seen commonly in persons exposed to sun light.
- X-ray irradiation
- Arsenic
- Burn and scars
- Genetic disorders (Xeroderma pigmentosum, Basal cell nevus syndrome, Albinism).
- Fair skinned individual.

Remember with ROAD = BASE (RODent Ulcer = Basal cell carcinoma, otherwise you may/will forget; for sure)

Origin

Basal cell carcinoma ***arises form basal layer of the epidermis,*** but occasionally a basal cell tumour may arise from basal cells of the hair follicles of sweat glands.

It usually occurs in middle aged, white people, residing in the tropical countries. Exposure to sunlight and arsenical dermatitis are important predisposing factor. It is a slow growing malignant tumour and erodes the deeper tissues like a rodent (rat), and hence, aptly termed as ***"Rodent ulcer"***. It is also called as ***"Tear cancer"***, because it is commonly found in the region, where tears roll down.

Such tumours (from hair follicle and sweat gland) are mostly seen in the scalp, of an adolescent and are called as **'turban tumour'** (PGME).

Spread (MAHE 07)

- Basal cell carcinoma usually spread by local invasion. It gradually destroys the tissues that comes in contact, that is why this tumour is called as 'rodent ulcer' [Rodent = Rat, which eats what ever comes in its way]
- ***Lymphatic spread is not seen*** (AIIMS MAY 18), hence the regional lymph nodes are not enlarged. *This is due to early lymphatic obstruction by tumour,* (IMP. POINT) (UPSE 07)
- Hematogenous spread is also very rare.

Clinical feature

- SITE: About 90% of basal cell carcinoma is seen on the face above the line drawn from angle of mouth to the lobules of the ear. *The common sites are around* ***inner and outer canthus*** (NEET) ***of eye, nose, and the nasolabialfold*** (PGI88, MANY PGME). (Figure 13.18 & 13.19).
- Patient complains of a persisting ulcer or a nodule, with central necrosis and telangiectasia. The lesion is painless in the beginning; through it may itch. (IMP. POINT)
- The lesion grows slowly. They may bleed slightly.
- In about 10% of patients, they may also be found on the tongue, esophagus, penis, anal canal or lower limb. Lesions in nasolabial fold behave very aggressively.

Figure 13.18: Basal cell carcinoma just below lower eye lid; **Note: Rolled edges of basal cell carcinoma**

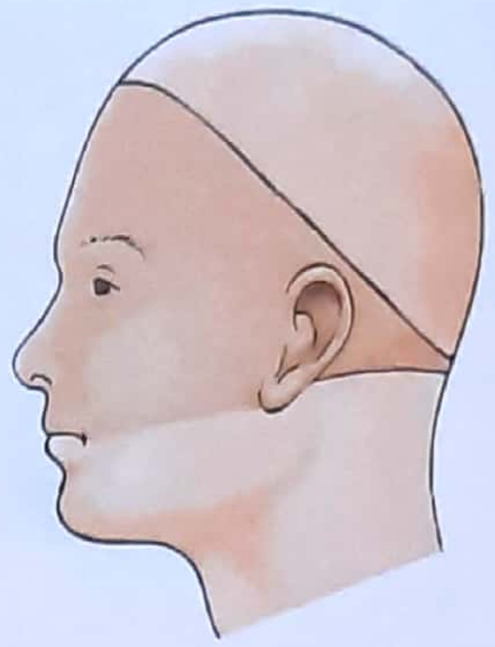

Figure 13.19: Dark shaded area represents the area of occurrence of Basal cell carcinoma

- There are multiple variants of BCC, and presentation can range from red, flesh-colored, or white macule or papule, to nodules and ulcerated lesions. (Figure 13.18)
- Growth patterns of these lesions can either be well-circumscribed or diffuse and the most common types of BCC are nodular and micronodular, superficial spreading, and infiltrative.
- The most common subtype is the nodular variant, characterized by raised, pearly pink papules with telangiectasias and occasionally a depressed tumor center with raised borders giving the classic "rodent ulcer" appearance.
- Superficial spreading BCC is confined to the epidermis as a flat, pink, scaling or crusting lesion, often mistaken for eczema, actinic keratosis, fungal infection, or psoriasis. This subtype typically appears on the trunk or extremities and the mean age of diagnosis is 57 years.
- The infiltrative form appears on the head and neck in the late 60s, often at embryonic fusion lines, with an opaque yellow-white color that blends with surrounding skin and has no raised edges.
- The morphea form subtype represents 2% to 3% of all BCC and is the most aggressive subtype. It usually presents as an indurated macule or papule with the appearance of an enlarging scar.
- The clinical margins are often indistinct, and the rate of positive margins after excision is high. There is also a pigmented variant of BCC that can be difficult to distinguish from certain melanoma subtypes.

Treatment

- Treatment involves the complete removal of the tumour to achieve a cure. Biopsy is mandatory to establish a pathologic diagnosis.
- Treatment of BCC varies according to size, location, type, and high- or low-risk. Treatment options include surgical excision, medical, or destructive therapies. Surgical excision should include 4 mm margins for small, primary BCC on cosmetically sensitive areas, and 10 mm margins otherwise. **Mohs microsurgical** excision is sequential horizontal excision and has been shown to be cost-effective and associated with low recurrence rates for BCC (1%). (Figure 13.20).
- It is the treatment of choice for morpheaform or other BCC with aggressive features, poorly delineated margins, recurrent tumors, or cosmetically sensitive areas, especially in the midface.
- A common approach used by dermatologists for very small (<2 mm) and low risk lesions is cautery and destruction.
- Other destructive techniques include cryosurgery and laser ablation.
- Radiation therapy can be used as adjuvant therapy following surgery, or as primary therapy in poor surgical candidates with low-risk lesions.
- Superficial medical therapies are generally reserved for patients in whom surgical and radiation treatment is not an option.

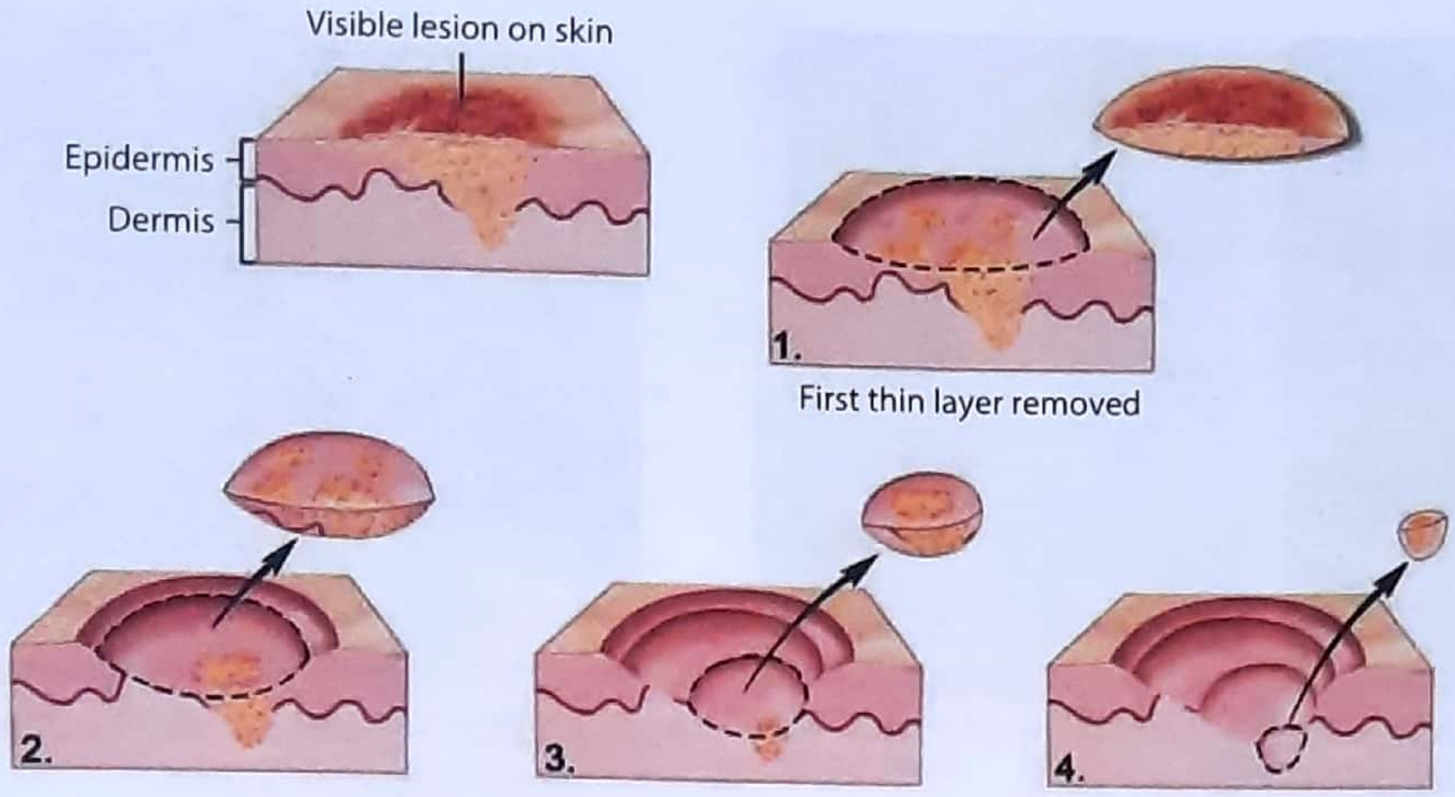

Figure 13.20: Mohs Surgery

- Topical imiquimod or 5-fluorouracil have been used for periods of 6 to 16 weeks for small, superficial BCC of the neck, trunk or extremities.
- Lastly, topical photodynamic therapy has shown some benefit in treatment of premalignant or superficial low-risk lesions as well.
- Patients with BCC need to have regular follow-up with full skin examinations every 6 to 12 months.
- Sixty-six percent of recurrences develop within 3 years, and with a few exceptions occurring decades after initial treatment, the remaining recur within 5 years of initial treatment. A second primary BCC may develop after treatment and, in 40% of cases, presents within the first 3 years after treatment.

Squamous Cell Carcinoma (Epidermoid Carcinoma)

- Squamous cell carcinoma is *second most common* type of skin malignancy and accounts for about 30% of all skin malignancy. (**NOTE:** most common being basal cell carcinoma, approx: 60%)
- Squamous cell carcinoma is a malignant skin tumour **arising from prickle cell layer of the epidermis,** commonly affecting exposed part of the body.
- Through it is a low grade malignancy, at times it may grow rapidly and may metastasize via the blood and lymphatic system.
- *A Squamous cell carcinoma is more malignant than a basal cell carcinoma* (MANY PGME).
- Squamous cell carcinoma may arise de-novo or there may be **underlying factors** such as solar keratosis, Bowen's disease, radiation injury, chronic unstable scar or contact with arsenical compounds.

Clinical feature

- *The most common presentation is proliferative or ulcerative growth* (PGME). A warty growth may also be present at times. Figure 13.21.
- In the *ulcerative type* a typical carcinomatous ulcer with raised *rolled out and everted margin* develop (JIPMER81, DELHI 86). Please see figure 13.21.
- Base is indurated, which later becomes fixed to deeper structure. Floor is usually covered by greyish white slough or blood stained discharge. If Infection supervenes early, it increases the serosanguinous discharge. Figure 13.22.
- ***The proliferative type*** is a sessile, cauliflower like mass, covered with crusts with an indurated base, due to sloughing out of a portion, this may appear ulcero- proliferative. Figure 13.21.
- In early stage when invasion through dermoepidermal junction has not occurred the presentation may be defined as red, scaling plaque.
- Some invasive lesions may present as a hyperkeratotic lesions.
- Clinical risk factors for recurrence include presentation with neurologic symptoms, immunosuppression, tumor with poorly defined borders, and tumor that arises at a site of prior radiation. Perineural involvement also has a poorer survival

Figure 13.21: Squamous cell carcinoma (A) Near left knee joint (B) left wrist joint

Figure 13.22: Squamous cell carcinoma forming in a chronic wound

with increased local recurrence and lymph node metastasis. Grades of differentiation are based on the ratio of differentiated to undifferentiated cells, with a lower ratio associated with a greater metastatic and recurrent potential. Large (>2 cm) lesions, depth of invasion >4 mm, rapid growth, and location on the ear, lips, nose, scalp, or genitals are all also indicators of worse prognosis.

Treatment

When feasible, wide surgical excision including subcutaneous fat is the treatment of choice for SCC. Margins of 4 mm are recommended for low-risk lesions and 6 mm for high-risk lesions. **Mohs microsurgical excision** is indicated for positive margins, recurrent tumors, sites where cosmesis or function preservation is critical, poorly differentiated tumors, invasive lesions,

KEY BOX 13.2

Differentiation of Epithelioma and Rodent Ulcer

Features	**Squamous Cell Carcinoma** (Epithelioma)	**Basal Cell Carcinoma (Rodent Ulcer)**
History		
Occurrence	No specificity	White race residing in tropics
Usual sites	Any part of body	Usually face or exposed part
Commences as	Crack, fissure or nodule	Nodule, cystic swelling or ulcer
Progress	Rapid	Very slow
Signs		
Appearance	Cauliflower, ulcerated	Ulcerated lesion
Margin	Rolled out, everted	Raised and beaded
Tissue base	Indurated and fixed	Slightly indurated
Lymphatic spread	Commonly present	Absent
Histopathology		
Originates from	Prickle cell layer	Basal cell layer

and verrucous tumors. Using this modality often results in lower recurrence rates. It has also found use in nail bed lesions and in those arising in a background of osteomyelitis. The role of lymph node dissection in the setting of SCC continues to evolve. Lymphadenectomy is indicated following fineneedle aspiration or core biopsy for clinically palpable lymph nodes or nodes detected on cross-sectional imaging. Nodes should also be removed from susceptible regional lymph node basins in patients with SCC in the setting of chronic wounds. Patients with parotid disease benefit from a superficial or total parotidectomy (with facial nerve preservation) and adjuvant radiotherapy. Sentinel lymph node dissection may be used in high risk cases with clinically negative nodal disease. Radiation therapy is typically reserved as primary therapy for those who are poor surgical candidates, and as adjuvant therapy after surgical resection for large, high-risk tumors. When used as primary therapy, cure rates may approach 90%.

Marjolin's Ulcer

This is a carcinoma that arise in a scar; most commonly in bum scar (figure 13.23). Histologically it is **squamous cell carcinoma;** (AL 06) however occasionally basal cell carcinoma may also develop. **These lesions may develop many years (10-20 years) after the original injury or burn.** See figure 13.23. The characteristic features are:

- It **grows slowly**, as the scar is relatively avascular.
- Due to loss of nerves in scar, it is painless condition.
- Lymph nodes are usually not involved, because lymphatics are already destroyed, due to injury or burn, but when the carcinomatous ulcer (carcinoma) invades normal tissue regional lymph node may be enlarged.
- Wide excision is treatment of choice. Prophylactic lymph node dissection does not alter mortality.
- Adjuvant radiotherapy improves survival.

MALIGNANT MELANOMA

What was relatively uncommon disease 50 years back, has now become alarmingly more common. *The important clinical features of a melanoma include a pigmented lesion with irregular, raised surface and irregular borders.*

The tumour occurs most commonly in the fifth decade of life and the incidence is approximately equal in men and women.

Figure 13.23: Marjolin's ulcer in a 20 year old burn scar on hip

The most common site in male is trunk and back and in female most common site is lower extremity (between knee to ankle) at dermal/ epidermal junction (MANY PGME).

Melanoma arises from transformed melanocytes and can arise any where, melanocytes have migrated during embryogenesis (AIIMS,PGI).

The eye, central nervous system, gastrointestinal tract, and even the gallbladder have been reported as primary sites of the disease.

Over 90% are found on the skin. Metastatic melanomas with unknown primary sites probably arise from completely regressed lesions that are difficult to locate.

Once the melanocyte has transformed into the malignant phenotype, the growth of the lesion is radial in the plane of the epidermis. Even though micro invasion of the dermis can be observed during this radial growth phase, metastases do not occur. The transformed cells in the vertical growth phase are morphologically different and express different cell surface antigens.

Risk factors - UV radiation, Personal History of skin cancers. PUVA Therapy, Immunosuppression, Dysplastic nevi, genital nevus , sputz nevi, Xeroderma pigmentosa, B-K mode syndrome

There are ***four common distinct types*** of melanoma in *order of decreasing frequency: superficial spreading (M/C), nodular, lentigo maligna, and acral lentiginous,* however, the most common variety in dark skinned person is Acral lantiginous melanoma.

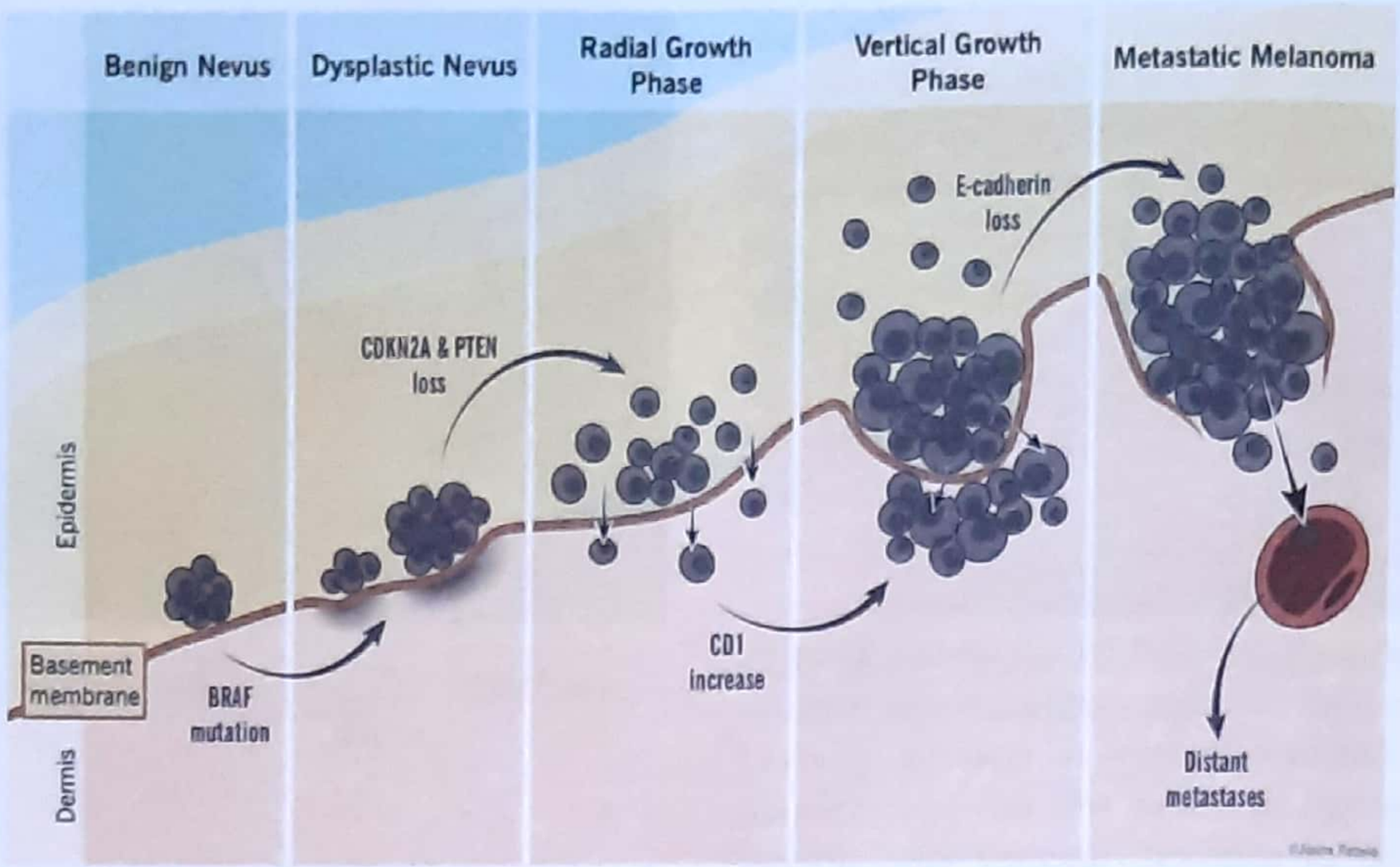

Figure 13.24: Progression of benign nevus to malignant melanoma

1. Superficial Spreading

Superficial spreading type is the moSt common type *(AL 91, AIIMS 01)*, representing Seventy percent of all melanoma. These lesions occur anywhere on the skin **except the hands and feet**. They measure 1 to 2cm in a diameter. There is a relatively long radial growth phase before vertical growth begins. Nearly half of these cancer develop from preexisting mole. See figure 13.25.

To remember: Superficial Spreading is moSt common type. *(IMP PGME QUESTION)*

2. Nodular

The nodular type accounts for 15 to 20% of melanomas and are ***most malignant of all variety*** *(PGL 99, AI-03)*. These lesions are darker and raised, and carries poor prognosis due to greater depth invasion. See figure 13.26.

3. Lentigo Maligna

Lentigo maligna account 5 to 10% of all melanomas. It occurs **mostly on the *face (most common site)*** *(NEET)*, ***neck and the back of the hands of elderly people*** *(AIIMS 2001)*. They tend to become quite large before a diagnosis is

Figure 13.25: Superficial Spreading

Figure 13.26: Nodular

Figure 13.27: Lentigo Maligna

Figure 13.28: Acral Lentiginous

made, but has the best prognosis because invasive growth occurs late. *This is Least* ***Malig****nant variety and has best prognosis*. (MANY PGME) See figure 13.27.

Just to remember: ***Le***ntigo ***Mal***igma is ***Le***ast ***Mal***ignant & hence has the best prognosis. (MANY PGME)

4. Acral Lentiginous

It is rare type of malignant melanoma. It occurs on the **sole (most common site)** (NEET), palm and under nail bed *(subungual)*. Acral lentiginous type accounts for a higher percentage in dark skinned people than in people with less pigmented skin. The nail bed lesions appear as blue black discolourations of the posterior nail fold and are most common on the great toe or thumb. *This type of malignant melanoma has* ***worst prognosis.*** (NEET, PGI, AL 88, MANY PGME). See figure 13.28.

Miscellaneous Types

(i) Amelanotic melanoma

This is malignant melanoma with *no visible pigmentation and carries a poor prognosis,* either due to delay in diagnosis or aggressive behavior, or both.

(ii) Secondary melanoma

This accounts for about 4% of metastatic melanoma. It may represent with out unidentified primary lesion. Satellite secondaries are quite common in the skin around the primary melanoma.

(iii) Desmoplastic melanoma

This frequently arises in a recurrent melanoma or lentigo maligna melanoma. It is usually not pigmented and may grow to a large size. The prognosis is poor.

(iv) Malignant blue nevus

It show no involvement of the functional layer of the epidermis and may arise in a preexisting benign blue nevus. Long term survival has been reported, despite metastatic spread.

Malignant melanoma metastasized to GIT, lung, liver and lees to kidney.

Prognostic Factor

The original staging system classified melanoma into local (stage I), regional lymph node (stage II), and metastatic into local (stage III) disease. Therefore limiting its usefulness in prognostic studies. The most current staging system is from the American Joint Committee on Cancer (AJCC).

Clark's Level

Clark used the histologic level (figure 13.29)

(I) Superficial to basement membrane [in situ]

(II) Papillary dermis invasion

(III) Papillary/reticular dermal junction invasion

(IV) Reticular dermis invasion

(V) Subcutaneous fat or tissue invasion

Please see figure 13.29

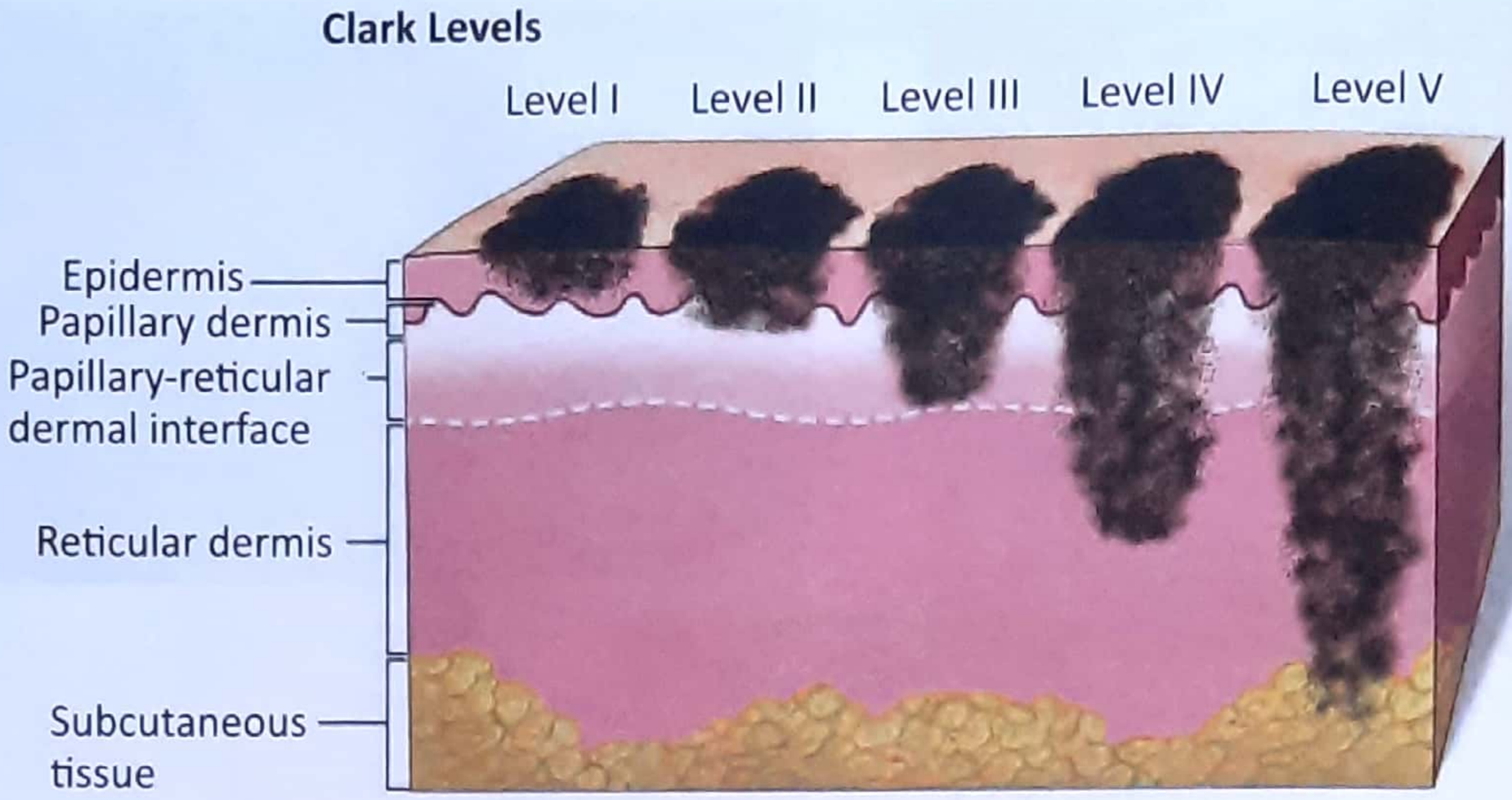

Figure 13.29: Progression of benign nevus to malignant melanoma

Breslow modified the approach. The lesions were measure from the granular layer of the epidermis or the base of the ulcer to the greatest depth of the tumour.

I. 0.75 mm or less

II. 0.76 to 1.5 mm

III. 1.51 to 3.0 mm

IV. 3.0 mm or more

These level of invasion have been subsequently modified and incorporated in the AJCC staging system, (see in key box 13.3 & 13.4 on next page)

Visual examination is used for screening. *(NEET)*

Prognosis *(MANY PGME)*

- Evidence of tumour in regional lymph nodes is a poor prognostic sign.
- The presence of *distant metastasis is a grave prognostic sign,* *(MANY PGME)*
- Independent of histologic type and depth of a invasion, people with *lesions of the extremities have better prognosis than people with melanomas of the trunk or face* *(MANY PGME)*.
- Presence of ulceration in a lesion carries a worse prognosis, *(IMP. POINT)*
- *Women have melanomas in more favorable anatomic sites, these lesions are less likely to contain ulceration. Females have a higher survival rate than male* *(PGME-MANY TIMES, AL 92, UP 94)*.

KEY BOX 13.3	
Staging and Clinical Prognosis of Malignant Melanoma	
Clark's level	**5 year survival**
I. Epidermis only	98%
II. Invades papillary dermis	96%
III. Fills papillary dermis	94%
IV. Invades reticular dermis	78%
V. Subcutaneous tissue invasion	44%
Breslow thickness	**10 year survival**
I. <0.76 mm	92%
II. <0.76 mm-1.5 mm	76%
III. >1.51-3.0 mm	50%
IV. > 3mm	30%
Lymph node involvement	**8 year survival < 40%**

- Nodular melanomas have the same prognosis as superficial spreading type, when lesions are matched for depth of invasion. Lentigo maligna type however, have a better prognosis and acral lentiginous lesions have a worse prognosis. *(VERY IMP. POINT)*
- Lesions that are suspicious of melanoma can be identified by their clinical characteristic after referred to as ABCDE.

(A) Asymmetry - Asymmetric shape or contour

(B) Border - Irregular border

(C) Color - Color variation

(D) Diameter - >6mm

(E) Evaluation or Elevation - Elevation of lesions

Treatment

- The treatment of melanoma is primarily surgical.
- Radiation therapy, regional and systemic chemotherapy and immunotherapy are effective in a limited set of circumstances, but none is a first line treatment option.
- *All suspicious lesions should undergo* ***excisional biopsy*** *(NEET) with 1 cm margin of normal skin (AIIMS 06, MANY PGME, UPSC 07).* Once the diagnosis of melanoma is made; the biopsy scar and any remains of the lesion need to be removed to eradicate any remaining tumour.
- **For in situ lesions** a **0.5 to 1cm margin of** *(NEET)* normal skin is adequate for cure.
- *A T_1 melanoma (less than 0.76 mm deep) requires a 1cm margin to prevent local recurrence. (NEET)*
- For thicker lesions a 2-3 cm margin is recommended. The surrounding tissue should be removed down to the fascia to remove all lymphatic channels.
- All clinically positive nodes should be removed by regional nodal dissection. In patients with thin lesion (less than 0.75 mm) the tumour cells are still localized in the surrounding tissue, the cure rate is excellent with wide excision of the primary lesion, for these patients treatment of regional lymph nodes is not necessary.
- With very thick lesions (more than 4 mm), it is highly likely that the tumour cells have already spread to the regional lymph nodes and distant sites, hence removal of the lymph nodes has no effect on survival.

KEY BOX 13.4

AJCC (American Joint Committee on cancer) staging system

Primary	Breslow	Clark's level
Tis	Melanoma in situ	I
T_1	Melanoma < 0.75 mm	II
T_2	Melanoma 0,76-1.5 mm	III
T_3	Melanoma 1.51 mm-4.0 mm	IV
T_4	Melanoma more than 4.0 mm	V

NODE:

N_0 - No nodes involvement

N_1 - Nodes involved but of less than 3 cm in diameter

N_2 - Any node of mote than 3 cm

- In patients with intermediate thickness tumours (T2 and Ts, 0.76 to 4.0 mm) and no clinical evidence of nodal or metastasis disease, the use of prophylactic dissection on clinically negative nodes is controversial.
- One surgical modality gaining acceptance is the use of intraoperative methods to* locate the pattern of lymphatic drainage from the primary lesion. Vital blue dye or a radioisotope is injected at the site of the melanoma. This permits identification of the **first (sentinel) lymph node** draining the tumour. The node is removed, and if micrometastases are identified in frozen section examination, a complete lymph node dissection is performed. (Figure 13.30)
- When patients develop distant metastases; surgical treatment may be indicated. Solitary lesions in the brain, gut, or skin; that are symptomatic should be excised when possible.
- The most promising newer modality of melanoma treatment is in the use of immunologic manipulation. The use of intravenous interferon alpha 2b (TNF alpha-2b) in patients with lesions of 4mm or more (T4) or nodal metastasis (N_1) has given good results.
- Vaccines have been developed with the hope of stimulating the body's own immune system against the tumour. These antibodies have been used alone or linked to a radioisotope or cytotoxic agent in an effort to selectively kill tumour cells.

- Chemotherapeutic agent (e.g; **melphalan**) is the treatment of choice for patients with local recurrence or in transit lesions (local disease in lymphatics) on extremity and that not amenable to excision.
- Radioresistant.
- Most patients with melanoma will not be surgical candidates. Although medical options for melanoma have historically been poor, several recent studies have shown promise in drug therapy for metastatic melanoma. BRAF inhibitors (sorafenib), anti-PD1 antibodies, CTLA antibodies (ipilimumab), and highdose interleukin-2 (IL-2) with and without vaccines have been shown in randomized studies to provide survival benefit in metastatic disease. Despite the excitement of recent drugs, surgery will likely play an adjunct role in treating individuals who develop resistance to these drugs over time.
- Tumors <1 mm thick require 0.5 to 1 cm margins. Tumors 1 to 2 mm thick require 1 to 2 cm margins, and tumors >2 mm thick require 2-cm margins.

****

OTHER SKIN MALIGNANCIES

Most of you can omit this topic, This is only for them; who are interested more on this Topic

Markel Cell Carcinoma (Primary Neuro-endocrine Carcinoma of the skin)

A variant of Squamous cell carcinoma, has only recently been demonstrated by immunohistochemical markers. These tumours are very aggressive, and wide local resection with 3-cm margins is recommended. Prophylactic regional lymph node dissection and adjuvant radiation therapy are recommended as well. Overall, the prognosis is worse than for malignant melanoma. (Figure 13.31)

Extra Mammary Paget's Disease

Paget's disease is thought to be a cutaneous extension of an underlying adenocarcinoma, through an associated tumour cannot always be demonstrated. (Figure 13.32)

Angiosarcoma

Angiosarcomas may arise spontaneously, mostly on the scalp, face, and neck. Tumors also may arise in areas of prior radiation therapy, or in the setting of chronic

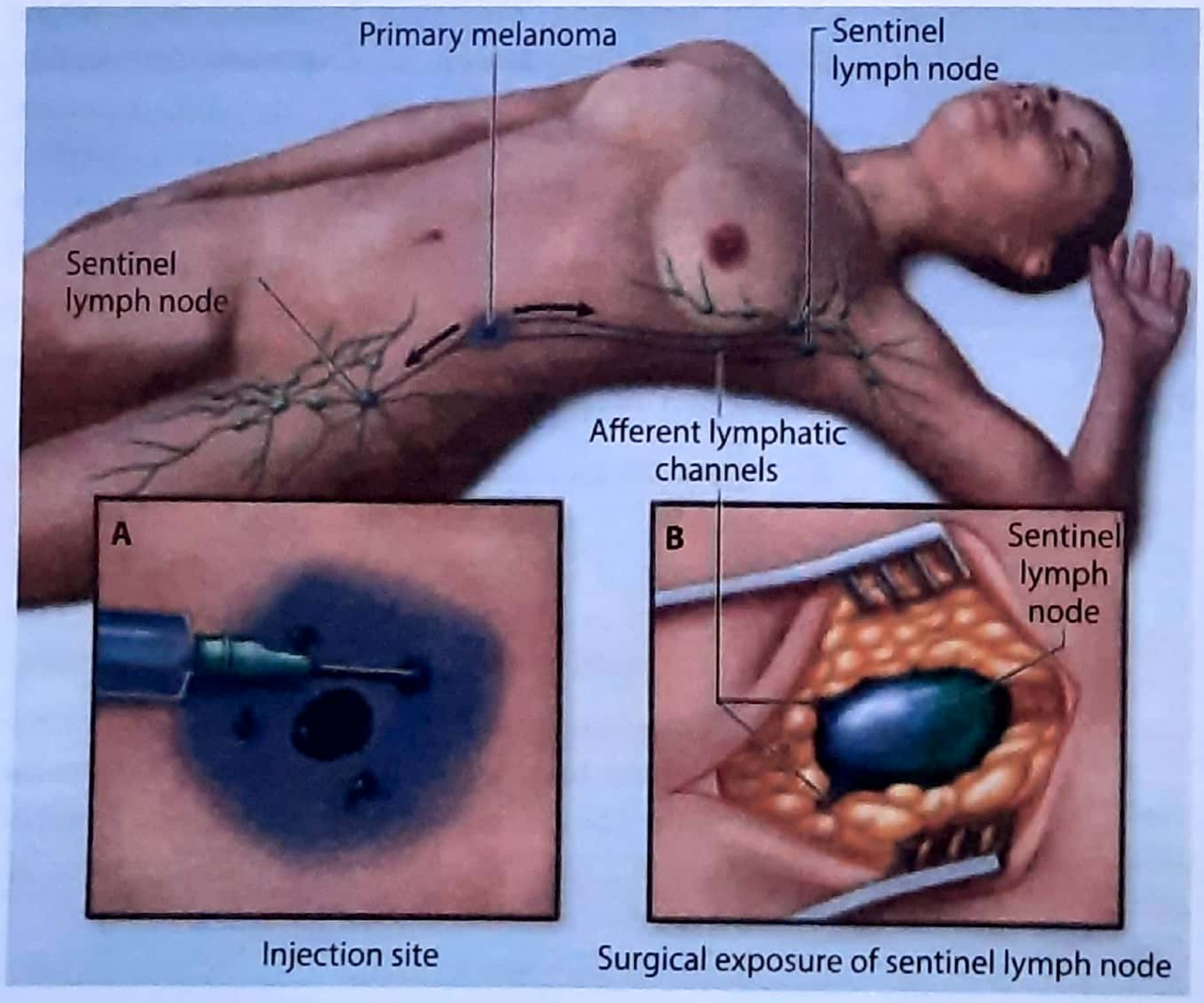

Figure 13.30: Technique of sentinel lymph node biopsy for cutaneous melanoma. (**A**) After injection of radioactive technetium-99-labeled sulfur colloid tracer at a lower abdominal wall primary cutaneous melanoma site, (**B**) Sentinel lymph node basins are identified

Figure 13.31: Merkel cell carcinoma seen just above the left knee in a 44-yea-old female

lymphedema of the arm, such as after mastectomy (**Stewart Treves syndrome**). Prognosis usually is poor, with 5-year survival rate is under 20%.

Kaposi's Sarcoma

- Kaposi's sarcoma (KS) appears as rubbery bluish nodules that occur primarily on the extremities but may appear anywhere on the skin and viscera. (Figure 13.33)

Figure 13.32: Extra Mammary Paget's Disease

Figure 13.33: Kaposi's Sarcoma

- Histologically the lesions are composed of capillaries lined by atypical endothelial cells. Early lesions may resemble hemangiomas. Classic KS is seen in people of Eastern or sub-Saharan Africa. Visceral spread of the lesions is rare, a subtype of the African variety has a predilection for spreading to lymph nodes.
- AIDS related KS occurs primarily in male homosexuals and not in intravenous drug abusers or hemophilics *(AI 91)*.
- In this form of the disease, the lesions spread rapidly to the nodes, the gastrointestinal and respiratory tract often are involved associated with concurrent infection with a herpes like virus.
- *Treatment* for all types of KS consists of radiation of the lesions. Combination chemotherapy is effective in controlling to the disease. Surgical treatment is reserved for lesion that interface with vital functions, such as bowel obstruction or airway compromise.

Fibrosarcoma

Fibrosarcoma are hard, irregular masses found in the subcutaneous fat. If they are not excised completely, metastases usually develop.

Liposarcoma

It arise in the deep muscle planes, and rarely from the subcutaneous tissue. They occur **most commonly** on the thigh **most common retroperitoneal tumor**. *(INICET NOV. 20)* An enlarging lipoma with pain should be excised and inspected to distinguish it from liposaroma.

Wide excision is the treatment of choice, with radiation therapy reserved for metastatic disease.

Cutaneous Malignant Lymphoma

The skin may be infiltrated by leukemic cells and by malignant lymphocytes in Non Hodgkin's lymphoma. Skin infiltration may even precede the onset of systemic disease. Involvement of the skin by Hodgkin's disease usually occurs late in the course of the illness and presents as a plaque, nodule or an ulcer. Microscopically there is a heavy lymphoid infiltrate and occasional Reed Sternberg cells are seen.

Non-Hodgkin's lymphomas can be either of B cell or more commonly of T cell type. 5% of B cell lymphomas arise in the skin. Clinically, they present as a smooth nodule or plaque of variable colour which slowly enlarges. T cell lymphomas encompass adult T cell lymphoma. mycosis fungoids and Sezary syndrome and often have cutaneous involvement.

Mycosis fungoides

It is a T-cell lymphoma which presents in the skin. It has been suggested that the incidence may be higher in industrial areas and in individuals exposed to certain industrial chemicals. It occurs in late middle age and in the elderly and presents as an area of localized eczema or as a plaque within the skin.

Sezary's syndrome

It presents with generalized exfoliative erythroderma, lymphadenopathy and involvement of the peripheral blood. Sezary cells are present in peripheral blood. The diagnosis can be difficult in the early stages as the histological features are rather non specific. The prognosis of all cutaneous lymphomas and leukemias is dependent on the grade and stage of disease. Ultimately, they spread to the lymph nodes when the outlook is poor. Surgical biopsy is required to make a diagnosis. Treatment is by radiation and cytotoxic chemotherapy.

Cutaneous Metastases

Cutaneous metastases almost occur at a last stage, and thus carry a poor prognosis. They occasionally arise from a silent internal malignancy. The deposit may be single or multiple and is often umbilicated. The most common primary sites are the bronchus or esophagus in men and the breast or ovaries in women. Metastases may occur in all areas or the skin, but the chest wall is the most common site, especially when the primary is a carcinoma of the breast.

KEY BOX 13.5

COMMON Terminologies USED IN TEXT

1. **Macule:** Circumscribed area of any size distinguished from surrounding skin by its colouration.
2. **Papule:** Elevated, solid area of 5mm or less.
3. **Nodule:** Elevated, solid area more than 5mm.
4. **Plaque:** Elevated, solid flat area more than 5mm.
5. **Vesicle:** Fluid-Filled, raised, cystic area Smut or less
6. **Bulla:** Fluid-Filled, raised, cystic area more than 5 mm.
7. **Blister:** Common term for vesicle and balk.
8. **Pustule:** Pus filled, cystic raised area.
9. **Excoriation:** A lesion characterized by breakage of epidermis.

Glomus tumour *(AIIMS 08)*

Glomus tumour is a rare, benign and exquisitely painful small tumour of the skin and subcutaneous tissue. This usually occurs on extremities **particularly in the nail beds of hand and feet**. *(NEET)* The GLOMUS is a specialized arteriovenous anastomosis surrounded by large pale glomus cells. Such glomus is most abundantly present in the nail bed at the tips of finger and toes and the palmar surface of phalanges. The function of the glomus is supposed to be concerned with heat regulation. The

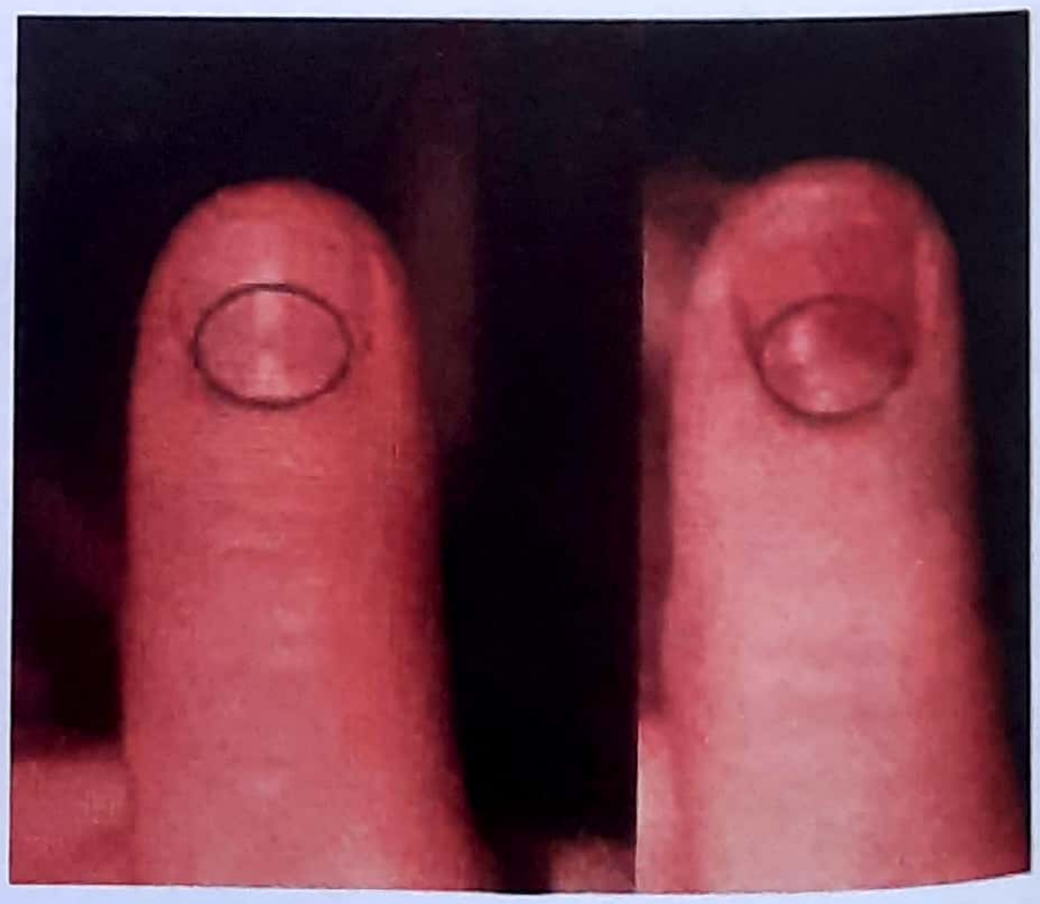

Figure 13.34: Glomus tumour

glomus tumour or the **glomangioma** is a benign and circumscribed tumour blue or reddish in colour. It is usually small and seldom exceeds 1cm in size. The tumor arises from modified smooth muscle cells. (Figure 13.34)

Pathology

The tumour consists of tortuous vascular channels in the wall of which there are large pale cells of the epitheloid type with clear or vacuolated cytoplasm. The cells may be clumped in large masses without any definite lumen. Plain muscle fibers intervene between the lumen and the clamp of epithelioid cells. Abundant nerve fibers mainly of non: myelinated variety are seen between the epithelioid cells and are responsible for exquisite pain, which is the most important symptom of this tumour.

Treatment

Since the tumour is radioresistant, the treatment of choice is excision of the tumour.

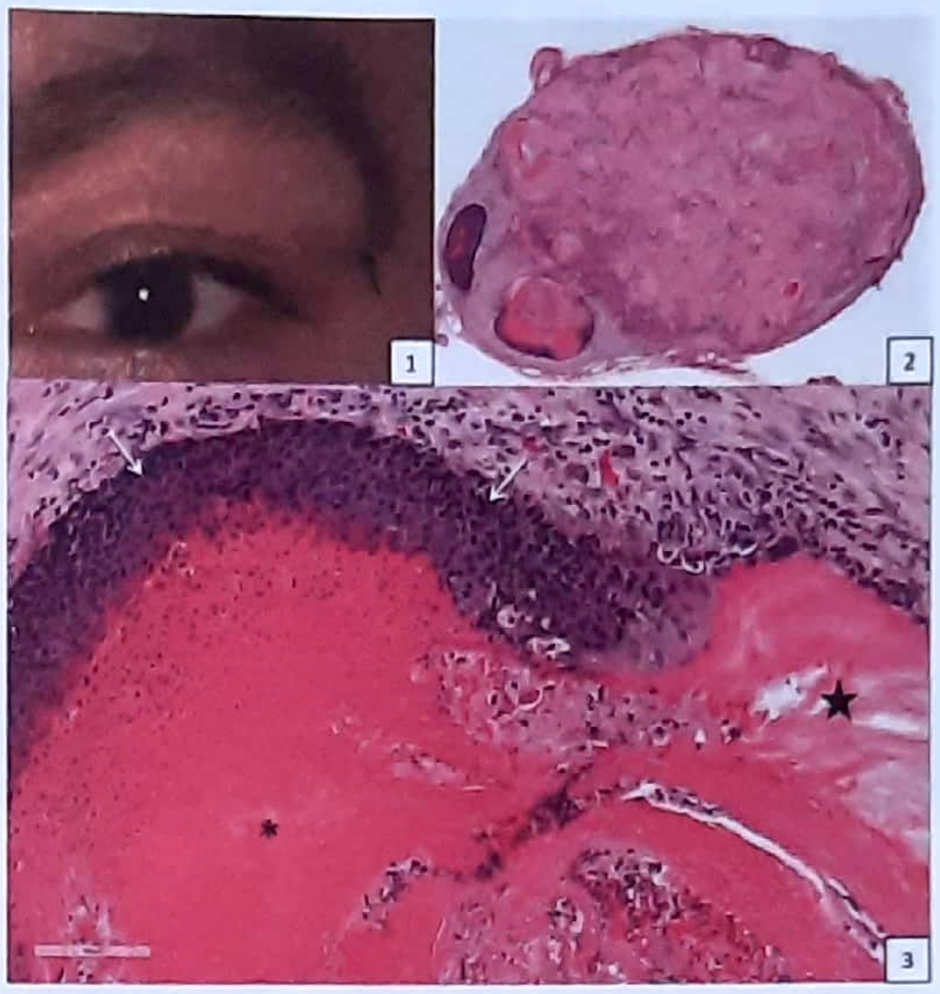

Figure 13.35: Pilomatrixoma

Pilomatrixoma

Pilomatrixoma *(calcified epithelioma of Malherbe)* is a benign hair follicle derived tumour. These are solitary, hard tumours that appear to grow from the deep surface of the skin. They occur only on the face, neck and arm. The size usually varies between 0.5-3cm in diameter. Clinically, it resembles a rather hard epidermoid cyst. (Figure 13.35)

Cylindroma

Cylindroma is a **malignant tumour** *(MANY PGME)* and is called so, because of arrangement of the stroma in a peculiar transparent cylinders, which are thought to be of apocrine in origin. The tumour gradually forms an extensive, turban like swelling extending over scalp. Cryotherapy may control progression of this condition.

Cylindroma is a **malignant tumour** *(UP PGMEE)*

NOTE: Oma suffix is usually used for benign tumour; but cylindroma is a malignant tumour.

****

Sample Questions for Prof Examination

Write short notes on the following:

1. Lipoma
2. Sebaceous cyst and cock's peculiar tumour.
3. Cavernous Hemangioma
4. Rodent ulcer
5. Malignant Melanoma
6. Basal cell carcinoma.
7. Marjolins ulcer
8. Hemangioma
9. Rodent ulcer
10. Discuss the premalignant lesions of the skin.

14 Scalp, Skull, Brain and Spinal Cord

Contents

- The scalp
- The skull
  - Fracture
  - Brain injury
- Neural tube defects
- Tumour of Brain

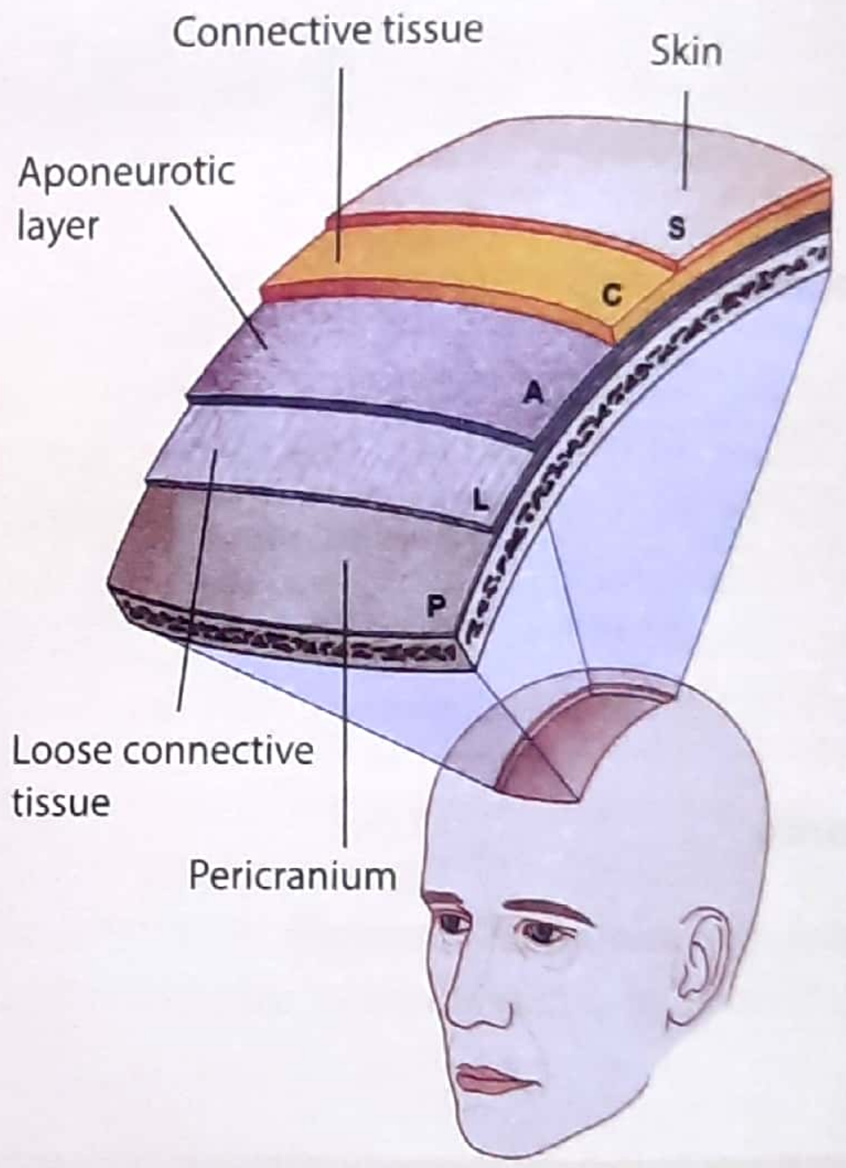

Figure 14.1: Layers of scalp

THE SCALP

The scalp covers the skull bones and consists of five layers. See figure 14.1.

S - **S**kin

C - Connective tissue

A - **A**poneurosis (galea aponeurotic)

L - Loose connective tissue

P - **P**ericranium

The arterial supply of scalp runs in the layers of connective tissue between the galea and skin (PGME). The scalp is very vascular and patient can lose large amount of blood after a laceration. Scalp may be injured in following manners:-

Scalp laceration

Laceration is a wound in which the skin or underlying tissues are torn as a result of application of blunt force:

- May be single or multiple.
- May or may not involved skull.

Scalp Incision

An incised wound is an injury caused by a weapon with a sharp cutting edge, when it is drawn across the skin.

Scalp Contusion

It signifies hemorrhage into the skin, the subcutaneous tissue or deeper tissues. It is due to an infiltration or extravasation of blood into the tissues, following rupture of small vessels, as result of application of blunt force.

Management

- Antibiotics.
- Scalp should be shaved and cleaned.
- Palpate for skull injury and if manage accordingly.
- Edges should be debrided & closed in layers,
- Symptomatic treatment should begun.

****

THE SKULL

The skull, anatomically has a vault and abase which consist of the anterior, middle and posterior fossa. Fractures may involve the skull, and it can be linear and depressed; either may be simple or compound. They increase the likely hood of an adjacent extradural hematoma. Fracture through air sinuses may lead to meningitis or pneumocephalus (intracranial air). Skull fracture is not due to traction (NEET).

Simple Linear Fracture

This accounts for **80% of all skull fractures**. The risk of associated extradural & subdural hematoma should always be kept in mind. If simple, a linear skull fracture does not require treatment.

Depressed Skull Fracture

Depressed skull fracture results due to blunt trauma to skull. Dura and brain may also get lacerated. Compound depressed fractures require a CT Scan and need to be fully explored by a neurosurgeon. Simple depressed fracture requires elevation, if the depression is more than 3-4 mm is adult, or if depression is close or over a venous sinus. (AL 96)

Basal Fracture

It is the fracture of the base of skull, and may cause escape of cranial contents (CSF, blood or even brain matter) and cranial nerve (except XII).

1. Fracture of Anterior cranial fossa

- Facture of anterior cranial fossa results in epistaxis, if cribriform plate is involved.
- Periorbital ecchymosis may be present.
- ***Raccoon's eye :*** Fractures of anterior (and sometimes middle) cranial fossa are associated with orbital hematoma, blood tracks forward into orbital tissue into the eyelid and behind the conjunctiva. *This may be diagnostic of fracture of the floor of the anterior cranial fossa* (UPSC 87)
- ***CSF rhinorrhoea*** : Patient may have persistent leakage of CSF from nose. This usually stops in 7-10 days and does not need operative intervention (AL 96) . Diagnosed by B2 transferrin.
- ***Pneumocephalus:*** May develop due to air entering the cranial cavity due to fracture of air sinuses.
- ***Cranial nerve injury:*** *The most common nerve injured is olfactory nerve* (PGME). Other nerves injured are III, IV, and V and rarely VI.

2. Fracture of middle cranial fossa

Clinical features may be in the form of:

- Epistaxis
- CSF otorrhea (Leakage of CSF from ear)
- Cranial nerve injury: VI, VII, (AIIMS 84) and VIII nerve.

3. Fracture of the posterior cranial fossa

Battle's sign (NEET) : Posterior cranial fossa fracture may produce a boggy swelling in the region of nape of neck or discolouration **posterior to mastoid process**. The nerve which are likely to be damaged are IX, X and XI (PGME)

****

BRAIN INJURY

Brain injury may be primary or secondary. Primary damage occurs immediately after trauma, where as secondary damage develops later .as a result of complication. Primary brain damage is irreversible. Please *see key box* 14.1.

NOTE: Primary brain damage occurs immediately after injury, While secondary brain damage occurs later, after many hours as a result of complication.

KEY BOX 14.1

Brain injury

A. Primary brain injury	B. Secondary brain injury
1. Concussion	1. Intra Cranial hematoma
2. Cortical contusion/ laceration	(i) Extradural
3. Diffused axonal injury	(ii) Subdural
4. Primary brain stem Injury	(iii) Sub arachnoid
	2. Traumatic cerebral edema
	3. Hypoxemia
	4. Ischemia
	5. Infection
	6. Epilepsy
	7. Metabolic/endocrine changes

Electrolyte abnormality seen after brain injury - Hyponatremia (M/C), Hypernatremia, hyperkalemia, hypomagnesemia, hypophosphatemia.

A. PRIMARY BRAIN INJURY

It is anatomical and physiological ***disruption at the time of impact and is irreversible.*** It is divided as:

1. Concussion

Concussion refers to an immediate but transient loss of consciousness, that is associated with short period of amnesia after a blunt impact.

Clinical Feature

- Autonomic signs like facial pallor, bradycardia, faintness with mild hypotension and sluggish pupillary reaction are present.
- There is no changes in CT scan.
- There occurs; only transient loss of consciousness followed by complete recovery with in 24 hours. So there occurs disruption of function without significant brain damage.

2. Contusions

It is usually a *bruise on the surface of brain* due to extravasation of blood but without rupture of pia arachnoid.

Type of contusion

(on the basis of mechanism of injury)

(i) Coup

(ii) Contrecoup

(iii) Intermediate coup

(iv) Gliding

(v) Herniation

(vi) Fracture **contusion**

A direct blow to head may cause damage to the brain at the site of blow (coup injury) or to the site opposite to the blow, when the brain moves within the skull and hits the opposite wall (contrecoup injury)

Clinical Picture

Depends upon the basis of its size, **location** and extent of swelling, hemorrhages. It may result in rapidly deteriorating clinical course.

(a) Frontal lobe contusion

1. Monoplegia or hemiplegia, depending up on the extent of damages.
2. Broca's dysphasia
3. Contra lateral head and eye turning
4. Change in personality and antisocial behaviour
5. Incontinence of urine and feces (due to loss of cortical inhibition)

(b) Parietal lobe contusion

1. Postural sensation disturbances
2. Sensation of passive movement
3. Accurate localization to light touch is impaired
4. Two point discrimination lost
5. Astereognosis
6. Sensory inattention
7. Wernicke's dysphasia
8. Anosgonia, dressing apraxia, geographical agnosia
9. Finger agnosia, acalculia, agraphia
10. Lower homonymous quadratonopia (due to optic radiations involvement)

(c) Temporal lobe contusion

1. Cortical deafness
2. Auditory hallucinations

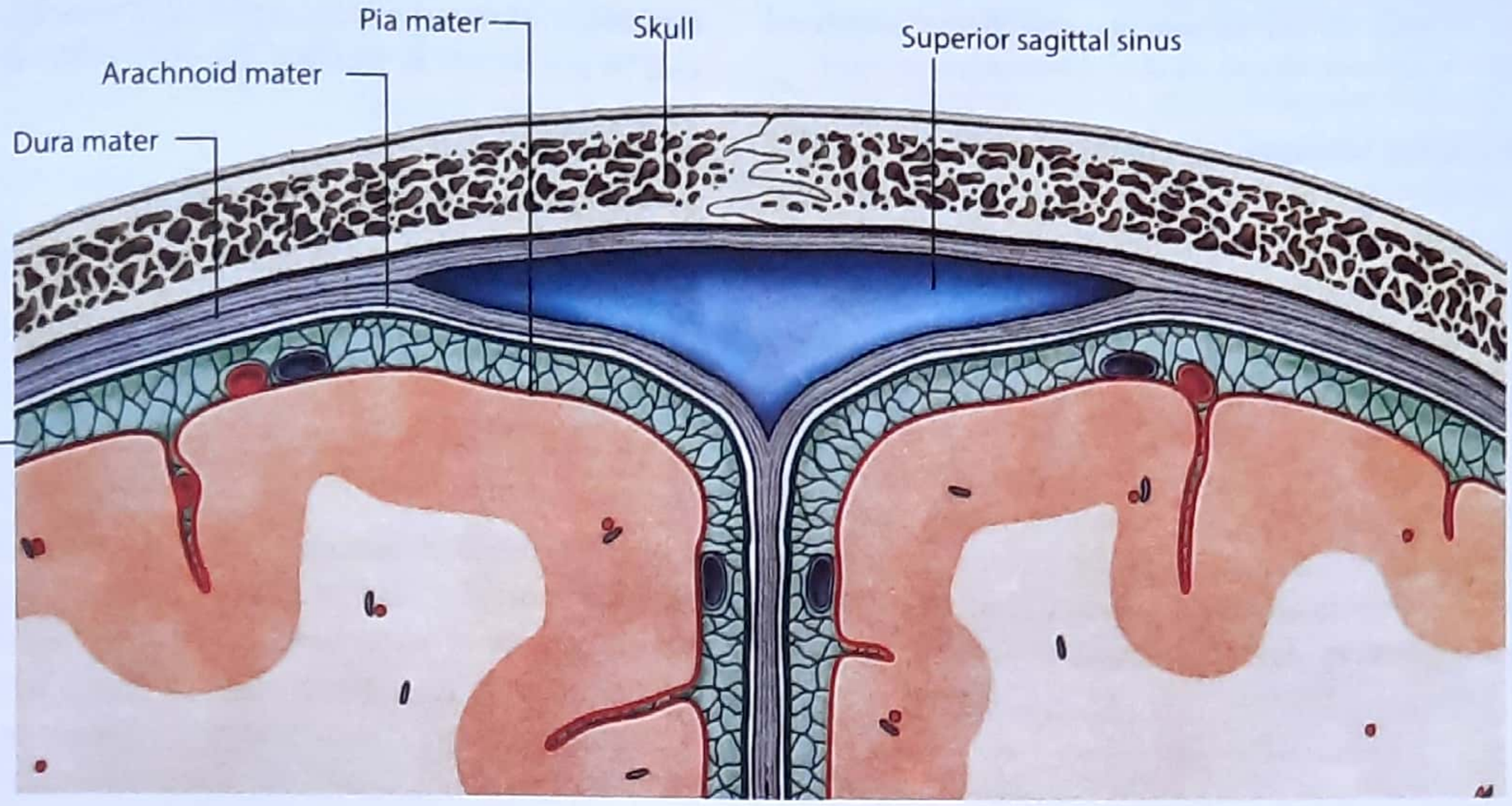

Figure 14.2: Cranial Meninges

3. Olfactory hallucination with complex partial seizure
4. Disturbance of memory & learning
5. Aggressive or antisocial behaviour
6. Inability to establish new memory
7. Wernicke's dysphasia
8. Upper homonymous quadratonopia

(d) Occipital lobe injury

1. Cortical blindness
2. Visual hallucination
3. Visual illusion
4. Prospagnosia

(e) Cerebellar injury

1. Ataxia
2. Dysdiadochokinesia
3. Intension tremor
4. Pendular reflexes
5. Nystagmus
6. Involuntary movement
7. Dysarthria

(f) Hypothalamic injury

Hyperpnea, excessive pulmonary secretion and irreversible shock, persistent hypothermia, diabetes insipidus.

3. Diffuse Axonal injury

There is diffuse and severe degeneration of white matter of brain due to acceleration and deceleration injury of axons, which may be completely disrupted and then retract, forming **axon balls.** Patient may become unconscious from time of injury and responds only to painful stimuli with generalized extensor spasm called decerebrate or brain stem attacks. Focal signs are rare.

4. Primary Brain stem injury

This type of injury occurs at the time of accident. It may be due to acute flexion or torsion or direct effect upon cells and nerve or due to vascular changes.

Clinical Feature

1. Impairment of consciousness
2. Brain stem seizures with hypotonicity, with pronated upper and extended lower extremities (***Decerebrate rigidity***) (PGME)
3. Postural hyper or hypotonicity
4. Nystagmus consisting of, to & fro movement of approximately equal range & slow velocity.
5. Pupils may be dilated & fixed or both may be constricted & very sluggish reacting or may be inequality.

RECAP: Friends; Till now we were discussing Primary (Immediate) brain injury. Now we will discuss Secondary brain injury

Pons-Duret hemorrhage *(NEET)* : Small linear area of bleeding in the mid brain and upper pons of brain stem. They are caused by a traumatic displacement & downward shift of brain stem.

B. SECONDARY BRAIN INJURY

After the primary injury; secondary processes (both systemic and local) takes place, that further damage the brain, and this is called as secondary brain damage. **Unlike the primary damages which is beyond surgeon's control, the secondary damage can be anticipated, and can be prevented & treated.** These are: (please see box 14.1 and revise it again)

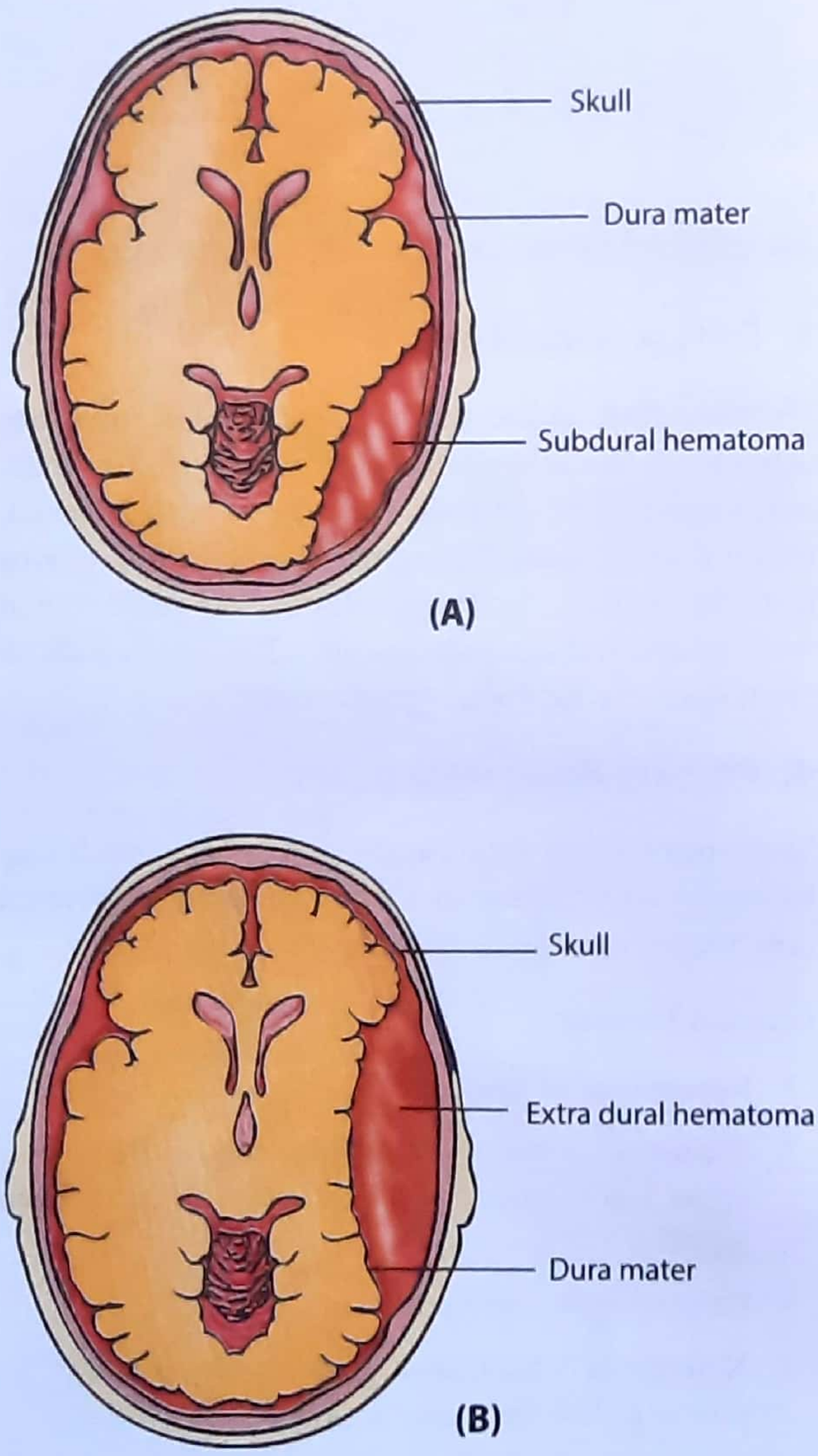

Figure 14-3: Subdural & Extradural hematoma

1. Intracranial Hematomas

It can be at various sites: epidural (extradural), subdural, sub arachnoid or intracerebral. See figure 14.2 and 14.3. We will now discuss them one by one.

(i) Extradural (epidural) Hematoma

Extradural hemorrhage constitute a major source of preventable mortality and occurs in about 1-2% hospital admitted cases of acute head injury. *In extradural hemorrhage there is an accumulation of blood between the skull and the dura.* The maximum incidence in usually between the ages of 11 and 60. The mortality rate varies from 10-40%. (Figure 14.3 (B) and 14.4).

Pathogenesis

To become clinically significant an extradural hematoma should at least be 25 grams in weight or about 25 ml in volume. The space between the dura mater and the inner table of the skull in a potential space. Hence stripping of the dura off the inner table is essential, before the torn branches of the meningeal vessels can bleed in extradural space.

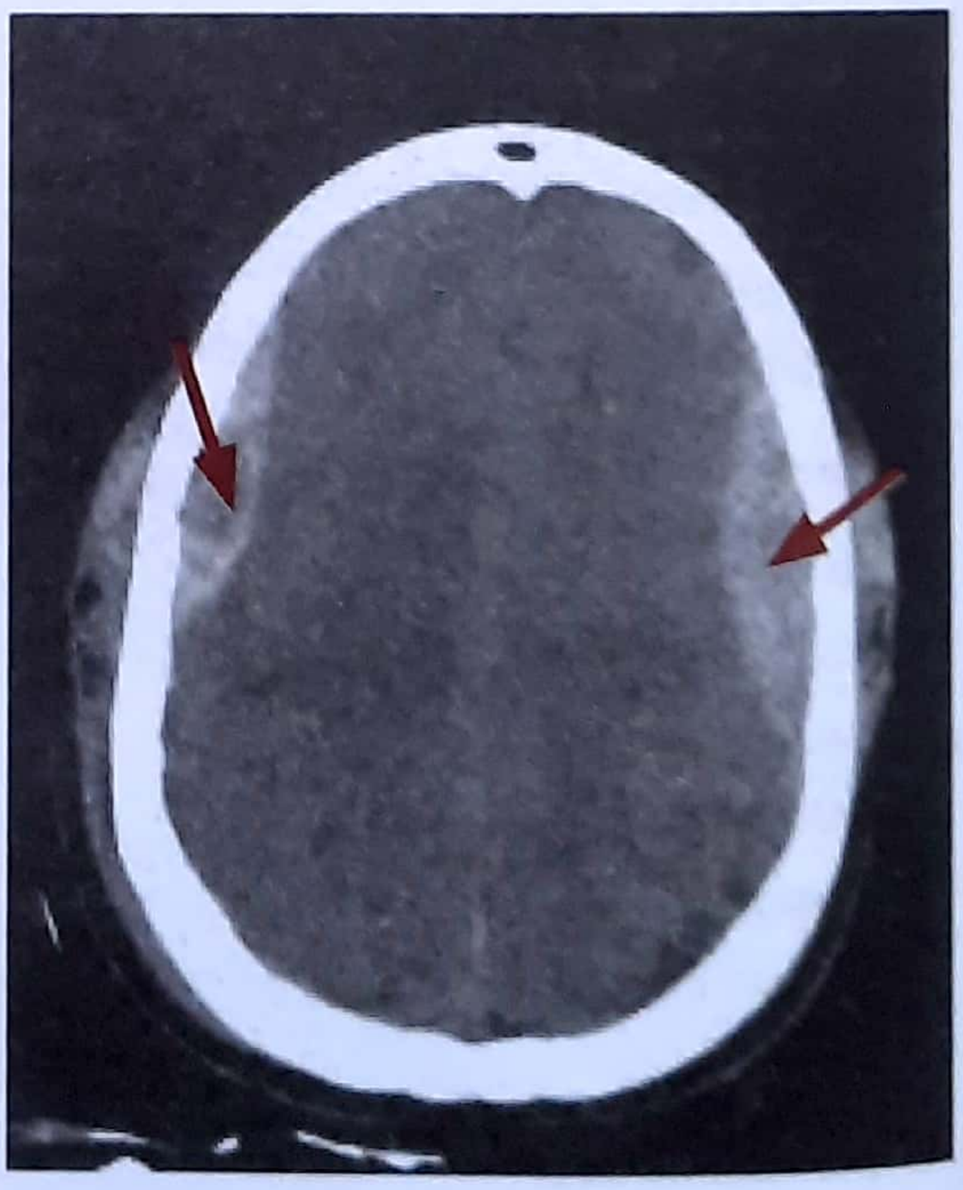

Figure 14.4 : Extradural hematoma

The firm adherence of the dura to the inner table in childhood explains the infrequency of extradural hemorrhage in children below three years of age.

Source of extradural Hematoma

Through *the middle meningeal artery* (MANY PGME) and its branches are the commonest source (90%) of bleeding in extradural hemorrhage. The hemorrhage is not always arterial, but may be venous from the middle meningeal veins (10%) and other venous sinuses. *An extradural hemorrhage of dangerous size occurs only in one location, i.e., the temporal fossa.* (PGME).

Clinical Features

(UPSC 86. KER 87 JIPMER 88)

- *Brief loss of consciousness followed by a* ***lucid interval*** (NEET, MANY PGME) and progressive obtundation.
- Ipsilateral pupillary dilatation.
- Contralateral hemiparesis (seen in 60 percent).
- OTHER FEATURES include headache, nausea, vomiting, seizures, unilateral hyperreflexia and positive Babinski's sign, <u>besides falling pulse and rising BP.</u> (AIMS 84, 82) (Bradycardia and hypertension). This is due to ***cushing's reflex. (raised ICT leads to bradycardia and hypertension)*** (UP 07) earliest sign following head injury is altered mental status.

Diagnosis

The frequent and widespread use of the CT scan in head injuries has made the diagnosis of all type of extradural hematomas easier. In spite of this,, acute clinical awareness of the protean manifestations of extradural hemorrhage is necessary. The history of injury is usually obvious, but quite often many be minor, thus arises the need to instruct the patients and their relatives to watch for the development of symptoms like headache, restlessness or drowsiness even if the head injury has been minor and the initial CT normal.

Contralateral hemiparesis is an important sign of extradural hematoma. Ipsilateral hemiparesis may also result, which is due to pressure on the opposite cerebral peduncle by the tentorial edge **(Kernohan's Phenomenon),** or from compression of the opposite motor cortex against the skull or rarely from bilateral extradural hematoma. Sensory sign and dysphasia may also occurs. Clinical signs are very important in making diagnosis:

1. Pupillary Signs

The first manifestation in some instances may be pupillary constriction due to irritation of the nerve fibres. Later, total oculomotor palsy may occur with ptosis and lateral deviation of the eye.

Pupillary dilatation is more common and occurs earlier in temporal hematomas. In posterior fossa hematomas, pupillary dilatation may not occur. **Bradycardia** is a reliable sign of increasing intracranial pressure due to an uncomplicated extradural hematoma. However, It is seen only in a small number of cases and it may occur in the absence of a hematoma. Lack of localizing sings, increasing rate of respiration, pulse rate and mild neck stiffness are indications to localization of the hematoma to the posterior fossa.

2. Plain X-rays

In most of the cases of extradural hemorrhage a fracture of the skull can be visualized in the plain X-ray.

3. CT scan

Acute epidural hematomas show up in the CT scan, as ***<u>bi-convex</u>*** *and rarely planoconvex zones of increased density adjacent to the inner table of the skull.* (MANY PGME)

Indication of CT

NICE Guidelines for CT Scan in head injury

- Glasgow coma score (GCS) < 13 at any point
- GCS 13 or 14 at 2 hours
- Focal neurological deficit
- Suspected open, depressed or basal skull fracture
- Seizures
- Vomiting > one episode

Urgent CT head scan if none of the above but :

- Age > 65
- Coagulopathy (e.g., on warfarin)
- Dangerous mechanism of injury (CT within 8 hours)
- Antegrade amnesia > 30 min (CT within 8 hours)

NICE = **N**ational **I**nstitute of health & **C**are an **E**xcellence Guidelines for computerized tomography (CT) in head injury

Treatment

Operative Techniques (AL 02, AIIMS 93)

(a) **When CT scan or angiogram is not available** or if there is no time for investigation emergency exploratory *burr holes or *craniotomy have to be made to save the life of the patient.

- If there is a fracture, the burrhole or craniotomy should be done, near the middle of the fracture since this is the most likely site for an extradural hematoma.
- If there is no fracture, a **temporal burrhole** should be made on the side of the dilated pupil.
- In a middle fossa EDH the temporal burrhole is preferably placed lower down than indicated in the classical diagrams, as only a low burrhole can detect a hematoma which may be subtemporal in location.
- If this exploration is negative, frontal and parietal burrholes are made on the same side. If there is no clot seen again at these sites, the same procedure should be repeated on the opposite side.

(b) **When the site of the EDH has been localized by CT scan** the burrhole is made at the appropriate site based upon the CT finding.

- Often the dilated pupil becomes smaller as soon as the clot is evacuated. This is a good prognostic sign. Over all mortality for extradural hematoma is 15%.

Craniotomy?

Craniotomy refers to removal of skull bone flap, where a single plate of bone cut with saw or power tool. This may leave a defect, if large may be repaired later by cranioplasty.

Burrhole?

Surgical creation of a hole in cranial cavity to evacuate hematoma.

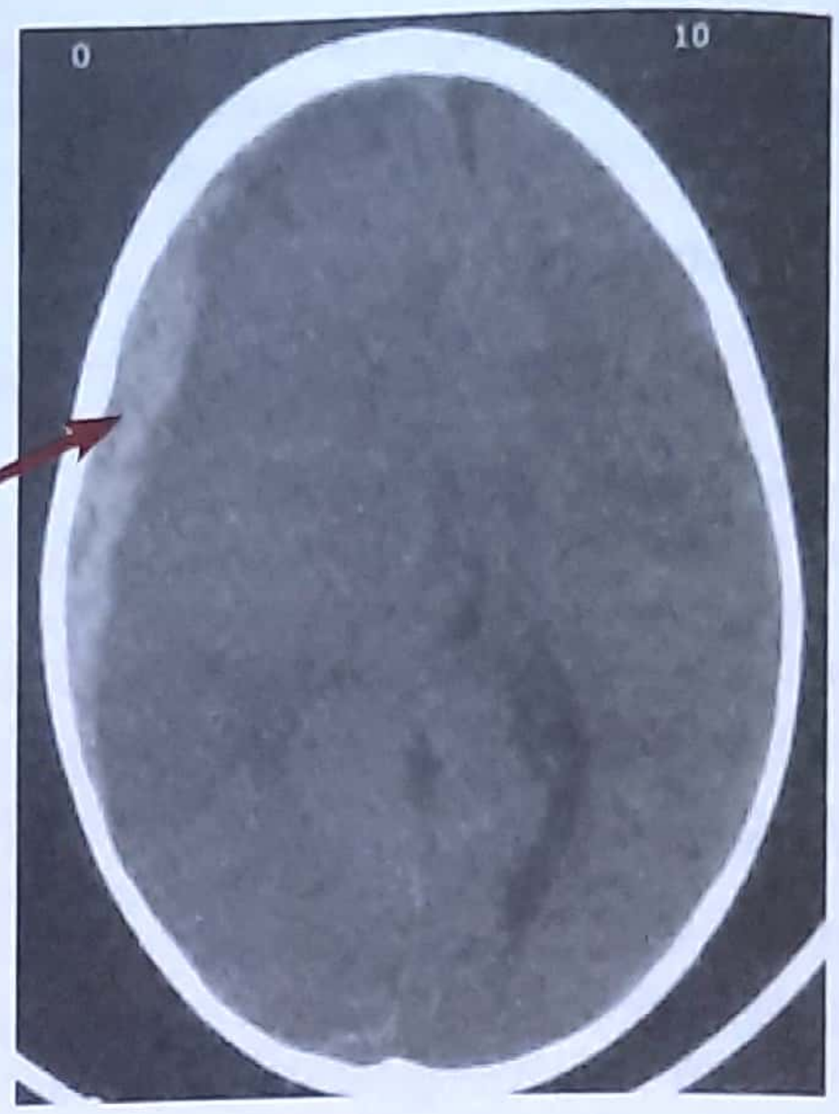

Figure 14.5 : Subdural Hematoma

(ii) Subdural Hematoma

Subdural hematoma is accumulation of blood in the subdural space, separated from the brain by arachnoid and sub arachnoid space. (Please see figure 14.3(B) & 14.5)

Classification

Subdural hemorrhage are classified as acute, subacute and chronic. The term **acute** is usually reserved for those cases that need surgical exploration within three days after the injury. The term **subacute** is used to denote those cases where the clinical picture of compression develops between one to three weeks, following an acute head injury, and **chronic subdural hematoma develops after 3 weeks.** (AL 89, KAR 06)

Etiopathogenesis

The **commonest cause of an acute subdural hematoma is trauma to the head** (NEET), which results in cerebral shifts within the skull. **The source** of bleeding is generally a **bridging cortical vein near the sagittal sinus** (NEET, PGME). Acute subdural hematoma caused by a bleeding traumatic aneurysm of the middle meningeal artery, even at 29 days after the trauma, has been reported. Bleeding dural AVM*s may result in subdural hematomas. {AVM* = Arterivenous malformation}

A whiplash injury of the cervical spine may cause a subdural hematoma due to acceleration and deceleration forces, and also from fall from a height and landing on the feet or buttocks. Subdural hematomas have been reported in battered babies. Boxing injuries may result in subdural hematomas. Acute subdural hematomas may also result from a number of nontraumatic causes.

Site of Hematoma

Though subdural hematomas may occur anywhere inside the skull, the common sites of hematoma are the

anterior-temporal, the inferior frontal and the parietal regions. These give rise to the classical picture of cerebral compression.

Clinical Picture

1. Conscious level

Deterioration of conciousness with a **lucid interval** may be seen *(PGI 97)*. The picture closely resembling an extra dural hematoma. A fluctuating level of consciousness may also be seen. Increasing restlessness is an important sign. In all these cases immediate CT or angiography or burrhole investigation is indicated.

2. Increased Intracranial pressure

Headache and vomiting due to increased intracranial pressure occurs. On fundus examination papilledema can be detected; reflecting increased intracranial pressure.

3. Localizing Signs

4. Associated injuries elsewhere in body.

Investigation

1. CT Scan

The hematoma is usually **sickle or crescent shaped in the acute and subacute stages** *(PGME MANY TIMES)*. Large acute subdural hematomas may appear biconvex and resemble an extradural hematoma.

2. Angiography

Angiography also helps to reveal suspected subdural or a intrgcerebral hematomas.

Acute subdural hematomas tend to have a crescent shape while chronic subdural and extradural hematomas are lenticular, though this is not always true *(PGME MANY TIMES)*.

3. Burr holes or Twist drill holes as diagnostic aids:

Exploratory burrholes at suitable sites are one of the best diagnostic aids when other investigations are not available. Such exploration helps in both diagnosis and treatment.

Treatment

The principles of treatment of acute subdural hematoma are:

1. Early evacuation of the clot by a suitable technique eg; Craniotomy.
2. Control of the bleeding vessels, where feasible.
3. Exclusion of other intracranial hematomas.
4. Treatment of associated brain edema and brain injuries.
5. Treatment of associated injuries elsewhere in the body

Postoperative Care

Head slightly elevated to keep the intracranial venous pressure low. A free airway and adequate respiration are essential to help the brain recover.

In patients with associated brain injury or edema, appropriate treatment with diuretics and ventilation is adopted, followed by general medical and nursing care.

(iii) Subarachnoid Hemorrhage

Subarachnoid hemorrhage is an invariable accompaniment of even very limited brain laceration and contusion. The hemorrhage is not as a rule profuse and may be confined to the presence of a few red blood cells in the CSF. If it is profuse it is likely that a cortical vessel has ruptured. Occasionally the blood stained CSF causes meningism severe enough to cause persistent and trouble some headache, nuchal pain and rigidity.

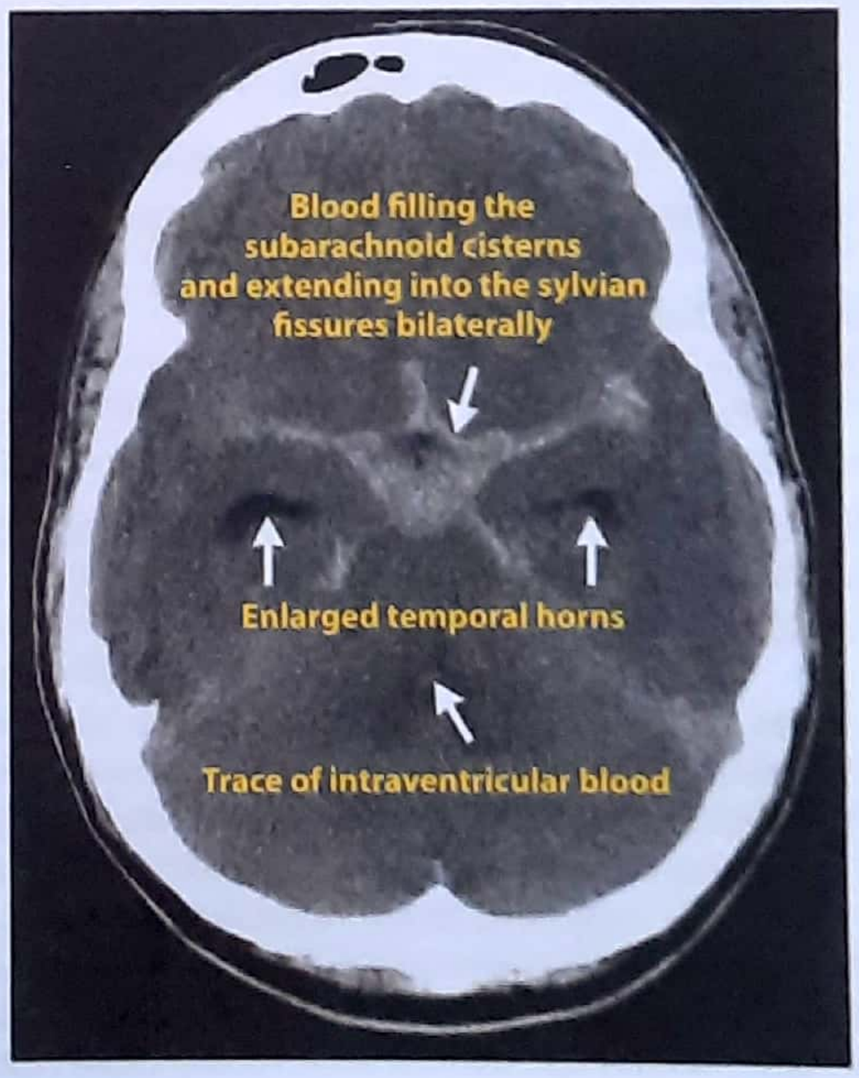

Figure 14.6 : Subarachnoid Hemorrhage

Traumatic Subarachnoid hemorrhage may result in acute hydrocephalus by blocking the CSF pathways. More commonly it causes late onset communicating hydrocephalus by interfering with CSF absorption. (Figure 14.6). *Blood is collected mostly in basal cistern.* (NEET)

Pathophysiology

- The blood supply of brain enters the skull via paired internal carotid and vertebral arteries, within the Subarachnoid space these vessels communicate to form the circle of willis and then branch out over the surface of brain before supplying brain tissue.
- Vessels may rupture into the Subarachnoid space.
- **Excluding head trauma, the most common cause of Subarachnoid hemorrhage is rupture of intracranial saccular aneurysm (Berry aneurysm or congenital aneurysm)** (NEET). Other rarer cause are rupture of a cerebral arteriovenous malformation or hemorrhage from a neoplasm.
- Aneurysm are situated at junctions of the major vessels of circle of willis. In order of frequency, the location of saccular aneurysms that bleed during life are:
  - (i) **Anterior communicating artery (32%) (M/C)** (NEET)
  - (ii) Junction of posterior communicating artery and internal carotid artery (30%)
  - (iii) Middle cerebral artery (10%)
  - (iv) Basilar artery (10%)
  - (v) Bifurcation of the internal carotid artery.
- The majority of aneurysm are common in patients with hypertension and those who are over 40 years.

Clinical Features

Patient has sudden severe headache, they may then lose consciousness or may become disoriented without going into deep coma. Occasionally the blood stained CSF causes meningism, severe enough to cause nuchal pain and rigidity.

NOTE: With the exception of penetrating injuries like gunshot wounds, it is almost impossible for severe brain damage to occur without an alteration in the level of consciousness. Alteration in the level of consciousness is an important clinical entity. Its relationship to the injury and its progress with time and therapy gives valuable information regarding the diagnosis. Unconsciousness which supervenes immediately after the injury but clears in a few minutes is usually explained as concussional. If such unconsciousness persists, it indicates the severity of the underlying primary neuronal damage.

Diagnosis and Treatment

The most important single factor affecting prognosis of operative treatment of surface hematomas is the speed in diagnosis and treatment.

Sooner a surface hematoma is diagnosed, and the sooner the ICP is lowered by emergency decompressive craniotomy (accompanied by IV mannitol during the period between the scan and the dural opening) the greater are the chances of recovery.

The CT scan when available is helpful in these cases, *when it is not available immediately, the choice for the surgeon lies between burrhole exploration* or radiological studies like cerebral angiography. (AIIMS)

Hunt hess scale used as clinical grading system to predict prognosis in patient with SAH.

It is imperative to subject the patient who is rapidly deteriorating or already critically ill, to immediate burrhole exploration which should be bilateral and multiple when ever necessary, *(important point)*

HHH therapy = HTN, hypervolemia, hemodilution

(Triple H therapy) : This is combination of induced hypertension, hypervolemia, and hemodilution which is often utilized to prevent and treat cerebral vasospasm after aneurysmal subarachnoid hemorrhage.

RECAP: *Till now we were discussing different types of intracranial hematoma, please see key box 14.1 on page no 148. (must)*

2. Traumatic Brain Edema

In head injuries, both **vasogenic** and **cytotoxic edema** occur, the former being the more prominent.

(a) Vasogenic edema

Vasogenic edema involves the white matter more than the grey matter. The spread of edema in the white matter is along the fibre tracts, Tissue hydrostatics forces as well as capillary action help the fluid to move along in the white matter.

From a localized contused area, vasogenic intercellular edema spreads locally to involves the surrounding and also the distant white matter. Depressed respiration, CO_2 accumulation, hypoxia and circulatory disturbance further contribute to brain edema.

Resolution of vasogenic edema occurs when the collected intercellular fluids is reabsorbed into the vascular compartment or escapes into the ventricles.

(b) Cellular or cytotoxic edema

This occurs predominantly in the grey matter and is due to the loss of intracellular potassium to the extracellular space and the ingress of chlorides and- water into the cell. This process is aided by disturbances of the neuropeptides in the area. When intracellular edema is intense, the swollen cells suffer from hypoxia and hypometabolism and get irreversibly damaged. Accumulation of lactic acid, superoxides and free radicals occurs and contribute to cytotoxic edema and cell destruction.

Sometimes brain edema occurs during or soon after evacuation of an extradural or subdural clot, as the brain suddenly herniates in a frightening fashion. Hyperventilation and antiedema measures are then urgently required.

Clinical picture

Traumatic edema, when localized, leads to focal neurological deficits. Widespread edema leads to a rapid rise of intracranial pressure and prolonged unconsciousness. On the CT an area of homogenous low attenuation will be seen.

- A some what *typical clinical course* may be as follows: following a moderate or severe head injury a patient is admitted semiconscious or unconscious. He continues to remain in the same state for a few hours and then the conscious level deteriorates.
- The CT shows narrowed, compressed ventricles and cisterns and increase density of the white matter, due to hyperemia, The condition is common in children (malignant brain edema) and with controlled ventilation and antiedema measure recovery may ensue.

Treatment

(JIPMER 81, DNB 89, MANY PGME)

When the patient arrives early, preventive measures include proper ventilation and maintenance of cerebral oxygenation, control of seizures and temperature and the maintenance of proper fluid balance.

(i) Pharmacologic muscle relaxation and controlled **hyperventilation** reduce intracranial pressure rapidly and may break the vicious cycle that perpetuates the edema. Controlled ventilation also corrects hypoxia and hypercapnia.

(ii) Moderate **hypothermia-has** been found helpful.

(iii) Drugs like **20% mannitol** reduce the bulk of the normal brain and provide the necessary space for the edematous brain *(UPSC 2000)*. However, there is the danger of the hyperosmolar solution escaping into the tissue spaces in hemorrhagic contusions making the condition worse. **Steroids are not helpful,** in traumatic brain edema. *(IMP. POINT)*

(iv) **Furosemide** has been found helpful and also the **Carbonic anhydrase inhibitor** (diamox) which reduces the production of CSF by the choroid plexus.

(v) **Dextran infusions** help to reduce the viscosity of the blood without hemodilution. They also reduce platelet adhesion and may be helpful in reducing one of the many factors that perpetuate traumatic edema.

(vi) Ion channel blockers, eg; **calcium antagonists,** are being increasingly used. The effect of nimodipine is uncertain, but selective inhibition of ion channel blockers that are linked to glutamate receptors show promise in reducing ischemic brain edema. **Surgery is not useful** *(NEET)*.

Here, you are strongly advised to revise key box 14.1 on page 148; once again.

3. Cerebral Ischemia

It occurs after severe head injury and is caused by hypoxia and/or impaired cerebral perfusion. Glutamate & free radical accumulation may also contribute to neurological damage.

4. Infection

Compound depressed fracture of base or skull fracture may lead to meningitis or cerebral abscess.

5. Post head injury epilepsy

The overall incidence of epilepsy after head injury is approximately 5%.The risk is greater in patients with penetrating injuries or clots. *The treatment consist of anti-epileptic (Phenytoin) for about 3 years after trauma.* *(AIIMS)*

6. Other less common complication of head injury

These are SIADH, hydrocephalus, traumatic aneurysm and carotid dissection.

RECAP: Till now we were discussing brain injuries; Primary brain injury (which include:- concussion, contusion, diffused axonal injury, and primary brain stem injury) & Secondary brain injury (Which include:- Intra cranial hematoma (extradural, subdural, subarachnoid), traumatic brain edema, cerebral ischemia, infection, epilepsy etc); **Now we will discuss the assessment of the severity of head injury**.

****

KEY BOX 14.2			
Adult GSS	**Score**	**Pediatric GCS**	**Score**
Eye opening		**Eye opening**	
Spontaneously	4	Spontaneously	4
To speech	3	To speech	3
To pain	2	To pain	2
No response	1	No response	1
Verbal response		**Best verbal response**	
Oriented	5	Alert, coos, babbles	5
Confused	4	Spontaneous irritable cry	4
Inappropriate	3	Cries only to pain	3
Incomprehensible	2	Moans to pain	2
No response	1	No response	1
Best motor response		**Best motor response**	
Obeys verbal commond	6	Spontaneous movement	6
Localizes to pain	5	Withdraws to touch	5
Withdraws from pain	4	Withdraws from pain	4
Abnormal flexion (decortibate)	3	Ab (n) Flexion to pain	3
Abnormal extension (decerobrate)	2	Ab (n) Extension to pain	2
No response	1	No response to pain	1

ASSESSMENT OF HEAD INJURY

This is assessed by **Glasgow Coma Scale** *(PGME-MANY TIMES)*. It is a scale for evaluating and quantitating the degree of Coma by determining the best motor, verbal, and eye opening response of patient to stimuli. Coma is diagnosed by the absence of motor, eye opening, and the verbal responses. A score of 7 or less indicates coma; while 9 or greater excludes the diagnosis of coma.

Coma is assesed by (Mnemonic) **MOVE : MOtor, Verbal & Eye** opening; response. *(MANY MANY PGME)*

Glasgow Coma Scale (GCS) *(MANY PGME)*

- Maximum GCS score is 15 & minimum score is 3 (Keybox 14.2).
- In case of intubation, verbal response is denoted as NT.

KEY BOX 14.3	
Pupils unreactive to light	**Score**
Both pupils	2
One pupil	1
Neither	0

GCS - P Score :

A new parameter "Pupil reactivity score" has been added to GCS & referred as GCS-P.

P stands for "Pupils unreactive to light".

Pupillary score is substracted from GCS score.

So GCS-P score ranges from 1 to 15.

Grading of injury severity:

Depending upon GCS score injuries are divided as-

Mild injury > 13

Moderate injury 9-12

Severe injury < 8

Mortality can be assesed by GCS score, **see box 14.2, 14.3, 14.4** :

****

KEY BOX 14.4		
GCS Score	**Severity of head injury**	**Mortality**
13-15	Mild	10%
9-12	Moderate	20%
3-8	Severe	70%

MANAGEMENT OF HEAD INJURIES

The management of the head injured patient varies with his level of consciousness and neurological responses.

1. General measures

1 An airway is established and adequate ventilation provided. Aspiration of vomitus into the lungs must be prevented.
2. All obvious bleeding is arrested.
3. Shock, if present, is treated by starting an IV line and a CVP line if needed. Hypotension may occur in lower brain stem injuries.
4. Both hypo and hyperthermia should be prevented.
5. A nasogastric tube is passed and the stomach contents aspirated.
6. Basic blood studies are carried out: Hb%, PCV, arterial blood gas analysis, biochemical parameters, serum electrolytes and blood grouping to be done.
7. Hypertonic saline and mannitol infusion are avoided until one is the sure that there is no hemorrhage or shock. In fact mannitol diuresis will make the patient lose electrolytes and this may lead to shock.
8. Adult respiratory distress syndrome (ARDS) may be present and in such cases assisted ventilation may become necessary.
9. Radiological investigations are carried out including CT when available.

2. Respiratory Care

As hypoxia is common in head injured patient, even when they appear to be ventilating properly, It is better to administer oxygen to maintain the PaO_2 above 80 mm Hg. The $PaCO_2$ is maintained between 25-30 mm Hg.

As the patient improves, sedation and muscle relax-ants may be necessary so that the patient does not fight the ventilator. Once the patient becomes conscious enough to obey commands and the intracranial pressure has been carried down, ventilation can be gradually withdrawn

3. Cardiovascular Status

Blood pressure above 160 mm Hg. systolic is treated with mild sedation and the administration of propranolol.

4. Control of Infection, seizures

Maintaining proper fluid and electrolyte balance is essential. Appropriate antibiotics are administered in adequate dose to prevent infection. In all serious head injuries, prophylactic anticonvulsant medication in the form PHENYTOIN 10-15 mg per kg. is given.

5. ICP Monitoring

(Normal ICP is 10-15 mm Hg ie; 120-180mm H_2O). ICP exceeding 20 mm of Hg should be treated. When there are lesions in the temporal lobe an ICP of even 15mm of Hg may be dangerous. Controlled hyperventilation to a hypocapnia level of 25-30 mm PCO_2 may bring down the ICP. Diuretic like furosemide & glycerol may be administered, once an intracranial hematoma is excluded. Mannitol may be infused at dose of 1 gm/per kg body weight as a bolus dose. Monitoring of electrolyte values in such circumstances is mandatory.

6. Temperature Control

Rise in body temperature could be due to neurogenic causes, but is more often secondary to chest infection, meningitis, or infection elsewhere in the body. Providing symptomatic relief with antipyretic, prevention of secondary infection and investigations to search for its cause constitute essential components in the management of pyrexia in head injury patient.

7. Nutrition and Other General Measures

The fluid & electrolyte balance as well as nutrition must be maintained. Total parenteral nutrition can be considered, but appropriate nasogastric feeding is generally sufficient in the majority of patients. (Chapter 5)

****

SPINAL CORD

NEURAL TUBE DEFECTS

The central nervous system develops from dorsal ectoderm known as the neural plate, which in early fetal life folds along its length to form the neural tube. The surrounding mesoderm forms the skull and vertebral column and is covered by skin. Defective closure of neural tube may occur through out its extent but is most common on lower end than upper end. (See key box 14.5, on next page)

KEY BOX 14.5

NEURAL TUBE DEFECT

(A) Defective closure the caudal end	(B) Defective closure of cranial end
• Spina bifida occulta • Meningocele • Meningomyelocele • Spina bifida	• Occipital meningocele • Anencephaly

A. Defective Closure of The Caudal End

Spine bifida is a disorder, in which the vertebral arches of lower vertebrae are not fused posteriorly. There are several degrees of severity. It has been discussed below in *order of increasing severity.*

1. Spina bifida occulta

- It is the mildest form and is characterized by failure of vertebral fusion only. (See figure 14.7)
- The overlying skin often shows a dimple or a tuft of hair. In few cases a sinus can be seen connecting the skin and the spinal canal.
- All these patients have increased incidence of meningitis, hydrocephalus and Arnold Chiary malformation*.

Arnold Chiary malformation: Condition in which the inferior poles of cerebellar hemispheres and medulla protrude through the foramen magnum into spinal cord.

2. Meningocele

- This is more severe degrees of anomaly than occulta.
- In meningocele there is associated protrusion of a meningeal sac filled with C.S.F. through the vertebral defect. (See figure 14.7)
- It is **most common in <u>Lumbo sacral spine</u>.** *(AI 89)*
- There is usually *no features* of nerve paralysis affecting the lower limbs, and bladder or bowel involvement.
- It is a *brilliantly transilluminant swelling, and transmitted pulsation* may be present. *(MANY PGME)*

3. Meningomyelocele

- It is more serious form than meningocele, and is commonest variety of spine bifida. *(MANY PGME)*

Figure 14.7: Diagramatic representation of various neural tube defect; read text for details

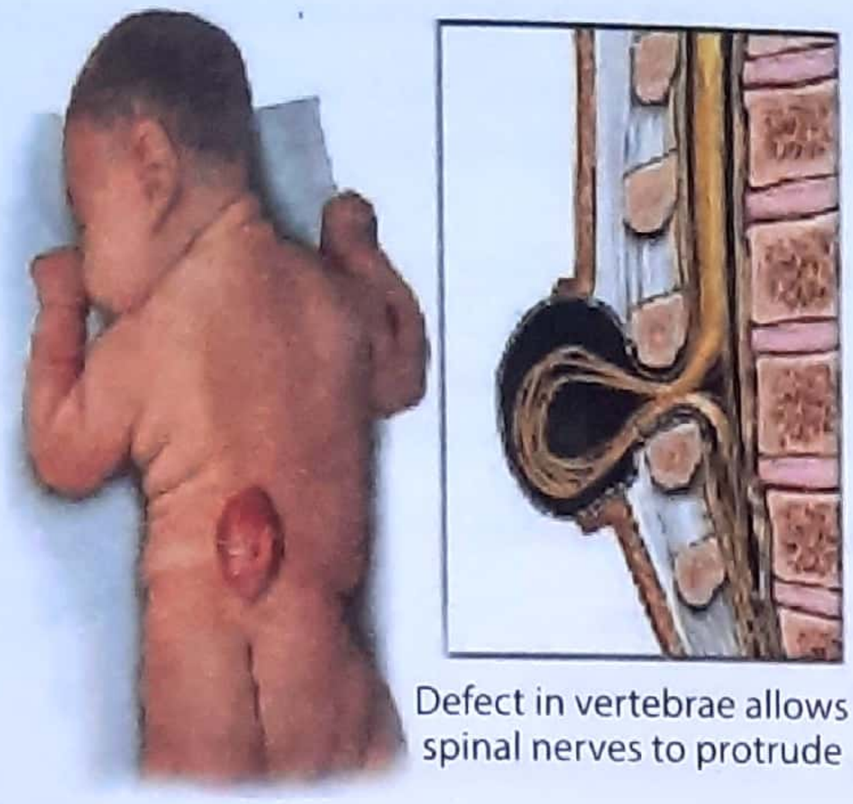

Figure 14.7(Extra): Meningocele

- **The commonest site is <u>lumbosacral region</u>** *(MANY PGME).*
- There occurs failure of development of normal skin at the summit of the swelling and at this point meninges, the spinal cord, and the nerve are attached and swelling may burst through this potentially weak point.
- Associated paralysis of the lower limb, bladder incontinence and rectal incontinence are common features of meningomyelocele.
- Transillumination test shows neural tissue as a dark shadow.

NOTE: In Lumbar meningocele similar swelling is seen in lumbar region

4. Spina bifida aperta

- It is most severe and fortunately very rare form of spina bifida, which results from complete failure of fusion of caudal end of neural plate. The neural plate open on the skin surface. Severe neurologic defects in the legs, bladder and rectum are present.

B. Defective Closure on The Cranial End

Neural tube abnormalities at the cranial end are less common. Complete failure of development of the cranial end of the neural tube results in **anencephaly,** which is incompatible with life.

Occipital meningocele is protrusion of a CSF filled sac of meninges through the skull in the occipital region. An **encephalocele** is similar but contains brain matter in the meningeal sac. (Figure 14.8)

Clinical Presentation

Spina bifida occulta

This is a common abnormality that is usually asymptomatic and discovered when a radiograph of the lumbosacral spine is obtained. Rarely, these patients have an associated fistulous communication between the skin and the spinal canal that predisposes to recurrent meningitis in childhood. Also rarely, there may be a keratin filled epidermal cyst in the spinal canal that may leak; causing chemical meningitis.

Meningocele, meningomyelocele, and spina bifida aperta present at birth with a detectable lesion in the lumbosacral region.

Meningocele

This is cystic and transilluminant, fluctuant, compressible swelling, and is not associated with severe neurologic deficit. When child cries, an expansile impulse is present. On palpating the swelling, a bony defect is usually found.

Meningomyelocele

This shows neural structures on transillumination of the cyst and is associated with lower limb weakness and with bladder and rectal dysfunction.

Spina bifida aperta

It appears as a flat lesion in which the open spinal cord is visible and produces a profound neurologic deficit.

Figure 14.8 : Occipitalmeningocele

All of these patients have an increased risk of meningitis and hydrocephalus from the frequently associated Arnold Chiary malformation.

Anencephaly

It is incompatible with life after birth. Occipital meningocele and encephalocele are similar to their spinal counterparts. The most common location of the cystic mass is the nape of the neck. When very large, an occipital meningocele may obstruct normal deli very of the baby.

Treatment

- Spina bifida occulta usually do not require treatment but surgical treatment is indicated when neurological, urological or orthopaedic symptoms progress or appear after infancy.
- The treatment of meningocele is by excision of sac. Majority of patients with meningocele recover after operation. Later on, a few may develop hydrocephalus.
- Meningomyelocele is treated by excision of sac, sparing and replacing spinal cord and nerves in the spinal canal.

TUMORS OF CNS

A wide variety of tumors affect the brain and spine. Primary benign and malignant tumors arise from various elements of CNs including neurons, glia and meninges.

The most common brain tumor is metastasis. Primary brain tumor represent 1.9% of all cases.

Classification

Other than metastases, brain tumor is classified based on their element of origin.

1. **Metastatic Tumors**
2. **Glial Tumors**
   - Astrocytoma
   - Oligodendroglioma
   - Ependymoma
   - Choroid plexus Papillioma
3. **Neural & Mixed Tumors**
   - Medulloblastoma
   - Ganglioma
4. **Miscellaneous Tumors**
   - Meningioma
   - Acoustic neuroma
   - Pituitary adenoma
   - Hemangioblastoma
   - Lymphoma

KEY BOX 14.6

Patterns of deficit generally associated with certain tumours

Tumour location	Expected deficit
Pituitary (e.g. pituitary adenoma)	Bitemporal hemianopia; gaze palsies
Cerebellopontine angle (e.g. vestibular schwannoma)	Hearing loss; balance disturbance; tinnitus
Anterior skull base (e.g. olfactory groove meningioma)	Anosmia; ipsilateral optic atrophy; contralateral papilloedema (Foster-Kennedy syndrome)
Occipital (e.g. glioma, metastasis)	Homonymous hemianopia with central sparing
Parietal (dominant hemisphere)	Acalculia; agraphia; left-right disorientation; finger agnosia **(Gerstmann syndrome)**
Parietal (e.g. glioma)	Sensory inattention; dressing apraxia; astereognosis
Temporal (e.g. glioma)	Memory distrubance; contralateral superior quadrantanopia; dysphasia (dominant hemisphere)
Frontal (e.g. glioma)	Personality change; gait disturbance; urinary incontinence
Brainstem (e.g. brainstem glioma)	Multiple cranial nerve deficits; long tract signs; nystagmus
Posterior fossa (e.g. medulloblastoma)	Ataxia; hydrocephalus

1. Metastatic Tumors - These are most common type of intracranial tumor.

- The source of most cerebral metastasis are -

  Lung > Breast > Kidney > GIT > Melanoma

- The Location of metastasis are grey + white junction, cerebellum and **meninges (leptomeningeal carcinomatosis)**.

Investigation include -

- MRI pre & post contrast (of choice)
- CT scan of breast, abdomen, pelvis and a bone scan to locate primary.

- Management depends on primary tumor, overall tumor burden, patients condition & location and number of metastases.
- Occasionaly diagnostic biopsy may be warranted in unknown primary.
  - VP shunt is done in hydrocephalus from increased ICP due to tumor.
  - Craniotomy for resection of upto 3 metastasis (usually single)
  - Stereotactic radiosurgery / Gamma knife / Cyberknife

2. Glial Tumors -

(a) *Astrocytoma:* In adults , it is supratentorial & in children - infratentorial.

- It is most common posterior fossa tumor in children.
- Astrocytomas are graded from grade I to IV.

Grade I - is pilocytic astrocytoma which is low grade, most common astrocytoma in children.

- It presents as a mural nodule without infiltration.
- Diagnosed by MRI.
- Treated by surgical excision.

Grade II - is low grade, diffuse astrocytoma.

- It presents in children & young adults.
- It shows nuclear atypia & low cellularity.
- Diagnosis → MRI
- Management is surgery followed by whole brain radiotherapy (WBRT).

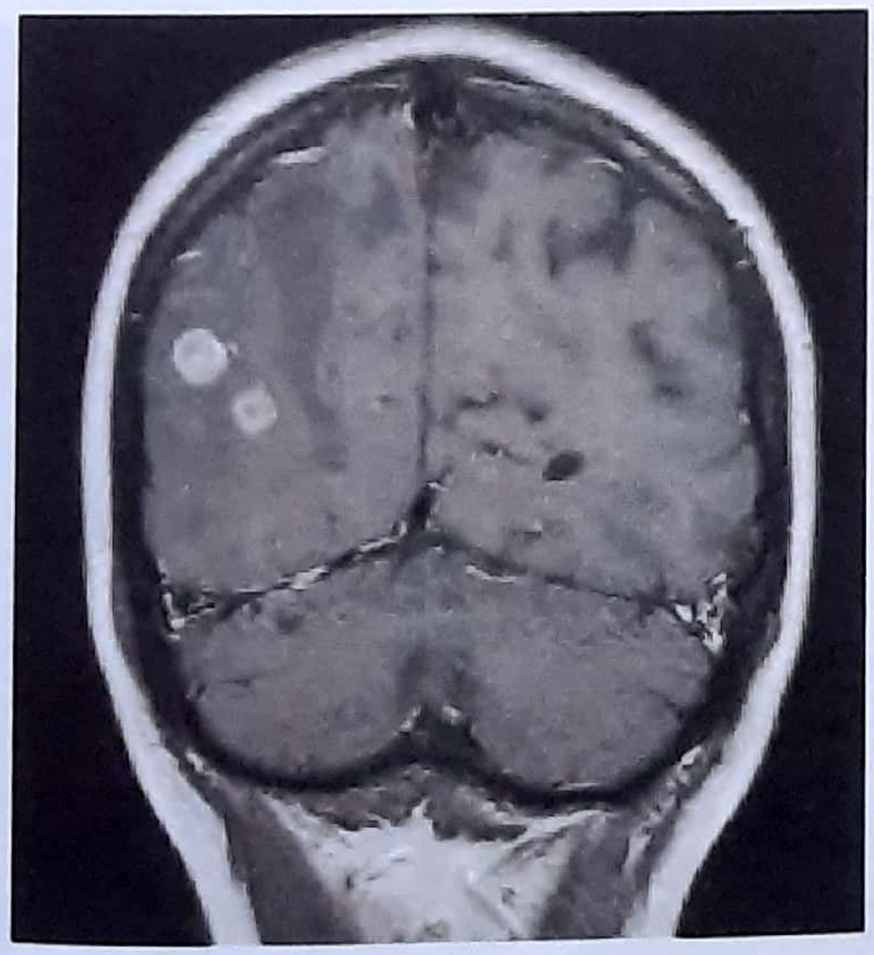

Figure 14.9 : T1-weighted magnetic resonance imaging with contrast. Two occipital lung metastases are demonstrated. They are well demarcated and enhance with gadolinium contrast.

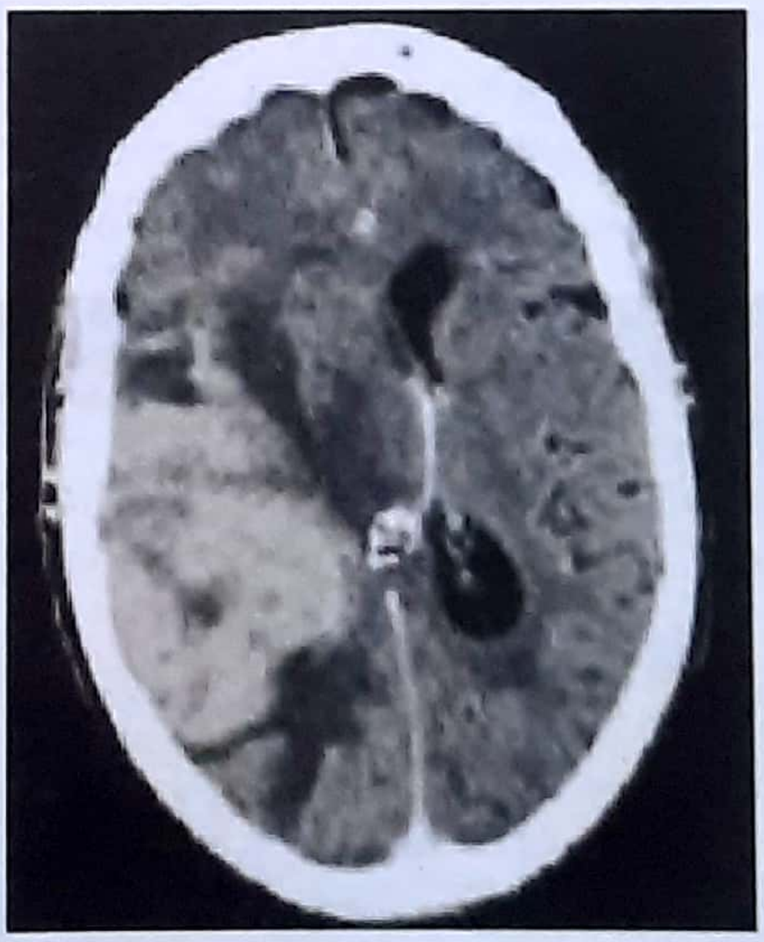

Figure 14.10 : Computed tomography with contrast demonstrate a heterogeneous right frontoparietal lesion with mass effect and mid-line shift, almost certainly a glioblastoma multiforme. A magnetic resonance imaging scan with and without contrast will aid evaluation.

Grade III - Anaplastic astrocytoma.

- It presents with seizure, personality change.
- Diagnosis → MRI shows irregular enhancing lesion.
- Management → Surgery followed by WBRT.

Grade IV - It is most aggressive (Glioblastoma multiforms) also called as Butterfly tumor.

- On histopathology - necrosis & pseudopalisading pattern seen.
- MRI – Ring enhancing lesion with central necrosis.
- Management - Surgery followed by external beam radiotherapy (EBRT).

(b) *Oligodendroglioma:* Approx. 10% of glioma.

- Often presents with seizure.
- Loss of heterozygosity on ..... 19p > 1p.
- Calcification & hemorrhage on CT or MRI suggests diagnosis.
- Prognosis is better them astrocytoma.
- Aggressive resection improves survival.
- Many will respond to procarbazine, lomustine & vincristine chemotherapy.

(c) *Ependymoma:* Most pediatric ependymoma are supratentorial 2/3 of adults are infratentorial.

- Most common symptoms are headache, nausea, vomiting, or vertigo (↑ ICP)
- Most common is myxopapillary ependymoma.
- It may also spread through CSF to form drop metastasis in the spinal canal.
- Gross total resection is often impossible because it arises from brainstem.
- Post o. radiotherapy significantly improves survival.
- If CSF spread is present → Craniospinal radiation is given.

(d) *Choroid plexus papilloma:* Papilloma usually occur in infants but also occur in adults.

- Papillomas are well circumscribed & widly enhance due to extensive vasculature.
- It usually presents with symptoms of increased ICP.
- Treatment is surgical excision.
- Radiation & chemotherapy not indicated.

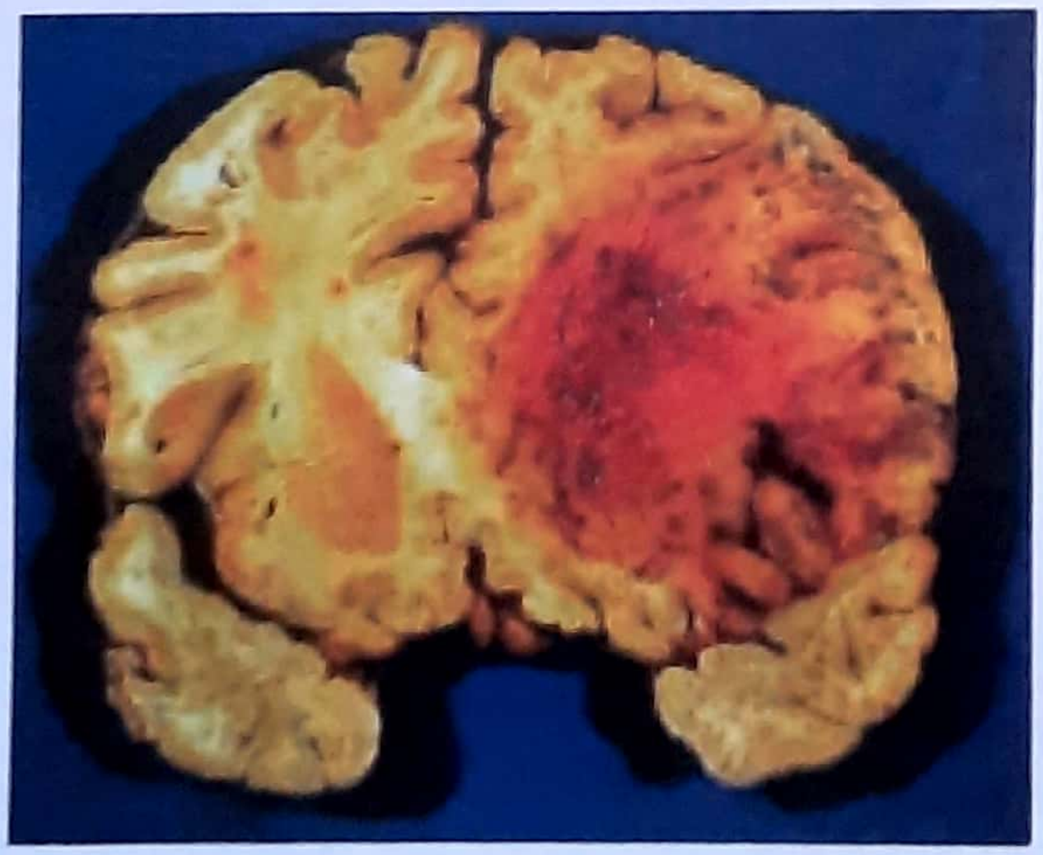

Figure 14.11 : Pathological specimen of glioblastoma multiforme

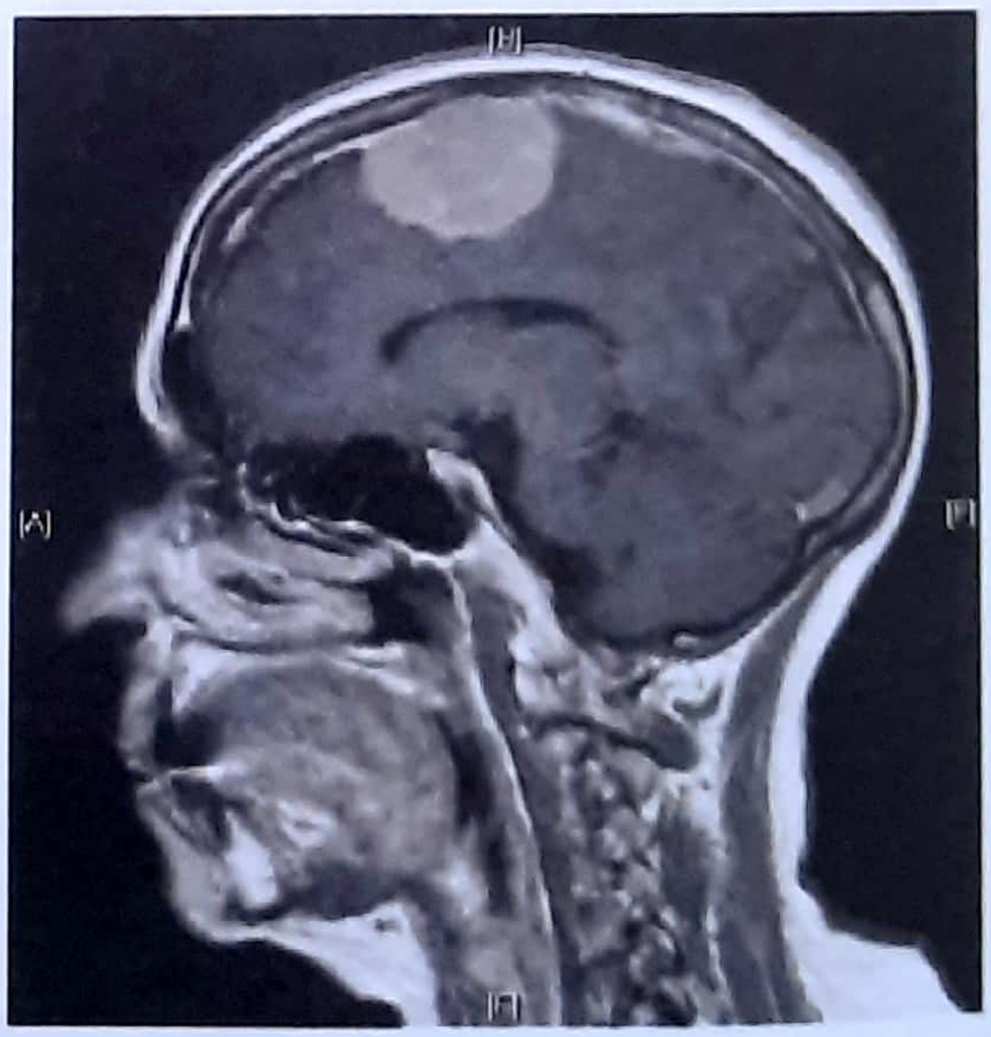

Figure 14.12 : On T1-weighted magnetic resonance imaging an extra-axial, durally-based lesion is seen to arise in the region of the falx. This is a meningioma

3. Neural and mixed tumors

(a) *Medulloblastoma*

- It is most common primary brain tumor in children (3-4 yr). There is second peak around age 30. They are usually midline, most occur in cerebellum and present with symptoms of raised ICP.
- Shows drop metastasis through CSF.
- Diagnosed by MRI
- **Management** - Surgical excision followed by radiation (highly radiosensitive) and chemotherapy (carmustine and vincristine).

(b) *Ganglioglioma*

- It is a mixed tumor.
- Occur in 1st 3 decade of life often in median temporal lobe as circumscribed mass that may contain cyst or calcium.
- Have good prognosis after complete surgical resection.

4. Miscellaneous tumor

(a) *Meningioma*

- It arises from meningeal cell/arachnoid cap cells.
- These are dural based tumors.
- Most common primary brain tumor in adults.
- It is slow growing well capsulated tumor.
- Previous cranial irradication increased incidence of meningioma.
- Diagnosis - MRI
- On histopathology, psommoma bodies are seen.
- Total surgical resection is curative.
- Simpson grading scale is used to characterise extent of resection.

(b) *Acoustic neuroma*

- Patients present with progressive hearing loss, tinnitus or balance difficulty.
- B/L acoustic neuroma are pathognomonic of NF-2 (chap - 22)
- Vestibular schommoma is treated with microsurgical resection (>3cm) or SRS (Gamma knife surgery) (<3 cm).

(c) *Hemangioblastoma :* Occur almost exclusively is posterior fossa.

- Associated with VHL syndrome.
- Many appear as cystic tumor (mural nodule)
- Surgical resection is curative for sporadic tumor.

(d) *Lymphoma*

- Increasing incidence of CNS lymphoma is due to increasing transplant & AIDS population - Usually NHL.
- Presenting symptoms include mental status change, headache, cranial nerve palsy.
- Lymphoma appear hyperdence on CT due to dense cellularity.
- A stereotactic biopsy is confirmatory for diagnosis.
- Treatment includes - steroids, methotrexate, WBRT, and chemotherapy.

SYNDROMES & BRAIN TUMOR

- NF-1 → 17q → Neurofibroma, schwannoma, meningioma
- NF-2 → 22q → Schwannoma, glioma, meningioma.
- Cowden's disease → PTEN → Astrocytoma.
- Li - Fraumeni syndrome → p 53 → Astrocytoma.
- Turcot syndrome → APC (5q) → Medulloblastoma.
- MEN - 1 → 11q → Pituitary adenoma.
- VHL → 3p → Hemangioblastoma.

****

Sample Questions for Prof Examination

Write short notes on the following:

1. Extradural hematoma
2. Spina bifida
3. Subdural hematoma
4. Discuss management of a case of head injury
5. Subarachnoid hemorrhage.
6. Glasgow Coma scale
7. Meningocele
8. Meningomyelocele

15 Mouth, Cheek and Tongue

Contents

- Stomatitis
- Oral candidiasis
- Bacterial infection
  - Vincent stomatitis
  - Cancrum oris
- Oral Ulceration
  - Apthous ulceration
  - Herpes ulcer
  - Traumatic ulcer
  - Syphilitic ulcer
  - Tubercular ulcer
  - Ulcers due to agranulocytosis
  - Carcinomatous ulcer
- Oral cysts
  - Mucus retention cyst
  - Ranula
  - Dermoid Cyst
- Cheek
  - Tumours of cheek
  - Carcinoma of the cheek
- Lip
  - Carcinoma of lip
- Tongue
  - Tongue tie
  - Macroglossia
  - Hyperkeratosis
  - Leukoplakia
  - Erythroplakia
  - Oral submucous fibrosis
  - Carcinoma of tongue

STOMATITIS

Stomatitis is a general term applied to inflammatory, erosive and ulcerative condition of oral mucous membrane, and can affect any age group. [Figure 15.1(a)]

The oral cavity is normally well protected from infection by antibacterial and antiviral property of saliva. Saliva has also a local immunological protection, however, occasionally the normal flora of oral cavity may become pathogenic; if there is nutritional and immunological deficiency. A good oral hygienic status is necessary to maintain the normal natural protective mechanism.

Predisposing Factor

A. General causes

1. *Low general condition and malnutrition*

   (i) *Deficiency*: Iron (Plummer Vinson syndrome), Vit. C, Vit B_{12}, some other Vit: 'B's and folic acid,

Figure 15.1(a) : Stomatitis

(ii) Diabetes mellitus.

(iii) Malignant cachexia, hypoprateinemia.

(iv) Cytotoxic drugs, poisons.

2. *Genetic condition* - Epidermolysis bullosa.
3. *Occupational hazard* - Lead exposure.

B. Local causes

Mechanical, chemical and physical injury, leading to chronic superficial inflammation viz.

1. SEVEN 'S's:-Smoking, Spirit (alcohol), Sharp tooth, Sepsis, Syphilis and Susceptibility.
2. Leukoplakia.
3. Chronic irritation- Dentures.
4. Radiotherapy.

Treatment

Treatment is mainly symptomatic, and is usually by removal of predisposing factor.

****

ORAL CANDIDIASIS

- Candida albicans is a part of the normal oral flora, but may become pathogenic in patient whose resistance is diminished.
- Acute oral candidiasis is commonly seen in AIDS patients, malnourished, immunocompromised or in patients with prolonged steroid therapy *(UP, AL 2002)*.
- It is also common in patients with diabetes and chronic liver disease.
- Characteristically, a small red patch appears on the buccal mucosa and tongue, which later turns white. Please see figure 15.1(b).

Treatment

Anti fungal drugs such as Amphotericin-B (AMB) or fluconazole; more recently itraconazol is given and usually cures the condition. Surgical excision of leukoplakic patch may be recommended for persistent lesions.

****

Figure 15.1(b) : Oral candidiasis

BACTERIAL INFECTION

Almost all suppurative oral infection originate primarily from tooth infection *(PGME)* ie; dental caries, dental pulp infection and alveolar abscess. This results in trismus and odynophagia. Common bacterial infections of oral cavity are described below:-

1. Vincent's stomatitis

- This is also known as ulcero membranous stomatitis.
- The inflammation is caused by spirochete *Borrelia vincenti,* a gram -ve fusiform anaerobic bacteria, which is normally present in oral cavity.
- Tonsillar infection by these organisms is called Vincent's angina. When this occurs on gingiva it is called ulcerative gingivitis **(Vincent's ulcer).**
- *Macroscopically,* there are widespread irregular ulcers with slough formation in the oral mucosa.
- This may progress to the gum with subsequent destruction.
- *Histologically,* there are features of nonspecific inflammation) infiltration of neutrophils and presence of large number of *B. Vincenti* and *Fusiform* bacilli.
- Patient is febrile, and have pain to disturb normal chewing and speaking.
- *Treatment* is with metronidazole with particular attention to oral hygiene.

2. Cancrum Oris (Gangrenous stomatitis)

- Cancrum oris affects, debilitated, malnourished children (PGI 97).
- The disease starts as an acute inflammation around mouth or nose, then inflammation spreads rapidly leading to edema, ischemia and *gangrene of cheek* and may even involve bony structures of face (Jaws) (AIIMS, MANY PGME).
- The exact cause is not known, but may be bacterial; Fusiformis and Borrelia are largely responsible.
- If not treated promptly, this condition is quickly fatal due to associated illness or complications; such as septicemia and aspiration pneumonia.

Treatment

1. Improvement of general condition.
2. Intravenous antibiotic therapy.
3. Debridement of necrotic tissue
4. Surgical reconstruction (plastic surgery) should be undertaken only when the general condition of the child improves. All the scarred tissue is excised and the defect is repaired with tubed pedicle skin flap *(Gillies flap)*

****

ORAL ULCERATIONS

1. Apthous (dyspeptic) ulceration

- This is a condition of unknown etiology occurring both in children and adults, particularly in association with different gastrointestinal disorders and sometimes in otherwise normal persons. The oral hygiene of patient is usually good.
- Gross morphological features are *multiple small painful shallow ulcers surrounded by red halos, appearing in crops is characteristic* (AIIMS 93).
- The common sites are tip of tongue & floor of the mouth.
- Histologically; there are features of nonspecific inflammation.
- *Apthous ulcer vary in size, number and frequency and are painful* (MANY PGME).
- The ulcers are usually small, multiple, with erythematous margins.
- A culture should be obtained from lesion and appropriate antibiotic should be used, if secondary bacterial infections are detected.
- Mouth should be kept clean and it should be rinsed thrice with diluted dettol water or antiseptic mouth wash.

2. Herpes ulcer

- This type of ulcer is usually found in children and adolescent.
- The virus remains in the skin and nerve ganglia (usually trigeminal nerve), which is reactivated time to time by physical or emotional stress. Malignancy and steroid use also leads to reactivation. A **painful** ulcer is formed at any part of oral mucosa but mostly on gingiva, tongue and hard palate.
- Conservative treatment with topical anesthetics and antiviral agent; like idoxuridine usually cures the condition, (IMP. POINT)

3. Traumatic (dental) Ulcer

- The most frequent cause of a solitary ulcer in oral cavity is trauma due to improper denture or sharp tooth.
- The ulcer may become deep, necrotic with indurated base, mimicking a carcinoma.
- The obvious source of irritation should be dealt with, and after removal of the cause the ulcer usually heals within two weeks. If healing does not occur, biopsy is recommended to exclude malignancy.

4. Syphilitic Ulcer

- Syphilitic ulcers are mainly seen in the second stage of syphilis and described as 'snail track' ulcer.
- They are painless. In tertiary stage gummatous ulcer are found.
- *Syphilitic ulcers are painless ulcers* (PGME). Please see key box 15.1.

5. Tuberculous Ulcer

- The tuberculous ulcer of oral cavity are shallow, often multiple, **very painful*** (PGME) yellowish lesion.
- The edges of oral tubercular ulcers are **sloping** rather than undermined, like tubercular ulcers at other sites. There may be associated tuberculosis of lung or larynx.

KEY BOX 15.1	
Painful tongue ulcer	**Painless tongue ulcer**
• Apthous (dyspeptic) ulcer • Herpetic ulcer • **Tubercular ulcers** • Traumatic ulcers	• Syphilitic ulcer • Early carcinomatous ulcer **Note:** Advanced carcinomatous ulcer may be painful

- Antitubercular treatment is effective, and cures the condition.
- Usually a pure tubercular ulcer anywhere in body is painless, only tubercular ulcer that occurs on tongue/oral cavity is painful. * See key box 15.1.

6. Ulcers Due to Agranulocytosis

- This condition occurs when the total leucocyte count is reduced to 1000 cells per microliter of blood, which may be even less than 400 cells and granulocytes are practically absent from the blood.
- The usual causes are aplastic anemia, kala-azar, chemotherapeutic agents and other drugs.
- In the early stage, mucosal congestion occurs, later on, there is ulceration with sloughing and membrane formation in the mouth.
- The lesion progresses down the esophagus and involves the whole alimentary tract.
- The diagnosis is confirmed by blood examination and treatment is directed towards underlying cause.

7. Carcinomatous ulcer

- It usually occurs in elderly individuals; above age of 50 years. The common site is at the margins particularly in anterior 2/3rd of the tongue.
- The carcinomatous ulcers are usually painless and solitary if not infected.
- Carcinomatous ulcers should be excises with a healthy margin of at least 2cms.

****

Figure 15.2: Mucous retention cyst

ORAL CYSTS

1. Mucous Retention cyst

- Small retention cysts may occur any where on mucous membrane of the mouth. The inner side of the lips and the inside of the mouth contain many small mucous secreting glands. When the ducts of these glands block, the formation of these cysts occurs.

Clinical feature

- Mucous cyst can occur at any age and presents as a small, painless slow growing swelling, usually on the inner side of lip or cheek. See figure 15.2.

Treatment

- Complete excision of the cyst under local anesthesia is treatment of choice.

2. Ranula (AI 2011)

- *Ranula is a thin walled, bluish extravasation cyst located beneath the tongue in the floor of the mouth* (AI-IMS 05).
- Ranula forms due to obstruction of duct of a mucous gland on the floor of the mouth or ***from one of the sublingual salivary gland*** (NEET, TN 91).
- It is so called, because of its resemblance with frog ***(rana tigrina)*** belly.
- Ranula are often unilateral.

Figure 15.3 (a) : Simple renula

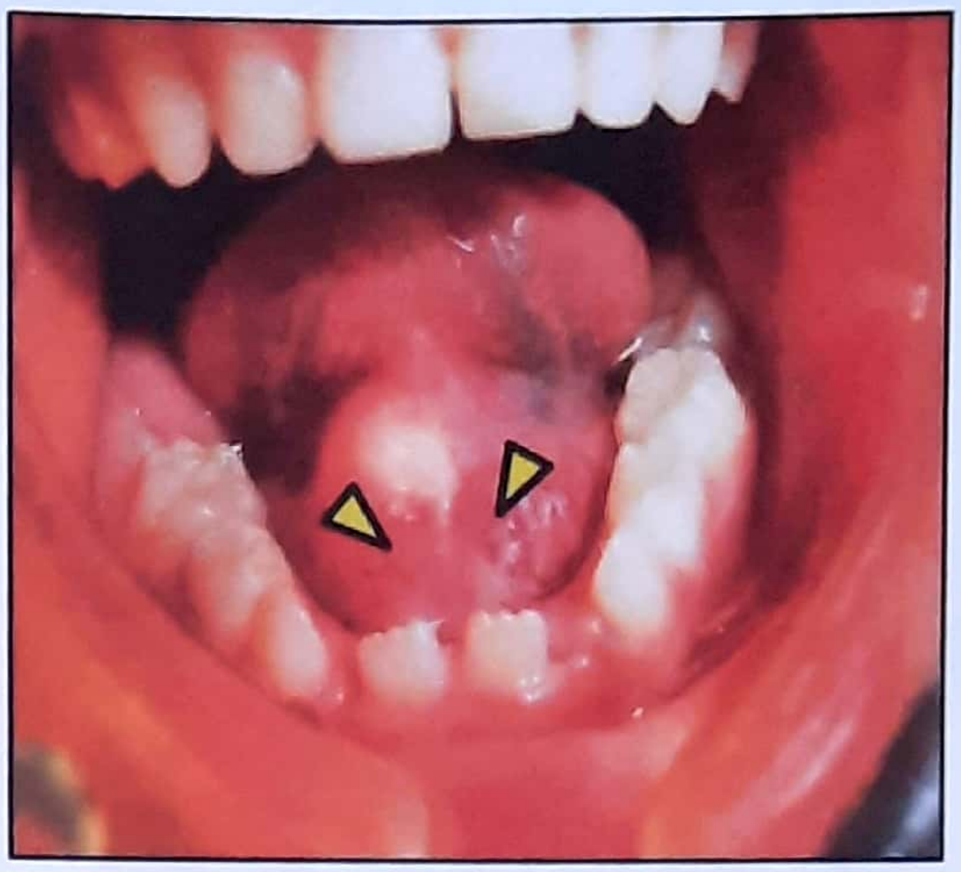

Figure 15.3 (b) : Sublingual Dermoid

Clinical feature

- Ranula is most commonly seen in children and young adults and affects both sexes equally.
- *Ranula is a fluctuant and bluish brilliantly transilluminant swelling,* and the only complaint is a slow growing swelling over a few weeks or months in the midline of tongue or floor of mouth.
- The size of swelling varies between 1-5 cm in diameter. Rarely a ranula may enlarge "and cause difficulty in speech and eating.

Type of Ranula

(i) Simple ranula

When the ranula is situated only on the floor of mouth without any cervical prolongation, it is called as simple ranula. See figure 15.3 (a).

(ii) Deep or plunging ranula:

When a ranula has cervical prolongation, it is called as deep or plunging ranula. It grows downwards by dissecting its way down; between the mylohyoid and the hyoglossus muscle.

Treatment

Complete excision of cyst is ideal treatment, and when not possible marsupialization gives satisfactory results.

Excision is associated with injury to submandibular duct.

3. Dermoid Cyst (Sublingual Dermoid)

- Dermoid cyst may be found in the midline of tongue (sublingual dermoid) or in floor of mouth and at times may enlarge enough to cause a visible swelling below the chin. Figure 15.3 (b)
- Dermoid cyst is situated in **midline,** where as a ranula is unilateral swelling in the floor of the mouth.
- Sub lingual dermoid is a congenital swelling as is formed at the point of fusion of the two mandibular arches (First arch mesoderm).
- The cyst is whitish in colour and is opaque.
- *Transillumination test is negative, where as ranula is brilliantly transilluminant.* (IMP POINT)
- **Treatment** consist of *complete excision of cyst.*

****

LESIONS OF THE CHEEK AND LIP

Anatomically, the cheek extends from the upper alveolar ridge down to the lower alveolar ridge, and from the commissure anteriorly to mandibular ramus and retromolar region posteriorly.

Tumour Of Cheek

Tumours of cheek can be classified as benign and malignant.



Figure 15.4 (a) : Verrucous carcinoma of oral cavity

A. Benign

Papilloma, Hemangioma, Lipoma, Neurofibroma, Lymphangioma, Ectopic salivary tumour (Pleomorphic adenoma), Fibroepithelial polyp, Granuloma.

B. Malignant

(a) **Primary:** Squamous cell carcinoma, Adenocarcinoma, Ectopic salivary tumour.

(b) **Secondary:** from direct invasion by adjacent malignancy.

CARCINOMA OF THE CHEEK

- In India, tobacco chewing is the most important cause of cheek cancer. It is also called as 'chutta cancer' as it is reported in people practice reverse smoking (smoking with the burning end of the cigarette or *bidee* inside the mouth).
- Most cancer common in men is oral carcinoma.
- The most common histological variety is squamous cell carcinoma, and has a male preponderance. *(PGME)*
- Tumours may be exophytic, ulcerative or verrucous* and may be associated with extensive leukoplakia.

*Verrucous = Raised, or warty

Etiology

1. Predisposing factors

The common predisposing factors are smoking, spirit, Candida infection, betelnut, pan leaf, tobacco chewing.

2. Premalignant condition

- Leukoplakia
- Erytheroplakia (17 times higher premalignant potential than leukoplakia)
- Chronic hyperplastic candidiasis
- Oral submucous fibrosis
- Oral lichen planus
- Discoid lupus erythematous

Clinical feature

- Cheek cancer arises either at the commissure or around retromolar area and majority being situated posteriorly.
- The onset of the disease is insidious, and in advanced cases some patients may present with trismus due to deep neoplastic infiltration into the buccinator muscle.
- It may present as a small ulcer to a large fungating foul smelling tumour.
- Carcinoma cheek is a slow growing tumour and the lymph node spread remains confined to the suprahyoid area for a long time.

Spread

1. *Local:* Involving the buccinator muscle; extension posteriorly involves the anterior pillar of the fauces and soft palate; ulcero-infiltrative lesions will often involve the overlying skin of the cheek, resulting in multiple sinuses; and sometimes the mandible is also involved.
2. *Lymphatic spread* to the submental, submandibular, parotid and lateral pharyngeal nodes.
3. Spread through blood is rare.

Investigation

An adequate biopsy (FNAB) from multiple sites helps in diagnosis. Oral pantomography (OPG) can help assess alveolar and jaw involvement.

Treatment

The treatment consist of:

- Surgery
- Radiotherapy
- Chemotherapy

Surgery

- In cancer of cheek, the lymph node enlargement is limited usually to submandibular group. The radical excision of the primary tumour is done along with biopsy of regional lymph node.
- Surgery is contraindicated, if there is considerable posterior extension to retromolar region.

Radio therapy

For small lesions (<2 cm) and with no regional lymph node and bone involvement, radiotherapy is treatment of choice.

Chemotherapy

It is given; if the cancer is advanced and metastases has occurred, and surgical excision or radiotherapy is not possible. The most common chemotherapeutic agent used is *cis*-Platin[AIIMS 93], 5FU, Docetaxel, methotrexate paclitaxel.

****

CARCINOMA LIP

- Carcinoma of the lip is one of the common malignancy of oral cavity and is usually seen in heavy smoker.
- *Carcinoma of lip accounts approximately 10-15% of all face and head malignancies* [AL 96].

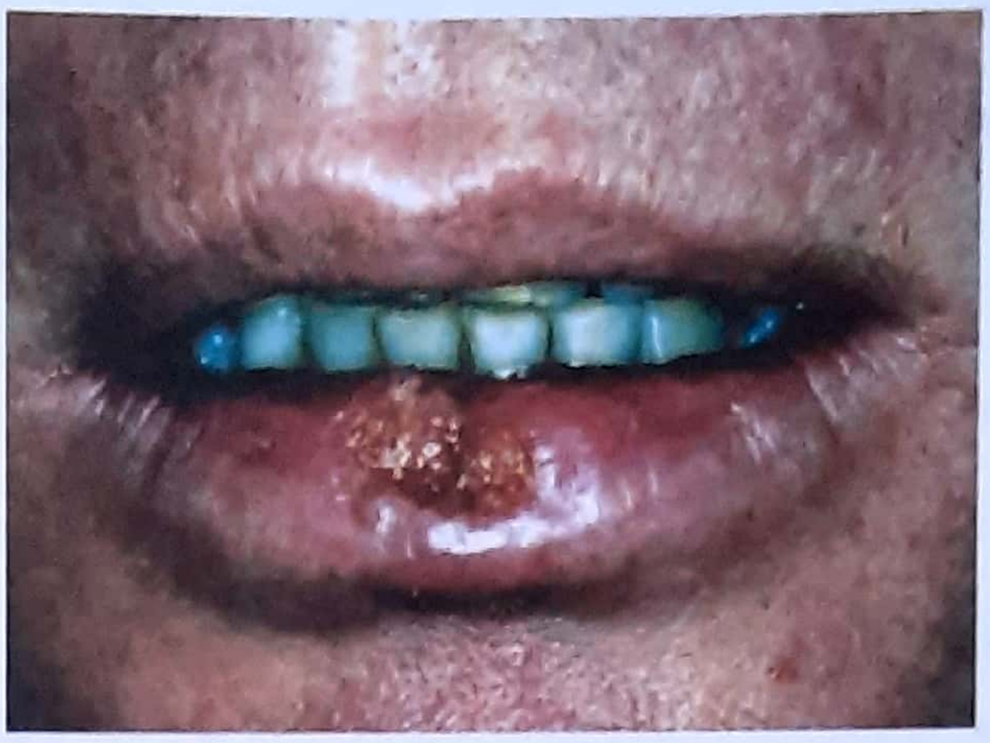

Figure 15.4 (b) : Squamous cell carcinoma of the lower lip

- *The commonest site for lip cancer is vermilion border of lower lip* [UP 87, AIIMS, PGI, UPSE 07].
- Please see figure 15.5, 15.4(b).

Predisposing factor

- 90% of the cases are seen in males over age of 40 years, and the incidence increases with advancing age with highest incidence in 6th decade.
- Persons with light coloured skin, blue eye and light coloured hair, when exposed to sunlight are more likely to develop lip cancer. Carcinoma of the lip is rarely seen in blacks.
- There is *definite correlation between lip cancer and exposure to sunlight.* [IMP. POINT]
- Other predisposing factors are:
  - (i) Syphilis
  - (ii) Tobacco (khaini)
  - (iii) Heavy alcohol abuse

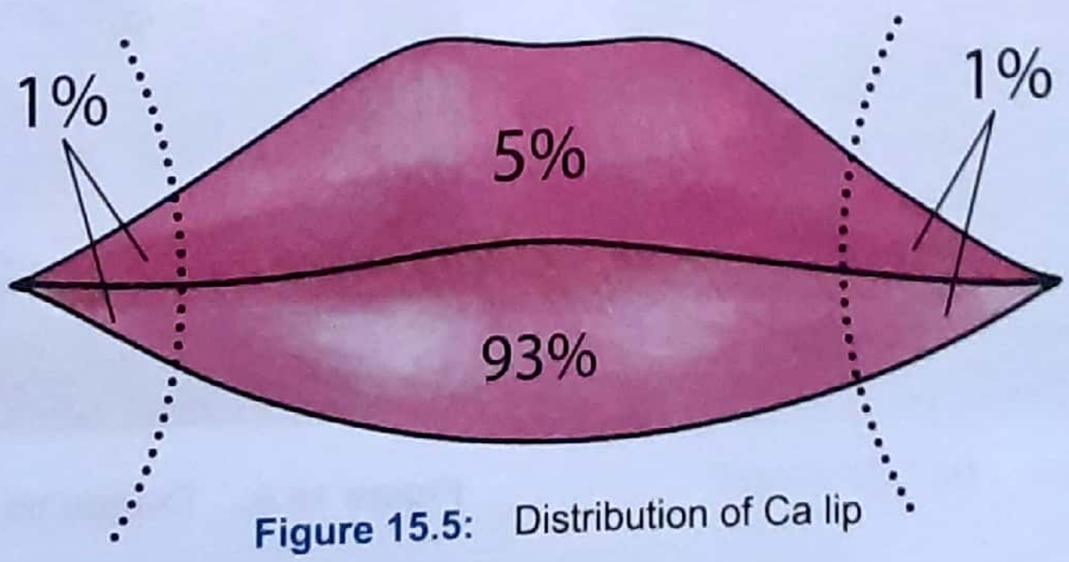

Figure 15.5: Distribution of Ca lip

Pathology

- A lip carcinoma starts as a nodule or a crack and may progress in two forms -
  1. Indurated nodule, warty mass or exophytic lesions.
  2. Endophytic lesion or ulcerated lesion.
- Microscopically lip cancer is usually squamous cell carcinoma, occasionally basal cell carcinoma and rarely melanoma.

Clinical feature

- *Lip cancer usually presents as a nodule or a non healing ulcer.* (IMP. POINT)
- It is usually painless.
- The lesion may bleed & offensive discharge may be present.
- Edges of ulcer is everted and base of ulcer is hard and indurated.

Spread (UPSE 07)

- Most common mode of spread is local and tumour tends to spread laterally rather than infiltrating deep. In late cases it can spread into anterior triangle of neck and invade the mandible.
- Lymphatic spread occurs late & hematogenous spread is rare.

Investigation

- **Biopsy** is taken from edge of the ulcer, and it should always include some normal adjacent tissue.
- *Oral pantomography* (OPG) of jaw can help assess alveolar and jaw involvement.

Treatment

1. Surgery

- *If lesion is less than 2cm in diameter,* ***local excision is usually curative*** (NEET). *Up to 1/3 of the lower lip can be removed safely with primary closure* (MANY PGME)

When excision of more than 1/3 of lip is required closure is achieved by transposition of a segment of the opposite lip on a vascular pedicle (**Abbe flap**) (PGME).

Abbe or Abbe - Esthander Flap used in lip reconstruction is based on labial artery (AIIMS MAY 09).

- If cervical lymph nodes are involved block dissection is necessary.

2. Radiotherapy

It has a high cure rate but is reserved for unresectable lesions. For lesions without lymph node metastases; 5 year survival is 90%.

****

DISEASES OF TONGUE

TONGUE TIE

Tongue tie is a congenital condition, where frenum linguae is short and stunted (Figure 15.6). The elevation or protrusion of the tongue may become limited. The deformity in most infants does not produce disability, however in some infant it may interfere with voice with advancement of age. Some times division of the frenum linguae may become necessary.

MACROGLOSSIA

Macroglossia is a chronic, persistent, painless, enlargement of the tongue, which is *disproportionate to the oral cavity.*

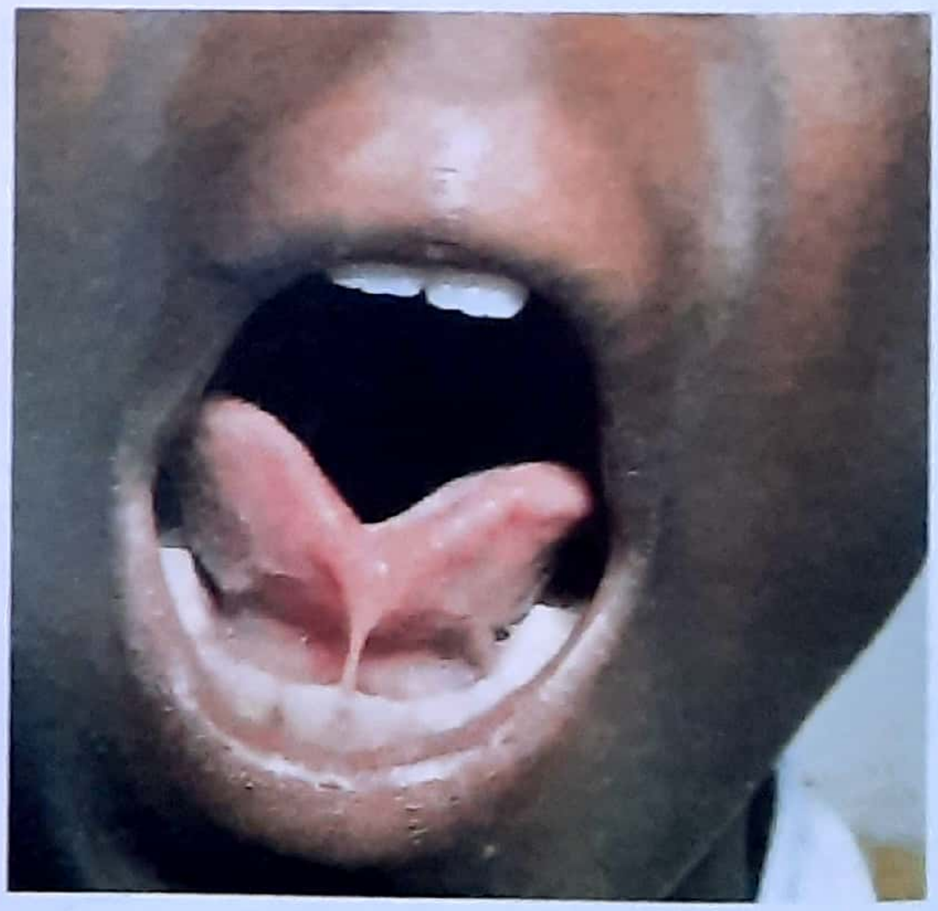

Figure 15.6: Tongue tie

Causes

1. Lymphangioma

Usually noticed soon after birth as a small localized patch of dilated lymph vessels. It may remain stationary for some period, but quite often increases rapidly and causes macroglossia.

2. Hemangioma or arteriovenous fistula

The tongue may be enormously large in case of AV fistula, and pulsation can be observed and felt.

3. Neurofibromatosis

Usually occurs in association with von Reckling hausen's disease of peripheral nerves.

4. Primary mesodermal amyloidosis.

5. Muscular macroglossia

This condition is found in congenital hypothyroidism (cretinism) and in acromegaly. The protruded tongue is often dry and cracked.

****

HYPERKERATOSIS

Hyperkeratosis occurs when there is excessive keratinization, and a thick layer of keratin is present on the surface of tongue. The **variants are:-**

1. Leukoplakia
2. Speckled leukoplakia
3. Erytheroplakia
4. Hairy leukoplakia

1. Leukoplakia

Leukoplakia is a described as a white hyperkeratotic patch in the mouth (Figure 15.7). It may be described as small circumscribed white patch to an extensive lesion involving wide areas of the oral cavity. *Leukoplakia is most common premalignant lesion of oral cavity* (MANY PGME).

Predisposing factor

[Six'S' + C]

1. Smoking and smokeless tobacco chewing (M/C cause).
2. Sepsis
3. Spices
4. Syphilis
5. Spirits (Alcohol)
6. Sharp edges of tooth
7. Candida infection

Clinical feature

- The patch or plaque is caused by epidermal thickening or hyperkeratosis. The etiology is not absolutely clear, but tobacco chewing and smoking are the most important causes.
- These are commonly found in older people. Common sites of involvement are buccal mucosa, vermilion border of the lip, tongue, hard and soft palate. This is less common in floor of the mouth and other intra-oral sites.
- Human papilloma virus (HPV) may have some role.
- These appear as well demarcated and localized, multifocal or diffuse, leathery discrete areas of mucosal patches. The surface may be smooth, wrinkled, cracked or fissured. The colour may be white, yellowish or grey. The lesions are soft but later thickness and induration gives a firm to very firm feel.
- *In contrast to simple keratosis this condition is irreversible; even when the causative agent is withdrawn.*
- *Malignancy occurs in about 10% cases* (PGME).
- Those with dysplasia & speckled or nodular leukoplakia, are more prone to develop malignancy than the homogeneous type.

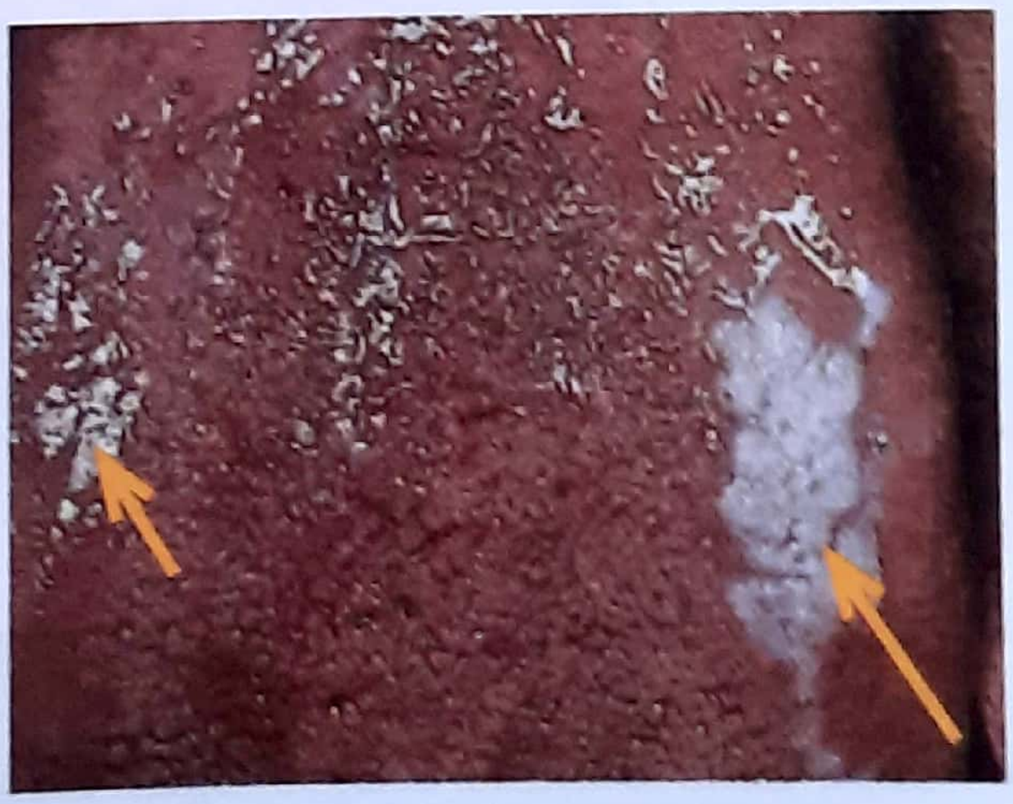

Figure 15.7 (a) : Leukoplakia

Figure 15.7(b) : Speckled leukoplakia on the lateral border of the tongue. Histology confirmed carcinoma in situ

Figure 15.7(c): Erythroplakia of the left soft palate and lateral pharyngeal wall

2. Speckled leukoplakia

When there occurs shedding of keratinized layer at places with several red smooth areas surrounded by whitish condensations with variable degree of dysplasia; the condition is called as speckled leukoplakia.

- Small hyper keratotic patch should be excised.
- Large patches should be examined time to time.
- When biopsy report shows severe dysplasia or Ca-in-situ, surgical excision or carbon dioxide laser excision of the lesion is mandatory.

3. Erythroplakia

- When in speckled leukoplakia, which is a combination of red and white lesions, the red areas are predominant component, the condition is known as erythroplakia.,
- Malignant transformation occurs in more than 50%.
- *The risk of malignant change in erythroplakia is 17 times more than leukoplakia* (MANY PGME).

4. Hairy Leukoplakia

- This is a condition with characteristic corrugated or hairy surface resulting from marked epithelial thickening (acanthosis) and hyperkeratosis. The lesion constitutes white patches occurring anywhere on the oral mucosa.
- This occurs virtually only in patients with AIDS.

Management of a case of leukoplakia

- Remove the predisposing cause such as smoking and alcohol intake.
- Biopsy should be taken for histopathological examination.

****

ORAL SUBMUCOUS FIBROSIS

This is a slowly progressive lesion usually appearing in middle aged persons addicted to betel nut, pan leaf, tobacco. This is practically a disorder of the Indian subcontinent.

Figure 15.7(d) : Oral submucous fibrosis of the right buccal mucosa and soft palate

Etiopathogenesis

Etiopathogenesis is not clear. But a hypersensitive reaction to chewed betel nut, tobacco, chilli and vitamin deficiencies have been attributed to the condition. Experimentally, it has been observed that alkaloids in betelnut particularly:

(i) *Arecoline* stimulates collagen synthesis and results in proliferation of fibroblasts in the buccal mucosa, and

(ii) *Tannin* stabilizes the collagen fibrils and also makes them resistant to degradation by collagenase.

Clinical feature

- The resultant submucosal fibrosis occurs **deep** to the mucosa *(hence submucous)* of cheek, palate, tongue and gingivae (gum).
- A mottled or marble pallor of the mucosa appears due to the collagen deposition in the submucosa.
- *Bands of fibrous tissue* developing deep in the submucosa, *which limit jaw and tongue movement.* (AIIMS 01).
- *The earliest symptom is burning sensation in mouth and discomfort on eating spicy food* (MANY PGME).
- *Submucous fibrosis is a premalignant condition for development of squamous cell carcinoma of oral cavity* (MANY PGME)

Treatment

- Treatment aims at prophylaxis (abstinence from tobacco, betel nut and spicy food).
- *Intralesional injection of steroid may be helpful* (PGME)
- In advanced cases surgical excision of the fibrous band and grafting may be helpful in opening the mouth, but this does not prevent the onset of malignancy (squamous cell carcinoma) in atrophic oral mucosa.

****

ULCERS OF TONGUE

The causes of ulcers on the tongue are :

1. Traumatic (dental) ulcer.
2. Apthous (dyspeptic) ulcer
3. Herpetic ulcer
4. Tubercular ulcer
5. Syphilitic ulcer
6. Malignant ulcer

These have been described earlier in this chapter.

****

CARCINOMA OF THE TONGUE

Tongue lesions account for about 15% of all head and neck tumours.

Etiology

1. Carcinoma of tongue usually affect middle aged or elderly people and majority being more than 50 years.
2. Men are affected more commonly than women (male, female ratio being 4 : 1).
3. **Predisposing factors**

   These are 6'S's: **Smoking** (NEET), syphilis, sharp tooth, sepsis, spirit (alcohol), spices.
4. **Premalignant conditions** (MANY PGME)

   (a) Highly potential
   - Leukoplakia
   - Erythroplakia (17 times more than leukoplakia)
   - Chronic hyperplastic candidiasis.

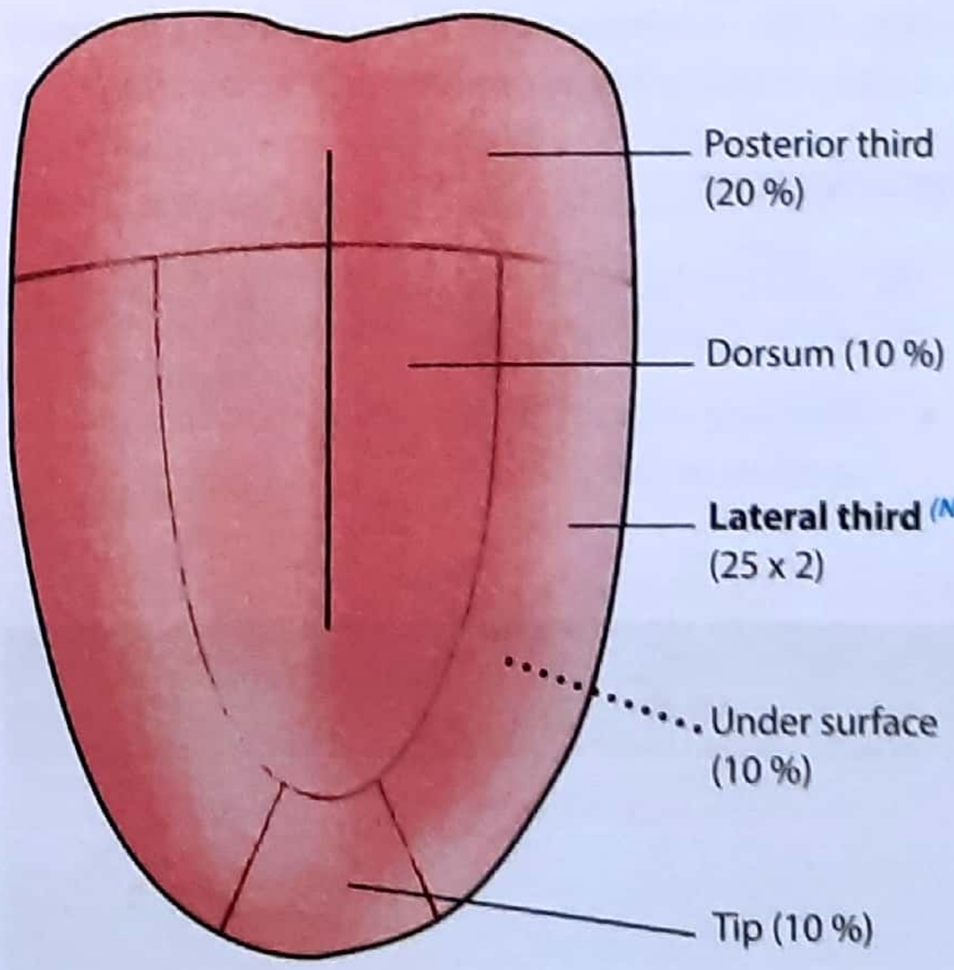

Figure 15.8: Showing distribution of Ca tongue

(b) *Moderate*

- Oral submucous fibrosis
- Syphilitic glossitis
- Sideropenic dysphagia (Plumer vinson syndrome)
- Papilloma of tongue and cheek

(c) *Doubtful*

- Oral lichen planus
- Discoid lupus erythematosus (DLE)
- Dyskeratosis congenita

Site

The majority of tongue cancers (about 50%) occur on the middle third of the lateral margins (AT 88, MANY TIMES). Please see figure 15.8 & 15.9.

- Approximately 25% occur on the posterior third of the tongue, 20% on the anterior third and very few (4%) on the dorsum. (Figure 15.8)
- In India; it is twice as common in posterior third due to extensive tobacco chewing.

Pathology

- Microscopically four types of tongue cancers are seen: *Ulcerative, warty growth, Fissure or as a indurated plaque.* Ulcerative type is most common variety. Please see key box 15.2.
- *Histologically, this is a* ***keratinizing squamous cell carcinoma*** (NEET, AIIMS 92). The carcinoma in posterior one-third is transitional cell epithelioma or rarely may be basal cell type or adenocarcinoma.

Clinical feature

1. *The commonest complaint is a painless mass or ulcer on the surface of tongue.* (MANY PGME)
   - Pain may occur later, due to local infiltration, ulceration or infection.
   - Patient may complain of pain in the ipsilateral ear due to the involvement of lingual nerve, referred through auriculotemporal nerve, as both of them are branch of mandibular nerve (PGI 98).
2. *Dysphagia:* Due to ankyloglossia and mechanical disadvantage
3. *Excessive salivation*
4. *Fetor in breath:* Bad breath is mainly due to necrosis and infection.
5. *Voice change:* This is due to involvement of the larynx or mechanical obstruction produced by posterior cancer.
6. *Broncho pneumonia:* Occurs due to inhalation of infected material.
7. *Lump in neck:* due to enlarged lymph node.

KEY BOX 15.2
Types of CA Tongue
• Ulcerative (M/C Type)
• Warty growth
• Fissure
• Indurated plaque

Spread

1. Lymphatic spread

Lymphatic spread is **early** (AIIMS 94)

(i) From the tip to the submental group on both sides (passing through the floor of the mouth) and also to the **jugulo-omohyoid group.**

(ii) From the anterior two-thirds to the submandibular group.

(iii) From the posterior third to the jugulo-digastric group and rarely to jugulo-omohyoid group.

(iv) The central lymphatics from either side of the median raphe to the **jugulo-digastric group**.

2. Blood spread

Very rare and occurs extremely late. It is only seen when the growth is in the extreme posterior part of the tongue.

TNM staging of oral cavity carcinoma

Primary tumour (size)

T_0 - No evidence of primary tumor

T_{is} - Carcinoma in-situ

T_1 - Tumor ≤ 2cm, ≤ 5mm depts of invasion (DOI)

T_2 - Tumor >2cm & <4cm in greatest dimension & DOI >5cm and <10mm.

T_3 - Tumor > 4cm in greatest dimension or any tumor > 10mm DOI

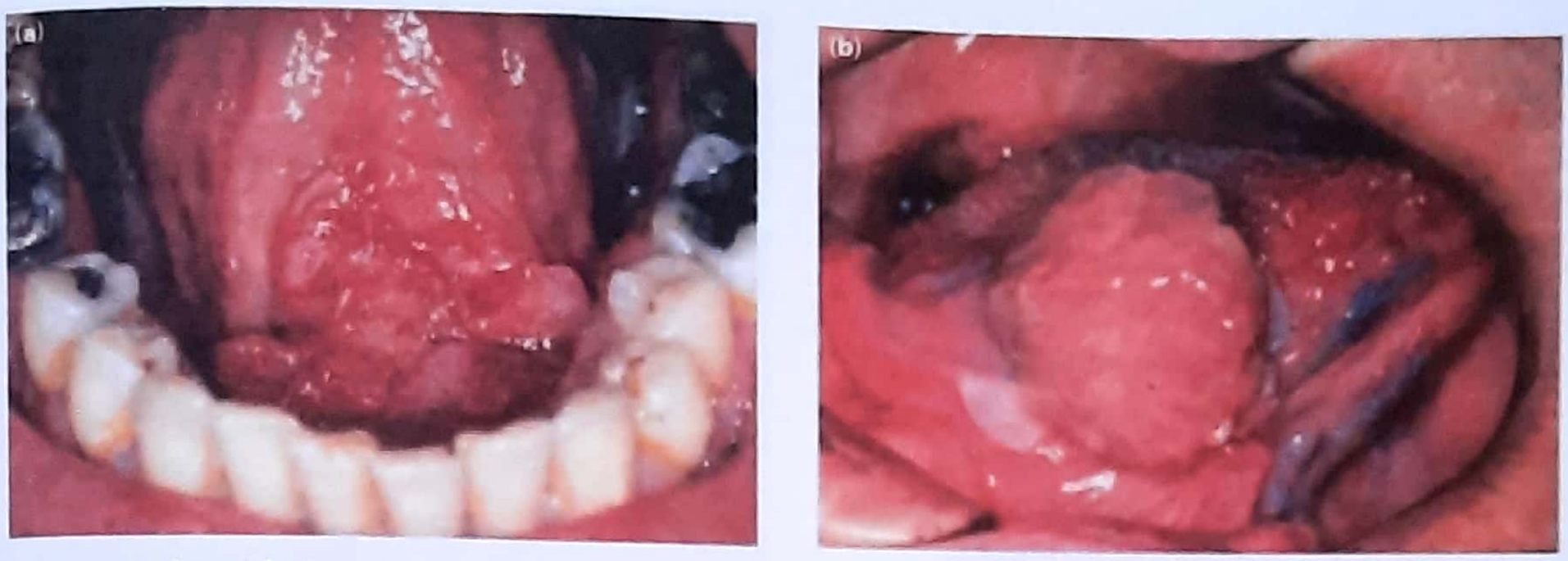

Figure 15.9 : **(a)** Ulcerative squamous cell carcinoma of the anterior floor of the mouth. **(b)** Exophytic squamous cell carcinoma of the right lateral border of the tongue.

T_4a (lip) - Primary tumor invading cortical bone, inferior alveolar nerve, floor of mouth or skin of face (e.g. - nose or chin).

T_4a (oral cavity) - Tumor invades adjacent strictures (cortical bone, into deep tongue musculature, maxillary sinus) or skin of face.

T4b (lip & oral) - Tumor invades masticator space, pterygoid plates, or skull base &/or encase the internal carotid artery.

Nodal involvement

Nx - Unable to assess regional lymph nodes

No - No evidence of regional metastases

N_1 - Metastasis in single ipsilateral LN ≤ 3cm in greatest dimension

N_2a- Metastasis in single ipsilateral LN >3cm & ≤ 6 cm.

N_2b- Metastasis in multiple ipsilateral LN all nodes ≤ 6 cm.

N_3a- Metastasis in a LN >6cm in greatest dimension & extranodal extension (-)

N_3b- Metastasis in any nodes with clinically overt extranodal extension present.

Staging

I	T_1 NoMo
II	T_2 NoMo
III	T_3 NoMo or T_1, T_2, T_3 , N_1, Mo
IV A	T_4a , No, 1 Mo or T_1, T_2, T_3 , 4a, N_2, Mo
IV B	Any T N3 Mo or T4b Any N Mo
IV C	Any T, Any N, M1

INVESTIGATION

When a clinical diagnosis of oral cancer is suspected, a comprehensive protocol of investigations should be instituted. A tissue diagnosis, typically by way of incisional biopsy, is essential.

Radiography

Plain radiography of the jaw is undertaken to facilitate adequate dental assessment rather than as a means to assessed for evidence of bone invasion.

Magnetic resonance imaging

The investigation of choice for cancer of the oral cavity, oropharynx and neck, will vary depending on institution protocol, resources and local expirtise. CT and MRI are both viable alternatives; however, MRI suffers less degredation by metallic dental restorations and provides excellent visualisation of soft-tissue infiltration of the tumour. Ideally it should be performed before diagnostic biopsy as biopsy frequently distorts the image of the primary tumour.

Computed tomography

CT is much more widely available than MRI but its utility may be restricted by artifact degredation of images by dental restorative materials. It is useful when bony invasion is suspected.

Positron emmission tomography combined with CT

Positron esmission tomography combined with CT (PET-CT) of the whole body uses the anatomical capabil-

ity of CT scanning in concert with radiolabelled tracers capable of localising to specific tissues.

Ultrasound

Ultrasound has become an integral part of head and neck services, particularly in association with one-stop clinics for the evaluation of undiagnosed neck lumps or presumed cervical metastasis. Used alongside fine-needle aspiration cytology (FNAC), ultrasound is capable of delineating and sampling cervical lymphadenopathy and both thyroid and salivary gland lesions/masses.

Fine-needle aspiration cytology

FNAC is useful for the assessment and pathological diagnosis of enlarged cervical lymph nodes.

Radionucleotide studies to assess bone invasion

A radioisotope bone scan of the facial skeleton adds little to the diagnosis and assessment of head and neck cancer, beyond that of clinical assessment, MRI and/or CT, and plain imaging.

Treatment

A. FOR ANTERIOR *2/3* OF TONGUE

Stage I (Tumour size less than 2 cm)

- These are treated by either, radiotherapy or surgery.
- *Lesions less than 2cm is treated with interstitial radiotherapy with Iridium^{192} wire or cesium^{137}.* (AIIMS 02)
- *Small carcinoma of less than 1 cm confined to the lateral border may be removed by local excision with a 2 cm margin of normal tongue.* (PGME)

Stage II (Tumour size between 2-4 cm)

- *Primary lesion; larger than 2 cm is usually treated with external beam radiation.*
- Surgery may be required, if there is failure of radiotherapy or due to its non availability.

Very important

Stage I & II (T_1, T_2) lesions are managed equally well by surgery or radiotherapy. Therefore; considerations like post operative disfigurement, loss of function, fitness for surgery, availability or non availability of radiotherapy influences the choice of therapy.

KEY BOX 15.3

Clinical features of oral cancer that warrent investigation

- Persistent oral swelling for >3 weeks
- Mouth ulceration for >3 weeks
- Sore tongue
- Difficulty swallowing
- Jaw or facial swelling
- Painless neck lump
- Unexplained tooth mobility
- Trismus

Stage III (Size more than 4 cm with lymph-node positive)

- Stage III lesion requires wide surgical excision; ie; a **composite resection involving the primary tumour, and half of mandible with lymph node is done; (commando operation).** (NEET, PGME)
- For very large lesions; radiotherapy can give reasonably fair results.

Stage IV (Metastases)

These lesions may be treated by preoperative radio-therapy of both primary and the neck node and 6-7 week later resection is carried out. Neck dissection may also be required.

B. FOR TUMOURS OF POSTERIOR 1/3

Early lesions tend to remain silent and when they are diagnosed, it is already much advanced (stage III/IV). **Radiation therapy is the treatment of choice** and along with primary lesions, both side of neck is usually irradiated.

****

NOTES :

Sample Questions for Prof Examination

1. Describe the etiopathology, clinical features, investigations and management of carcinoma of tongue.
2. Describe the etiology, pathology, clinical features and management of carcinoma cheek.
3. Write short notes on:
   (i) Submucous fibrosis
   (ii) Erytheroplakia
   (iii) Ranula

16 Cleft Lip and Palate

Contents

- Cleft lip
  - Classification
- Cleft Palate
  - Classification
- Treatment of cleft lip and palate
- Complication due to cleft lip and palate

CLEFT LIP AND PALATE

Cleft lip and palate is a gap in the lip; mostly congenital but may be acquired due to trauma.

Incidence

- The incidence of cleft lip and palate is 1 in 600 live births, and isolated cleft palate in 1 in 1000 live births.
- The typical distribution of cleft type is: *(AIIMS 91)*
  1. Cleft lip alone - 15%
  2. Cleft lip and palate - 45%
  3. Isolated cleft palate - 40%
- Cleft lip/palate predominates in males, where as cleft palate alone appears more common in female.
- *Isolated unilateral cleft lip deformity is more common on the left side (60% of cases)* *(PGI 80)*

Etiology

- A family history of cleft lip and palate, in which the first degree relative is affected, increases the risk to one in 25 live births.
- **Maternal age:** child born at the late age of the mother are prone to suffer from congenital disorder.
- These defects may be caused by maternal diseases during pregnancy. Other predisposing factors may be:
  1. Vitamin deficiency (A, B) during pregnancy
  2. X-ray exposure
  3. Rubella infection

Figure 16.1: Unilateral Cleft Lip

- Excess corticosteroids intake during pregnancy.
- This disorder is more common in newborns, born to a diabetic mother.
- Certain endocrine disorder.
- Some congenital syndrome are associated with this condition. In ***Pierre Robin syndrome,*** (AIIMS 85) there is isolated cleft palate, retrognathia and posteriorly displaced tongue (glossoptosis). Posteriorly displaced tongue (glossoptosis) leads to respiratory obstruction.

Development (AIIMS 85)

The **cleft (hare) lip** (NEET) **occurs *due to failure of fusion* between the maxillary process of one side (forming the lateral parts of lip) and medial nasal process** (forming the central area or 'Philtrum'). The nasal deformity usually accompanies the cleft lip in form of a broadened and depressed nostril.

The **cleft palate** occurs *due to failure of* palatal processes of maxilla to fuse with each other and with the pre-maxilla (developed from the medial nasal process) (PGME).

- The deformity may be associated with other congenital anomalies eg; hydrocephalus, congenital blindness, and-mental deficiency.

Classification

1. Central cleft

It is exactly central and very rare. It is due to failure of fusion of two globular processes derived from the median nasal process.

2. Lateral cleft

This is common type. This is due to failure of fusion between the median nasal process and the maxillary process. The cleft is between the philtrum and the lateral part of upper lip. This can be further divided in:

(a) **Unilateral or bilateral:** *Left side is more common.* (PGI 80)

(b) **Complete or incomplete (Partial):** when the cleft extend in the nostril it is called as complete.

(c) **Compound:** When cleft lip associated with a cleft in alveolus.

(d) **Complicated:** when cleft lip is associated with a cleft in the palate.

****

CLEFT PALATE

Cleft palate is **gap in the palate,** mostly congenital.

Incomplete

1. Bifid uvula: Cleft of the uvula only.
2. Cleft of the soft palate along its entire length.
3. Cleft of the whole length of the soft palate and the posterior part of the hard palate. This is also known as intra-maxillary cleft palate and is due to a failure of fusion of the palatine process. (Figure 16.2)

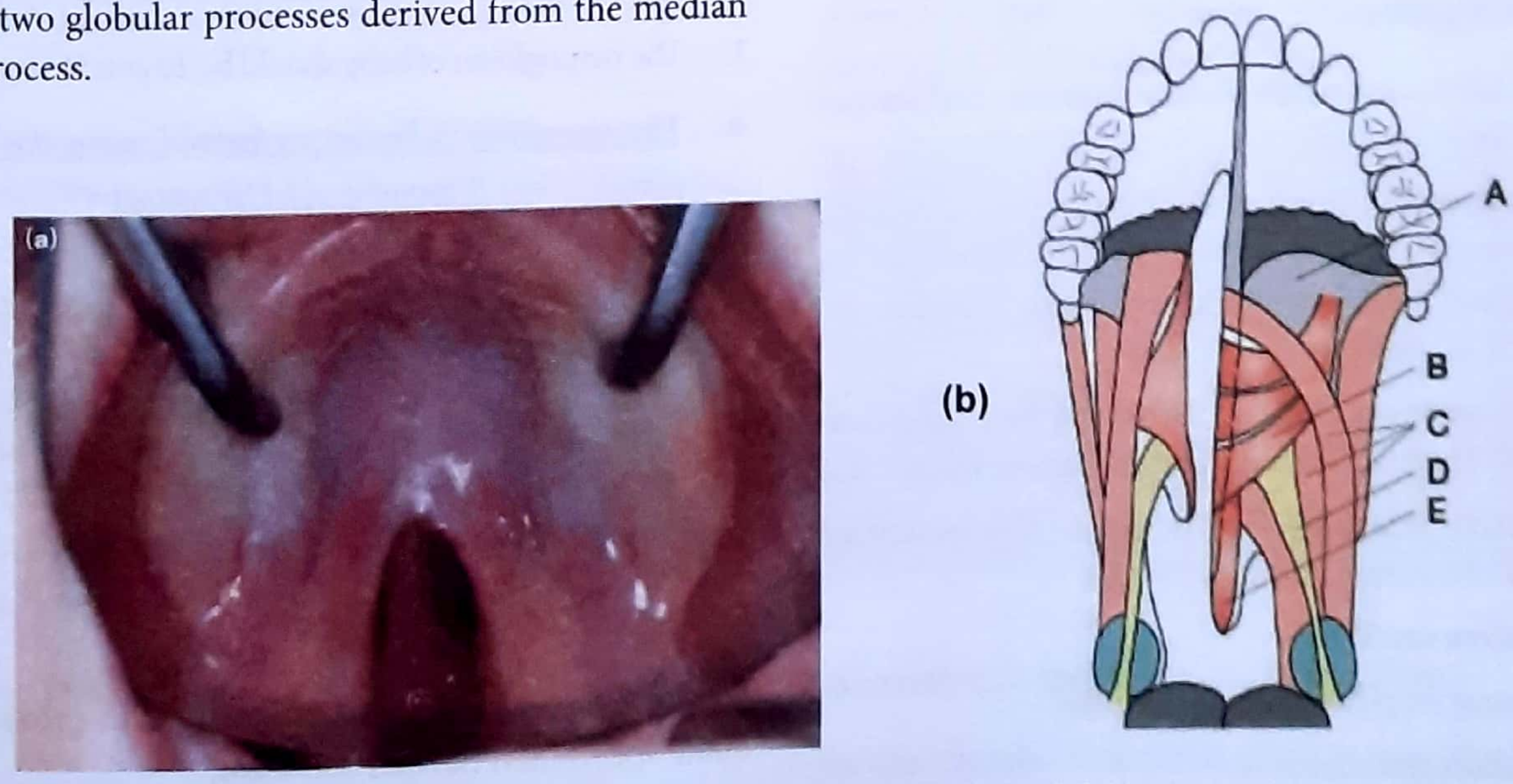

Figure 16.2 : **(a)** Cleft of soft palate and incomplete cleft of hand palate. **(b)** Muslces of the soft palate; left, cleft palate; right, normal anatomy. A, tensor palati; B, levator palati; C, palatopharyngeus; D, palatoglossus; E, musculus uvulae.

Figure 16.3 (a) : Bilateral cleft lip

Figure 16.3 (b) : Left side cleft lip & alveolus

Complete

Cleft on the soft palate and whole length of the hard palate, so that nose and mouth are one cavity. It is due to failure of fusion between the palatine processes and the premaxilla.

Problems

Due to cleft lip

1. Ugly looking face
2. Defective sucking
3. Defective dentition
4. Defective speech particularly with the labial letters B, F, M, P, V,W.
5. Complete cleft lip leads to misshaped development of nose.

Due to cleft palate

Problems due to cleft palate is more common and serious than cleft lip

1. **Defective suction:** for effective suction a vacuum (or negative pressure) is necessary inside the mouth, which can not be created due to a gap between oral cavity and nasal cavity.
2. **Defective speech:** particularly with the palatal consonant. There will be nasal intonation in voice.
3. **Defective hearing;** This is due to the associated edema of internal auditory meatus
4. **Defective smell**
5. Recurrent respiratory tract infection.
6. Aspiration pneumonitis.
7. **Defective dentition**, because of irregular development of alveolus.

Treatment of Cleft Lip

Aim of Operation

Mainly for cosmetic reason and also for functional recovery.

Timing for operation *(AI 98, 98, MANY PGME)*

The operation on cleft lip should be performed within 6 months from birth, ie. before the primary dentition appears. Otherwise, the defective dentition, if develops, is difficult to correct.

Rule of 10' *(Millard) is usually followed, which means, that* ***at the time of operation:***

1. Age of baby should be ***10 weeks*** or more.
2. The weight of the baby should be *10 lbs (4.5 kgs)*
3. The hemoglobin of baby should be *10 gms %.*

- *The operation is better performed when the child is about* 2.5 *to 3 months old (10 weeks)* *(NEET, PGME MANY TIMES)*
- Various operation done for cleft lip are shoog, Tennison, Millar, LeMesurier etc.
- *Repair of cleft lip is always done earlier than the cleft palate because of moulding effect of intact lip on the growing alveolus,* *(MANY PGME)*

Treatment of Cleft Palate

The **aim of treatment** of cleft palate is to provide adequate speech and normal dentition.

KEY BOX 16.1		
TIMING OF PRIMARY CLEFT LIP AND PALATE PROCEDURES		
Cleft lip alone		
Unilateral (one side)	One operation at 5-6 months	
Bilateral (both sides)	One operation at 4-5 months	
Cleft palate alone		
Soft palate only	One operation at 6 months	
Soft and hard palate	Two operations	Soft palate at 6 months
		Hard palate at 15-18 months
Cleft lip and palate		
Unilateral	Two operations	Cleft lip and soft palate at 5-6 months
		Hard palate and gum pad with or without lip revision at 15-18 months
Bilateral	Two operations	Cleft lip and soft palate at 4-5 months
		Hard palate and gum pad with or without lip revision at 15-18 months

Timing of cleft palate operation *(AIIMS 98)*

The optimum time for cleft palate repair is between 14 to 18 months i.e.: before the child starts speaking, because once the child has learn to speak, it is very difficult to correct nasal intonation.

Recently many plastic surgeons has started doing repair a bit earlier ie. **between the age of 9 months and 1 year**, *(NEET)* because a child starts making efforts to speak at that age.

It is advocated that early repair of the cleft of hard palate may cause maldevelopment of the maxillae, which will be evident in later life. So, the ideal treatment should be early repair of soft palate only, before the child starts speaking ie; at 6 months of life. Closure of hard palate defect should be postponed until the facial development, ie; 15-18 months of life. Please read key box 16.1.

LAHSAL System of Classification of Cleft lip & palate *(NEET)*

In this system, month is divided into 6 parts - i.e., LAHSAL

L - Right **L**ip
A - Right **A**lveolus
H - **H**ard Palate
S - **S**oft Palate
A - Left **A**lveolus
L - Left **L**ip

Complete cleft is indicated with a capital letter & incomplete cleft with small leter.

L	Right Lip
A	Right Alveolus
H	Hard Palate
S	Soft Palate
A	Left Alveolus
L	Left Lip

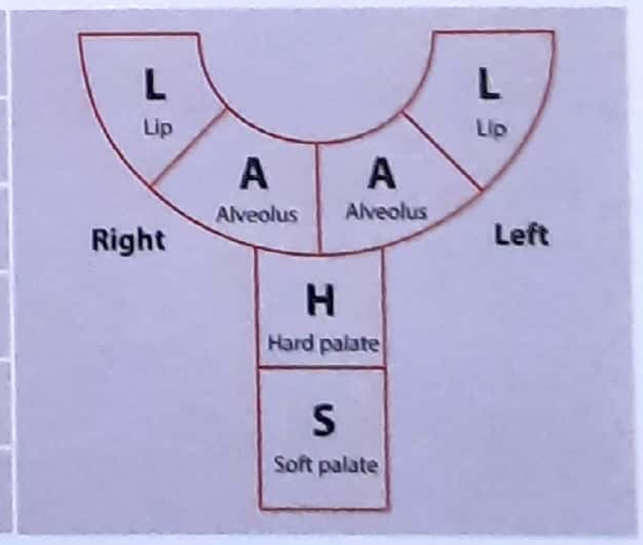

Kernahan's striped Y classification -

In this, Incisive foramen is taken as reference.

****

17 The Gums and Jaws

Contents

- Epulis
- Alveolar abscess
- Osteomyelitis of jaw
- Jaw Tumours
  - Dental cyst
  - Complication due to cleft lip and palate
  - Dentigerous cyst
  - Primordial cyst
  - Adamantinoma
  - Malignant ameloblastoma
  - Giant cell reparative granuloma
  - Giant cell tumour (osteoclastoma)
  - Bone cyst
    - Aneurysmal
    - Simple
  - Chondroma
  - Torus
  - Fibrous *dysplasia*

JAW SWELLINGS

Swellings of the jaws are caused by numerous lesions and may arise from the (i) mucoperiosteum or (ii) from the tooth germs or (iii) from the bones. Some common jaw swelling are discussed here.

EPULIS

- Epulis is a Greek word and means 'upon the gum'.
- It is a swelling *situated upon the gum and arises from the alveolar margin of the jaw* (NEET, PGI 99). It can oriinate from the mucous membrane, periosteum or bone. Figure 17-1.
- True epulides are growths, arising from the gum, where as false epulides occur due to hyperplasia of the gum following chronic irritation, eg; granulomatous epulis.

Epulis are of 4 type

Types

1. Fibrous (true) epulis

- This is **commonest type;** arising from periodontal membrane and presents under gum.
- It is small (1cm) soft, red and smooth at the onset.
- As it progresses, it becomes firm and pink due to more collagen deposition in the epulis.
- It may be pedunculated or sessile.

Figure 17.1: Epulis (a swelling upon gum)

- A rapid growing sarcomatous transformation can occur, called as sarcomatous epulis and should be differentiated from fibrous epulis.
- Treatment is by complete excision.

2. Myeloid or giant cell epulis

Myeloid epulis is much less common than fibrous epulis.

There are two views about it's origin:

(i) It is an osteoclastoma arising in the peripheral part of jaw.

(ii) It is an inflammatory hyperplasia due to local irritation.

- Giant cell epulis is rapidly growing, soft and vascular.
- Excision of growth with a wedge of bony margin is advised.

3. Granulomatous epulis

It is not a true epulis. In fact it is a slow growing localized collection of granulation tissue around a carious tooth, or at the site of continuous irritability by a denture.

- It is of the same colour as that of the gum, and is frequently found between two teeth.
- It should be excised and associated dental sepsis should be treated.
- *Pregnancy epulis* (Gingivitis gravidarum) is a variant of this condition. In addition to local irritation, hormone influence is a probable cause.

4. Carcinomatous epulis

- This is actually squamous cell carcinoma (epithelioma) of the gum arising from the mucosa of the alveolar margin.
- This is a painful, infected and infiltrating lesion to start with, which later becomes frankly fungating and ulcerating and invades bone. Cervical lymph node are often enlarged.

****

INFLAMMATORY CONDITIONS OF JAW

Alveolar Abscess

- The teeth are often the seat of infection originating from dental caries, later affecting the pulp space and root.
- Alveolar abscess may result from a infected dental pulp. The pus collects into the adjacent soft tissue and points towards labial or buccal sulcus. Figure 17.2
- The condition is revealed by pain and the onset of a localized swelling called as gum boil.
- It is a very painful condition.
- Treatment consist of extraction of the tooth with antibiotics.

Osteomyelitis of Jaw

In osteomyelitis of the jaws; it is the mandible which is involved more commonly than the maxilla.

Etiology

- Most common organism is *Staphylococcus.*
- Due to neglected alveolar abscess.

Figure 17.2: Alveolar abscess

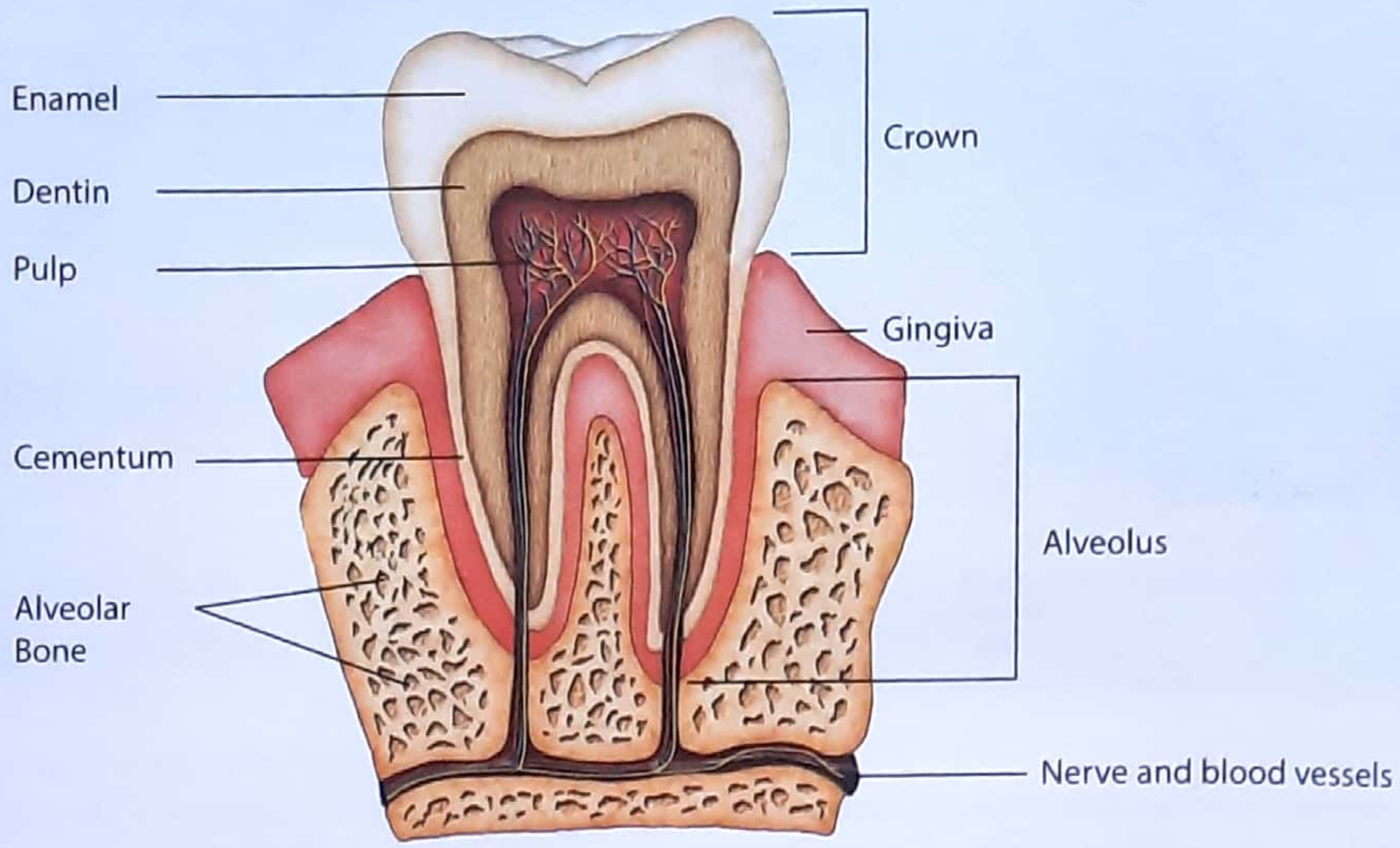

Figure 17.3: Anatomy of a tooth

- Following dental extraction, when done during acute inflammation.
- Compound fracture of mandible.
- Following radiotherapy
- Phosphorus poisoning
- Chronic infection such as tuberculosis, Actinomycosis.

Clinical feature

- There is severe deep seated pain, with facial edema and induration over the affected area
- A discharging sinus fixed to bone can be seen.
- Numbness of chin in the distribution of mental nerve may be present. This is due to compression of mental nerve.
- Submandibular lymph node may be enlarged and there is moderate pyrexia.
- However, the patient is never so ill as that a patient with osteomyelitis of long bone.

Treatment

A suitable antibiotic should be given with sequestrectomy (removal of dead, diseased bone). If there is sinus formation it should be explored.

****

JAW TUMOURS

Jaw tumour can be divided; as central (expanding) or peripheral. See key box 17.1, on next page and go through it 3 times; before moving forward.

1. CENTRAL (EXPANDING) JAW TUMOURS

When both the surfaces of jaw are involved. It is further divided as following for discussion purpose.

(A). ODONTOGENIC TUMOURS

Arising from epithelial remnants of tooth forming organs.

1. Benign Odontogenic Swelling

These are as following:

(i) Radicular Cyst (Dental cyst, periapical cyst, periodontal cyst)

- Radicular cysts derive their epithelium from odontogenic remnant in the periodontal ligament and are a result of chronic inflammation.
- **The inflammation is usually a result of pulp death, and therefore the cysts are commonly found at the apices of teeth (apical cysts).** (NEET) See figure 17.3.

KEY BOX 17.1

JAW TUMOUR

JAW TUMOUR

1. CENTRAL (EXPANDING)

(When both surfaces of the jaw involved)

A. Odontogenic

(epithelial lining is derived from epithelial remnants of tooth forming organ)

Benign (Odontomes)

1. Dental cyst (Radicular periapical cyst)
2. Dentigerous cyst (Follicular odontome)
3. Primordial cyst. (Odontogenic keratocyst)
4. Adamantinoma (Ameloblastoma)

Malignant

1. Malignant Ameloblastoma
2. Ameloblastic fibrosarcoma

B. Non odontogenic

(lining is derived from sources other than tooth forming organ)

Benign

1. Giant cell reparative granuloma
2. Giant cell tumour (osteoclastoma)
3. Bone cyst
   a. Aneurysmal
   a. Simple

Malignant

1. CA maxillary antrum

2. PERIPHERAL

(Only one of the surface is involved)

Benign

- Osteoma
- Chondroma
- Torus

Malignant

- Osteosarcoma
- Chondrosarcoma
- Carcinoma of the jaw

- Radicular cysts may persist following extraction of the offending tooth, when they are called residual cysts.
- Radicular cysts are the commonest cystic lesion in the jaw and account for over half of all jaw cysts *(PGME)*.
- The peak frequency is in the fourth decade.
- Approximately 60% are found in the maxilla especially associated with anterior teeth.
- They may present as slowly enlarging swellings.
- Egg shell cracking may be elicited when the cortical bone is grossly thinned. Occasionally, a sinus may be present discharging into oral cavity or outside the skin. Radicular cysts are rare in deciduous teeth.

Radiographs

The cysts appear as round or ovoid radiolucencies with a sclerotic margin. Cysts are lined by non-keratinized stratified squamous cell epithelium supported by a chronically inflamed capsule.

Histology

Cholesterol crystals may be seen within the fibrous capsule. The cyst content vary from a straw coloured fluid to a cheesy brownish paste.

Treatment

Treatment is by removing the inflammatory source by root canal filling, or extraction of the offending tooth and enucleation of the cysts.

(ii) Dentigerous cyst (Follicular odontome or cyst)

- The dentigerous cyst, also known as the follicular cyst is defined, as a cysts which envelops the whole or part of the **crown of an unerupted tooth** *(NEET, PGME)* which is displaced deeper by cysts preventing its eruption *(AI 88)*. See figure 17.4.
- They occur at any age but have the highest incidence in the third and fourth decades and are more common in men than women.
- The cysts are twice as common in the mandible as in the maxilla and most frequently involve those teeth which are impacted or erupt late. The majority are associated with *mandibular (lower) third molars and* they may be associated with supernumerary teeth.

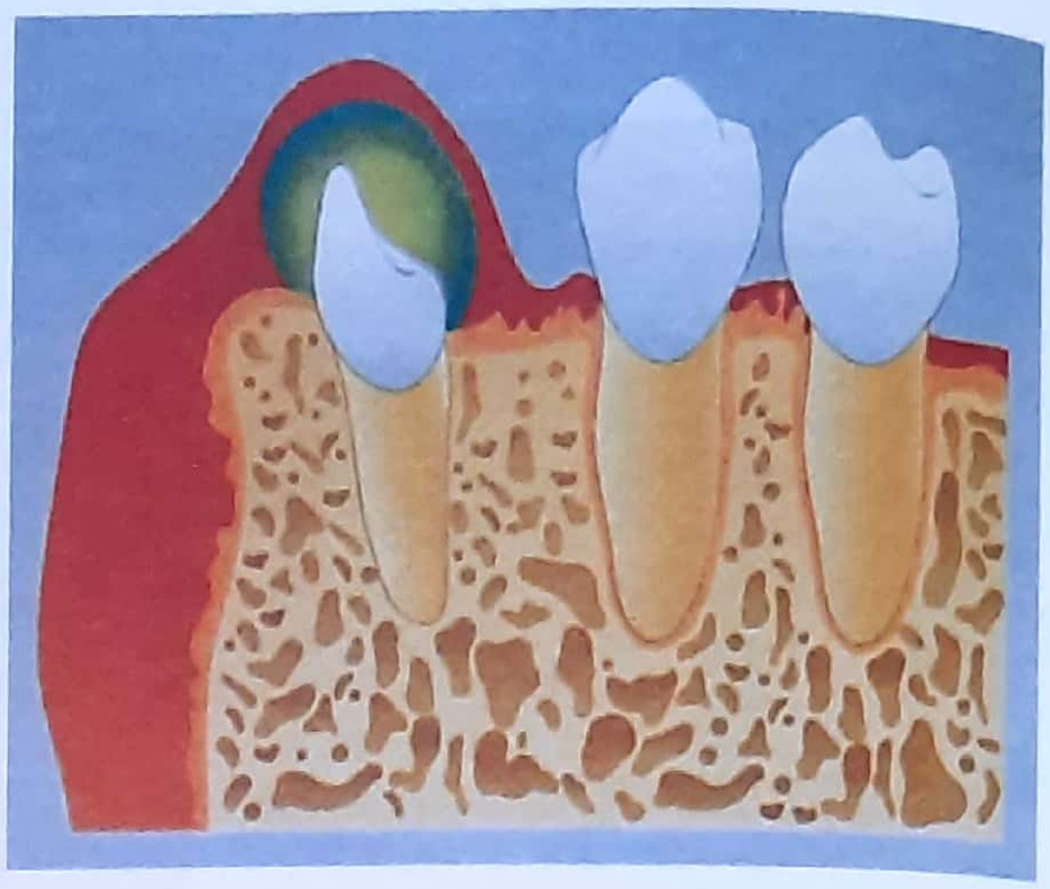

Figure 17.4: Dentigerous Cyst

- The majority are discovered on routine dental radiographs, taken because of missing tooth. Otherwise
- They escape detection until they have enlarged sufficiently to produce expansion of jaw.
- Pain is usually not a feature; unless the cyst becomes infected.

Treatment

In a growing child dentigerous cysts require early intervention as these cysts grow rapidly in children, and because the involving tooth should be given the chance to erupt. The best results are obtained with marsupialization, as enucleation may lead to damage to the involved tooth. In adult the tooth is unlikely to erupt and therefore enucleation, together with removal of the associated tooth is the preferred option.

(iii) Odontogenic Kertocysts (primordial cyst)

It is a relatively uncommon cyst, arises from the remnants of the dental lamina. The term keratocysts is used to include all cysts with significant degree of keratinization. Odontogenic keratocysts have a bimodal age distribution with the first peak in the second to third decades, and the second peak in the fifth to sixth decades.

- Odontogenic keratocysts are twice as common in men as in women. Approximately three quarters of keratocysts arise in the mandible and the majority of these are found at the angle of mandible. They can however, occur any where in the maxilla and mandible.

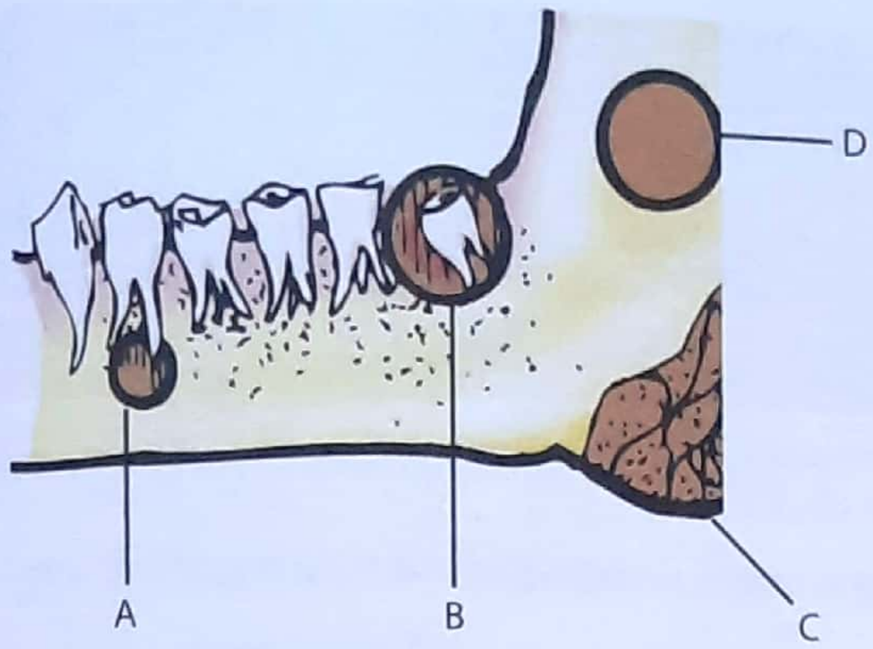

Figure 17.5: (A) Dental cyst (B) Dentigerous cyst (C) Adamantinoma (D) Solitary bone cyst

- The majority of the cysts are symptomless and are found on routine radiological examination. When the cyst is large, the mandible is weakened and a pathological fracture may result.
- In large cysts, teeth may be displaced and rarely cause proptosis and diplopia. The cysts tend to grow in an anteroposterior direction within the medulla of the bone causing bony expansion, only in the later stage.
- An important clinical feature of kertocysts is **their tendency of recur after surgical treatment**. *(NEET)* The recurrence rate has been reported from 10-60%.
- Locally aggressive.

Treatment

At present, there is significant controversy about the optimum treatment of odontogenic keratocysts. Various modalities include:-

1. Conservative approach
2. Careful enucleating of the cyst in one piece.
3. If there is any doubt about the adequacy of the enucleation, then an osteotomy should be carried out.
4. Radical excision should be reserved for those cases which have breached the lower border of the mandible, or those which involve the condyles and those which have undergone ameloblastic change or transformed to a carcinoma.

(iv) Adamantinoma (Ameloblastoma, fibrocystic disease of jaw, eve's disease)

Ameloblastoma is a benign but locally invasive neoplasm. The exact origin of the neoplastic epithelium is unclear although the strong resemblance to ameloblasts supports an odontogenic origin. The predominant opinion is that it is derived from the remnants of the dental lamina *(PGME)*.

Clinical features

- *Ameloblastoma is the most common solid odontogenic tumors;* but only account for approximately 1 % of all oral tumour.
- They are usually diagnosed in the fourth and fifth decades.
- About 70% of the tumour occur in the mandible, of which three-quarters are in the molar region & the ascending ramus, 20% in the premolar region, and 10% in the incisor region.
- Ameloblastoma are slow growing and usually asymptomatic in the early stages.
- As the lesion enlarges it cause bony expansion which can lead to facial deformity.
- The expansion is bony hard, but in advanced cases egg shell cracking may be apparent due to thinning of the cortical plate.
- Perforation of the cortex and extension into the soft tissues in a feature of advanced disease .
- In the maxilla, expansion is uncommon as the lesion can expand into the maxillary sinus and into the pterygomaxillary space. Other clinical manifestations include loose teeth, ill fitting dentures, malocclusion, ulceration discharge and nasal obstruction.

Radiography

Radiographs appear as multilocular radiolucencies. There may be erosion of adjacent roots.

Histology

There is considerable variation in the histopathology of ameloblastoma and many patterns are described. There appears no difference in clinical behaviour between the various histological types: They are -

1. Follicular
2. Plexiform
3. Acathomatous
4. Basal cell
5. Granular

Treatment

Simple curettage is not sufficient; and recurrence rates of 50% have been reported with enucleation. *The recommended treatment is radical resection of the affected part of the jaw.* *(MANY PGME)*

KEY BOX 17.2

DIFFERENTIAL DIAGNOSTIC POINTS BETWEEN GIANT CELL TUMOUR, ADAMANTINOMA AND GIANT REPARATIVE CELL GRANULOMA

Feature	Giant cell tumour1	Adamantinoma	Giant cell reparative granulo
Age	Commonly between 30 and 50 years	Commonly between 20 and 30 years	Below 21 years
Sex	More in males	Bom in males and females	Almost equal sex ratio
Rapidity of growth	Comparatively rapid growth	Slow growth	Slow growth
Expansion	Both the inner and outer walls are expanded	Expansion more out-wards	Both wall
Pathological fracture	Not uncommon	Very rare	May occur
Egg-shell crackling	Present	May be present	Present
Sinus/fustula	Rare	Buccal fistula common in later stage	Rare
X-ray appearance	Soap bobble appearance, multiple large cystic areas are present Trabeculations not marked	Small cystic areas with prominent trabeculae; but trabeculation is usu-ally faint	Similar to giant cell tumour
Biopsy	Mostly giant cells in cellu-lar stroma.	Plexiform and alveolar arrangement lined with columnar cell, fibrous and osseous tissue	Mostly connective tissue 'and osteoid tissue with a few giant
Recurrence	Common	Common	
Malignancy	10% cases	Very uncommon	

At this point you are strongly advised to go through key box 17.1; on page 187 once again.

2. Malignant Odontogenic Swelling

(i) Malignant ameloblastoma

- It has been defined as a neoplasm in which the pat-tern of an ameloblastoma and cytological features of malignancy are shown by the primary growth in the jaws or by any metastatic growth.
- Most of them are found in the mandible (80%). The mean age at presentation is 40 years and there is a slight predilection for men.
- Metastases have been reported in lungs, lymph nodes, spleen, kidney and to the lower ribs.
- The recommended **treatment** is radical excision of the primary tumour, together with neck dissection, if there is evidence of neck node involvement.
- Radiotherapy has been used for distant metastases.

(ii) Ameloblastic fibrosarcoma

- The average age at presentation is 30 years and the sex distribution is equal. Over two-thirds are found in the posterior part of mandible.
- Ameloblastic fibrosarcomas present with pain, swelling, paresthesia of the lip, bleeding and ulcer-ation.
- Radiographs show a poorly defined multilocular ra-diolucency with gross thinning of the cortex. Root resorption is common.
- Metastases to neck nodes have been reported.

- Radical surgery should be the primary mode of treatment. Radiotherapy has not been helpful.

B. NON ODONTOGENIC TUMOURS

These tumours originates from sources other than tooth forming organ. Please see key box 17.1; on page 187.

1. Benign Non-Odontogenic Tumours

(i) Giant cell reparative granuloma

- These are tumours conditions, which arise due to peculiar bone reaction to some injury of undetermined nature.
- It is a non-neoplastic condition related to some trivial trauma. It occurs below 21 years of age.
- The swelling occurs both in the upper and lower jaw.
- Most of them occur in the mandible, near the premolar or molar region. The patient reports for a painless, slowly increasing swelling of the jaw. The teeth may be irregular due to malignant.
- The skiagram shows a translucent multicystic area with delicate fibrous septa, the giant cell reparative granuloma is treated by curettage either intraorally or extraorally.

(ii) Giant cell Tumour (Osteoclastoma)

It is a common tumour of the lower jaw. It may involve both the body and ramus of the mandible. When it occurs in the upper jaw the tumour fills the maxillary antrum. It commonly occurs in males between 30 to 50 years. The patient reports for a swelling of the jaw. The tumour may grow fairly rapidly. The egg- shell crackling is present 'in the late stage. Radiography shows the **typical soap bubble appearance** *(PGME)*.

Treatment:

The outer wall of the cavity is removed, tumour is then scooped out. The cavity is curetted. The cavity, when big is filled with cancellous bone grafts.

(iii) Bone cyst

(a) Solitary bone cyst

Solitary bone cysts are non-epithelialized bone cysts seen most commonly in the long bones of children, but occasionally they present in the jaws, almost exclusively in the mandible. They are rare and occur mainly in childhood and adolescence.

Clinical features

Most solitary bone cysts are diagnosed by chance following dental radiographs. Pain is infrequent and very occasionally patient complain of labial paraesthesia.

Radiographs

The cyst appears as an irregular radiolucent area with slight cortication.

The pathogenesis of solitary bone cysts is not known. It has been suggested that trauma is the initiating factor which leads to a blood clot which fails to resolve and forms a cavity. However; in the majority of patients there is no history of related trauma.

Treatment

Although the natural history of the cyst is to resolve spontaneously, surgery is required to confirm the diagnosis. The cyst cavity is opened to confirm its nature, and then tightly packed before closing.

(b) Aneurysmal Bone Cyst

It is a non neoplastic lesion of bone of unknown pathogenesis. The cysts occur predominantly, in **children and adolescents** with the peak incidence in the **second decade.** There is a **female** preponderance. *Approximately 60% are found in the mandible, especially at the angle* *(PGME)*.

The lesion presents as a firm localized swelling which is painful in about half the patients. Extension into soft tissues is rare.

- The radiographic features are not diagnostic as is FNAC. The cyst produce a radiolucent ovoid expansion which is usually unilocular but may occasionally be multilocular.
- A primary lesion of bone initiate an osseous arteriovenous malformation which leads, via its hemodynamic forces, to a secondary bone lesion which is termed an aneurysmal bone cyst.

2. Malignant Non Odontogenic Swelling of Jaw

(i) Carcinoma of Maxillary Sinus

It arises from the sinus lining and may remain silent for a longtime

Clinical features

- Diseases is common in 40-60 age group, with preponderance in males.
- Early features of maxillary sinus malignancy are nasal stuffiness, blood stained nasal discharge, facial paraesthesia or pain and epiphora.
- Late features will depend on the direction of spread and extent of .growth. Medial spread towards nasal cavity gives rise to nasal obstruction, discharge and epistaxis. Anterior spread causes swelling of the cheek and later invasion of the facial skin. Inferior spread causes expansion of alveolus with dental pain, loosening of teeth, poor fitting of dentures, ulceration of gingivae and swelling in the hard palate. Superior spread invades the orbit causing proptosis, diplopia, ocular pain and epiphora. Posterior spread is into pterygomaxillary fossa, pterygoid plates and the muscles causing trismus.
- Lymphatic spread - Nodal metastasis are uncommon and occur only in the late stages of disease. Submandibular and upper deep cervical nodes may be enlarge. Systemic metastases are rare.

Diagnosis

Radiograph of sinuses- opacity of the involved sinus with expansion and destruction of the bony walls. CT Scan is the best non invasive method to find the extent of disease.

Treatment

Combination of radiotherapy and surgery gives better results than alone. Surgery in the form of extended or radical maxillectomy with or without lymph node dissection is recommended.

2. PERIPHERAL JAW TUMOURS

Osteoma

Osteoma is occasionally seen in jaw, especially in the lower jaw. They are localized overgrowth of bony exostoses. It is painless slow growing tumour with neuralgic pain. The tumour is excised locally.

Chondroma

Chondroma may rarely occur in the lower jaw. Chondroma may undergo malignant change, when it turns to chondro-sarcoma, radiography shows multiple translucent areas. The tumour is scooped out, unless malignant.

Torus

It is a round elevation or swelling.

Torus mandibularis

It is an exostosis that develops on the lingual aspect of the body of mandible, perhaps transmitted as a genetic trait.

Torus palatinus

A benign exostosis located in the midline of the hard palate.

Fibrous Dysplasia

- It is an osteodystrophy characterized by presence of cysts and replacement of bone by fibrous or fibro-osseous tissue. It may be polyostotic or monostotic.
- The jaws are the common sites with preponderance of fibrocellular element and myxomatous degeneration within it, giving rise to a bone cyst.
- It is slow growing bony swelling commonly situated in the ramus or angle of the mandible. When the fibro-osseous element is preponderant, it leads to localized irregular bone formation.
- It is a slow growing painless bony swelling and may grow to a very big size, where it may be mistaken for a sarcoma.
- The tumour mass consists of fibrous tissue enclosed within laminated layers of bones.
- The polyostotic type involving the facial bones gives rise to an ugly deformity - of the face, described as *leontiasis osseum*. Almost all the facial bones are involved.
- The tumour mass consists of fibrous tissue with areas of ossification and calcification.
- Radiography reveals calcified ring like shadows.
- It may rarely turn into sarcoma.

****

Sample Questions for Prof Examination

1. How will you classify odontome?

   Discuss the pathology, clinical features and management of adamantinoma.

Write short notes on following.

2. Dental cyst.
3. Epulis.
4. Dentigerous cyst.

18 The Salivary Gland

Contents

- Composition of saliva
- Function of saliva
- Surgical anatomy
  - Parotid gland
  - Sub mandibular gland
  - Lingual nerve
- Acute parotitis
- Acute suppurative parotitis
- Mumps parotitis
- Salivary gland neoplasm
  - Pleomorphic adenoma
  - Warthin's tumours
  - Carcinoma
- Frey's syndrome

THE SALIVARY GLANDS

The oral cavity contains, Six major salivary gland and approximately 450 minor salivary glands, which are scattered throughout oral mucosa. Minor salivary glands are also called as accessory glands or ectopic salivary glands.

There are three pairs (six major salivary gland;) namely; parotid, sub-mandibular and sub-lingual salivary glands. *About 90% of saliva is secreted from major salivary gland and only 10% by minor salivary gland.* Please read key box 18.1.

COMPOSITION OF SALIVA

In ***twenty four hours, about 1200-1500 ml of saliva is secreted*** *(MANY PGME)*. It's P_H is around 6.0, about 99% of saliva is water and rest is solid. Of the solid material, the electrolytes like, Na^+, K^+ and bicarbonate ions, organic matters; like amylase, mucin, lysozyme, H_2CO_3 are important. The saliva also contains calcium, amino acid and immuno-globulins.

FUNCTION OF SALIVA

- Lysozyme present in the saliva cause lysis of many bacteria present in oral cavity.
- Mucin; present in saliva provides lubrication to food and makes the food slippery. Facilitation of swallowing is also helped by watery nature of saliva.

KEY BOX 18.1

SALIVARY GLANDS

- Two parotid glands
- Two submandibular glands
- Two sub lingual glands
- More than 450 minor salivary glands.

- Salivary amylase, acts on starch present in food and splits it.
- Immunoglobulins present in saliva protects against various bacteria.
- Saliva helps in speech and some times in sex.

****

SURGICAL ANATOMY

There are three pairs of major salivary glands; namely, the parotid, submandibular and sublingual.

1. The Parotid Gland

- The parotid gland, one on either side, *lie in the groove between the ramus of mandible and mastoid process ie; below the ear. When the gland enlarges the groove is obliterated and ear lobule is pushed forward* (IMP. POINT) Please see figure 18.1(a). **Swelling of Deep lobe present in parapharyngeal space.** (NEET)
- The duct of parotid gland ***(duct of stensen)*** (AP 84) passes anteriorly, on masseter and after crossing the medial border of masseter muscle, turns deeply into buccal fat pad and *pierces the buccinator muscle* and **opens** into the vestibule of the oral cavity, *near the crown of the upper second molar tooth*. (PGME MANY TIMES)
- Several important structures enter and pass through or just deep to the parotid gland. These include the *facial nerve (VII), the external carotid artery and its branches, and the retromandibular vein and its tributaries,* (MANY PGME).
- The five terminal branches of the facial nerve (VII) the *temporal, zygomatic, buccal, mandibular and cervical* emerges from the upper, anterior and lower border of parotid gland.
- The external carotid artery enters the inferior surface of the gland and divides into maxillary and superficial temporal arteries; the later giver rise to transverse facial artery.
- The retromandibular vein is formed in the substance of the parotid gland, when the superficial temporal and maxillary vein join together.

2. Sub Mandibular Salivary Gland

- The submandibular glands are smaller than the parotid glands and are hook shaped. The larger arm of the hook is directed forward in the horizontal plane below the mylohyoid muscle, and is therefore outside the boundaries of the oral cavity, this larger superficial part of the gland is directly against a shallow impression on the medial side of the mandible (submandibular fossa) inferior to the mylohyoid line; the smaller arm of the hook (or deep part) of the gland, loops around the posterior margin of the mylohyoid muscle to enter and lie within the floor of the oral cavity, where it is lateral to the root of the tongue on the lateral surface of the hyoglossus muscle. See figure 18.1(b).
- The submandibular duct *(wharton's duct)* emerges from the medial side of the deep part of the gland in the oral cavity; and passes forward to open on the summit of a small sublingual papilla lateral to the base of frenulum of the tongue. (COMED 07)

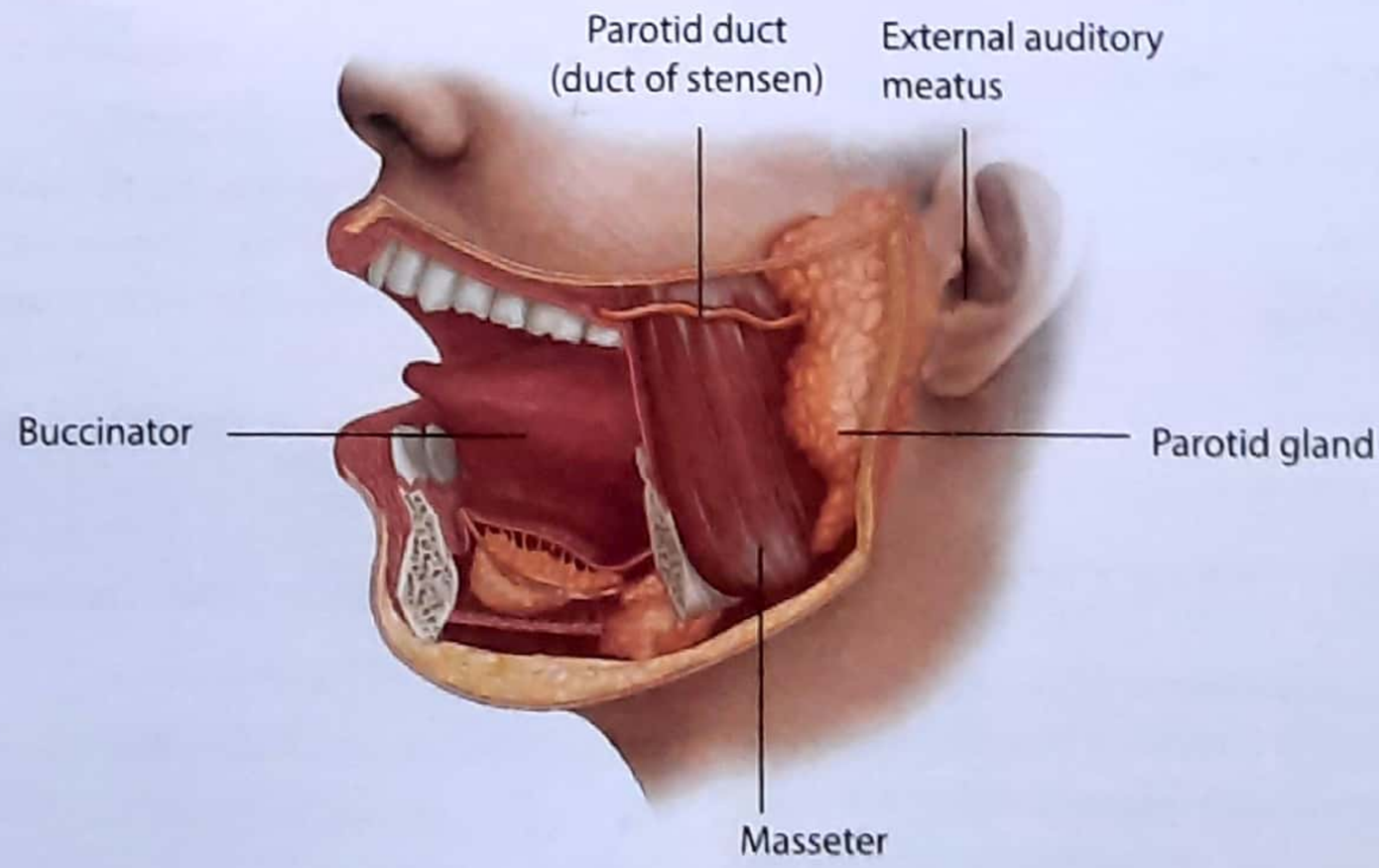

Figure 18.1(a): Location of parotid gland

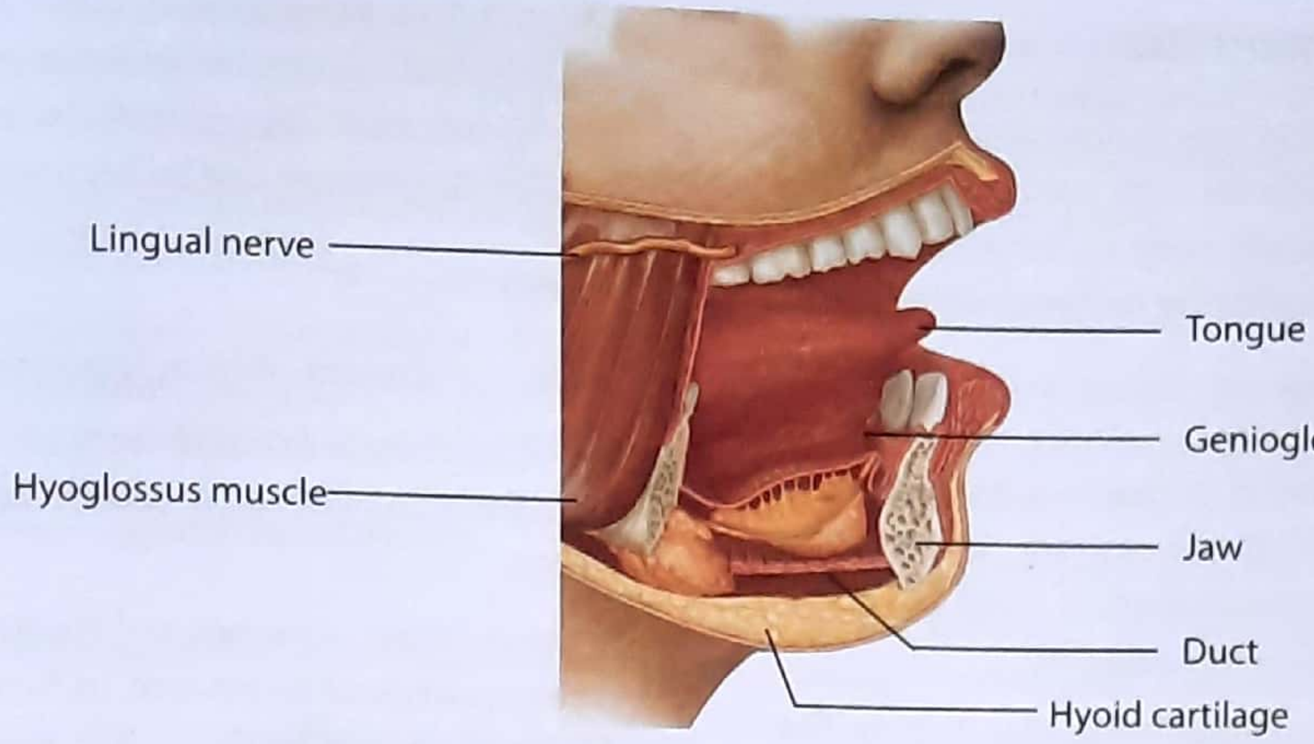

Figure 18.1(b): Location of mandibular gland

- *The lingual nerve loops under the submandibular duct* (AIIMS 87) crossing first to the lateral side, and then the medial side of the duct, as the nerve descends antero-medially through the floor of the oral cavity and then ascends into the tongue.

3. Sublingual Glands

- The sublingual glands are the smallest of the three major paired salivary glands. Each is almond shaped and is immediately lateral to the submandibular duct and associated lingual nerve in the floor of the oral cavity.
- Each sublingual gland lies directly against the medial surface of the mandible, where it forms a shallow groove (sub-lingual fossa) superior to the anterior one third of the mylohyoid line.
- The superior margin of the sublingual gland raises an elongate fold of mucosa (sublingual fold). Which extends from the posterolateral aspect of the floor of the oral cavity to the sublingual papilla beside the base of the frenulum of the tongue at the midline anteriorly.
- The sublingual gland drains into the oral cavity via numerous small duct *(duct of Rivinus)*.

Note : Most common location of ectopic salivary gland is cervical lymph node.

Nerve supply

The *secretomotor fibers* (that is, the supplying nerve fibers, which when stimulated, produce secretion) of the salivary glands *are parasympathetic fibers.* These parasympathetic motor fibers arise from a center called **'salivary nucleus'** situated in the lower part of pons and upper part of medulla. The *cranial part* of this center is called the *superior salivary nucleus,* whereas the *caudal part* is known as the *inferior salivary nucleus.*

Parasympathetic fibers arising from the *superior salivary nucleus* proceed first *via facial nerve and then via chorda tympani nerve* to reach the *sub mandibular and sublingual glands* (MANY PGME). *The para-sympathetic nerve supply for the parotid gland comes from inferior salivary nucleus via the glossopharyngeal nerve,* (MANY PGME).

Stimulation of parasympathetic nerves causes salivary secretion, as well as dilatation of the blood vessels. Sympathetic supply to the salivary gland is not of so much importance, because it's stimulation causes only small amount of secretion.

****

DISEASE OF SALIVARY GLAND

I have divided the diseases of salivary gland in three broad group for discussion.

I. **Inflammatory disorders of salivary glands**
II. **Salivary gland calculi**
III. **Salivary gland neoplasm**

Now lets discuss them one by one.....

I. Inflammatory Disorders of Salivary Gland

1. Acute parotitis

Acute parotitis is acute inflammatory condition of parotid salivary gland. Acute parotitis can be subdivided into acute suppurative (bacterial) parotitis and viral parotitis (endemic parotitis, mumps parotitis).

2. Acute suppurative parotitis

In earlier days, this condition was more common in dehydrated and debilitated patients with poor oral hygiene, but now it is more commonly seen in an otherwise fit adult with no obvious precipitating factors.

Etiopathogonesis (ORISSA 99)

In debilitated and dehydrated patients, whose salivary glands are not secreting adequate amount of saliva; are prone to develop the infection as there is rapid growth of organism in such favourable environment.

- The infecting organism enters the gland from the mouth through stensen's duct.
- The infecting organism is usually *Staphylococcus aureus* and *S. viridans*.

Clinical Feature

- Patient present with fever and malaise. Dehydration, may be present.
- *If superficial lobe of parotid is involved, we will notice swelling in parotid region. In case of deep lobe involvement, a bulge in lateral pharyngeal wall will be noticed.* (PGI81, MANY PGME). Figure 18.2(a)
- Local edema and tenderness will be present and over lying skin will be warm.
- The pain may increase by eating or drinking. In more severe cases, trismus may be presents.
- *Fluctuation is usually not a feature of a parotid abscess* (IMP. POINT) due to presence of tense parotid fascia. That is why, for draining parotid abscess one should not wait for fluctuation test to become positive.

Treatment

- Treatment consist of broad spectrum antibiotics.
- Initially, it is safe to continue with conservative treatment in form of broad spectrum antibiotics and pain killers.
- If the swelling does not reduce in size and pain increases, **surgical treatment in form of incision and drainage** should be done. *It is unwise to wait for the appearance of fluctuation to be positive (which is a very late feature due to tense parotid fascia).* (MANY PGME)
- *Sialography is absolutely contraindicated during acute infection.* AI 2005)

3. Mumps Parotitis (Viral Parotitis)

- *Mumps is the most common cause of acute painful parotid swelling in children and young adults* (PGME).
- Mumps is a contagious disease and spread via *air droplets of infected saliva* (PGME).
- The disease starts with a prodromal period of 1-2 days, during which the patient experiences fever, malaise, nausea and headache.

Figure 18.2(a): Acute suppurative parotitis

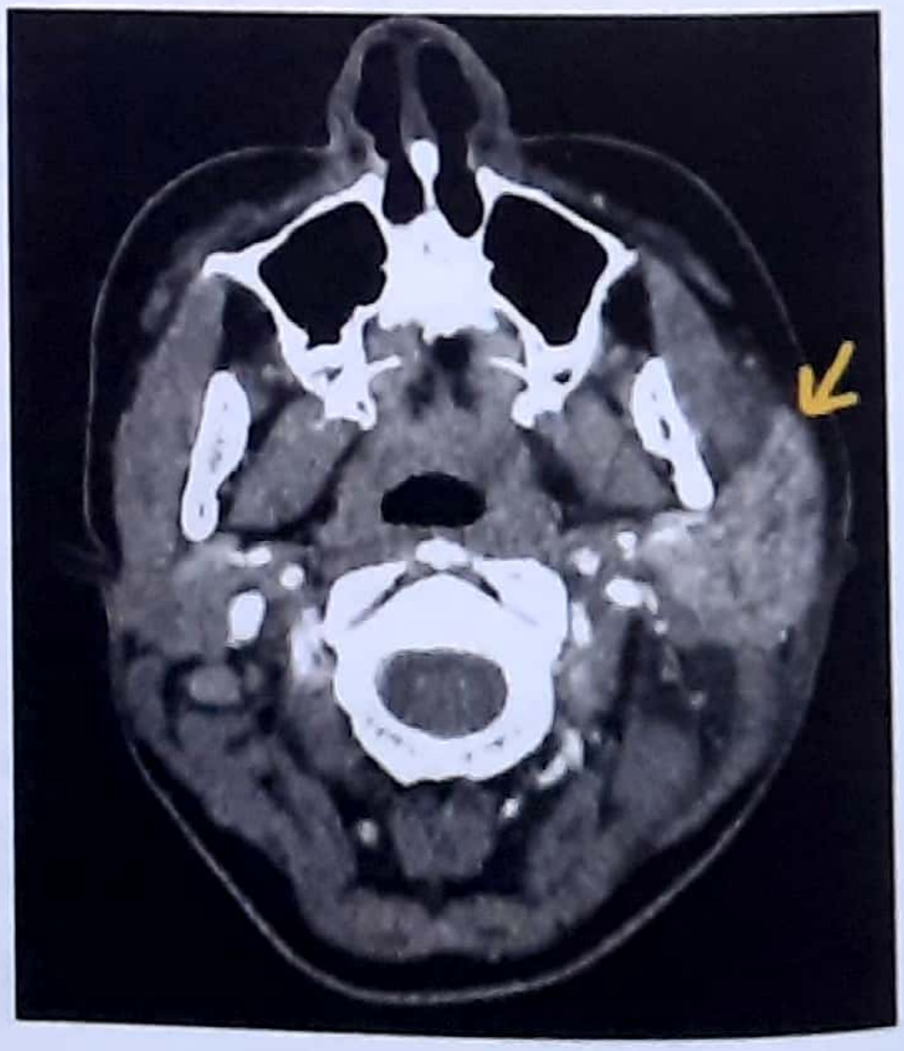

Figure 18.2(b): Mumps parotitis

- This is followed by pain and swelling of both parotid gland. Unilateral enlargement can also occur, but in most of the time it is bilateral.
- Patient complains of severe parotid pain which is exacerbated by eating and drinking.
- Treatment is essentially symptomatic. Symptoms usually resolve spontaneously in 5-10 days. One episode of infection gives lifelong immunity. *(PGME)*

Now lets discuss second group of parotid disorders

II Salivary Gland Calculi (Sialolithiasis)

- Sialolithiasis is a condition where, stone formation occurs in **either salivary gland or ducts** draining it. Stone may obstruct the duct, which can lead to inflammation and **intermittent painful** swelling of the affected gland
- ***About 80% of all salivary stones occurs in the submandibular gland or its duct*** *(NEET, AIIMS NOV 99, JUNE 99, MANY PGME)* 10% in the parotid; and 7% in the sublingual gland and remainder in the minor salivary glands.

Remember with: **S**abse **j**yada **S**tone **S**ubmandibular Salivary gland me hota hai; **S**eventy to eighty percent:

Etiology

Secretion of the submandibular salivary gland is viscid, rich in minerals and has to drain upwards against gravity onto the floor of the mouth, the tortuous course of mandibular duct further increases the problem of stone formation is submandibular gland. As a contrast, the parotid secretion is thin with less salt content, and the flow is down ward to the oral cavity, that explains why calculi are less common in parotid gland and more common in submandibular gland.

Clinical feature

- The patient usually presents with **recurrent attacks of acute painful swelling** in the region of the affected salivary gland.
- The pain is rapid in onset, within a minute of starting the meal and the swelling resolves over a period of one to two hour after meal. This is because, salivary secretion rapidly increases with the meal.
- The patient may also complain of a chronically enlarged mass in the submandibular triangle. The gland may be tender on palpation. Please see figure 18.3 & 18.4.
- Sialography is done to find stone.

Investigations

Nearly 80% **of submandibular stones are radio -opaque,** and can be identified using plain radiographs. The **majority of parotid stones are radiolucent** and can not be detected on plain radiography. *(IMP POINT)*

Treatment

1. If the stone is trapped at the duct papilla it can be released by gently probing and carrying out dilatation of the papilla. It may be necessary to slit the duct in order to release the stone. *(PGME)*

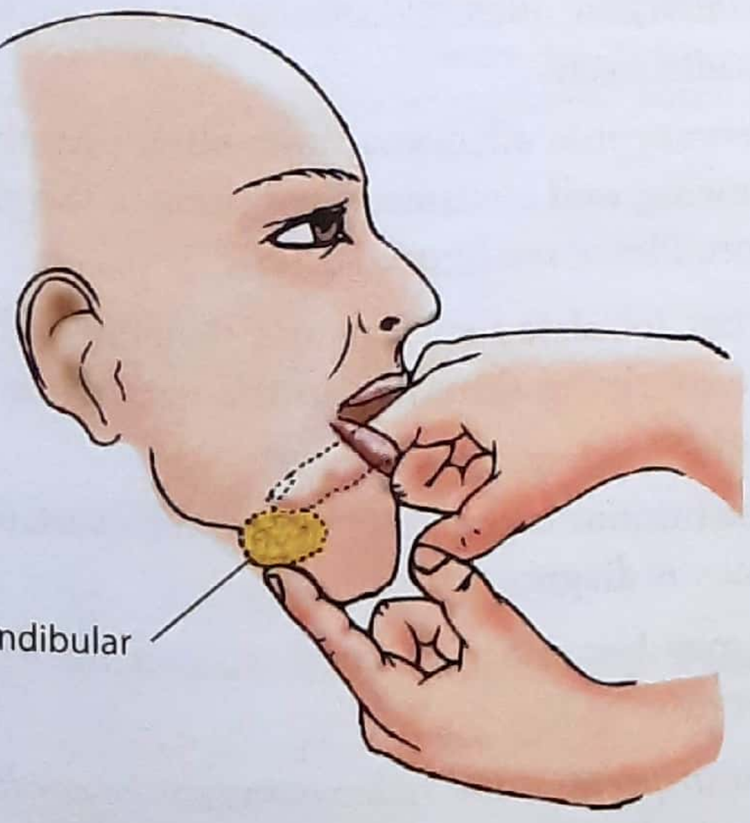

Figure 18.3: Method of palpation of submandibular salivary gland

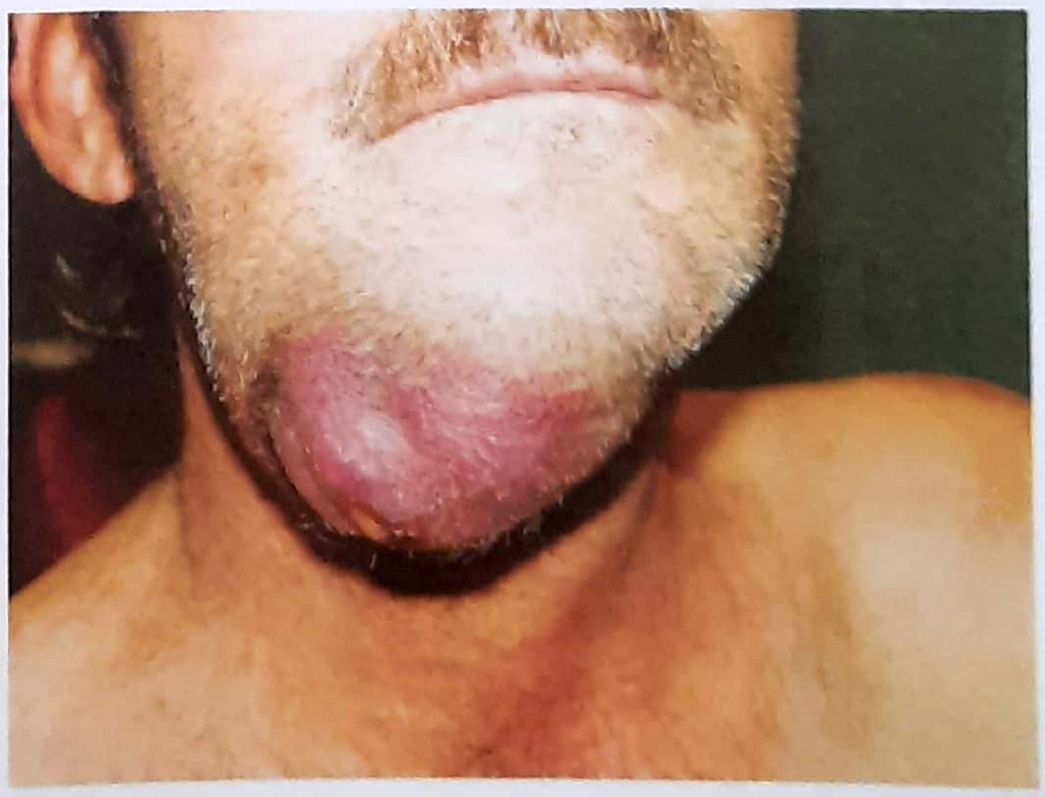

Figure 18.4: Submandibular lymphadenitis

2. *If the stone is in the submandibular duct, (ie; in the floor of the mouth), it can be released by opening the duct longitudinally.* (PGME, AIIMS)
3. Calculi in the substance of the submandibular gland are approached from out side the mouth and the gland is removed after legation of duct distally.
4. Anteriorly placed parotid duct stones may also be removed through the mouth; while symptomatic stones in the substance of gland require parotidectomy.

Now we will discuss third group of disorders; ie; Neoplasms of salivary gland

III. Salivary Gland Neoplasm

- Tumours of salivary gland are relatively uncommon and present less than 2% of all head and neck neoplasm
- *The majority of neoplasms arise in the parotid gland (70%)* (MANY PGME), where as tumours of the submandibular salivary gland (22%) and sublingual and minor salivary glands (8%) are less common. (PGME)

(NOTE: Minor salivary glands are also called as accessory or ectopic salivary gland).

- The ratio of malignant and benign tumours varies as well. Among all; 80% *of parotid neoplasms are benign, 20% are malignant;* (PGME MANY TIMES)
- *In submandibular and sublingual gland.* 50% *neoplasms are benign and 50% malignant, where as in minor salivary glands* 25% *are benign and* 75% *are malignant.* (UP, PGI, AIIMS)

Here; first we will discuss benign salivary tumours, followed by malignant tumours

KEY BOX 18.2			
Salivary gland tumours - frequency and distribution			
Type	**Location**	**Frequency**	**Malignant (%)**
Major	Parotid Submandibular Sublingual	Common Uncommon Very rare	10-20 50 85
Minor	Upper aerodigestive tract	Rare	90

A. BENIGN TUMOURS OF SALIVARY GLANDS

Benign tumours of salivary glands include pleomorphic adenomas, and a variety of monomorphic adenomas including warthin's tumours, oncocytoma, basal cell adenomas, canalicular adenomas. *About 80% of parotid neoplasms are benign and 80% of them are pleomorphic adenoma.* (MANY PGME)

1. Pleomorphic Adenoma (Mixed Parotid Tumour; MPT)

- This is ***commonest benign salivary tumour,*** *accounting for 40-70% of all salivary gland tumour* (NEET, AIIMS JUNE 98, AL 02, 06) *and most commonly occurring in superficial lobe of parotid gland.* (NEET, AIIMS JUNE 93)
- It can occur at any age, but mean age for pleomorphic adenoma is 42 years. It has equal sex incidence.
- *Pleomorphic adenoma (Mixed parotid tumour) is named so because it contains both mesenchymal (stromal) and epithelial components* (NEET, PGI 80, DELHI 87,88)

Pathology

- *Although the lesion is benign and well circumscribed, encapsulation* (NEET) *is often incomplete.*
- Histologically, it shows an acinar pattern with mucoid stroma and pseudocartilaginous cells. The mucoid stroma is due to production of mucin by the tumour cell.

Clinical feature

- Males and females are equally affected and the mean age of occurrence is 42 years. *In about 80% cases pleomorphic adenoma involve* ***superficial lobe*** *of the parotid gland.* (PGME)
- Pleomorphic adenoma most often presents as slow growing well circumscribed mass in the parotid region. Please see figure 18.5(a).
- It has lobulated surface and is neither adherent to the overlying skin, nor to the underlying masseter muscle.
- The tumour is generally firm and it's variable consistency is diagnostic feature.
- It may become very large without involving facial nerve.
- On *inspection; the space between the ear lobule and mastoid process is filled by the tumour,* see figure 18.5(a), note obliteration of space.

Figure 18.5 (a) : Pleomorphic adenoma

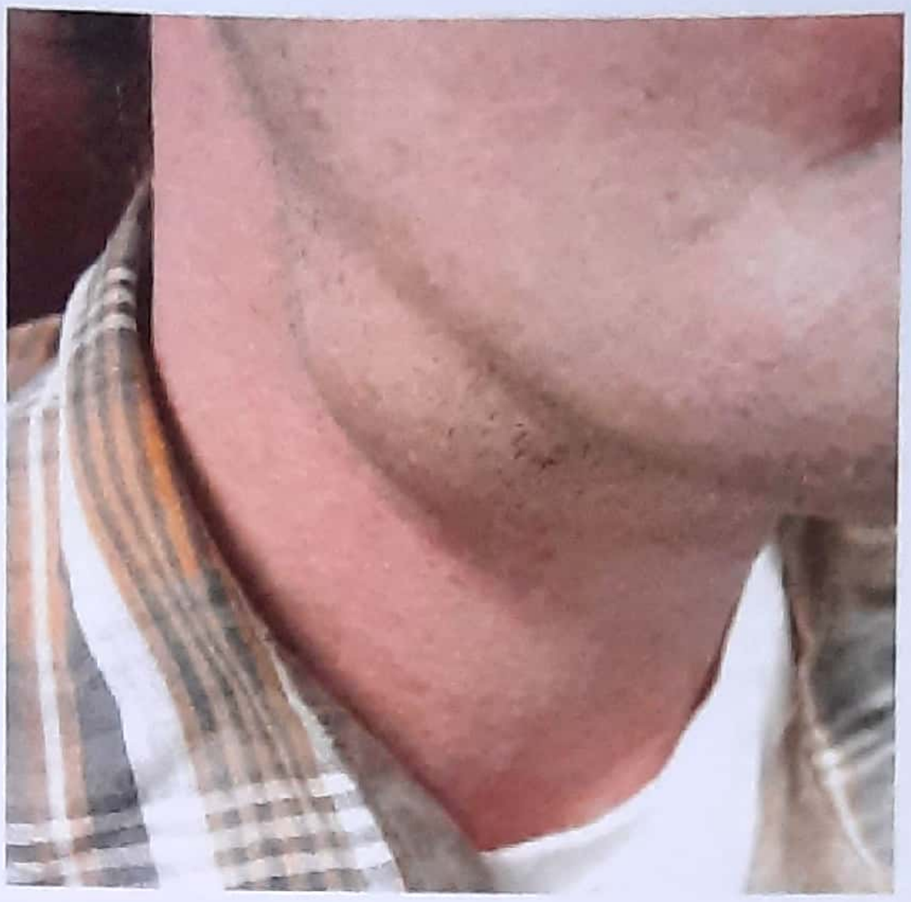

Figure 18.5(b) : Submandibular salivary gland enlargement

- If the pleomorphic adenoma *involves deep lobe of parotid gland*, it will push the tonsil and the pillar of the fauces, towards the midline *and may appear in lateral pharyngeal wall*. (MANY PGME)

Malignant change of a pleomorphic adenoma (VERY IMPORTANT TOPIC)

The **risk of malignant transformation of pleomorphic adenoma is about 2% within first 5 years**, (NEET) but increases to about 10% once the benign tumour has been present for more than 15 years. The malignant tumour arising in a pleomorphic adenoma is termed as *carcinoma ex pleomorphic*.

Malignant transformation is suggested when the tumour: (PGME MANY TIME)

1. Becomes *painful*
2. Starts *growing rapidly*
3. *feels stony hard*
4. *Involvement of facial nerve* is an important feature and highly suggestive of malignancy.
5. *Cervical lymphadenopathy* is present.
6. *Trismus* due to involvement of pterygoid muscle
7. *Gets fixed to the masseter and mandible.*
8. Over lying skin is involved

Investigation

1. *FNAC:* Diagnosis of salivary gland tumour can be made by fine needle aspiration cytology. If *can provide an accurate pre-operative diagnosis in 80-90% of cases* & is most *helpful investigation* (AIIMS 94).
2. **Open *surgical biopsy* is contraindicated as it may lead to spillage of the contents and increases chances of spread.** (NEET)
3. *CT Scan and MRI Scan* are fairly helpful for parotid gland tumours, they confirm the mass in the gland, and image its borders, invasive nature and involvement of lymph nodes.

Treatment (AIIMS JUNE 01, AIIMS JUNE 98, PGI JUNE 2000, AL 97)

- *Like all benign parotid tumours, the treatment of choice for parotid tumour is surgical excision with a margin of normal tissue (ie; superficial parotidectomy)* (NEET, AIIMS 2001, NOV 95, AI 97, PGI 99).
- *Greater auricular N. damage - Numbness during shaving.* (AIIMS MAY 19)
- Great care should be taken as to not to damage the facial nerve.
- *Damage to marginal mandibular nerve causes lower lip paralysis.* (AIIMS JUNE 20)
- Surgical Landmarks for preservation of Facial Nerve during Parotidectomy:

KEY BOX 18.3

Classification of salivary gland tumours (simplified)

Type	Subgroup	Common examples
1. Adenoma	Pleomorphic	Pleomorphic adenoma
	Monomorphic	Adenolymphoma (Warthin's tumour)
II. Carcinoma	low grade	Acinic cell carcinoma Adenoid cyctic carcinoma Low-grade mucoepidermoid carcinoma
	High grade	Adenocarcinoma Squamous cell carcinoma High-grade mucoepidermoid carcinoma
III. Non-epithelial tumours		Haemangioma, lymphangioma
IV. Lymphomas	Primary lymphomas	Non-Hodgkin's lymphomas
	Secondary lymphomas	Lymphomas in Sjogren's syndrome
V. Secondary tumours	Local	Tumours of the head and neck especially
	Distant	Skin and bronchus
VI. Unclassified tumours		
VII. Tumour-like lesions	Solid lesions	Benign lymphoepithelial lesion Adenomatoid hyperplasia
	Cystic lesions	Salivary gland cysts

- Tympano-*mastoid suture line* (NEET)
- *Tragel Pointer* (NEET)
- *Posterior belly of diagostric muscle* (NEET)
- Retromandibular Vein
- Styloid Process of Temporal bone

- *Enucleation should be avoided* as it is associated with high recurrence rate.
- In case of *deep lobe involvement*, *Total parotidectomy is done conserving the facial nerve.* (NEET)

Figure 18.6 (a) : Pleomorphic Adenoma

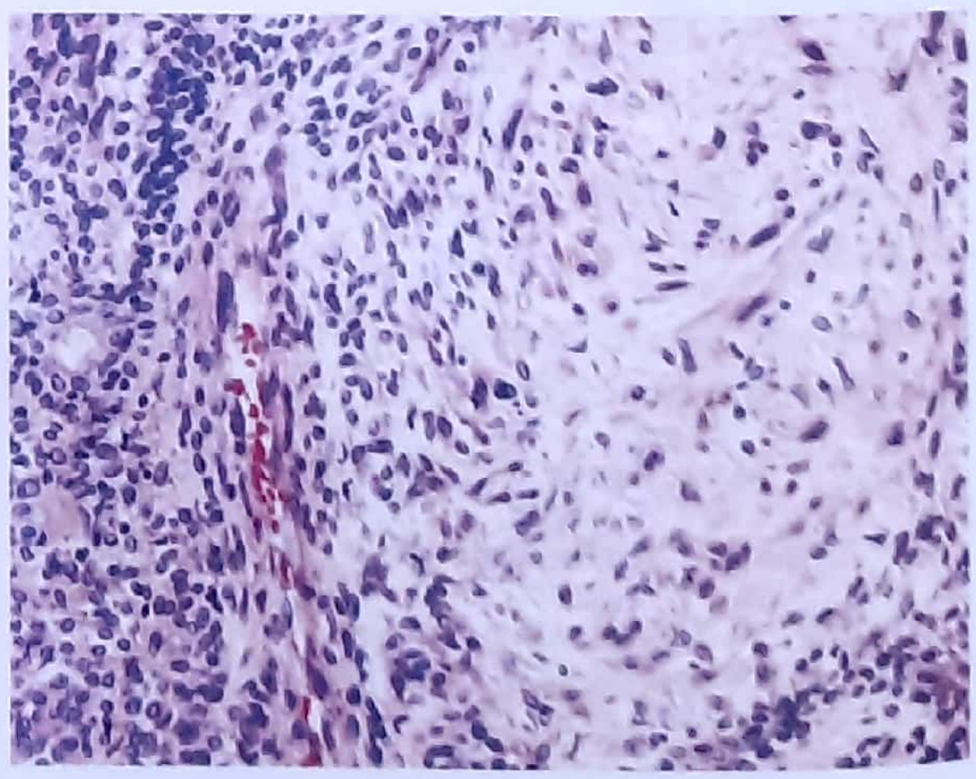

Figure 18.6 (b) : Pleomorphic Adenoma

- **If facial nerve is injured, immediate repair is done.** *(NEET)*
- Slow growing *submandibular adenomas* (*fig: 18.5b*) are treated by *excision of the whole gland*. *(PGME)*

Warthin's tumour (ADENOLYMPHOMA OR PAPILLARY CYSTADENOMA LYMPHOMATOSUM) *(NEET, AIIMS MAY 2005, JUNE 2003,MANY PGME)*

- This is second most common variety of benign tumour of parotid and represents about 10-15% of parotid tumour.
- It almost always occur in the lower portion of the parotid gland, overlying the mandible.
- In about 10% *of cases warthin's tumour is bilateral.*
- These tumours are more common in men than women and typically occur in **older age group** (more than 60 years).

Pathology

- The tumour is composed of ***cystic spaces*** lined by columnar epithelium within an abundant **lymphoid tissue**, that is why it is also called papillary cystadenoma lymphomatosum. *(MANY PGME)* (Figure 18.7)
- These are encapsulated lesions and ***do not*** *undergo malignant transformation*.
- However, they are susceptible to infection and some times may convert into parotid abscesses.

Clinical features

1. It presents as a **slow growing painless swelling** over the angle of the mandible.
2. The overlying skin looks normal.
3. The surface of the swelling is smooth and well defined and the margin is distinct.
4. Its consistency is soft, often fluctuate but not translucent.
5. The regional lymph nodes are not enlarged.
6. Interestingly these tumours show, a **"hot spot"** *(AI 88, MANY PGME)* on isotopic scanning with TC_{99m} pertechnetate, so a preoperative diagnosis can be made without FNAC. Please read key box 18.4, next page

Treatment *(AIIMS NOV 2001, AI 98, 96)*

Treatment of choice for warthin's tumour is surgical excision ***(superficial parotidectomy)*** *and the prognosis is very good*.

B. MALIGNANT TUMOUR OF PAROTID GLAND

Malignant tumours comprise 20% of all parotid neoplasm, *often characterized by pain and facial nerve paralysis, which are rarely found in benign tumours.*

- About 50% of submandibular gland neoplasm are malignant and about 75% of sublingual gland and minor salivary gland neoplasm are malignant.

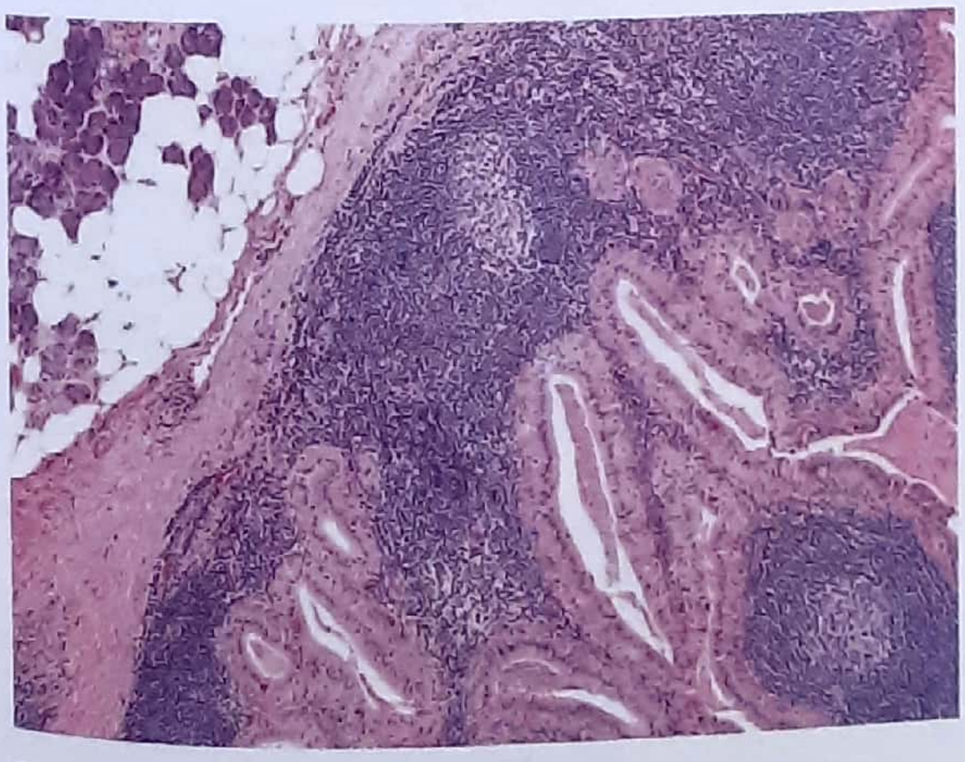

Figure 18.7 : Warthin's tumour

Figure 18.8 : Warthin's tumour

KEY BOX 18.4		
Differentiation Of Mixed Parotid And Warthin's Tumour *(VERY IMPORTANT FOR PGME)*		
Features	**Mixed Tumour**	**Warthin's Tumours**
Occurrence	Common	Uncommon
Affection	Unilateral	May be bilateral
Age	Young & middle age	Middle and old age
Situation	Above and in front of angle of jaw	Over angle of jaw
Size	May be large	Usually small
Surface	Usually bosselated	Smooth
Consistency	Rubbery hard	Soft
Fluctuation	Absent	Present
Malignant change	More Common	*Rarely* occurs
Investigation		
99m Tc scan	Cold spot	**Hot spot** *(MANY PGME)*
Histopathology	Pleomorphic with	Multiple acini
	pseudo cartilage	and *lymphoid tissue*

- Submandibular and sublingual gland tumours present as a neck mass or as floor of mouth swelling, respectively.
- *Malignant tumours of sublingual or submandibular salivary gland may invade the lingual or hypoglossal nerve causing paresthesia or paralysis.* *(PGI 97)*
- Minor salivary gland tumour presents as painless submucosal masses, about 75% of them are malignant and are most frequently seen at the junction of the hard and soft palate.

Types

- *Mucoepidermoid carcinoma is most common type of parotid malignancy & minor salivary gland malignancy* *(NEET)* and accounts for about 6-8 % of all parotid neoplasm. They arise from mucin secreting, and epidermal cells.
- ***Adenoid cystic carcinoma*** *is the second most common type of malignant parotid neoplasm.* The *tendency of this tumour to invade the perineural lymphatics account for the high frequency of facial nerve involvement* *(NEET, AIIMS 96, 97)*
- Other malignant neoplasms of parotid glands are squamous cell carcinoma, adenocarcinoma, and malignant lymphoma.

Clinical feature

- The *chief complaint* of a parotid malignancy is a painless lump in the parotid region to start with, but becomes painful at a later stage. *The lump increases in size rapidly* *(PGME)*. (Figure 18.9).
- The *pain may radiate to the* ear and over the side of face. *(PGME)*.
- On palpation, the lump is *hard with irregular surface and indistinct margin*.
- The swelling is fixed to underlying muscle (masseter) and gradually *restricts the jaw movement, resulting in trismus*.
- The *facial nerve is often infiltrated by tumour, and leads to facial paralysis*.
- *The cervical lymph nodes are almost always enlarged and hard.*

Investigation

- FNAC
- CT Scan
- MRI Scan

Treatment

- The primary treatment of salivary malignancies is surgical excision. Basic surgical principles include the en-bloc removal of the involved gland with preservation of all nerve unless invaded directly by tumour.
- For parotid tumours that arise in the **superficial lobe, superficial parotidectomy with preservation of facial nerve is indicated.** If the tumour extends into the deep lobe of the parotid, a total parotidectomy with nerve preservation is performed. Although malignant tumour may abut the facial nerve, if a plane of dissection can be developed without leaving gross tumour, it is preferable to preserve the nerve.
- If the nerve is encased by tumour and preservation would mean leaving gross residual disease, the nerve is sacrificed.
- The removal of submandibular malignancies includes en-bloc resection of the gland and submental and submandibular lymph nodes. Radical resection is indicated for tumour that has invaded the mandible, tongue or floor of mouth.
- Nerves at risk during submandibular gland excision-
  1. Lingual nerve
  2. Hypoglossal nerve
  3. Marginal mandibular nerve
- Postoperative radiation treatment plays an important role in the treatment of salivary malignancies. The presence of extra-glandular disease, perineural invasion of regional structures, regional metastasis and high grade histology are all indications for radiation treatment.
- Before concluding this topic, revise whole story; kindly go through key box 18.5 on next page.

****

Frey's syndrome (Gustatory sweating) *(KARN. 94)*

- This is a common **complication** of parotidectomy occurring in up to 54% of cases. During meals, the parotid region and the cheek in front of it becomes red, hot and painful; very soon perspiration appear on this area. Cutaneous hyperesthesia is also present over this area and becomes evident to the patient while shaving. Please see figure 18.10.
- Frey's syndrome is due to *injury to auriculotemporal nerve* *(MANY PGME)*
- Surgical treatment is not successful and most patients either learn to live with it or alternatively use an antiperspirant.
- Other rare complications of parotidectomy are sialocele or salivary fistula.

Figure 18.9: A patient with malignant tumour of parotid

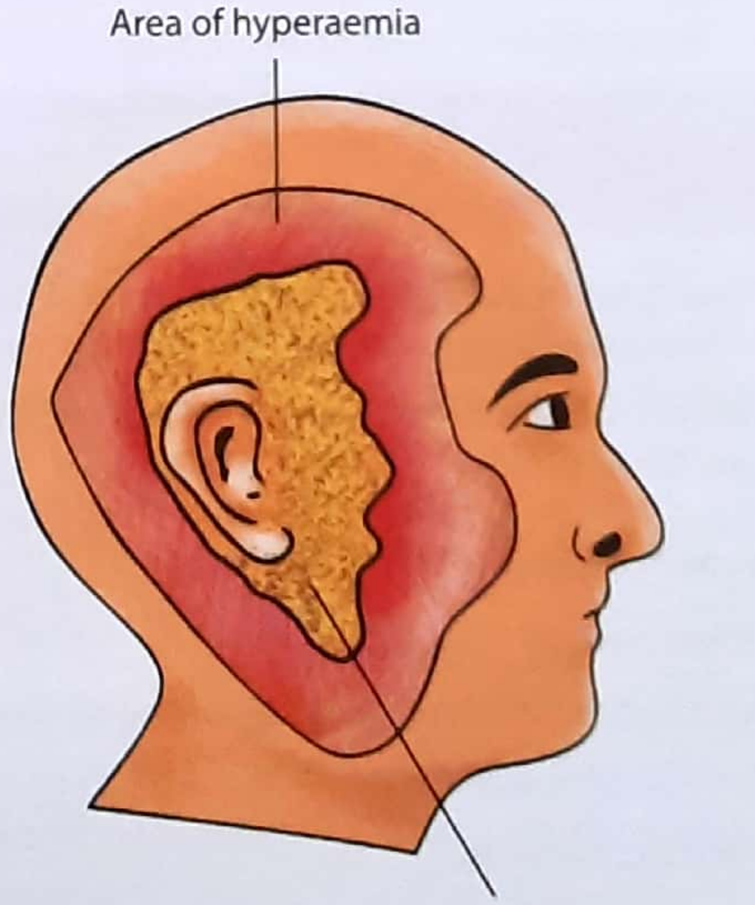

Figure 18.10: Frey's syndrome

KEY BOX 18.5

SALIVARY GLAND NEOPLASM

1. Adenomas	Pleomorphic adenoma	• Any age; M : F = 1 : 1 • 80% of all parotid tumours • 50% of all submandibular tumours
	Warthin's tumour	• >60 years; • M : F = 4 : 1 • 15% of parotid tumours
2. Carcinomas	Acinic cell carcinoma	Often low grade
	Mucoepidermoid carcinoma (M/C malignancy)	Often low grade
	Adenoid cystic carcinoma **(M/C in minor Salivary Glands)** *(NEET)*	• **Perineural spread** *(NEET)* • Pulmonary metastases
	Adenocarcinoma, Squamous cell carcinoma, carcinoma	All have a poor prognosis
	Carcinoma in pleomorphic adenoma	Very rare
3. Non- epithelial	Hemangioma	Mostly in infants, usually parotid; frequent spontaneous regression
	Lymphangioma	Any gland affected
	Neurofibroma, neurilemoma	
4. Malignant lymphoma	85% Non Hodgkin's	More common in patients with Sjogren's syndrome
5. Unclassified		

Sample Questions for Prof Examination

1. Classify various salivary gland tumour? What are the various sites of its occurrence? Describe the treatment of mixed parotid tumour.
2. What is mixed parotid tumour? What are the various sites of its occurrence? Describe the treatment of mixed parotid tumour.

Write short notes on following.

3. Mixed parotid tumour.
4. Discuss the epithelial tumours of the salivary glands.
5. Pleomorphic adenoma.
6. Warthin's tumour.
7. Enumerate differentiating features between pleomorphic adenoma & Warthin's tumours.
8. Differentiating feature between benign & malignant parotid tumour.

19 The Neck

Contents

- Surgical anatomy
- Swelling of neck
  - Thyroglossal cyst
  - Thyroglossal fistula
  - Sub hyroid bursal cyst
  - Branchial cyst
  - Branchial fistula
  - Cystic hygroma
  - Carotid body tumour
  - Sternomastoid tumour
  - Cervical rib
- Cervical lymph node
- Cervical lymph node dissection

SURGICAL ANATOMY OF NECK

The neck is divided into anterior and posterior triangle.

ANTERIOR TRIANGLE OF THE NECK

The anterior triangle of the neck is outlined by the anterior border of the sternocleidomastoid muscle laterally, the inferior border of the mandible superiorly and the midline of the neck medially. It is further subdivided into several smaller triangles as follows: Fig. 19.1.

1. Submandibular Triangle

This is outlined by the inferior border of the mandible superiorly and by the anterior and posterior bellies of the digastric muscle inferiorly. (Fig. 19.1)

2. Submental Triangle

This is outlined by the hyoid bone inferiorly, anterior belly of digastric muscle laterally, and midline of neck. (Fig. 19.1)

3. Muscular Triangle

It is outlined by the hyoid bone superiorly, the superior belly of the omohyoid muscle, and the anterior border of the sternocleidomastoid muscle laterally, and the midline.

4. Carotid Triangle

It is outlined by the superior belly of the omohyoid muscle antero-inferiorly, the stylohyoid muscle and posterior belly of the digastric superiorly, and the anterior border of the sternocleidomastoid muscle posteriorly, (Fig.19.1)

POSTERIOR TRIANGLE

Is bounded anteriorly by posterior border of sternocleidomastoid muscle, posteriorly by anterior border of trapezius and the inferiorly superior border of clavicle, (Fig. 19.1)

****

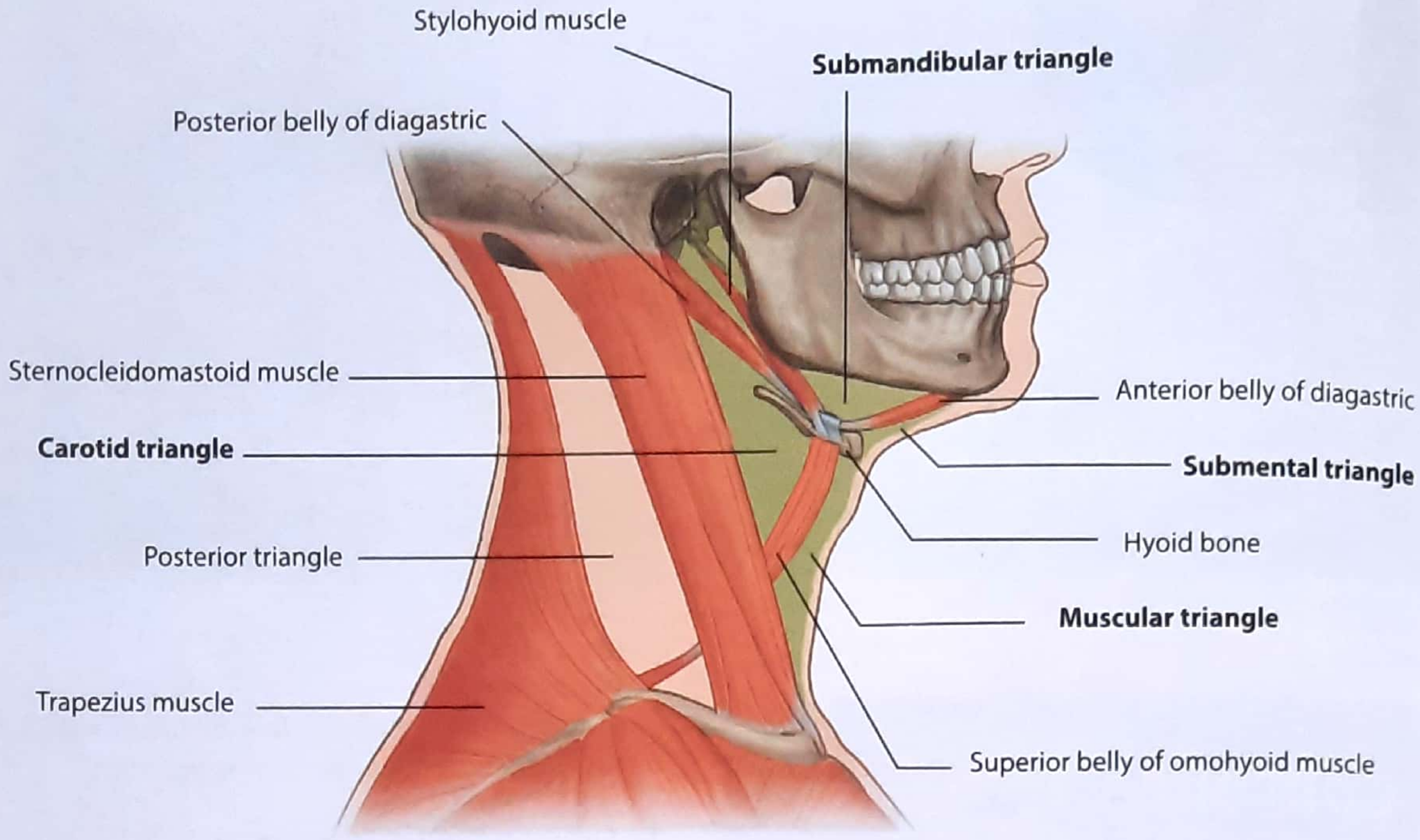

Figure 19.1: Showing Different Triangles of Neck

SWELLINGS IN THE NECK

Swelling of neck can be divided into **midline** swelling and **lateral** swelling.

1. Midline swellings

From above downwards these are:-

1. Ludwig's angina.
2. Enlarged submental lymph nodes.
3. Sublingual dermoid.
4. Thyroglossal cyst.
5. Sub-hyoid bursitis.
6. Adenoma of the thyroid isthmus.
7. Cold abscess.
8. Retrosternal goitre.
9. Thymic swelling.
10. Thyroid swellings.

2. Lateral swellings

(a) Submandibular triangle

1. Lymph nodes.
2. Submandibular salivary gland enlargement.
3. Plunging/deep ranula.
4. Extension of growth from the jaw.

(b) Carotid triangle

1. Thyroid swellings.
2. Branchial cyst.
3. Carotid body tumour.
4. Lymph nodes.
5. Laryngocele.
6. Aneurysm of the carotid artery.
7. Sternomastoid tumour (newborn baby).

(c) Posterior triangle

1. Cystic hygroma.
2. Pharyngeal pouch.
3. Lymph nodes.
4. Subclavian artery aneurysm.
5. Cervical rib.

NOTE: ***An enlarged/metastatic lymph node may present as a neck swelling, almost any where in neck.***

SWELLING IN THE NECK

ANTERIOR TRIANGLE

Mid line triangle | Submental triangle | Submandibular triangle | Carotid triangle

Observe movement on swallowing

Moves

- Thyroid
- Pretracheal LN
- Laryegocele
- Subhyoid bursal cyst
- Thyroglossal cyst

Observe movement on projection of tongue

Does not move
- Thyroid
- Pretracheal LN
- Laryngocele
- Sub-hyoid bursal cyst

Does not move
- Thyroglossal cyst

Do not move

Midline
- LN
- Ranula
- Cervical dermoid
- Cold abscess
- Aneurysm of innominate artery

Submetal triangle
- L.N.
- Ranula
- Cervical dermoid

Sub-mandibular triangle
- Submandibular gland
- Plunging ranula
- Lymphnode

Carotid triangle
- L.N.
- Carotid body tumour
- Branchial cyst
- Carotid aneurysm

POSTERIOR TRIANGLE
- Cystic hygroma
- Pharyngeal pouch
- Cervical rib

Note: (Lymph Node, cold abscess, sebaceous cyst, fibroma, neurofibroma, hemangioma can occur any where in the neck)

NINETEEN

I have described, some common and clinically important neck swellings below.

MIDLINE NECK SWELLINGS

1. Thyroglossal cyst

It is a cystic swelling present in midline of neck, and is developed in the remnant of the thyroglossal tract. It is a tubulo-embryonic type of dermoid cyst. (PGME)

Formation

The thyroglossal tract extends from the foramen cecum of the tongue through geniohyoid muscles to the level of hyoid bone, where it may cross in front of hyoid bone or through the bone; to finish at the isthmus of thyroid gland. This tract may finally result in the following possibilities:

(i) Total obliteration

(ii) **Formation of cyst (Thyroglossal cyst)**

(iii) Presence of lingual thyroid

(iv) Levator glandulae thyroidae.

Clinical feature

- Though it is congenital, generally seen between 20-35 years and affects more commonly women.
- Patient usually present with a painless swelling in neck, and if the cyst gets infected; it may become painful.

Figure 19.2: Thyroglossal cyst (NEET)

Examination

1. Position

A cyst may occur at any point in course of thyroglossal tract in the mid line of neck, ie; from the foramen caecum to the suprasternal notch. Please see figure 19.2

The **commonest sites** in order of frequency are: *beneath the hyoid (Sub-hyoid),* in the region of the thyroid cartilage, suprahyoid and the level of the cricoid cartilage. (MANY PGME, AIIMS 07)

KEY POINT: *M/C site is sub hyoid.* (AIIMS, AI, MANY PGME)

2. Consistency

- It is soft and cystic swelling and fluctuation test is positive, but transillumination is negative.
- The swelling is spherical or oval and *moves upwards on protrusion of the tongue and also moves with- deglutition.* (MANY PGME, AL 06)

Treatment

The cyst should be excised and the fibrous tract dissected out till it reaches the foramen cecum. It is *necessary to excise the mid portion of the hyoid bone to reduce recurrence.* (MANY PGME), AIIMS 07

Complication

- Recurrent infection
- Rupture and fistula formation
- Sinus formation
- May occasionally lead to papillary carcinoma.

2. Thyroglossal fistula

Thyroglossal cyst is a congenital condition, but a thyroglossal fistula is never congenital (MANY PGME). This (acquired) fistula originates from:

(i) *Bursting of an infected thyroglossal cyst* (M/C cause)

(ii) Incision of infected thyroglossal cyst

(iii) Incomplete removal of thyroglossal cyst.

- Thyroglossal fistula is found in children and young adults.
- On examination there is an opening in the midline of neck, at the level of the thyroid cartilage. *The opening on the skin move up when the tongue is protruded.*

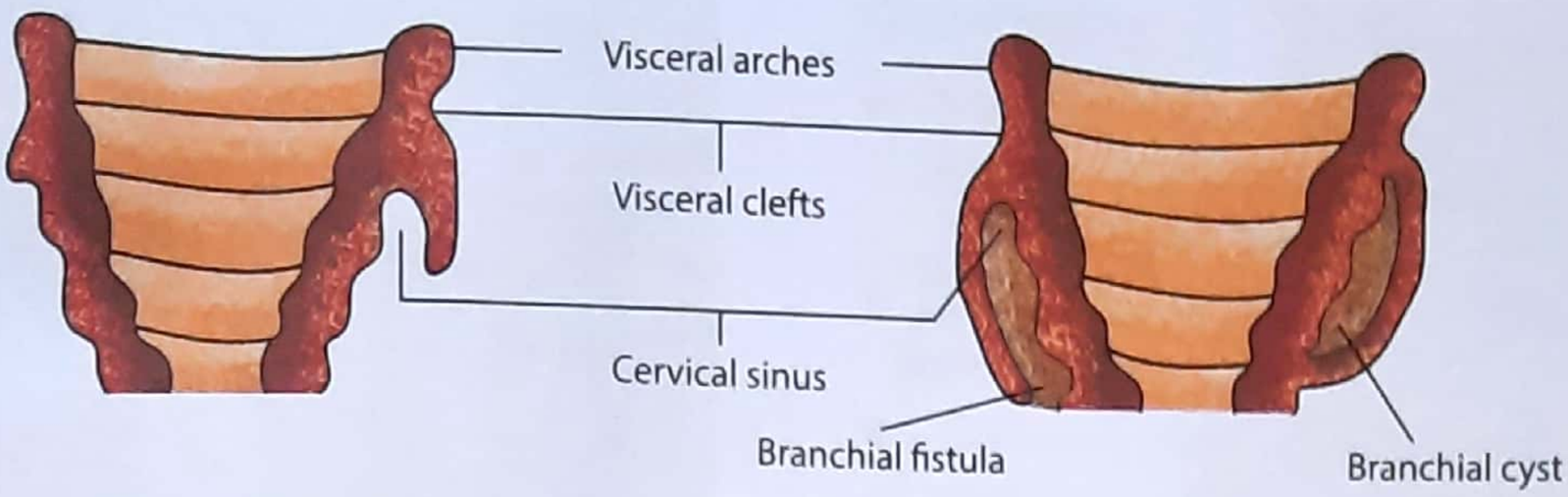

Figure 19.3: Development of brachial cyst & fistula

Treatment

Through excision of cyst along with fistulous tract, *and* *body of hyoid bone* and if needed a core of lingual muscle, this is called as ***Sistruck's operation***. (NEET, PGME)

3. Sub-hyoid bursal cyst

It is an enlargement of Sub-hyoid bursa with accumulation of inflammatory fluid within it, hence it may be called as sub-hyoid bursitis.

- Pain and swelling, just below the hyoid bone in the midline is characteristic feature.
- Complete excision of the cyst is treatment of choice.

Other midline neck swelling like thyroid adenoma, sub-lingual dermoid cyst, retrosternal goiter has been described elsewhere in this book.

Thyroid adenoma: page 244

Retrosternal goiter: page 233

Sublingual dermoid cyst: Page 169

Recap : We were discussing midline swelling of neck; now we will discuss lateral swellings of neck.

LATERAL NECK SWELLINGS

1. Branchial Cyst (PGI 07)

Development

The neck and pharynx are formed by five pairs of visceral arches which contain skeletal, muscular, neural and vascular elements. The arches are separated on the outside by visceral clefts lined by squamous epithelium and **on the inside by visceral pouches lined by columnar epithelium**.

The growth of second arch is much quicker than that of arches below; so that it hangs down to enclose a groove known as cervical sinus. Ultimately, the second arch meets the fifth arch and fuses, thereby enclosing an island lined by squamous epithelium which disappears. **If it persists then it forms branchial cyst**, (NEET) and if *second arch fails to fuse with the fifth then the opening of cervical sinus persist as branchial fistula* (AIIMS MAY 07). Please see Figure 19.3 and key box 19.2. It's wall consist of lymphoid tissue. (NEET)

Clinical feature

- Although; it is a congenital condition, the majority of patient presents in **3rd decade of their life.** (IMP POINT)

KEY BOX 19.2

Arch	Skeletal	Muscular	Nerve	Artery
First	Mandible	Muscles of mastication	Mandibular nerve	Facial
Second	Lesser cornu of hyoid and stylohyoid ligament	Platysma, facial muscles	Facial	External carotid
Third	Greater cornu of hyoid and its body	Stylopharyngeus	Glossopharyngeal	Internal carotid

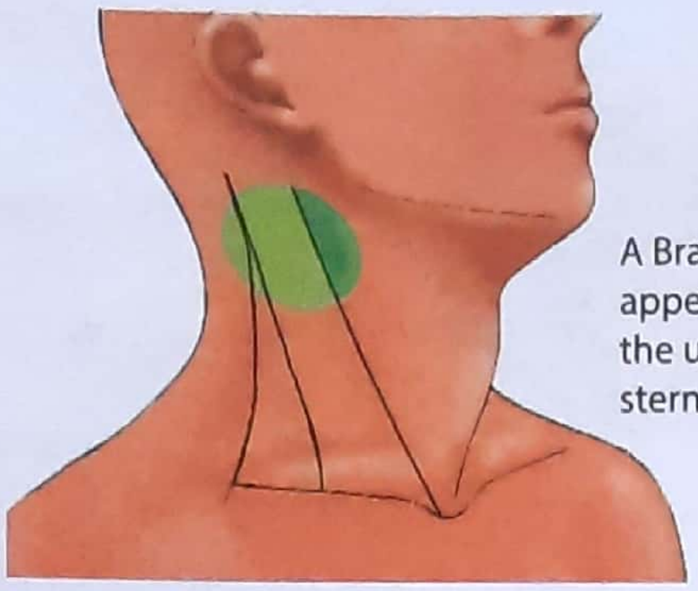

A Branchial cyst appears from beneath the upper third of the sternomastoid muscle

Figure 19.4(a): Branchial cyst

Figure 19.4(b): Branchial cyst

- It present as a painless swelling in the **upper outer part of the neck.** If the cyst get infected, it may become painful.
- *It is usually unilateral and found at the junction of the **upper third and middle third of the sternocleidomastoid muscle**, at its anterior border near the angle of mandible.* Please see Fig. 19.4a & b.
- It is round or oval in shape and soft in consistency.
- It is a transilluminant swelling.
- May contain granulation tissue.

Complication

- Recurrent infection
- Acquired branchial fistula, due to rupture or improper incision.
- Bronchiogenic carcinoma

Treatment

Complete excision is the treatment of choice. While during surgery, surgeon must take" at most care in avoiding injury to common carotid artery and IX; XI and XII cranial nerves.

2. Brachial fistula

Branchial fistulas can be of two types:-

Types

(A) Congenital branchial fistula

Which develops from failure of fusion between second and fifth visceral (branchial) arches.

(B) Acquired branchial fistula

Which develops due to infection in a branchial cyst and subsequent rupture or due to inadvertent incision on branchial cyst.

Clinical feature

- The condition is usually unilateral and is most commonly *seen in the second decade of life.*
- The *external orifice* is nearly always situated *in the lower third* of the neck, *near the anterior border of the Sternocleidomastoid muscle.* (Key box 19.3; page 214)
- In *most of the cases internal orifice is not present* and tract ends blindly at or close to lateral pharyngeal wall and in fact, in true sense it is a "branchial sinus"
- Occasionally inner opening of fistula may be present on the lateral pharyngeal wall behind the tonsil.
- The fistulous tract is lined by ciliated columnar epithelium.

Treatment

Treatment consist of complete excision of the tract. Complete removal is necessary to prevent recurrence.

3. Cystic Hygroma (Lymphangioma) (NEET)

It is a multilocular cystic swelling of clear lymph and considered as a benign lymphatic tumour.

Etiology

- Cystic *hygroma develops as a result of sequestration of a portion of the jugular lymph sac in the neck from the lymphatic system.* (NEET)
- *Cystic hygroma has been found in association with Turner's syndrome.* (PGME)

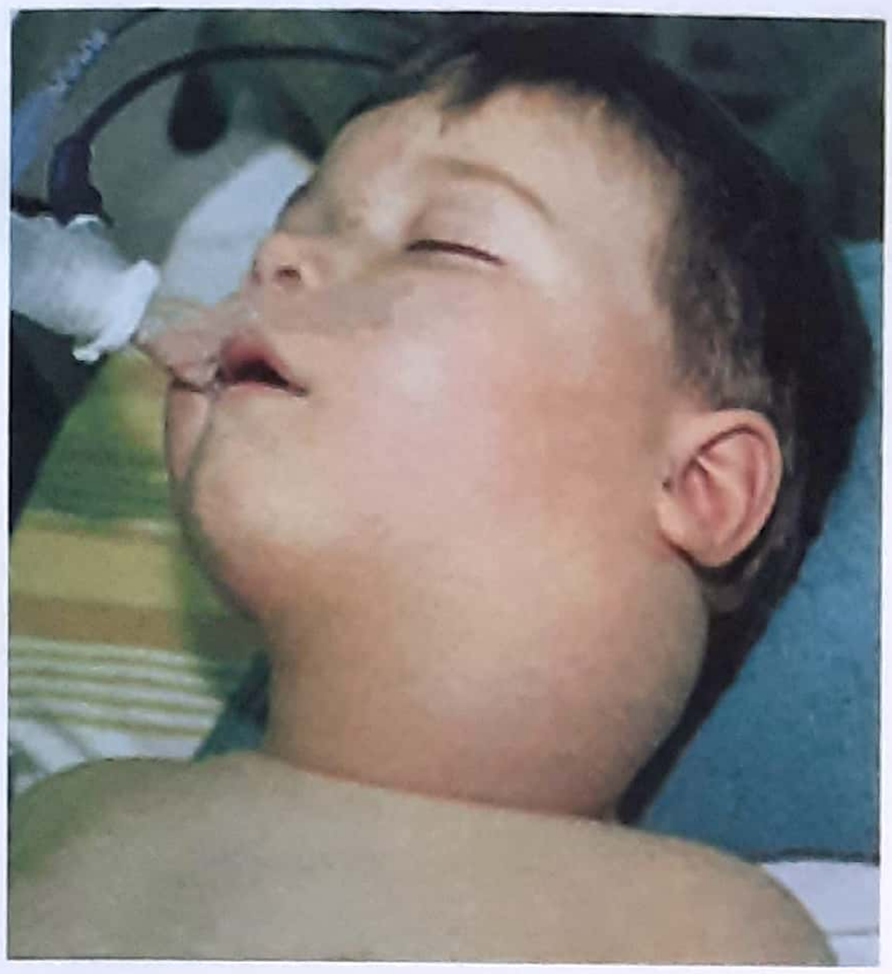

Figure 19.5: Cystic hygroma

Pathology

- The lesion consists of *multilocular cysts,* deeper the cysts smaller is their size, and if it presents as a single swelling, it is called as *hydrocele of neck.*
- Apart from the neck, it may also be present in thorax, axilla, abdomen, tongue and groin Figure 19.5 & 19.6 a & b.
- The cysts are lined by endothelium.
- Cystic hygroma does not undergo malignant change.
- Some times, spontaneous regression of a cystic hygroma can occur.

Clinical feature

- It usually manifests in the neonate or in early infancy, and occasionally may be present at birth and at time may be so large as to obstruct labour.
- *It's* ***usual position is at the lower third of neck in the posterior triangle.*** (NEET, IMP. POINT)
- The female newborn is more commonly affected.
- **Impulse on coughing is present** ie; swelling increases in size when the child coughs or cries. (IMP. POINT)
- It is painless, soft, partially *compressible,* fluctuating and *brilliantly transilluminant swelling.*
- The behavior of cystic hygroma in an infant is difficult to predict, it may enlarge rapidly to cause respiratory tract obstruction, demanding aspiration of the cyst content and even at times an emergency tracheostomy.

Treatment

1. *Conservative* About 25% *of small cystic hygroma regresses spontaneously.* It is reasonable to delay treatment of small lesion that are not symptomatic, enlarging or disfiguring.
2. *Aspiration and injection* of bleomycin may be useful. Recently sclerosing agent like picibanil (OK-432) reduce the size of lesion.
3. ***Surgical excision*** It is **still the mainstay of treatment.** (NEET) Early surgery is technically easier. Recurrence rate range between 5-15%.
4. *Laser* It is used for intralaryngeal extension of cystic hygroma, which is life threatening and is difficult to treat.

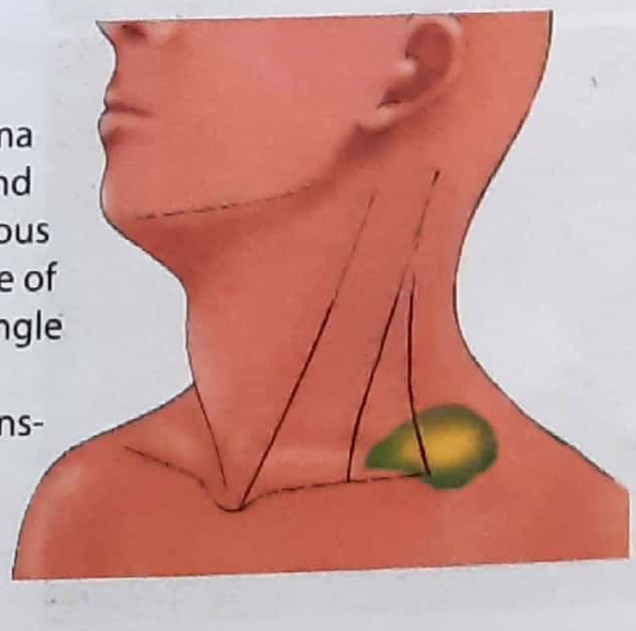

Figure 19.6 (a) : Cystic hygroma

Figure 19.6 (b) : Cystic hygroma on soft tissue ultrasonography

4. Carotid body tumour

(Potato tumour, Chemodectoma, non-chromophin paraganglionoma)

- This is a rare neurogenic tumour, *arising from the chemoreceptor cells on the medial side of the carotid bulb.* Please see figure 19.7(a).
- The chemoreceptors respond to change in blood oxygen and carbondioxide tension.
- Chronic hypoxia, leads to hyperplasia of these chemorepceptors, and that is why its incidence is higher in high altitude natives.

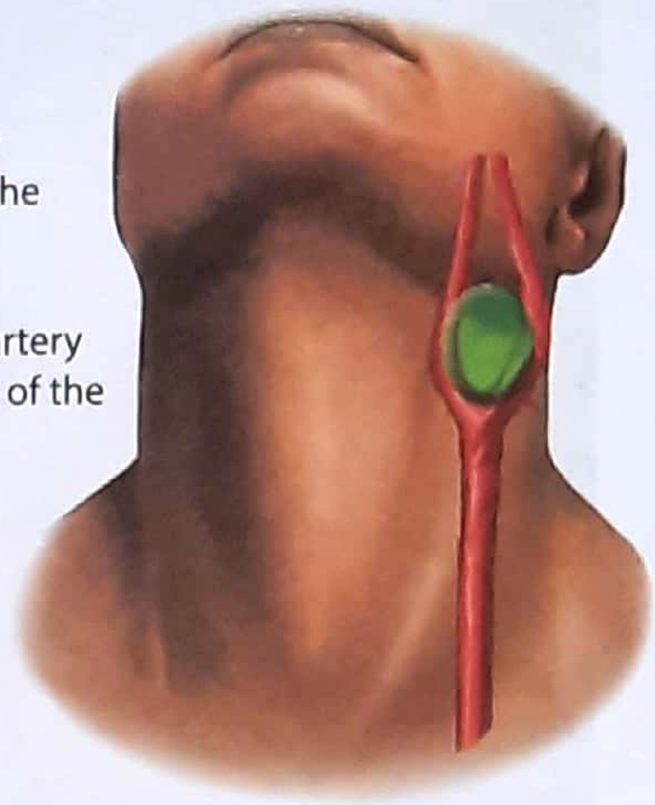

Figure 19.7 (a) : Carotid body tumour

Pathology

- The tumour is well encapsulated. It looks yellow or orange on cut surface. This is a firm and compact tumour and **appears like a potato,** hence called as "potato tumour". (Figure 19.7b)
- It is firmly adherent to the carotid artery and it is often impossible to excise the tumour without sacrificing part of common, internal or external carotid artery.
- The tumour is composed of characteristic cell nests, and alveolar arrangements of chief cells.
- It is a benign and hormonally inactive tumour, and in about 5-10% regional metastases can occur.

Clinical feature

- The tumour commonly presents in **the fifth decade of life with equal frequency in men and women.** (NEET) In about 10% familial incidence is noticed, and when familial it is bilateral in 30% cases.

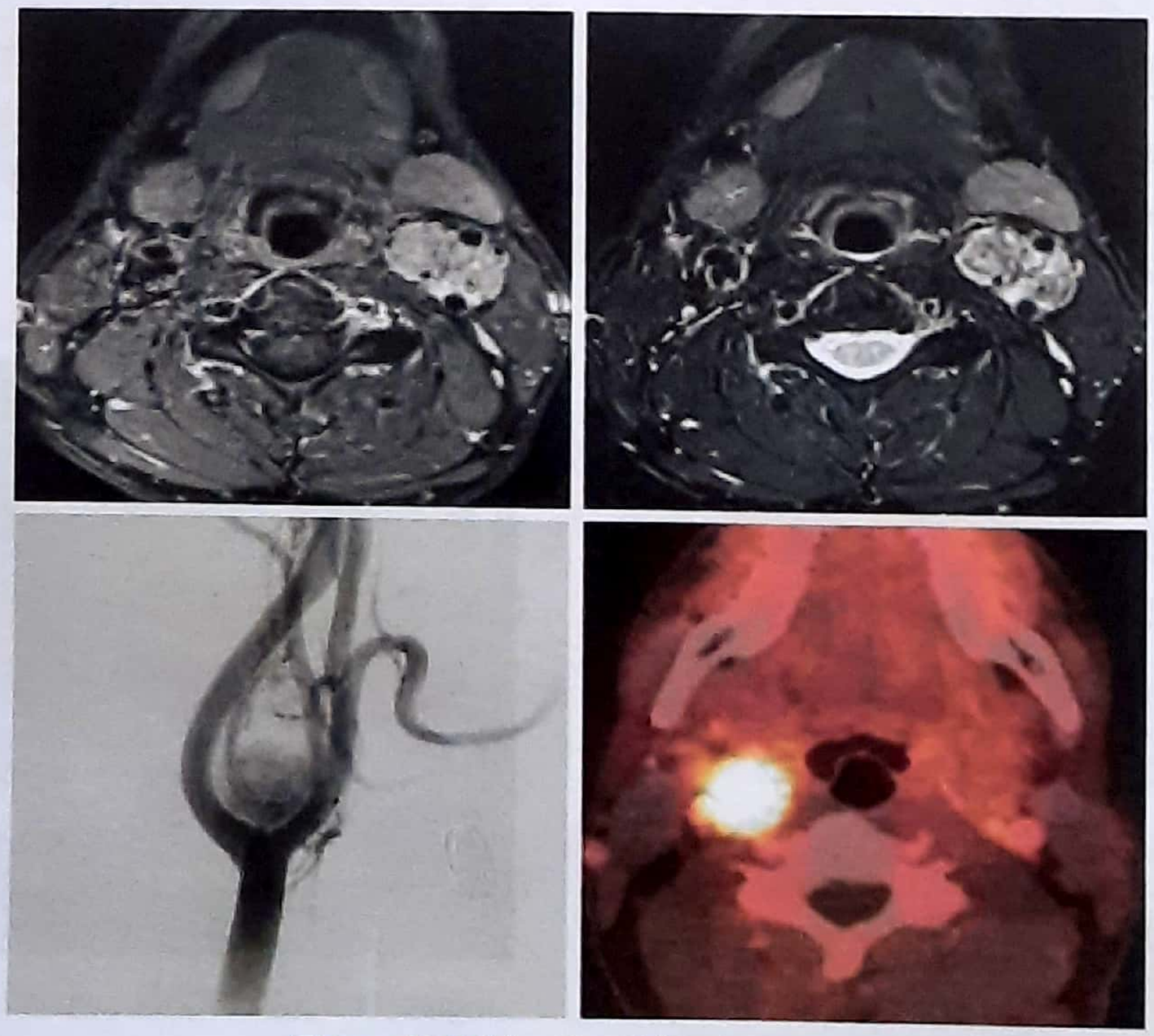

Figure 19.7 (b): Carotid body tumour

- In majority of cases it is unilateral but occasionally, bilateral tumours may be seen.
- The patient presents with a *long history (in years) of a very slowly enlarging painless lump in the lateral side of neck.* (IMP. POINT)
- The lump is firm, rubbery, pulsatile and is situated beneath the *anterior border of sternocleidomastoid.*
- It is a round tumour and is mobile from side to side *but not* up and down. (PGME)
- In l/3rd of cases the tumour is deep to the bifurcation of the carotid artery and first symptoms may be due to compression of esophagus and larynx. Some patients may present with Horner's syndrome.

Investigation

1. Duplex study.
2. Carotid arteriography to demonstrate the carotid bifurcation, which is usually splayed.
3. FNAC is **contraindicated** for fear of hemorrhage and pseudoaneurysm formation.
4. CT/**MRI Scan**: They **delineate the extent of the tumour and its relationship to surrounding structures.** (NEET)

Treatment

- Surgical excision is the only treatment.
- Because these tumours are **very slow growing** and rarely metastasize, the need for surgical removal must be **considered carefully,** because complication of surgery are potentially serious. The **operation is best avoided in elderly patients,** because most patients will outlive the tumour, but in patients below 50 years the ideal treatment is surgical excision. (PGME)
- Radiotherapy has no role, as this tumour is radioresistant.

5. Sternomastoid tumour (Congenital torticollis) (AIIMS 10, 06)

Though it is called as congenital torticollis, yet it is **not a true congenital abnormality.** The mother may notice a swelling in the neck of the infant at birth or in first few weeks of life. She may also complains that the **face and the neck is turned to one side,** and the deformity is not corrected voluntarily. The lilt becomes more obvious, when the length of neck grows ie; after the age of about 4 years.

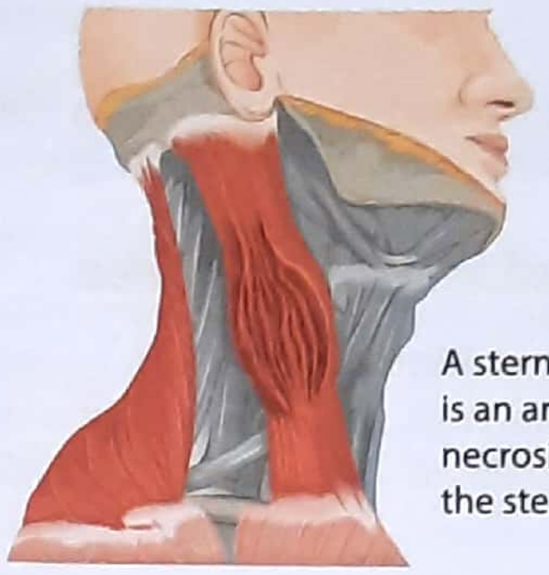

A sternomastoid tumour is an area of oedema and necrosis in the lower third of the sternomastoid muscle.

Figure 19.8: Location of sternomastoid tumour

- It is a fusiform palpable swelling, usually in the lower third of sternocleidomastoid muscle (Figure 19.8)
- In the beginning, the swelling is firm but gradually becomes hard and shrinks and become impalpable.
- It results due to birth trauma consisting of edema and hematoma formation, which is gradually replaced by fibrous tissue, which later contract the affected sternocleidomastoid muscle; resulting in torticollis.

Treatment

In about 80% children operative treatment is not required and spontaneous resolution occus; which is helped by physiotherapy, but operation is the only treatment when the torticollis has developed, the best technique is to divide sternocleidomastoid at the lower attachment at the clavicular end, followed by fitting of corrective brace for 2-3 months, followed with strict physiotherapy schedule.

Figure 19.9: A boy with congenital torticollis

Torticollis?

A deformity of neck, which tilts head to one side, with the chin pointing to the opposite side. (Fig 19.9)

6. Cervical rib and Scalene syndrome

- A cervical rib, **is an additional rib,** which arises from the 7th cervical vertebra and is usually attached to first rib anteriorly closed to the insertion of scalenus anterior.
- This anomaly is present *only is less than 0.5 percent of population* and only 10 percent of them are symptomatic.
- It may be a complete rib with a joint or an incomplete rib attached to first rib by a fibrous band.

Clinical feature

- **In 90% cases with cervical rib, there is no symptom** and diagnosis of cervical rib is made only on X-ray for some other disease.

KEY BOX 19.3		
Situation : Exact site of the swelling is very useful for diagnosis		
1.	Parotid gland	Parotid region
2.	Branchial cyst	At upper third of anterior triangle at level of hyoid bone
3.	Submandibular gland	In submandibular triangle
4.	Carotid body tumour	In carotid triangle
5.	Pharyngeal pouch	Posterior triangle at level of cricoid cartilage
6.	Sternomastoid tumour	Along middle third of sternomastoid muscle
7.	Cystic hygroma	Lower part of posterior triangle
8.	Sublingual dermoid	In submental triangle
9.	Thyroglossal cyst	Anteriorly in midline in vicinity of hyoid bone
10.	Thyroid swelling	In thyroid region
11.	Carotid-aneurysm	Along course of the carotid-artery
12.	Cervical rib	In lower part of posterior-triangle
13.	Lymph nodes	Anywhere in the neck

A cervical rib rarely causes a visible swelling. It may cause a subclavian artery aneurysm

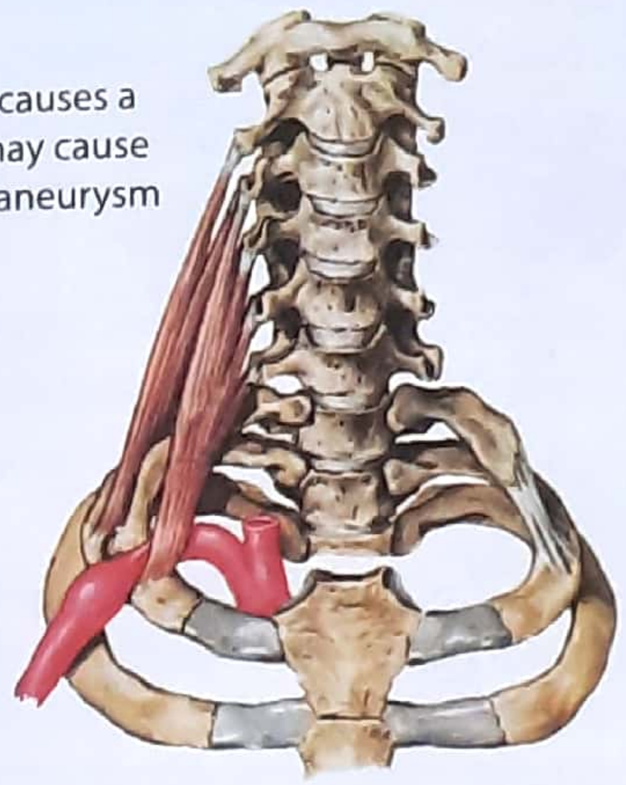

Figure 19.10 (a): The site of cervical rib

- Occasionally a *bony hard lump* may be felt in posterior triangle of the neck. See figure -19.10(a) and 19.10 (b).
- Only about 10 percent patients with cervical rib have symptoms, which can be **divided in two groups:**
  - (A) Nerve compression symptoms
  - (B) Vascular symptoms

Figure 19.10 (b) : The Cervical rib

(A) Nerve compression symptoms

It is due to compression of lower trunk of branchial plexus (C8-T1) by cervical rib (PGME). The symptoms are pain and paraesthesia along the medial aspect of forearm, and in the ring and little finger, which is some times relieved by raising the arm and shoulder. There may be associated weakness, paralysis and atrophy of muscles of hand and forearm.

(B) Vascular symptoms

Patient complains of pain, numbness in forearm and hand. Colour changes, such as pallor and cyanosis may be present on keeping the arm elevated or dependent respectively.- A cervical rib may produce subclavian artery aneurysm. Raynaud's phenomena may also be present.

Examination

- Look for the signs of chronic ischemia.
- A bony hard lump can be palpated in posterior triangle of neck.
- **ADSON'S TEST**: In patient with a cervical rib **adson's test is positive,** (method described below)

Method: The patient is asked to sit and inspire deeply, and extend his head backward and turn his face to affected side. The radial pulse is palpated, which is felt to become weak or even absent due to compression of subclavian artery. Please read key box 19.4 carefully. Please also see figure 23.18 on page no. 311.

Treatment

In mild cases, shoulder exercises are advised together with analgesics.

Surgery is **indicated** for following :-

- Intense pain not relieved by conservative treatment.
- Atrophy of muscle.
- Sensory loss.
- Patients with vascular symptoms.

Surgical Options

- Cervical sympathectomy
- Scalenotomy: division of scalenus anterior muscle or band
- Extra periosteal resection of cervical rib

Friends, I have discussed common swellings of neck in this chapter. Submandibular salivary gland enlargement, Laryngocele, pharyngeal pouch have been discussed elsewhere in this book.

****

CERVICAL LYPMHADENOPATHY

Cervical lymph adenopathy may be of ***three types, ie; Inflammatory, infective and neoplastic.*** Among all causes **tubercular lymphadenitis is the most common cause of enlarged cervical lymph node in India,** and *most commonly enlarged lymph node is jugulodigastric group of lymph node.*

KEY BOX 19.4

Test	Maneuver	Result
ADSON TEST	Affected arm is abducted 30° at the shoulder while maximally extended. While extending the neck and turning head towards ipsilateral shoulder, patient inhales deeply	Decrease or absence of ipsilateral radial pulse
Elevated Arm Stress Test (EAST) or ROOS	Arms are placed in the surrender position with shoulders abducted to 90° and in external rotation, with elbows flexed to 90°. Patient slowly opens and closes hand for 3 min	Precipitates pain, paresthesias, heaviness or weakness
Upper Limb Tension Test (ULTT) or ELVEY	Position 1: arms abducted to 90° with elbows flexed Position 2: active dorsiflexion of both wrists Position 3: head is tilted ear to shoulder, in both directions	Positions 1 and 2 elicit symptoms on the ipsilateral side, while position 3 elicits symptoms on the contralateral side

In fact, in India any neck swelling in children and young adult should be considered as enlarged tubercular lymph node until proven otherwise.

Etiology

Inflammatory and Infective

1. Acute infection in draining area
2. Tuberculosis (M/C)
3. Syphilis
4. Infectious mononucleosis
5. Toxoplasmosis
6. Cytomegalovirus
7. Measles
8. Filariasis
9. Actinomycosis'

Neoplastic

1. Primary

- Leukemia
- Lymphoma*
- Hodgkin's disease

2. Secondary

- From distant organs: (most common to supraclavicular lymph node)

Miscellaneous: Sarcoidosis

NOTE: *Most common cause of a neck swelling is an enlarged lymph node (MANY PGME).*

Examination (IMPORTANT FOR VIVA EXAM)

Palpation of the neck glands can be performed both from the front and behind. However it should ideally be performed from the back by standing behind the patient **as follows:**

- The patient is seated comfortably on the table, and his head is flexed on the side to be examined (so as to relax the muscles and the deep fascia). The examiner palpates the relaxed side of the neck by the same hand ie; right hand for the right side of the neck and vice versa; and at the same time, examiner keeps his other hand on the head of the patient.
- Palpation is commenced first with the flat of the fingers to find out the presence of any lump. The next step is to palpate each swelling with tips of the fingers for tenderness, surface, edge, consistency, etc. Neck nodes are palpated systematically as follows:

(A) Superficial group

1. Submental
2. Submandibular
3. Preauricular
4. Postauricular
5. External jugular
6. Occipital

(B) Deep group

(Lying in relation to carotid sheath by the side of pharynx, larynx, trachea, esophagus and subclavian vein)

1. Upper anterior cervical
2. Lower anterior cervical
3. Upper posterior cervical
4. Lower posterior cervical
5. Along spinal accessory
6. Supraclavicular.

Then, the opposite side of the neck is examined in a similar fashion. Further details of cervical lymph nodes are given later in this chapter.

TUBERCULOUS LYMPHADENITIS

Lymphadenitis is most common cause of neck swelling in India. The infections reaches the cervical lymph node from:

1. Tonsil, adenoids and dental caries
2. From apex of lung (air born) and rarely
3. Hematogenous.

When infection comes from tonsil, or adenoid, it involves cortex of the lymph node, while medulla of the lymph node is involved, when infection is hematogenous.

Pathology

Classically, four stages are identified; which may progress over weeks to months.

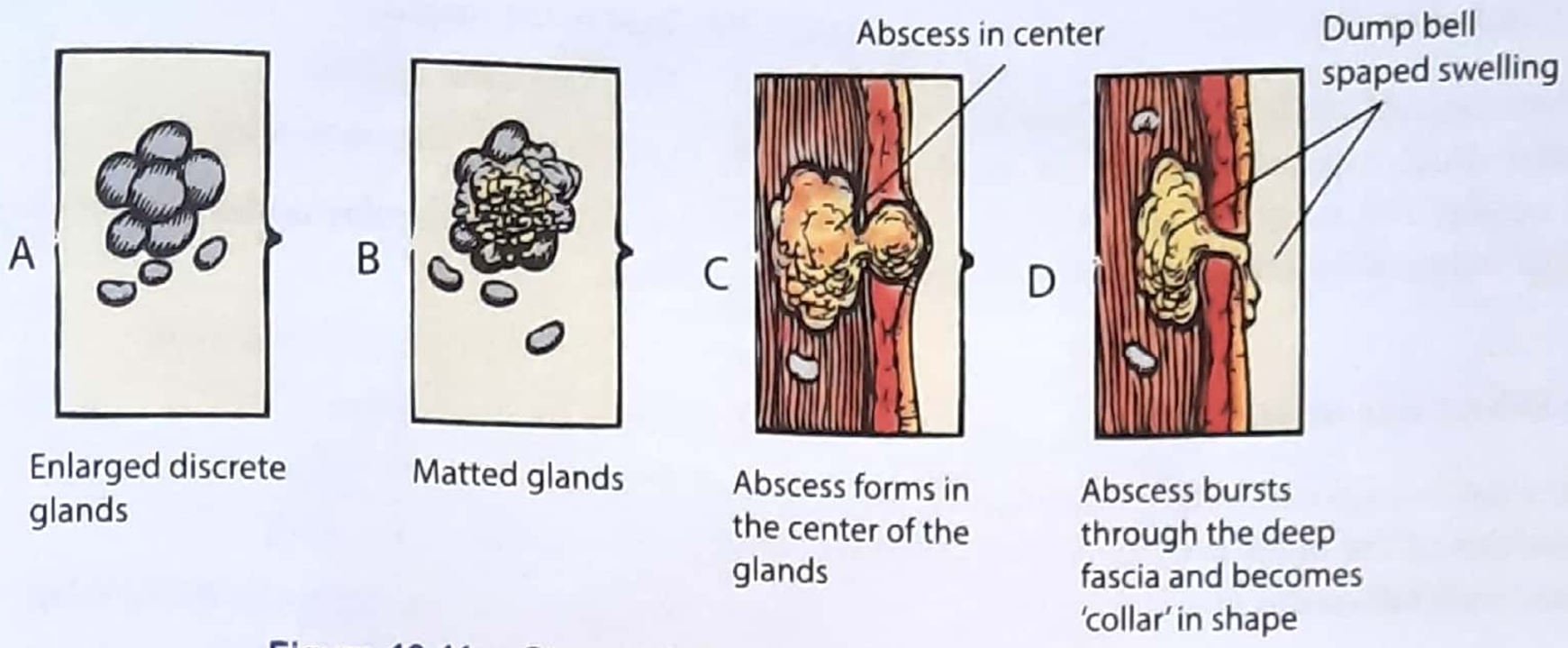

Figure 19.11: Stages of tuberculous lymphadenitis

Stage I

The lymph node gets ***Simply enlarged,*** remains discrete and are not matted. See figure 19.11A.

Stage II

With the advent of lymphadenitis the enlarged lymph nodes become adherent to each other: called as ****matted lymph nodes.*** See figure 19.11B.

* *(MATTED)* for understanding : On examining lymph node, they appear as if you are moving hands over bunch of grapes or moving hand on a mat (for hindi speakers; chatai).

Stage III

This is stage of ***Cold abscess formation.*** Cold abscess formation occurs due to caseation within the lymph nodes (Fig 19.11C). In the beginning, the cold, abscess remains deep to the deep fascia, after a few weeks, the deep fascia becomes eroded at one point and pus flows through this small opening from deep fascia to superficial fascia, giving away dumb bell like arrangement and is termed as COLLAR STUD ABSCESS. Please see figure 19.11C.

Stage IV

The abscess gradually enlarges and may burst resulting in ***Chronic discharging sinus or ulcer*** formation. 19.11D.

Clinical feature

- Though it can occur in all age group, the disease is more common in malnourished children and young adult
- Often history of contact with a tubercular patient is present.
- Constitutional features such as malaise, lassitude, evening rise fever with sweats, anemia and loss of weight may be present.
- There may be history suggestive of pulmonary T.B. such as cough and hemoptysis.
- Weight toss is a very common feature.

Investigation

1. **Blood Examination** TLC/DLC, lymphocytosis, ESR is raised.
2. **Mantoux test** is positive, however a negative Mantoux test does not rule out tuberculosis.
3. **X ray chest** for pulmonary tuberculosis
4. **Tubercular ELISA** has high sensitivity and specificity, upto 80-90%.
5. PCR has now become most sensitive *non-invasive* test.
6. **Excisional biopsy** This is done, when there is doubt about the diagnosis.

Treatment

The treatment depends upon the clinical stage, at the time of presentation:

Stage I and II

Patient should be given Antitubercular drugs for at least 6 months. If there is no change in the size of swelling, excision of the swelling should be done.

Stage III (Cold abscess)

The treatment for cold abscess is aspiration followed by antitubercular drug. Aspiration should be done with a wide bore needle. For recurrent cold abscess, incision and drainage followed by curettage of abscess cavity is done.

Stage IV (Tubercular sinus)

Tubercular sinus is explored, after encircling the sinus tract and excision of the whole tract along with caseating node is done, with full course of ATT.

****

LYMPHATICS OF THE NECK

The lymphatics of "the neck are arranged into

A. Deep arid

B. Superficial chains.

(A) Deep nodes

These are organized into

- Superior deep jugular (cervical) nodes
- Middle deep jugular (cervical) nodes
- Inferior deep jugular (cervical) nodes
- Retropharyngeal nodes
- Paratracheal nodes
- Infrahyoid, prelaryngeal and pretracheal nodes.
- Lingual nodes.

The deep jugular chain extends from the base of the skull to the clavicle and is formed into

- Superior deep jugular nodes
- Middle deep jugular nodes and
- Inferior deep jugular groups of lymph nodes

The superior deep jugular nodes receive primary drainage from the

1. Soft palate
2. Tonsils
3. Palatoglossal arch
4. Palatopharyngeal arch
5. Posterior tongue
6. Base of the tongue
7. Pyriform sinus and the
8. Larynx above the vocal folds

The middle deep jugular nodes receive primary drainage from:

1. The larynx above the vocal folds
2. Lower pyriform sinus
3. Posterior cricoid
4. Secondary drainage from
   (a) The deep jugular nodes above them
   (b) And the lower retropharyngeal nodes

The inferior deep jugular nodes receive primary drainage from:-

1. The thyroid
2. Trachea and
3. Cervical esophagus.
4. Secondary drainage from
   (a) The deep jugular nodes above
   (b) The paratracheal nodes.

The **retropharyngeal and paratracheal nodes** lie posteriorly around the midline viscera and receive drainage from:

1. Midline viscera
2. Deep structures in the midline of the head
3. The nasopharynx
4. Posterior nasal cavity
5. Paranasal sinuses
6. Posterior oropharynx.

They drain towards the deep jugular chain.

(B) Superficial Chains

1. Occipital (retroauricular)
2. Mastoid
3. Superficial Parotid
4. Deep Parotid
5. Preauricular
6. Infraauricular
7. Intraglandular parotid
8. Buccinator
9. Nasolabial
10. Mandibular

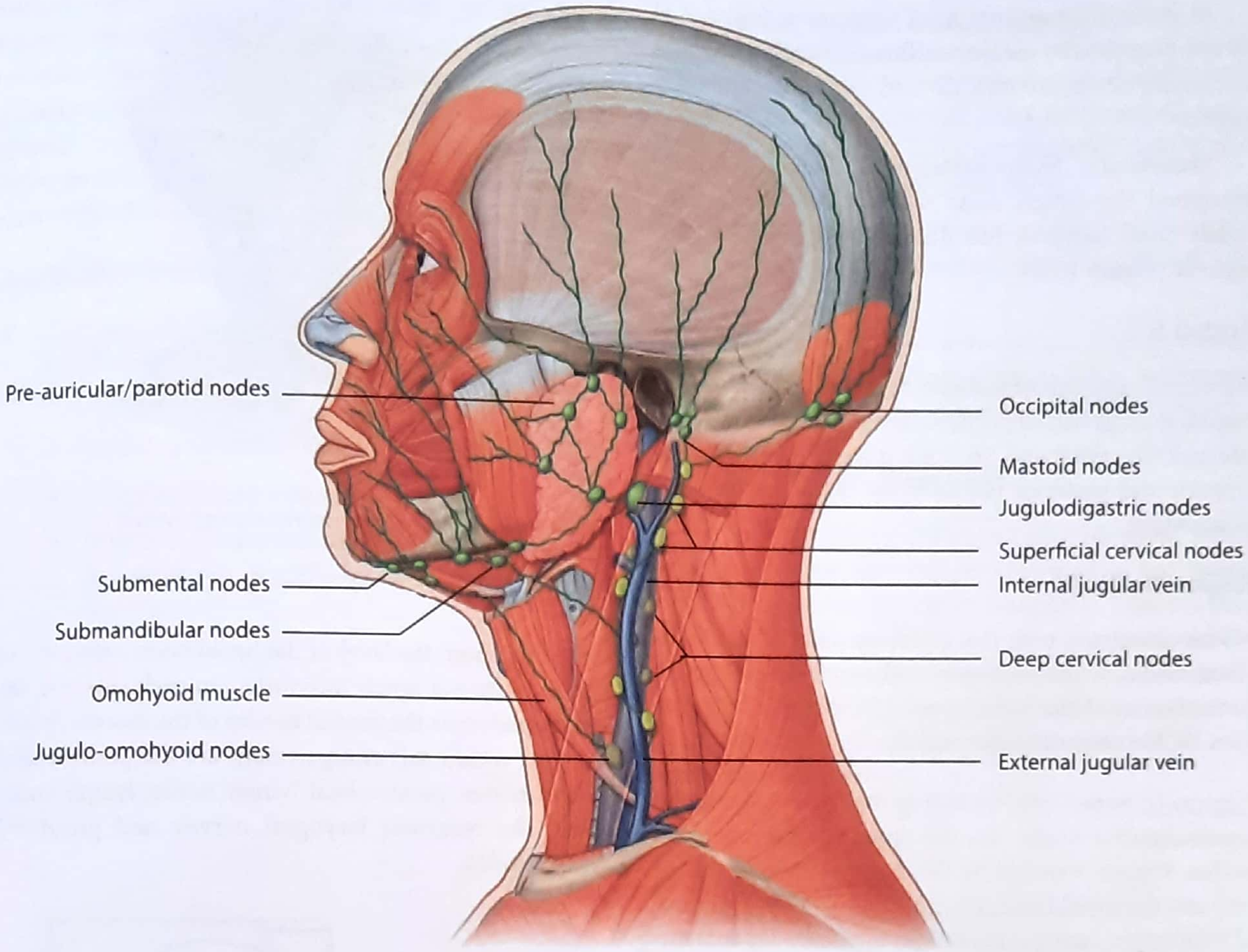

Figure 19.12: Diagrammatic presentation of cervical lymph node

11. Anterior cervical (Superficial jugular)
12. Superficial cervical (External jugular)

To remove the incongruence among various systems of classifications the lymph nodes of neck were later divided in to seven levels (initially only six levels were described later on the seventh was added)

Simplified Nodal Classification

Level 1: Submandibular, submental.

Level II: Internal jugular from skull base to carotid bifurcation.

Level III: Internal jugular below carotid bifurcation to omohyoid.

Level IV: Internal jugular below omohyoid.

Level V: Posterior triangle.

Level VI: Adjacent to thyroid.

Level VII: Tracheal esophageal groove and superior mediastinum

Probable Source of Nodal Metastasis

Level 1: Oral cavity, submandibular gland.

Level 2: Nasal pharynx, oral pharynx, parotid, supraglottic larynx.

Level 3: Oral pharynx, hypopharynx, supraglottic larynx.

Level 4: Subglottic larynx, hypopharynx, esophagus, thyroid.

Level 5: Nasal pharynx, oral pharynx.

Level 6 & 7: Thyroid, larynx, lung.

At present the system most commonly followed is the one proposed by **memorial Sloan Kettering hospital** and lymph nodes are now divided in to six anatomical regions

Memorial Sloan-Kettering Cancer Center developed the lymph node regional definitions most widely used today. It has divided lymph nodes in 6 regions: (Figure 19.13)

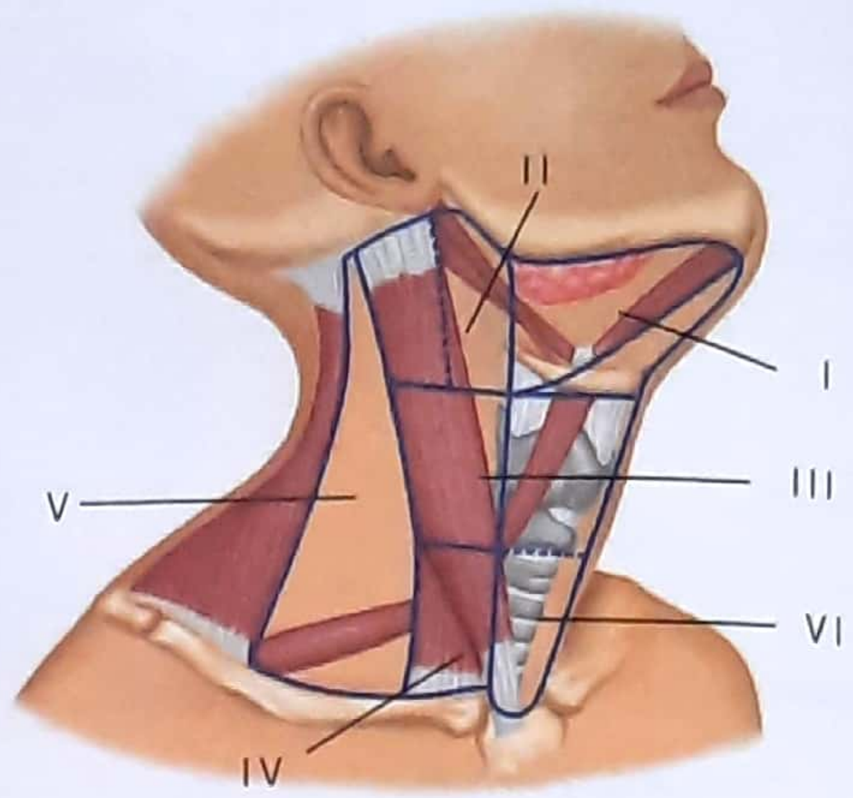

Figure 19.13: Levels of cervical lymph nodes

Region I:

Submental and submandibular triangles. **Ia** is the submental triangle bound by the anterior bellies of the digastric and the mylohyoid. **Ib** is the triangle formed by the anterior and posterior bellies of the digastric and body of mandible.

Region II, III, IV:

Nodes associated with the IJV; fibro adipose tissue located medial to the posterior border of SCM and lateral to the border of the sternohyoid. (IJV = Internal jugular vein, SCM= sternocleidomastoid)

Region II: upper third including the upper jugular and jugulodigastric nodes and the upper posterior cervical nodes. Region bounded by the digastric muscle superiorly and the hyoid Jyane (clinical landmark) or the carotid bifurcation (surgical landmark) interiorly. **IIa** contains nodes in the region anterior to the spinal accessory nerve and **IIb** posterior to the spinal accessory nerve.

Region III: middle third jugular nodes extending from the carotid bifurcation superiorly to the cricothyroid notch (clinical landmark) or omohyoid muscle (surgical landmark).

Region IV: lower jugular nodes extending from the omohyoid muscle superiorly to the clavicle interiorly.

Region V:

Posterior triangle group of lymph nodes located along the lower half of the spinal accessory nerve and the transverse cervical artery. The supraclavicular nodes are also included .in this group. The posterior boundary is (he anterior border of the trapezius muscle, the anterior boundary is the posterior border of the sternocleidomastoid muscle, and the Inferior boundary is the clavicle.

Region VI:

Anterior compartment group comprises lymph-nodes surrounding the midline visceral structures of the neck extending from the level of the hyoid bone superiorly to the suprasternal notch inferiorly. On each side, the lateral boundary is the medial border of the carotid sheath. Located within this compartment are the perithyroidal lymph nodes, paratracheal lymph nodes, lymph nodes along the recurrent laryngeal nerves, and precricoid lymph nodes.

****

CERVICAL LYMPH NODE DISSECTION

Cervical lymph node dissection is done in cases of malignancies of head and neck regions, that have metastasized to the cervical lymph nodes. The current classification and nomenclature of cervical dissection is described below:

1. Radical neck dissection *(PGI 07)*

This is the standard basic procedure for cervical lymphadenectomy, and all other procedures represent one or more modifications to this procedure. Originally described by Crile in 1906, this procedure is an en bloc clearance of:

- All fibro fatty tissue from one side of the neck
- The lymph nodes from levels I-V & lymph nodes that surround the tail of the parotid gland
- The spinal accessory nerve
- The internal jugular vein
- Sternocleidomastoid muscle

Radical neck dissection does not include the removal of the postauricular, suboccipital, perifacial, buccinators, retropharyngeal, or central compartment nodes. This procedure is now limited to patients with advanced neck disease, recurrent disease after chemoradiation or gross extracapsular spread to the spinal accessory nerve, sternomastoid muscle and the internal jugular vein.

Post Radical Neck dissection Shoulder Syndrome:

- Occurs due to excision of spinal accessory nerve *(MAY BE FUTURE PGME Q)* and resultant ***atrophy of trapezius***. *(NEET)* clinical features are:-
  - In ability to abduct shoulder beyond 90°
  - Chronic shoulder pain
  - Shoulder Girdle deformity — Shoulder drooping deformity & shoulder abduction and external rotation.

2. Modified Radical Neck Dissection

When modification of the radical neck dissection involves *preservation of one or more nonlymphatic structures,* the procedure is termed a modified radical neck dissection. This operation involves the:

- Removal of the same lymph node groups as those involved in the radical neck dissection **(levels I-V)** *(NEET)*
- *Preservation of 1 or more of the 3 nonlymphatic structures: viz; the spinal accessory nerve, the internal jugular vein, and the sternomastoid muscle.* *(NEET)*

3. Selective Neck Dissection

When the modification involves one or more lymph node groups that are routinely removed in the radical neck dissection, the procedure is termed a selective neck dissection. This term refers to a type of neck dissection in which one or more lymph node groups normally removed in a radical neck dissection are preserved. Selective neck dissections are further classified into the following categories:

Lymph nodes dissected
Levels I-V

Other structures excised
Sternocleidomastoid muscle
Internal jugular vein
Spinal accessory nerve
Submandibular gland

Classical radical neck dissection

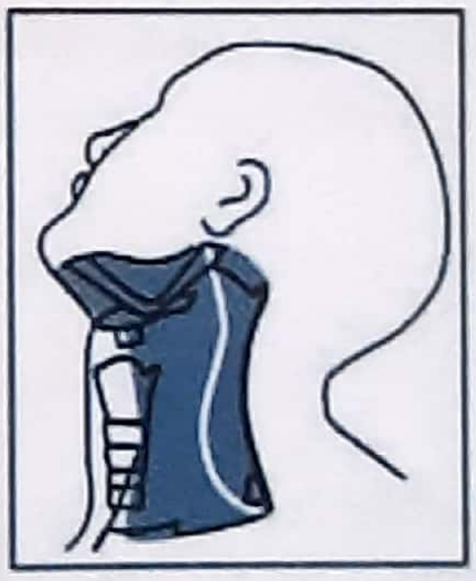

Lymph nodes dissected
Levels I-V

Other structures excised
Sternocleidomastoid muscle
Internal jugular vein
Submandibular gland

Structures preserved
Spinal accessory nerve

Modified radical neck dissection Type I

Lymph nodes dissected
Levels I-V

Other structures excised
Internal jugular vein
Submandibular gland

Structures preserved
Sternocleidomastoid muscle
Spinal accessory nerve

Modified radical neck dissection Type II

Lymph nodes dissected
Levels I-V

Other structures excised
Submandibular gland

Structures preserved
Sternocleidomastoid muscle
Internal jugular vein
Spinal accessory nerve

Modified radical neck dissection Type III

Figure 19.14 : Various radical neck dissection

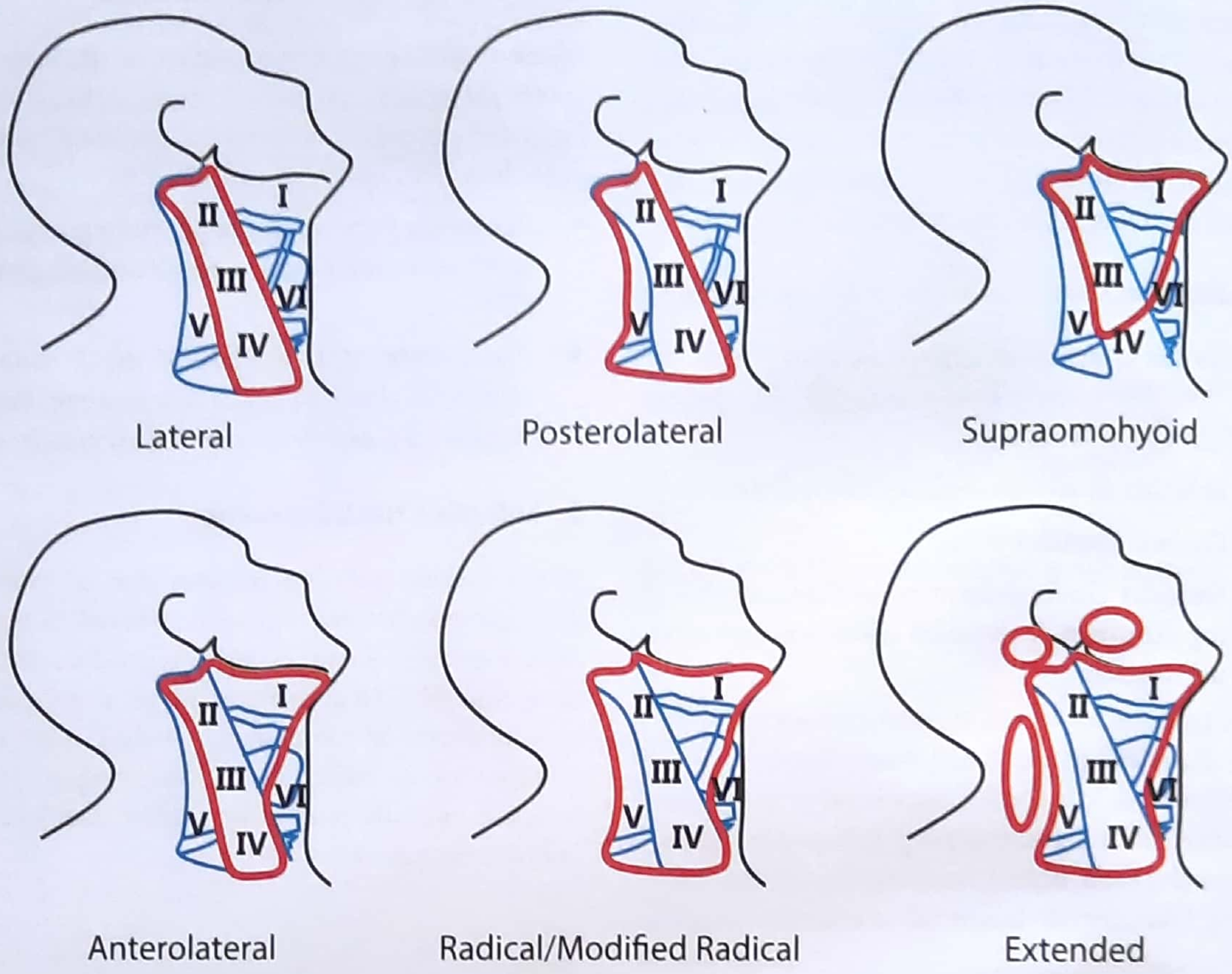

Figure 19.15 : Selective neck dissection

- **Supraomohyoid neck dissection** (levels I, II, III) N0, N1 of oropharyngeal casses.
- Lateral neck dissection (levels II, HI, IV)
- Anterior compartment neck dissection (level VI)
- Posterolateral neck dissection (levels II, III, IV, V)

4. Extended Radical Neck Dissection

When the modification involves removal of additional lymph node groups or nonlymphatic structures relative to the radical neck dissection, the procedure is termed an extended radical neck dissection. In cases of advanced neck disease, certain lymphatic or nonlymphatic structures not routinely included in the aforementioned neck dissections, may have to be removed. Extended neck dissection is the term used to describe these procedures. Retropharyngeal lymph nodes, the hypoglossal nerve, portions of the prevertebral musculature, or the carotid artery and some of the structures that may occasionally have to be excised to obtain negative tumour margins.

****

NOTE: _____

Sample Questions for Prof Examination

1. Mention the cystic swellings of the neck and describe the differential diagnosis of them.
2. Discuss different cystic swellings of the neck.
3. Describe in detail the pathology and clinical features of tuberculous cervical lymphadenitis and outline the treatment.
4. Discuss the differential, diagnosis of cervical lymphadenopathy.
5. Enumerate midline swellings of neck.
6. Discuss lateral swellings of neck.

Write short notes on

7. Thyroglossal cyst.
8. Branchial cyst.
9. Cystic hygroma.
10. Primary thyrotoxicosis.
11. Tubercular cervical lymphadenitis.
12. Thyroglossal cyst.
13. Thyroglossal fistula.
14. Scalenus anticus syndrome, cause and management.

20 The Thyroid Gland

Contents

- Surgical anatomy
- Physiology of thyroid hormone
- Investigation of thyroid disorder
  - Imagine technique
  - Test of function of thyroid
  - Specific test for thyroid
- Goiter
- Disease of thyroid
  - Development and congenital disease
    - Developmental anomalies of shape
    - Development anomalies of position
    - Remnant of thyroglossal duct
  - Disease related to release of thyroid hormone
    - Hyperthyroidism
    - Hypothyroidism
  - Immunological disease of the thyroid
    - Grave's disease
    - Hashimoto's thyroiditis
  - Inflammatory thyroid disease
    - Subacute thyroiditis: De-Quervain's thyroiditis
    - Riedel's thyroiditis
    - Acute (suppurative) thyroiditis
  - Thyroid Neoplasm
    - Benign
      - Solitary thyroid nodule (95% are benign)
      - Follicular Adenoma
    - Malignant
      - Anaplastic carcinoma
      - Medullary carcinoma
      - Malignant lymphoma
      - Medullary carcinoma
- Thyroidectomy
- Solitary thyroid nodule

SURGICAL ANATOMY

- Thyroid is an endocrine gland situated in the lower part of front and sides of neck. Adult thyroid gland is brown in colour and firm in consistency. *It is bilobed gland, joined by an isthmus which overlies the second to fourth tracheal rings.* (PGME)
- The lobes lies lateral to the larynx and trachea, and are in close apposition to them. A third pyramidal lobe may project upwards from isthmus or one of the lobes.
- The gland is enclosed in a sheath of pretracheal fascia, so that it moves on swallowing. Superficially it is covered by the-'sternohyoid and sternothyroid muscles.
- **Suspensory ligament of berry** is a pair of strong condensed connective tissue which binds the gland firmly to each side of cricoid cartilage.
- **The thyroid moves with deglutition due to it's attachment with larynx and trachea by:**

  (i) Ligament of berry

  (ii) Posterior lamina of pre tracheal fascia which is closely adherent to the trachea on the back.

  (iii) A fibro-muscular slip known as levator glandulae thyroidae. Please also see key box 20.1.

- Thyroid hormone regulates the basal metabolic rate, stimulates somatic and psychic growth and plays an important role in calcium metabolism.

Situation and Extent of Thyroid

The gland lies **against vertebral level C-5 to T-l** (POME), clasping the upper part of trachea. Each lobe extends from the middle of thyroid cartilage to the fourth or fifth tracheal ring. The thyroid isthmus extends from *second to third tracheal ring.* The right lobe of the gland is often larger than the left. Please see Figure 20.1 & 20.2 and key box 20.2.

On an average thyroid gland **weight about 20-25gms** (PGME). It is slightly larger in female than male. Size of gland further increases during menstruation and pregnancy.

Arterial Supply

The thyroid gland is supplied mainly by:-

1. **Superior thyroid artery:** Branch of external carotid artery (PGME)

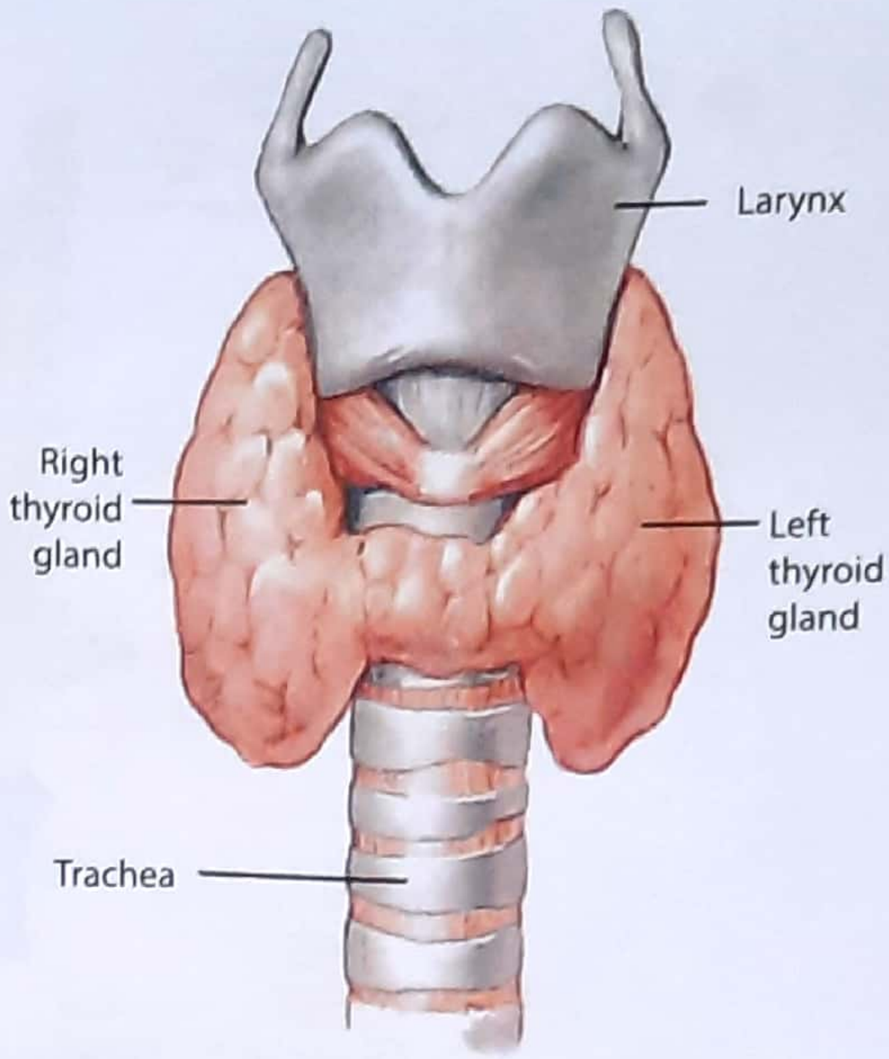

Figure 20.1: Location of thyroid gland

2. **Inferior thyroid artery:** Branch of thyrocervical trunk

3. **Thyroid Ima Artery:** In about 3% individuals the thyroid gland is also supplied by lowest thyroid artery (thyroid Ima artery) which arises from *branchiocephalic trunk* or directly from arch of aorta.

Venous Drainage

1. Superior thyroid vein

It emerges at the upper pole and accompanies the superior thyroid artery. It ends either in the internal jugular vein or in the common facial vein.

2. Middle thyroid vein

This is a short wide channel vessel which emerges at the middle of lobe and soon enters the internal jugular vein.

It is first vessel encountered during thyroidectomy (MANY PGME) and merits careful ligation, when it is met during development of intercapsular space.

3. Inferior thyroid vein

This leaves the lower border of gland and pass through the loose fascial space to join left brachiocephalic vein. They are fragile and require to be ligated singly.

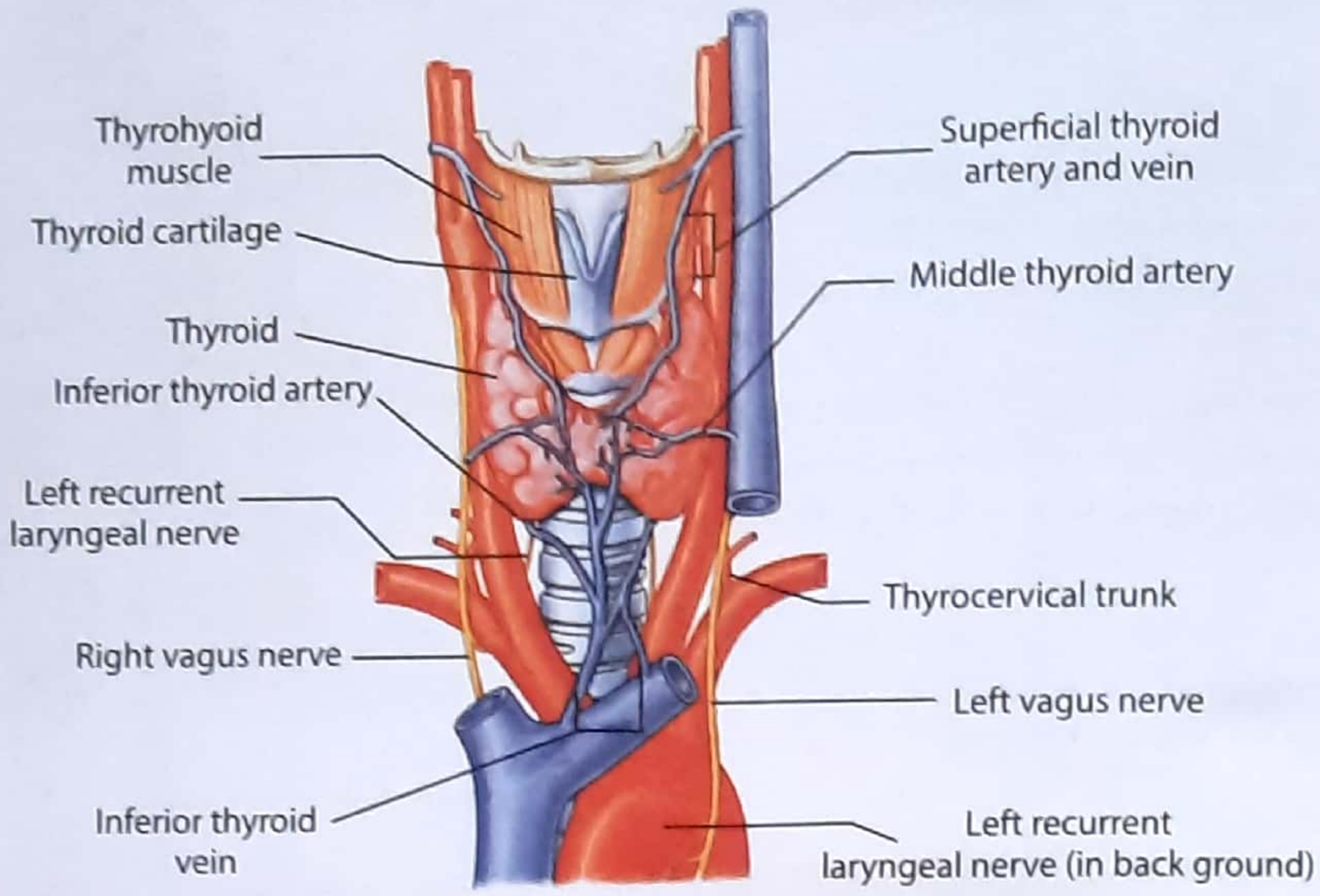

Figure 20.2: Location of thyroid gland with relation

4. Thyroid vein of Kocher

It may emerge between the middle and inferior thyroid veins, and drain into internal jugular vein.

Lymph drainage

There is extensive lymphatic network within gland. Although some lymph channels pass directly to juxta thyroid ie; pretracheal (delphic) nodes, para tracheal nodes and nodes on the superior and inferior thyroid veins, and from these to deep cervical lymph node and mediastinal lymph node.

DEVELOPMENT

Thyroid gland starts forming in 3rd week of gestation. The thyroid gland develops as an endodermal out growth from midline of the floor of pharynx between the 1st and 2nd pharyngeal pouch. Later this thickening becomes a diverticulum called thyroglossal duct. As development continues the duct elongates, and its distal end becomes bilobed. The duct becomes a solid cord and migrates down the neck; passing either anterior or posterior to developing hyoid bone. By age of 7th week of gestation, it reaches to its final position in relation to larynx and trachea. Meanwhile the solid cord connecting the thyroid to tongue break up and disappears. The site of origin of thyroglossal duct on the tongue remains as a pit called foramen cecum. As a result of epithelial proliferation, the bilobed terminal swelling of the thyroglossal duct expands to form the thyroid gland.

- **The parafollicular 'C' cells** are derived from the 4th **pharyngeal pouch (Ultimo-branchial body)** and migrate from neural crest to thyroid, and lie in the superioposterior region of the gland. (PGME)
- Thyroid follicles appear initially at 8th week and colloid formation begins by the 11th weeks of gestation.

KEY BOX 20.1

Other swelling which move with deglutition

- Sub hyoid bursitis
- Pretracheal and prelaryngeal lymph node
- Thyroglossal cyst

KEY BOX 20.2

IMPORTANT CLOSE RELATION OF THYROID

These are mainly (PGME)

1. Recurrent laryngeal nerve
2. External laryngeal nerve
3. Parathyroid gland

PHYSIOLOGY OF HORMONE SYNTHESIS

- **The average daily iodine requirement is about 0.1 mg,** which can be derived from food such as fish, milk and eggs or as additive in bread and salt.
- In the stomach and jejunum iodine is rapidly converted to iodide and absorbed into blood stream, from where it is distributed uniformly throughout extra cellular space.
- Iodine is actively transported into the thyroid follicular cells by an ATP dependent process. Thyroid is the storage site of greater than 90% of body's iodine content and account for 33% of plasma iodine loss. The remaining plasma iodine is cleared via renal excretion. Small amount of iodine is also excreted in saliva, milk and GI. secretions.

BIOSYNTHESIS OF THYROID HORMONES

1. Iodine in the food is **converted to iodide** in GI tract which is absorbed in blood and transported to thyroid gland. Please go through figure 20.3 & 20.4.

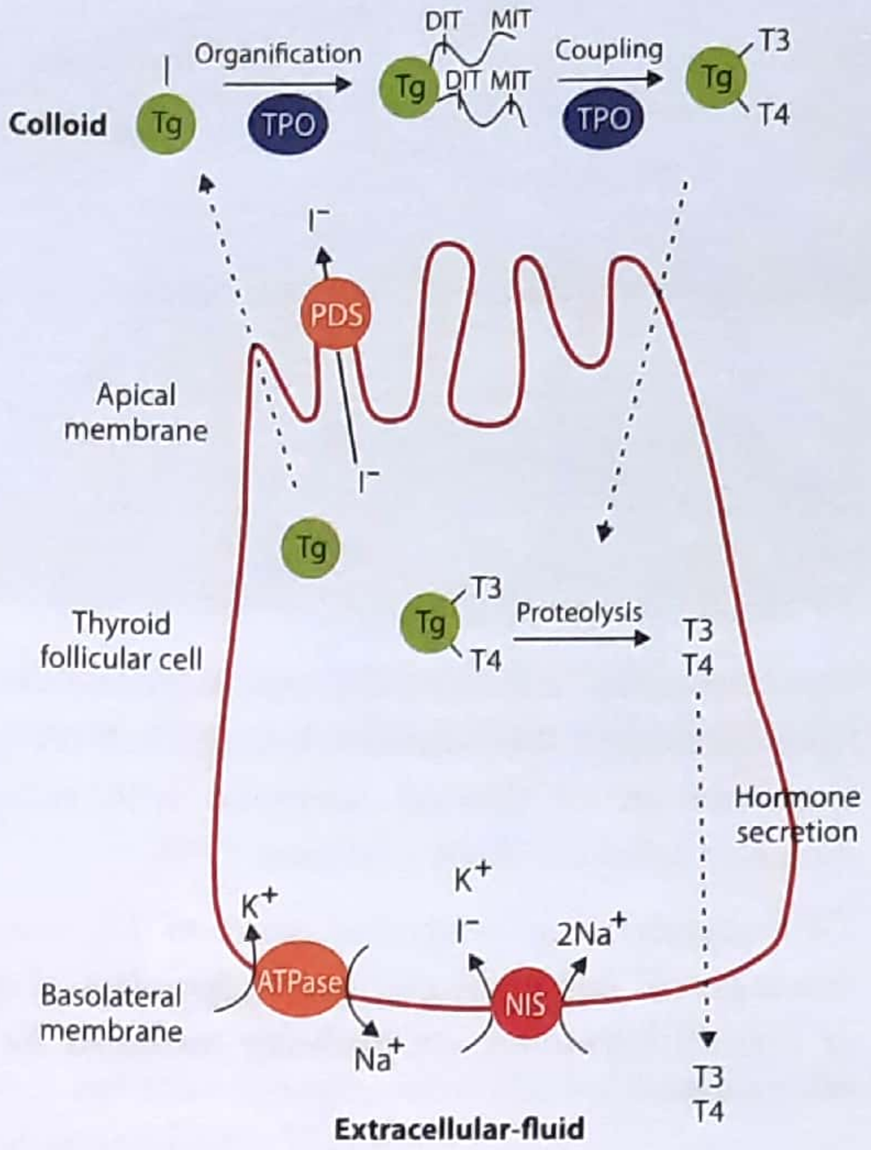

Figure 20.3: Biosynthesis of thyroid hormones

2. *Iodide Trapping*
   - From the blood; iodine is taken up by follicular cells of **thyroid called iodide trapping.**
   - This trapping is against electrochemical gradient and requires energy via an intrinsic membrane protein Na^+ I symporter *(NIS). Perchlorate and pertechnate inhibit iodide trapping and TSH facilitates it.* (PGME)

3. *Oxidation of iodide*

Inside the follicular cells the *iodides are readily oxidized to 'iodine by enzyme peroxidase.* Sulfonamide, PAS, Carbimazole & Propylthiouracil block this step.

4. *Organification*

The follicular cells synthesize thyroglobulin which consists of two units of polypeptide chain. Each polypeptide chain is formed by several tyrosine molecules. Iodine atoms are now attach to tyrosine to form **M**onoiodotyrosine (MIT) and **D**iiodotyrosine (DIT).

5. *Coupling*

The two DIT fuses via ether bonds and forms T_4 (thyroxin). The one DIT and one MIT fuse to form T_3. The T_3 and T_4 still remain attach to thyroglobulin.

- Coupling requires oxidation in presence of peroxidase.
- Coupling is facilitated by TSH and inhibited by anti-thyroid (propylthiouracil and carbimazole) drugs.
- The follicular cells now extrude thyroglobulin containing T_3 or T4 in colloid of acinus, where thyroid hormone is stored.

6. *Release*

When necessary the apical portion of follicular cells engulfs little thyroglobulin from the colloids of acinus.

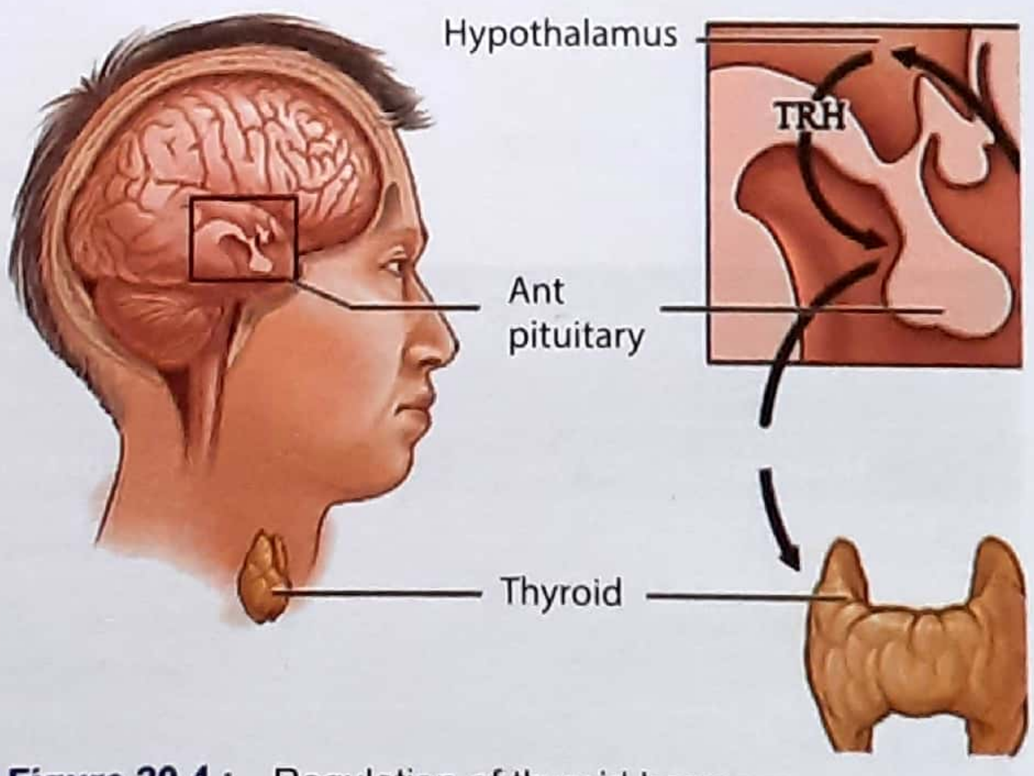

Figure 20.4 : Regulation of thyroid hormone

The engulfed thyroglobulin now fuses with the lysosome of follicular cells and then subjected to proteolysis by a protease enzyme and as a result; T3 or T4 are released into venous blood.

Peripheral Metabolism of Thyroid Hormone

- T4 and T3 are transported in plasma, bound to thyroxin binding globulin and thyroxin binding prealbumin. The *total plasma T4 : T3 rate is about 40:1, because of greater affinity of binding protein to T4 and slower metabolism of T4* (PGME)
- The metabolic effect of thyroid hormone results from binding of the hormone to target cell receptor. Combination of thyroid hormone with receptor *increases cellular mRNA synthesis.* (PGME)
- T4 *is converted in peripheral tissue to T3, which is much potent hormone, and main physiological effect of thyroid hormones are probably mediated by T3.* (MANY PGME)

Recap till now we were discussing brief surgical anatomy and physiology; now we will discuss clinical part:

INVESTIGATION OF THYROID DISORDERS

Initial investigations fall into three groups

A. Imaging techniques
B. Tests of thyroid function; both direct and indirect
C. Investigation concerned with specific identification of thyroid disease. First go through **key Box 20.3**, before going in details:

A. IMAGING TECHNIQUES

1. Radiograph

- Radiograph will show the position and size of the gland, and whether there is deviation or compression of the trachea.
- Dense opacity in a soft tissue shadow of the thyroid will suggests calcification in a multinodular goiter.

2. Ultrasound scan of Neck

This will help to known

1. Whether the swelling in neck is arising from thyroid gland, or some other structure of neck (eg; lymph node).
2. It will also help to determine whether the swelling is cystic or solid in nature.
3. Tells about the size and multicentricity of nodule.
4. Assess cervical lymphadenopathy for metastasis.
5. Help in performing USG guided FNAB (Fine needle aspiration biopsy).
6. Please see USG image in figure 20.5.

3. Radioactive Isotope Scan

It is done for *scanning the size and functional activity of discrete thyroid swellings.* Isotopes commonly used are technetium pertechnate (^{99m}TC) or I^{123} and I^{131}.

On scanning nodule may be of 3 types:

(i) Hot (Overactive) nodule

These nodule takes up isotopes, while surrounding gland does not.

KEY BOX 20.3		
Investigations		
Imaging of the gland	**Test of thyroid function**	**Specific test**
• Radiograph	• Ultra sensitive TSH estimation	• Thyroid antibodies
• Ultrasound scan	• Serum total thyroxine and total tri-iodothyronine	• Fine needle aspiration cytology
• Radio active isotope scan	• Free T4 and free T3 Level	• Tumour markers

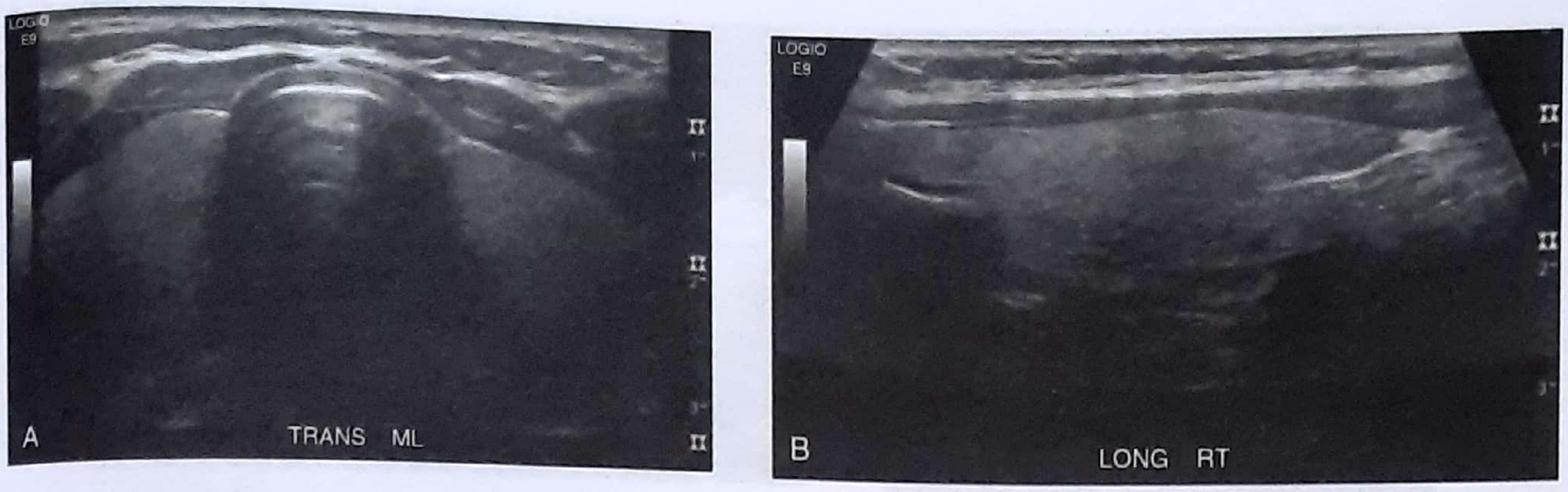

Figure 20.5 : Normal appearance of the thyroid gland on neck ultrasound. Note the homogeneous echogenicity with uniform echotexture of the gland. (A) Transverse midline view with the two lobes on either side of the trachea. (B) Longitudinal view of the right thyroid lobe.

(ii) Warm (active) nodule

It takes up isotope as so does by the normal surrounding thyroid tissue.

(iii) Cold (under active) nodule

It does not take isotope, while the surrounding thyroid tissue does take the isotope.

So Radioactive I_2 ablation is C/I. *(AIIMS MAY 17)*

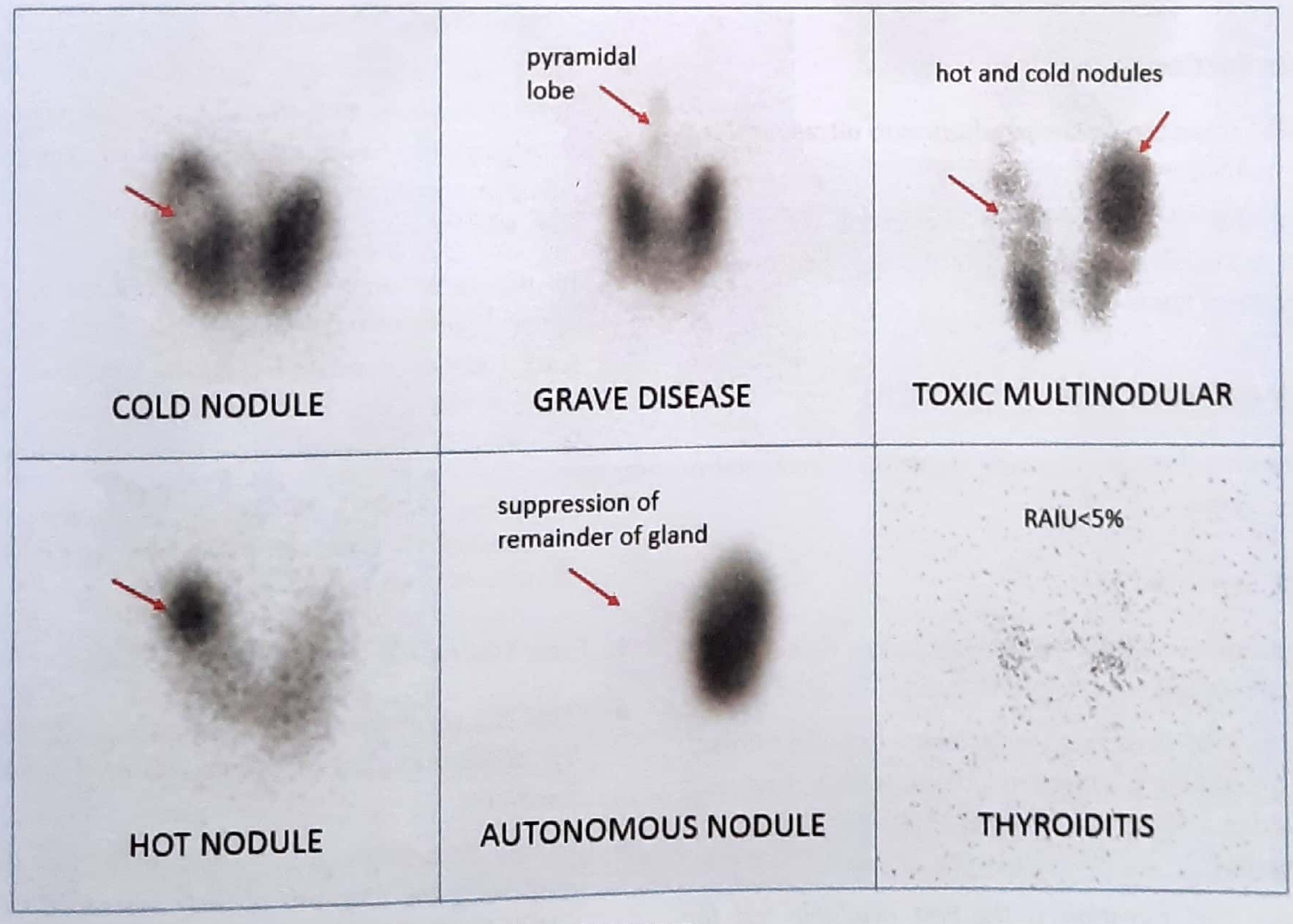

Figure 20.6 : Hot and cold nodule on radio isotope scan

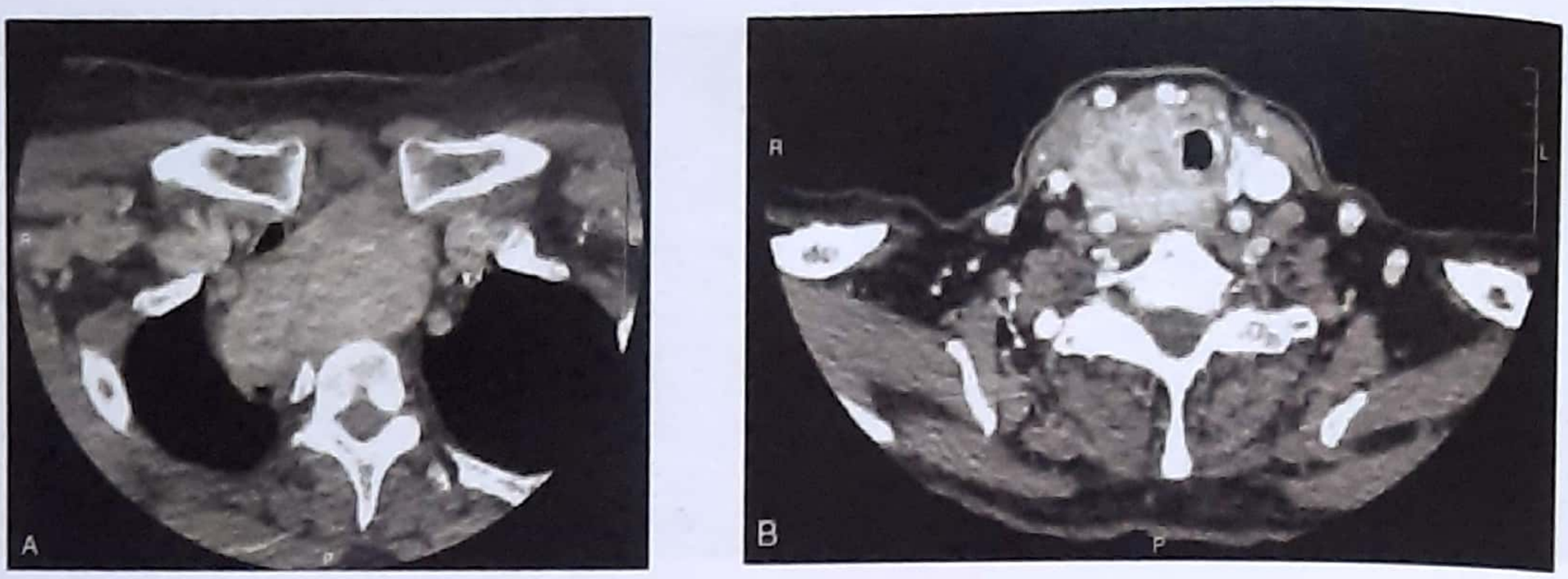

Figure 20.7 : Computed tomography (CT) scans provide useful anatomic information about the thyroid in selected scenarios. (A) Contrast-enhanced CT scan demonstrating a left-sided substernal goiter extending into the posterior mediastinum and crossing over to the right side with tracheal compression and deviation of both the trachea and esophagus. (B) Contrast-enhanced CT scan of a bulky locally advanced follicular thyroid cancer originating in the right lobe with invasion into the lateral tracheal wall and esophagus and obliteration of the right internal jugular vein.

KEY POINT: *About 80% of discrete swelling are cold, but malignancy has been shown to occurs in only 15-20% of all cold nodule.* (NEET, JIPMER 87)

- It is important to note that all warm nodules are not benign; in fact 5% of them are malignant. (IMP POINT)

Please see figure 20.6 and 20.7.1

4. Cross Sectional Imaging

CT or MRI scans can be useful adjuncts to ultrasound for specific indications.

CT is useful for determining the extent of airway invasion & MRI is superior at determining the presence of prevertebral fascia invasion.

B. TEST OF FUNCTION OF THYROID

These tests are directed to know about functional status of thyroid gland.

1. Ultra Sensitive TSH

- Ultrasensitive *serum TSH assay is now first line test for thyroid function* (MANY PGME).
- Serum TSH is elevated in primary hypothyroidism and in pituitary hyperthyroidism, which is usually caused by a *thyrotrop adenoma* of pituitary. (Pituitary *adenoma)*
- *Serum TSH elevation is the best available test for primary hypothyroidism.* (MANY PGME)
- Please see key box 20.4, above on next page.

2. Serum total thyroxine (T4) and total Tri-Iodo thyroxine (T3)

- This is measurement of both free and bound (ie; bound to specific thyroxine binding globulin TBG) component of the hormone.
- *Total T4 levels are increased not only, in hyperthyroidism, but also in patient with increased thyroglobulin level and TBG levels as in pregnancy, estrogen progesterone excess, and oral contraceptive use.* (MANY PGME)
- In the same way, total T. level is decreased in *hypothyroidism and also with decreased thyroglobulin* level caused by anabolic steroid use and protein loosing disorders like nephrotic syndrome, and impaired protein synthesis (eg; hepatic failure).

NOTE: Thyroglobulin is a protein and in these disorders protein is either lost or not synthesized. Note: thyroxine is present in plasma bound to protein.

3. Free T4 and T3 level

- This is a very sensitive test, and accurately measured by radioimmuno assay of biologically active thyroid hormone.
- In free T3 and T4, free *T3 has more place value in confirming the diagnosis of early hyperthyroidism.* In which level of free T4 and free T3 rises before total hormone levels.

KEY BOX 20.4		
Ultrasensitive Serum TSH	**Serum Free T4 and T3 Index**	**Diagnosis**
Elevated	Elevated	Pituitary hyperthyroidism
	Normal	Incipient Primary-Hypothyroidism
	Decreased	Primary Hypothyroidism
Normal	Elevated	Very rare
	Normal	Euthyroid
	Decreased	Pituitary Hypothalamic Hypothyroidism
Decreased	Elevated	Primary Hyperthyroidism (Thyrotoxicosis)
	Normal	Incipient Thyrotoxicosis
	Decreased	Pituitary Hypothalamic Hypothyroidism

Technetium-99m pertechnetate thyroid scan demonstrates normal findings in a thyroid gland



Technetium-99m pertechnetate thyroid scan demonstrates a thyrotoxic goiter (Graves' disease)

Technetium-99m pertechnetate thyroid scan demonstrates a multinodular goiter

Technetium-99m pertechnetate thyroid scan demonstrates an hypersecreting adenoma (autonomous nodule) with increased activity. Uptake in the remainder of the thyroid is suppressed

Figure 20.7.1: Isotope scanning pictures

- Free T3 Level is diagnostic in T3 toxicity in which T4 is normal and TSH is suppressed.

RECAP: Till now we have discussed;

A. Imaging of Thyroid (X-ray, USG neck Isotope Scanning cross sectional imaging.

B. Thyroid Function Test, (TSH assay & T3 & T4 estimation.

Now we will discuss Specific test for thyroid.

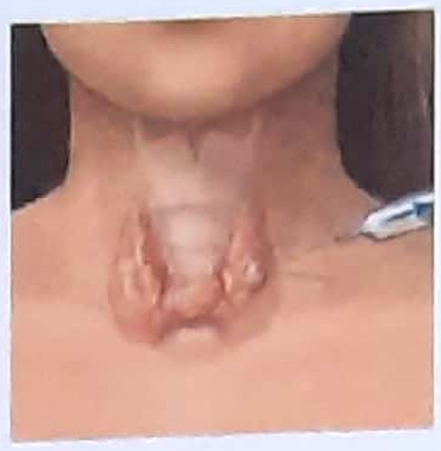

Negative suction created by a syringe in nodule

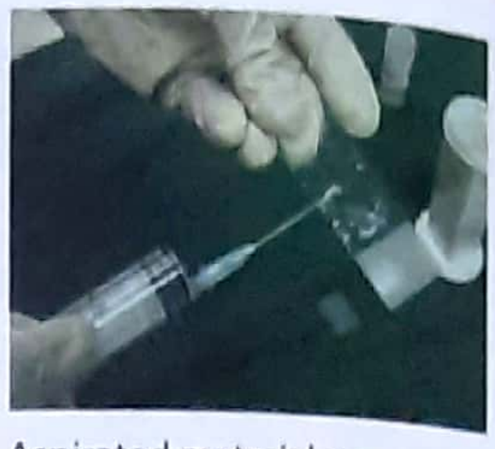

Aspirated material smeared over a glass slide for histo-pathological examination.

Figure 20.8: Method of FNAC

C. SPECIFIC TEST FOR THYROID

1. Thyroid antibodies

Antibodies to thyroglobulin and follicular cell cytoplasm have been detected in various autoimmune disease of thyroid particularly, high titer is found in about 95% of patients with hashimoto's thyroiditis and 80% with grave's disease have detectable antibodies against the TSH receptors.

2. Aspiration and FNAC

- Fine needle aspiration biopsy of the thyroid has become very popular in evaluation of thyroid nodule. *It is now* ***the first investigation test for a thyroid nodule.*** *(NEET, MANY PGME)*
- A 21-gauge needle is inserted directly into the nodule. The material is aspirated, and is smeared over a slide for cytological examination. (See figure 20.8)
- 6 Follicular clusters each with 10 cells each is considered as adequate FNAC sample. *(AIIMS JUNE 20)*
- With the exception of ***follicular tumours*** **an experienced pathologist is able to give an accurate histopathological diagnosis.** *(NEET)* However; *FNAC is unable to differentiate between benign follicular adenoma and follicular carcinoma of thyroid.* *(MANY PGME, VERY IMP. POINT)*
- Bethesda classification of FNAC. See in box 20.4:1; below.

3. Tumour Marker

(i) Serum Thyroglobulin

It is increased in goiter, hyperthyroidism, thyroiditis and tumours (papillary carcinoma and follicular carcinoma)

(ii) Serum calcitonin

It is tumour maker for medullary carcinoma of thyroid. *(AIIMS 90,05, AI 97)*

RECAP: ***Till*** *now we were discussing anatomy, physiology and investigations related to thyroid. Now we will discuss diseases related to thyroid gland. Before discussing diseases of thyroid gland we must understand the term "Goiter".*

****

KEY BOX 20.4:1

Bethesda classification of FNAC

Thy 1	Non diagnostic	} Repeat
Thy 1c	Non diagnostic cystic	} USG - guided FNAC
Thy 2	Non neoplastic (benign)	Follow up
Thy 3	Follicular	Hemithyroidectomy
Thy 4	Suspicious of malignancy	} Surgery
Thy 5	Malignant	} Surgery

GOITER

The normal thyroid is neither visible non palpable and its weight is about 20-25 grams (PGME). The term goiter [from Latin gutter = the throat] is used to describe generalized enlargement of the thyroid gland.

Thyroid enlargement can be classified as follow:

(a) Diffused enlargement (Figure 20.9)

- **Endemic goiter:** *It* is due to primary Iodine deficiency. This is ***most common cause*** **of diffused enlargement of thyroid**. (NEET, AI 96) It is hyperplastic.
- **Physiologic:** Pregnancy, puberty
- **Goiter due to secondary iodine deficiency,** Goitrogens (thiouracil type drugs, PASA, Lithium).
- **Genetic defect:** Pendred syndrome.
- **Diet**-uncooked brassica, cabbage. (PGME)

(b) Multinodular Goitre

When on palpating a thyroid gland more than one nodules are appreciated: (Figure 20.9)

(a) Toxic

- Diffused
- Multinodular Toxic adenoma

(b) Neoplastic

- Benign
- Malignant:
  - (i) Primary thyroid tumour
  - (ii) Secondary thyroid tumour (M/C from breast)

Please know one more condition, retrosternal goitre.

Retrosternal goitre

- A goitre is said to be retrosternal, substernal or mediastinal if more than half of the thyroid tissue is below the opening of thoracic cage.
- Mediastinal goitres can be primary or secondary.

A. Primary mediastinal goitre (1%)

- Arise from accessory (ectopic) thyroid tissue located in the chest
- Supplied by intrathoracic blood vessels
- Require median sternotomy if surgery indicated

B. Secondary mediastinal goitre (99%)

- Arise from downward extension of cervical nodular goitre.
- Derive their blood supply from the superior and inferior thyroid arteries
- Removed mostly by cervical incision

****

Now let us come to the point, ie; Diseases related to thyroid glands:-

Figure 20.9: A patient with goiter

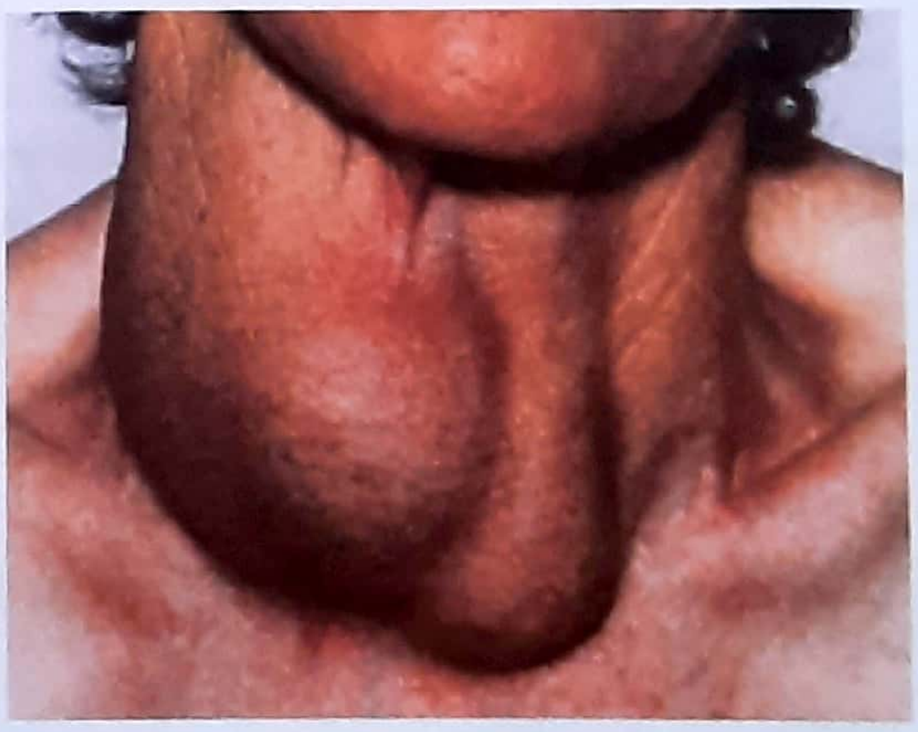

Figure 20.10: A patient of multi nodular goiter

- Free T3 Level is diagnostic in T3 toxicity in which T4 is normal and TSH is suppressed.

RECAP: Till now we have discussed;

A. Imaging of Thyroid (X-ray, USG neck Isotope Scanning cross sectional imaging.

B. Thyroid Function Test, (TSH assay & T3 & T4 estimation.

Now we will discuss Specific test for thyroid.

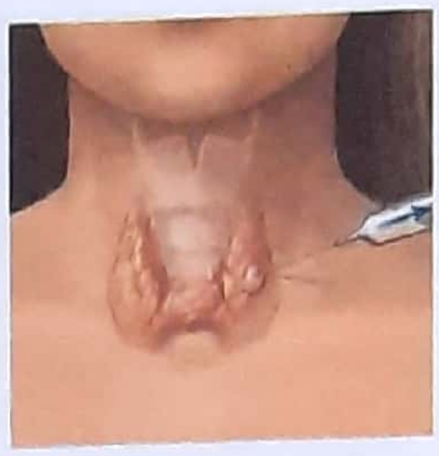

Negative suction created by a syringe in nodule

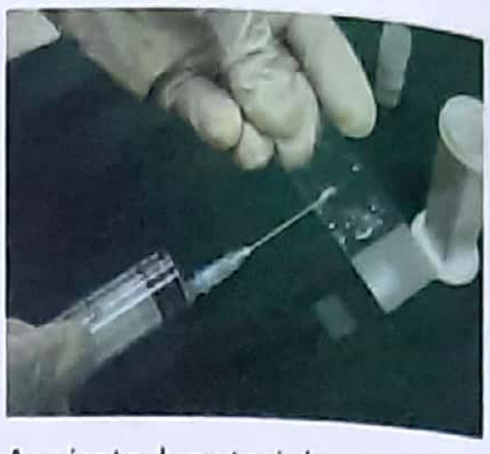

Aspirated material smeared over a glass slide for histo-pathological examination.

Figure 20.8: Method of FNAC

C. SPECIFIC TEST FOR THYROID

1. Thyroid antibodies

Antibodies to thyroglobulin and follicular cell cytoplasm have been detected in various autoimmune disease of thyroid particularly, high titer is found in about 95% of patients with hashimoto's thyroiditis and 80% with grave's disease have detectable antibodies against the TSH receptors.

2. Aspiration and FNAC

- Fine needle aspiration biopsy of the thyroid has become very popular in evaluation of thyroid nodule. *It is now* ***the first investigation test for a thyroid nodule.*** *(NEET, MANY PGME)*
- A 21-gauge needle is inserted directly into the nodule. The material is aspirated, and is smeared over a slide for cytological examination. (See figure 20.8)
- 6 Follicular clusters each with 10 cells each is considered as adequate FNAC sample. *(AIIMS JUNE 20)*
- With the exception of ***follicular tumours*** **an experienced pathologist is able to give an accurate histopathological diagnosis.** *(NEET)* However; *FNAC is unable to differentiate between benign follicular adenoma and follicular carcinoma of thyroid.* *(MANY PGME, VERY IMP. POINT)*
- Bethesda classification of FNAC. See in box 20.4:1; below.

3. Tumour Marker

(i) Serum Thyroglobulin

It is increased in goiter, hyperthyroidism, thyroiditis and tumours (papillary carcinoma and follicular carcinoma)

(ii) Serum calcitonin

It is tumour maker for medullary carcinoma of thyroid. *(AIIMS 90,05, AI 97)*

RECAP: ***Till*** *now we were discussing anatomy, physiology and investigations related to thyroid. Now we will discuss diseases related to thyroid gland. Before discussing diseases of thyroid gland we must understand the term "Goiter".*

****

KEY BOX 20.4:1

Bethesda classification of FNAC

Thy 1	Non diagnostic	} Repeat
Thy 1c	Non diagnostic cystic	} USG - guided FNAC
Thy 2	Non neoplastic (benign)	Follow up
Thy 3	Follicular	Hemithyroidectomy
Thy 4	Suspicious of malignancy	} Surgery
Thy 5	Malignant	} Surgery

GOITER

The normal thyroid is neither visible non palpable and its weight is about 20-25 grams (PGME). The term goiter [from Latin gutter = the throat] is used to describe generalized enlargement of the thyroid gland.

Thyroid enlargement can be classified as follow:

(a) Diffused enlargement (Figure 20.9)

- **Endemic goiter:** *It* is due to primary Iodine deficiency. This is ***most common cause*** **of diffused enlargement of thyroid.** (NEET, AI 96) It is hyperplastic.
- **Physiologic:** Pregnancy, puberty
- **Goiter due to secondary iodine deficiency,** Goitrogens (thiouracil type drugs, PASA, Lithium).
- **Genetic defect:** Pendred syndrome.
- **Diet**-uncooked brassica, cabbage. (PGME)

(b) Multinodular Goitre

When on palpating a thyroid gland more than one nodules are appreciated: (Figure 20.9)

(a) Toxic

- Diffused
- Multinodular Toxic adenoma

(b) Neoplastic

- Benign
- Malignant:
  - (i) Primary thyroid tumour
  - (ii) Secondary thyroid tumour (M/C from breast)

Please know one more condition, retrosternal goitre.

Retrosternal goitre

- A goitre is said to be retrosternal, substernal or mediastinal if more than half of the thyroid tissue is below the opening of thoracic cage.
- Mediastinal goitres can be primary or secondary.

A. Primary mediastinal goitre (1%)

- Arise from accessory (ectopic) thyroid tissue located in the chest
- Supplied by intrathoracic blood vessels
- Require median sternotomy if surgery indicated

B. Secondary mediastinal goitre (99%)

- Arise from downward extension of cervical nodular goitre.
- Derive their blood supply from the superior and inferior thyroid arteries
- Removed mostly by cervical incision

****

Now let us come to the point, ie; Diseases related to thyroid glands:-

Figure 20.9: A patient with goiter

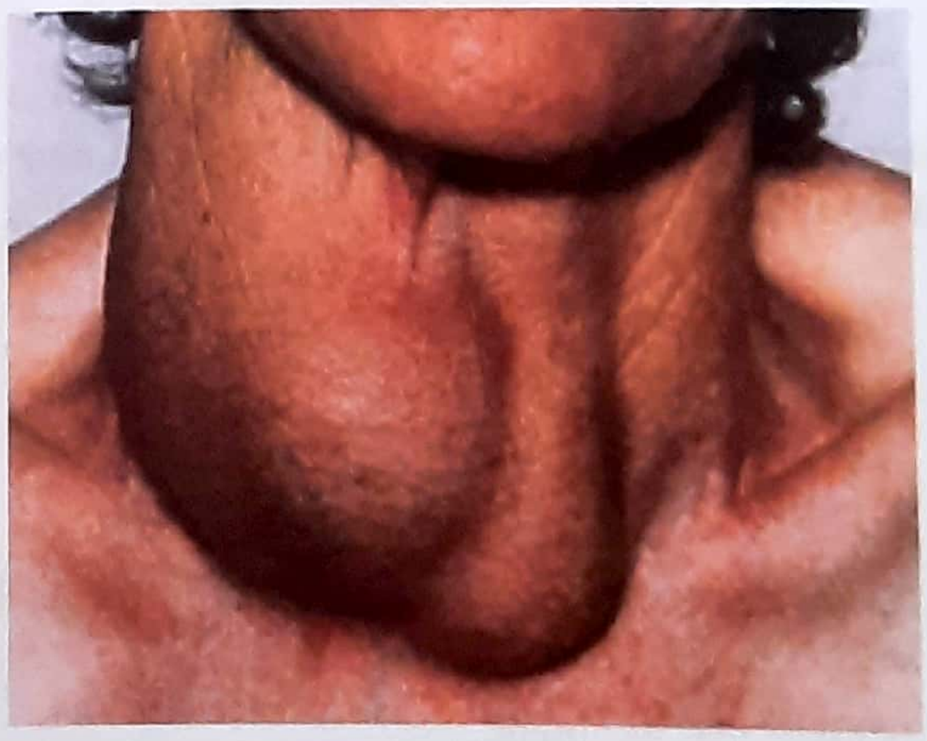

Figure 20.10: A patient of multi nodular goiter

DISEASES OF THE THYROID

First Known what we will discuss, and under which topic: we will discuss diseases of thyroid, one by one under these sub headings:

A. Developmental and congenital disease

1. Developmental anomalies in shape
2. Development anomalies in position
3. Remnant of thyroglossal duct

B. Disease related to release of thyroid hormone

1. Hyperthyroidism.
2. Hypothyroidism.

C. Immunological disease of the thyroid

1. Grave's disease, (imp. topic)
2. Hashimoto's thyroiditis. Mnemonic: **G**irl's **H**ostel

D. Inflammatory thyroid disease

1. Subacute thyroiditis: De-Quervain's thyroiditis.
2. Acute (suppurative) thyroiditis.
3. Riedel's thyroiditis Mnemonic: **DAR**

E. Thyroid Neoplasm

1. Benign

- Solitary thyroid nodule (95% are benign)
- Follicular Adenoma

2. Malignant

- Papillary carcinoma
- Follicular carcinoma
- Anaplastic carcinoma
- Medullary carcinoma
- Malignant lymphoma

I have given an over view of disease of thyroid, now we will discuss them, one by one.

A. Developmental & Congenital Disorders of Thyroid

1. Disorders In shape

1. Shape of pyramidal lobe may be defective during development. (Figure 20.7)
2. Isthmus may be absent.
3. One lobe of gland may be very small or absent.

2. Disorders in position

(a) Lingual thyroid

Thyroid may lie under the mucosa of *dorsum of the tongue* and may form a swelling that may cause difficulty in swallowing.

(b) Intra lingual thyroid

The thyroid may be embedded in the *muscular substance of tongue.*

(c) Supra-hyoid thyroid

The gland may lie in the middle of neck, above the hyoid bone.

(d) Infra-hyoid thyroid

Gland may lie below hyoid bone, but above its normal position.

(e) Intra-thoracic thyroid

The entire gland or part of it may lie in thorax.

(f) Retro-sternal thyroid

- It may develop from ectopic thyroid tissue. Most arise from the lower pole of the multinodular goiter. If the neck is short and pretracheal muscles are strong the negative intrathoracic pressure tend to draw the nodular goiter into superior mediastinum.

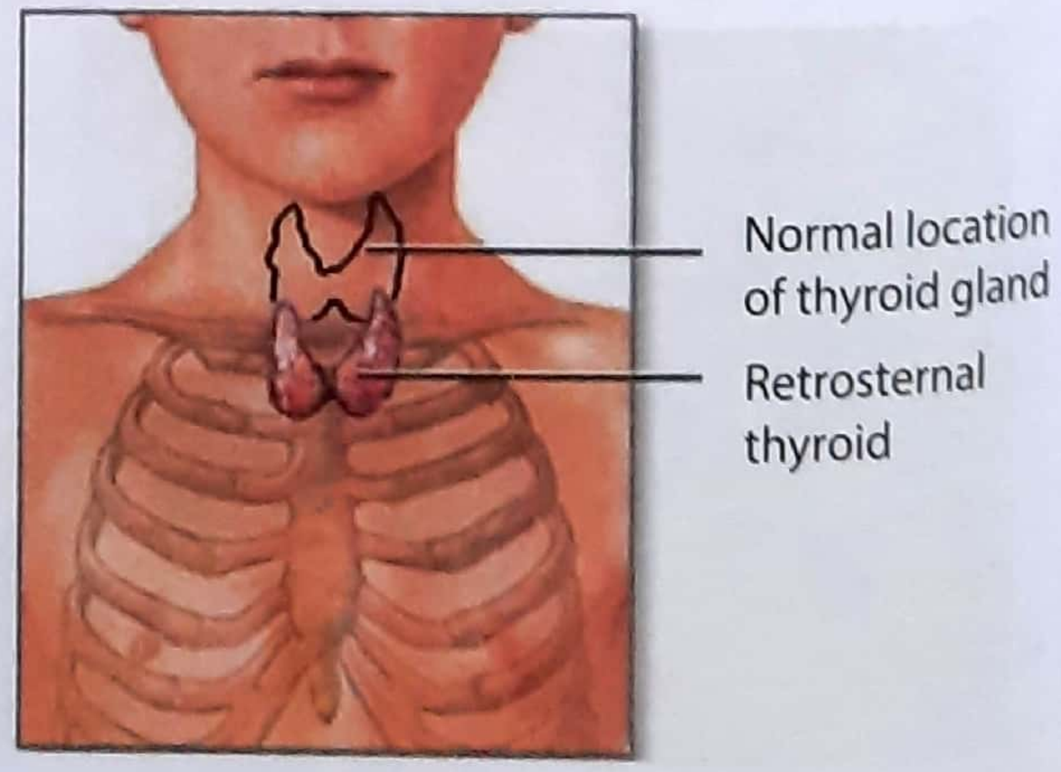

Figure 20.10.1: Retrosternal goiter

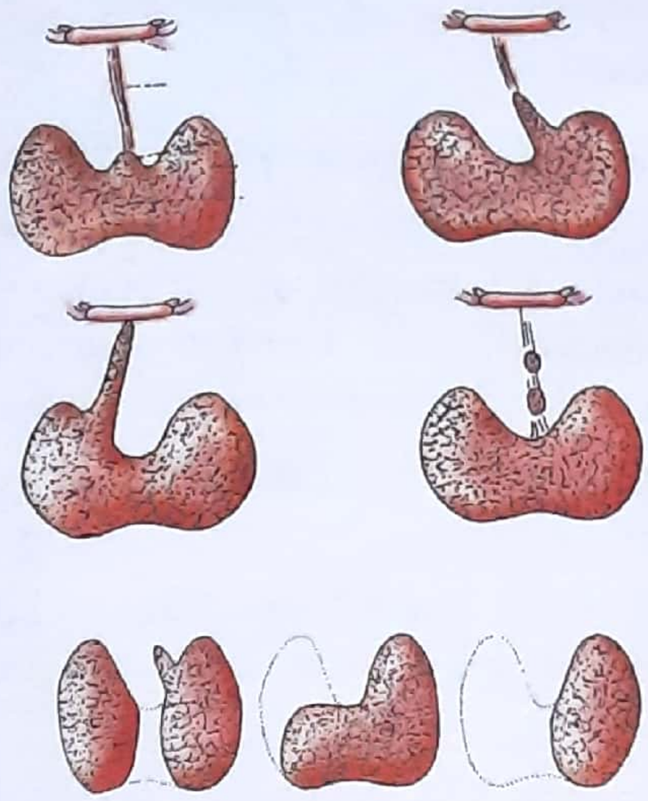

Figure 20.11: Developmental disorder of thyroid gland

- It may produce symptoms, like dyspnea due to tracheal obstruction, dysphagia due to esophageal obstruction and engorgement of neck vein due to compression of major veins in the thorax.
- Most common presenting feature in retrosternal thyroid is dyspnea (PGI 97)

(g) Ectopic thyroid tissue

Small amount of thyroid tissue may be present in larynx, esophagus, pleura, pericardium and ovaries.

3. Disorder/anomalies of thyroglossal tract

- This tract extends,from the foramen cecum of the tongue to isthmus of thyroid.
- Usually this tract' disappears, but occasionally it may persist, and a cyst or fistula may develop from this tract which is known as thyroglossal cyst and thyroglossal fistula respectively.

(a) Thyroglossal cyst

It appears form cystic degeneration of a part of thyroglossal tract. It is often complicated with infection because it is lined by nodules of lymphatics which communicates to the lymph nodes of the neck.

- The cyst is always in midline of neck.
- *The* ***commonest position of thyroglossal cyst is just below the hyoid bone (ie: subhyoid).*** (NEET, AIIMS 97, UP, AI 98). Please see figure 20.13.

Figure 20.12 : Thyroglossal cyst

Treatment

A thyroglossal cyst is always excised. When it presents with infection and abscess formation, incision and drainage is treatment of choice.

Once infection is controlled, it should be treated by *complete excision with removal of central portion of hyoid bone.* (IMP. POINT)

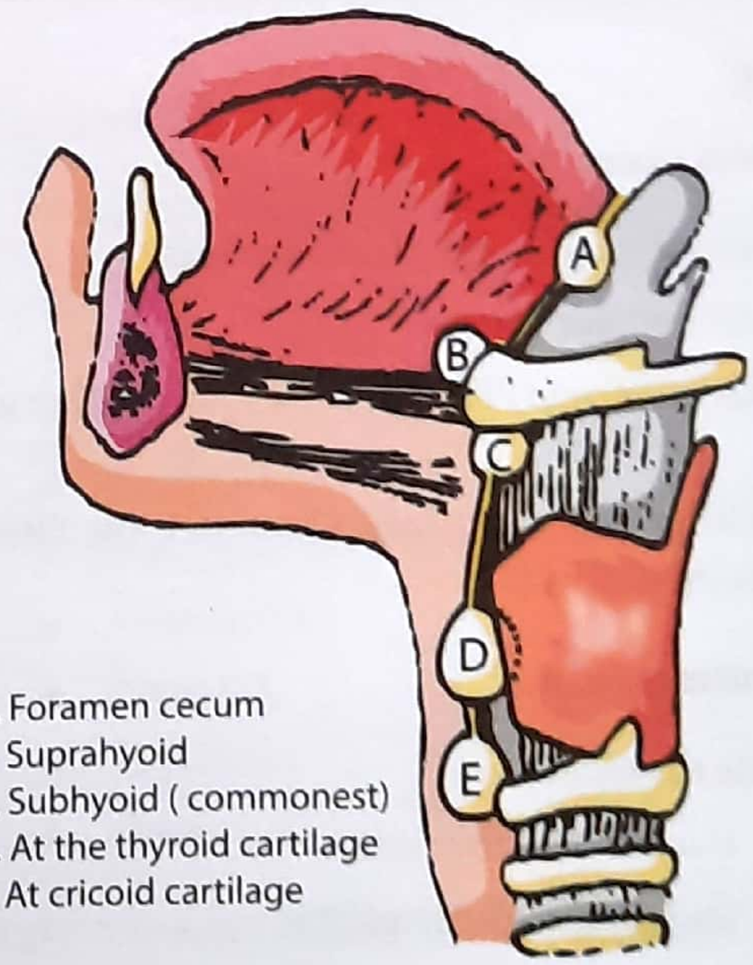

A. Foramen cecum
B. Suprahyoid
C. Subhyoid (commonest)
D. At the thyroid cartilage
E. At cricoid cartilage

Figure 20.13: Common location of Thyroglossal cyst

(b) Thyroglossal fistula

In fact it is not a fistula. It is a sinus.

NOTE: Must know what is a fistula and what is a sinus.

Fistula: Abnormal tube like passage from a normal cavity or tube to a free surface or to another tube.

Sinus: Any cavity having a narrow opening at one end. So it must be clear to every one that fistula has opening at it's both end but it is connected by a tubular tract, while sinus opens at one end only.

A **thyroglossal fistula** is formed when an infected thyroglossal cyst bursts, or following it's incomplete surgical removal.

Treatment: *Sistrunk operation:* In it excision [surgical removal] of the whole of thyroglossal tracts is done.

Recap:

we were discussing first part; ie; developmental and congenital disorder of thyroid. Now we will come to second part that is disease related with thyroid hormone synthesis; lets start the fresh topic from next page.

B. Disease Of Thyroid Hormone Secretion

1. HYPERTHYROIDISM

- This is symptom of thyroid due to raised level of thyroid hormone. Please read key box 20.4 carefully.

Causes

Common cause

1 Diffused toxic goiter - Grave's disease

2. Toxic nodular goiter

3. **Toxic adenoma (T3, T4↑, ↑ed Radioiodine uptake)** *(NEET)*

4. Intake of excess of thyroid hormone viz; Eltroxin in hypothyroidism.

Less common cause

1. Some thyroiditis
   - Hashimoto's thyroiditis
   - De Quervain's thyroiditis
2. TSH secreting adenoma of pituitary
3. Increased secretion of TRH (thyrotropin releasing hormone) by hypothalamus.

Rare Causes

- *Thyrotoxicosis Factitia:* When hyperthyroidism develops by taking large dose of L-thyroxin.
- *Carcinoma:* A large mass of carcinoma can produce thyrotoxicosis (*NOTE: A patient with carcinoma of thyroid is in euthyroid state in 99% cases.)*
- *Neonatal thyrotoxicosis:* babies born to hyperthyroid mothers.
- *Struma ovarri:* Thyroid secreting ovarian tumour. Hyperthyroidism is further divided as primary and secondary.
- Please read key box 20.4 once again very carefully; it will help you in many exams.

(a) Primary hyperthyroidism

The main cause of primary hyperthyroidism is Grave's disease. The disease usually occurs in previously normal thyroid gland. The gland is usually diffusely enlarged. In primary thyrotoxicosis neurological (CNS) symptoms are more prominent.

(b) Secondary hyperthyroidism

Usually superimposed on a nontoxic multi nodular goiter in long standing cases. In secondary hyperthyroidism the CVS symptoms are more prominent. The condition is autonomous and is independent of TSH & LATS. Kindley go through Key box 20.5 below.

Diagnosis

1. T3 and T4 estimation
2. TSH estimation
3. Thyroid scanning

Treatment

1. **Antithyroid Drugs**
   - a. *Hormone synthesis inhibitors*
     - Propylthiouracil
     - Carbimazole
   - b. *Beta blacker*-improves CVS and CNS symptoms.
   - c. *Inorganic iodine*- lugol's Iodine

KEY BOX 20.4		
	Hyperthyroid	**Hypothyroid**
Laboratory		
Free T4 and T3 indices	↑	↓
Physiologic mechanisms		
Cellular metabolism and protein synthesis	↑	↓
Protentiation of β-adrenergic effects	↑	↓
Insulin antagonism	↑	↓
Clinical Effects		
Basal metabolic rate	↑	↓
Goiter	Usually present	May be present
Body weight	↓	Normal or ↑
Activity	Hyperactive, insomnia	Letharge, somnolence
Reflexes	Brisk	Slow
Cardiovascular	Tachycardia, arrhythmia	Bradycardia
Gastrointestinal	Mild diarrhea	Constipation
Hair	Fine	Coarse, brittle; hair loss
Myxedema	Circumscribed patches, mainly pretibial	Generalized, especially extremities and face
Temperature tolerance	Heat-intolerant	Cold-intolerant
Other	Exophthalmos (in Graves' disease) amenorrhea, infertility osteoporosis, myopathy	Mental and growth retardation (in childhood; cretinism); anemia, hypercholesterolemia

2. Radioactive Iodine therapy

It has been tried with success, but it has certain complication, such as:-

Complications of Radioactive Iodine therapy (UPSC 87,88)

(i) Acute

- Neck pain and swelling
- Thyroiditis
- Sialoadenitis
- Cerebral edema
- Nausea, vomiting

(ii) Long term

- Bore marrow suppression (leukemia)
- Infertility
- Pulmonary fibrosis
- Increased risk of cancer such as:
  - Anaplastic CA of thyroid
  - Neck pain and swelling
  - Gastric CA
  - Lung CA
  - HCC
  - Breast CA

3. Surgery: In form of *Subtotal thyroidectomy.*

Also know one more topic

Thyroid Storm? (AI 02)

Thyroid storm is a condition of hyperthyroidism accompanied by fever, central nervous system agitation, or depression-and cardiovascular dysfunction. Severe thyrotoxic reactions appears suddenly within 3-4 days.

Precipitating Cause

- Infection
- Surgery: if euthyroid state is not achieved in a patient with hyperthyroidism at the time of surgery.
- Trauma
- Occasionally due to amiodarone administration

Treatment (AIIMS 03)

It is mainly supportive

- O_2, inhalation
- IV-drip
- Non-aspirin compound should be used to treat pyrexia. (Aspirin should not be used)
- Lugol's Iodine-decrease iodine uptake and secretion of thyroid hormone
- B-blockers like propranolol for cardiovascular dysfunction
- Steroid.

The mortality rate of this condition is between 5-10%; if not detected and treated early.

ALSO NOTE:

Hyperthyroidism?

Symptom due to raised level of thyroid hormone

Thyrotoxicosis?

The *disease* with all its manifestation, which are not always due to raised 'thyroxine' level. This may result from release of preformed hormone in conditions, without thyroid hyperfunction. viz; Thyroiditis, thyroid crisis.

Please read key box 20.5.

2. HYPOTHYROIDISM

Hypothyroidism occurs when the thyroid gland fail to secrete sufficient thyroid hormone. This is usually due to a primary disorder of thyroid gland, but can also occurs secondary to disease of anterior pituitary.

KEY BOX 20.5

Primary Thyrotoxicosis	Secondary Thyrotoxicosis
1. Usually occus between 15-45 years, commonly in late 2nd and 3rd decade	1. Usually occurs in middle aged or elderly between 40-45 years.
2. The onset is abrupt. Features of thyrotoxicosis and the enlargement of thyroid occurs almost simultaneously.	2. Onset is insidious. Features of thyrotoxicosis appear later.
3. No history of any preexisting goiter.	3. History of preexisting goiter is present for long time.
4. This has usually autoimmune origin.	4. This is related to hyperplasia involution cycle.
5. The goiter is diffuse, vascular, symmetrically enlarged, smooth and occasionally with thrill and bruit.	5. The goiter is asymmetrically enlarged, any irregular and solitary or multinodular without thrill and bruit.
6. Neurological features and psychic disturbances are markedly present.	6. Neurological features and psychic disturbances are absent.
7. Cardiovascular features are present. But cardiac failure is rare.	7. Cardiovascular feature are marked.
8. Exophthalmos, toxic eye signs are marked.	8. Typically exophthalmos and eye sign are not present, but lid lag may be present.
9. T3, T4 are maredly high.	9. T3, T4 are comparatively less elevated.

Figure 20.14 : Histology of thyrotoxicosis

KEY BOX 20.7/1

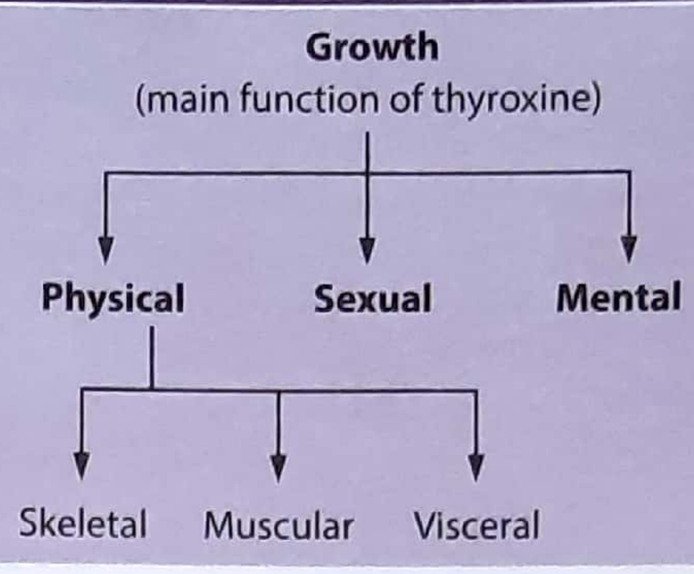

Causes

1. Autoimmune thyroiditis - Hashimoto's thyroiditis.
2. Iatrogenic - Thyroidectomy, radioiodine therapy.
3. Dyshormonogenesis
   (i) Dehalogenase deficiency
   (ii) Peroxidase deficiency (pander's syndrome: hypothyroidism + nerve deafness)
4. ***Secondary hypothyroidism*** due to decreased TSH secretion from pituitary. (See key box 20.6)
5. ***Tertiary hypothyroidism*** when hypothalamus is unable to secrete TrRH (which, is responsible for secretion of TSH for pituitary. (See key box 20.6)

Types

(a) Infantile or fetal hypothyroidism (Cretinism)

For clinical features; please see key box 20.7.1 & 20.7.2

KEY BOX 20.6

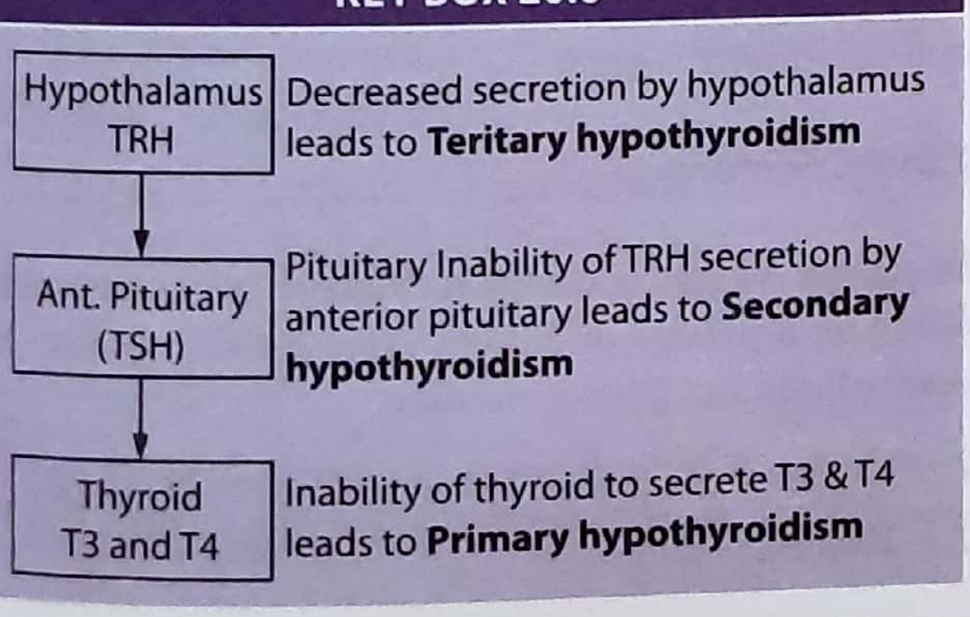

Three possible causes should be considered for cretinism; are:

1. During fetal life, the thyroid may fail to develop (agenesis)
2. One or more of the enzyme concerned with thyroid hormone synthesis may be congenitally absent (Dyshormonogenesis)
3. In endemic goiter area, insufficient thyroid hormone may be synthesized, because of lack of iodine in maternal diet. Please see key box 20.7.1 & 20.7.2 once again for clinical features.

Diagnosis and treatment

In last two condition enlargement of the thyroid gland (goiter) is present.

- Condition is confirmed by finding a low T4 & high TSH.
- Immediate treatment with thyroxin is begun.

(b) Adult hypothyroidism

It is state of thyroid deficiency with feature of lethargy, tiredness, cold intolerance, .weight gain, menstrual irregularity, dry skin, cold extremity. (See box 20.4.)

Diagnosis and treatment

- Condition is confirmed by low T4 and high TSH.
- Serum TSH estimation is most useful to assess gland function. *Treatment* is oral thyroxin.

RECAP: Till now we *have discussed two disorders of thyroid gland, ie; congenital and hormonal, now we will discuss third; that is immunological disorders of thyroid, Viz; Grave's disease and Hashimoto's autoimmune thyroiditis*

KEY BOX 20.7/2

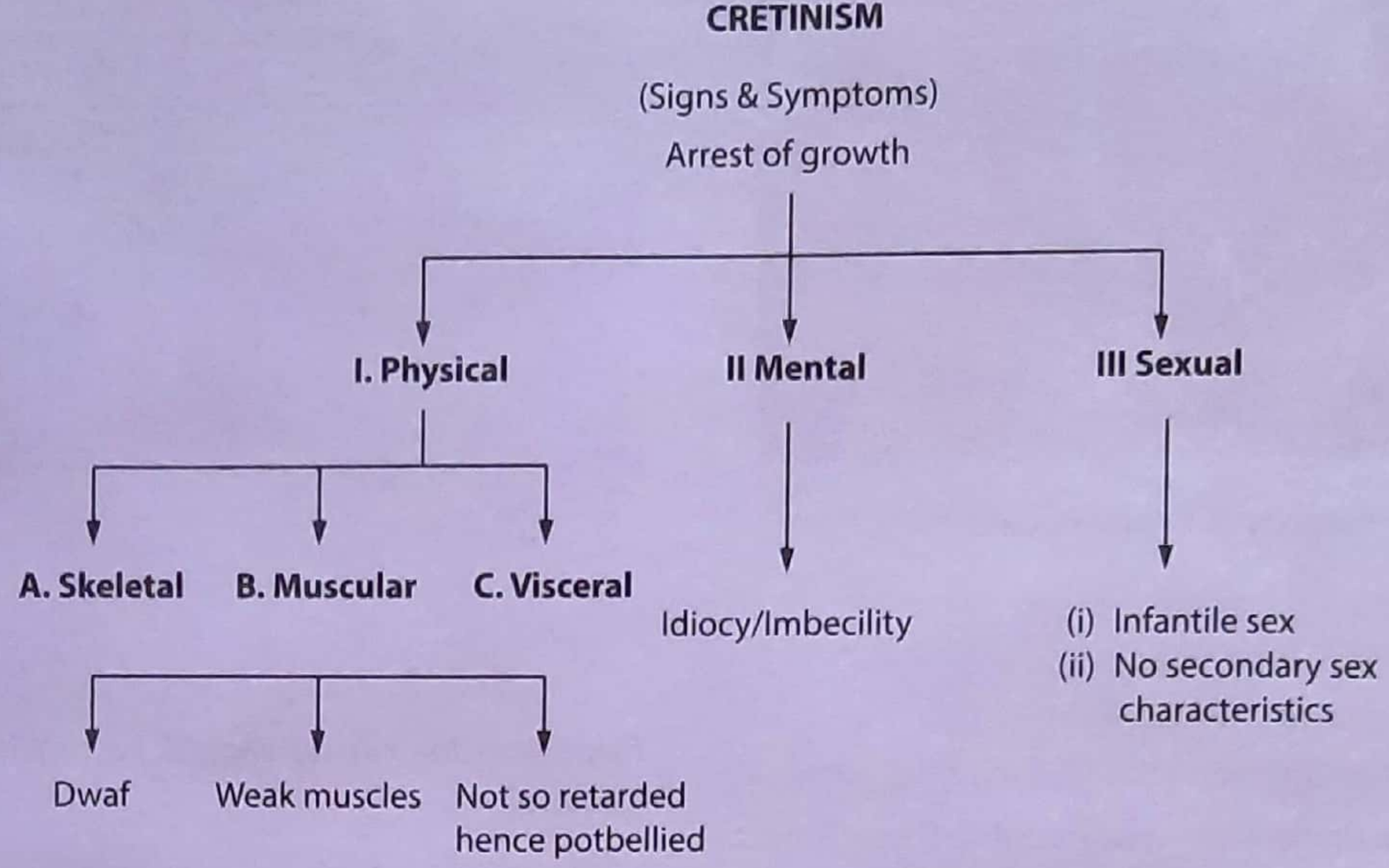

C. Immunological Disease of The Thyroid

1 Grave's Disease (Diffused toxic goiter or Primary toxic goiter)

Grave's disease is responsible for *great majority* of cases of *hyperthyroidism*. It is relatively common disease, affecting female four to five times more commonly than male. It has its highest incidence between 15-40 years of age group. Patients with grave's disease often suffer from some other autoimmune disease such as pernicious anemia, and there is an overlap with hashimoto's disease.

Friends, always make a habit to understand basics of the disease from its name. Here; as the name diffused toxic goiter, the enlargement of thyroid gland (goiter) is diffused and the patients is toxic ie; in hyperthyroid state.

Etiology

Grave's disease is an *autoimmune disease* characterized by the presence of *autoantibodies of the IgG class directed against the TSH receptors* (in serum). The combination of antibody with the receptor leads to stimulation of the cell to produce thyroid hormone.

There are many other antibodies detected in vitro:

l. Long Acting Thyroid Stimulators (LATS)

2. Thyroid Stimulating Immunoglobulin (TSI)

3. TSH Binding Inhibitory Immunoglobulin (TB-II)

- It should to be noted that serum levels of antibodies do not correlate precisely with severity of disease.
- The stimulating antibodies are of **IgG class,** and cross the placenta during pregnancy and stimulate the fetal thyroid tissue causing neonatal hyperthyroidism *(MANY PGME)*.

(JUST TO REMEMBER) **G**. for Graves disease, occurs due to presence of Ig**G** class of antibodies, which can **G**o (means passes) through placenta, and cause neonatal hyperthyroidism] [that is **G- G- G-]**

Pathology

Due to continuous stimulation of thyroid gland there occurs acinar cell hypertrophy and hyperplasia. The acinar cells, which are normally flat, becomes tall and columnar. The normal colloid disappears and the cell are empty, and rich vascularity is seen.

Clinical Feature

In graves disease a **classical triad** is seen (mnemonic **GET**) ie; a patient of Grave's disease **GET: G**oiter, **E**xophthalmos and **T**hyrotoxicosis.

1. **G**oiter
2. **E**xophthalmos

Figure 20.15: Extrathyroidal manifestations of Graves disease. (A) Orbitopathy (exophthalmos) (B) Dermopathy (pretibial myxedemal). (C) Acropachy

3. Thyrotoxicosis, though many other features may be present in small number of patient.

Now let us take each of them one by one:

1. Goiter

Enlargement of thyroid is known as goiter. In grave's diseases the *enlargement of thyroid is diffused and symmetric.* Obstructive symptoms due to enlargement of gland and causing pressure on trachea and esophagus ie; dyspnea and dysphagia can occur.

On palpation thyroid is smooth and extremely vascular. A bruit may be heard on the goiter.

2. Exophthalmos

- Exophthalmos means protrusion of the eye ball. In grave's disease it may be unilateral and bilateral (AIIMS).
- Exophthalmos and proptosis occurs due to infiltration of retro-orbital tissue by lymphocytic fluid and fat.
- Staring appearance and lid lag is brought about by widening of the palpable fissure, due to an excessive response of sympathetically innervated levator palpebrae superiors muscle, because of sympathetic over activity in thyrotoxicosis, as a result of increased secretion of catecholamines.

Malignant Exophthalmos ?

This occurs in untreated cases of Grave's disease.

Untreated disease

↓

Exopthalmos

↓

Exposure keratitis

↓

Conjunctivitis

↓

Chemosis

↓

In extreme case may cause optic nerve damage and blindness.

3. Thyrotoxicosis

Features of thyrotoxicosis are present in a patient of Grave's disease. These are A, B, C, D, E, F, G, H

A. **A**ppetite is increased.

B. **B**MR is increased, hence **weight loss** occurs.

C. **C**old weather preference,& hot weather intolerance.

D. **D**iarrhea: as a result of increased smooth muscle over activity of small intestine.

E. **E**xcitability

F. **F**acial flushing and perspiration.

G. **G**rave's disease patient has wasting of muscle.

H. **H**ypertension

M. **P**retibial Myxedema: this is thickening of skin with mucin like deposit in lower part of leg on skin over tibia.

N. None

O. Oligomenorrhea

P. Palpitation-very common symptom

NOTE: with above A, B, C, D ..... you can easily remember features of hyperthyroidism/thyrotoxicosis; and answer them if asked in prof examination.

Management

Investigation

1. T3, T4 and TSH estimation
   - T3 and T4 is increased, while TSH is markedly decreased
   - Most reliable test is estimation of free T4.
2. Thyroid scan will show warm scan (discussed earlier in investigation or of this chapter)
3. *Thyroid antibodies:* A high liter of thyroid antibodies are found.
4. *Other Tests:* Serum creatinine, serum cholesterol should be done.

Treatment

There are mainly four approaches for treatment of this condition. These are:

(i) Anti-thyroid drugs
(ii) Radioactive iodine
(iii) Surgery
(iv) B-blocker

(i) Anti thyroid drugs: Drugs used are:

Carbimazole: It acts by blocking oxidation of iodide to iodine.

***P**ropyl thiouracil:* Weaker in potency than carbimazole. It is drug of choice in **P**regnancy, *(MANY PGME)*.

Iodides are given prior to surgery to reduce size & vascularity. *(NEET)*

(ii) Radioactive Iodine

This treatment destroys thyroid cells and reduces the mass of functioning thyroid tissue and it *should not be advised* to a pregnant women and nursing mother.

(iii) Surgery

The aim of surgery is to reduce the functioning thyroid mass. In case of big diffused toxic goiter and toxic nodular goiter this is treatment of choice. Surgical procedure most commonly done is subtotal thyroidectomy, leaving about 6-8 grams of thyroid tissue. (**NOTE:** Normal weight=25-30 grams).

(iv) B-blocker: They improve CNS and CVS symptoms.

2. Hashimoto's Autoimmune Thyroiditis

Hashimoto's thyroiditis is responsible for ***most cases of primary hypothyroidism (↓T4, ↑TSH)*** *(IMCET NOV 20, AI 2000)*. It generally **affects middle aged female** (45-65 yr). *(NEET)*

Etiology

This disease is believed to be as a result of an autoimmune response against thyroid glands. Most patient with Hashimoto's disease have **different IgG autoantibodies in their serum**; namely:

1. Anti thyroglobulin antibody. (M/C antibody in serum) *(JIPMER 79, AIIMS M, 85)*
2. Antibody directed against a component of colloid other than thyroglobulin.
3. Antibodies against thyroid TSH receptor.

Pathology

Atrophy of follicles with

- Oncocytic (Hurthle Cell) metaplasia
- Abundant lymphoplasmacytic infiltrate
- Varying degree of fibrosis
- Foci of squamous metaplasia

Figure 20.16 : Sonographic features of Hashimoto thyroiditis. In this image, the thyroid gland is enlarged, predominantly hyperechoic, and diffusely heterogeneous, with irregular echotexture and poorly defined hyperechoic regions separated by fibrous strands.

Clinical feature

1. In early stage the thyroid is enlarged diffusely.
2. On Palpation: the gland is firm and rubbery with coarsely nodular (bosselated) appearance [**NOTE:** consider bosselated as moving your hand oven a bunch of grapes]
3. As the disease progresses, the gland becomes smaller, and the end result is markedly atrophic fibrosed thyroid.
   - Thyroid function at the time of presentation is *variable*. Patients are commonly either *euthyroid or mildly hypothyroid*. However in some rare early cases there may be hyperthyroidism due to release of thyroid hormone as a result of destruction of thyroid tissue, a condition known as *hashitoxicosis*. (PGME)
   - Histopathological examination shows *Askanazy or Hurthel cells*. (**H***ashimoto's thyroiditis*/**H***urthel cells*) (AI 95)

Treatment

Without treatment, Hashimoto's disease progress to primary hypothyroidism. Thyroxine is given as a supplementary dose as this disease results in hypothyroidism.

Complication of Hashimoto's disease (PGME)

1. Permanent hypothyroidism
2. Papillary carcinoma of thyroid
3. Malignant B-cell lymphoma (MANY PGME)

(D) Inflammatory Thyroid Diseases

1. Subacute thyroiditis or De-Quervain's thyroiditis

This condition is also known as granulomatous thyroiditis.

- It is an uncommon *inflammatory condition* (AI 02) of thyroid. It affects both sexes and all age groups.
- A viral origin is considered most likely. Inflammation of thyroid usually follows upper respiratory tract infection.
- The most common virus implicated is Coxsackie viruses. ESR is often elevated, which suggests inflammatory nature.

Clinical feature (AI 02)

- Patient presents with *fever, body ache and painful enlargement* of thyroid gland, (because this is an inflammatory condition).
- The gland is enlarge, tender to touch, soft to firm in consistency. The condition usually regress spontaneously with time. It may also be painless. (MAHE 07)
- Patients are usually in euthyroid state.
- There may be a thyrotoxic state with lower radioiodine uptake.

Treatment: Analgesic and antipyretic.

2. Riedel's Thyroiditis

- It is a very rare chronic disorder of thyroid usually occurring in elderly women. The disease is some times associated with *similar fibrosing lesion in the retroperitoneum and mediastinum,* (IMP. POINT)

Clinical feature

The gland is usually mildly enlarged and replaced wholly by <u>*stony hard tissue (woody thyroiditis)*</u>. The clinical feature may be because of this.

- The fibrosis may constrict trachea; causing dyspnea & stridor
- Esophagus-Causing dysphagia
- Recurrent laryngeal nerve involvement causing hoarseness of voice.
- Patients are usually euthyroid, hypothyroidism is seen in only about 30%.

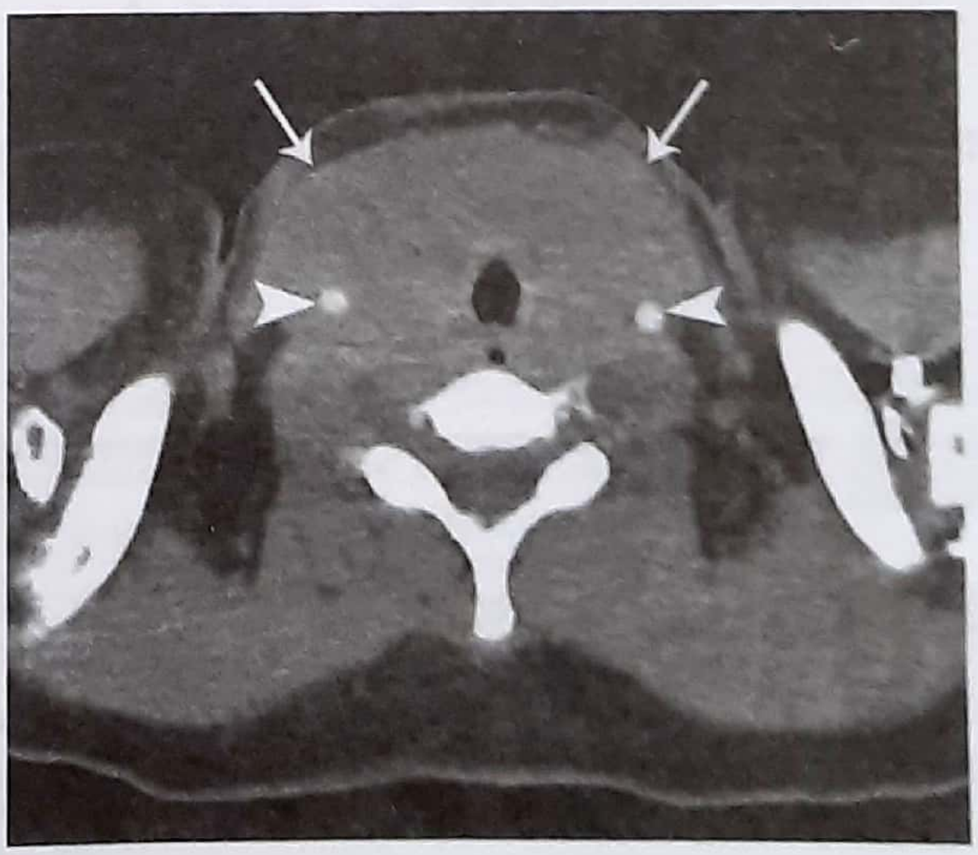

Figure 20.17 : Reidel's thyroiditis associated with massive neck fibrosis

Treatment

1. By the time, patient presents it is too late for surgery.
2. If there is Hypothyroidism-Thyroxine should be given to obtain euthyroid state.
3. In selected cases in whom there is much pressure on trachea:- isthmectomy can be done to relive pressure on trachea, which will relieve dyspnea.

3. Acute thyroiditis

- This condition usually follows upper respiratory tract infection and usually affects younger age group.
- Because of it's inflammatory nature there is severe pain in thyroid and in adjacent necks, and fever with chills and rigor. *(AIIMS)*
- Patient may complain of dysphagia.

Treatment consist of broad spectrum antibiotics and drainage of abscess, if suppuration has occurred.

RECAP: Till now we have discussed

(A) Developmental and congenital disease

1. Developmental anomalies of shape
2. Development anomalies of position
3. Remnant of thyroglossal duct.

(B) Disease related to release of thyroid hormone

1. Hyperthyroidism.
2. Hypothyroidism.

(C) Immunological disease of the thyroid

1. Grave's disease, (**imp.topic**)
2. Hashimoto's thyroiditis.

(D) Inflammatory thyroid disease

1. Subacute thyroiditis: De-Quervain's thyroiditis.
2. Riedel's thyroiditis
3. Acute (suppurative) thyroiditis.

Now we will discuss last group of disorders, tumour of thyroids

E. TUMOURS OF THYROID

First of all see the flow chart in key box 20-8 on next page and then only proceed so that you can understand it better

Benign Tumours

Almost all benign thyroid tumours arise from glandular epithelium and are termed as adenoma. Most common adenoma arising from thyroid is follicular adenoma.

1. Follicular Adenoma

They present as clinically solitary nodules and the distinction between a follicular carcinoma and a follicular adenoma can only be made by histological examination (and not by FNAC), as in adenoma, invasion of the capsule does not occurs.

Treatment is therefore, by wide excision (lobectomy) or hemithyroidectomy.

2. Papillary adenoma

It is a benign neoplasm showing papillary process. It is a rare condition. In fact, all papillary tumour should be considered as malignant even if encapsulated.

MALIGNANT TUMOURS OF THYROID

NOTE: *every point I have mentioned in this text is very important and require repeated revision, as only 18% is retained by most intellect, so considering that you are most intelligent, you will require more than 5 revisions*

Etiology

1. Thyroid cancer affects female about three times as frequently as male. (F : M; ratio 3 : 1)
2. *Iodine deficiency or goitrogenic drugs* administration over a long period may produce carcinoma.
3. *In long standing goiter:* Carcinoma most commonly arising in long standing goiter is follicular carcinoma. *(AI 96, AIIMS 97, 01)*

   (**To remember :** FOr long cases of goiter: FOllicular)

4. Papillary carcinoma may rarely arise from thyroglossal cyst.
5. **Radiation exposure increases chances of carcinoma formation; most commonly Papillary carcinoma** *(NEET)* (to remember **Pa-Ra; Papillary in Radiation**) *(MANY PGME)*
6. Malignant lymphoma is more common in patients with Hashimoto's disease.

Now we will discuss malignant tumour one by one. First of all, kindly go through its classification mentioned in a flow chart in key box 20.8; on next page.

KEY BOX 20.8

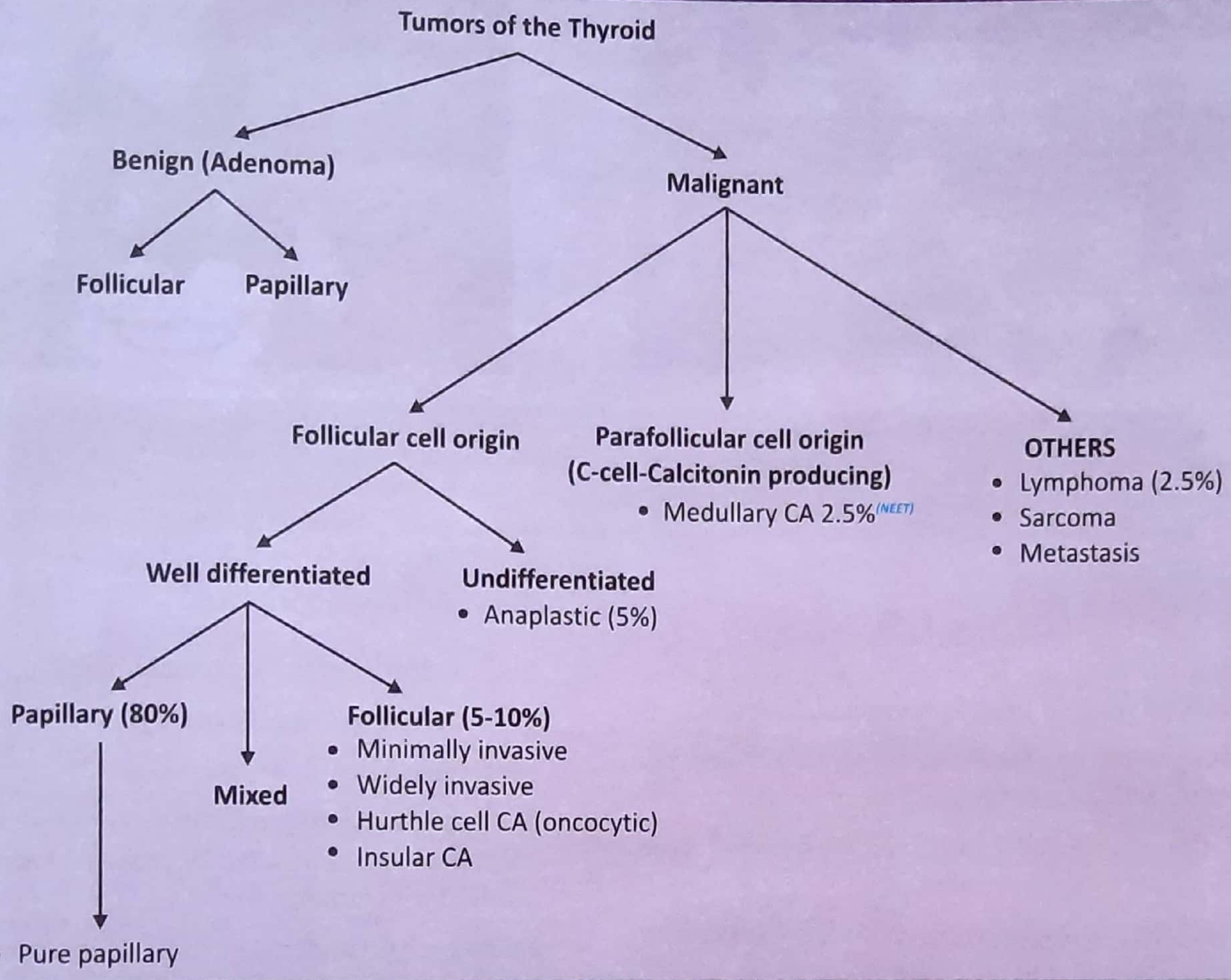

Order of occurence of thyroid cancer - Papillary > Follicular > Anaplastic > Medullary > Lymphoma (PFAML)

(I) FOLLICULAR CELL ORIGIN

Arising from follicular cells of thyroid tissue. It is further divided as:-

(A) Differentiated Tumours

(i) Papillary carcinoma

It is ***most common*** (NEET, PGME) and account for 80% of all thyroid malignancies. The condition is three times more common in female, {just to remember: Papillary carcinoma is most Popular among all thyroid carcinoma ie; 80%} [MANY PGME]

Pathology

- Papillary carcinoma are *not encapsulated* (or very rarely capsulated). (encapsulated means; with in a capsule).
- Tumour tends to invade lymphatics and to surrounding tissue, *lymph node metastasis is quite early*. (AI 89, MANY PGME, PGI JUNE 07, PGI JUNE 07). [Papillary metastasize quite Pahle (early)]
- Sometime the tumour may contains *localized deposits of calcium in connective tissue layers, which are called psammoma bodies*. (PGI 2000, PGI JUNE 07)
- Characteristic pale, empty nuclei *(or orphan annie eyed nuclei* (*snake* eye like) are present, orphan mean snake.
- *Multi centricity* of the primary tumour is the most important feature of this cancer. (PGI DEC 08)
- Genes implicated in Papillary carcinomas is - RAS, RET, BRAF.

Clinical Features

- It is *most slow growing* among the malignant tumour of thyroid. (AIIMS 03) It tends to be bilateral.

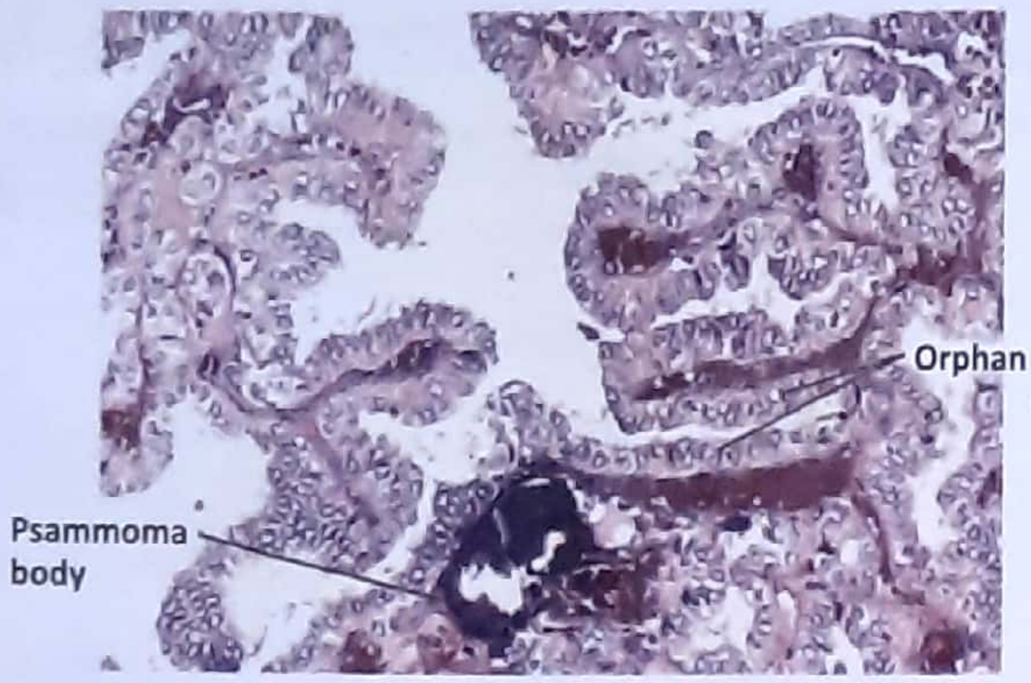

Figure 20.18 Here in the figure we can see cells with nuclei which have a cleared out appaearance, known as "Orphan Annie Eye" nuclei. (These are so named because they have a "cleared out" appearance, similar to Little Orphan Annie's eyes. Little Orphan Annie was a comic strip).

- *Most papillary thyroid carcinoma present themselves as a slow growing solitary thyroid nodule* (PGI 96)
- Though this neoplasm can appear at any age, the peak incidence is in third and fourth decade.
- It shows a peculiar tendency to become more malignant with advanced age.
- Recurrent laryngeal nerve is in close relation to thyroid gland, and therefore likely to be involve in advanced thyroid malignancy, which results in *laryngeal paralysis and hoarseness of voice*. (PGI 96)

Diagnosis

1. Straight X-ray of neck - may reveal calcium flecks suggesting psammoma bodies.
2. Radioiodine scan: shows cold nodule
3. Patients are usually euthyroid.
4. FNAB.

Treatment

Because of its slow growing nature; it has **best prognosis among all thyroid malignancies**. (NEET, MANY PGME)

1. **Surgery** is treatment of choice. Total or near total thyroidectomy with appropriate central and lateral neck dissection for lymph node involvement is done. (AI 09, AIIMS 11)

2. **Radioiodine therapy is recommended in:** (NEET)
   (i) Unresectable local invasion.
   (ii) Presence of distant metastases.

- A modified radical neck dissection is performed only if lymph node in lateral triangle are found to be involved with tumour.
- Following thyroidectomy, all individuals with papillary (also with follicular) carcinoma should be placed on suppressive dose of thyroxine for life long to suppress TSH production.

Just to remember: Papillary carcinoma is most Popular cancer of thyroid, which Penetrates lymphatics early (early lymph node involvement) & has Psammoma bodies and or Phan eyed nuclei. It Progresses Politely (slowly) hence **Prognosis is best.**

Certain terms related to papillary Carcinoma

Occult papillary Carcinoma

This refers to primary lesion <1.5 cm in diameter, which is often not palpable. (AIIMS 96)

Minimal papillary carcinoma

Refers to a small papillary tumour (<1 cm in diameter), having no local invasion, and not associated with lymph node metastasis. These tumour are incidentally found in young patient, at the time of thyroidectomy done; for some other benign condition.

Lateral Aberrant thyroid *(NEET, AIIMS 02)*

Papillary carcinoma involves lymph node early. In some cases, patient may present only with a lymph node in neck and the tumour is too small to be palpable. This lymph node which is enlarge is know as lateral aberrant thyroid.

KEY POINT: Patient with all thyroid carcinoma are euthyroid as a rule. Very rarely, well differentiated carcinoma may secret hormone and cause Hyperthyroidism.

Most of you can ommid below given classification. However it is being given for those students who are more interested on this topics.

Classification of thyroid cancer

Staging guide for thyroid cancer (AJCC 8e)					
Age at diagnosis	**T - category**	**N - category**	**M - category**	**Stage**	**Expected 10-yr DSS**
Differentiated thyroid cancer					
<55 years	any T	any N	M0	**I**	98-100%
	any T	any N	M1	**II**	85-95%
≥ 55 years	T1	N0/NX	M0	**I**	98-100%
	T1	N1	M0	**II**	85-95%
	T2	N0/NX	M0	**I**	98-100%
	T2	N1	M0	**II**	85-95%
	T3a/T3b	any N	M0	**II**	85-95%
	T4a	any N	M0	**III**	60-70%
	T4b	any N	M0	**IVA**	<50%
	any T	any N	M1	**IVB**	<50%
Medullary thyroid cancer					
any	T1	N0	M0	**I**	
	T2	N0	M0	**II**	
	T3	N0	M0	**II**	
	T1 -3	N1a	M0	**III**	
	T4a	any N	M0	**IVA**	
	T1-3	N1b	M0	**IVA**	
	T4b	any N	M0	**IVB**	
	any T	any N	M1	**IVC**	
Anaplastic thyroid cancer					
any	T1-T3a	N0/NX	M0	**IVA**	
	T1-T3a	N1	M0	**IVB**	
	T3b	any N	M0	**IVB**	
	T4	any N	M0	**IVB**	
	any T	any N	M1	**IVC**	

TNM definitions (AJCC 8e) for papillary, follicular, poorly differentiated, Hurthle cell, medullary, and anaplastic thyroid carcinomas	
TX	Primary tumor cannot be assessed
T0	No evidence of primary tumor
T1	Tumor ≤ 2 cm in greatest dimension limited to the thyroid
T1a	Tumor ≤ 1 cm in greatest dimension limited to the thyroid
T1b	Tumor > 1 cm but ≤2 cm in greatest dimension limited to the thyroid
T2	Tumor > 2 cm but ≤ 4 cm in greatest dimension limited to the thyroid
T3*	Tumor > 4 cm limited to the thyroid or gross extrathyroidal extension invading only strap muscles
T3a*	Tumor > 4 cm limited to the thyroid
T3b*	Gross extrathyroidal extension invading only strap muscles (sternohyoid) from a tumor of any size
T4	Includes gross extrathyroidal extension into major neck structures
T4a	Gross extrathyroidal extension invading subcutaneous soft tissues, larynx, trachea, esophagus, or recurrent laryngeal nerve from a tumor or any size
T4b	Gross extrathyroidal extension invading prevertebral fascia or encasing carotid artery or mediastinal vessels from a tumor of any size
NX	Regional lymph nodes cannot be assessed
N0	No evidence of regional lymph nodes metastasis
N0a*	One or more cytologic or histologically confirmed benign lymph node
N0b*	No radiologic or clinical evidence of locoregional lymph node metastasis
N1*	Metastasis to regional nodes
N1a*	Metastasis to level VI or VII (pretracheal, paratracheal, or prelaryngeal/Delphian, or upper mediastinal) lymph nodes; this can be unilateral or bilateral disease
N1b*	Metastasis to unilateral, bilateral, or contralateral lateral neck lymph nodes (levels I, II, III, IV, or V) or retropharyngeal lymph nodes
M0	No distant metastasis
M1	Distant metastasis
*all categories may be subdivided as solitary tumor(s) and multifocal rumor (m) - the largest tumor determines the classification	

(ii) Follicular Carcinoma

Follicular carcinoma accounts for about 5-10% of all thyroid cancer and commonly **occurs in a goiter which was present FOr long time.** *(NEET, AIIMS 98, MANY PGME)*

Catch: **FO**llicular carcinoma occurs in a goiter present **FO**r longtime

Pathology

- **It appears to be encapsulated**.
- Most important feature is **capsular invasion** and **angioinvasion** (vascular invasion) *(MANY PGME)*
- This carcinoma usually **does not** metastasize to regional lymph node. *(AL 94, MANY PGME)*
- **But hematogenous spread** *(AIIMS 97)* to distinct sites, such as bone, lung, liver occur quite early (because tumour is angioinvasive) causing **pulsatile vascular secondaries.** *(AIIMS 99, AL 95, COMED 07)*
- **Multicentricity,** which is common in papillary carcinoma, **is much rare** in this carcinoma. There are **two varieties** of follicular carcinoma:
  (a) The one is encapsulated, well differentiated low grade malignancy.
  (b) The other variety show vascular invasion quite early and tumour is most aggressive.
- **Differentiated from follicular adenoma on the basis of Capsular and Vascular invasion** histopathologically can be understood from figure 20.19.

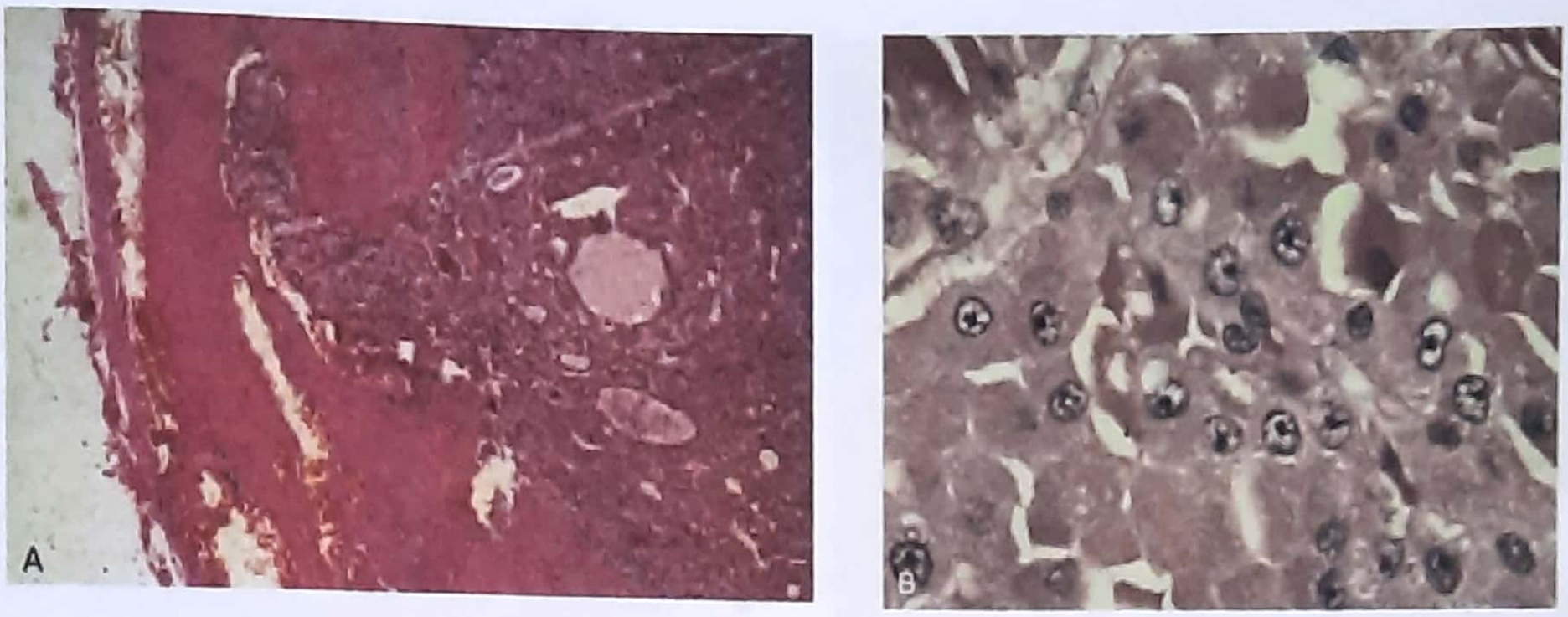

Figure 20.19 : (a) Hematotoxylin and eosin (H&E) staining of a follicular lesion. High-power examination reveals capsular invasion by follicular cells, which is consistent with a diagnosis of follicular thyroid cancer. (B) H & E staining of Hurthle cell cancer showing vesicular nuclei with irregular macronucleoli.

Clinical feature

- This carcinoma tend to occur in older age group usually **around 5th and 6th decade**.
- Three times more common in female than male.
- Often there is history of long standing goiter.
- Regional lymph nodes are seldom involved. *(PGME MANY TIMES)*
- ***FNAC can not differentiate between follicular adenoma and follicular carcinoma*** *(NEET, AL 95,AIIMS 04, MANY PGME).*

Treatment

For Local disease: Total thyroidectomy, **hemithyroidectomy** *(NEET)*.

For Metastatic lesion: Near total thyroidectomy (ie; as much tissue is resectable) along with:

- **Radio iodine (I^{131})** *(NEET)*
- External radiation *(PGI 01)*
- Chemotherapy

Hurthle cell carcinoma

This is a variety of follicular carcinoma and the prognosis of this tumour is intermediate between two type of follicular carcinoma. It has a tendency to occur bilaterally, and rarely take up I^{131}.

(iii) Mixed (Papillary & Follicular Carcinoma)

They comprise only 1-2% of all carcinoma of thyroid and usually behave like papillary carcinoma.

B. UNDIFFERENTIATED (ANAPLASTIC CARCINOMA)

- This accounts for about 5% of all thyroid malignancy.
- Macroscopically the tumour is not encapsulated and usually extends to remaining thyroid tissue. *(PGI 2008)*
- It may extend even out side thyroid to involve adjacent structure and may cause tracheal or esophageal obstruction.
- Regional lymph nodes are frequently enlarged.
- Distant metastases to lung and bone are common. *(PGI 2008)*
- **Highly aggressive and worst prognosis of all thyroid cancers**. *(NEET)*

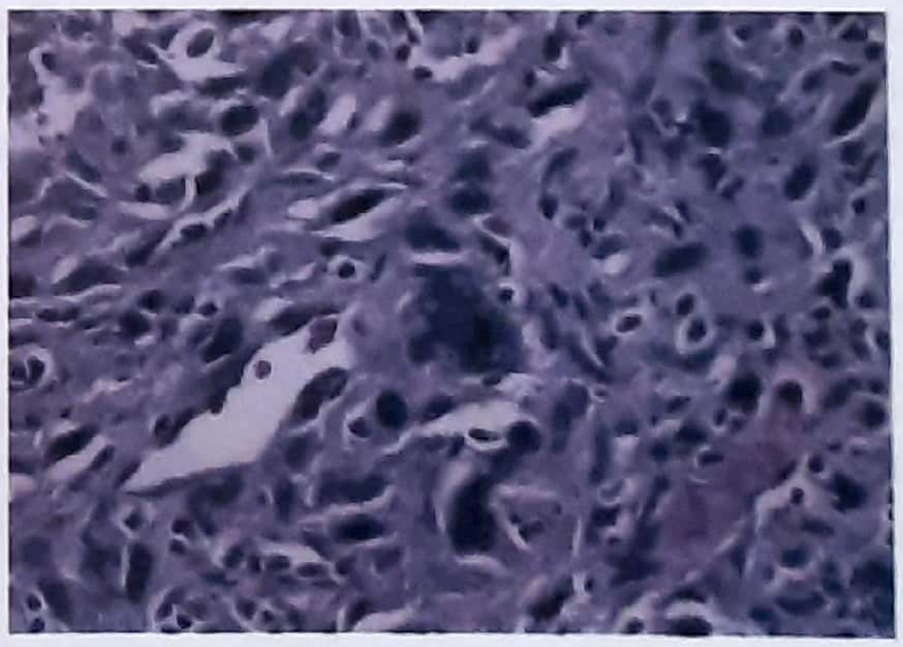

Figure 20.20 : Anaplastic thyroid cancer. Hematotoxylin and eosin staining showing marked nuclear pleomorphism, oval to spindle-shaped cells, and multinucleated tumor cell.

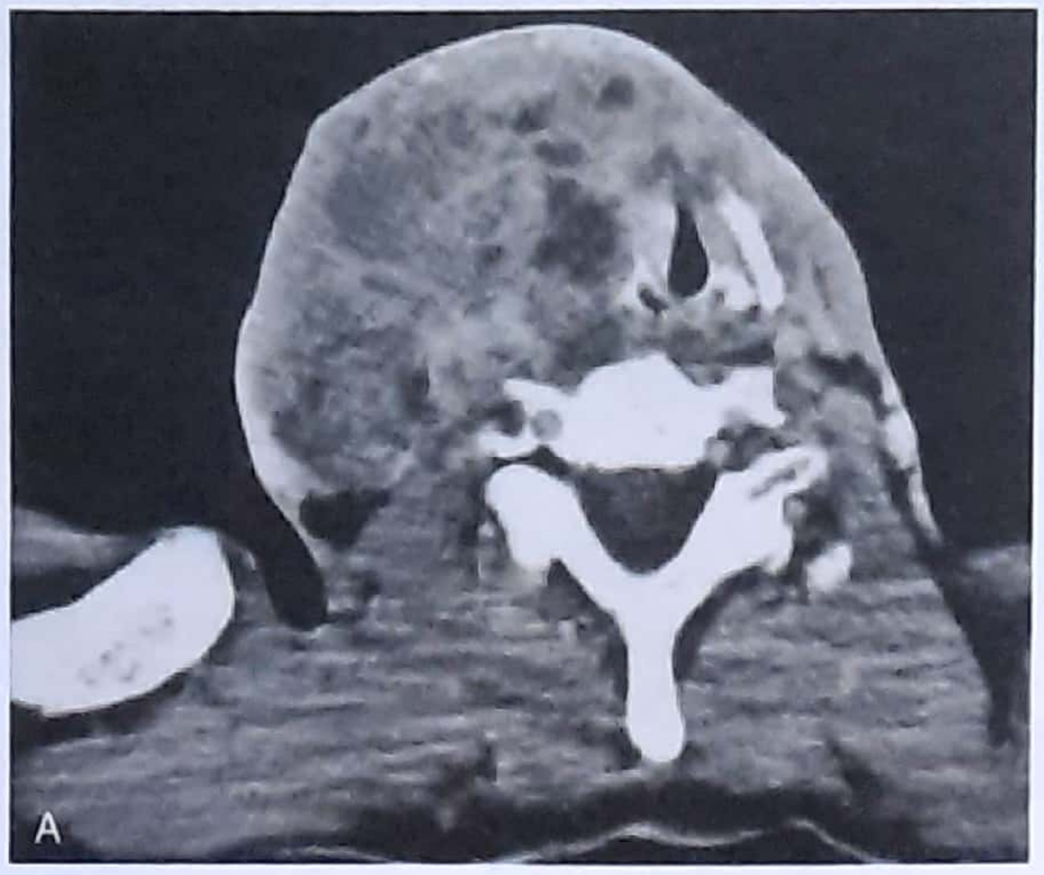

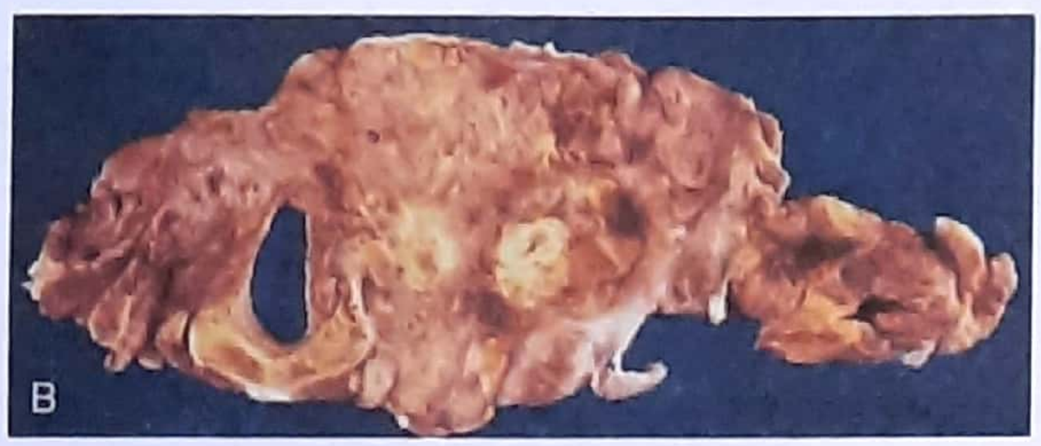

Figure 20.21 : (A) and (B) Rapidly enlarging thyroid mass in a 70 year old man. Computed tomography image demonstrates displacement of the larynx and lateral involvement of both jugular veins. The patient died within 6 months of rapidly progressing follicular cancer.

Clinical feature

This carcinoma usually affect elderly (more than 50 years) *(PGI 04, 08)*. The gland is often fixed to surrounding structure and show **poor movement on swallowing** *(PGI 04)*. By the time patient comes to Surgeon, there is already invasion to trachea and esophagus (usual cause of death). The consistency of gland is hard or very firm. There is sudden increase in size with hoarseness of voice, and often patient dies within 6 months of disease.*(NEET)*

Treatment

Total thyroidectomy with modified neck dissection is treatment of choice, but many patient reach to the surgeon in advance stage when surgery is not possible, and the tumour has already extended into the surrounding structures.

At this point you are advised to revise key box # 20-8 once again on page 245.

II. PARA FOLLICULAR CELL ORIGIN TUMOUR

Medullary carcinoma of thyroid

- It account for about 2.5% of all thyroid malignancies.
- It **arises from the C-cell** ie; **calcitonin** producing cells or parafollicular cells. *(AIMS 93, PGI 01)*
- It occurs at all age; incidence in male is **equal** to female
- **Note:** Almost all other diseases of thyroid are more common in females.
- **Associated with RET Protoncogene mutation.** *(NEET, PGME)*
- The tumour may arise sporadically or it may be familial *(PGI 01, MANY PGME)* Around 20-25% are familial.

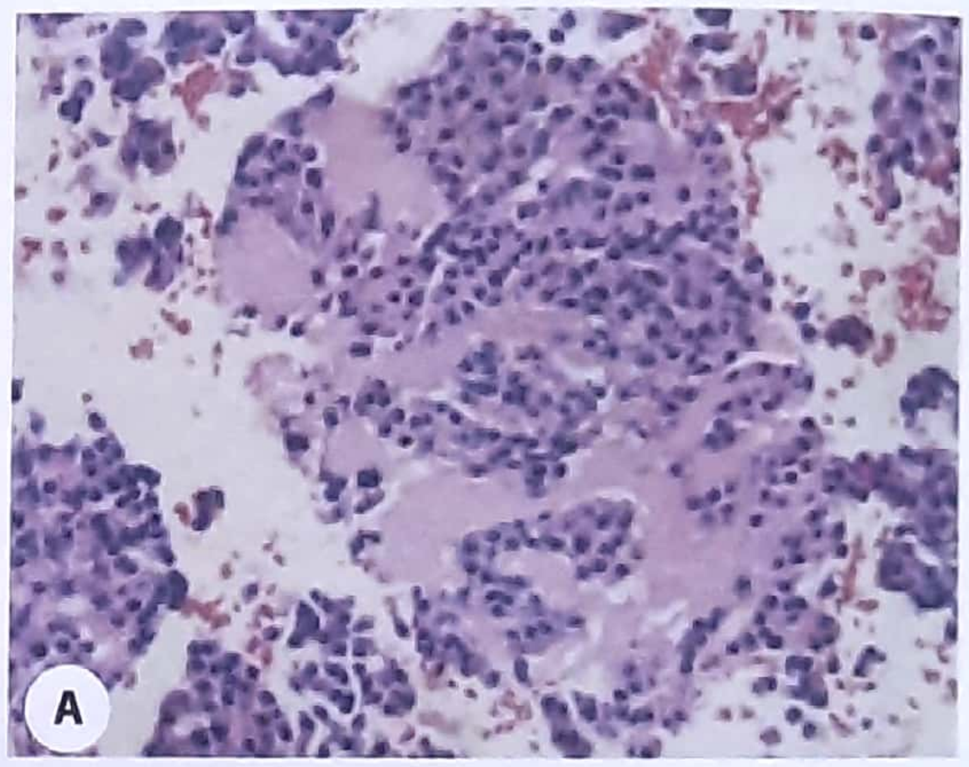

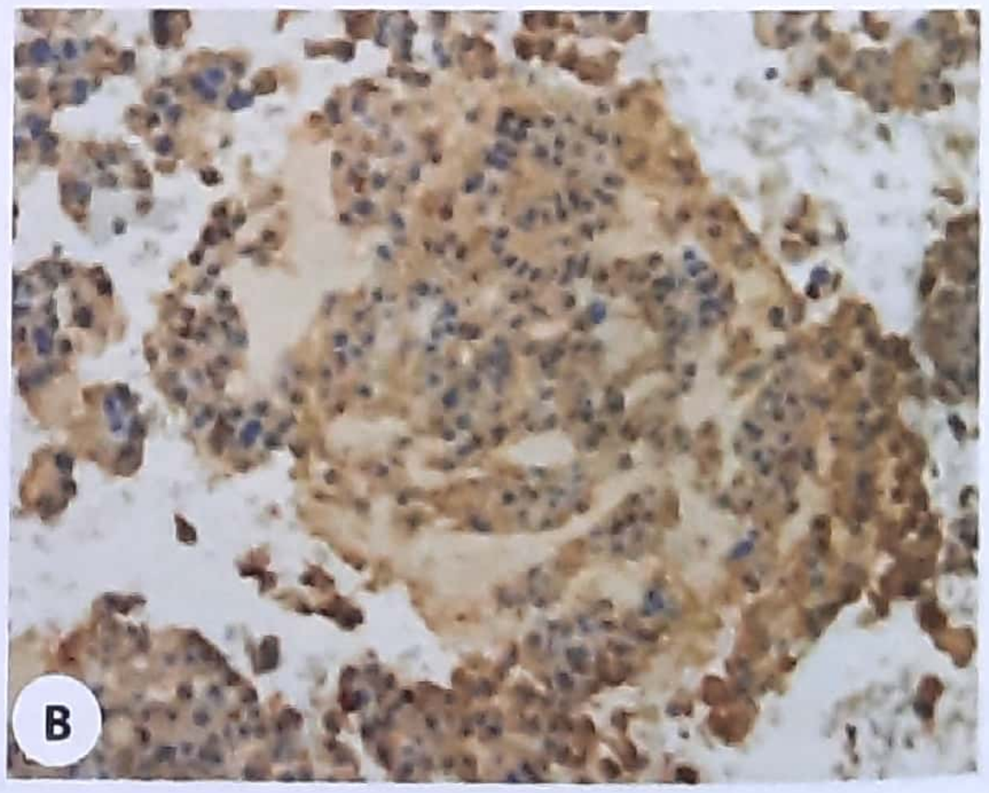

Figure 20.22 : Medullary thyroid cancer (MTC). (A) Hematoxylin and eosin staining of an MTC specimen showing plasmacytoid morphology with eccentric round nuclei. "salt-and-pepper" chromatin, small nucleoli, and amyloid infiltrate. (B) MTC exhibits cytoplasmic positivity on calcitonin staining.

- When familial (**MEN type II it is likely to be associated)** (NEET) either with hyperparathyroidism and pheochromocytoma and MCT and is known as MEN type IIa-sipple's syndrome (AIIMS 99, 2000).
- **In MEN type IIb:** MCT is associated with pheochromocytoma thick lip, lax ligaments and multiple mucosal neuroma with marfanoid habitus.
- The stroma **contains amyloid in most cases** (NEET, AIIMS 2000, PGL 01, AL 02, MANY PGME, PGI NOV 2010)
- Involvement of lymph node occurs in 50-60% of case of medullary carcinoma and **blood borne metastasis are also common**. Metastasis to bone are osteoblastic.

Clinical feature (PGME MANY TIMES)

- Medullary carcinoma have a slow but progressive growth pattern.
- Local invasion of neck structure is common; causing dyspnea (due to tracheal obstruction), dysphagia (due to esophageal obstruction) or hoarseness (due to compression of recurrent laryngeal nerve).
- Most of the patient clinically present with diarrhea which may result from increased intestinal motility and impaired intestinal water and electrolyte flux (Neuroendocrine tumor). (PGI 2010)

Investigation

- **A raised plasma calcitonin level** (NEET, AIIMS 98, AI 95,99, AIIMS 94, 97, 95) **is diagnostic**, however this calcitonin excess is *not* associated with hypocalcemia.
- Tumor cells may secrete serotonin, ACTH and VIP also.

Treatment

Treatment of choice is total thyroidectomy and resection of involved lymph node of neck (AIIMS 05, PGI 05, PGI 2000, AIIMS 08).

- Radiotherapy is not effective, but has some role in residual or recurrent cancer.

Please revise key box 20-8 once again on page 245.

- Prognosis is not good in metastasis. CEA is better (IMP. POINT) prognostic marker than calcitonin. (important point)

(III) NON THYROID CELL ORIGIN TUMOUR

Malignant lymphoma

- Rare (<2.5%), rapidly growing.
- Mainly occurs in elderly females, usually non Hodgkin's B-cell type; Mostly develops in longstanding Hashimoto's Thyroiditis (Chronic Lymphocytic Thyroiditis)
- Using presents as rapidly enlarging (often painless) mass may cause :
  - Acute respiratory distress
  - Hoarseness
  - Dysphagia
  - Fever
- Diagnosed by FNAC
- Treated by Chemotherapy (CHOP regimen)
  - Cyclophosphamide
  - Doxonubicin
  - Vincristin
  - Prednisolone
- It occurs mainly in elderly female, particularly as a complication of **Hashimoto's thyroiditis**.
- **Treatment** is by ***external beam radiotherapy*** if the lesion is localized to the thyroid gland, and by ***chemotherapy*** in more widespread disease.
- *Before concluding this topic kindly go through Key box 20.9, next page.*

****

THYROIDECTOMY

- The various conditions for which thyroid surgery is indicated are mentioned below

Indication of surgery in a thyroid nodule

- Malignant nodule (Biopsy proven)
- Toxic Nodule
- Causing pressure symptoms eg. dyspnea, hoarseness
- Cosmetic reasons
- Patient's request.

- Preoperative indirect laryngoscopy and fasting serum calcium are always obtained. (PGME)
- Pre-operative serum T3 and T4 should be done and must be normal before surgery.
- Removal of thyroid (thyroidectomy) may be necessary in hyperthyroidism and malignancy of thyroid.
- Thyroidectomy may be total or partial.

KEY BOX 20.9

Differential Features of Thyroid Carcinoma

Feature	Papillary Carcinoma	Follicular Carcinoma	Anaplastic Carcinoma	Medullary Carcinoma
Cell of origin	Follicular epithelial cell	Follicular epithelial cell	Follicular epithelial cell	Parafollicular or "C" cell
Frequency	80%	10%	5%	5%
Age and sex	F > M = 3 : 1	F > M	F > M	F = M
Incidence	15-35 years	> 30 years	> 50 years	30-60 years
Local features	Infiltrative masses multifocal and bilateral; lymph nodes often positive	May be grossly infiltrative or "encapsulated" angio-invasive	Massively infiltration locally.	Slowly growing mass; infiltrative
Lymphatic metastasis	+++	+/–	+++	+ (early)
Blood borne metastasis	Late; uncommon	+++	+++	+ (early)
Five year survival rate	90% slow growing	65%	Nil	50%
Tumour markers	Thyroglobulin	Thyroglobulin	None	Calcitonin

- In *Partial thyroidectomy, the Posterior parts of both lobe are left behind i.e., Preserved.* (MAY BE FUTURE PGME)
- While performing **Thyroidectomy** the superior thyroid artery is ligated *near* the gland to save external laryngeal nerve, and inferior thyroid artery in ligated *away* form the gland to save the recurrent laryngeal nerve. (AIIMS 03 & MANY PGME)

Post Operative Complication (VERY IMPORTANT PGME TOPIC)

1. Hemorrhage (AIIMS-2000)

Due to slipping of ligature on the superior thyroid artery.

- Hematoma, thus resulting may cause **airway compromise** and must be evacuated immediately in O.T. (AIIMS 99)
- Hematomas may occur immediately or later on. Treatment is evacuation/aspiration of hematoma.
- **Hemorrhage is usually due to superior thyroid artery.** (NEET)

2. Respiratory obstruction

Causes of respiratory obstruction includes:

- *Laryngeal edema* - M/C Cause,
- Tension hematoma
- Bilateral recurrent laryngeal nerve paralysis
- Tracheomalacia

3. Recurrent laryngeal nerve paralysis (Hoarseness)

- It may be unilateral or bilateral, transient or permanent.
- Bilateral paralysis causes respiratory obstruction, dyspnea and stridor.
- *It is must to check vocal cord status by laryngoscopy before surgery.* (NEET)

4. Injury to other nerves (AIIMS JUNE 20)

- *External branch of superior laryngeal nerve.*
- Cervical sympathetic chain-*causing Horner's syndrome (Ansa cervicalis).*

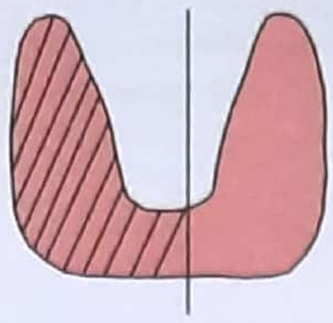

1. **Hemithyroidectomy** = Lobectomy (1) + Isthmusectomy
2. **Subtotal thyroidectomy** = 2 × Subtotal lobectomy + Isthmusectomy - 8gm of tissue left behind.

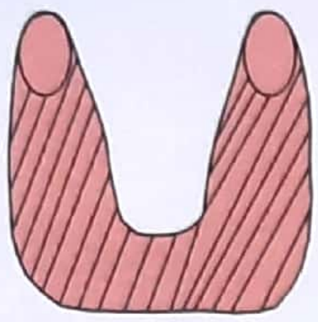

3. **Total thyroidectomy** = 2 × Lobectomy + Isthmusectomy
4. **Near total thyroidectomy** = also known as **hartley Dunhill procedure**
   - Lobectomy + subtotal lobectomy + Isthmusectomy
   - A part of tissue is left behind in one lobe.

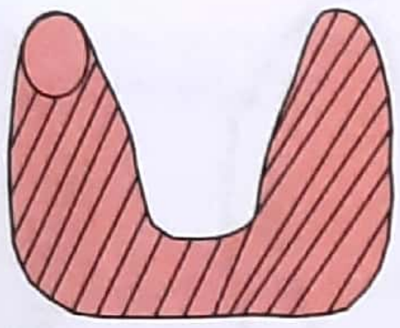

Figure 20.23 : Types of thyroid surgery

5. Parathyroid insufficiency (Hypocalcaemia)

It is due to:

(i) Damage to blood supply of parathyroid gland during surgery (more common cause) *(PGME)*.

(ii) Removal of all parathyroid glands.

- Seen usually after Total or Subtotal thyroidectomy *(AI 08)*.
- *Features of* ***Hypocalcemia*** *(NEET)*:- Circum oral and finger tip numbness, tingling, tetany, carpopedal spasm and laryngeal stridor, Usually presents 2-5 days after operation. *(AIIMS 03, 04)*

Treatment

Oral calcium with vitamin D supplement. *(AI 01)*

- IV calcium gluconate may be required in severe cases. See key box 20.10, next page.

6. Thyroid insufficiency

Occurs usually in 2 years, but sometimes may be delayed up to 5 years. *(PGME, AIIMS)*

7. Thyrotoxic crisis (Thyroid Storm)

It is acute exacerbation of thyrotoxicosis, in patients who have underwent surgery with out attaining euthyroid state. *(PGME, COMED 07)*

8. Chest infection

9. Wound infection

****

KEY BOX 20.10

Management of post op. Hypocalcemia

(AI 01, AIIMS Nov 2000, AI 2000)

- **Transient hypocalcemia**
  - Asymptomatic with calcium level >8 mg/dl → No t/t required, only dietry adjustment
  - Mild symptoms or calcium level <8 mg/dl → Oral calcium
  - Severe symptoms → IV calcium (calcium gluconate)
- **Prolonged/Permanent hypocalcemia** → Oral calcium + Vit D

(Note: normal serum Ca+ = 9-11 mg/dl)

SOLITARY THYROID NODULE

Thyroid swelling which appears to be ***isolated,*** and confined to one or other lateral lobe or to the isthmus is not uncommon. Most of the swelling are either, of the following:-

1. **Simple nodular goiter:** formed from inactive colloid (benign colloid nodule). This is most common cause of solitary thyroid nodule (70%). Please see figure 20.25.
2. Apparently **localized manifestation of simple multinodular goiter** (when in a multinodular goiter only one lobe in clinically palpable)
3. **Neoplastic group** either benign or malignant, cystic or solid. (Follicular adenoma is 2nd most common cause of solitary thyroid nodule-25%)

Clinical Feature

A clinically palpable solitary nodule is a cluster of nodule of non-toxic goiter usually between 1-4 cm, in total size.

The patient complains mainly of a localized swelling in the neck, which moves with deglutition. Occasionally patient may complain of acute pain, and sudden (rapid) increase in the size of swelling, when there occurs hemorrhage inside the nodule.

Diagnosis

The main problem is to diagnose the nature of the nodule. Which can be attained by the following investigation.

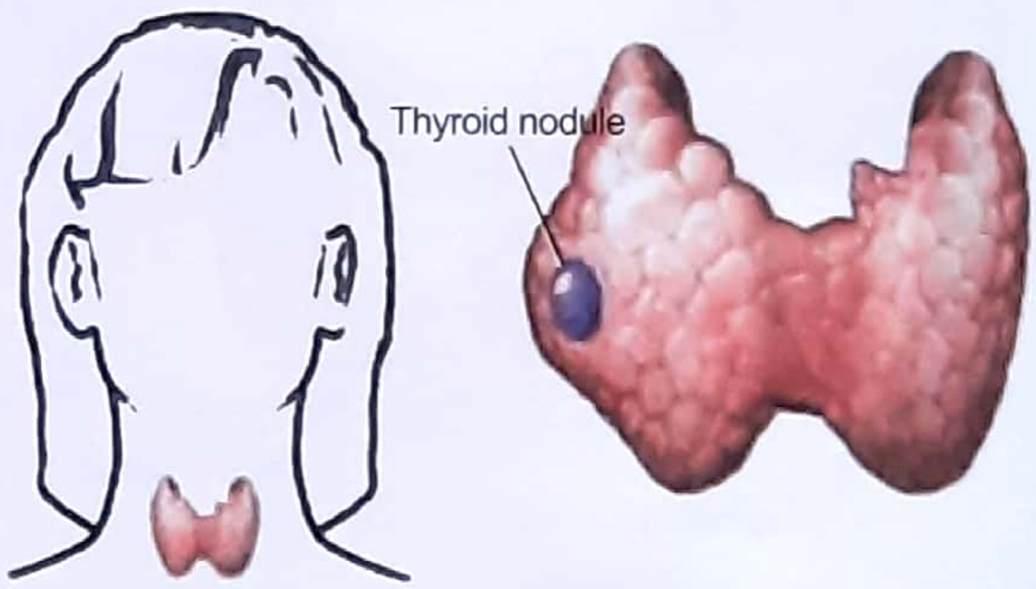

Figure 20.24: Digramatic representation of solitary thyroid nodule

Figure 20.25: Solitary thyroid nodule

1. Thyroid function test

This test is not very useful as diagnostic test since most patient with thyroid cancer and benign thyroid swelling are in euthyroid state.

2. Radioactive Scan

It is very helpful to differentiate "hot" from "cold" nodule,

(i) *Hot Nodule* unlikely to be a carcinoma and indicate to be a toxic nodule

(ii) *Cold nodule* more suspicious to be a malignant nodule (Hot and cold nodule for details see page 196)

3. Ultrasound Scanning

It is commonly used in diagnosing a thyroid nodule. It can accurately tell; whether the nodule is cystic or solid or a combination of both. But the main problem with ultrasound is that, it can not predict the underlying pathology, ie; can not tell whether, it is a benign or a malignant swelling.

4. Aspiration of Fluid

In a case of cystic swelling - It can be done for treatment as well as for cytological examination of aspirated fluid.

5. Needle Biopsy

This is a very important investigation modality. Three major techniques used are:

(i) *Fine needle aspiration cytology (FNAC) for solitary thyroid nodule.* (NEET) Using 21 gauge needle. It is helpful in providing specimen for cytological examination. *This has now become the first investigation for a solitary thyroid nodule. See fig. 20.8 at page 232* (MANY PGME)

(ii) *Large Needle Biopsy*: Using 16-18 gauge needle. Provides tissue for histopathological study.

(iii) *Cutting needle Biopsy:* Using *silverman needle,* technique is used only in nodules of more than 2 cm in diameter. The main problem with this technique is hemorrhage and vascular injury.

Indication of surgery in a thyroid nodule

- Malignant nodule (biopsy proven).
- Toxic Nodule
- Causing pressure symptoms eg. dyspnea, hoarseness
- Cosmetic reasons
- Patient's request.

Treatment

- The treatment plan depends upon the pathological nature of the nodule which is diagnosed by various special investigation, which have been discussed above.
- Once the diagnosis is confirmed, that it is neither a toxic non-neoplastic, nor a cystic swelling, but a simple nodular swelling, the treatment becomes mainly cosmetic in patient above 40 year of age. **The best surgical option for a simple thyroid nodule (nonmalignant) is hemithyroidectomy.** (NEET)
- As the estimated risk of malignancy is about 5-20%, and keeping the fact in mind that these goiter may infrequently turn toxic- the treatment is excision of solitary nodule along with a margin of normal thyroid tissue around it (lobectomy). The excised tissue is sent for histopathological examination.
- If carcinoma is detected after histopathological examination, total thyroidectomy is advised. Please see key box 20.11.
- Thyroid nodule with lymphadenopathy indicate malignancy so treatment total thyroidectomy along with modified radical neck dissection.

****

EXAMINATION OF THYROID

A normal thyroid gland is usually not palpable except in thin necks. 2 methods are popular for examination of thyroid.

1. Lahey's Method

Palpation of each lobe of thyroid glands is better carried out from the front by LAHEY'S METHOD; in which for palpation of right lobe, thyroid gland is pushed from left to right to make it more prominent for palpation with the other hand and vice versa.

2. Crile's method

It is useful in doubtful cases of slight enlargement of the thyroid gland or for appreciation of small nodule present in the substance of the thyroid gland.

KEY BOX 20.11

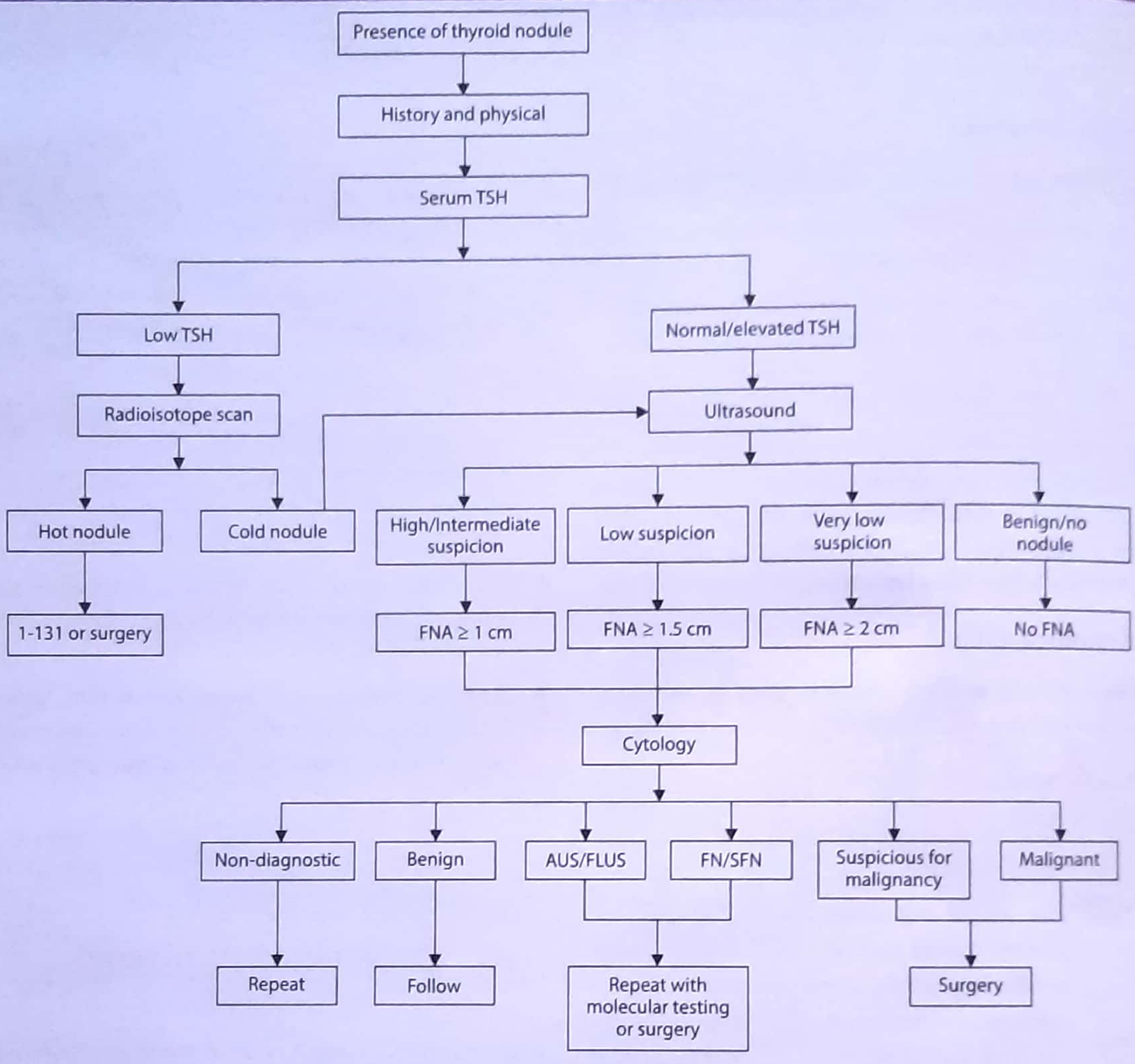

Workup of a thyroid nodule. *AUS*, Atypia of undetermined significance; *FLUS;* follicular lesion of undetermined significance; *FN*; follicular neoplasm; *FNA;* fine-needle aspiration biopsy; *SFN;* suspicious for follicular neoplasm; *TSH*; thyroid-stimulating hormone.

Method

In this simple manoeuvre the index finger is kept on the thyroid gland while the patient is asked to swallow. The lower border of the gland is palpated when it moves up. This test also helps to exclude the possibility of the retrosternal goiter. **Palpate the swelling as per the useful five headings:**

1. **Palpation of skin over the swelling for increase in temperature:** They are present in inflammatory swellings, e.g. acute thyroiditis, Thyroglossal abscess etc.
2. **Palpation of swelling underneath the skin for surface, edge, and shape:** Surface is smooth and the edge is well defined in primary thyrotoxicosis, colloid goiter and adenoma, while the surface is nodular and edge may be well defined or ill-defined in multinodular goitre or carcinoma of thyroid.
3. **Palpation of the swelling for knowing content by performing the following tests:**
   (i) *Fluctuation:* It is a useful test to find out consistency (solid or liquid) of a lump. Consistency may be uniform or variable. *Normally fluctuation is positive in cystic swellings and negative*

in solid swellings. However, it is worth keeping in mind that in a case of thyroid gland, cystic swelling may feel solid, due to the presence of fluid under tension.

(ii) *Pulsation and thrill.* These when felt at lateral lobes near superior poles is pathognomonic of toxic goitre due to increased vascularity.

4. **Palpation of the adjoining structures:** Following structures are carefully examined for finding out mobility or fixity of the swelling:

(i) ***Skin***

(ii) ***Muscles:*** (Sternomastoid and infrahyoid muscles) whether they are adherent to the swelling. Inflammatory *or* malignant swelling may become adherent to the surrounding muscle.

(iii) ***Artery:*** Normally, the common carotid artery is felt at the level of upper border of the thyroid cartilage. It is merely displaced backwards by a benign thyroid swelling. In malignancy of the thyroid, carotid sheath is infiltrated and compressed completely; hence carotid pulsation is not palpable (**positive Berry's sign**)

(iv) ***Nerves:***

(A) Recurrent laryngeal nerve involvement by a malignant growth will result in hoarseness of voice.

(B) Sympathetic trunk involvement results in ***horner's syndrome*** on the affected side, which is characterized by:

(a) Slight sinking of the eyeball into the orbit (enophthalmos due to paralysis of Muller's muscle)

(b) Drooping of the upper eyelid (pseudoptosis due to paralysis of sympathetic fibres)

(c) Contraction of the pupil (miosis due to paralysis of dilator pupillae) with absent spinociliary reflex

(d) Absence of swelling (anhidrosis); and

(e) Flushing of the face and nasal congestion due to vasodilatation.

(v) ***Organs***

Trachea: check the position of trachea by feeling with tip of one finger in suprasternal notch; wherein it should be felt exactly in centre. Compression of trachea from both sides by a thyroid swelling produces a scabbard (narrowed) trachea which can be tested clinically by **kocher's test,** ie; stridor is produced by applying pressure on the lateral lobes of the enlarged thyroid. Esophagus compression may result dysphagia.

5. Palpation of the opposite lobe (especially in unilateral lesion), the skin and other structures for clinical evidence of infiltration by an advanced malignant growth of the thyroid.

****

Sample Questions for Prof Examination

1. Discuss primary thyrotoxicosis.
2. Discuss the management of solitary thyroid nodule.
3. Classify thyrotoxicosis. How will you manage secondary thyrotoxicosis in a patient of M.N.G. aged 60 yrs.
4. Describe various tests for evaluating the functions of thyroid gland. Dicuss the clinical features and treatment of a patient of Grave's disease.
5. What are the causes of bilateral asymmetrical enlargement of Goiter? Give differences between primary an secondary thyrotoxicosis?
6. Discuss the etiology pathology clinical feature and management of nontoxic multinodular goiter.
7. Write short notes on medullary Ca of thyroid.
8. Write short note on follicular Ca of thyroid/Papillary Ca of thyroid.

21 Parathyroid and Adrenals

Contents

- Para Thyroid Gland
  - Surgical anatomy
  - Hyperparathyroidism
  - Hyperthyroidism
- Adrenal Gland
  - Cushing syndrome
  - Primary hyper aldosteronism (conn's syndrome)
  - Secondary hyperaldosteronism
  - Neoplasm of adrenal

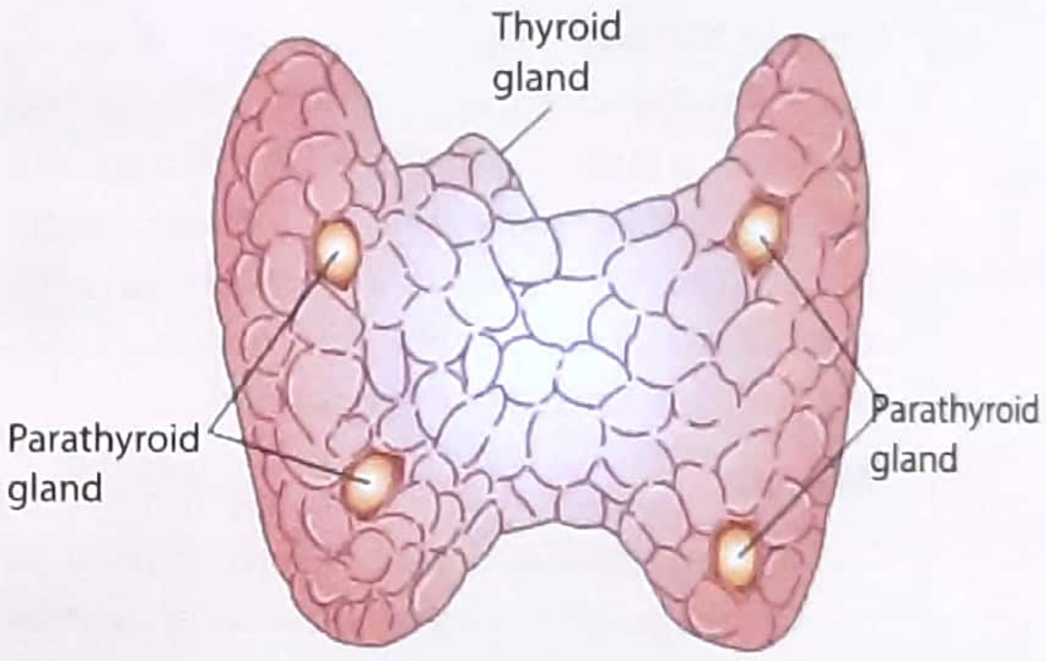

Figure 21.1: Posterior view of Thyroid gland

PARA THYROID GLAND

Parathyroid glands are usually four in number, situated in two pairs one above the other; on posterior aspect of the thyroid gland. The gland is small about 68 mm in diameter. Please see figure 21.1

Development

Superior parathyroid glands are derived from endoderm of 4th branchial pouch. (PGME)

Inferior parathyroid glands are developed from 3rd branchial pouch along with thymus. (PGME)

Blood supply

The arterial supply to both superior and inferior thyroid glands in predominantly from inferior thyroid artery. (PGME)

Physiology

The hormone secreted by parathyroid gland is parathormone (PTH) which **is a polypeptide,** *containing 84 amino acids* (PGME). It's secretion is *not controlled by pituitary gland.* (PGME)

Function

PTH causes **rise of *ionized fraction* of serum calcium.**

This is done by the following mechanisms:

1. By causing resorption of bone
2. It converts Vit D into active principle, which is 1, 25-dihydrocholecalciferol is kidney.

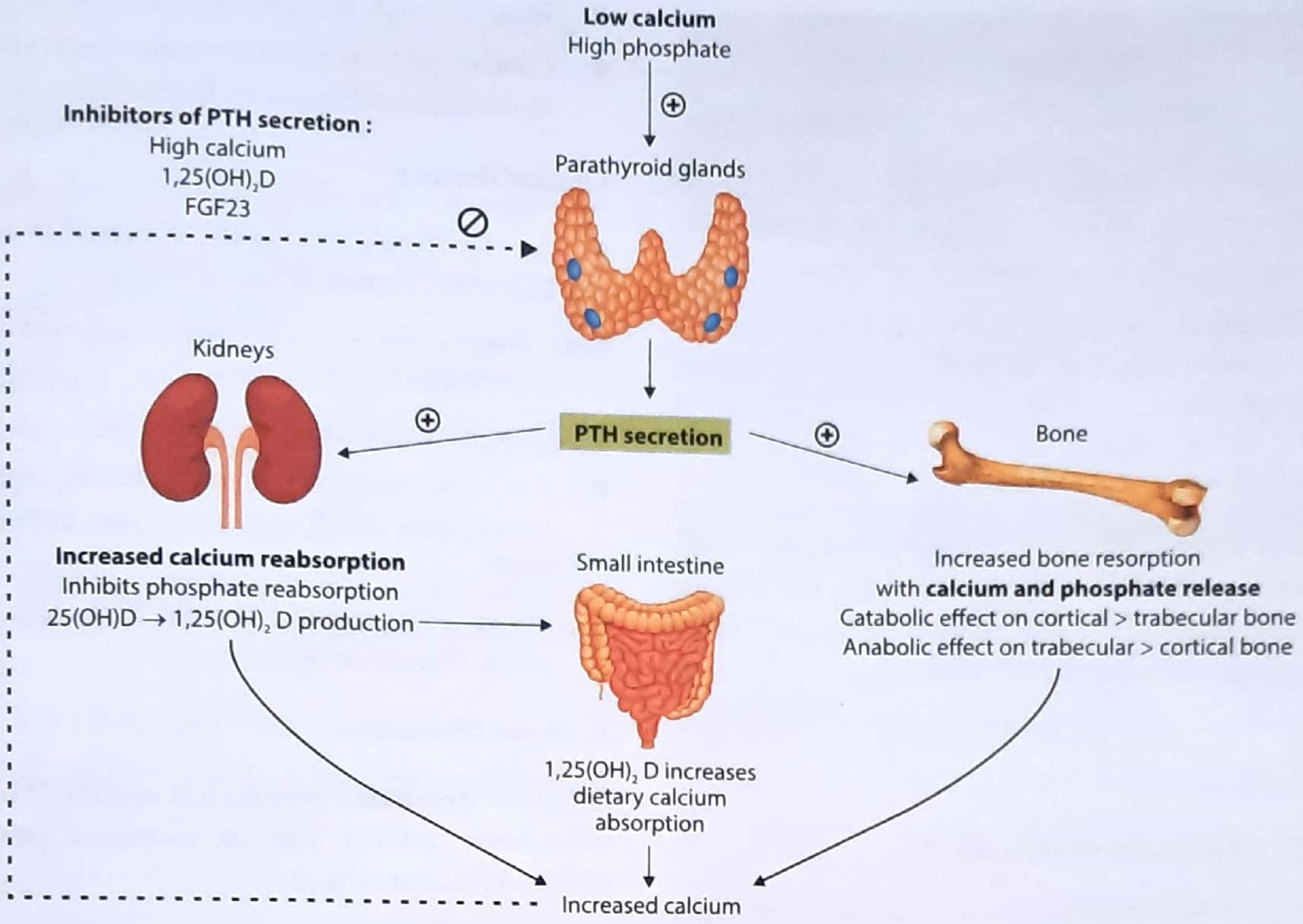

Figure 21.2: Regulators of parathyroid hormone *(PTH)* secretion and PTH effects on calcium homeostasis. FGF23, Fibroblast grwoth factor 23; 25(OH)D, 25-hydroxyvitamin D; $1,25(OH)_2$ D, 1,25-dihydroxyvitamin D.

3. PTH causes increased reabsorption of calcium in the distal convoluted tubule. (Figure 21.2) and key box 21.1.

HYPER PARATHYROIDISMS

Hyperparathyroidism is classified as primary, secondary and tertiary.

First of all I will try to explain each condition; then we will discuss them one by one.

Primary hyperparathyroidism

It is a de-novo condition, that means disease lies in parathyroid gland. In this condition there occurs a parathormone secreting adenoma in **one of the four** parathyroid gland.

Secondary hyperparathyroidism

It is due to increased parathormone secretion, secondary to prolonged hypocalcemia and is seen in case of chronic renal failure, malabsorption, osteomalacia and rickets,

KEY BOX 21.1

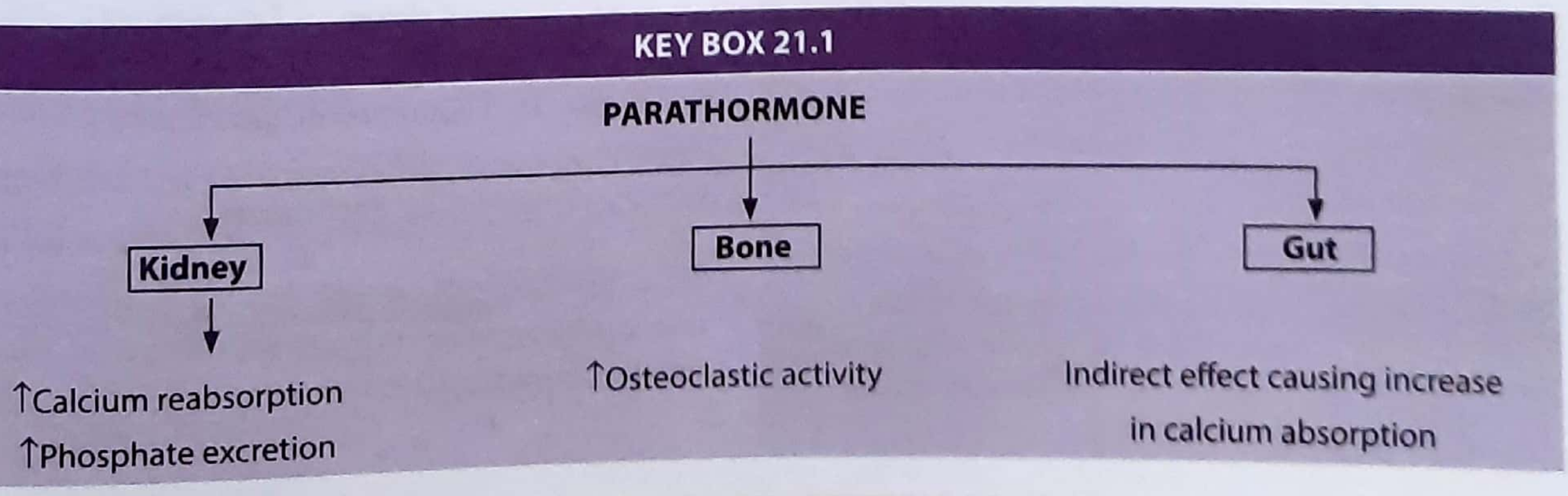

NOTE: That the cause of it is not a parathyroid adenoma but other than it, away from the gland.

- The serum calcium level is usually normal or low.
- In secondary hyperparathyroidism all four glands are involved and hyperplasia of all four gland occurs.
- Vertebral body shows *"rugger jersey pattern"* *(PGME)*
- *Metastatic calcification* is also commoner in secondary hyperparathyroidism than in primary hyperparathyroidism.

Tertiary hyperparathyroidism

This occurs in few cases of secondary hyperparathyroidism where, continuous stimulation of the parathyroid gland results in adenoma formation in one of the thyroid gland, causing autonomous PTH secretion.

Now we will discuss primary hyperparathyroidism in detail.

Primary hyperparathyroidism

- In at **least 80% of the patients with primary hyper parathyroidism, the cause is an adenoma of one parathyroid gland**. *(NEET, AIIMS 87, AL 89)*
- Parathyroid adenoma most commonly involves ***inferior parathyroid gland*** *(AIIMS 02)*.
- Hyperplasia of all four glands is a much less common cause.

KEY BOX 21.2.1

Summary *(MANY PGME)*

Features of Primary hyperparathyroidism

Bone	**CVS**
• Bone pain	• Hypertension
• Osteopenia	• Myocardial/vascular calcification
• Sub periosteal bone resorption	**Psychiatric**
• Pseudo tumour	• Anxiety
• Pathological fracture	• Dementia
Gastro intestinal	• Mood changes
• Peptic ulcer	**Renal**
• Pancreatitis	• Renal stone
• Constipation	• Urinary tract calculi

Other Feature: Following symptoms may also be present, eg; Muscle weakness (myopathy), tiredenss, anorexia, thirst, polyuria.

- In some cases gland show a nodular hyperplasia.
- Carcinoma is very uncommon cause of hyperparathyroidism and accounts for less than 2% of patients.

Clinical feature

- As like thyroid disease the disease is more common in female. Female/Male ratio is 2:1

NOTE: Only one; disease medullary carcinoma of thyroid in which male, female ratio is equal)

- Usually affects in 5th decade of life.
- The *most common presentation is asymptomatic hypercalcemia which occurs* in about 60% of patients. *(PGME)*
- About 20% patients present with recurrent renal stone. Please see figure 21.3

1. Bone Disease

Extensive **decalcification** occurs as a result of increased osteoclastic activity due to increased parathormone (PTH). Which results in -

- Bone pain
- Sub-periosteal erosion (On radial aspect of middle phalanges and clavicle)
- Cysts in bone-Pseudotumours

2. Renal disease

In hyperparathyroidism the level of serum calcium is increased, deposition of calcium salts *(metastatic calcification)* may occur in many parts of body such as

Kidney - Renal stone (nephrocalcinosis)

Cornea - Corneal calcification

Calcium may also get deposited in renal blood vessels (intima) causing renal ischemia and hypertension.

3. Abdominal Pain (Abdominal groans)

Calcium stimulates gastrin secretion

Calcium → ↑ Gastrin

↓

↑ Secretion of .gastric juice

↓

Peptic ulcer

↓

Epigastic pain and dyspepsia

- Hypercalcemia can cause pancreatitis, which may also present as epigastric pain radiating to back.

4. Psychiatric Moan

These patient often a middle aged female are often depressed and anxious.

Investigation *(PGI 80, 85, AMU 88, AIIMS 81)*

1. *Serum calcium:* Increased serum calcium
2. *Serum phosphate : In* about half of the patients *serum phosphate is decreased*.
3. *Serum PTH assay:* Detection of serum PTH
4. *Serum alkaline phosphatase*: Due to destruction of bone, elevated level of serum alkaline phosphate is detected.
5. *X-ray:* Will reveal bone destruction.
6. *Ultrasound of neck:* will detect enlarged parathyroid.
7. *CT Scan*
8. *Isotope scan*

Treatment

The treatment of Primary hyperparathyroidism depends upon the cause :

Medical

Non-surgical option for patient with hyperparathyroidism include:

1. Exclude progressive rise in serum calcium.
2. Estrogen or bis-phosphonate therapy to lower serum calcium.
3. Dietary calcium restriction, adequate hydration.

Surgery

First of all preoperatively correction of hypercalcemia is done, by giving rapid infusion of normal saline drip and furosemide. Then the:

Treatment strategy is as follows:

(a) Single parathyroid adenoma (85%): Resection *(AIIMS 95)*

(b) Two adenomas (5%): Resection

(c) Hyperplasia of all four glands: Resection of 3 1/2 glands *or* all four glands with autotransplantation of one of the gland in **forearm (Brachioradialis)** or sternocleidomastoid muscle.

KEY BOX 21.2.2

Indications for surgical intervention in secondary hyperparathyroidism.

Essential components

1. Persistently high serum level of intact PTH >500 pg/ml
2. Hyperphosphataemia (serum P >6 mg/dl) or hypercalcaemia (serum Ca >2.5 mmol/L or 10 mg/dl) which is refractory to medical management
3. Estimated volume of the largest gland >300-500 mm^3 or long axis >1 cm

Clinical findings

If patients have one of these symptoms, parathyroidectomy should be recommended:

- Severe osteitis fibrosa with associated high bone turnover.
- Subjective symptoms (bone and joint pain, arthralgia, muscle weakness, irritability, purititis, depression)
- Progressive ectopic calcification
- Calciphylaxis
- Progressive reduction in bone mineral content
- Anaemia resistant to erythropoietin stimulating agent (ESA)
- Dilated cardiomyopathy/cardiac failure

Note: Hypocalcemia is most common postoperative complication after excision of parathyroid adenoma, which results due to increased uptake of calcium by bone. *(AIIMS 92)*

Miami Criteria *(NEET-20)* **-** Used to determine the extent of resection of parathyroid gland done in a case of primary hyperparathyroidism due to adenoma.

- A decrease in intraoperative PTH level.
- A successful exploration was defined as a 50% or more decline in intraoperative PTH level from base line and a normal or near normal intraoperative PTH level at 10 minutes post excision.

Complication

Recurrent laryngeal nerve damage, permanent hypoparathyroidism & persistent or recurrent hypoparathyroidism.

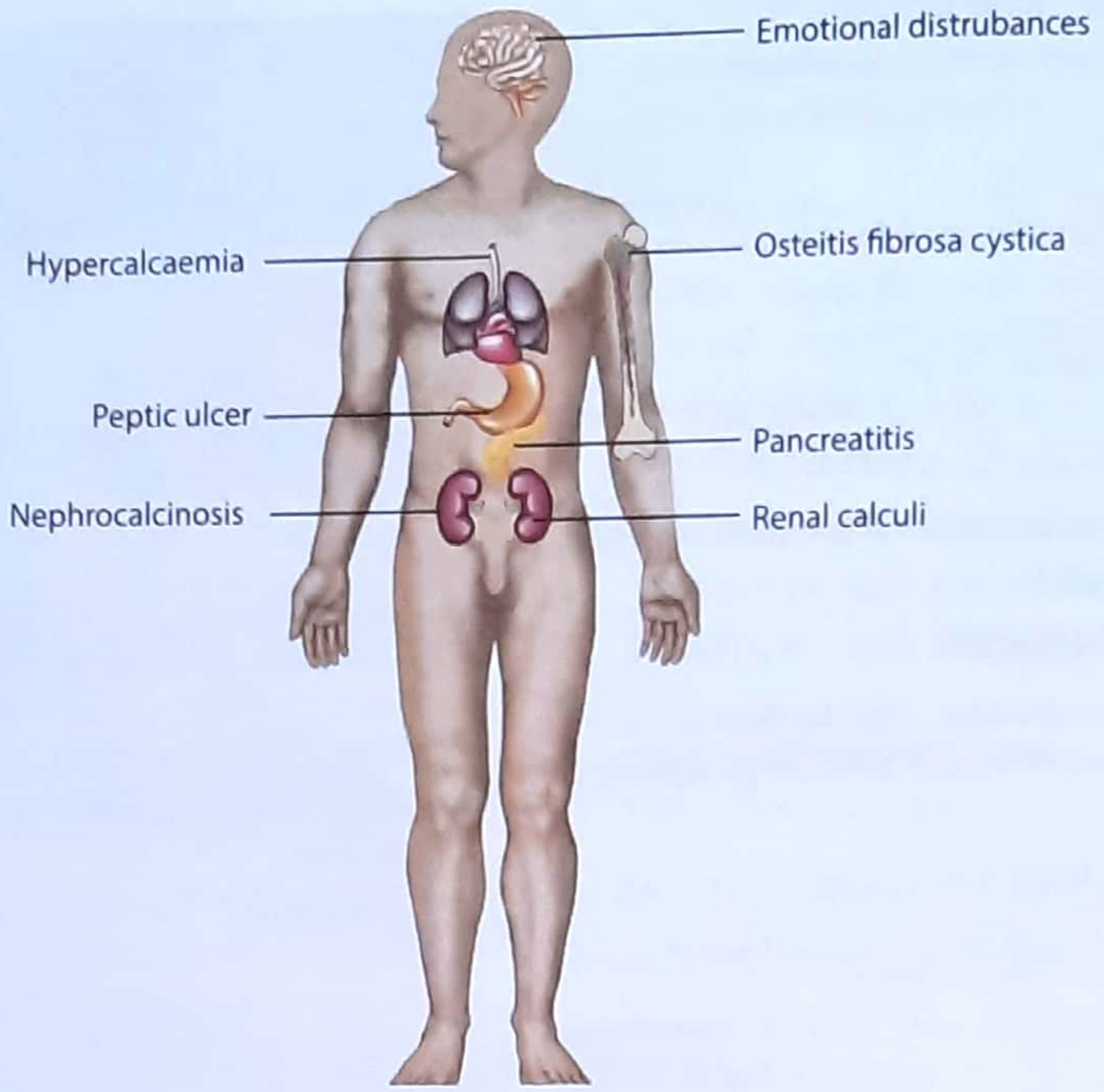

Figure 21.3: Chief clinical manifestations of hyperparathyroidism

Persistent disease is defined as an elevated serum calcium within 6 weeks of surgical intervention & recurrent disease is defined as an increase in calcium levels after 6 months with an intervening period of normocalcemia.

****

Parathyroid Carcinoma

- It is a very rare disease; and is responsible for only 1-2% of cases of hyperparathyroidism.
- Classically presents with features of severe hypercalcemia and very high PTH level.
- Palpable neck mass can be found.

Treatment

Excision of tumour mass, with ipsilateral thyroid lobectomy and lymph node dissection.

****

Hypoparathyroidism

Causes

1. The **most common cause** of hypoparathyroidism is *damage to parathyroid gland during thyroid surgery.* (PGME).
   - Bruising or slight damage to the blood supply (inferior thyroid artery) of parathyroid may cause transient hypocalcemia.
   - It takes about 2-5 days to reach a low calcium level which returns to normal in next 3-5 days.
2. **Idiopathic hypoparathyroidism:** A rare disease. It may be as a result of the presence of antibodies against parathyroid tissue.
3. **Di-George syndrome:** Infants born with this syndrome suffers from hypoparathyroidism, as well as depression of cell mediated immunity. Since they have neither parathyroid gland nor thymus. (**NOTE:** both develop from third branchial pouch).

Clinical feature

- *Earliest manifestation of hypoparathyroidism is numbness and tingling in circum oral area, finger and toes due to hypocalcaemia.* (IMP. POINT)

KEY BOX 21.3

Management of hypocalcemia

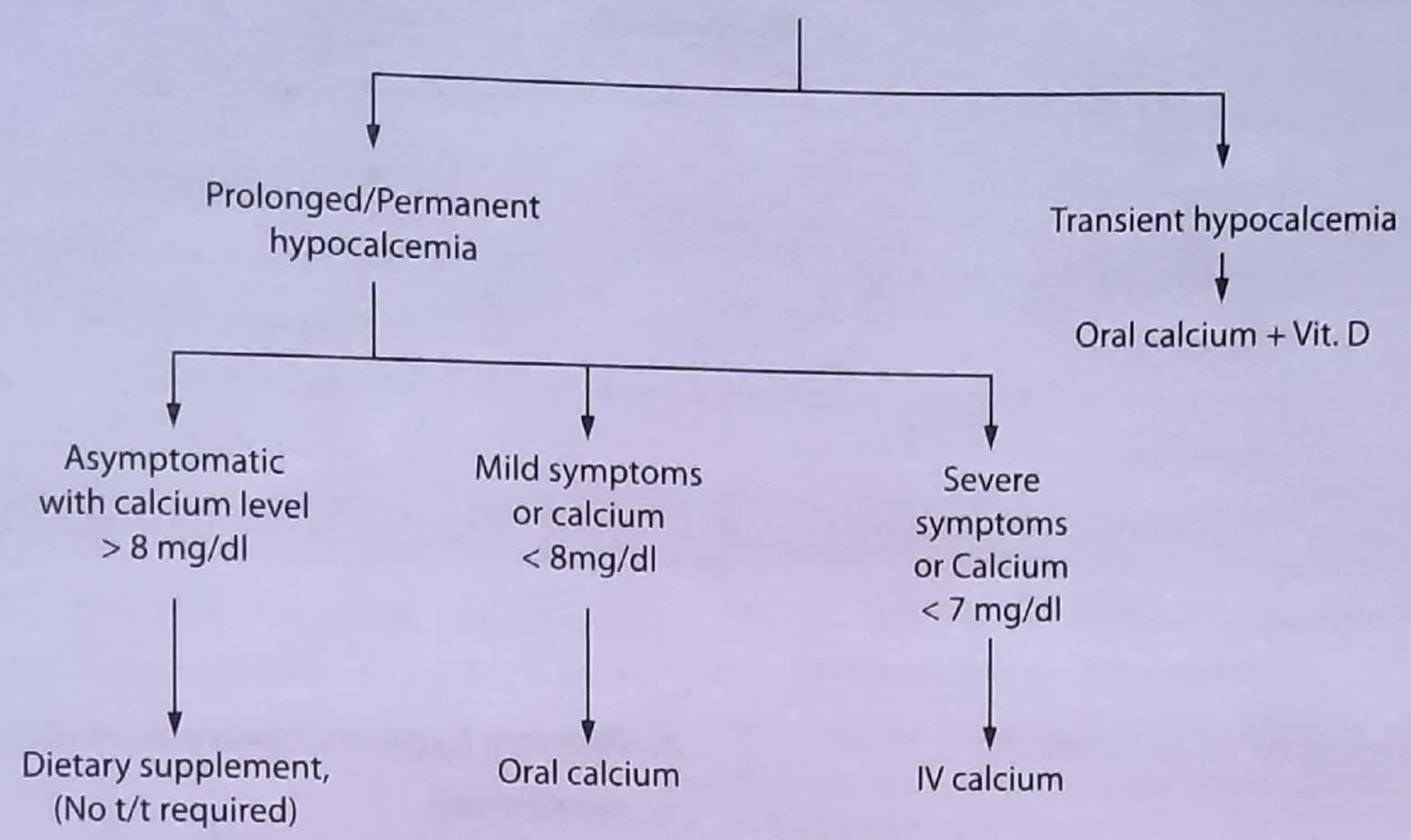

- Mental symptoms in form of anxiousness and depression are also common.
- In severe hypocalcaemia **tetany** may develop. There may be carpopedal spasm, ie; MP joint is flexed with extension at inter phalangeal joint and adduction of thumb.
- A stridor is a dangerous complication of severe tetany due to spasm of muscle of respiration.
- On ECG:- prolongation of QT interval.

Diagnosis

This is established by estimating serum calcium level, which is usually less than 7mg % (normal value = 9-11 mg%).

Treatment of hypocalcemia

I have made a flow chart for better & easy understanding see box 21.3; read it from there.

****

ADRENAL GLAND

Adrenal glands are two in number, which lie retroperitoneally in close proximity to the upper pole of the kidney. *Adrenal gland is essential for life* (PGME). The life saving hormone such as corticosteroids, catecholamines are secreted by adrenals. See key box 21.4 and figure 21.4.

A. Diseases Related To Adrenal Cortex

1. Cushing Syndrome

[Kidney read this topic from a standard medicine book Harrison's] I have out lined some important facts only.

- Gushing syndrome, occurs *when there is prolonged elevated Glucocorticoid (cortisol) level*. (MANY PGME)
- *Most common cause of cushing syndrome is chronic iatrogenic administration of corticosteroids.* (MANY PGME)
- Other causes are *adrenal hyperplasia (2nd most common),* tumour of adrenal cortex, or ACTH releasing pituitary adenoma.

Clinical manifestations

These are: truncal obesity, buffalo hump, moon facies, stria on lower abdomen, hypertension, hirsutism and edema. Late features are osteoporosis with pathological fractures, atherosclerosis, and glucose intolerance, acne and infertility.

Diagnosis: is made by

(i) Estimation of 24 hours urinary free cortisol excretion.

(ii) Dexamethasone suppression test,

(iii) ACTH stimulation test,

KEY BOX 21.4

ADRENAL GLAND

Adrenal cortex

Synthesizes and secretes

- Glucocorticoids
- Aldosterone
- Androgen
- Estrogen (very small amount)

Adrenal medulla

Synthesizes and secretes

- Catecholamines
- Nor adrenaline
- Adrenaline
- Dopamine

(iv) Contrast enhanced CT of adrenal.

Treatment

- Adrenalectomy should be initial treatment in all patients of cushing syndrome due to adrenal adenoma or carcinoma.
- Hypophysectomy is advised, if ACTH hypersecretion from pituitary is the cause.

NOTE: *Adrenal is only gland in body, which is fully developed at birth. Weight of each gland is about 5 grams.*

2. Primary hyperaldosteronism (Conn's syndrome)

- In it stimulus (cause) for increased aldosterone secretion is in adrenal gland ***it self.***
- Most common cause is adrenal adenoma.
- Hypertension with spontaneous hypokalemia are important.
- Edema is characteristically absent *(MANY PGME)*
- High aldosterone and low renin level in the blood suggest primary hyperaldosteronism.

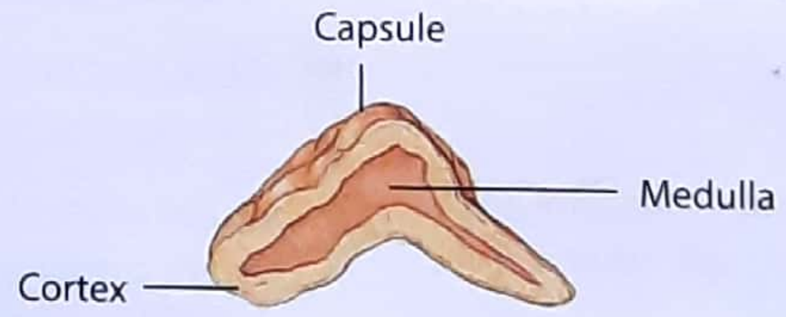

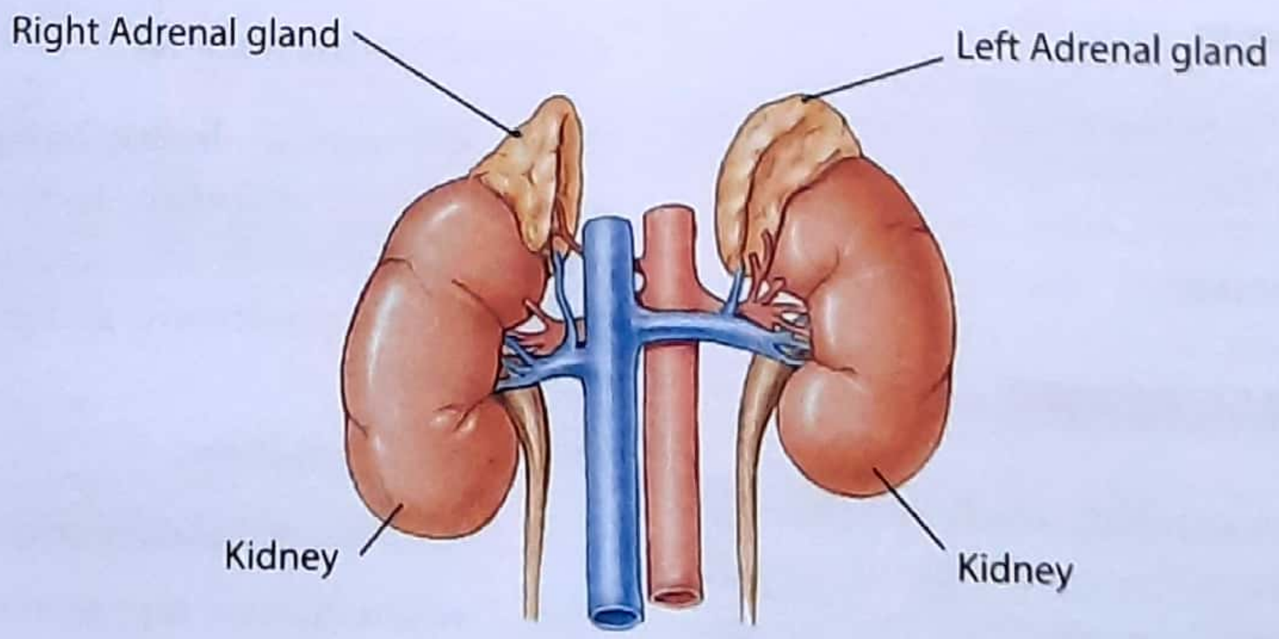

Figure 21.4: The Adrenal gland

- Treatment is surgical excision of adenoma.

3. Secondary hyperaldosteronism

- It is a condition of increased aldosterone secretion due to a stimulus lying *out side the adrenal gland*. It occurs in response to activation of renin, angiotensin system. Renin level is high.

4. Adreno-genital syndrome

It is due to increased secretion of adrenal androgen (for details read Harrisons')

B. Diseases of Adrenal Medulla

Adrenal medulla secretes catecholamines -The major role of which is metabolic. Adrenal medulla is composed of:

(i) *Chromaffin tissue* -They act as storage for catecholamines.

(ii) *Sympathetic neurons* : Please see key box 21.5.

Pheochromocytoma

- It is also called as chromaffin tumour, as it arises from chromaffin cells.
- Most common site of pheochromocytoma is adrenal medulla.
- Most common extra adrenal site is organ of zucker Kandl at the aortic bifurcation.
- There is **so called 10% rule:** *(MANY PGME)*
  - 10% of the tumours are bilateral
  - 10% of the tumours are multiple
  - 10% of the tumours are extra adrenal
  - 10% of the tumours are malignant
  - 10% of the tumour are familial (associated with MEN-II)
  - 10% of tumours occurs in children.
- It should be noted that malignancy is more common in extra adrenal tumours. *(IMP. POINT)*

Clinical feature

- Paroxysmal (on/off) hypertension (due to increased catecholamine) is the classical presentation, but in up to 3-0% there may be sustained hypertension.
- ***Headache is most common symptom, followed*** by sweating and palpitation. *(PGME)*
- Paroxysm are characterized by headache, anxiety, pallor, sweating and usually tachycardia.
- If noradrenaline is major catecholamine, secreted then bradycardia may be present.
- Arrythmia, chest pain and acute MI can occurs.
- Pulmonary edema, hypertensive encephalopathy and cerebrovascular accident can occur.

Diagnosis

- The diagnosis is confirmed by demonstrating increased excretion rate of urinary adrenaline and noradrenaline or their metabolite (metanephrine, nor-metanephrine or VMA).
- CT scan is an excellent technique for localizing pheochromocytomas in adrenal.
- Nuclear imaging with ^{131}I-MIBG is valuable in diagnosing pheochromocytoma. (MIBG = Meta lodo Benzyl Guanidine).

Treatment

- Preoperative preparation aims to fit patients for surgery that is by controlling hypertension by giving β blocker only after blocking α receptors.
- Plenty of fluid to control hypovolemia.
- Phenoxy benzamine is used to control hypertension.
- Propranolol is given to control tachycardia.
- **Surgical excision** is treatment of choice for both benign and malignant tumours.
- During surgical procedure least manipulation is done and adrenal vein is ligated at first step.

KEY BOX 21.5

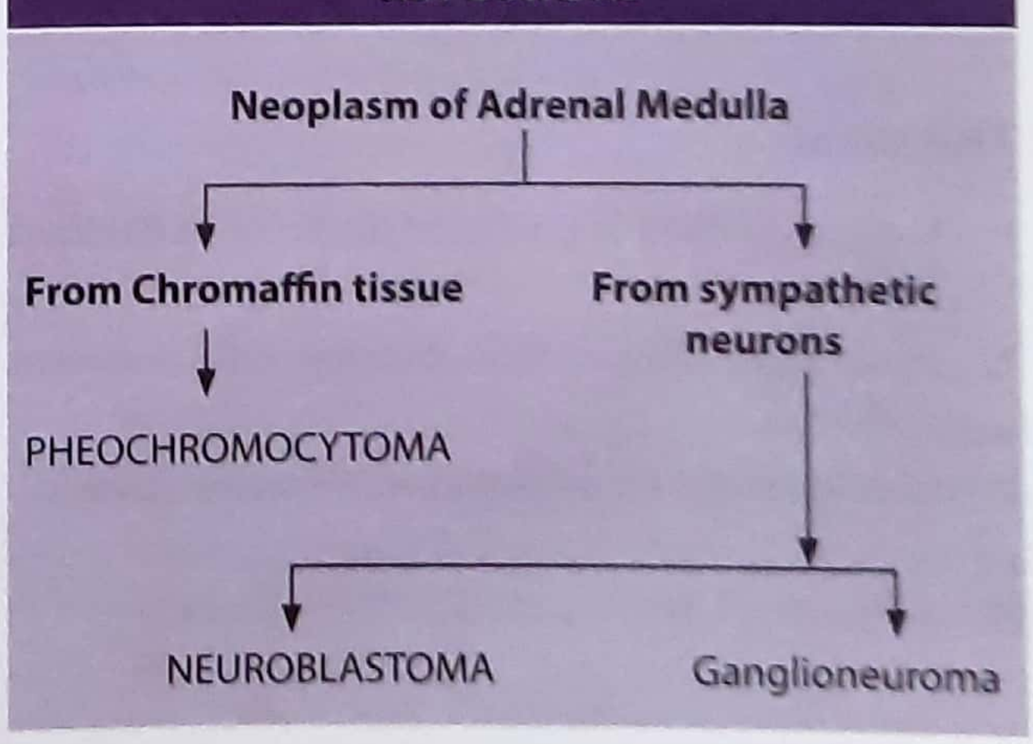

- Now a days procedure of choice is **laparoscopic adrenalectomy**. (NEET 20) After it, patient may present with adrenal crisis (hypotension, lethargic).

Neuroblastoma

- It is highly malignant tumour of neural crest origin, **arising from sympathetic chain.**
- Most common site is adrenal medulla.
- It is the *most common solid abdominal tumour in infancy*. (MANY PGME)

Clinical feature

- Most common presentation is asymptomatic, *irregular,* firm, abdominal lump (note: wilm's tumour is smooth)
- Usually, the tumour attains massive size, which spread directly to adjacent structures.
- Venous spread to the bone and liver (particularly) is very important. Paraaortic nodes may be involve.
- The abdominal mass may cross the midline, (note: wilm's tumour; the most common D/D of neuroblasstoma does not cross mid line).
- OTHER FEATURES- Failure to thrive, weight loss, abdominal pain, fever, anemia, hypertension flushing and sweating

Diagnosis

- Most accurate method of biochemical diagnosis is by estimation of all catecholamine and their metabolite in 24 hours urine collection.
- *VMA and HVA are important metabolite of cathecholamine found in urine* (MANY PGME)
- X-ray show fine *stipple calcification* (AIIMS 2000).
- CT scan is helpful in staging the disease.

Treatment

1. Surgical excision is treatment of choice in localized disease.
2. In advanced disease, chemotherapy is the treatment of choice.
3. Radiotherapy - for palliation of metastasis disease.

****

MEN SYNDROME

Three type of MEN syndromes are recognized.

Multiple Endocrine Neoplasia (MEN) Syndromes

MEN1 (11q13)

Parathyroid adenoma (90%)

Enteropancreatic tumor (30-70%)

- Gastrinoma (>50%)
- Insulinoma (10-30%)
- Non-functioning & PPoma (20-55%)
- Glucagonoma (<3%)
- VIPoma (<1%)

Pituitary adenoma (15-50%)

- Prolactinoma (60%)
- Somatotrophinoma (25%)
- Corticotrophinoma (<5%)
- Non-functioning (<5%)

Associated Tumors

- Adrenal cortical tumor (20-70%)
- Pheochromocytoma (<1%)
- Bronchopulmonary NET (2%)
- Thymic NET (2%)
- Gastric NET (10%)
- Lipomas (>33%)
- Angiofibromas (85%)
- Collagenomas (70%)
- Meningiomas (8%)

MEN2 (10 cen-10q11.2)

MEN2A

- MTC (90%)
- Pheochromocytoma (>50%)
- Parathyroid adenoma (10–25%)

MEN2B (also known as **MEN3**)

- MTC (100%)
- MTC (>90%)

Pheochromocytoma (>50%)
Associated abnormalities (40–50%)

- Mucosal neuromas
- Marfanoid habitus
- Medullated corneal nerve fibers
- Megacolon

MEN4 (12p13)

- Parathyroid adenoma
- Pituitary adenoma
- Reproduction organ tumors (e.g. testicular cancer, neuroendocrine cervical carcinoma)
- ?Adrenal + renal tumors

****

Adrenal Incidentaloma *(MAHE 07, 07; UP 08)*

- Adrenal lesions discovered during imaging performed for unrelated reasons.
- Incidence on CT scan — 0.4 to 4.4%

Differential Diagnosis:

(a) Non-functioning Lesions

Benign	Malignant
• Cortical adenoma (MC –36-94%)	• Metastasis
• Myelolipoma	• Adrenocortical Cancer
• Cyst	
• Ganglioneuroma	
• Hemorrhage	

(b) Functioning Lesion

Benign	Malignant
• Aldosteronoma	• Adrenocortical Cancer
• Cortisol producing adenoma	• Malignant pheochromocytroma
• Sex Steroid producing adenoma	
• Pheochormocytoma	

Investigations

Aim

To identify functioning tumors and tumors with increased risk for malignancy.

Tests for Function:

1. Low dose (1 mg) Dexamethasone Suppression test 24 hour urine Cortisol, 17-ketosterids
2. 24 hour urine for catecholamines, metanephrines, VMA or plasma metanephrine.
3. In hypertensive patients S. electrolytes, plasma aldosterone, plasma renin.

Tests for malignant potential

1. CT Scan: Features of malignancy are Hyperattenuating lesion, irregular border, local invasion or lymphadenopathy
2. MRI Scan

Treatment

Adrenalectomy is indicated in *(MAHE 07, 08; UP 08)*

1. Functioning lesions
2. Solitary metastatic lesion (unilateral)
3. Lesions with high risk of malignancy
   (a) lesions > 5 cm
   (b) lesions 3-5 cm in young patients, with suspicions imaging features, minimal comorbidity.

Nonfunctioning lesions < 3cm — Followd with repeat CT/MRI every 6 months. Please see key box 21.6 next page.

****

KEY BOX 21.6

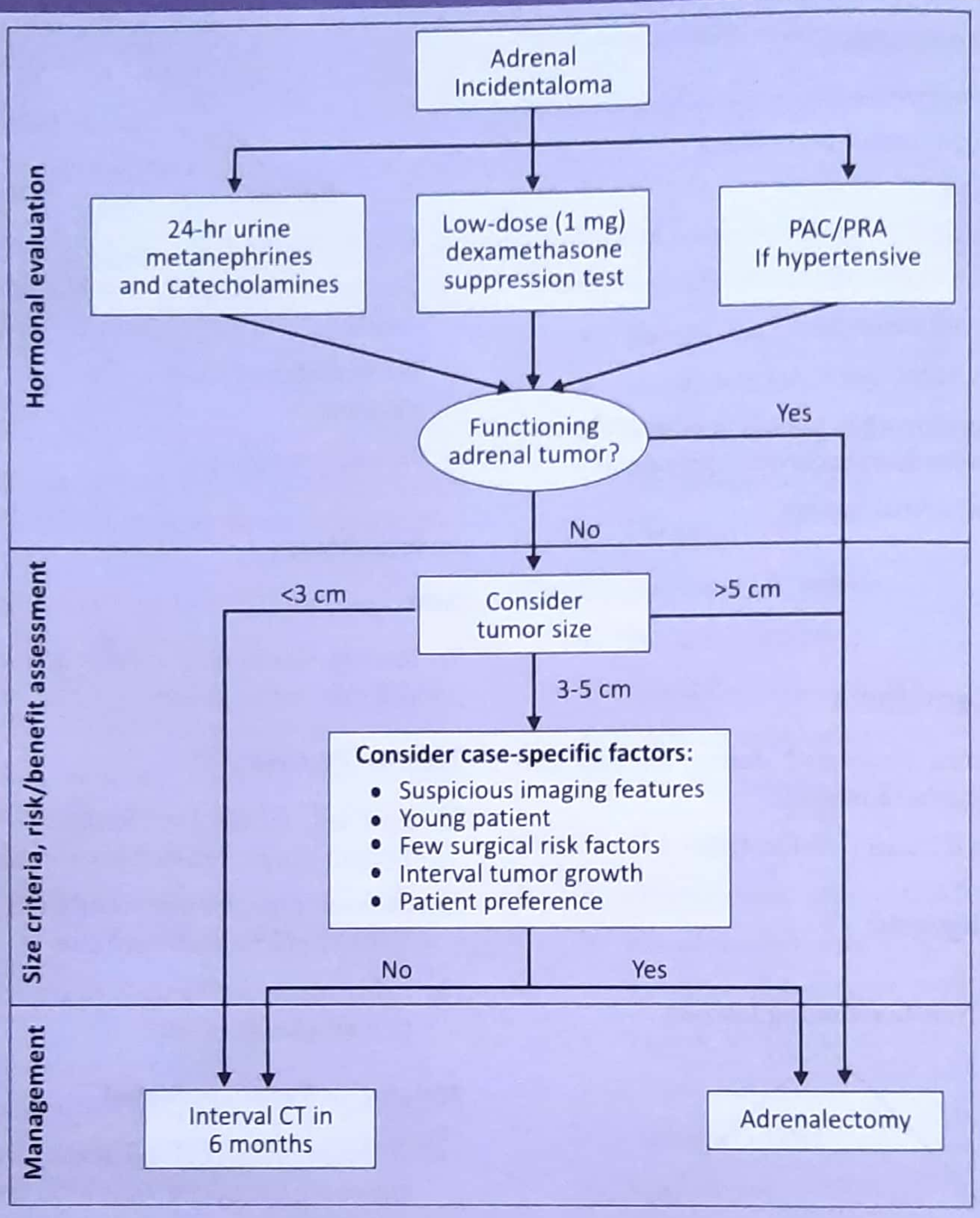

Algorithm for the management of an adrenal incidentaloma. Adrenalectomy is recommended for all patients with functional tumors. For nonfunctioning tumors, the risk for malignancy is assessed according to size. Tumors larger than 5 cm on computed tomography carry a more than 25% risk for malignancy and need to be removed. Those smaller than 3 cm can be safely observed. Case-specific factors must be considered for intermediate-sized tumors. CT, Computed tomography; PAC, Plasma aldosterone concentration, in ng/dL; PRA. Plasma renin activity, in ng/(ml • hg)

22 Chest Wall, Pleura and Lungs

Contents

- Disease of chest wall
  - Pectus excavatum
  - Pectus carinatum
  - Tietze's disease
  - Cold abscess of chest wall
  - Empyema Necessitans
- Disease of pleura and lung
  - Pneumothorax
  - Hemothorax
  - Empyema thoracis
  - Lung abscess
  - Lung tumors
- Chest trauma
  - Rib fracture
  - Stove in chest
  - Flial chest
  - Traumatic pneumathorax
  - Traumatic hemothorax
  - Surgical emphysema

DISEASES OF THE CHEST WALL

Pectus Excavatum (Funnel Chest)

This is a congenital deformity, where in there occurs depression of the body of the sternum, and the xiphoid process, associated with inward curving of the costal cartilage and adjacent part of ribs. The patient usually does not have any symptom except deformity and in extreme cases, decreased lung capacity.

Pectus Carinatum (Pigeon Chest)

This is also a congenital deformity; which may occasionally be associated with congenital heart disease. This deformity is believed to result from over growth of costal cartilage, resulting in unusually prominent and pushed forward sternum.

Tietze's Disease

The condition is characterized by *painful swelling at 2nd costochondfal joint.* There is no radiological abnormality. Anti-inflammatory drugs may be helpful.

Cold Abscess of The Chest Wall

Cold abscess of the chest wall mainly originates from the tuberculous lymphadenitis of the lymph nodes of the neck or the internal mammary group and rarely from Pott's spine. It should be treated with aspiration and anti-tuberculous treatment (ATT).

Figure 22.1: The lung

Empyema Necessitans

When pus, in a patient of empyema burrows to the chest wall and becomes superficial and presents as a visible subcutaneous swelling; the condition is known as empyema necessitans (UPSC02). The swelling is usually present between 3-6 intercostal space. It is a *reducible swelling*, and as it is connected to pleural space, impulse on coughing is present. The condition is treated by intercostal drainage (ICD).

****

DISEASES OF THE PLEURA

Before going into details, Lets see what is pleura and pleural cavity (pleural space).

The pleura is thin membrane of fibrous tissue, surfaced by single layer of flat mesothelial cells. It clothes (like a shut) each lung and lines the thoracic cavity. Each pleura has **two parts** (Please see figure 22.2)

1. A Parietal layer, which lines the thoracic wall, covers the thoracic surface of diaphragm and lateral aspect of the mediastinum
2. A Visceral layer completely covers the outer surfaces of the lungs. The parietal and visceral layers of pleura are separated from one another by a slit like space, known as pleural cavity (pleural space). This cavity normally contains 10-15 ml of pleural fluid, which covers the surfaces of pleura as a thin film, and permits the two layers to move on each other with the minimum of friction.

Clinical Conditions

Air in pleural cavity	Pneumothorax
Fluid in pleural cavity	Hydrothorax
Blood in pleural cavity	Hemothorax
Pus in pleural cavity	Pyothorax
Organized pus in pleural cavity	Empyema
Lymph in pleural cavity	Chylothorax

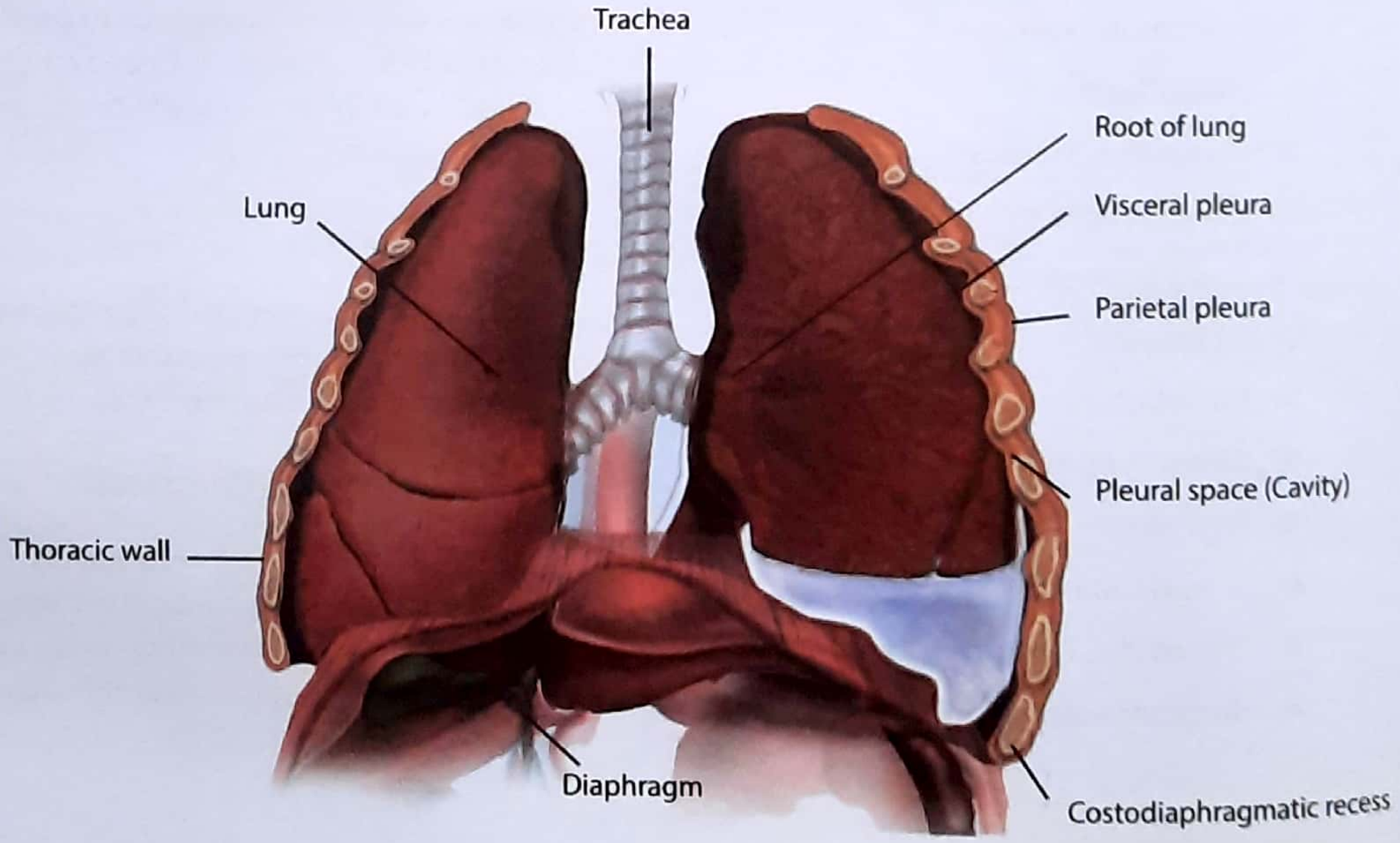

Figure 22.2: Note the pleural cavity (space)

Now each condition will be discussed on by one.

Pneumothorax

Accumulation of air in the pleural cavity is known as pneumothorax. If the accumulation of air is large enough, it will push lung parenchyma, which may collapse and become non-functional.

Causes

I. Primary spontaneous (Idiopathic)

When no cause of pneumothorax can be established.

II. Secondary spontaneous

This occurs due to:

- Rupture of emphysematous bullae
- Suppurative disease of lung rupturing into pleura; eg; Pneumonia, lung abscess, bronchiectasis.
- Rupture of congenital bullae
- Diffuse fibrosing pulmonary disease eg; sarcoidosis, interstitial fibrosis, Pneumoconiosis.

III. Traumatic

Penetrating trauma: Stab wound, fractured ribs

Blunt trauma chest: Road traffic accident, fall from height.

IV. latrogenic

- Procedures such as placement of a central intravenous line.
- Thoracocentesis.
- Bronchoscopy.
- Tracheal intubation.
- Positive pressure mechanical ventilation, especially with high peak pressure.

Types of pneumothorax

1. **Closed Pneumothorax**: Air reaches the pleural cavity through a small rent in the lung which subsequently heals rapidly. This condition is also known as simple pneumothorax and usually is not a serious condition.
2. **Open Pneumothorax**: Air enters the pleural cavity through a penetrating (stab) wound and passes in and out of the chest wall through each breath. The opening remains patent and pressure in the pleural cavity is equal to that of the atmosphere. Please see figure 22.3(A).
3. **Tension Pneumothorax**: In this, the pleuropulmonary communication acts as a ***check valve,*** which allows the air to enter into the pleural cavity during each act of inspiration *but prevents* escape of air during expiration. Very large amount of air may be trapped in the pleural cavity and mediastinal shift is progressive and obvious, resulting in severe dyspnea, decreased venous return and acidosis. Please see figure 22.3B & key box 22.0.

Clinical feature

- Sudden onset of unilateral chest pain and dyspnea is the common presentation. In an otherwise healthy adult, the dyspnea may soon regress, however rapidly worsening dyspnea may indicate developing tension pneumothorax.
- Other features are anxiety, restlessness, hypotension, tachycardia, cold and clammy skin and shock.
- Signs of pneumothorax are hyperresonant percussion note, restricted chest movement, diminished air entry to affected side. In tension pneumothorax, the trachea and apex beat my shift to opposite side.

KEY BOX 22.0

Mechanism of tension Pneumothorax

↓

Large amount of air is trapped in the pleural cavity due to development of check value

↓

Collapse of affected lung due to increasing pressure in pleural space resulting in severe dyspnea

↓

Displacement of mediastinum and trachea to opposite side.

↓

Kinking or SVC/IVC leading to impaired venous return to heart

↓

Hypotension, Hypoxia and Hypercarbia

↓

Acidosis

KEY BOX 22.1		
Clinical Sign	**Cardiac Temponade**	**Tension Pneumothorax**
BP	Low	Low
Heart sounds	Muffled	Normal
Breath sounds	Normal	Absent
Neck vein	Distended	Flat
Respiration	± Normal	Tachypnea
Treatment	Needle Pericardiocentesis	chest tube/ Needles Thoracentesis

Investigation

A chest X-ray is the chief investigation. (PGME)

Treatment

It is almost same for all types of pneumothorax.

1. A small pneumothorax should be observed. It may resolve on its own.
2. **In distressing form, insertion of a large bore needle (cannula) into the chest, via the second intercostal space in midclavicular line to relieve tension.** (NEET) The needle is connected to under water seal. In children, In adults, 5th intercostal space, mid axial line
3. **Intercostal tube drainage:** *An intercostal tube water seal drainage in **second** **intercostal space** in midclavicular line in cases; when pneumothorax exceed 30% of chest cavity.* (AIIMS JUNE 97, AIIMS 89, AI 92).
4. In cases with recurrent spontaneous pneumothorax pleurectomy and pleurodesis can be helpful.

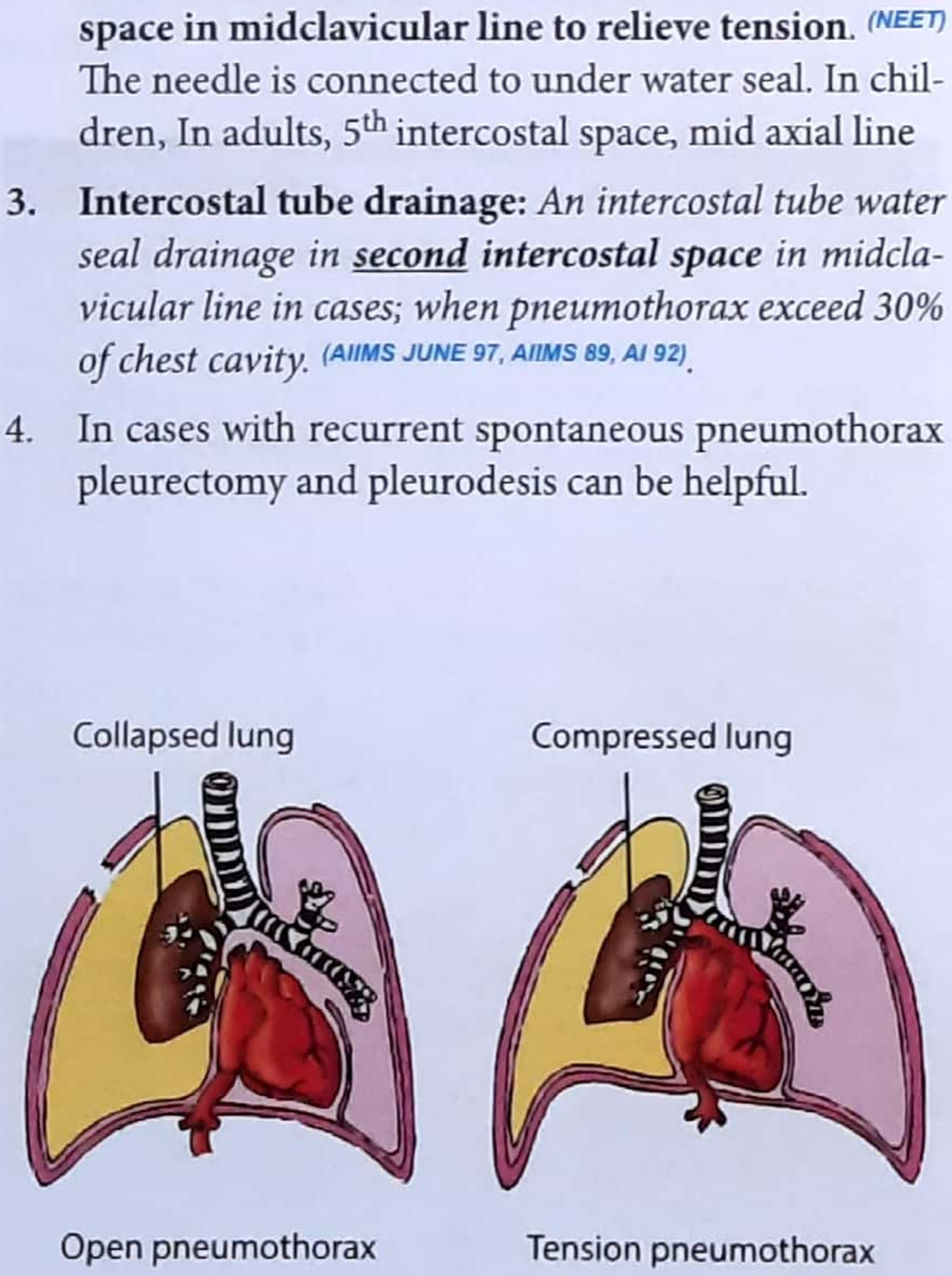

Figure 22.3: Types of pneumothorax

HEMOTHORAX

Hemothorax is a condition; in which blood is present in the pleural cavity.

- This condition often results from lung laceration or tear of intercostal or internal mammary artery due to blunt or penetrating trauma to chest.
- The diagnosis is made by X-ray of the chest. *[Also see traumatic hemothorax later in this chapter].*

Treatment

- All hemothorax that is visible on a chest X-ray require placement of a large caliber chest tube (ICD tube).
- **ICD tube is inserted** (NEET) in the sixth or seventh intercostal space at mid axillary line*.

[Mid axillary line: line drawn vertically down ward from mid axilla (arm pit)].*

Major Hemothorax (PGI JUNE 99)

- If the initial blood loss is *more than 1500 ml* (>30% of blood volume) or if tube drainage is more than 200-250 ml/hour for consecutive 3 hours, it will require exploratory thoracotomy (opening of thorax) and identifying bleeding vessels and it's ligation.

Indication of open thoracotomy

1. Initial drainage of blood > 1500 ml
2. Continuous bleeding of > 200 ml/hr for ≥ 3 hrs.
3. Rupture of bronchus aorta, esophagus or diaphragm
4. Cardiac Temponade. (NEET)

EMPYEMA THORACIS

Empyema thoracis means collection of ***organized pus*** in the pleural cavity.

Introduction

Pleural cavity separates thoracic wall from lungs. Normally it contains a thin layer of fluid separating parietal from visceral membrane. This fluid is an ultrafiltrate of plasma. Normal pleural fluid volume is 0.10-2ml/kg or less than 15 ml in a 70 kg individual. It is formed and reabsorbed by perietal pleura with very little contribution from visceral pleura.

KEY BOX 22.1.1

Pathogenesis of empyema

Contamination from a source contiguous to the pleural space (50%-60%)

- Lung
- Mediastinum
- Deep cervical area
- Chest wall and spine
- Subphrenic area

Direct inoculation of the pleural space (30%-40%)

- Minor thoracic interventions
- Postoperative infections
- Penetrating chest injuries

Hematogenous infection of the pleural space from a distant site (<1%)

Definition

A *parapneumonic* effusion is any pleural effusion associated with suppurative parenchymal lung disease. *Simple parapneumonic effusions* are uninfected, free flowing fluid collections. *Complicated parapneumonic effusions* are early infected fluid collections, prone to develop loculations by fibrinous septation. **Thoracic empyema is a collection of frank pus with in the pleural space (pleural cavity).**

The diagnosis can only be confirmed by examination of the empyema fluid. If this is frankly purulent then no douot remains, but if it is not obviously turbid, then diagnostic confirmation will require the microscopic finding of a cell count containing a predominance of polymorphonuclear leukocytes. The finding of organisms on gram's stain' or on culture is also confirmatory, although these may have been suppressed by antibiotics, and are not always detectable. Empyema may be described as acute or chronic but the division between the two is indistinct and arbitrary, the later term usually being reserved, for those cases in which organization has reached an advanced stage with formation of a pleural ring.

Etiology

1. **From outside**
   - (i) Penetrating chest injury
   - (ii) Secondarily infected hemothorax, due to repeated aspiration,
   - (iii) Following thoracotomy
2. **From the underlying lung**
   - (i) Pneumonia *(M/C cause of Empyema -70%)*
   - (ii) Tuberculosis
   - (iii) Lung abscess
   - (iv) Bronchiectasis
3. **Esophageal rupture**
4. **From source below the diaphragm**
   - Sub-phrenic abscess
   - Liver abscess

Pathophysiology & classification

American thoracic society classified pleural cavity infections into three stages based on the natural history of the disease:-

1. Exudative stage,
2. Fibrinopurulent stage, and
3. Organizing stage.

These stages are not sharply defined, but represent a continuous spectrum.

Stage 1 or the exudative stage

The pleural fluid is a thin exudate (also called simple parapneumonic effusion), which usually resolves with antibiotic therapy.

Stage 2 or the fibrinopurulent stage

This is characterized by infection of the pleural fluid. During this stage, the fluid becomes turbid and may contain bacteria and cellular debris. This is also termed a complicated parapneumonic effusion. Fibrin is deposited on the pleural surfaces and as the stage progresses, fibrinopurulent membranes partition the pleural surfaces compromising lung expansion. If not drained, increasing amounts of bacteria appear and the fluid becomes frankly purulent, giving rise to a true empyema.

Stage 3 or the chronic or organizing stage

In this stage fibroblasts migrate into the pleural cavity and produce an inelastic membrane called the pleural peel cortex, a ring entrapping the lung and rendering it essentially function less. At this stage, simple tube thoracostomy is inefficient and a more formal evaluation of the pleural space infection becomes necessary. This stage may begin in two weeks but usually takes 4-6 weeks to develop.

Clinical presentation

The **clinical presentation** can range from absence of symptoms, to a severe febrile illness with toxemia and shock. It is difficult to distinguish patients with infected pleural effusions from those with sterile parapneumonic effusions on the basis of history and physical examination alone. Clinical manifestations include fever, dyspnea, chest pain, and cough with mucopurulent sputum. Occasionally, an empyema or a complicated effusion is manifested by failure of response or worsening of the clinical condition, despite adequate antibiotic therapy for pneumonia.

Physical examination often reveals decreased breath sounds, dull percussion and restricted respiratory movement with chronicity. Some times an empyema may erode the chest wall and present as a spontaneously draining subcutaneous abscess, known as **empyema necessitans.** Chronic empyema may cause chondritis and osteomyelitis of the ribs, broneho-pleural fistula, pericarditis, mediastinal and vertebral abscesses, disseminated infection and failure. Anemia and leucocytosis may be present but are nonspecific.

Microbiology

- In the preantibiotic era, *Streptoccus pneumoniae* accounted for 50-70% of cases but with the introduction of antibiotics, anaerobic organisms are now the most common bacteria isolated form infected pleural effusions, being identified in up to 75% of cases, either alone (35%) or in combination with aerobic organisms (40%). Aerobes alone are recovered in only 24% of cases.
- *Staphylococcus aureus* is also a common cause of empyema in otherwise healthy adults, children and in patient who have had chest trauma or prior surgery. Empyemas in immunocompromised patients may be caused by *S. aureus*; aerobic negative bacilli, fungi and mycobacteria.
- Gram negative rods are found most commonly in empyemas complicating trauma during gastro-esophageal and other thoracic surgery.
- *Staphylococcus aureus* is a common infecting organism in childhood empyema particularly in infancy, accounting for 92% of empyemas in children under the age of two years. Gram negative organisms other than *Hemophilus influenzae* are relatively unusual causes of empyema in childhood.

Diagnosis

- Where as the history and physical finding may be suggestive, the diagnosis can be made with confidence with chest X-ray and thoracocentesis.

(i) Pleural fluid analysis (see box 22.3)

If the patient has a transudative effusion, no further laboratory tests on the pleural fluid are indicated. If the patient has an exudative pleural effusion, the remaining pleural fluid is sent for WBC and differential cytologic examination, gram's stain and cultures for aerobic and anaerobic bacteria, and mycobacteria and fungi if clinically indicated.

- The aspiration of frank pus confirms the presence of empyema. In this case pus should be sent for gram staining and culture sensitivity to guide initial therapy.

(ii) Imaging

(a) Plain X-ray chest

The PA and lateral view is the best initial diagnostic modality.

KEY BOX 22.2

Summary of Empyema

Class	Diagnostic criteria	Treatment
Insignificant effusion	Small <10mm thick on a lateral decubitus film	Antibiotics, Tboracoceatesis-usually unnecessary
Parapaeumonic effusion	>10mm thick on lateral decubitus film	Antibiotics, thoracocentesis
Simple effusion	PH>7.3 and/or lactate dehydrogenase value 500IU; glucose levet>60mg/dL; negative Gram stain and culture	Antibiotics, thoracocentesis

KEY BOX 22.3		
PLEURAL FLUID ANALYSIS		
Criteria	**Transudate**	**Exudate**
• Colour	Clear or light yellow	Cloudy or purulent
• Cells	<250mm3	>250 m3
• Proteins	<3gm/dL	>3gm/dL
• Pleural fluid/Serum protein ratio	<0.5	>0.5
• Glucose ratio	>1.0	<1.0
• LDH	Low (<200 IU/L) Normal (60-150 IU/L)	High >200 IU/L
• PH	>7.2	<7.2
• Specific gravity	<1.016	>1.016

(b) Computed tomography

CT is helpful in:-

1. Differentiating pleural fluid from peripheral parenchymal infiltrates or pleural thickening
2. Evaluating the parenchymal disease
3. Determining the presence of loculations
4. Characterizing the pleural surfaces and
5. Guiding and assessing therapy.

(c) Ultrasonography

Provides guidance for thoracentesis and can distinguish solid from liquid pleural pathology.

Management

There are two basic principles of successful management of empyema.

1. Control of infection with *adequate antibiotics.*
2. *Drainage of pus.* (Pleural drainage) Now lets take them one by one:-

1. Antibiotics

Early appropriate antimicrobial therapy for pneumonia minimizes development of parapneumonic effusion and aborts the progression of uncomplicated effusion to complicated effusion or empyema.

Antibiotics suitable for single agent therapy include beta-lactam antibiotics with a beta lactamase inhibitor eg; Amo-xicillin/clavulanate, or ampicillin/sulbactum, quinolones and imipenem. These agents cover the common pathogens associated with empyema, including anaerobic bacteria. Cephalosporins may require addition of metronidazole or clindamycin if anaerobic pathogens are suspected. Aminoglycosides are less capable of entering the empyema collection and are inactivated by the acidic pH of the pleural fluid.

- The duration of antibiotic therapy is dictated by the response of the pneumonia and the adequacy of pleural drainage. Patient who requires prolonged drainage may require several weeks of antibiotics. Patient who respond favourably can be treated for 10-14 day with antibiotics for the underlying pneumonia.
- In case of tuberculous empyema a full course of ATT (6 months) is given.

2. Pleural Drainage

Indications

(i) Persistent fever and leucocytosis after an initial course of antibiotics.

(ii) Anaerobic pleuropulmonary infection,

(iii) Virulent organisms such as *Streptococcus pyogenes, Staphylococcus aureus, Klebsiella pneumonae*

(iv) Air fluid level in pleural space on chest x-ray,

(v) Large parapneumonic effusion occupying more than 40% of the hemithorax.

Drainage of the pleural space can be done by following procedures:

(A) Minimal Invasive Procedure

(i) Thoracocentesis

- This is aspiration of pleural fluid collection by a wide bore needle.
- Up to 25% of patients with culture positive parapneunomonic effusions in the exudative stage may respond to complete removal of pleural fluid by thoracocentesis. Patients with pneumonia caused by anaerobic bacteria or Staphylococcus aureus are less likely to respond, because of the early formation of loculations.

(ii) Image guided percutaneous catheter drainage

By using CT and USG it becomes easy to place one or more drainage catheters into specific loculations. This is the single most significant advantage of guided over non guided therapy. Image guided thoracostomy may fail if the catheter is repeatedly occluded by fibrinous debris.

(iii) Chest tube drainage (Inter costal drainage)

- Indications for the tube thoracostomy include complicated parapneumonic effusion and empyema, as indicated by gross pus in the pleural space. If the CT of the chest demonstrates a multiloculated effusion, tube thoracotomy is inadequate and the pleural space infection should be approached by either VATS or open thoracotomy. (see later in this chapter)
- Chest tube drainage needs to be reserved for patients in the exudative or early fibrinopurulent stage of empyema formation. These patients have relatively nonviscous fluid and minimal loculations allowing adequate drainage.
- Patients who fail to respond to chest tube drainage should be evaluated for clogged tubes, presence of loculations, thick pleural surfaces, broncho pleural fistulas (BPF) that impede lung expansion, incorrect tube placement or a kinked tube.
- The chest tubes are left in place until the pleural cavity is obliterated by expansion of the lung, pleural fluid is serous, and less than 20-50 ml per day for 3-5 days, infection is controlled & any BPF, if present has sealed.
- In patients with an established empyema, when there are no residual signs of infection and the lung is stuck to the chest wall, tubes are opened to the atmosphere, allowing greater patient mobility and slowly withdrawn from the pleural space over a period of several days or weeks to allow resolution of the infection and obliteration of any residual cavity.
- Complications include subcutaneous emphysema, chest wall hematoma, hemothorax, lung lacerations, chylothorax and injury to mediastinal structures, diaphragm or intraabdominal viscera.

Technique of Intercostal tube drainage (ICD)

(Often asked in final prof, surgery viva)

- The patient remains seated with arm and forearm flexed, so that right hand touching left shoulder and the left hand touching right shoulder.
- The ideal site for insertion of the tube is 6th or 7th intercostal space *(UPPGU, AIIMS 2000, AL 02)* in midaxillary line. Other favoured site is the 8th or 9th inter costal space between posterior axillary line, lateral to scapular line:
- Skin is infiltrated with local anesthetic down up to the pleural cavity.
- A small incision is made in the intercostal space for introduction of the trocar and cannula. The incision in made **just above the lower rib** *to avoid damage of intercostal vessel because intercostal vessels and nerves lie immediately under each rib.*
- After making an incision trochar and cannula is pushed into the pleural cavity. The trochar is then withdrawn and a catheter is quickly introduced through cannula. Once being sure that the catheter is in pleural cavity the cannula is slowly withdrawn.
- If pus starts coming through the catheter, means the catheter is placed rightly in a pleural space.
- The catheter is fixed to the skin by a strong silk suture, so that it does not move in or out with body movement, and then adhesive dressing is done.
- The catheter is then connected to a water seal drain. Because of water seal drainage, no air can be drawn back into pleural space and there is no danger of the fluid present in the bottle, being drawn back in pleural cavity as the bottle is kept below the chest level. Please see figure 22.4.

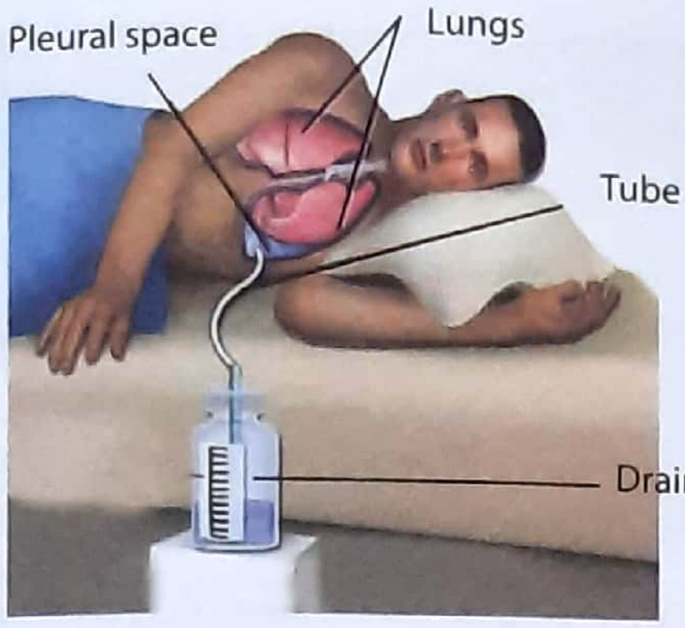

Figure 22.4: Intercostal drainage (ICD)

Complications of ICD

(i) Sub cutaneous emphysema
(ii) Chest wall hematoma
(iii) Hemothorax
(iv) Lung parenchyma injury
(v) Injury to mediastinal structures, diaphragm and intra abdominal viscera

When should tube taken out?

- When there is evidence of chest expansion on X-ray chest.
- Draining pleural fluid turn serous from purulent.
- Column movement is less than 1cm.
- Pleural fluid drainage is less than 25-50 ml/day for 3-5 consecutive days.
- Infection has been controlled with proper antibiotics.

(iv) Intrapleural fibrinolytic agents

The instillation of fibrinolytic agents into the pleural space is intended to decrease the viscosity of the pleural fluid. It also practically debride, the restrictive pleural fibrin sheets that prevent re-expansion of the lung. Fibrinolytic therapy benefits patients with parapneumonic effusions in the exudative or early fibrinopurulent stages, that have failed chest tube drainage. Presence of multiple loculations decreases response, because the agents can not distribute throughout the pleural space.

Streptokinase (250,000 U), Urokinase (250,000 U) or tissue plasminogen activator (4-6 mg) are administered as a solution in 50-100ml of sterile normal saline through chest tubes or catheters. The tubes are clamped and patients are encouraged to change their positions at regular intervals to enhance distribution of the instilled agent. After four to six hours, the chest tubes are undamped and suction restored. This procedure can be repeated daily until clinical improvement is achieved, radiographic resolution is obtained or significant pleural fluid drainage ceases. Success rates for fibrinolytic agents vary between 70% and 90%.

RECAP : till now we were discussing minimally invasive drainage procedure; in which invasion to human body is minimal; now we will discuss open surgical drainage procedure.

(B) Surgical Drainage Procedures

Patients with late fibrinopurulent organized chronic empyema requires surgical intervention to promote drainage because there is considerable fibrosis, constricting the lung parenchyma.

(i) Video assisted thoracic surgery (VATS)

This is particularly useful during the fibrinopurulent stage of empyema. Early fibrin membranes or thin peels can usually be removed from the visceral pleura to allow lung re expansion. Before closure, chest tubes are placed in pleural cavity for postoperative drainage of the pleural space. In organized stage, VATS is often unsuccessful, due to the thicker and more adherent pleural peel entrapping the lung, and an open procedure becomes mandatory.

(ii) Open surgical drainage

It may be an appropriate treatment for patients who are judge to be too ill to undergo the more major procedures; like thoracotomy and decortication.

- It involves resection of the lowest rib above and below, from where pus has to be drained.
- An incision large enough to allow adequate drainage, is made on pleural cavity and a wide bore rubber tube surrounded by gauze is inserted in the wound. This results in gradual obliteration of the empyema space which allows ultimate removal of the tube and complete cure.

(iii) Thoracotomy

This is opening of the thorax and opening the pleural space. Thoracotomy is usually performed during the fibrinopurulent stage and the initial phase or the organizing stage. Blunt finger dissection usually suffices to disrupt the fibrinous septations, and allows access to all other areas of the pleural cavity.

(iv) Decortication

Indication for decortication are:-

(a) The presence of a fibrous peel or ring due to chronic empyema.

(b) In a chronic organized hemothorax, decortication is *begun by incising the fibrous membranes in forms of stripes down to the visceral pleura.* All fibrin material overlying the visceral pleura is removed to promote complete reexpansion of the collapsed lung. Drainage is achieved by placing two or more chest tubes to assure complete evacuation of pus and fibrinous exudates, thus decortication involves the excision of the thickened and fibrosed visceral and parietal pleura.

[Friends I have written bit more on this topic, because; empyema and pleural effusion is almost always asked in final prof examination, you will definitely get 1 Question on it either in theory paper or an a short case or in viva or operations (ICD). It is also an important topic for medicine paper and PGME examination].

****

LUNG ABSCESS

Lung abscess is a focus of infection within the lung associated with parenchymal necrosis, usually with cavitation.

Etiology and Pathogenesis

Causes of lung abscess are:-

(i) Primary necrotizing pneumonia (most common), aerobic *infection-Staph aureus, Streptococci, Klebsiella, Pseudomonas, M. tuberculosis* and *Atypical microbacteria.*

(ii) Aspiration pneumonia (gastric contents or infected saliva mixed infection).

(iii) Bronchial obstruction - Neoplasm, Foreign body.

(iv) Complication of systemic sepsis.

(v) Complication of chest trauma.

(vi) Direct extension from extraparenchymal infection:- empyema, mediastinal, hepatic & subphrenic abscesses.

(vii) Superimposed structural abnormalities e.g;- Bronchogenie cyst.

Aspiration has a well recognized association with altered state of consciousness, including alcoholic stupor, drug overdoses, head trauma, cardiopulmonary resuscitation and after general anesthesia. Because **most episodes of aspiration occur with the patient supine, the abscess is characteristically located in posterior segment of upper lobes and superior segment of both lower lobes.** (NEET) *The location more commonly found on right than left.* (MANY PGME)

- *Least common site for lung abscess is left upper lobe* (PGI JUNE 99)
- Staphylococcal lung abscess is more common in first year of life and has characteristic pathology, most frequently with pyopneumothorax and pneumatocele and clinically characterized by a remarkable tendency to resolve completely with antibiotic alone.
- Over half of the pneumonia seen in seriously ill hospitalized patient are gram -ve *(Klebsiella, Pseudomonas;* etc)'and a significant proportion of a .such patient develop lung abscesses.
- Systemic abscess can produce multiple bilateral foci of parenchymal infection that are radiologically discrete and are most frequently caused by *Staphylococcus* and other gram +ve organism.
- A cavitary necrotizing infection can also form abscess distal to an obstructing carcinoma or intrabronchial foreign body. The **most common causes** are
  - *Aspiration of oropharyngeal secretion* (M/C cause)
  - Secondary to a chronic URTI (sinusitis, dental abscess)
  - Following bronchial obstruction from a neoplasm.

Clinical presentation

The patient appears ill, and is likely to have fever, cough, pleuritic chest pain and recent onset of copious foul spu-

KEY BOX 22.4

Causes of lung abscess

I. Primary

A. Necrotizing pneumonia
   1. *Staphylococcus aureus, Klebsiella, Pseudomonas, Mycobacterium*
   2. *Bacteroides, Fusobacterium Actinomyces*
   3. *Entamoeba, Echinococcus*

B. Aspiration pneumonia
   1. Anesthesia
   2. Stroke
   3. Drugs or alcohol

C. Esophageal disease
   1. Achalasia, Zenker's diverticulum, gastroesophageal reflux

D. Immunodeficiency
   1. Cancer (and chemotherapy)
   2. Diabetes
   3. Organ transplantation
   4. Steroid therapy
   5. Malnutrition

II. Secondary

A. Bronchial obstruction
   1. Neoplasm
   2. Foreign body

B. Systemic sepsis
   1. Septic pulmonary emboli
   2. Seeding of pulmonary infarct

C. Complication of pulmonary trauma
   1. Infection of hematoma or contusion
   2. Contaminated foreign body or penetrating injury

D. Direct extension from extraparenchymal infection
   1. Pleural empyema
   2. Mediastinal, hepatic, subphrenic abscess

tum production. Hemoptysis and pyopneumothorax can occur. In contrast to pneumonia, dyspnea is not a prominent symptom.

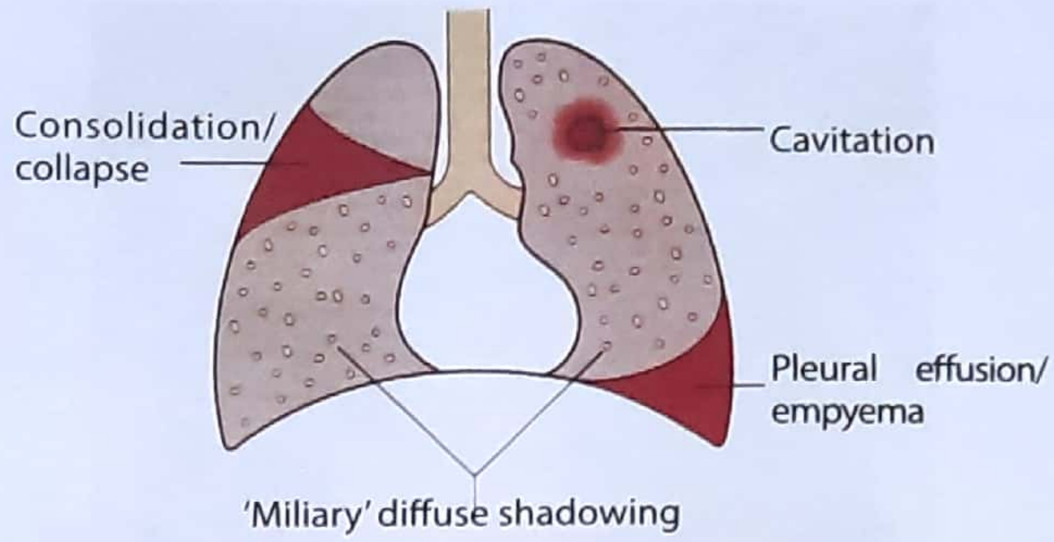

Figure 22.5: Chest X-ray: major manifestations and differential diagnosis of pulmonary TB. Less common manifestations include pneumothorax ARDS, cor pulmonale and loc~emphysema. .

Diagnosis

Diagnosis is confined with a combination of sputum culture, brochoscopy and radiology.

(i) Chest X-ray : A chest X-ray shows a solid opacity, which later cavitates in the middle. If it communicates with bronchus; there is fluid level at the bottom.

(ii) Bronchoscopy : May be performed for diagnosis to rule out foreign body, stenosis, carcinoma. Bronchoscopy also assist in drainage of the cavity either directly or by way of transbroncheal catheterization.

Indications for surgical drainage procedures for lung abscesses

1. Failure of medical therapy
2. Abscess under tension
3. Abscess increasing in size during appropriate treatment
4. Contralateral lung contamination
5. Abscess >4-6 cm in diameter
6. Necrotizing infection with multiple abscesses, hemoptysis, abscess rupture, or pyopneumothorax
7. Inability to exclude a cavitating carcinoma

Treatment

Primary treatment of acute abscess consist of appropriate antibiotics therapy and postural drainage. Most patient (90%) respond to medical management with rapid decrease in fluid, collapse-of abscess wall and complete healing occur in 3-4 months.

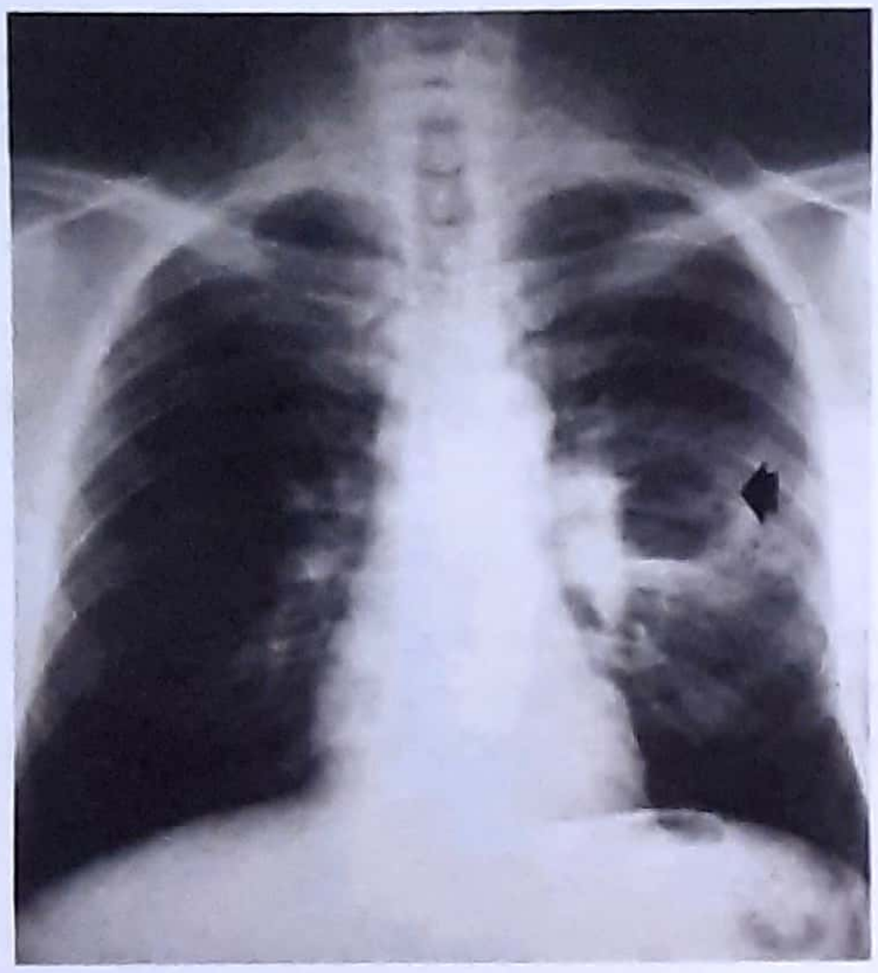

Figure 22.5.1 : Chest X-ray (lung abscess)

Surgical options are:

(i) Tube pneumonostomy (percutaneous catheter drainage that usually connected to water seal bottle) usually adequate.

(ii) Pneumonotomy - Is almost never used these days, patient who fail catheter drainage cannot tolerate resection.

(iii) Pulmonary resection - Is the most definite operative treatment. Indications are failure of simple approache, serious hemorrhage, suspicious of associated carcinoma and very large and centrally located abscesses.

Note : Intralobular sequestration of lung takes blood supply from descending abdominal aorta.

****

LUNG TUMORS

(1) Hamartoma

- Most common benign tumor of lung.
- More common in 40-60 yrs of males.
- Popcorn calcification is diagnostic.
- Treatment is by excision.

(2) Bronchial adenoma

- Slow growing, centrally located endometrial lesions.
- These incluse carcinoids (most common), adenocystic tumor.
- Presentation include recurrent hemoptysis (most common), chronic cough, lobar collapse, abscess.
- Treated by excision.

(3) Lung cancer

- Associated with maximum cancer related mortality in both male & female.

Risk factors - Smoking, pollution, environmental cause, exposures.

Types

(a) Small cell carcinoma

Also known as oat cell carcinoma

- Strongest association with smoking.
- More common in males.
- Poor prognosis.
- Maximum paraneoplastic syndrome.
- Highly chemosensitive.
- it is most common lung cancer to give rise to SVC syndrome.
- SVC syndrome presents with facial and cerebral edema, HTN, Breathlessness, CT shows - Thrombus in SVC

Management - Small cell - Chemotherapy
- No small cell - Radiotherapy
- Steroids

Histopathology - Azzopardi effect
- Salt & pepper chromatin

IHC marker - Chromogranin

(b) Non Small cell carcinoma

i. Squamous cell carcinoma

- Most lung cancer in India.
- Centrally placed, associated with smoking (most common in smokes)

- Releases PTHrP

↓

It causes hypercalcemia

- Most common lung cancer to give rise to pancoast tumor.

Horners syndrome (ptosis, miosis, anhidrosis, enophthalmos)
Histopathology - Keratin pearls
LHC - cytokeratin (+) p. 40

Pain along Ulnar nerve

ii. Adenocarcinoma

- More common in females.
- Most common lung cancer overall.
- Peripherally located - slow growing cancer.
- Metastasis - early to lymph node & distant site
- Marker -Napsin 4
- Mutations - ALK, RAS

iii. Bronchoalveolar Carcinoma

- Adenocarcinoma in situ. Lepidic pattern of growth (grows along broncho-alveolar lining)
  - Multifocal
  - Can involve other lung
  - Resectable

X-ray / CT - Ground glass appearance

Clinical feature

Most common - Cough, Hemoptysis, Wt. loss, Pleural effusion, SVC syndrome, Horner's syndrome.

Investigation - X-Ray (initial)
CECT (IOC)
PET - CT for staging

TNM Staging

Tx	Primary tumor can't be assessed
T0	No evidence of primary tumor
Tis	Carcinoma in situ
T1	<3 cm surronded by lung / visceral pleura
T1mi	Minimally invasive adenocarcinoma
T1a	≤ 1 cm
T1b	>1 to ≤ 2 cm
T1c	> 2 to ≤ 3 cm
T2	> 3 to ≤ 5 cm or involvement of main bronchus, regardless of distance from carina or invasion of visceral pleura or atelectasis or post obstruction pneumonitis extending to hilum.
T2a	> 3 to ≤ 4 cm
T2b	> 4 to ≤ 5 cm
T3	>5 to ≤ 7 cm in greatest dimension or any size tumor that involves chest wall, pericardium, phrenic nerve or satellite nodule in the same lobs
T4	> 7 cm in greates dimension or any tumor with invasion of mediastinum, diaphragm, heart, great vessels, RLN, carina trachea, esophagus, spien or separate tumor in different lobe of ipsilateral lung.

KEY BOX 22.5

MEDIASTINAL MASS

Anterior mediastinum	Middle mediastinum	Posterior mediastinum
Along with myasthenia gravis • Thymoma (MC in Ant. Med.) • Lymphoma • Germ cell tumors • Thyroid & parathyroid mass • Thymic cyst • Thymoma (mc Ant. med. mass)	Cysts (MC in mid med.) ↓ Bronchogenic, enterogenous • Vascular mass • L.N. enlargement • Lymphoma (MC mild med. mass)	Neurogenic tumor (MC overall & in children & Post. med. mass) • Meningocele • Lymphoma • Pheochromocytoma

N1	Ipsilateral peribronchial and/or hilar nodes & intrapulmonary nodes.
N2	Ipsilateral mediastinal &/or subcarinal nodes
N3	Contralateral mediastinal or hilar; ipsilateral / contraindicated scalene or supraclavicular
M1	Distant metastasis
M1a	Tumor in contralateral lung or pleural / pericardial nodule / malignant effusion
M1b	Single extrathoracic metastasis, including single non-regional LN.
M1c	Multiple extrathoracic metastasis in 1 or more orgnas.

Investigation

- Mediastinoscopy → To assess & take biopsy from mediastinal LN.
- Endobronchial US (EBUS)

  EBUS → FNAC

  helps to target Peripheral lesion

Sugery to lung cancer

Assess, Thoraco score to see if patient is fit for surgery.

- Wedge resection - done for early lesions.
- Lobectomy - early lesions.
- Pneumonectomy
- Bronchoscopic resection
- Most common - Anterolateral thoracotomy.

****

CHEST TRAUMA

Rib fracture

Rib fracture are the most common injury sustained after a blunt trauma to chest. It is more common in older people as with aging; the chest wall loses compliance.

- It may occur due to direct or indirect injuries. Fracture of the ribs occur commonly at the site of maximum curvature at the anterior and posterior angle. 7th, 8th and 9th ribs are usually fractured.
- It can be diagnosed clinically by:
  - Pain in the chest wall during deep inspiration.
  - Pain is also aggravated by anteroposterior compression of chest *(springing test)*
  - Local tenderness at the site of fracture.
  - Surgical emphysema is diagnostic of rib fracture. Local crepitus may be palpable.
  - X-ray helps in confirming the diagnosis.
  - 1st step after initial resuscitation (NEET)

Complication of Rib fracture

- Pneumothorax
- Hemothorax
- Surgical emphysema
- Atelectasis
- Pneumonia

Treatment

- **Analgesics**
- **Prophylactic antibiotics**
- If pain is persistent and unbearable intercostal **nerve block** is helpful.
- Physiotherapy and early ambulation.

Stove-in Chest

- This is a severe chest injury resulting by a high energy localized crushing force which produces multiple rib fracture and an indentation (hollow) in chest wall.
- The affected side suffers a reduction in the size of hemithorax resulting in hypoxia.
- Treatment consists of emergency strapping and elevation of depressed chest segment.

Flail chest

- A flail chest result due to crush injury to the chest wall, where in there occurs **comminuted fractures of two of more ribs,** (NEET) each with a fracture anteriorly at or near costochondral junction and posteriorly near the angle, with the intervening segment of rib having no connection in front and behind. This segment of chest wall moves independently from the others and thus becomes a floating segment. Please see figure 22.6. It can be life life threatening.

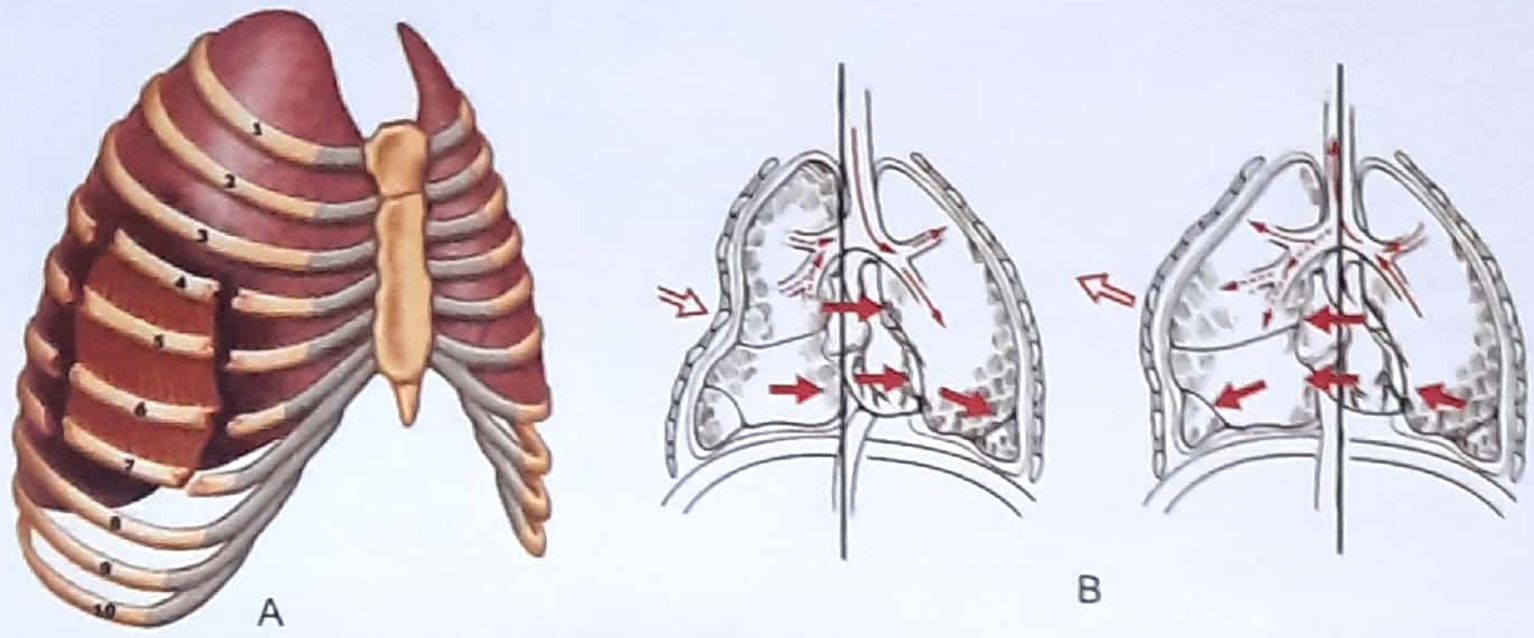

Figure 22.6: Flail chest

- The floating segment is sucked in during inspiration and pushed out during expiration, exactly opposite to what happens in normal respiration, hence known as **paradoxical respiration.** *(NEET, PGI JUNE 06)*
- Paradoxical respiration and the pendulum movement of air result in severe hypoxia and carbon dioxide retention.
- Work of Breathing is increased because paradoxical breathing is painful.

Diagnosis

The **condition is usually apparent on inspection of the patient's chest and inspiratory pattern.** *(NEET)*

- The flail segment and rib fracture can be palpated.
- Rib fracture can be seen on X-ray.

Management

1. Mild cases

- **Analgesics** - 1st treatment of flail chest.
- Firm strapping of the chest wall with adhesive plaster. This will help in correcting paradoxical respiration, mediastinal movement. Strapping also reduces the pain.
- Oxygen therapy
- Elevation of flail segment by K-wire or towel clips.

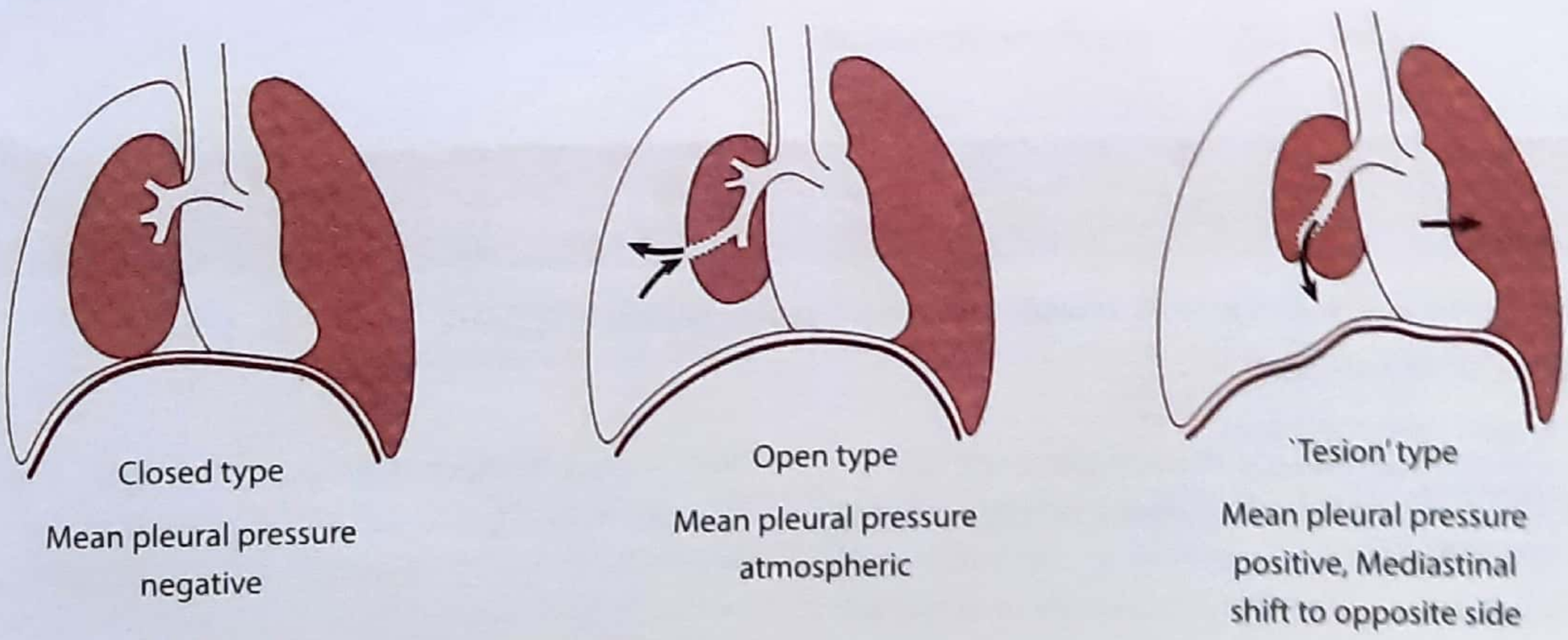

Figure 22.7: Types of Pneumothorax

2. Severe cases

- Analgesics.
- IPPV *(AI89)*
- **Endotracheal intubation and intermittent positive pressure ventilation (IPPV) is needed** *(NEET)* for about 3 weeks until the fracture becomes less mobile. *(NEET, PGI JUNE 06)*
- Some patient may require tracheostomy which will decrease dead space and repeated suction of broncho-pulmonary secretions.
- Antibiotics should be started.
- Thoracotomy with fracture fixation may be occasionally required if the associated lung injury is to be treated at the same time.
- Stabilization of the ribs is done by steel wire or nails or clips.

Traumatic Pneumothorax

This is accumulation of air in pleural space due to blunt or penetrating trauma. It can be of following type.

1. Open pneumothorax (sucking wound of the chest)
2. Closed pneumothorax
   (i) Simple pneumothorax
   (ii) Tension pneumothorax I have discussed pneumothorax, earlier in this chapter.

Surgical Emphysema (Interstitial Emphysema)

- It occurs following entry of air in the subcutaneous tissues, due to damage to the lung and parietal pleura by the fragment of fractured rib. Entrapped air gradually spreads into the loose subcutaneous tissue and fascial planes.
- Presence of air in subcutaneous plane present as a soft tissue boggy swelling. A crunching sound /crepitus can be heard when the tissue is palpated.

Treatment

- Analgesics and prophylactic antibiotics.
- Oxygen therapy.
- Multiple punctures on skin.
- Some patient may require chest tube placement.

Traumatic Hemothorax

Hemothorax may result from laceration of a vessel of the chest wall or lungs. It occurs in most of the cases with chest trauma. The bleeding may be minimal or massive depending upon the vessel involved. *Massive hemothorax (>1500 ml) is commonly due to intercostal (most common) or internal mammary artery rupture* *(NEET, AIIMS JUNE 94)*. Hemothorax has been discussed in detail earlier in this chapter on page 272.

****

Sample Questions for Prof Examination

1. Write etiology, pathogenesis, investigation and management of empyema.
2. Write short notes on:
   Tension pneumothorax.
   Empyema.
   Lung abscess.
   Flail chest.

23 Arterial Disorder

Contents

- Peripheral vascular disease
  - Atherosclerotic obstructions
  - Buerger's disease
- Acute thromboembolism
- Vasospastic disorders
- Raynaud's phenomenon
- Gangrene
- Amputation
- Arterial aneurysm
- Arterio-venous fistula
- Subclavian steal syndrome
- Thoracic outlet syndrome

ARTERIAL OCCLUSION

Arterial occlusion may be acute (sudden), or slow and progressive. Acute occlusion may result due to an embolus or trauma. At various places, the clinical picture produced are different:

In lower limbs it causes intermittent claudication, rest pain and gangrene, in the **heart;** angina and myocardial infarction may result. **Carotid artery insufficiency** may result in transient ischemic attacks (TIA). Renal artery insufficiency may lead to renovascular hypertension, **Mesenteric artery insufficiency** may lead to recurrent abdominal pain and gangrene of intestine.

****

PERIPHERAL VASCULAR DISEASE (PVD)

The causes of impaired circulation to the limbs are :

1. **Atherosclerotic obstruction** (ASO)
2. **Buerger's disease (Thromboangiitis obliterans)**
3. **Mechanical trauma, cold or chemical injury**
4. **Spasm (Raynaud's disease)**
5. **Emboli**
6. **Thrombosis**

In this chapter; we will discuss some important peripheral vascular disease.

Atherosclerotic Obstruction (ASO)

Atherosclerosis is thickening of the large and medium sized arteries resulting from deposition of specific atheromatous lesions. "Arteriosclerosis" is a nonspecific term that denotes thickening and *loss of elasticity* ("hardening") of the arteries from any cause. Changes associated, with aging and hypertension often lead to arteriosclerosis.

The **basic abnormality in atherosclerosis is deposition of complex lipid in the intima of large and medium sized artery**. The causes is uncertain. The major risk factor has been listed below.

Risk factors

1. **Increasing age:** Significant disease is rare under 30 years.
2. **Morbid obesity:** > 30% of ideal body weight.
3. **Lack of physical exercise:** Incidence greater in persons with sedentary occupation; regular exercise (20 minutes; twice weekly) decreases risk.

Highly significant factors

1. Male sex

Males are affected more than females; female incidence increases after menopause; sex incidence is equal after age 65 years.

2. Family history

History of ischemic heart disease in a parent or sibling under age 55 years.

3. Hyperlipidemia

The major risk factor in patient under 45 years of age. Specific lipoproteins involved in increased risk are as follows:

Total cholesterol > 6 mmol/L (> 240 mg/dl)

Total triglyceride > 2.8 mmol/L (250 mg/dl)

LDL-cholesterol > 4.2 mmol/L (> 160 mg/dl)

Low HDL-cholesterol:. < 0.9 mmol/L (< 35 mg/dl)

4. Hypertension

The major risk factor in patients over 45 years of age; hypertensive person have a five fold increased risk compared with normotensive persons.

5. Cigarette smoking

Ten cigarettes per day increases the risk three fold; cessation of smoking decrease risk to normal after 1 year.

6. Diabetes mellitus

Both type I and type II diabetes mellitus are associated with a two fold increase in risk.

Pathology

The lesions of atherosclerosis are fatty streak, the fibrous atheromatous plaque, and complicated lesions. The latter two are responsible for clinically significant disease.

Please go through this flow chart before proceeding further

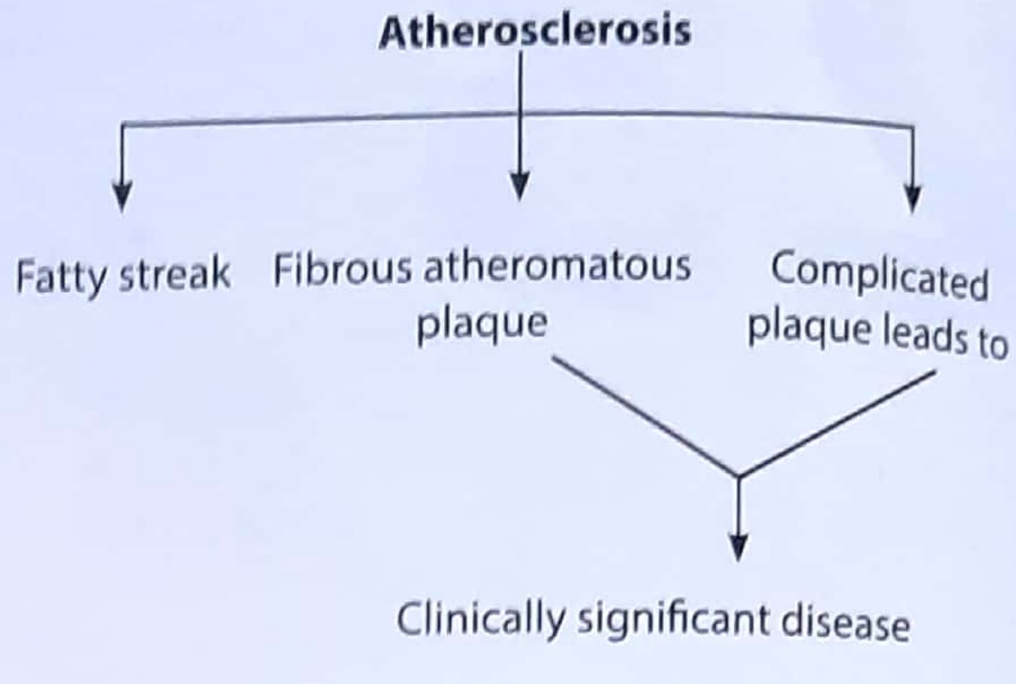

A. The Fatty Streak

Fatty streaks are thin, flat yellow streak in the intima. They consist of macrophages and smooth muscle cells, whose cytoplasm has become distended with lipid (to form foam cells). Fatty streak occur maximally around the aortic Valve ring and thoracic aorta. They are present very early in life, often in the first year, and are seen all over the world irrespective of sex, race, or environment. They increase in number until about age 20 years and then remain static or decrease. There is controversy about whether some fatty streak progress into fibrous atheromatous plaques or whether they are independent of atherosclerosis. Fig; 23.1.

B. The Fibrous Atheromatous Plaque

This is the **basic lesion** of clinical atherosclerosis *(AIIMS 2000)*. It consists of **three zones.**

1. *A **fibrous cap**;* which lies under the endothelium, consisting of dense collagen and scattered smooth muscle cells and macrophages.
2. The ***lipid zone**;* which consists of foam cells (lipid laden macrophages and smooth muscle cells) and extracellular lipid and debris.
3. The ***basal zone**;* is composed of proliferated smooth muscles and connective tissue. Different plaques contain varying amounts of these three layers; some are mainly fibrous, and others predominantly fatty. The fibrous atheromatous plaque appears grossly as a yellow white elevation on the intimal surface of the artery.

Fibrous atheromatous plaques are present in the aorta in most cases. Involvement of muscular arteries such as the coronary, carotid, vertebrobasilar, mesenteric, renal, and iliofemoral arteries is associated with luminal stenosis and is responsible for many of the clinical manifestations of atherosclerosis.

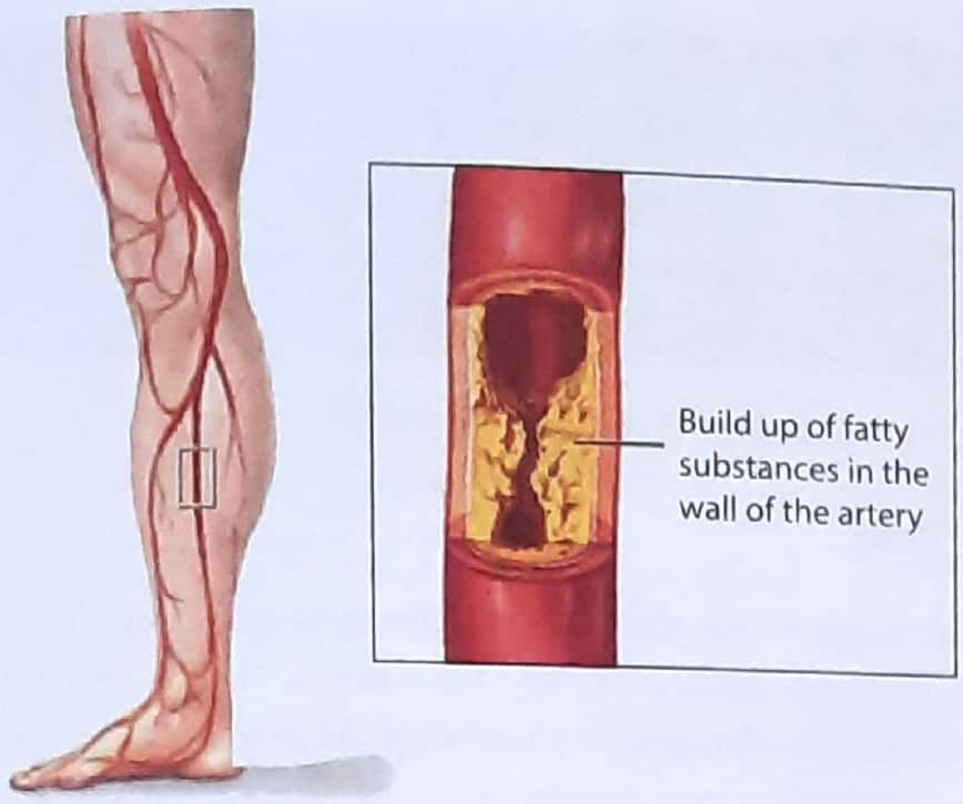

Figure 23.1: Build up of fatty streak

C. *The complicated plaque*

Thrombosis is the most important complication of atherosclerosis, since it may cause complete occlusion of the artery. Thrombosis is caused by :

1. Slowing and turbulence of blood flow in the artery in the region of the plaque.
2. Ulceration of the plaque.

Dystrophic calcification is very common and occurs in the lipid zone of the plaque. Severely affected vessels (including the aorta) may become converted to calcific tubes. **Ulceration** of the endothelium overlying the plaque may cause the lipid contents of the plaque to be discharged into the circulation as cholesterol emboli. Ulceration of the plaque may also precipitate arterial thrombosis at the site. Vascularization of the plaque occurs by ingrowth of poorly supported vessels from the medial aspect. These may rupture, leading to **hemorrhage** into the plaque, which may then expand sufficiently to occlude the lumen of the artery. Hemorrhage may also cause ulceration and thrombosis. **Aneurysms** may develop in arteries weakened by extensive plaque formation. The abdominal aorta is the favoured site for atherosclerotic aneurysms *(PGME)*.

Clinical effects

A. Narrowing of affected Arteries

Ischemia from arterial narrowing is responsible for most of the clinical effects of atherosclerosis. A decrease in blood flow usually occurs only with severe (>-70%) narrowing of the vessel. Aortic narrowing is almost never sufficient to cause symptoms. However, narrowing of coronary, cerebral, renal, mesenteric, and iliofemoral vessels often causes ischemic changes in the organ due to reduced tissues supply. Superimposed thrombotic occlusion of these arteries may cause infarction. Please see key box 23.1.

KEY BOX 23.1

Clinical effects of atherosclerosis related to the major arteries involved.

Artery involved	Clinical Effect
Aorta	Atherosclerotic aneurysms cholesterol embolism
Internal carotid artery	Chronic cerebral ischemia cerebral infarction ("stroke") Transient ischemic attacks - TIA
Circle of Willis	Contributes to rupture of berry aneurysms
Vertebrobasilar system	Cerebellar ischemia and infarction Brain stem ischemia and infarction
Coronary arteries	Myocardial infarction Chronic myocardial ischemia Angina pectoris Chronic heart failure Arrhythmias and heart block
Celiac and mesenteric arteries	Intestinal ischemia and infarction, colitis
Renal arteries	Renal artery stenosis renovascular hypertension
Iliofemoral arteries	Peripheral vascular disease, intermittent claudication, Gangrene (discussed in, this chapter)

B. Embolism

Ulceration of the atheromatous plaque may result in embolization of the lipid contents of the plaque. This is important in the cerebral circulation, where small emboli produce transient ischemic attacks (TIA). Emboli can sometimes be visualized in the retinal arteries on funduscopic examination.

C. Aneurysm

In severe atherosclerotic involvement of the aorta, the wall may be weakened to an extent that leads to dilatation

or aneurysm formation. *Atherosclerotic aneurysms occur mainly in the lower abdominal aorta* and may appear as a fusiform dilatation of the whole vessel circumference or a saccular bulge on one side on it. (Saccular aneurysm)

Till now, I was giving you a little bit on atherosclerosis, and its clinical effect, now lets discuss the peripheral arterial occlusion, a true surgical topic.

PERIPHERAL ARTERIAL OCCLUSION

Insufficiency of peripheral arteries is more common in lower limb due to poor collateral circulation, while they rarely produce symptoms of arterial insufficiency in the upper limb because of rich collateral pathways. The effect of arterial blockade depends on:

1. The anatomical arrangement of arteries and collateral circulation of the organ.
2. The degree of occlusion
3. The speed of occlusion
4. The circulatory demands of the tissue.

Atherosclerotic changes predominantly affect the bifurcation of abdominal aorta and the common iliac arteries, these patients usually develop buttock and thigh claudication and may have *erectile impotence* (***Leriche's syndrome***). *(UPSE 08)*

Clinical Feature

(AIIMS NOV 99, AIIMS NOV 98, PGI JUNE 2000, PGI DEC 98)

7Ps are:-

- **P**ain
- **P**allor
- **P**ulselessness
- **P**oikilothermia
- **P**aresis/Paralysis
- **P**araesthesia
- **P**ressure changes

Lets take each of them one by one:

1. Pain

Pain is generally the first symptom of ischemic disease. Progressive ischemia of the lower limb produces *intermittent claudication*, with pain in the calf muscles precipitated by exercise and relieved by rest.* Patient often describe the pain as burning/or crampy.

***Claudication?**: *(TN 89)* Claudication means "I limp". When a patient of peripheral arterial insufficiency (either due to atherosclerosis or Buerger's disease) walks, the muscles used in walking (Calf muscle and other small muscles of foot) starts working and require increased amount of oxygen (blood supply); which can not be supplied due to arterial insufficiency. Pain is due to ischemia of nerves and accumulation of metabolites of anaerobic metabolism-Substance 'P'. *(AI 09)*

For hindi speakers, Claudication = *Langda kar chalna.*

- Distance after which the patient feels severe pain, & becomes unable to walk, is called as ***claudication distance.***
- More is the claudication distance, means less is the ischaemia and less is the claudication distance more is the limb ischemia.
- **Pseudoclaudication seen in lumbar canal stenosis.** *(NEET)*

KEY BOX 23.2

Signs and symptoms of acute limb ischemia

DESCRIPTION	CATEGORY		
	VIABLE	THREATENED	IRREVERSIBLE
Clinical description	Not immediately threatened	Salvageable if promptly treated	Major tissue loss, amputation unavoidable
Capillary return	Intact	Intact, slow	Absent
Muscle weakness	None	Mild, partial	Profound, paralysis (rigor)
Sensory loss	None	Mild, incomplete	Profound aneshtetic
Arteriovenous Doppler finding	Audible	Inaudible or audible	Inaudible

KEY BOX 23.3

Classification of peripheral arterial disease based on the fontaine and Rutherford classification

FONTAINE CLASSIFICATION		RUTHERFORD CLASSIFICATION		
STAGE	**CLINICAL**	**GRADE**	**CATEGORY**	**CLINICAL**
I	Asymptomatic	0	0	Asymptomatic
IIa	Mild claudication	I	1	Mild claudication
IIb	Moderate to severe claudication	I	2	Moderate claudication
		I	3	Severe claudication
III	Ischemic rest pain	II	4	Ischemic rest pain
IV	Ulceration or gangrene	III	5	Minor tissue loss
		III	6	Major tissue loss

Site of Pain

The site of pain depends on the level of arterial occlusion.

***For Example*:**

In the buttock (AIIMS NOV 16): Occlusion is at the bifurcation of the common iliac artery or the aorta.

Claudication + Impotence = Leriche syndrome (NEET)

In the thigh: When the arterial occlusion is at the opening of superficial femoral artery.

In the calf (NEET): When the arterial occlusion is at the **femoropopliteal junction** (very common).

In the foot: Pain in foot is felt when there is occlusion of tibial and plantar arteries (more common in Buerger's disease).

2. *Pallor*

An acute arterial occlusion produces marked pallor and progresses to gangrene.

Chronic arterial occlusion may produce no visible change initially, but later may show skin changes.

KEY BOX 23.4

Nonatherosclerotic causes of intermittent claudication

- Aortic coarctation
- Arterial fibrodysplasia
- Iliac syndrome of the cyclist
- Peripheral emboli
- Persistent sciatic artery
- Popliteal aneurysm
- Popliteal cyst
- Popliteal entrapment
- Primary vascular tumors
- Pseudoxanthoma elasticum
- Remote trauma or radiation injury
- Takayasu's disease
- Thromboangitis obliterans

KEY BOX 23.5

Boyd's Grading of claudication

Boyd's has graded intermittent claudication as below

Grade I: The patient feels pain alter walking a certain distance but the pain passes away after further small walk, and .patient keeps on walking. (Because with the exercise, the metabolites Washes off into circulation).

Grade II: The patient feels pain after walking for some distance, and does not pass away and the pain is felt, though mild, however patient keeps on walking.

Grade III: The pain On walking for some distance is so severe that patient stops walking and takes rest. This distance to the claudication distance.

Some authors add: Grade IV: which is pain even at rest.

In a normal person the straightened leg can be raise up to 90° and toes remain pink, however in an ischemic leg elevation to 15° or 30° may cause pallor. An angle less than 20° indicates severe ischemia. This is called as *Buerger's postural test and the angle is known as Buerger's angle.*

3. Pulselessness

All the palpable pulse below an occlusion are usually absent **or** if good collateral circulation has developed; pulses may be felt though weak and diminished. Diminution of pulse can be appreciated by comparing it with the pulses of other limb.

4. Poikilothermia

With chronic ischemia, the temperature of the skin of foot decreases due to diminished blood supply. This is best detected by palpating the foot with dorsum of the hand. The ischemic limb will feel cool as compared to opposite limb.

5. Paresthesia

Paresthesia and numbness are common in moderate as well as in severe ischemia. The patient often notices numbness or pins and needle sensation in the skin of foot. This is caused by diversion of blood from the skin to the muscle; due to increased demand by the muscles.

6. Paralysis

Acute and chronic ischemia may lead to gangrene and paralysis of affected limb.

7. Pressure changes

Ischemic limb is vulnerable to pressure. Common pressure areas are the heels, malleoli, head of the fifth metatarsal and tips of toes. These areas may show evidence of trophic changes; viz; minor ulceration or gangrene.

8. Other Features (& skin changes)

- Thinning of skin
- Loss of hair
- Loss of subcutaneous fat
- Loss of shininess of skin
- Brittle nail
- Muscle wasting

Please read Key box 23.6 and 23.7 carefully.

Investigation

1. General investigation

This include TLC, DLC, ESR blood sugar, lipid profile, urine examination. A chest X-ray and ECG are always obtained in patient with peripheral vascular disease. An echocardiogram is useful in confirming the cardiac status of the patient as many of patients may have co-existing cardiac disease.

KEY BOX 23.6

Differential Diagnosis of Claudication

1. Osteo-arthrotic claudication
2. Neurological claudication: disc prolapse, sciatica, Cauda aquina syndrome
3. Muscular claudication
   (i) Muscle trauma, tear
   (ii) Myositis
4. **Vascular claudication**

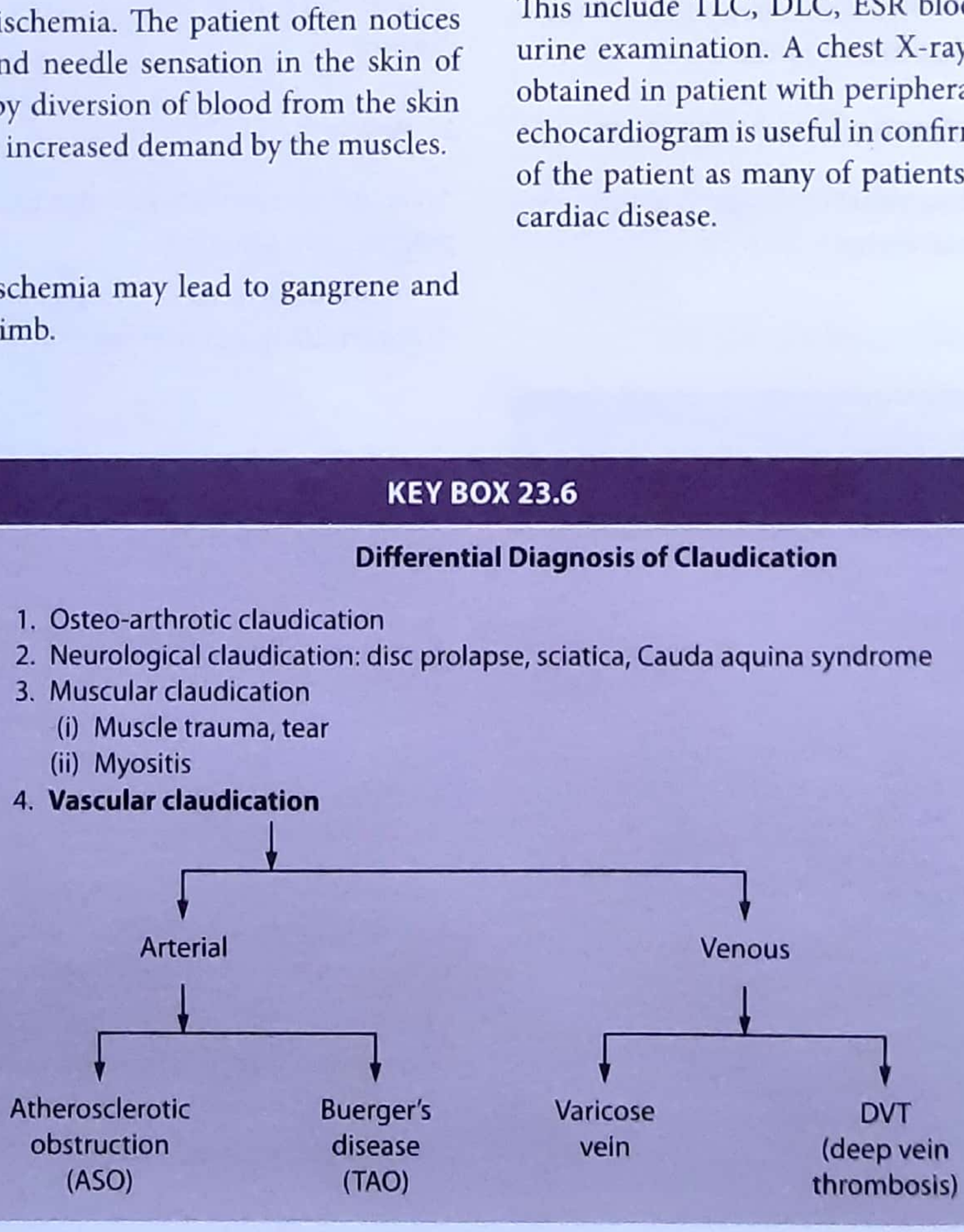

KEY BOX 23.7

Clinical categories of chronic limb ischemia

Grade	Category	Clinical Description	Objective criteria
0	0	Asymptomatic-no hemodynamically significant occlusive disease	Normal treadmill or reactive hyperemia test
	1	Mild claudication	Able to complete treadmill exercise; AP after exercise >50 mmHg but at least 20 mmHg lower than resting value
I	2	Moderate claudication	Between categories 1 and 3
	3	Severe claudication	Cannot complete standard treadmill exercise *and* AP after exercise <50 mmHg
II[b]	4	Ischemic rest pain	Resting AP <40 mmHg, flat or barely pulsatile ankle or metatarsal PVR; TP <30 mmHg
III[b]	5	Minor tissue loss-nonhealing ulcer, focal gangrene with diffuse pedal ischemia	Resting AP <60 mmHg, ankle or metatarsal PVR flat or barely pulsatile; TP <40 mmHg
	6	Major tissue loss-extending above TM level, functional foot no longer salvageable	Same as category 5

Five minutes at 2 miles per hour on a 12% incline of treadmill excercise,
Grade II and III, categories 4, 5 and 6, are encompassed by the term chronic critical ischemia,
AP = ankle pressure; PVR = pulse volume recording; TM = transmetatarsal; TP = toe pressure.

2. Doppler ultrasound

This is helpful in detecting the flow of blood in the vessels.

3. Ankle-Brachial index (ABI)

This is obtained by dividing the systolic blood pressure at the ankle by the systolic blood pressure at brachial artery.

- ABI = Systolic ankle pressure/systolic brachial pressure
- **ABI is normally more than 1.0** *(NEET)* ie; ankle pressure is more than brachial pressure.
- If it is less than 1 (ie; < 0.9), it indicates occlusive arterial disease.

ABI	Symptoms
>1.3 *(NEET)*	Calcified vessels
> 0.9	None
0.8-0.5	Claudication
0.49-0.3	Rest pain
<0.3 *(NEET)*	Gangrene (Iminent necrosis)

4. Arteriography

Arteriography is X-ray visualization of arterial anatomy. This is done by injection of contrast media (Conray 400) directly into abdominal aorta through translumbar route or through a catheter into aorta from a peripheral artery through seldinger's technique.

Arteriography will show

(i) Site and degree of arterial obstruction

(ii) Degree of arterial obstruction

(iii) Status of collateral circulation

Figure 23.3 next page

5. Digital substraction arteriography (DSA)

This is special type of angiography, where in the overlying shadows produced by soft tissue and bone is **substracted** (removed, which interferes in interpretation of findings) by using a computer.

Figure : Colour duplex scanner

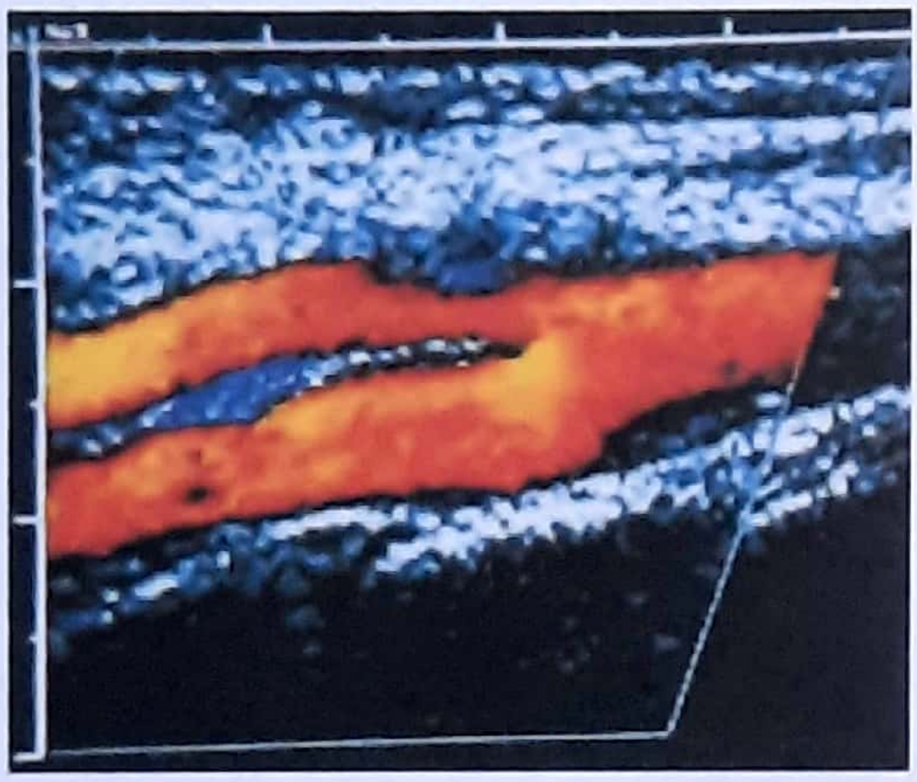

Figure 23.2 : Colour duplex scan of carotid vessels in the neck showing stenosis at the common carotid bifurcation

6. Isotope Technique

Xenon^{133} dissolved in isotonic saline is injected intramuscularly, the clearance of which has been used to study the blood flow in the calf muscles.

Recently, Techne-tium^{99} has become the isotope of choice though the technique remains essentially the same.

More recently, intravenous injection of the isotope has been used to obtain a clear view of the arteries. For this a gamma camera is used to picturise the blood flow in a limb.

7. Angioscopy

This is endoscopic visualization of the vascular system, after passing a small endoscope in the lumen of artery.

Treatment

A. Medical treatment

- Patient should be always advised to stop smoking.
- Anemia & hyperglycemia, if present should be corrected.
- Walking stimulates in development of collateral circulation; therefore walking is encouraged if possible.
- Pain should be relieved by pain killers.
- **Aspirin**-Sustained release tablets of aspirin 150 mg/day may be prescribed for its antiadhesive effects on platelets.
- Blood thinning agents like *pentoxyphyllin* may be used as it increases red blood cell flexibility.
- Foot infections and injuries should be prevented.
- Claudication distance can be increased by raising the heels by 1cm (heel raise). This reduces the work of the calf muscle.

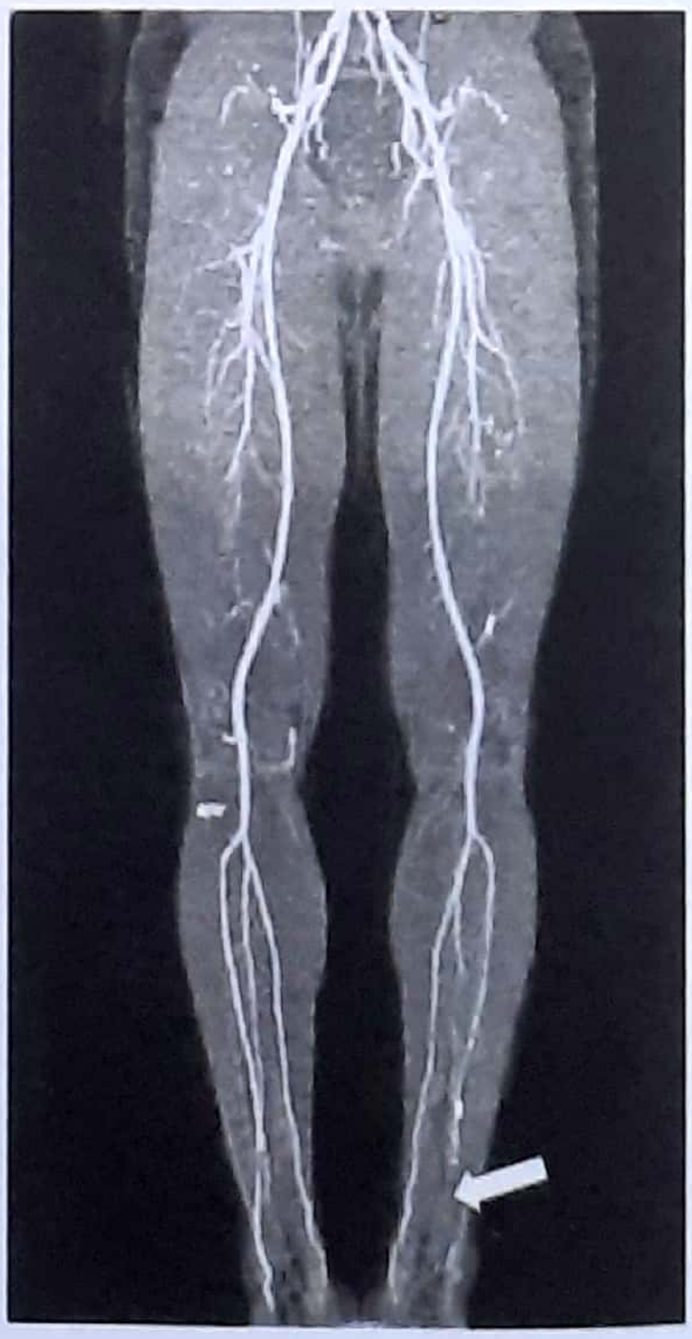

Figure 23.3 : High-resolution computed tomography angiography of a patient with normal right lower extremity arterial circulation. Distant occlusive disease is noted in the left tibial arteries (*arrow*)

- *Chemical sympathectomy:* This is done by injecting 1% lignocaine and 5 ml of 5% Phenol around sympathetic chain.

B. Surgical Treatment

Indication for surgical treatment are:

(i) Severely incapacitating claudication

(ii) Rest pain

(iii) Ischemic ulceration.

Various surgical procedures are given here:

1. Revascularization Procedures

Surgical option

The type of surgery depends upon the site of occlusion of the vessels and fitness of patient for surgery. If there is an occlusion in any pipe, what should one do either reconstruct it, or dilate the pipe intraluminally to obtain adequate flow of the fluid.

I have summarized the **surgical options in** a chart.

Reconstruction procedures	**Dilatation procedures**
• Aorta femoral reconstruction	• Percutaneous trans luminal angioplasties (PTA)
	• Balloon dilatation
• Femoropopliteal reconstruction	• Intraluminal stenting
• Axillofemoral bypass	
• Profundaplasty	
• Endarterectomy	

KEY BOX 23.8

Complications of arterial revascularization

Compartment syndrome
Ischemic neuropathy
Muscle necrosis
Recurrent thrombosis
Lower leg swelling
Reperfusion syndrome
- Hypotension
- Hyperkalemia
- Myoglobinuria
- Renal failure

2. Lumbar sympathectomy

It is seldom indicated as a sole treatment for patients with occlusion of peripheral arteries in the lower limb. Lumbar sympathectomy helps in early healing of ischemic ulcer (if present) and reduces pain.

3. Amputation

If there is gangrene in the leg or foot, amputation is only the course.

Please read key box 23.9, (on next page) carefully.

****

BUERGER'S DISEASE (THROMBO ANGIITIS OBLITERANS, TAO)

Buerger's disease is *inflammatory reaction in the arterial wall with involvement of neighboring vein and nerve, terminating in thrombosis of the artery.*

- It is also known as **Thromboangiitis obliterans.** Now split the word:-

  Thrombo - Thrombosis

  +

  angiitis-Inflammation (of medium and small sized arteries) (with formation of micro abscess)

  + Obliterans -Obliteration

- There ***panvasculitis*** ie; arteritis, periarteritis and phlebitis (inflammation of vein) and periphlebitis. *(MANY PGME)*
- The disease starts in the *distal small arteries and spreads upwards.* *(IMP, POINT)*
- Buerger's disease (TAO) **involve** the ***small and medium sized arteries of ankle and foot in majority of cases,*** *(PGME MANY TIMES)* however arteries of forearm are involved in about only 5-10% cases.

NOTE: **Large arteries are not involved** *(MANY PGME)*

- Buerger's disease affects not only the arteries and veins of upper and lower extremities, but has been demonstrated to occur in cerebral, ocular, spermatic, me-senteric, renal and coronary vessels.
- Involvement of superficial vein may result in migratory superficial thrombophlebitis.

KEY BOX 23.9

Summary of endovascular treatment strategies using device-based infrapopliteal intervention

INTERVENTION	ADVANTAGES	DISADVANTAGES
Angioplasty	• Easy to use • Broad range of applications	• Failure in long lesions calcifies lesions, and disease at multiple levels
Balloon-expandable stent	• Overcomes arterial recoil from angioplasty • Useful in treatment of flow-limiting dissection	• Crushability can lead to restenosis • Poor distal runoff can result in stent thrombosis • Limited data
Self-expanding stent	• Vessel conformability and wall apposition prevent kinking and crushing of stent	• Limited sizes • Limited data; multicenter trials under way
Bioabsorbable stent	• Overcomes arterial recoil from angioplasty • Absorbed long term to prevent risk of stent thrombosis	• Limited data; multicenter trials under way
Cryoplasty	• Reduces the risk of flow-limiting dissection, therefore reducing the need for stent implantation	• Short-term results of multicenter trial are promising; however, long-term data are limited
Cutting balloon	• Useful in anastomotic segments of bypass grafts and in-stent restenosis where "watermelon seeding" can prevent adequate expansion of plaque	• Limited data
Mechanical atherectomy	• Allows for debulking of plaque without the need for stent implantation in most cases • Allows for removal of plaque for histologic analysis	• Limited use in areas of heavy calcification • No large, randomized, prospective trial comparing this technique to angioplasty and stenting
Later	• Useful in acute thrombotic and chronic total occlusions	• Minimal data in infrapopliteal arteries • Need adjunctive treatment with angioplasty, stenting, or atherectomy

Incidence

The disease is found more frequently in men between 20 and 40 years of age (peak age being 30 years). It is uncommon in women, who constitute only about 10% of all patients with Buerger's disease.

'Rule of 10' for Buerger's disease?

- In 10% cases the disease is bilateral (both legs).
- In 10% cases females are affected:
- In 10% cases upper limb in affected.

Etiology

The etiology of Buerger's disease is not well understood.

(i) *Cigarette smoking* (>20) has striking association with this disease. *(AIIMS JUNE 97)*

(ii) There has been some *hormonal influence seen with estrogen, which* suggests the sex distribution.The disease is very less common in female smokers. *(AHMS 97, MANY PGME).*

(iii) Because the incidence is very low, even in chronic heavy smokers and autoimmune pathology has also been proposed.

(iv) A Genetic factor has been suggested by the fact that blacks are rarely affected whereas Jewish are more susceptible to disease.

(v) Fibrinogen level often is elevated in a patient with Buerger's disease and hence a hypercoagulable state has also been postulated as a possible theory.

Pathology (IMPORTANT)

- In acute phase, there is marked swelling and neutrophil infiltration of the entire neurovascular bundles.
- Thrombosis *is common with micro-abscess formation.* *(MANY PGME)*

- In the late stage the affected artery becomes occluded and contracted with marked fibrotic reaction affecting all **the layers of the artery**, viz; the adventitia, the media and intima.
- This whole *fibrotic process gradually also involves the* ***adjacent vein and nerve*** (NEET, AIIMS JUNE 97).

Clinical Feature

The clinical features of buerger's disease are that due to chronic ischemia. These are '7ps' which has been described in detail earlier in this chapter. Kindly do read it on page no 243.

7Ps are

(i) **P**ain-mainly in foot
(ii) **P**allor (**P**aleness)
(iii) **P**ulselessness (weakness of pulse)
(iv) **P**oikilothermia (cold limb)
(v) **P**aralysis
(vi) **P**aresthesia
(vii) **P**ressure change- Trophic changes, minor ulceration and gangrene

Treatment

A. General measures

1. ***Stop smoking:*** is the best advice to the patient. The patient should be bluntly told that he could either have his cigarettes or his legs.
2. ***Promote walking:*** Patient should be told to exercise regularly to reduce their claudication distance, as this is known to promote collateral circulation and the symptoms may not progress or may in fact disappear. Buerger's exercises may be of use in a bed ridden patient.
3. ***Care of feet:*** Exposure to extremes of temperatures, especially cold weather, should be avoided. Well fitting footwear should be worn. Patient should cut their nails carefully, to avoid trauma to the toes.
4. ***Weight reduction***
5. ***Heel raise*** *in footwear* increases claudication distance.

B. Drug therapy

1. ***Aspirin:*** Low-dose is recommended for it's antiplatelet effect. Ticlopidine (250 mg b.i.d.) has the same effect but is more expensive.

Figure 23.4: Dry Gangrene in a patient with Buerger's disease

2. ***Analgesics:*** These are required for treatment of rest pain. One should begin with paracetamol and use gradually more potent analgesics (ibuprofen, diclofenac, and ketorolac). Opioid analgesic should be avoided as far as possible because of it's abuse potential.
3. ***Pentoxyfylline:*** (400 mg tablet): This agent reduces the blood viscosity (dose: 400 mg t.d.s. increasing it to 800 mg. td.s.). The effect may be seen only after 2-3 weeks.
4. ***Naftidofuryl:*** This drug alters the tissue metabolism allowing a greater oxygen debt to be incurred by tissues. It appears to be a promising agent for treatment of intermittent claudication.
5. Other agents like carnitine, prostacycline has been used with some success.

NOTE: *Vasodilator and anticoagulants have no role in treatment of Buerger's disease.*

C. Surgical treatment (AIIMS JUNE 01)

Direct arterial surgery and angioplasties are not feasible because arteries involved are too small to be reconstructed; and mostly located distal to the knee or elbow.

1. Sympathectomy

Sympathectomy has been widely employed for relief of vasospasm in Buerger's disease. *It increases blood flow to the skin, but does not increase muscle blood flow.*

(i) Lumbar sympathectomy (AIIMS JUNE 97, AI 05):

Current indication of lumbar sympathectomy include the following:

KEY BOX 23.10

Difference between Atherosclerotic obstruction (ASO) and Buerger's disease (thromboangiitis obliterans-TAO)

Feature	Atherosclerotic obstruction (ASO)	Buerger's disease (TAO)
Site of lesion *(AIIMS FEB 97, AI 02)*	Large and medium sized arteries (aortic, iliac, femoral and popliteal)	Small arteries (tibial, dorsalis pedis, plantar, digital)
Age at most *(AIIMS NOV 99)*	> 40 years	20-40 years
Sex predilection	M > F	Only in 10% women
Smoking history	Common	Seen only in smokers, but poor correlation with quantity
Thrombophlebitis *(AI 02)*	Rare	Common
Progression of disease	Proximal to distal	Distal to proximal
Duration of symptoms	Months to years	Much shorter
Venous involvement	Not seen	Common
Inflammatory reaction	None	Profound
Angiography	Proximal lesions extensive collateral (tree root appearance)	Distal arterial involvement 'cork-screw' collaterals
Amenability to bypass surgery	Good	Poor
Histology	Atheroma or calcification in arterial wall	Thrombus and inflammatory reactions in all three layers of the artery

TWENTY THREE

- Non-healing ischemic ulcer.
- Ischemic rest pain.
- Vasospastic condition- Raynaud's phenomenon.
- Hyperhidrosis (abnormal increased sweating).
- Causalgia (complex regional pain syndrome).

It is *important* to note that lumbar sympathectomy has no role in the treatment of intermittent claudication. *(AIIMS SEP 96)*, because lumbar sympathectomy increase blood flow only to the skin and not to the muscles of calf and foot. In this way lumbar sympathectomy promotes healing of an ischemic ulcer; if present.

- In lumbar sympathectomy, 2nd to 4th lumbar sympathetic ganglia are removed. **Removal of 1st lumbar sympathetic ganglia results in retrograde ejaculation, hence it is preserved**. *(NEET, JIPMER 92)*
- Chemical sympathectomy done by phenol.

(ii) Cervicodorsal sympathectomy

In this 2nd and 3rd thoracic ganglion are removed. *The stellate ganglion is left intact in order to prevent the development of Horner's syndrome* (Ptosis, Enophthalmos and Myosis). {**Mnemohic = PEM i.e.: Protein** Energy Malnutrition}. Please read Horner syndrome on page no. 252 chapter 20.

2. Amputation

It is indicated if there is intractable pain and if severe infection is present and conservative treatment or sympathectomy has failed. It is advisable to avoid above knee (AK) amputation, and below knee (BK) amputation should be generally done.

3. Free omental graft

(Omentoplasty): Free omental grafts provides microvascular transplantation and has been successfully tried.

Please read Key box 23.10 before moving to next topic.

****

ACUTE THROMBOEMBOLISM

Acute arterial thrombosis and embolism present with severe pain in affected limb or organ. Emboli may lodge in the brain, retina, lungs, mesenteric vessels, spleen, kidney or in lower limb. Despite advances in surgical techniques and better management modalities, mortality due to acute limb ischemia is still as high as 20%.

Etiology

- Acute arterial occlusion may be caused by
  - (i) an embolus
  - (ii) trauma or
  - (iii) thrombosis
- The heart is the source of embolus in 80-90% of episodes. The clot (embolus) most frequently originates from the left atrium (PGME).
- Ulceration in atherosclerotic plaque can lead to dislodgment of an embolus containing platelets, thrombus or debris.
- In India the *most common source of the embolus is from the heart,* and rheumatic valvular heart disease is the most common etiology. I have listed the common cause of embolism and thrombosis below.

KEY BOX 23.11

Differentiating Feature

Features	Embolism	Thrombosis
1. Identifiable source of embolus	Heart	Uncommon
2. History of previous claudication	Not present	Common
3. Contralateral pulses	Normal	Often absent
4. Onset	Sudden	Gradual
5. Loss of function	Rapid, over 4-6 hours and is often complete	Slow and incomplete, because collaterals have already developed

(a) Embolism

1. **Cardiac Source** (60-70% -M/C)
- Atrial fibrillation
- Bacterial endocarditis
- Post myocardial infarction
- Atrial myxoma

2. **Non-Cardiac source (15-20%)**
- Aneurysm
- Atherosclerotic arterial disease

3. **Postoperative: About 5%**

4. **Unknown: 10-15%**

(b) Thrombosis

- Atherosclerotic stenosis
- Aneurysm
- Repeated trauma to an artery
- Hypercoagulable states
  - Anti-phospholipid syndrome
  - Protein C & S deficiency
  - Antithrombin III deficiency
  - Postpartum
- Iatrogenic
  - Angiography
  - Cardiac catheterization
  - Intraarterial injection
- Unknown cause

Common sites of location of emboli

Location	*Incidence*
Femoral	45% (M/C) PGME
Aortoiliac	25%
Popliteal	15%
Brachial	7%
Axillary	6%
Others	2%

Clinical Features

The clinical features of acute limb ischaemia due to arterial occlusion can be summarized by the FIVE P'S.

(i) **Pain** : There is intense, unremitting to the opposite side.

(ii) ***Pulselessness*** : Absence of pulses in the affected limb, is the most specific sign.

(iii) ***Paraesthesia*** (NEET): This may be present in the affected limb.

(iv) ***Paresis*** : This is a late feature.

(v) ***Poikilothermia*** *(cold limb)*: The affected limb is cool as compared to the other part.

Clinically it is very difficult to differentiate between thrombosis and embolism in extremities, however it is very important to differentiate between the two condition, because the treatment plans for both condition is entirely different. Please see key box 23.11.

Management

Early definitive treatment is very important to prevent irreversible ischemia. There is a so called **'Gold period' of about 6 hours** from the onset of symptoms. All efforts should be directed towards restoring the limb Circulation within this period; especially in a case of embolism, however limb salvage has been reported even up to 24 hours and beyond in some rare cases.

Features of **nonviability of limb include:**

- Persistent skin mottling or duskiness, which does not blench on pressure.
- Turgidity of muscles (swollen muscles)
- Complete paralysis and loss of sensation
- Established gangrene

KEY BOX 23.12

Thrombolytic Agents

Agent	Systemic	Intra-arterial
Streptokinase	2.5 lacks antes i.v. over 30 minutes	5000-20000 units/ hour followed by 1.0 lack unit/hr for 24 hour
Urokinase	2 lacks unit over 10-20 minutes followed by 25000 units iv/hr for 12-24 hours	4000 units/minute for 30 minute
TPA	40-50 mg over 2 hours	

In such cases limb revascularization and salvage should not be attempted and primary amputation is the best option.

Investigation

In most of the cases the diagnosis is clinical, which is supported by following:-

- The relevant investigations include an ECG, X-ray chest, Hb, TLC, DLC, blood urea, serum creatinine.
- Echocardiography helps to rule out or confirm a cardiac lesion, if the same is suspected.
- Doppler ultrasound may be used to detect flow in the vessels and to measure the pressure in the peripheral arteries.
- Coagulation profile especially PT and APPT.
- Angiography is rarely indicated.

Treatment

1. Heparin

Heparin should be administered systemically to prevent the proximal and distal propagation of thrombosis in the

KEY BOX 23.13

Contraindications to thrombolytic therapy

Absolute contraindications

Established cerebrovascular events (including transient ischemic attack) within last 2 months
Active bleeding diathesis
Recent (<10 days) gastrointestinal bleeding
Neurosurgery (intracranial or spinal) within last 3 months
Intracranial trauma within last 3 months
Intracranial malignancy or metastasis

Relative major contraindications

Cardiopulmonary resuscitation within last 10 days
Major nonvascular surgery or trauma within last 10 days
Uncontrolled hypertension (>180 mmHg systolic or > 110 mmHg diastolic)
Puncture of noncompressible vessel
Intracranial tumor
Recent eye surgery

Minor contraindications

Hepatic failure, particularly with coagulopathy
Bacterial endocarditis
Pregnancy
Diabetic hemorrhagic retinopathy

involved artery. Limb circulation may be restored either by emergency embolectomy or by thrombolytic therapy.

2. Embolectomy

Embolectomy is treatment of choice for acute embolism (PGME). The operation can be performed under local, regional or general anesthesia, the artery bulging by clot is exposed, and a small longitudinal incision is made over it after placing a vascular clamp. Clot begins to come out through the incision line and is removed together with the embolus, then the artery is closed by Continuous suture with proline. (5-0 or 6-0; a very thin suture). Please see figure 23.5

3. Thrombolytic therapy

By stimulating the plasmin system, thrombolytic agents brings about lysis of fibrin, and causes the dissolution of the clot. The three commonly used agents are:

(i) Streptokinase (a bacterial enzyme)

(ii) Urokinase (extracted from renal parenchymal cells)

(iii) Tissue plasminogen activator (TPA manufactured synthetically). Please see key box 23.12

Contraindication to thrombolytic therapy include

(i) An intracerebral lesion or a recent stroke

(ii) Pregnancy,

(iii) Recent surgery,

(iv) Previous history of GI bleed and allergy to the drug.

Please read key box 23.13 carefully.

Complication of thrombolytic therapy

Include anaphylaxis and bleeding, which should be treated by stopping the drug immediately, and giving fresh frozen plasma, blood transfusion and epsilon amino caproic acid.

****

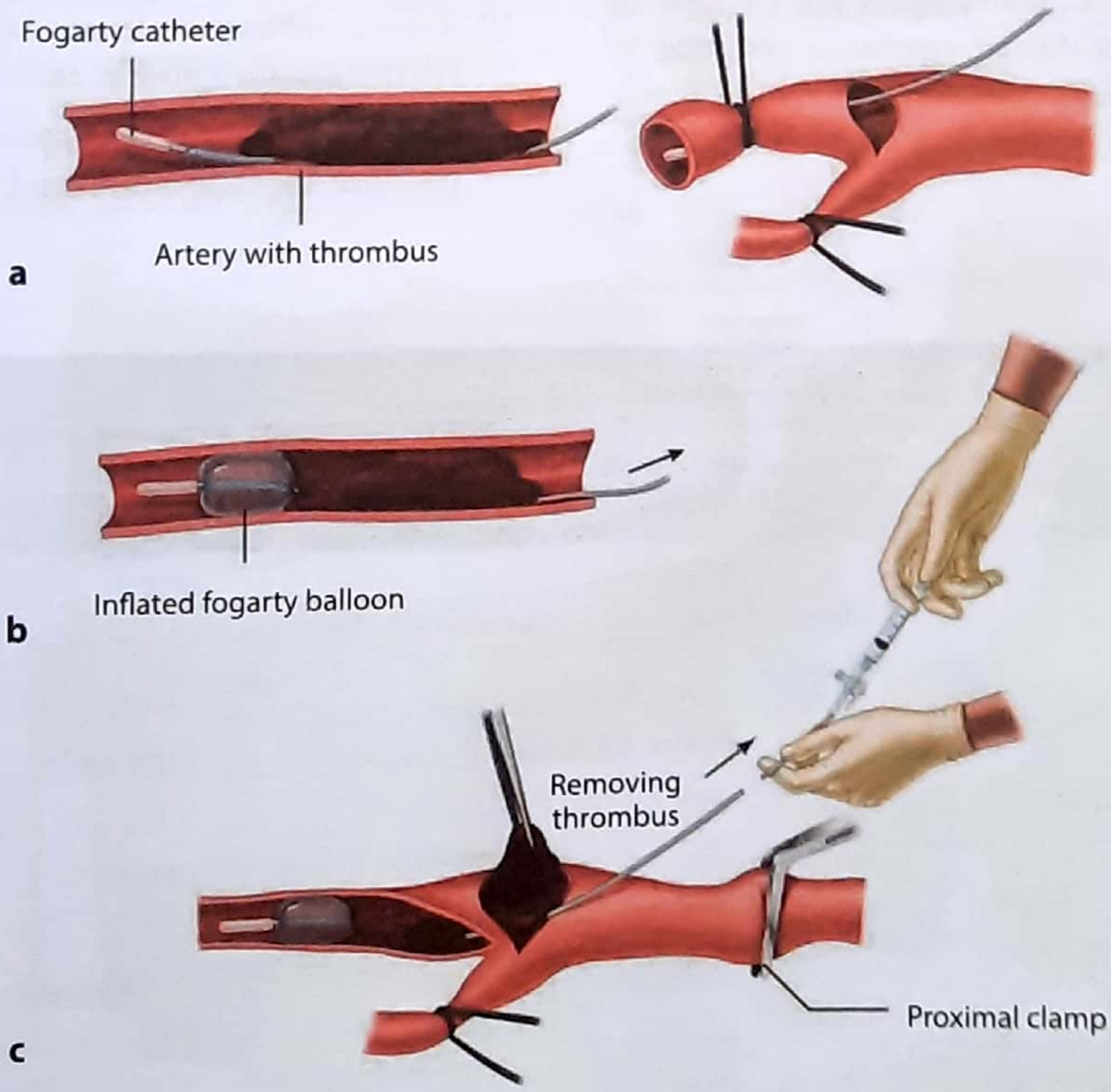

Figure 23.5 : Embolectomy

VASOSPASTIC DISORDERS

Raynaud's Phenomenon (AI 03)

This is characterized by episodic attacks of *vasospasms* resulting in closure of the arterioles of most distal parts of **extremities in response to cold (M/C) and/or emotional stress** (NEET).

Because only terminal arterioles are affected, and arteries are not affected hence the peripheral pulses are normally palpable. Raynaud's phenomenon is characterized by the following three stages in that sequence, having abrupt onset precipitated by cold or emotional stress.

Stage I: Pallor (local syncope)

Pallor or blanching is due to spasm of small arterioles. The limb becomes cold and turn pale.

Stage II: Cyanosis (due to asphyxia)

The limb becomes swollen and turns blue due to accumulation of deoxygenated blood and metabolites in the dilated capillaries.

Stage III: Rubor (Redness, red engorgement)

The subsequent arterial relaxation leads to flow of oxygenated blood into dilated capillaries resulting in hyperaemia which manifests as redness (rubor). Please remember with help of key box 23.14.

KEY BOX 23.14

Raynaud's Phenomenon

(P → C → R = PCR)

Pallor (White)

↓

Cynosis (Blue)

↓

Rubor (Red)

Two varieties of Raynaud's phenomenon are recognized depending upon etiological causes:

1. Primary (or idiopathic) Raynaud's phenomenon

It is **termed as *Raynaud's disease,*** where in actual pathology is commonly not known! It usually occurs in young women affecting finger tips of both the hands.

2. Secondary Raynaud's Phenomenon

This is associated with *some identifiable causes, such* as:

(i) *Arterial obliteration lesion:* Atherosclerosis, Buerger's disease, thrombosis, embolism, cervical rib.

(ii) *Nervous lesion:* Cervical spondylitis, cervical disc prolapse, thoracic outlet syndrome.

KEY BOX 23.15

PRIMARY VS SECONDARY RAYNAUD'S PHENOMENON

Characteristics	Primary	Secondary
Associated diseases	No	Yes
Age at onset	Younger (<30)	Older (>30)
Nail fold capillaries	Normal	Large tortuous
Autoantibodies	Negative to low	Frequent
Endothelial cell activation	Yes	Yes
Endothelial damage	No	Frequent
Occlusions	No	Yes
Digital gangrene	Rare (superficial)	Common
α2 adrenergic activity	High	High
Calcitonin gene-related peptide	Low	Low

(iii) *Systemic disease:* Hypothyroidism, Diabetes mellitus, malnutrition, Collagen disease, SLE, Scleroderma.

(iv) *Occupational hazards:* Cold exposure, drill machines.

(v) *Miscellaneous:* Neoplasm, chilblains, frost bite, ergot poisoning.

Treatment

The patient should be explained and reassured that this disease is usually mild and self limiting.

General measures

Cessation of smoking and avoidance of cold is very important. Patient should be advised to wear gloves.

- Oral contraceptives, beta blockers and ergot preparation are contraindicated. *(PGME)*

Drug therapy

For moderately severe cases nifedipine, diltiazam are useful. Other drugs used are:

- Pentoxyfylline
- Intraarterial reserpine may be useful in severe cases.

Surgery

Cervicodorsal sympathectomy:

The role of cervicodorsal sympathectomy is doubtful, It may be tried in patient with digital ulceration.

OTHER VASOSPASTIC DISORDERS

1. Acrocyanosis

It occurs exclusively in women. Patient presents with edema, coolness, and cyanosis of hand; leg and feet due to cutaneous vasospasm.

2. Frostbite

This is due to exposure of the foot to extreme cold and windy condition, usually at high altitudes. Most of the effect of frost bite arises not from direct damage to tissue by cold but from vascular reaction during **warming**.

Treatment is rewarming with 42°C water.

3. Chilblains (Erythema Pernio)

This is due to the *abnormal sensitivity of capillaries of skin and subcutaneous tissue to cold, leading to development of edema and vasospasm. It commonly affects children and young adult female.* *(NEET)*

4. Trench Foot (Immersion foot)

It is a condition resembling frostbite affecting the feet of soldiers who are obliged to keep their feet in cold wet socks for prolonged period. The condition is predisposed by tight clothing or ill fitting boots.

Also know

Erythromelalgia

Opposite of Raynaud's disease in this condition, heat provokes an attack and the patient seeks relief with cold water. It is ***vasodilatory*** condition (cf; Raynaud's disease; a *vasospastic* condition).

****

GANGRENE

Gangrene is the condition where there is macroscopic death of a part of the body or an organ with super added putrefaction and loss of function. Classically there are **five criteria;**

- Loss of arterial pulsation
- Loss of temperature
- Loss of sensation
- Loss of colour
- Loss of function

Remember this with this FACT:

Clinical criteria of gangrene; Mnemonic = loss of **FACTS**

- Loss of **F**unctions
- Loss of **A**rterial pulsation
- Loss of **C**olour
- Loss of **T**emperature
- Loss of **S**ensation

Clinical Types

1. Dry gangrene

There is slow and gradual arterial occlusion, while the veins remain open and as a result of which; tissues are drained and become desiccated (dried and mummified).

- There is no infective process.

Figure 23.6: Dry gangrene of distal foot

Figure 23.7: Wet gangrene

- The affected part look dry, mummified due to desiccated as a result of gradual slowing of circulation.
- The skin is wrinkled and in early stage look greasy.
- There is no smell.
- Later due to hemolysis the colour becomes greenish and finally black due to formation of black iron sulphide. Fig 23.6. (Notice line of demarcation).

Line of demarcation

A bright red line of demarcation appears within few days between the living and dead tissue, where the blood supply to former is good. This is the zone of inflammatory reaction due to contact of the dead with the living tissue.

2. Wet gangrene

Moist gangrene occurs when venous as well as arterial obstruction to the tissue is present, when the artery is suddenly occluded, as by injury or ligation of both the artery and the vein or embolus and in diabetes. Wet gangrene may also develop due to infection in a dry gangrene.

- The principal difference between dry and wet gangrene is that in later, there is also stasis of venous blood and much bacterial infection in later. The venous occlusion increases the exudate which cannot be dried up. Please read key box 23.16. carefully and see figure 23.7.

KEY BOX 23.16

Differentiation of Dry And Moist (Wet) Gangrene

Features	Dry Gangrene	Wet gangrene
Onset	Gradual	Rapid
Local signs		
Colour	Dry, black, mummified	Purplish, moist with blisters
Line of demarcation	Well defined	Absent or ill defined
Sepsis	Mild or none	Gross with putrefaction
Malodour	Minimal	Stinking smell
Toxic Signs	Usually absent	Usually present
Etiology	TAO, Raynaud's disease etc.	Diabetes, embolism etc.
Mechanism	Slow arterial obstruction	Arterial venous obstruction or sudden arterial obstruction

KEY BOX 23.17

Gangrene

↓

Causes

↓

TIPS

Trauma

Infection

Carbuncle

Cellulitis

Erysipelas

Physiological agents

A - Acid

B - Base and burn

C - Cold (**frost bite** and Chemical)

D - Diathermy

E - Electric

Secondary causes

RESTED

R - Raynaud's disease

E - Embolism

S - Senile (old age)

T - **Thrombus**

E - Ergot

D - Diabetes

Burger's disease (NEET)

Atherosclerosis (NEET)

Pregangrene Stage

This is a stage, when the blood supply to that part is so precarious that it will soon be inadequate for tissue to be alive. This stage is characterized by **'CHOR'.**

C - Colour change

H - Hyperesthesia

O - Oedema (edema)

R - Rest pain

Causes of Gangrene (TIPS)

T - Trauma

I - Infection

P - Physical agents

S - Secondary causes

I have made a funny flow chart for you (See key box 23.17)

Management

There are certain basis facts which should be taken under consideration.

- A limb saving attitude is needed in cases of gangrene affecting upper limb.
- A life saving urgent amputation is essential for broadly crushed limb, and rapidly spreading gangrene.
- For a patient of senile or an embolic gangrene, the treatment must also include that of heart failure or atrial fibrillation (if present).

****

AMPUTATION

Amputation is a procedure where in a part of the limb is removed through one or more bones. It should be distinguished from disarticulation where in a part is removed through a joint.

Indication

Over all injury is the commonest cause for amputation in developing countries. The injury may be sustained in road traffic accident, or in upper limb by chopper or thrasher machines. The common indications for amputation are given below.

- Injury
- Peripheral vascular disease ie; ASO, Buerger' s disease etc.
- Life threatening infection
- Gangrene
- Nerve injuries

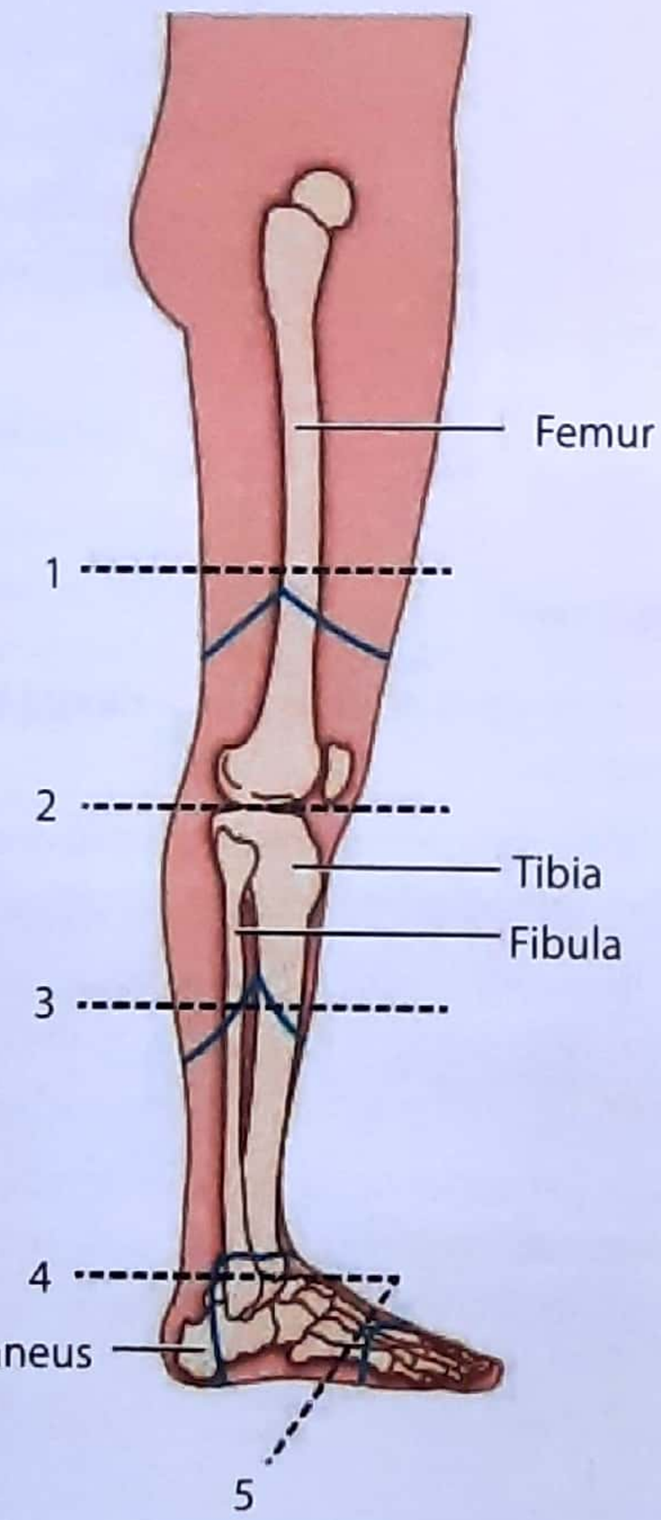

1. Above knee (transfemoral)
2. Through knee (knee disarticulation - Gritti Stokes)
3. Below knee (transtibial)
4. Ankle (ankle disarticulation - symes)
5. Forefoot (transmetatarsal)

Figure 23.8: Various amputation

Types

1. Guillotine or open amputation

It is a type of amputation where the *skin wound is not closed* over the amputated stump. It is usually done when the wound is not healthy.

- A second operation is done some days later to close the stump; once the infection has been controlled.

2. Closed amputation

Where the skin is closed primarily, ie; at the time of operation.

Procedures

1. *Digital amputation*, transects the proximal phalanx and is associated with minimal gait disturbance.
2. *Ray amputation* refers to the amputation of a single digit and its metatarsal head, and is associated with minimal gait disturbance.
3. *Trans- metatarsal amputation* refers to the amputation of the forefoot, transecting the five metatarsal bones mid-shaft, with a posteriorly based flap. There is minimal gait disturbance postoperatively.
4. *Syme's amputation:* This is done through the ankle joint. Trauma to the forefoot with good vascularity of heel and ankle are chief indication of this procedure.
5. *Below-knee amputation* transects the tibia and fibula a palm's breadth below the tibial plateau, with coverage achieved by a longer posterior flap. Ambulation (walking) with a unilateral below knee amputation can be achieved in 70%-100% of patients.
6. *Above-knee amputation* transects the femur at the distal third of the shaft. The anterior and posterior flaps are generally equal. Ambulation (walking) with a unilateral above knee amputation can be achieved in 10%-40% of patient.

****

ARTERIAL ANEURYSMS

Arterial aneurysm is defined as permanent dilatation of an artery of more than 1.5 times the normal diameter.

Classification

(a) Depending upon shape

Fusiform - Generalized dilatation of the artery.

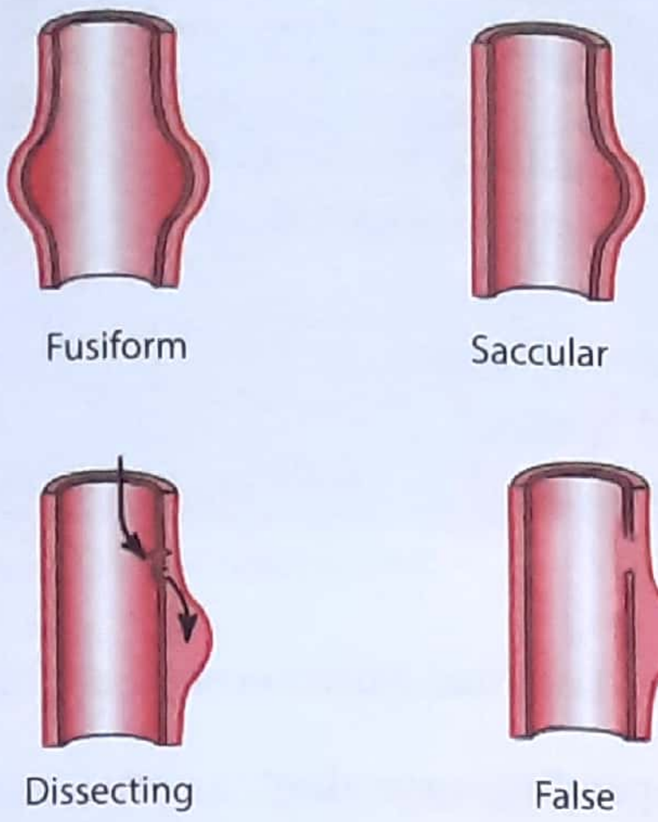

Figure 23.9 : Types of arterial aneurysm

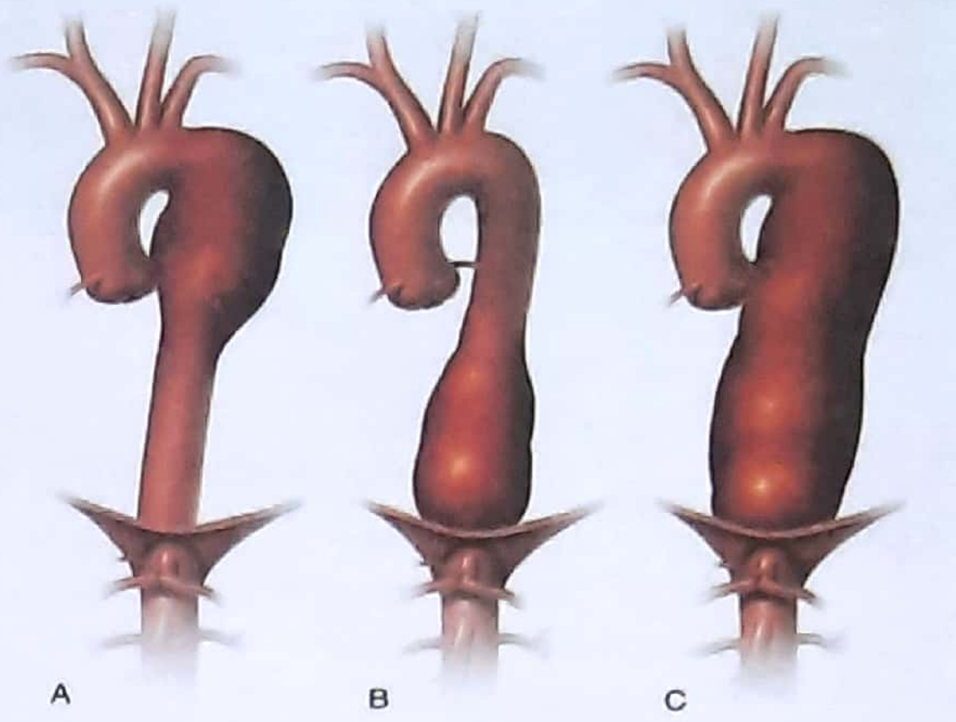

Figure 23.10 : Classification, descending thoracic aortic aneurysm, (A) Type A, distal to the left subclavian artery to the sixth intercostal space (B) Type B, sixth intercostal space to above diaphragm (twelfth intercostal space) (C) Type C, entire descending thoracic aorta, distal to the left subclavian artery to above the diaphram (twelfth intercostal space)

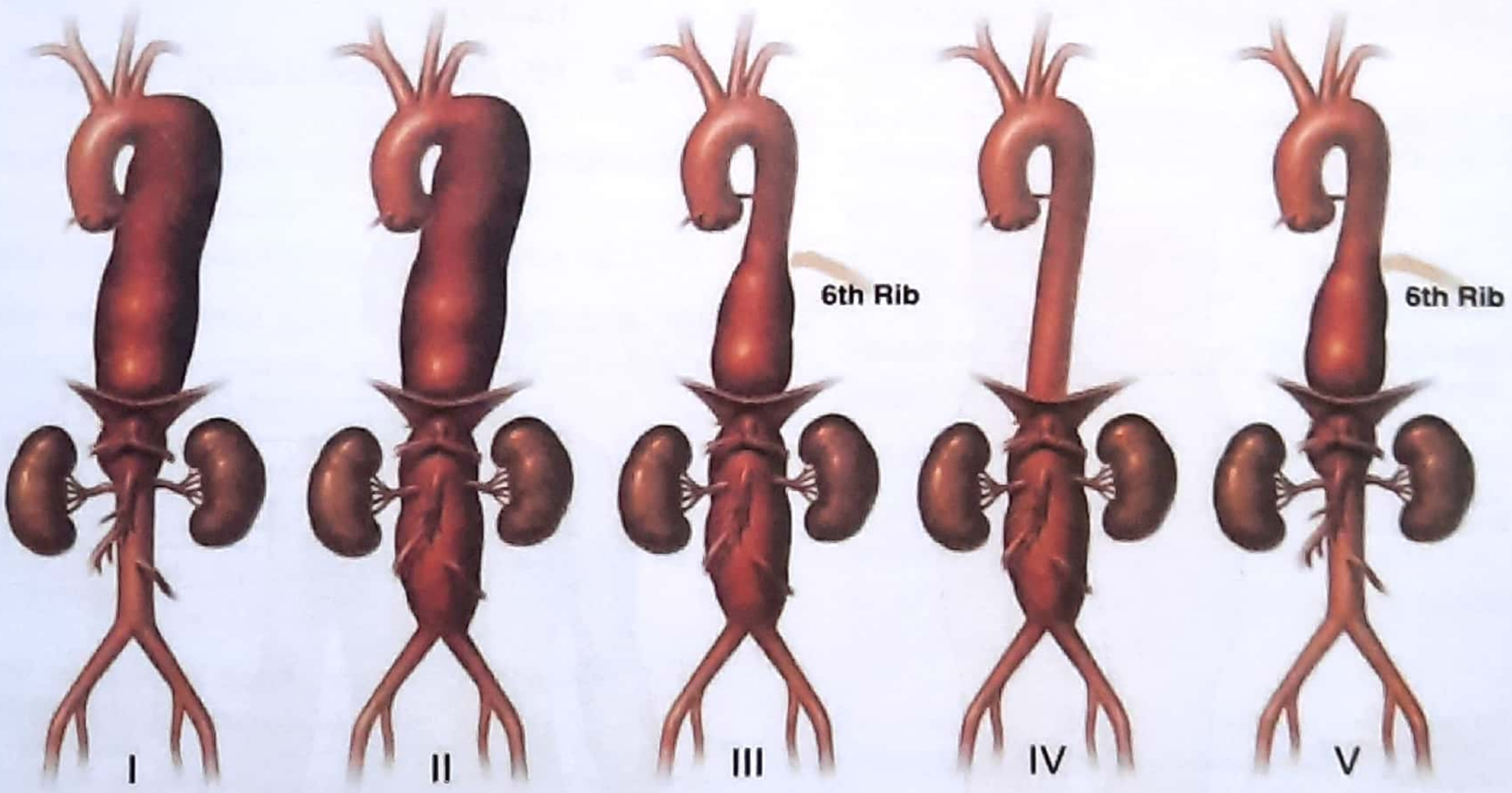

Figure 23.11 : Normal thoracoabdominal aorta aneurysm classification. Extent I, distal to the left subclavian artery to above the renal arteries; Extent II, distal to the left subclavian artery to below the renal arteries; Extent III, from the sixth intercostal space to below the renal arteries; Extent IV, from the twelfth intercostal space to the iliac bifurcation (total abdominal aortic aneurysm); Extent V, below the sixth intercostal space to just above the renal arteries (modified Crawford classification).

KEY BOX 23.18

Risk factors for aneurysm development, expansion, and rupture.

SYMPTOM	RISK FACTORS
AAA development	Tobacco use Hypercholesterolemia Hypertension Male gender Family history (male predominance)
AAA expansion	Advanced age Severe cardiac disease Previous stroke Tobacco use Cardiac or renal transplantation
AAA rupture	Female gender ↓ FEV_1 Larger initial abdominal aortic diameter Higher mean blood pressure Current tobacco use (length of time smoking >> amount) Cardiac or renal transplantation Critical wall stress- wall strength relationship

*AAA : Abdominal aortic aneurysm

KEY BOX 23.19

Peripheral Arterial Aneurysm *(PGME)*
(in decreasing order of frequency)

- **Popliteal artery (M/C site** *(NEET, AIIMS 08)*)
- Femoral artery
- Subclavian artery
- Axillary artery
- Carotid artery

Saccular - Localized dilatation of the arterial wall.

(b) Depending upon size

Macro aneurysm, Micro aneurysm

(c) Depending upon structure

(i) ***True*** The aneurysm *has all the layers* of an arterial wall.

(ii) ***False*** **(Pseudo-aneurysm)** (most common cause): *All layers of the arterial wall are not present.* Diagnosis can be assumed if there is:

- History of trauma, drug abuse
- Sudden appearance of pulsatile swelling after trauma
- MC site is Femoral artery *(PGI 08)*

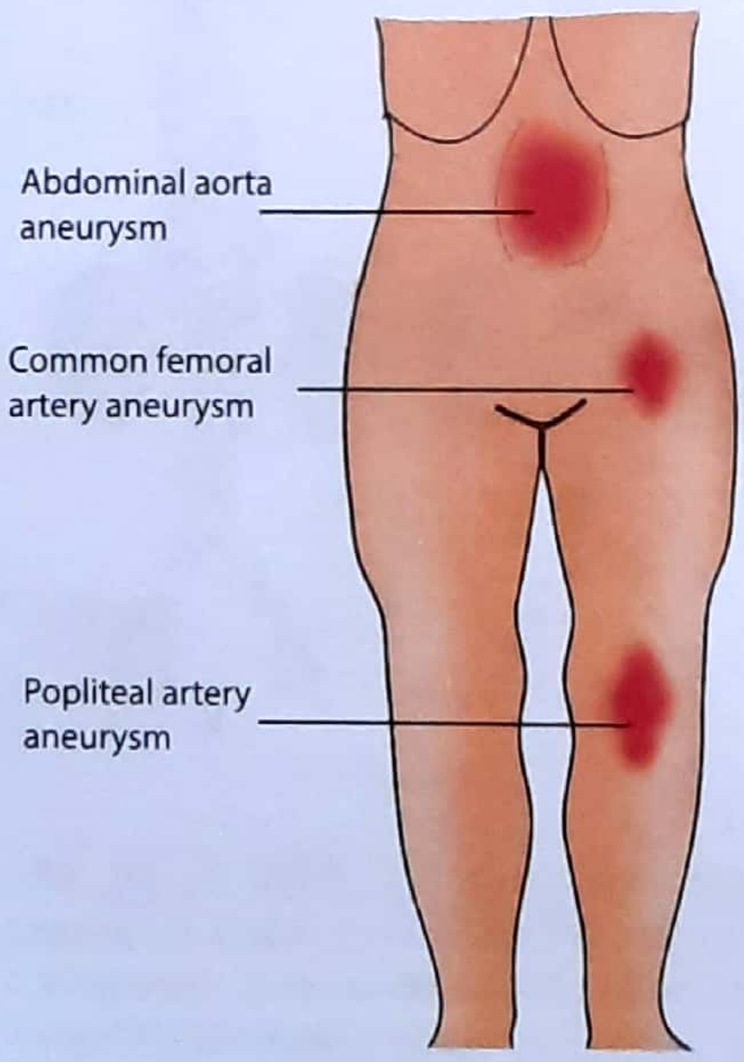

Figure 23.12 : Common sites of aneurysm

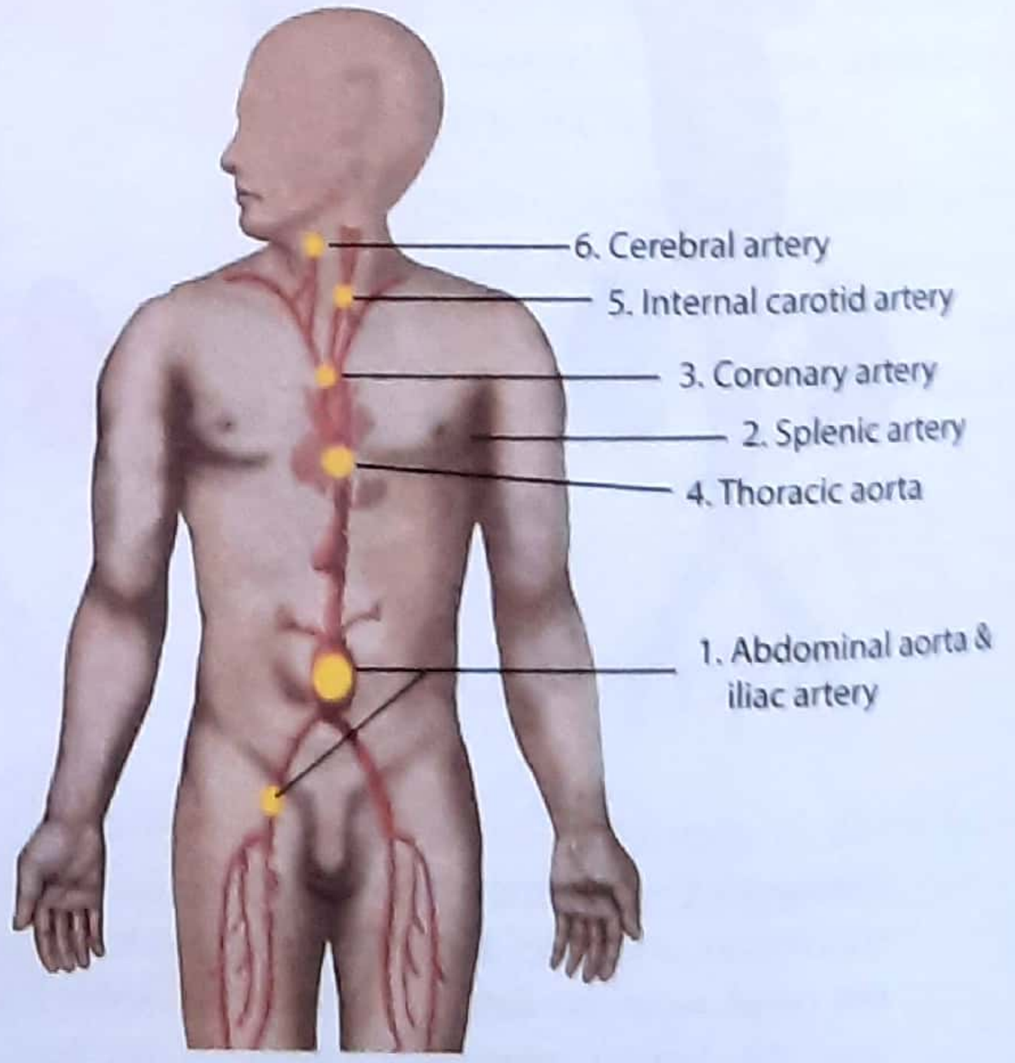

Figure 23.13 : Sites of arterial aneurysm; numbered in order of frequency

(iii) ***Dissecting:*** Tear in the intima separates the layers of arterial wall creating a true and a false lumen.

(d) Depending upon location

Central - Involving aorta

Peripheral - Involving peripheral arteries

Visceral - Involving visceral arteries

Cerebral - Involving cerebral arteries

Also see figure 23.10, 23.11 on page 305.

Etiology

1. *Atherosclerosis (90%):* This is *now the most common cause of arterial aneurysm.* It account for more than 90% of all arterial aneurysm. (AL 96, DELHI 89, JIPMER 80, AI 10)
2. *Nonspecific aorto-arteritis*: It is second most common cause of aneurysm. These include Takayasu arteritis, SLE and polyarteritis nodosa.
3. *Mechanical*: This include trauma and arterial puncture.
4. *Infective:* Infective causes are bacterial (mycotic) or syphilitic (luetic) and fungal.
5. *Connective tissue disorder:* Marian's syndrome

Clinical feature

- Most abdominal aortic aneurysm are **asymptomatic** and are detected incidently during routine physical examination or radiological investigation, eg; USG.
- **Pain** in an aneurysm *is an ominous symptom, and* indicate a rapid increase in the size, erosion of adjacent bone or an impending rupture.
- *The aorta is most common site for aneurysm*, and abdominal aorta *(descending aorta below renal artery)* **is** *most common site, followed by splenic artery* (NEET, PGI 88, PGME MANY TIMES). Fig. 23.13
- Aortic aneurysms most commonly rupture into left retroperitoneum. (AI 09)
- *Peripheral arterial aneurysms* are less common than aortic aneurysm. In *descending order of frequency these aneurysms occurs in popliteal, femoral, subclavian, axillary and carotid arteries* (SCTIMS 98, AIIMS).
- The aneurysms involving brachial, radial, ulnar, profunda femoris, tibial & peroneal arteries are uncommon.
- *Commonest presenting symptom of a peripheral aneurysm is dull aching pain and a pulsatile swelling.*

Treatment

- The presence of an aneurysm of 5 cm or more in diameter is a definite indication for surgery.

Aim of surgery

- The ***aim of surgery*** is to eliminate the risk of rupture and to relieve symptoms (Although aneurysm of any size can rupture, the *risk of rupture increases steeply, when the aneurysm is 6 cm or more in diameter)* (DELHI 96).

Indication

- AAA (Abdominal aortic aneurysm) → >5.5 cm
- Ascending thoracic aorta >5.5cm
- Descending thoracic aorta > 6cm
- Popliteal artery aneurysm > 2-3cm
- Any symptomatic aneurysm

Operative options

1. ***Arterial ligation:*** This is now obsolete. (Huntarian Ligature)
2. ***Wiring of aneurysmal sac***
3. ***Wrapping of the aneurysmal sac:*** A strip of fascia lata, Cellophane may be wrapped around the aneurysmal sac to strengthen its wall and prevent rupture.
4. ***Excision and Grafting:*** This is most popular operation and is commonly performed. Dacron graft* or autogenous vein may be used for grafting. *Dacron is best material for aortic graft.* (DELHI 97, 92, JIPMER 81, PGME MANY TIMES) . **Ideal material for femoropopliteal bypass, is reverse saphenous vein** (NEET).
5. ***Excision and end to end suturing (anastomosis):*** This is only possible in case of peripheral aneurysm, where in the aneurysm is excised and cut ends of an artery/ aorta are mobilized and approximated for end-to-end anastomosis.

DACRON GRAFT? It is a synthetic textile material used to replace normal body tissue. It is usually made in tubular form to replace or repair blood vessels, aortic aneurysm. The graft causes very low reaction, because it is chemically inert, harmless, and easily tolerated by body.

****

Aortic Dissection

A tear in intimal layer and blood enters between intima and media layer of aorta.

Risk factors

- Hypertension (most important)
- Connective tissue disorder
- Vascular inflammation
- Disruption of intima and media

Genetic factors

- Marfan's syndrome
- Loeyes - Dietz syndrome

Clinical feature

- Earliest symptom is chest pain
- Myocardial infarction
- Renal failure
- Pleural effusion (left)

Investigation

- If patient is stable; investigation of choice is CT-angiography.
- In unstable patient, Investigation of choice is transesophageal echo-cardiography.

Classification :

Please see figure 23.15 for better understanding.

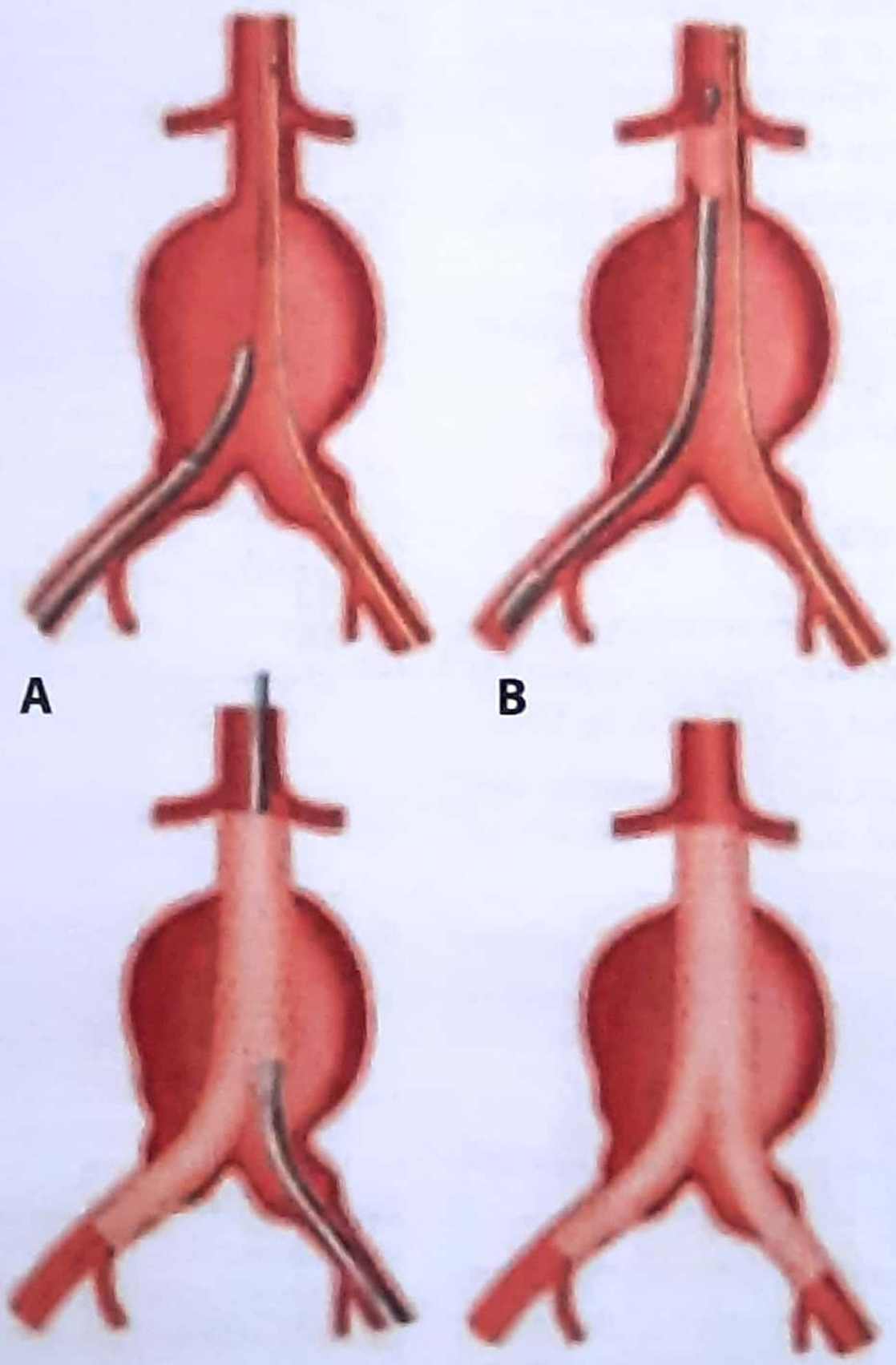

Figure 23.14 : (A) During an endovascular aortic aneurysm repair, the main endograft device is inserted through a femoral artery approach. (B) The device is deployed in the aorta just below the renal arteries. (C) A contralateral iliac endograft device is inserted through a contralateral gate opening, which is next deployed. (D) Completion of deployment of the endograft device should fully exclude an aortic aneurysm while preserving flow of the renal and hypogastric arteries.

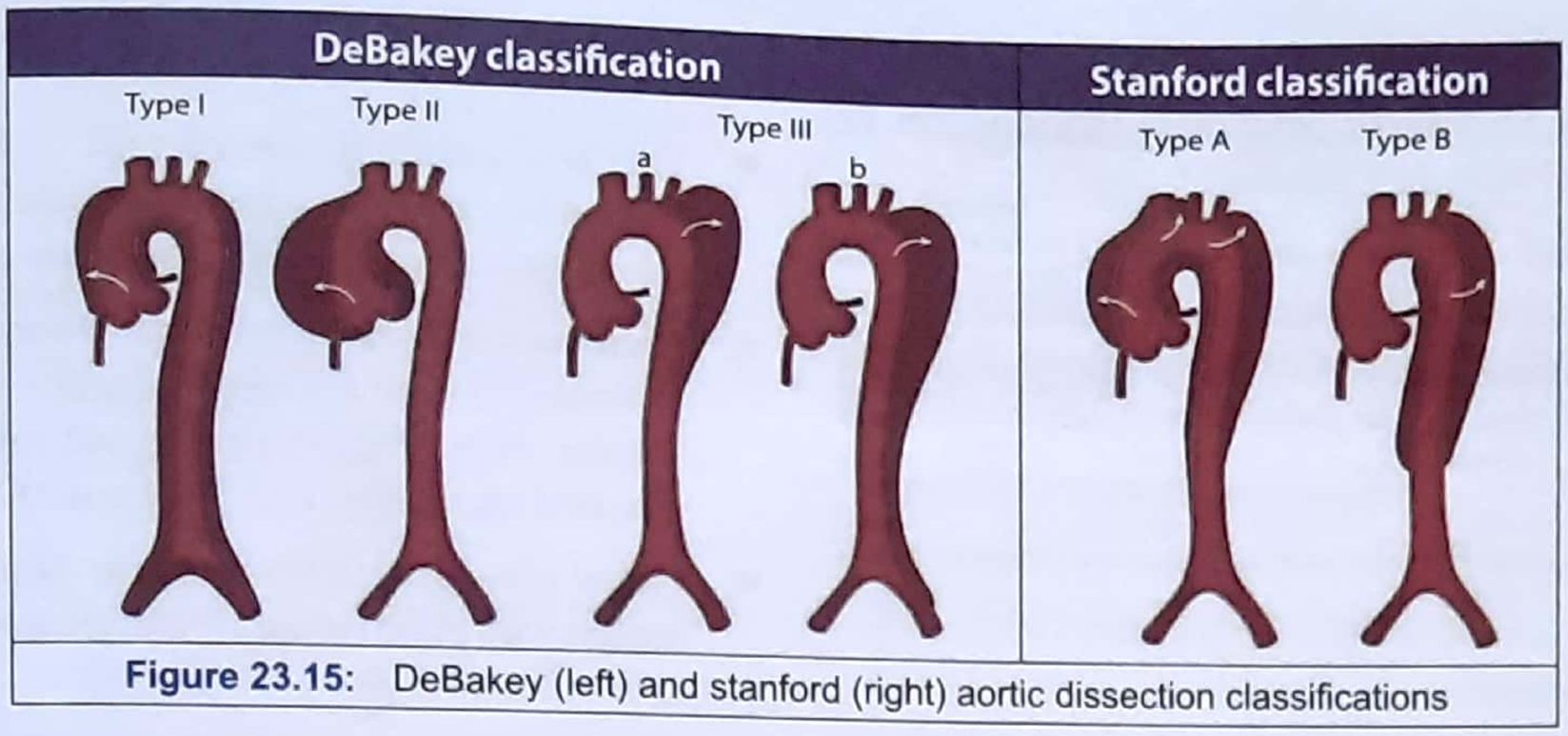

Figure 23.15: DeBakey (left) and stanford (right) aortic dissection classifications

Management

1st line dry
short acting β blocker (esmolol)
↓
For Permissive hypotension

In DeBakey I, II
↓
Surgery
(Dacron Graft Repair)

In DeBakey III
↓
Monitor
↓
If Deterorating
↓
Surgery

DACRON GRAFT? It is a synthetic textile material used to replace normal body tissue. It is usually made in tubular form to replace or repair blood vessels, aortic aneurysm. The graft causes very low reaction, because it is chemically inert, harmless, and easily tolerated by body.

****

ARTERIO-VENOUS FISTULA

An arterio venous fistula (A-V fistula) is an **abnormal direct connection between an artery and a vein.** A-V fistula may be congenital or acquired due to penetrating traumatic injury, the *latter* is by far more common. *(PGME, AI 06)*

Etiology

1. Congenital developmental defect
2. Rupture of arterial aneurysm into the adjacent vein.
3. Penetrating injuries that pierce the wall of the artery and vein producing communication.
4. Inflammatory necrosis of adjacent vessels.
5. Iatrogenic: Created for dialysis in forearm and legs of the patient.

Effects due to A-V fistula

1. Structural effects

(i) Veins become *dilated tortuous and thick walled,* due to transmission of high pressure in artery to the vein (arterialized vein) *(AI 01)*

(ii) The lesion, particularly the congenital variety may be diffused, and the surgery may be difficult or impossible.

(iii) The congenital variety may lead to overgrowth of the part; known as *local gigantism* *(AIIMS NOV 01)*

2. Physiological effects

(i) There is an arteriovenous shunt.

(ii) The effects are due to leak of high pressure arterial circulation into vein, thus increased venous return. *(PGME)*

(iii) There is tachycardia and increased cardiac output. Left ventricle enlarges leading to cardiac failure. *(AI 01)*

(iv) *In large fistula pulse pressure is high.*

Clinical Feature

- A-V fistula *presents as a compressible, pulsatile swelling. Overlying skin has raised temperature and dermal pigmentation is present.*

- Local thrill and audible thrill are present.
- A typical continuous machinery murmur can be heard over most A-V fistulae.
- **Nicoladoni Branham's sign** *(AI 02, PGI, DEC 98)* Occlusal pressure on the artery *proximal* to the fistula leads to reduction in the size of the mass, cessation of thrill and bruit, and **fall in pulse rate (Bradycardia) and pressure.** *(AIIMS 08)*

NOTE: Remember with Branham's sign of Bradycardia. (Bra sign of Bra)

Treatment

The treatment of multiple small, congenital A-V fistulae may be impossible. Surgical exposure and disconnection of an AV fistula needs considerable surgical skills. Endovascular surgery using a stent is often the treatment of choice.

Cirsoid aneurysm

An AV connective over scalp/face treated by surgical resection or occlusion. (Figure 23.16)

****

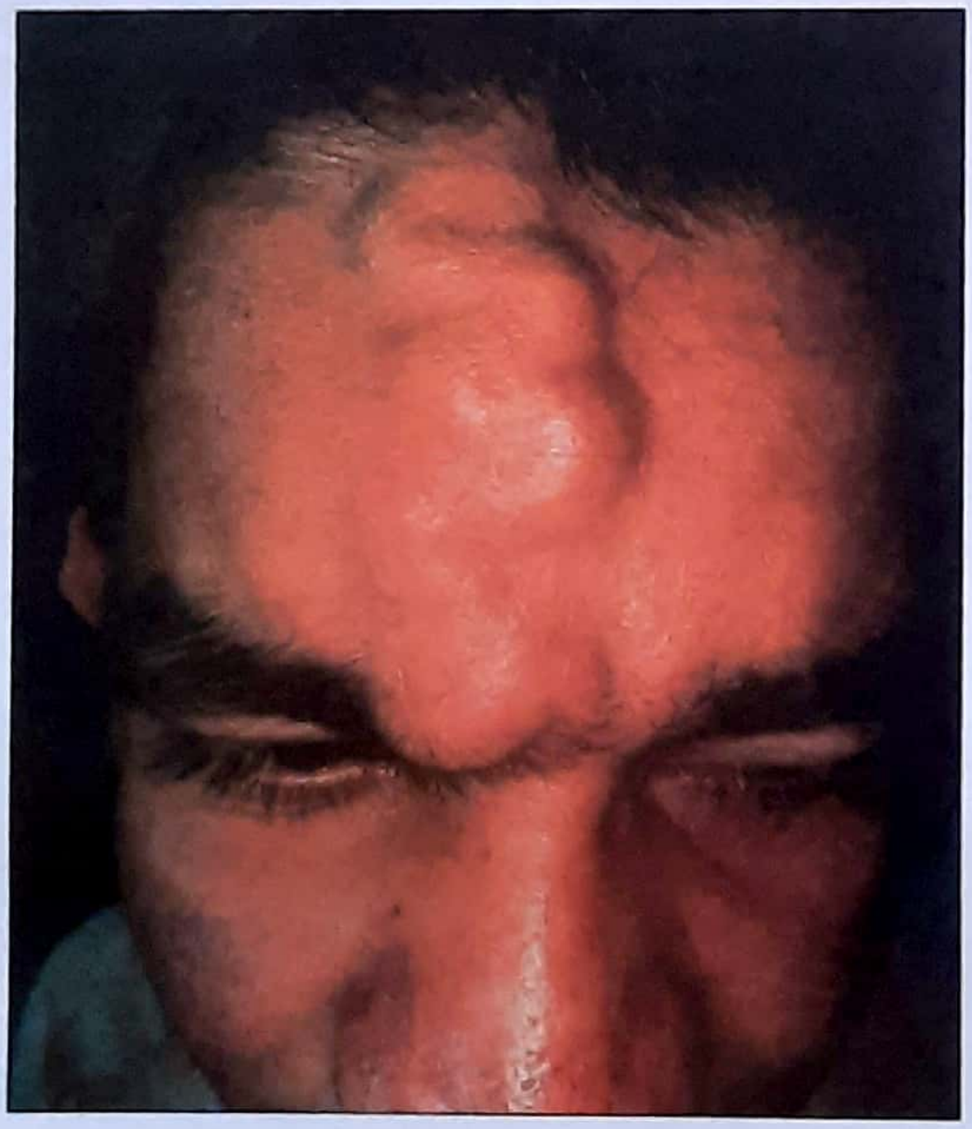

Figure 23.16 : Cirsoid aneurysm

SUB-CLAVIAN STEAL SYNDROME

- This is a condition characterized by the development of neurological symptoms viz; clouding of consciousness, upon exercise of the upper extremity.
- There occurs proximal occlusion of subclavian, with reversal of flow to the vertebral artery ie; the blood is stolen from subclavian artery and passed into the vertebral artery [figure 23.17(a) and 23.17(b)].
- Patient often gives history of arm claudication. On examination pulse rate and blood pressure is reduced in the affected arm.
- Duplex scanning and digital subtraction angiography (DSA) will confirm the diagnosis.
- In symptomatic patients, percutaneous angioplasties and/or a bypass may improve the symptom.

Thoracic outlet syndrome

- This syndrome is caused by compression of brachial plexus or subclavian vessels in the region of thoracic inlet. It most common affects 20-45 yrs age person.

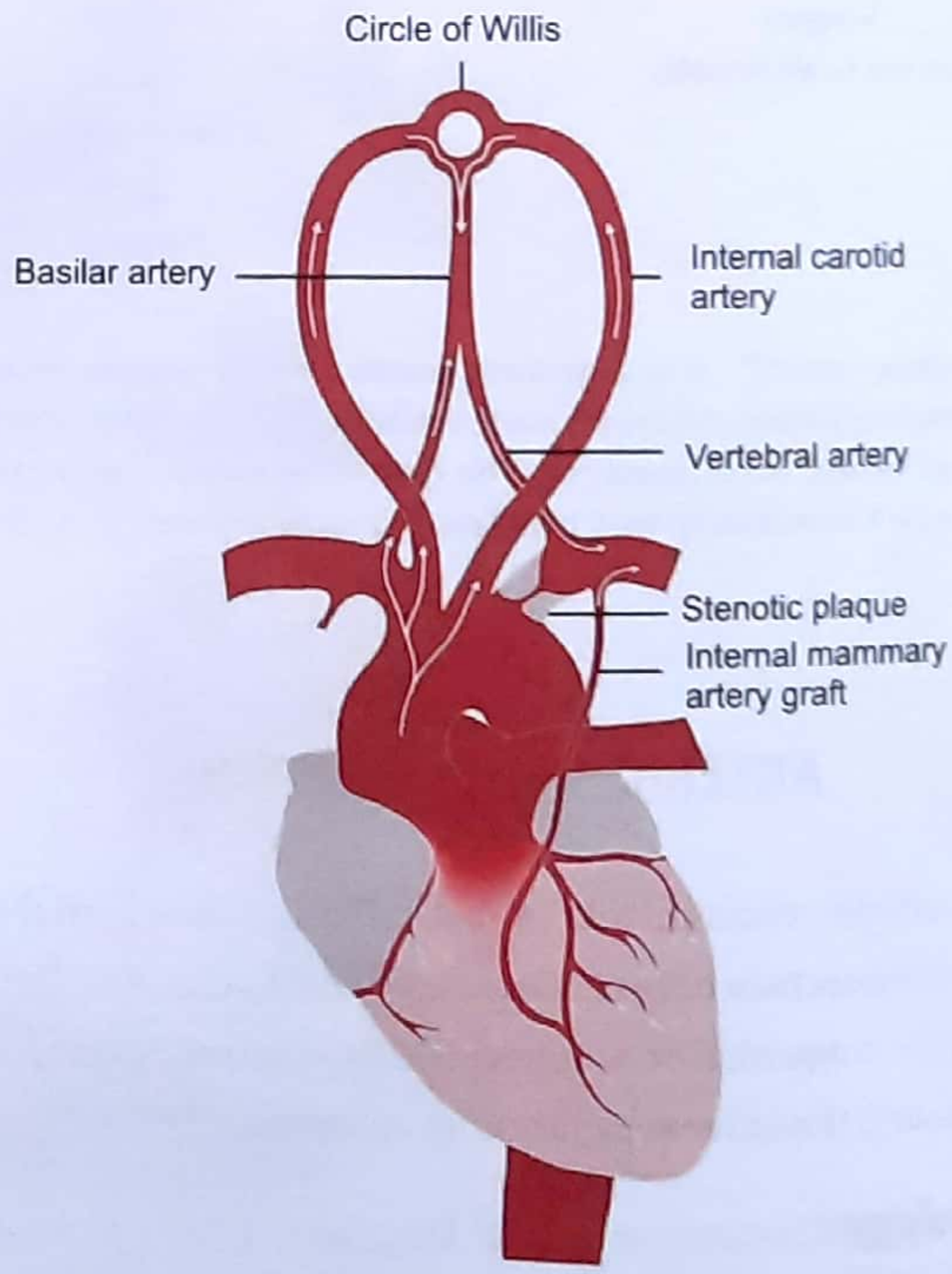

Figure 23.17(a) : Direction of blood flow in Subclavian steal syndrome

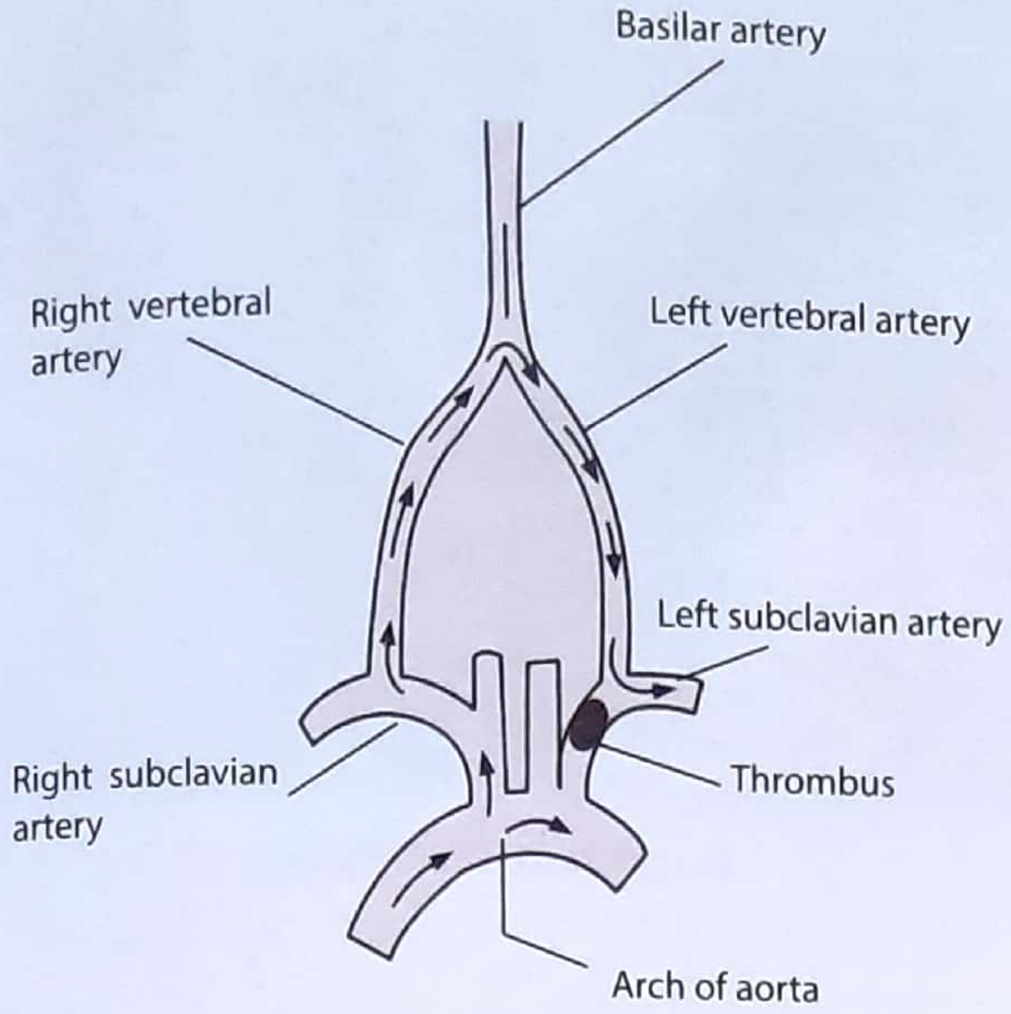

Figure 23.17(b) : Direction of blood flow in Subclavian steal syndrome

Cause

- Bone - cervical rib, ab(n) first rib, long transverse process of C7.

Muscle - Scalenus

Trauma - Neck hematoma, clavicular fracture.

Tumor

Arthritis

Clinical feature

If subclavian artery compressed

↓

Decreased pulse, Embolic phenomenon

Subclavian vein compressed → Swelling of limb

Brachial plexus compressed → Ulnar nerve (MC)

↓

Pain, paraesthesia and numbness usually in the finger & hands in ulnar nerve distribution

Tests

1. Adson test

- Affected arm is abducted 30° at the shoulder while maximally extended. While extending the neck and turning head towards I/L shoulder, patient inhales deeply. (Figure 23.18)

Figure 23.18 : Adson test

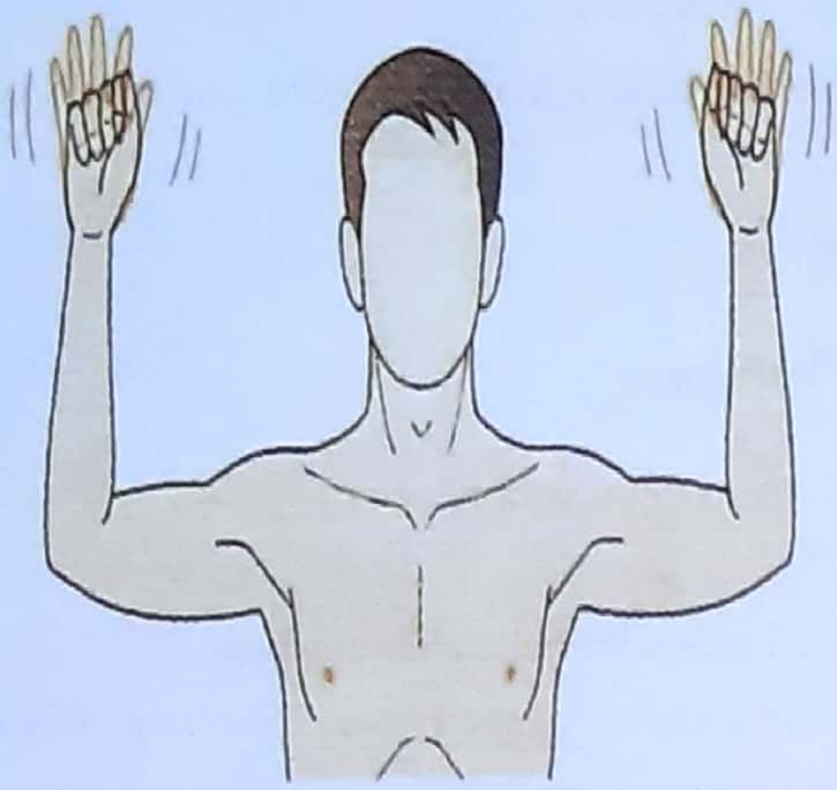

Figure 23.19 : Roos test

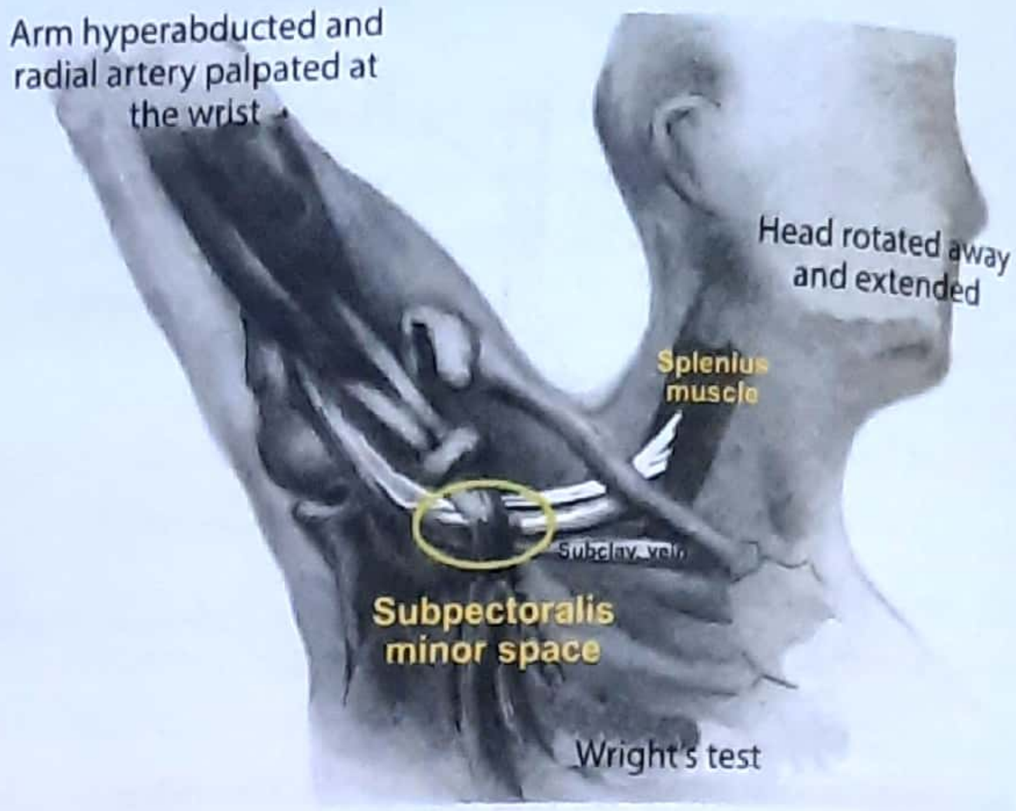

Figure 23.20 : Writht's test

- Decrease or absent radial pulse.

2. Roos test

- Arms are placed in surrender position with shoulders abducted 90° and in external rotation, with elbow flexed at 90°. Patient slowly opens & closes hand for 3 min.

3. Wright hyperabduction test

- Patients arm is hyperabducted.
- Patients symptoms are aggrevated.
- Investigation of choice is CT angiography.
- Cervical rib resection, however most respond to physiotherapy.

Management

- If cervical rib is present resection is done. However, majority of cases respond to physiotherapy.

****

Sample Questions for Prof Examination

1. How would you investigate a patient of peripheral vascular disease.
2. Discuss intermittent claudication. How will you investigate a case of this condition in a man of 45 years and brief out management.
3. What are the causes of chronic peripheral vascular insufficiency. Discuss Buerger's disease.
4. Enumerate causes of gangrenes.
5. Classify chronic peripheral vascular insufficiency. Discuss Buerger's disease.
6. Discuss the clinical picture, investigations and treatment of a chronic smoker suffering from pain in lower limb after walking.
7. **Write short notes on:**

   Raynaud's phenomenon

   Thromboembolism

   Raynaud's disease.

24 Venous Disorder and Lymphedema

Contents

- Varicose vein
- Venous thrombosis
- Pulmonary embolism
- Lymphedema

VENOUS DISORDER

Venous disorders mostly affect the lower limb. It is therefore very important to understand the surgical anatomy of the venous system in the limbs, which is discussed below.

CEAP classification of chronic venous disorders

1. Clinical classification

C0 → No signs of venous disease

C1 → Telangiectasia or reticular veins (1-3 mm)

C2 → Vancose veins (>3 mm)

C2r → Recurrent Varicose Veins

C3 → Edema

C4a → Pigmentation or eczema

C4b → Lipodermatosclerosis (mc site - medial aspect of leg) or atrophie blanche *(INICET NOV. 20)*

C4c → Corona phlebectasia

C5 → Healed venous ulcer

C6 → Active venous ulcer

C6r → Recurrent active venous ulcer

2. Etiological classification

Ec → Congenital (eg. Klippel-trenaunary syndrome)

Ep → Primary

Es → Secondary (post thrombotic)

En → No venous cause identified

3. Anatomical classification

As → Superficial veins

Ap → Perforator veins

Ad → Deep veins

An → No venous location identified

4. Pathophysiological classification

Pr → Reflux

P0 → Obstruction

Pn → No venous pathophysiology identified

Pr,0 → Reflux & obstructed

Varicose Veins

Varicose veins may be described as *elongated dilated tortuous** vein.

* *Tortuous = full of twist and turn.*

In this section we will discuss, only the varicosity of the saphenous venous system. Please see key box 24.1.

SURGICAL ANATOMY OF SAPHENOUS VENOUS SYSTEM

The venous blood from the limbs return via the deep and superficial veins. In the upper limb, the superficial veins are more important in draining blood back to heart. In the lower limb; the superficial veins carry only about 10% of the blood, while about 90% passes via the deep vein.

Venous system of the leg can be considered under three

1. Superficial veins
2. Deep veins
3. Perforating veins

KEYBOX 24.1

Common sites of varicosity

1. **Superficial venous system of the lower limb:** A varicose vein bulges outwards under the skin the veins commonly involved are:
   - Short saphenous vein varicosity (on lateral aspect of leg).
   - Long saphenous vein varicosity (on medial aspect of leg and thigh).
2. **Hemorrhoidal venous plexus in anal canal**
3. **Esophageal varices in esophagus**
4. **Varicocele varicosity** of the pampiniform plexus of spermatic cord

1. Superficial venous system

Superficial venous plexus comprise long & short saphenous veins and their tributaries. They have following characteristics :

- They lie in the superficial fascia between the skin and deep fascia.

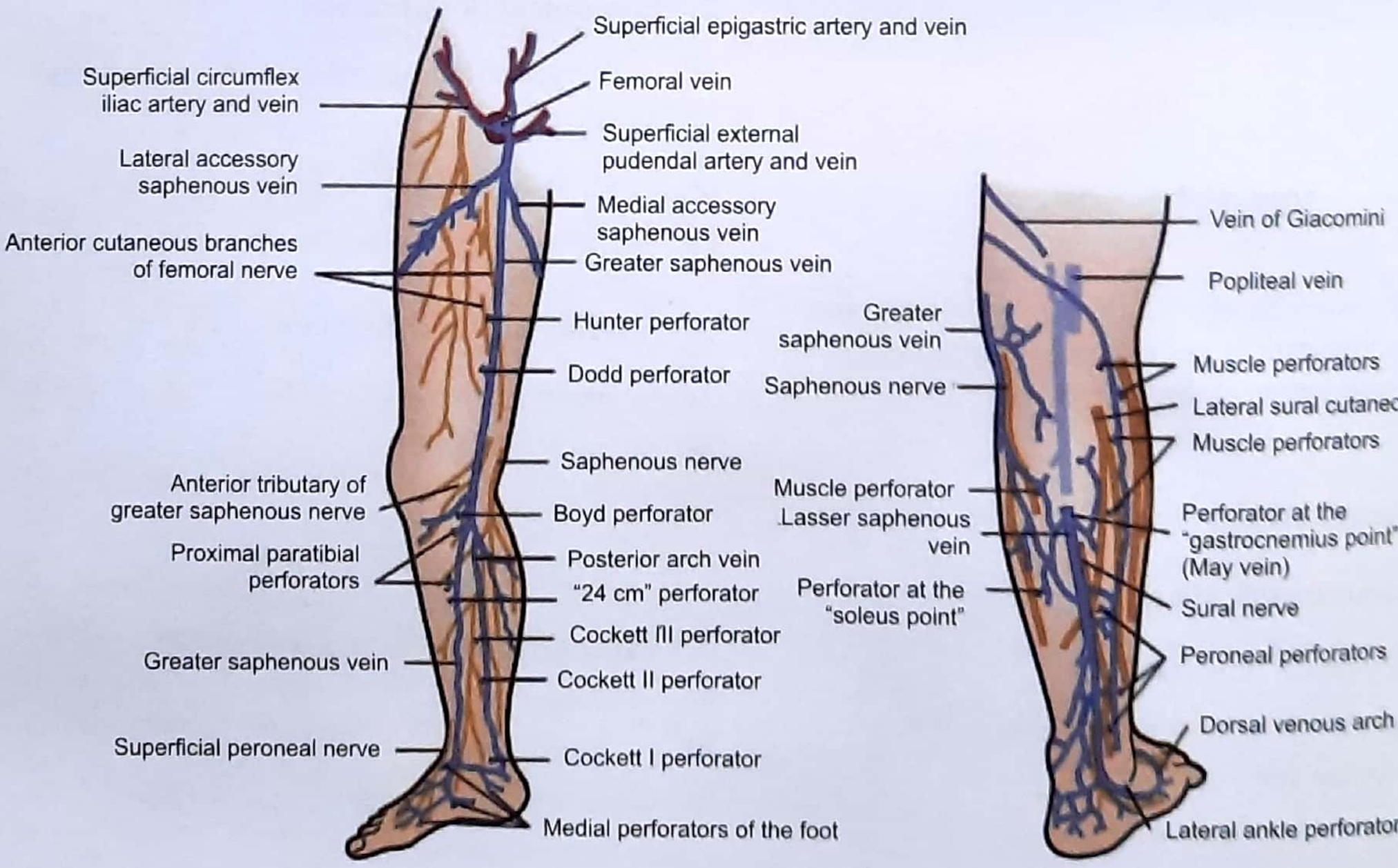

Figure 24.1: Venous drainage of the lower limb

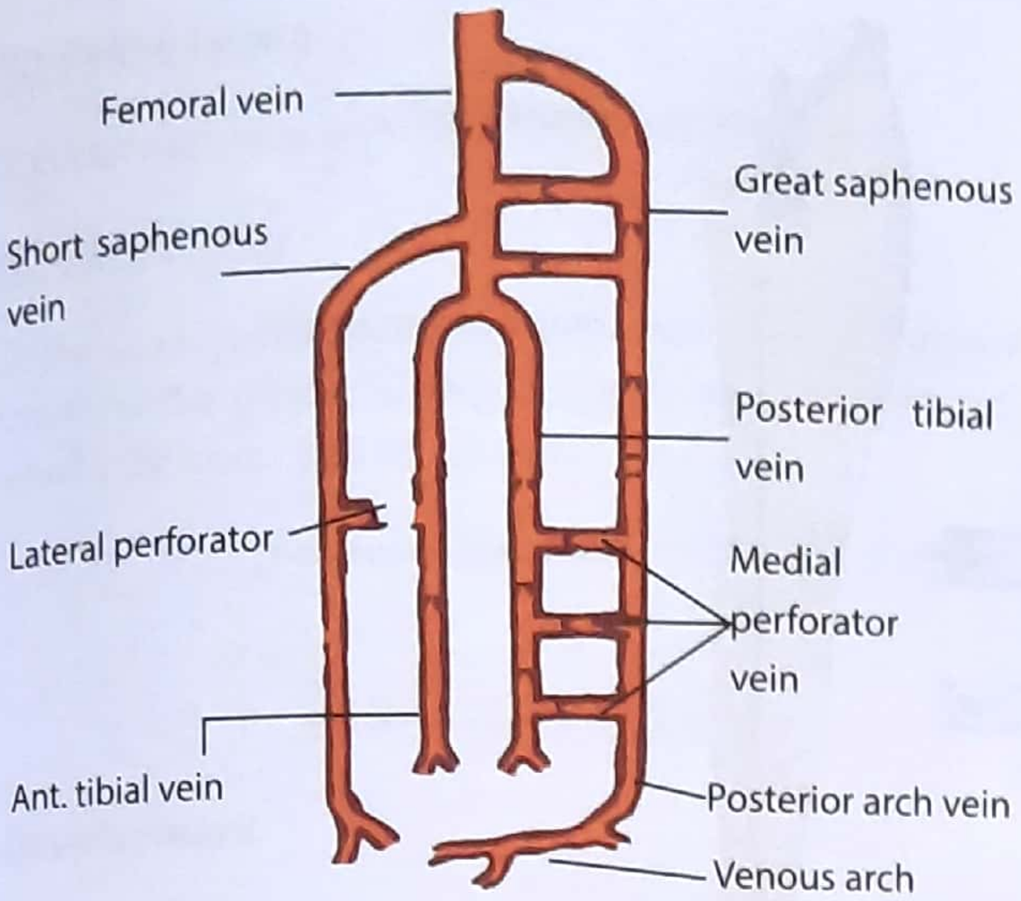

Figure 24.2 (a): Venous system of lower limb

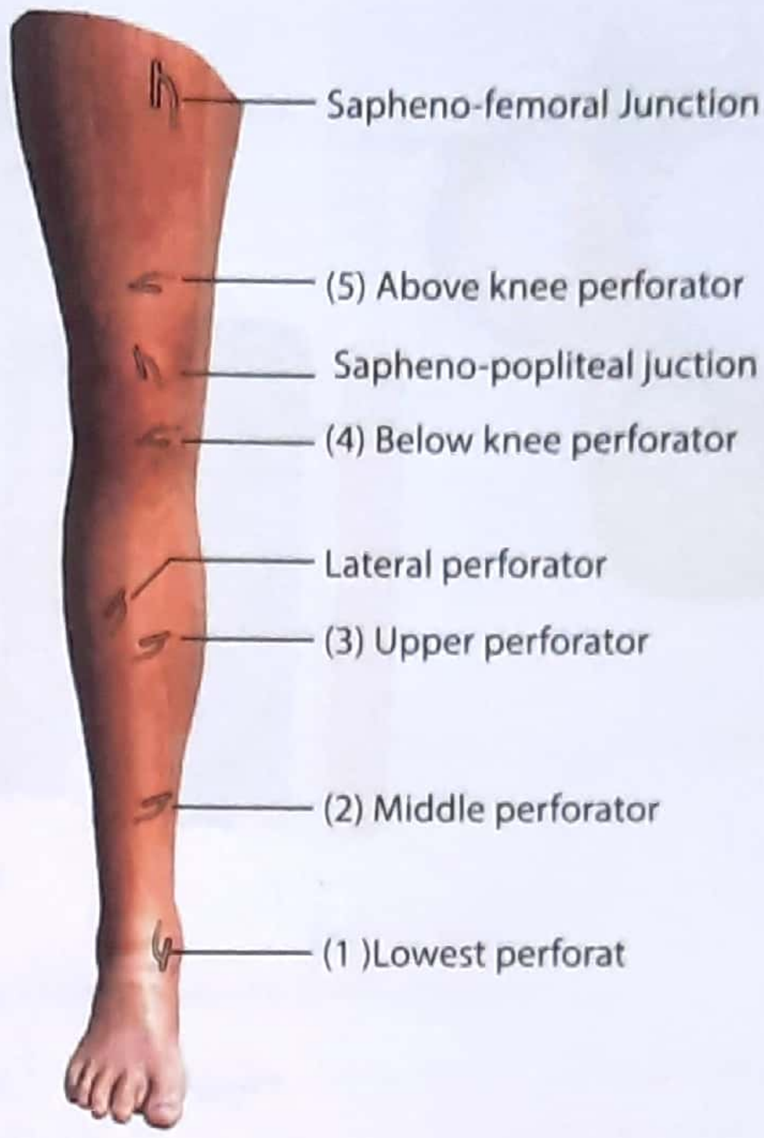

Figure 24.2 (b): Note: site of perforators (connecting veins) in lower limb venous system

- They are low pressure system.
- They have numerous valve, which are responsible for unidirectional *flow of Hood from superficial veins to deep veins.*

NOTE: Normally the blood from the superficial venous system flows into deep venous system.

(i) Long (Great) saphenous vein

This is longest vein of the body (PGME). It commences from the medial part of the dorsal venous arch of the foot and courses in front of the medial malleolus to the postero-medial aspect of the knee joint, and then runs (ascends) upwards in the thigh towards the saphenous opening which lies about 1.5 inch (3.75cm) below and lateral to the pubic tubercle. Then it pierces the cribriform fascia and passes deeply to enter the femoral vein. The vein contains more than 12 valves. (Please see figure 24.1, 24.2(a) & 24.3)

- In lower half of leg **long saphenous vein** is closely related to **saphenous nerve** and can be damaged during surgery of long saphenous varicosity (AIIMS 03)

(ii) Short (small) saphenous vein

This vein begins behind the lateral malleolus as a continuation of lateral marginal vein of the foot. It first ascends along the lateral border of the tendoachilles and then along the midline of the back of leg. It perforates between the deep fascia and passes between the two heads of the gastrocnemius into the lower part of the popliteal fossa and ends into the popliteal vein; 3.5 cm above the level of knee joint. It has 7-13 valves. *Sural nerve is in close relation with short saphenous vein and may be injured during its stripping.* (PGME) {* Stripping= removing)

2. Deep venous system

They are anterior & posterior tibial, popliteal and femoral veins. These are accompanied by main arteries and is well supported by powerful muscles. These muscles are most important factor in the return of blood to the heart.

With in the ***soleus muscle***, which is the most powerful muscle of the calf, there are venous sinuses (or plexus) These are devoid of valves. In the upright position of the body, the venous return from the lower limb depends largely on the contracture of calf muscles. *This muscles is there fore, called as* ***'calf pump'*** *or* ***'peripheral heart'*** (PGME). When this muscle contracts blood contained in large sinuses is pumped into the posterior tibial and the peroneal veins. When the muscle relaxes, blood flows into sinuses from superficial veins.

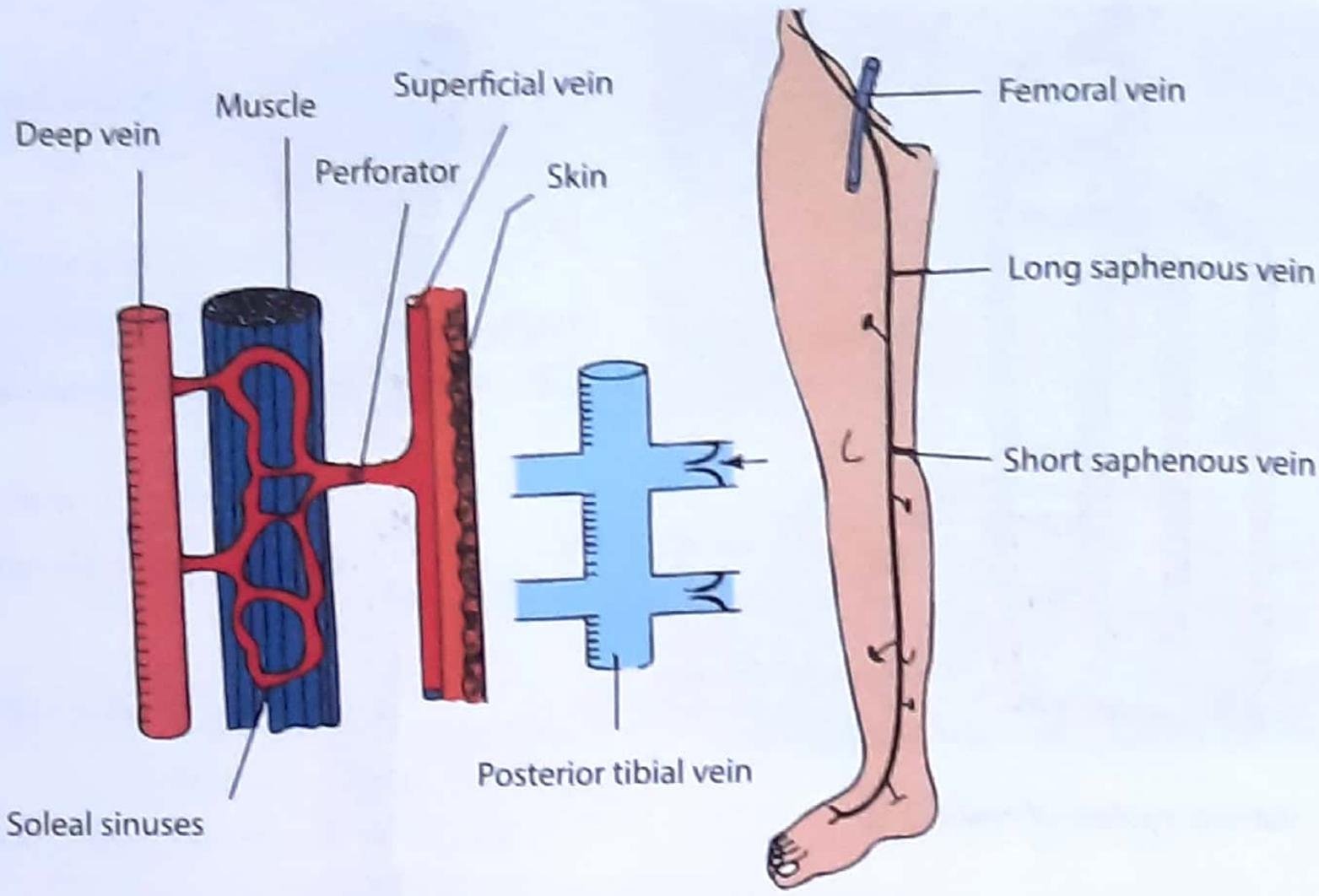

Figure 24.3: Venous system of lower limb

3. Perforating Veins (Communicating Veins/ Perforators) (AIIMS 07)

They ***connect*** the superficial veins to the deep veins. They have valves, which permit only one way flow of blood that is from the **superficial to deep veins.** *Main Perforators (from below upwards) are:* (Must see figure 24.1, 24.2, 24.4)

(A) In the leg :

A. On the medial aspect (3 perforators)

(i) *Lower medial perforators* -lie 5 cms above and posteroinferior to medial malleolus.

(ii) *Middle median perforator* lies 10 cms above the medial malleolus.

(iii) *Upper medial perforator* lies 15 cms above the medial malleolus.

(b) On the lateral aspect (1 perforator)

A lateral perforator is present at the junction of middle and lower third of leg. It connects short saphenous vein to the peroneal vein/anterior tibial vein (Fig. 24.2(a&b) & 24.4)

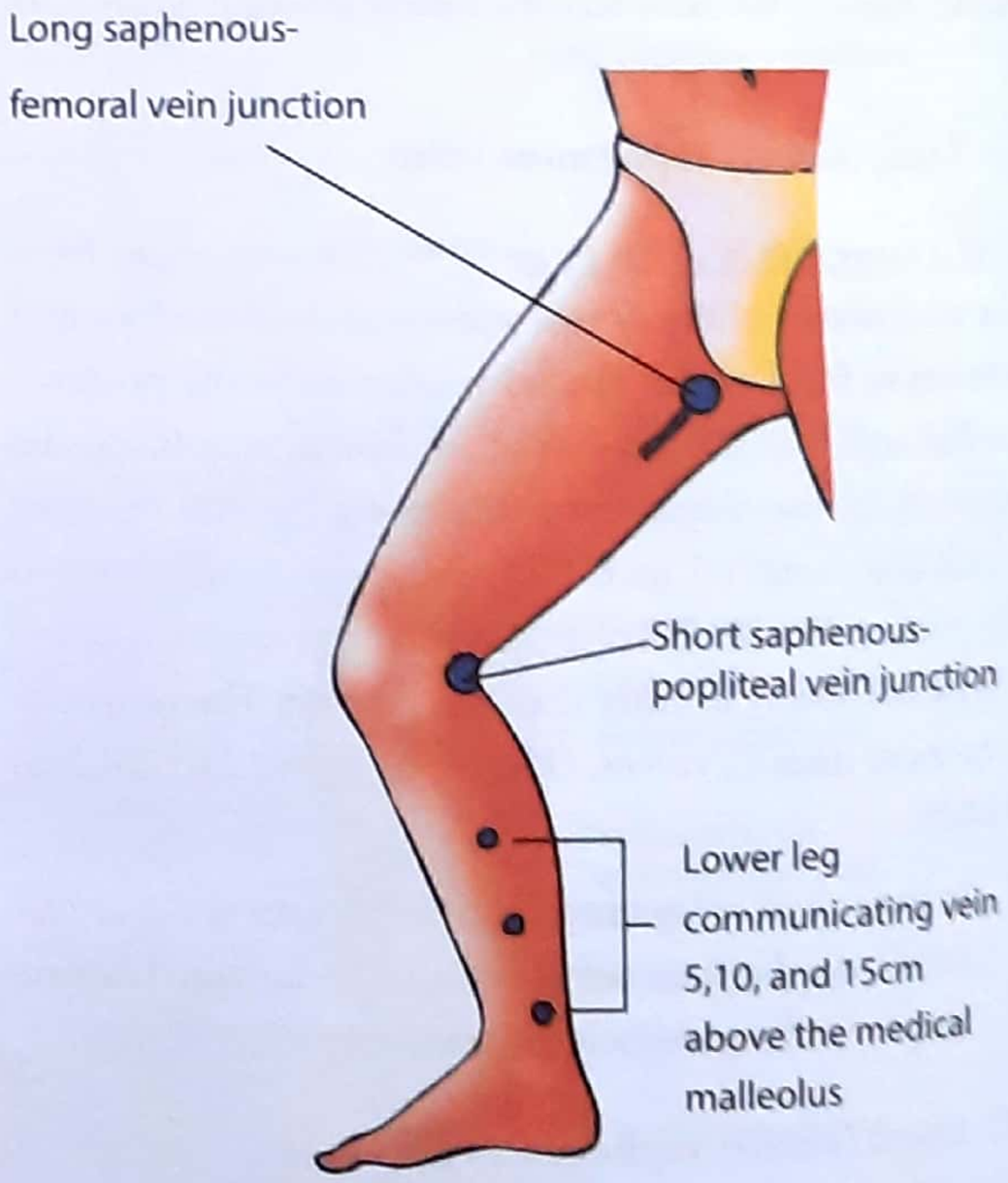

Figure 24.4: Sites of 5 perforating (connecting) veins in lower limb

(B) Below knee :

A perforating vein is present just below the knee.

(C) Above knee :

In the thigh just above knee, adductor canal perforator connects the greater saphenous vein with the femoral vein in the lower part of the adductor canal.

****

VARICOSE VEINS

Development

Under normal condition the blood in the superficial venous system flows into deep venous system. Superficial venous Long saphenous-femoral vein junction Short saphenous-popliteal vein junction Lower leg communicating vein 5, 10, and 15cm above the medial malleolus system is protected from the reflux of blood from high pressure deep venous system due to the presence of unidirectional valve in the deep and perforating veins. But, if some how this mechanism breaks down; there will be retrograde flow of high pressure deep venous blood into superficial veins of leg leading to dilatation and tortuosity of superficial vein, termed as varicose veins. *This varicosity is most common with long saphenous vein; ie. in medial side of the leg.* **(AIIMS JUNE 99, MANY PGME)**

Physiology

Blood is normally propelled from lower limb to the heart against the gravity by the following mechanisms:-

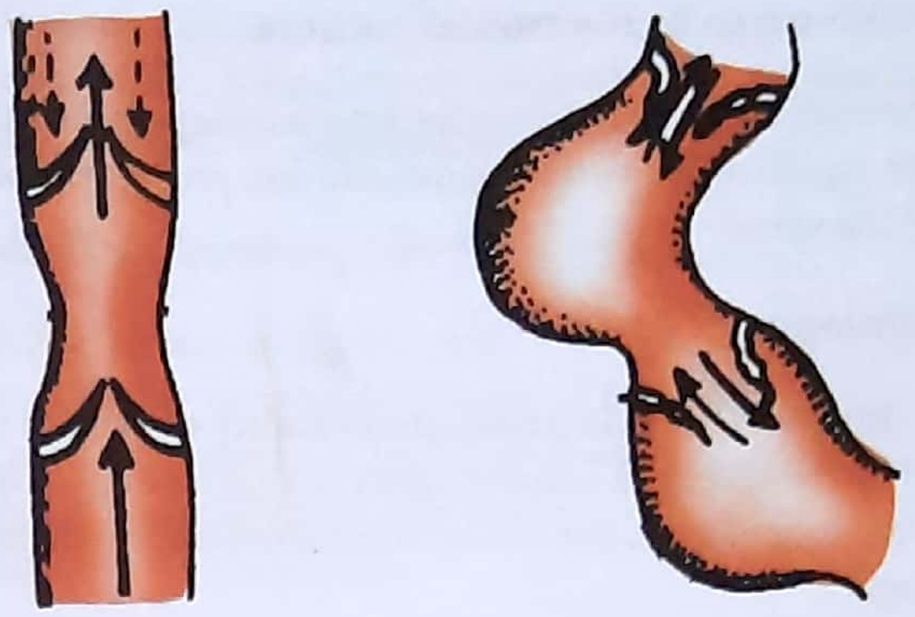

Figure 24.5 (a): Valves in vein (A) Competent valve (B) Incompetent valve

1. Negative Pressure in the thorax

During inspiration the intrapleural pressure falls from -2.5 mm Hg to -6 mm Hg. This negative pressure is transmitted to the veins of legs, thus drop in venous pressure during inspiration increases the venous return from lower limb.

2. Muscle pump or calf pump

Alternate contraction and relaxation of the muscles of leg especially soleus which acts as peripheral heart, increases venous return to heart.

3. Competent valves in the vein

The valves in the veins allow unidirectional flow of the blood, that is hi upward direction. So these valves help in propelling the blood upwards against gravity. (Fig. 24.5a)

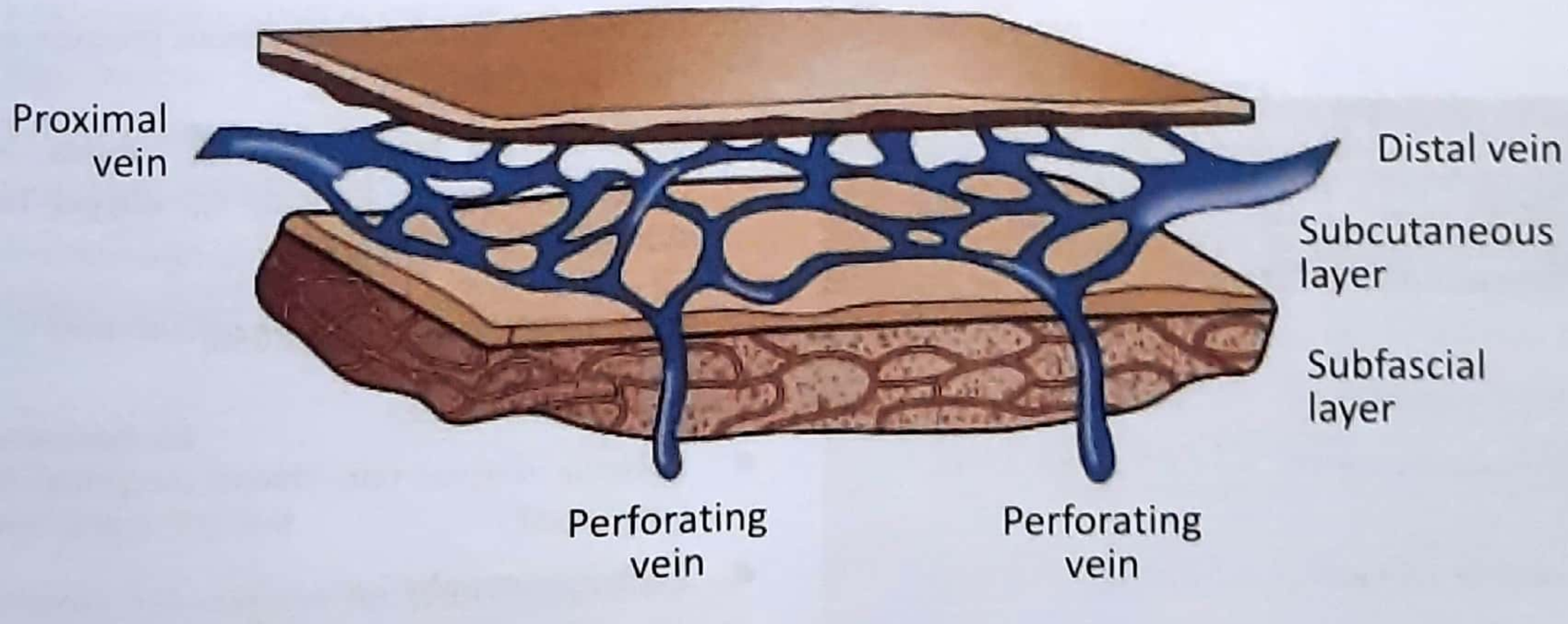

Figure 24.5 (b): Dilation of superficial venous tributaries caused by increased transmission of pressure by the perforating veins

4. Visatergo by the arterial pressure

Pressure transmitted from the arterial tree passes through the capillary bed to the venous end and propels the blood in the veins.

Etiology

Primary cause is intrinsic abnormality of venous wall. (NEET) However the cause of varicose vein formation is not well under stood, but can be considered under two headings.

A. Primary varicosity

When varicosity develop without any obvious cause. It may be due to:

1. *Hereditary:* Due to congenital-weakness of the valves or the vein wall. Rarely, it may be due to congenital absence of valves.
2. *Familial:* Varicose veins are more common in certain families.
3. *Endocrinal:* Hormonal imbalance especially during pregnancy *may* predispose to varicose veins.
4. Contributory factors are
   (i) *Obesity*
   (ii) *Occupation* eg; prolonged standing
   (iii) *Habit:* of wearing tight garments
   (iv) Muscle weakness leading to poor musculovenous pumping action.
5. Idiopathic: Primary ankle perforator incompetence.

B. Secondary varicosity

When varicosities develop due to some known cause; such as:

Figure 24.6: Varicose vein of lower limb. (tortuous and dilated veins)

1. Proximal obstruction to blood flow as in
   (i) Pregnancy
   (ii) Abdominal mass
      (a) Fibroids, ovarian cyst
      (b) Abdominal lymphadenopathy
      (c) Pelvic cancer
      (d) Loaded colon
   (iii) Ascites
   (iv) Iliac vein thrombosis
   (v) Retroperitoneal fibrosis
2. Destruction of valves as occurs in deep vein thrombosis.
3. Increased blood flow and venous pressure as in arteriovenous fistula.
4. Varicose vein associated with various degree of congenital venous anomaly eg; Klippel Trenaunay syndrome*.

KEY BOX 24.2	
Etiology of Varicose Veins	
Primary	**Secondary**
• Often familial	• Following DVT
• Valvular incompetence	• Pregnancy
• Congenital absence of valve	• AV malformation
• Weakness of vein wall	• Trauma
• Prolonged standing	• Pelvic tumours

* ***KLIPPEL TRENAUNAY SYNDROME*** (AIIMS 91, 02)

Classical **triad** include:-

- Pulsatile varicose vein (due to congenital A-V malformation)
- Limb hypertrophy
- Cutaneous birth mark (Portwine strain & hemangiomas)

Figure 24.7: Varicose ulcer in lower limb (Note; the hyperpigmentation of skin around ulcer)

Clinical Feature

- The commonest symptom is tired and aching sensation in the affected lower limb, particularly in calf and leg at the end of the day.
- Patients also complain of tortuous and dilated veins in the lower limb. (Fig. 24.6)
- Pain may be bursting or severe in nature and may be particularly localized to the site of the incompetent perforating veins.
- Patient may often present with no other symptoms except dilated and tortuous veins of the leg. These dilated veins *may or may not* be associated with following complications.
  - Ankle swelling towards evening
  - Pigmentation
  - Itching of overlying skin
  - Eczema of affected skin
  - Venous ulceration (Fig. 24.7)
  - Disfigurement

Local Examination

Morrissey Cough impulse

The limb is elevated to empty the vein, and then the patient is asked to cough. If an expansile impulse in felt in the long saphenous vein, means saphenofemoral valve is incompetent. A single varix situated at the saphenous opening is called as ***'Saphena varix'.***

Brodic-Trendelenburg test (PGI JUNE 02)

With the patient lying, the limb is raised to empty the veins. A rubber trourniquet is applied at the saphenofemoral junction at the fossa ovalis (4 cm below and lateral to the pubic tubercle) or directly pressure can be applied by thumb over the fossa ovalis.

Observation: Normally the gradual filling of superficial veins occur from below after the patient stands. When the pressure is removed (ie., by removing tourniquet or thumb) - *If there is rapid filling from above, means incompetence of sapheno femoral valve:* (ORISSA 98)

Three Tourniquet test

3 tourniquet's are tied, first at thigh, below sapheno femoral junction, 2nd below knee and third just above knee. These prevent blood flow to each blow out from above as well as below. Now the patient is asked to stand-up and appearance of varicosity is looked for, within 30 seconds in each segment.

The leg is also observed for retrograde filling of the distal segment, after removal of the tourniquets one by one from below upwards, the exact levels of perforators can thus be assessed.

Perthe's test

A tourniquet is tied around the upper thigh, tight enough to occlude the long saphenous vein. Now the patient is asked to walk for few minutes. If the deep vein and perforating veins are functionally normal, the superficial veins shrink. If the superficial vein gets dilated, either the deep system is blocked or the perforating veins (perforators) below the level of the tourniquet are incompetent.

Pratt's test

This test is to assess the incompetence of perforators. The patient in asked to lie in supine position, an elastic compression bandage is applied from the toe to upper third of the thigh to empty the varicose vein. A tourniquet is than tied just above the bandage. The patient is then asked to stand up and the bandage is removed from above down wards. The appearance of blowout indicates the site of incompetent perforators and are marked by a pen.

Investigation

1. Duplex ultrasound imaging
2. I^{125} fibrinbgen leg scanning
3. Plethysmography
4. Venography

Complication of varicose veins

1. **Pigmentation**
2. Eczema
3. Ulceration (mc site - Gaiter area = Medial of lower $1/3^{rd}$ of leg). *(NEET)*
4. Periostitis
5. **Thrombophlebitis**
6. Calcification
7. Hemorrhage
8. Deformities of the foot - Talipes equinus
9. **Lipodermosclerosis** (figure 24.8)

Figure 24.8 : Lipodermosclerosis, atrophie blanche, and brawny edema

Treatment

1. Conservative

- Avoidance of prolonged standing.
- Elevation of limb, preferably above the heart level during rest or at night will improve venous drainage.
- Exercises : Exercise of the leg to strengthen the calf muscle eg; bicycling exercise.
- Supporting crepe bandage and elastic stocking.
- Antibiotic if ulceration but they don't speed up healing.

2. Sclerosant injection *(PGI 88)*

Injection of a sclerosant (eg; **5% ethanolamine oleate**) into an empty varicose vein will damage the intimal lining of the vein, and cause sclerosis of it, leading to complete obliteration of the vein. *Sclerotherapy is more effective, when varicosity is less than 3mm in diameter.* *(MAY BE FUTURE PGME QUES.)*

Sclerosing agents are - Sodium tetradecyl sulphate, Hypertonic saline , Polidocanol .

3. Surgical treatment

Indication for surgical treatment

- Disabling pain
- Recurrent superficial thrombophlebitis
- Erosion of superficial skin with bleeding
- Venous ulceration
- Varicosity diameter more than 3 mm.
- Saphenofemoral incompetence
- Failure of conservation therapy

Aim of Operation

1. To stop retrograde venous flow, from deep to superficial vein by ligating the incompetent veins at the following sites.
   (i) Saphenofemoral junction
   (ii) Sapheno-popliteal junction
   (iii) At the incompetent perforating vein
2. Excision of varicosity

Methods

1. Ligation alone-**Trendelenburg's operation** *(NEET)*
2. **Ligation and stripping**-treatment of choice *(PGI 01, AI- IMS 84, 86)* (figure 24.9)
3. Ligation and retrograde sclerotherapy.
4. Multiple avulsion or excision of veins

5. *Cockett and Dodd* operation: treatment of choice for incompetent perforators (AP 96, UPSE 08) Cockett and Dodd's operation — SubFascialligation of incompetent perforators.
6. SEPS: SubFascial Endoscopic Perforator Surgery (AI 09)

* **Stripping:** Surgical procedure in which a vein is removed.

Newer Surgical Techniques

1. Vein valve transplantation (harvested from the brachial vein)
2. Femoral vein valvuloplasty
3. External vein valvuloplasty

Contraindication of Surgery & Sclerotherapy (AIIMS 2000, JUNE 2000)

1. Women taking contraceptive Pills, because there are chances of Deep vein thrombosis & thromboembolism.
2. Pregnancy
3. Deep vein Thrombosis
4. Thrombophlebitis

{Mnemonic: DPT}

****

VENOUS THROMBOSIS

Thrombosis of the veins may affect superficial veins (superficial thrombophlebitis) or the deep veins (deep venous thrombosis-DVT). The latter is much dangerous because of its potential risk of pulmonary embolism, which is a life threatening condition.

(A) Superficial Thrombophlebitis (AI 09)

The most common cause of superficial thrombophlebitis is *cannulation of the vein* for an intravenous infusion (AIIMS 04). The affected vein is painful and appear as a cord like inflamed area on palpation. Spontaneous thrombophlebitis, especially the migrating type, is mostly idiopathic but may be due to condition like Buerger's disease, Polycythemia or visceral malignancy. See key box 24.3.

The initial treatment of localized non-complicated thrombophlebitis involves conservative therapy, which consists of anti-inflammatory medication and compression stockings. The recommended treatment of a superficial thrombophlebitis, involving a ≥5 cm great saphenous vein segment is a midtreatment dose of LMWH (enoxaparin 60 mg daily subcutaneously)

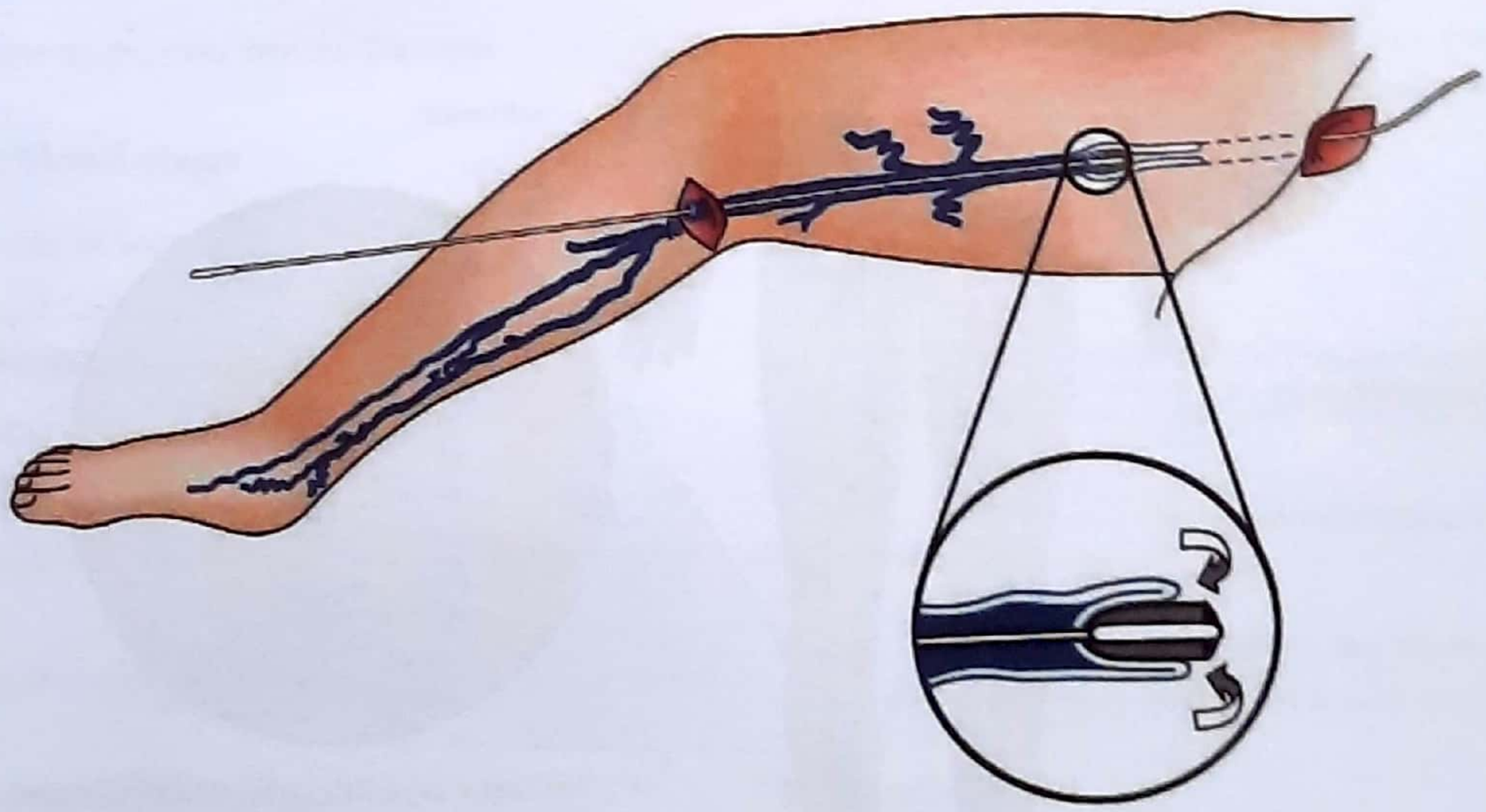

Figure 24.9: Stripping of the saphenous vein for superficial venous reflux caused by an incompetent saphenofemoral junction

KEY BOX 24.3

Migratory superficial thrombophlebitis (Trousseau's syndrome) *(POME-MAMY TIMES)*

Episodes of inflammation of superficial veins at multiple site occur with carcinomas of internal organs. This was described for the first time by trouseau-A french physician who had pancreatic carcinoma and died of it Diseased associated with trousseau's syndrome are:

- CA Pancreas (M/C)
- CA Stomach
- CA Lung
- CA ovary
- CA colon
- CA prostate
- Buerger's disease (TAO) (M/C non-malignant cause)
- Polycythemia

Also note:

Troisier's sign: Enlargement of left supra clavicular lymph node (virchow's nbdel iftay Indicate metastasis from the malignancy tumours ftom distant, organs, eg; stomach, oesophagus, testis, breast, bronchus, pancreas.

Trosseau's Sign: Carpopedal spasm elicited in hypocalcaemia

or fondaparinux (2.5 mg daily subcutaneously) for a 6-week period. A similar treatment is recommended if the thrombophlebitis ascends the great saphenous vein with 3 cm from the saphenofemoral junction.

When the thrombophlebitis involves clusters of varicosities, particularly in the lower extremities, excision may be indicated. Selective removal of the entire vein along its course is indicated only in the rare case of suppurative septic thrombophlebitis after all other sources of sepsis have been excluded.

(B) DEEP VEIN THROMBOSIS (DVT)

Deep venous thrombosis (also known as phlebo-thrombosis) is thrombosis of deep venous system of an extremity. It is manifested clinically by swelling, pain, erythema, calf tenderness and low grade pyrexia, and is some times complicated by pulmonary embolism.

Predisposing Factors *(AIIMS AS, 97, 01)*

The important factors that predispose to this condition are , called as **virchow's triad** which consist of abnormality in:

(i) Venous wall

(ii) Venous flow (stasis of blood) and

(iii) Hypercoagulability (↑viscosity)

Remember it with the help of following:

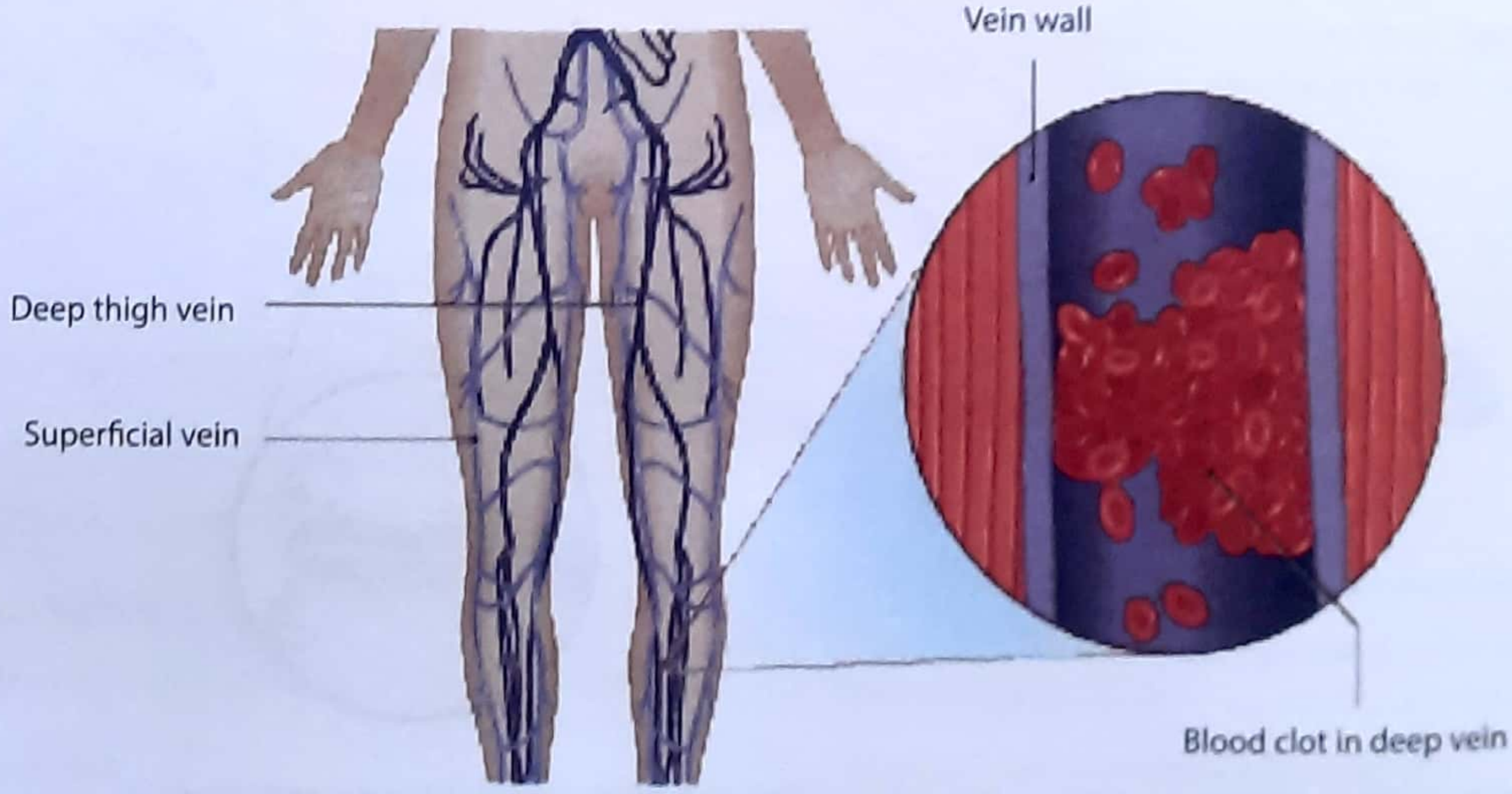

Figure 24.10: A blood clot in the deep vein of the calf which causes deep vein thrombosis

KEY BOX 24.4
Hypercoagulable states
• Factor V Leiden mutation
• Prothrombin gene mutation
• Protein C deficiency
• Protein S deficiency
• Antithrombin III deficiency
• Homocysteinemia
• Antiphospholipid syndrome
• Lupus antibody
• Anticardiolipin antibody

KEY BOX 24.5	
Predisposing Factors for DVT *(AI 2000, 03)*	
• Age>40 years	• Malignant disease
• Obesity	• Major surgery/Trauma
• Immobility (bed test > 4 days)	• Recent myocardial infarction
• Varicose vein	• Heart failure (CHF)
• Infections	• Polycythemia/ thrombocythemia
• Past history of DVT	• Connective tissue disorders
• Pregnancy/ Peurperium	• Paralysis
• Oral contraceptives	• Inflammatory bowel disease
• Previous DVT/PE	• Nephrotic syndrome
• Thrombophilia	• PNH or lupus anticoagulant

Virchow's triad: *(NEET, PGME MANY TIMES)*

V - Venous wall damage

V - Venous stasis

V - ↑ Viscosity (Hypercoagulability)

Now lets take each factor one by one.

1. Venous wall damage

Damage to the endothelium of wall may occur due to:-

- Varicose vein
- Previous thrombophlebitis
- Repeated trauma, due to previous IV cannulation
- Inflammatory process around the vein.

2. Venous blood stasis

Diminished rate of blood flow may be due to:

- **Prolonged bed rest (Hospitalization) - most imp. factor for development of DVT.** *(NEET)*
- Restriction of leg motion (as in casts for fracture)
- Congestive cardiac failure
- Compression of vein by tumour (especially pelvic tumour)
- Postoperative patients.

3. Hypercoagulability (Increased viscosity of blood) *(UPSC 2000)*

- Trauma (Surgical, child birth, mechanical)
- Hyperviscosity due to polycythemia
- Carcinoma
- Prolong use of oral contraceptive pills.
- ***Thrombophilia***: It is a group of disorder in which there is an increased chances for venous thrombosis due to lack of naturally occurring anticoagulants in blood eg; antithrombin III deficiency, protein C and protein S deficiency, antiphopholipid syndrome.
- Please read key box 24.4 & 24.5.

Surgical Risk of DVT *(AI 03)*

The risk of development of DVT is particularly high in postoperative patients. It has been classified as low, moderate and high.

A. Low risk

Age of patient less than 40 years, no other risk factor, minor elective surgery lasting for less than 30 minutes.

B. Moderate risk

Age of patient more than 40 years, abdominal and/or thoracic surgery lasting for more than 30 minutes.

KEY BOX 24.6	
Modified Wells criteria for predicting deep vein thrombosis (DVT)	
Variable	**Score**
Lower limb trauma or surgery or immobilization in a plaster cast	1
Bedridden for > 3 days or surgery in last 4 weeks	1
Tenderness along the line of femoral or popliteal veins	1
Entire limb swollen	1
Calf > 3cm larger circumference than the other side	1
10 cm below the tibial tuberosity	1
Pitting oedema	1
Dilated collateral superficial veins (Not varicose veins)	1
Previous DVT	1
Malignancy (including treatment up to 6 months ago)	1
Intravenous drug abuse	3
Alternative diagnosis more likely than DVT	-2
Well's score: ≤ 1 Low risk ≥ 2 High risk	

C. High risk

History of previous DVT or PE (pulmonary embolism), abdominal or pelvic surgery for malignancy, major lower extremity orthopedic procedure.

Clinical Feature

- The clinical spectrum of DVT varies greatly from no symptoms to severe pain and systemic signs of inflammation.
- In most cases, thrombosis causes an inflammatory reaction in vessel wall and gives rise to clinical picture of pain, tenderness and low grade pyrexia
- *Calf venous thrombosis occur most frequently in the calf vein (soleal veins),* though it may arise in the femoral or iliac veins (JIPMER 98)

Symptoms

1. Rapid onset of discomfort and tightness in the involved calf or thigh.
2. **Pain may be aggravated by muscular exercise.** (PGI MAY 19)
3. Symptom like *mild fever* (CMC 2001) may be present.

Signs

1. *Calf tenderness is most important and earliest sign for DVT of calf veins* (NEET, AIIMS 87, PGI, UP 91)
   - **Homan's sign**: Calf tenderness on forced ankle dorsiflexion
   - **Moses sign**: Calf tenderness due to direct pressure on calf
   - **Pratt's sign**: Calf tenderness on squeezing the calf from side to side.
2. Swelling of leg, foot and ankle (ankle edema)
3. Difference of circumference of the affected calf, as compared to opposite calf.
4. Dilated superficial veins: Because due to thrombosis of deep vein, superficial vein will not be drained in the deep vein. Note: Normally the blood from the superficial venous system flows into deep venous system.
5. If the thrombus is present in the femoral vein; pain and **tenderness will be present in thigh.** (PGI)
6. If the thrombus is involving iliofemoral vein, patient will have massive swelling, severe pain and tenderness of entire lower limb.
7. Affected vein is seen like cord & is palpable. (PGI)

Investigation

A high index of clinical suspicion is required.

Doppler ultrasonography

Indicate whether the vein is patent or obstructed.

Duplex ultrasonography (Investigation of choice)

(NEET, UPSC 07)

This is a non-invasive test and display the anatomy of vein, presence of and extent of the thrombus. This is the ideal test in case of DVT. It produces high quality pictures using a combination of B mode imaging.

Ascending Venography

Formerly it was investigation of choice, but now it is rarely indicated, as duplex scan is equally accurate and non-invasive. Duplex scan has replaced venography for

the assessment of varicose vein, DVT, chronic venous insufficiency.

Radionuclide scanning

Using I^{125} or $indium^{111}$ labelled platelets are sometimes required for confirming the diagnosis of subclinical DVT.

Magnetic resonance venography (MRV)

It is excellent non invasive diagnostic tool and is now investigation of choice in the diagnosis of proximal venous thrombosis (pelvic, iliac and IVC thrombosis)

Radio active fibrinogen uptake test

Fibrinogen labelled with iodine 125 is taken up by developing thrombus, which is given intravenously and is scanned at several points.

Differential diagnosis

- Lymphatic obstruction
- Calf muscle tear or hematoma
- Compartment syndrome
- Cellulitis
- Superficial thrombophlebitis
- Acute arterial occlusion.

Treatment (MAHE 07)

(A) Prophylaxis

Prevention is better than cure -

(i) Physiological measures

- Active leg exercise
- Limb elevation
- Calf muscle massage
- Adequate hydration
- Graduated compression stockings (TED stocking)
- Pneumatic compression devices (figure 24.11)
- Stop estrogen 6 weeks before surgery.
- Hirudin-a leech extract

(ii) Pharmacological measures

- Low-dose heparin: 5000 IU subcutaneously 2-3 times/day for 5 days after surgery. (AIIMS 06)
- Oral anticoagulants: Low dose warfarin 1-2 mg/day. (IMP. POINT)

The patient who has undergone major abdominal or orthopedic surgery, has sustained major trauma, or has prolonged immobility (>3 days) represents an elevated risk for the development of venous thromboembolism.

B. <u>Treatment of an established case of DVT</u>

(i) <u>General measures</u>

- Bed rest and elevation of leg by 15° for 7-8 days.
- Bandaging the whole limb with crepe bandage or stocking to increase the deep venous flow.

(ii) Drug Treatment

(i) Anti coagulants

Intravenous heparin restricts further deposition of fibrin and limits extension of the thrombus. An initial injec-

Figure 24.11: Pneumatic compression device

KEY BOX 24.7

Also know

Phlegmasia Cerulea dolens (Painful blue leg):

This is a severe form of iliofemoral veins thrombosis leading to cyanosis of leg. The affected leg is painful and blue.

Phlegmasia alba dolens (Painful while leg):

This is characterized by arterial spasm resulting in white painful leg, often seen in iliofemoral thrombophlebitis, and is called as milk leg of pregnancy (TN 90).

tion of heparin 5000 I.U. is given and controlled by the activated partial thromboplastin time (APTT). keeping 1.5-2.5 time the normal value (KARN 03). The duration of heparin treatment should be at least 5 years.

- Simultaneously the patient should be started on warfarin. Monitoring is preferably by INK (international normalized ratio), which should be kept between 2.5 and 3.5. (UPSC 2002).

(ii) Fibrinolytic therapy (Thrombolytic therapy)

Systemic thrombolytic therapy has been abandoned in favour of catheter directed thrombolysis. The commonly used agents are urokinase, streptokinase and recombinant tissue plasminogen activator (TPA, alteplase).

(iii) Operative procedures

It is required in only a few cases. The procedures are:

(i) Venous thrombectomy

It involves opening of the femoral vein in groin and removing all clots from the deep veins of the leg and pelvis. It is mainly done for patients with impending gangrene or to prevent pulmonary embolism.

(ii) Intravenous thrombolysis

In this; a catheter is passed into the affected vein and is infused with a fibrinolytic drug such as Urokinase or Streptokinase or tissue plasminogen activator (TPA).

(iii) Caval interruption procedures (Vena caval filters)

Pulmonary embolism may be prevented by inserting a filter in inferior vena cava, which traps large thrombi and prevents them in reaching and occluding the pulmonary artery. These filters are placed through femoral or jugular vein by a radiologist; under X-ray control. Please read key box 24.8.

KEY BOX 24.8

Indications for a vena cava filter

- Recurrent thromboembolism despite adequate anticoagulation
- Deep venous thrombosis in a patient with contraindications to anticoagulation
- Chronic pulmonary embolism and resultant pulmonary hypertension
- Complications of anticoagulation
- Propagating iliofemoral venous thrombus in anticoagulation

****

PULMONARY EMBOLISM

It is observed that about 15-20% of thrombi in the leg embolies. It is a dangerous complication of DVT and symptoms depends upon the size of the embolus.

The condition may manifest itself by either one of the following ways:

1. Acute massive pulmonary embolism

This is case of fatal pulmonary embolism, the embolus is usually found in the pulmonary trunk, obstructing right ventricular outflow tract. Severe cardiorespiratory symptoms develop. The condition is usually fatal.

2. Acute minor pulmonary embolism

In this case the size of embolus is small. Patient usually presents with chest pain and hemoptysis.

3. Chronic pulmonary embolism

This is due to recurrent small emboli which lead to a gradual onset of pulmonary hypertension.

Etiology

About 95% of pulmonary embolism follow DVT in leg veins (Calf veins) (PGME MANY TIMES). Other sources are right ventricle, pelvic, renal or hepatic vein.

Clinical Feature

- The commonest symptoms of pulmonary embolism in decreasing order of frequency are: *dyspnea, pleuritic chest pain, cough and hemoptysis.* Patient may have fever and tachycardia.
- Features of massive pulmonary embolism are syncope, altered sensorium, severe chest pain, central cyanosis and raise JVP.

Treatment

1. *Heparin*: Heparin is drug of choice for PE, Heparin is changed to oral anticoagulants after a few days, and should be continued, for at least 6 months.
2. *Thrombolytic therapy:* Urokinase or preferably TPA (tissue plasminogen activator) is used for thrombolysis. These agents can be given by intravenous route or by the intrapulmonary route (via an angiography catheter). The latter is usually preferred.
3. *Pulmonary embolectomy*
4. *Inferior vena caval filters* (described earlier)

Note - Air embolism in neural surgery is maximum is sitting position. (NEET)

****

LYMPHEDEMA

- Lymphedema is an interstitial edema of lymphatic origin. Lymphedema may be idiopathic (***Primary lymphedema***) or may caused by acquired insufficiency due to infection, obstruction or surgical destruction of lymphatics (***Secondary lymphedema***).
- Accumulation of lymph causes lymphatic vessel dilatation and incompetence of lymphatic valves. The protein rich fluid causes extremity swelling and predisposes it to infection. Subsequent *fibrosis is hallmark of all events that subsequently leads to nonpitting edema,* however deep fascia and deeper structures are usually not affected.

A. PRIMARY LYMPHEDEMA

This is diagnosed in the absences of any acquired disease damaging the lymphatic system. According to age of presentation it may be classified into: (Key box 24.9) and figure 24.12.

(i) Lymphedema congenita

It occurs at birth or early in infancy. The age of onset is at or within 2 years of birth. It is more common in males and is .more likely to be bilateral and involves the whole leg. It accounts for fewer than 10% of primary lymph edema cases.

- If *familial it is called as* ***milroy's disease.*** (AMU 85, JIPMER 92, AIPG). Associated anomalies of lymphatic system such as cystic hygroma or intestinal or pulmonary lymphangiectasia my be seen.

(ii) Lymphedema Praecox

It presents in adolescents and young adults. This is the most common variety and accounts for more than 80% cases of all primary lymphedema. If congenital this condition is known ***as Meige's disease.***

- It is ten times more common in woman than men. (F:M ratio 10 :1). Please see figure 24.12.

(iii) Lymphedema tarda

It presents in patients more than 35 years of age.

KEY BOX 24.9	
Primary Lymphedema	
Lymphedema congenita	0-2 years
Lymphedema Praeeox	2-35 years
Lymphedema tarda	after 35 year

Figure 24.12: Primary lymphedema of lower limb

B. SECONDARY LYMPHEDEMA (ACQUIRED/ OBSTRUCTIVE)

Lymphedema with characteristic loss of the normal perimalleolar shape, resulting in a "tree trunk" pattern. Dorsum of the foot is characteristically swollen, resulting in the appearance of the "buffalo hump."

(i) Inflammatory involvement of lymph nodes:

It may be due to acute, repeated infection or chronic infections, such as filariasis (*the most common cause*), tuberculosis and fungal infection. Other less common causes are:

- Malignancy
- Post operative: Block dissection of lymph nodes.
- Post radiation fibrosis
- Surgical trauma
- Mechanical injury

(ii) Filarial lymphedema: (UPSC 07)

Filariasis is most common cause of secondary lymphedema (AI 90). The common etiological agents are *Wuchereria broncrofti* and *Brugia malaya.*

The mechanism of lymphatic obstruction in filariasis is:

1 Obstruction of lymphatics by adult worms.
2. Intimal damage of lymphatic channels by toxin released by live or dead worm.
3. Secondary infection of the lymphatic or perilymphatic tissues.

Stages of the disease progression

Grade I

Pitting edema, relieved by rest or elevation of limb, no skin changes.

Grade II

Pitting edema which does not subside fully with rest or elevation, but still no skin changes.

Grade III

Partly pitting gross edema, not relieved by rest or elevation, thickening of skin and subcutaneous tissue.

Grade IV

Nonpitting gross edema, not relieved by rest or elevation or compression, pachydermia, varicosities, hyperkeratosis.

Complication (AI 04)

1. Thickening and hyperkeratosis of skin
2. Recurrent cellulitis
3. Recurrent lymphangitis
4. Eczema
5. Fibrosis of skin
6. ***Lymphangiosarcomas:*** It is an extremely rare malignant lymphatic tumour. It can occur in any extremity affected by chronic lymphedema, but is seen most commonly after a **mastectomy** (UPSC04) that is

Figure 24.13: Lymphoscintigraphic pattern in primary lymphedema. Note area of dermal backflow on the left and diminished number of lymph nodes in the groin

complicated by lymphedema of the arm. Most commonly seen in lymphedema of upper limb.

Investigation

(a) Peripheral smear may show Eosinophilia

(b) **Lymphoscintigraphy**

Lymphoscintigraphy (or isotope lymphography) has emerged as the test of choice in patients with suspected lymphedema. It cannot differentiate between primary and secondary lymphedemas; however, it has a sensitivity of 70% to 90% and a specificity of nearly 100% in differentiating lymphedema from other causes of limb swelling. (Figure 24.13)

(c) **Lymphangiography**

The most promising new test appears to be contrast magnetic resonance lymphangiography. The test is performed after intracutaneous injection of gadobenate dimeglumine into the interdigital webs of the dorsal foot.

(d) Another new test which holds promise to detect early disease is bioimpedance **spectroscopy**. Flow of electrical current in a particular region of the body is inversely related to the amount of fluid in the tissue. With early lymphedema and increased interstitial fluid, impedance decreases. While tested in small samples, sensitivity and specificity has been found to be 100%.

Management

1. Conservative measures

- Drug therapy: In case of filarial lymphedema; DEC* 4-6 mg/kg body weight/day 3 week.
- Antibiotics and antifungals if secondary infection has occured in the limb.
- Elevation of affected limb.
- Compression with elastic garments (most effective method)

* DEC = Diethyl carbamazine. (Hetrazan)

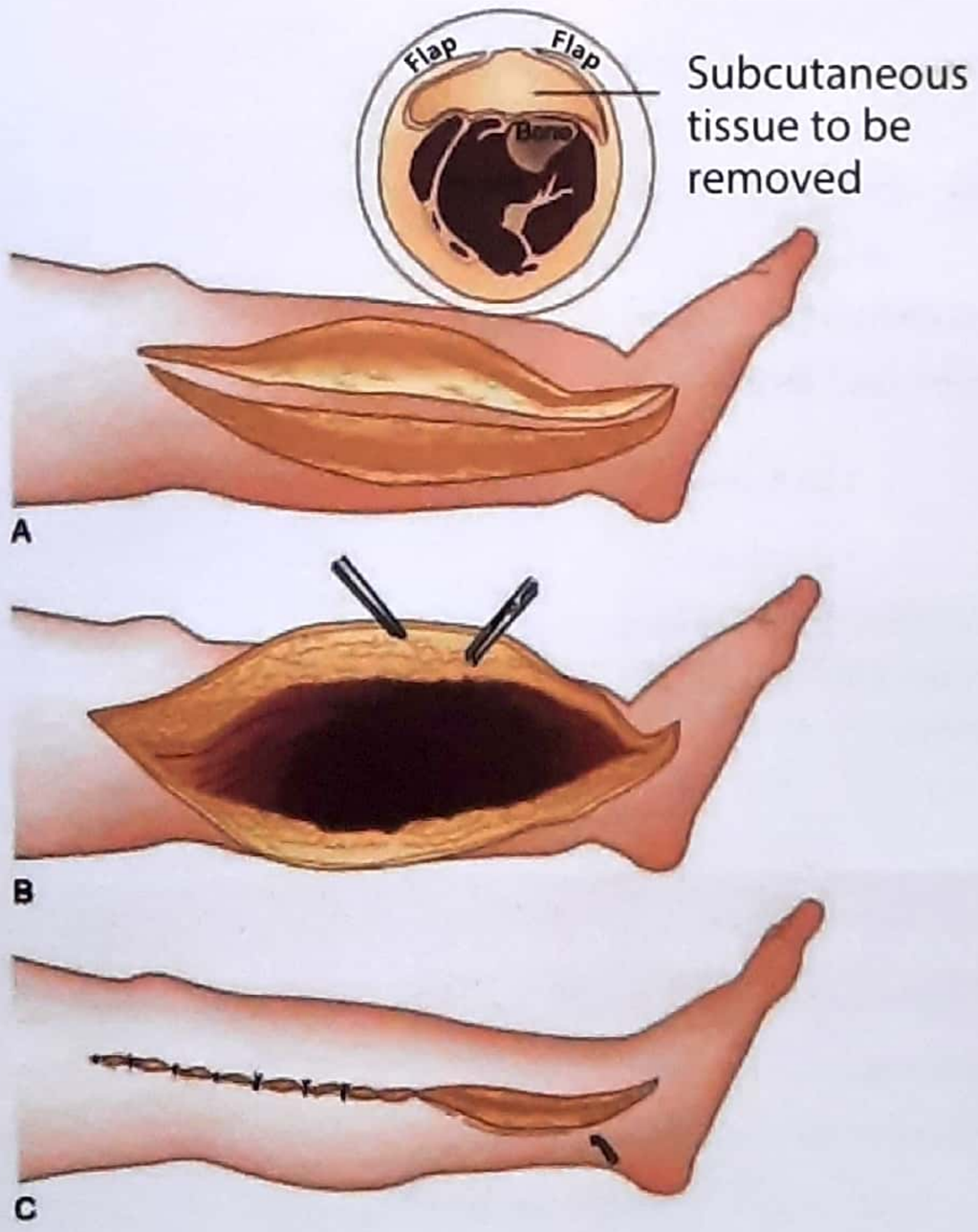

Figure 24.14: (A-C) Schematic representation of the Kontoleon or Homan procedure. Relatively thick skin flaps are raised anteriorly and posteriorly, and all subcutaneous tissue beneath the flaps and the underling medial calf deep fascia are removed along with the necessary redundant skin.

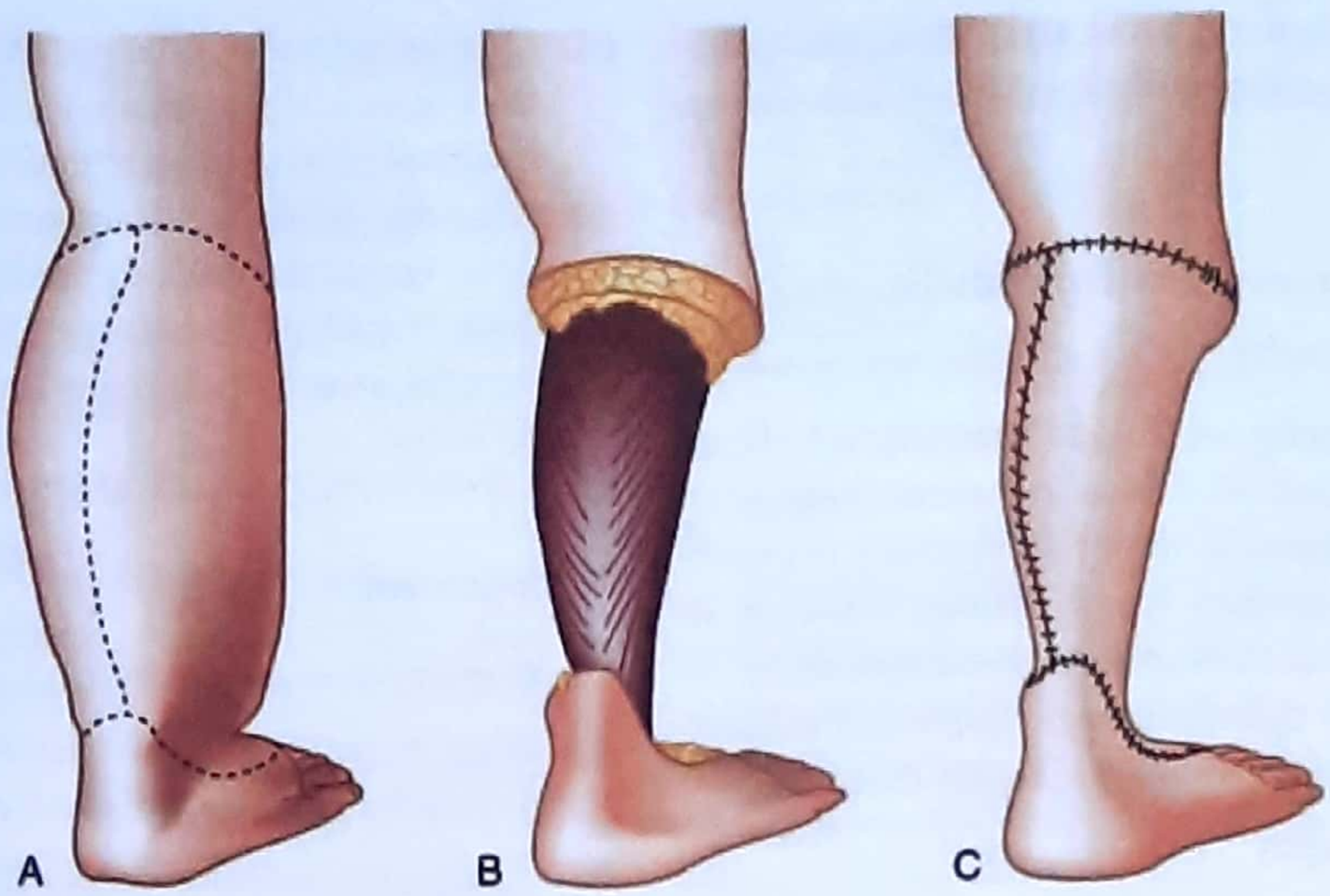

Figure 24.15: (A-C) Schematic representation of the Charles procedure. It involves complete and circumferential excision of the skin, subcutaneous tissue, and deep fascia of the involved leg and dorsum of the foot. Coverage is provided preferably by full-thickness grafting from the excised skin

2. Surgical treatment of lymphedema

(i) Debulking or excisional surgery:

Removal of edematous subcutaneous tissue is done to, reduce the lymphatic load from the epifascial compartment. Various surgical options are:

- Skin flap operation - Homan's operation (figure 24.14), sistrunk operation.
- Skin graft operation - charles operation (figure 24.15)
- Dermal flap operation-Thompson's swiss role operation.

(ii) Lymph drainage surgery

Since they do not reduce the size of limb, they are not done these days. Many of these are now of historical importance. Some of them are listed below:

(a) Kondoleon operation : In it drainage through windows in deep fascia is achieved.

(b) Mortorell's operation : Drainage is done through pedicled fascia.

(c) Omental Transposition : Omentum with a gastroepiploic vessel pedicle is used for drainage.

(d) Lymphovenous shunt (PGL 97) : This is done in filarial lymphedema, where dilated lymphatic channels are dissected and anastomosed to nearby veins by end to end anastomosis.

****

Sample Questions for Prof Examination

1. Discuss varicose veins of lower limb.
2. Discuss etiology, diagnosis and treatment of varicose veins.
3. Discuss venous system of lower limb. Discuss varicose veins
4. Discuss the method of diagnosis and management of varicose veins of the lower limb
5. Describe the pathology, clinical features and treatment of varicosities of the long saphenous vein.

25 The Breast

Contents

- Congenital abnormalities of breast
- Surgical anatomy
- Manifestation of breast disease
- Investigation of breast disease
- Mastalgia
- ANDI
- Inflammatory and related lesions of breast
- Benign neoplasm of breast
  - Fibro adenoma
  - Phylloid tumour
  - Duct papilloma
- Malignant neoplasm of breast
- Breast reconstruction
- Gynecomastia

Development of Breast

The epithelial lining of the ducts and acini of the breast is developed from ectoderm and supporting tissue is derived from mesenchyme. On each side of the ventral surface of young embryo, a thickened band of ectoderm develops called as the milk ridge; (see figure 25.1 on next page). It extends obliquely from axilla to inguinal region. In the human, the whole of this ridge atrophies, except only a small portion in each pectoral region, from which breast arises. Accessory breast tissue may occasionally arise along the course of milk ridge.

******

CONGENITAL ABNORMALITIES OF THE BREAST

Amastia

This means that there is no development of breast tissue. Bilateral absence of breast tissue and nipple is very rare. When breast tissue is unilaterally absent, the pectoral muscles of that side are also absent.

Polymastia

There is more than one breast on one or both side. The accessory breast tissue can occur any where along the milk ridge; but usually 7-10 cm below and medial to normal nipple. Accessory breast has been recorded in axilla (M/C site), groin, buttocks and thigh. See figure 25.1

Polythelia

There is imperfect development of mammary rudiment so that supernumerary nipple are situated irregularly over the breast.

Athelia

Absence of the nipple, a very rare condition.

******

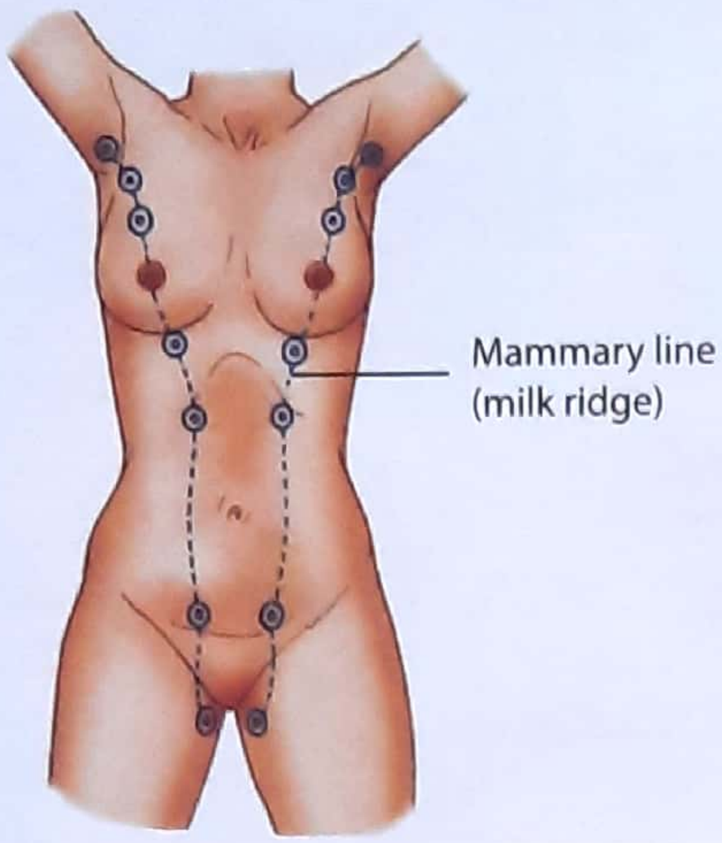

Figure 25-1: Accessory nipple may appear along the course of milk line

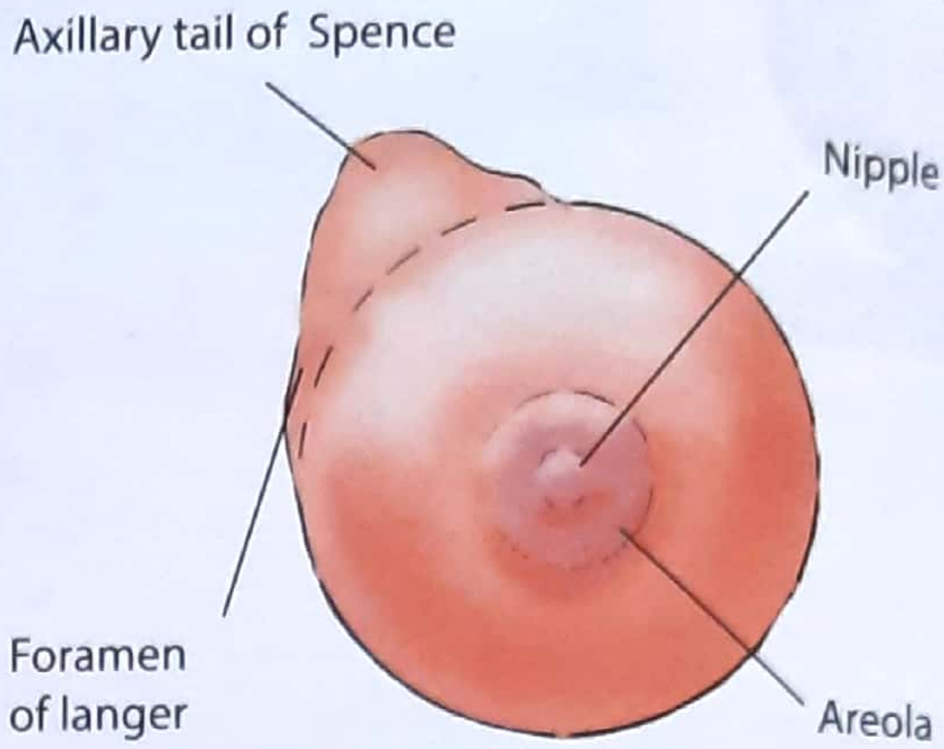

Figure 25.2: Axillary tail

SURGICAL ANATOMY

Extent

Vertical

Between 2nd to 6th rib.

Horizontal

It extends from the lateral border of sternum to mid axillary line.

NOTE : Mid axillary line is a vertical line drawn midway between the anterior and posterior axillary folds.

Axillary Tail of Spence

This is prolongation from the outer part of gland which passes up to the level of the 3" rib in axilla, where it is in direct contact with main lymph nodes of breast. This process of breast tissue enters into the axilla through an opening in the axillary facia, known as foramen of Langer (fig. 25.2). It is to be noted, that axillary tail in under the deep facia and not like the breast; which is superficial to this layer. When axillary tail is enlarged, it may be mistaken to a lipoma.

Architecture of Breast

The breast is composed of acini, which make up lobule, aggregations of which form the lobes of glands. The lobes are arranged in a radiating fashion like the spoke of a wheel & converge on nipple, where each lobe is drained by a duct.

Ten to fifteen collecting duct open onto nipple. Each duct draining a segment system of smaller duct and tubules (figure 25.3). The ducts are surrounded by connective tissue.

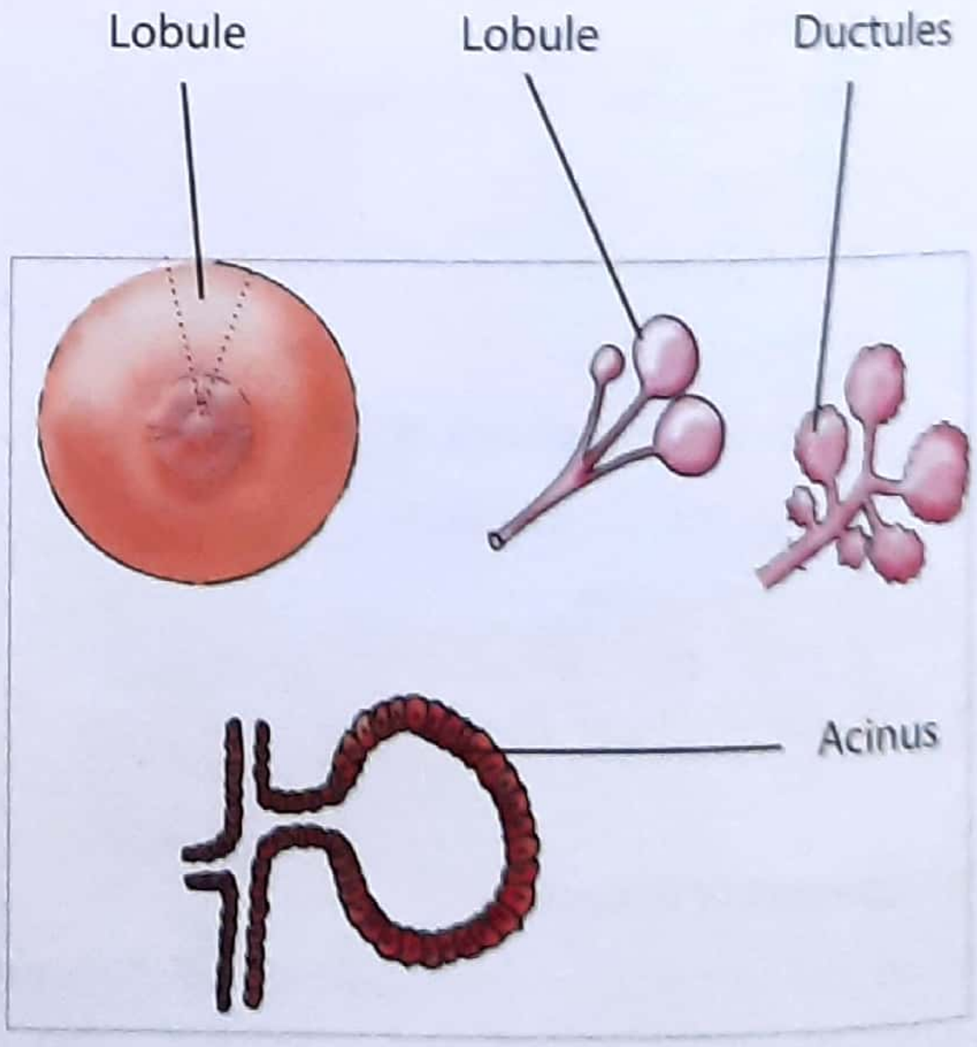

Figure 25.3: Architecture of Breast

Ligament of Cooper

The breast is anchored to the overlying skin and to underlying pectoral fascia by a band of connective tissue called ***"Ligament of cooper"*** (Fig. 25.4).

In breast cancer the malignant cell may invade, these ligaments and consequent contraction of these strand may cause ***dimpling of skin*** *(NEET)*, or firm attachment of un- derlying growth to the skin. In this condition; when skin is involved, skin can not be pinched up from the lump (breast cancer).

If the cancer cell grow along the ligament of cooper which binds the breast to the pectoral fascia, the breast become fixed to pectoralis major. It cannot then be moved in long axis of muscle.

Areola

The skin surrounding the base of nipple is pigmented and forms a circular areas called areola. This region is *rich in modified sebaceous gland*. *These glands enlarge during pregnancy and lactation to form raised* ***tubercles of Montgomery***. *(PGME)*

Blood Supply

1. *Internal thoracic artery* - a branch of subclavian artery through its perforating arteries.
2. The lateral thoracic, superior thoracic and acromiothoracic arteries.
3. Lateral branches of posterior intercostal arteries.

Lymphatic Drainage

Lymph node draining the breast *(MANY PGME)*

(Mnemonic : CIPLAA)

1. **C**-Central group
2. **I**-Internal mammary
3. **P**-Posterior axillary
4. **L**—Lateral axillary
5. **A**-Anterior axillary
6. **A**-Apical

Some lymph from breast also reaches the supraclavicular node, cephalic and posterior intercostal nodes.

The axillary lymph nodes, grouped by location, are shown in Fig. 25.2 & 25.6. Axillary nodes are typically described as three anatomic levels defined by their relationship to the pectoralis minor muscle. Level I nodes are located lateral to the lateral border of the pectoralis minor muscle. Level II nodes are located posterior to the pectoralis minor muscle as well as anterior to the pectoralis minor and posterior to the pectoralis major (Rotter or interpectoral nodes).

Level III nodes are located medial to the pectoralis minor muscle and include the subclavicular nodes. The apex of the axilla is def ined by the costoclavicular ligament (Halsted ligament),

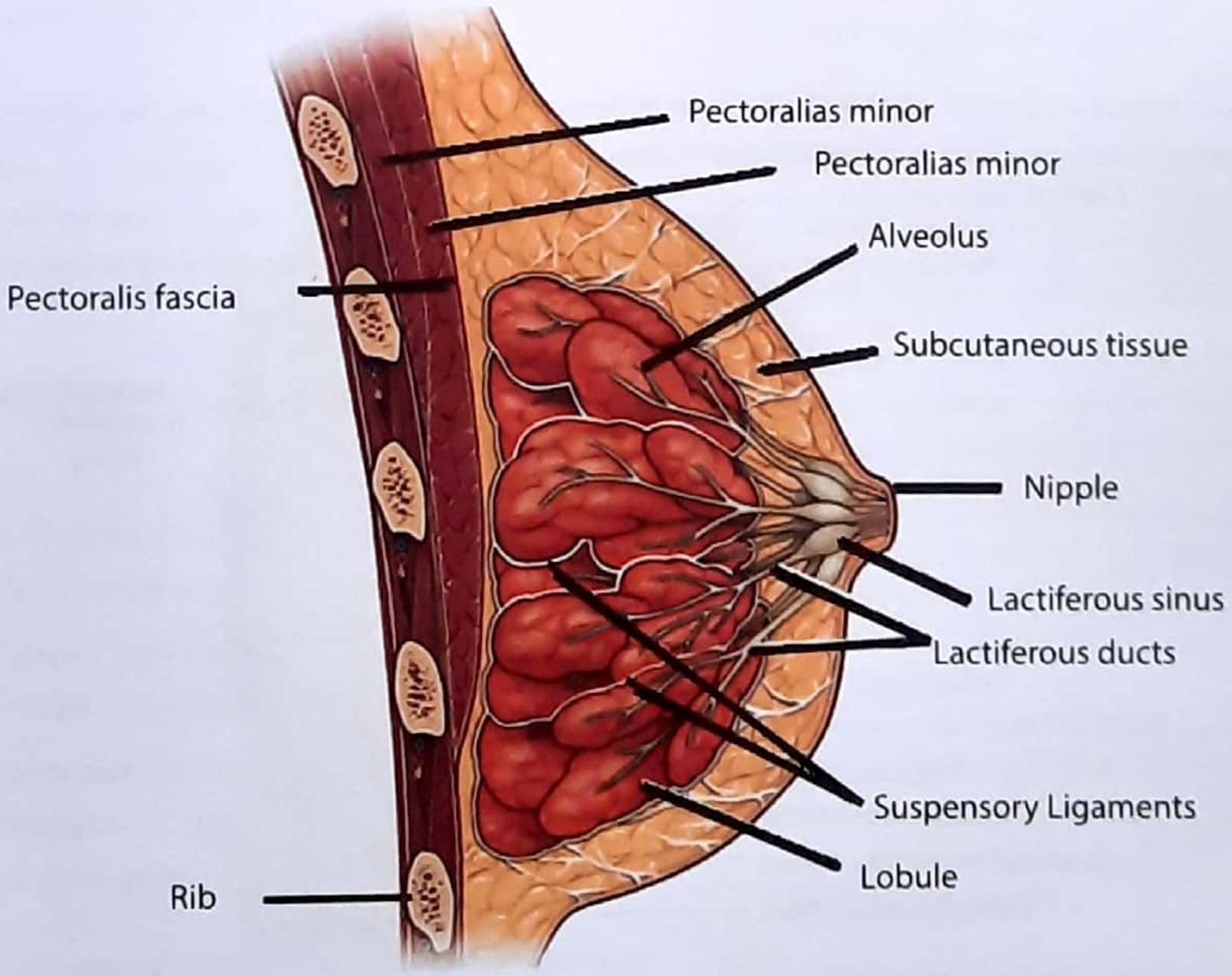

Figure 25.4: Architecture of the breast

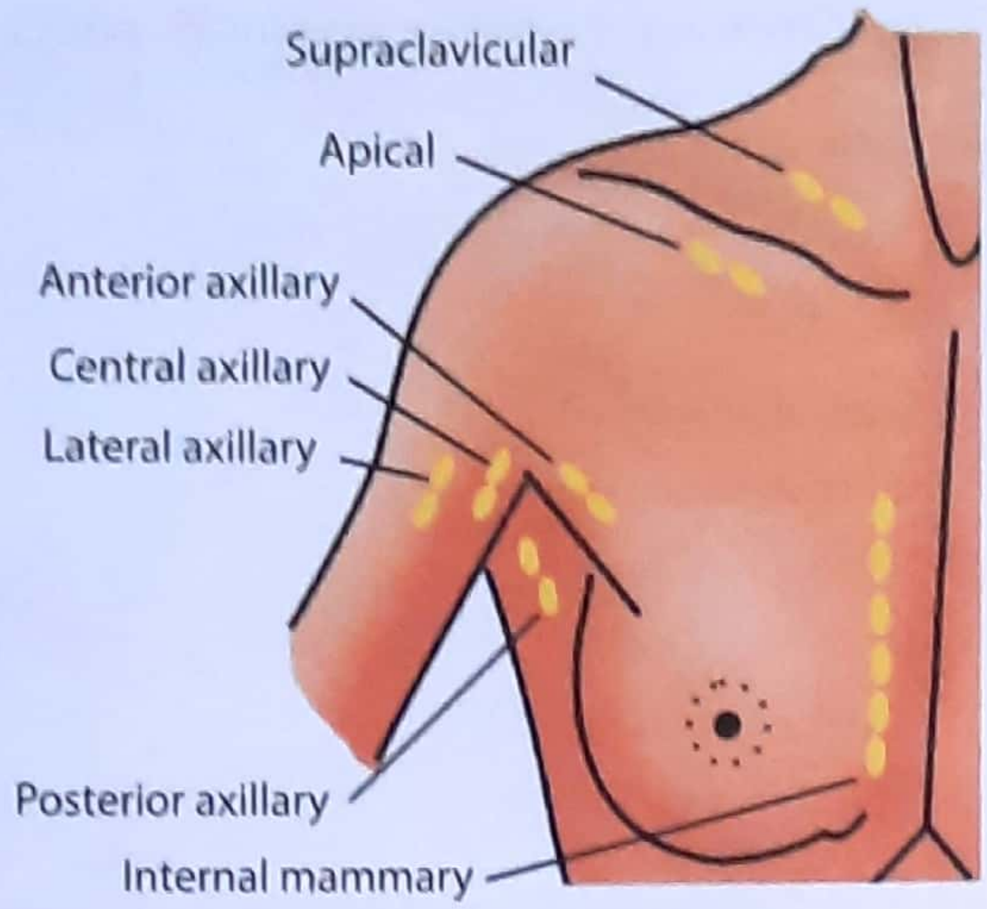

Figure 25.5 : Lymphatic drainage of breast

Lymphatic Vessels of The Breast

(A) Superficial lymphatics

They drain the skin over the breast except from nipple and areola, then the lymphatics pass radially to reach axillary, internal mammary, supraclavicular & cephalic lymph nodes.

(B) Deep lymphatics

They drain the parenchyma of the breast, nipple and areola.

About 75% of lymph from the breast drain into axillary lymph nodes, (NEET) *20% into the internal mammary nodes,- and only 5% into posterior intercostal nodes.*

Among the axillary nodes the lymphatics end mostly in anterior group (closely related to axillary tail) and partly in posterior and apical groups. Lymph from the anterior and posterior group passes to the central and lateral group and through them to apical group.

Sentinel node? It is the first lymph node draining the tumour bearing area of breast.

Now ***lets come to the point***

******

MANIFESTATIONS OF BREAST DISEASE

Breast disease manifest itself in one or combination of the following.

1. **Breast lump**
2. **Nipple discharge**
3. **Mastalgia (Painful breast)**
4. **Skin changes (over breast)**

Now lets take them one by one

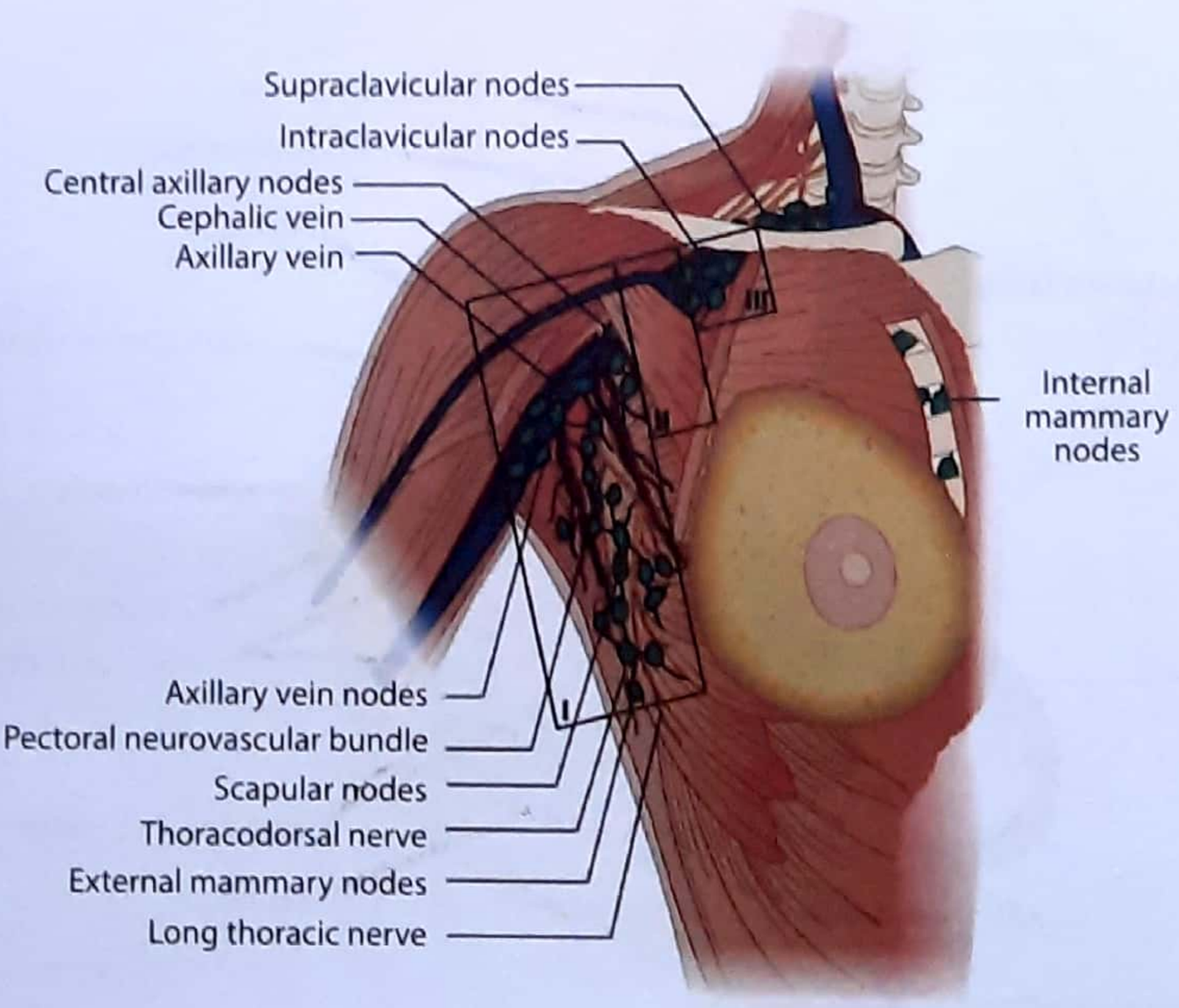

Figure 25.6 : Contents of the axilla. In this diagram, there are five named and contiguous groupings of lymph nodes

1. BREAST LUMP (BREAST MASS)

A mass in the breast is earliest manifestation of breast carcinoma and is therefore the most important symptom of breast disease.

Any mass in the breast must be evaluated for its cancer potential. This is particularly important:

1. If the patient is over 30 years
2. If the mass is of recent onset
3. If the mass has increased in size recently
4. If the mass is solitary
5. If the mass is solid

Solitary cyst of breast is clinically diagnosed by fluctuation test. The swelling is held with one hand and by the other hand the centre of the swelling is pressed, This displaces the fluid towards periphery, which is elicited on the holding hand which is displaced outward. ***If lump is fixed, indicates infiltration of pectoralis muscle & fascia.*** *(NEET)* **Aspiration* of the cyst is diagnostic** and on aspiration, one should look for:

(i) If aspirate is not blood stained,

(ii) There is no residual lump after aspiration

(iii) The cyst after aspiration does not refill

(iv) If the cytological evaluation of the aspirated fluid does not show evidence of malignant cell.

If above all four criteria are negative; the cyst can be considered as benign cyst (not malignant).

Consider cystic lesion, as a balloon filled with water.

NOTE: ***Aspiration** - Means sucking the fluid by a wide bore needle (usually by No. 18) after creating negative pressure by a syringe.

2. NIPPLE DISCHARGE

- Discharge from nipple is a common symptom of breast disease. Discharge of milk occurs in pregnancy and lactation and rarely at other times (Galactorrhea).
- Non-hemorrhagic nipple discharge is a common symptom in breast showing fibrocystic disease.
- Bloody discharge occurs in fibrocystic disease and in intraductal neoplasms; *most commonly intraductal papilloma and carcinoma*. *(MANY PGME)*

NOTE: ***Grumous means:** made up of coarse granular bodies in the centre.

Causes of nipple discharge (Key box: 25.1 & 25.2)

1. **Physiological causes :** During pregnancy & lactaption
2. **Galactorrhea**

This means secretion of milk not related to pregnancy or lactation. Causes include stress and mechanical stimulation of breast.

- Galactorrhea may occur as secondary phenomenon.
- It may occur as side effect of drugs that enhances dopamine activity, eg; chlorpromazine, metoclopramide and methyldopa .
- Hyperprolactinemia due to a prolactin secreting tumour or from a secondary source, such as *bron- chogenic carcinoma can cause galactorrhea.* *(MANY PGME)*

3. Duct Ectasia

Ectasia a Greek word means dilatation of any tubular vessels.

- In this there is abnormal dilatation of ductal system of the breast.
- It is a *commonest cause of nipple discharge*. It is often bilateral. The character of discharge is thick, opaque and of varying colour. *(MANY PGME)*

4. Fibrocystic Disease:

It produces multiple ductal discharge

5. Duct papilloma

The discharge is from a single duct. It is either serous* or serosanguineous** or frankly bloody.

NOTE:

1. What is serous discharge and serosanguinous discharge?

   Serous*- means having the nature of serum, Sanguineous - Sanguineous means bloody; so serosanguineous discharge contains both substances, ie; serum and blood.

2. Papillomas? is nipple like benign epithelial tumour [literary meaning of papilla, from which papilloma is derived, is nipple like]

6. Carcinoma

Papillary intraductal carcinoma and invasive carcinoma of breast can present as nipple discharge.

7. Unknown causes

Please go through key box 25.1, 25.2 & 25.3 before concluding this topic

Varieties of Nipple Discharge

1. Milk discharge

Often seen in late stage of pregnancy and in lactating mothers. Milk discharge can also be seen in case of "milk fistula" resulting from subareolar mastitis/subareolar abscess. Milk discharge is also occasionally seen with galactocele.

2. Serous discharge

When the discharge is serum like. It may be found in:-

(i) Continuous use of contraceptive pills

(ii) Fibroadenosis

(iii) Mammary duct ectasia

NOTE:

(i) Greenish black discharge is more common in fibroadenosis than serous discharge.

(ii) Thick creamy discharge is more common in mammary duct ectasia than serous discharge.

3. Bloody discharge

(i) Infiltrative or noninfiltrative ductal carcinoma

(ii) Duct papilloma. *(UP 97)*

(iii) Rarely in pregnancy due to physiological epithelial hyperplasia.

4. Greenish discharge *(AIIMS 98)*: Typically in duct ectasia and some times in ANDI.

KEY BOX 25.1

Cause of Nipple Discharge

(AIIMS 93, 97, 98, 04, PGI 97, 01, 04, AI 2005)

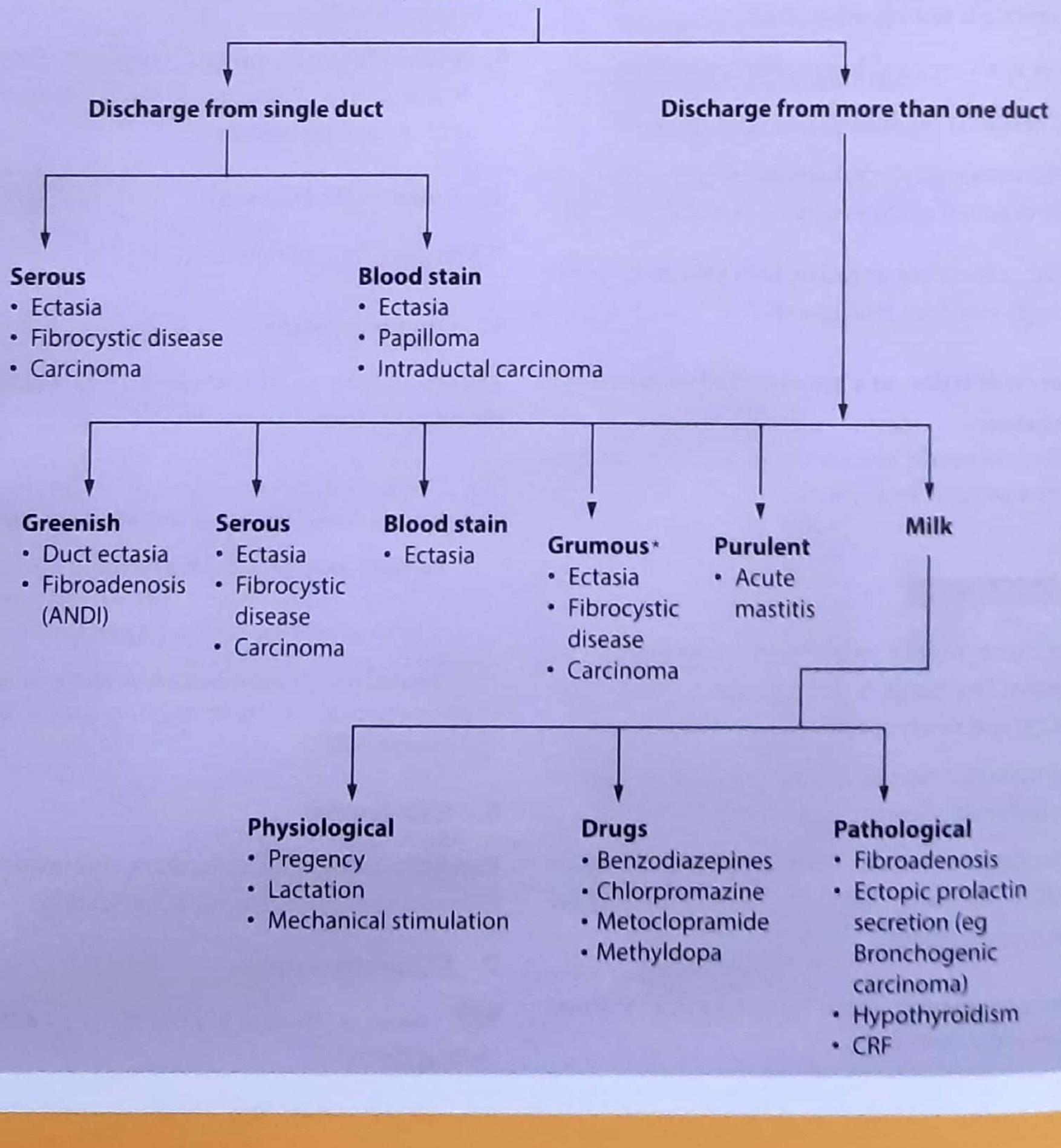

KEY BOX 25.2		
Type	**Causes**	
Blood stained	Single duct	Ectasia, ***papilloma*** (NEET), intraductal carcinoma
	Multiple duct	Ectasia. Fibrocystic disease, carcinoma
Serous	Single duct	Ectasia, Fibrocystic disease, carcinoma
	Multiple duct	Ectasia, Fibrocystic disease, carcinoma
Grumous		Ectasia
Purulent		Infection (mastitis), breast abscess
Milk	Physiological	Mechanical stimulation, extremes of reproductive age, post lactation
	Drugs	Drugs enhancing dopamine activity, eg; chlorpromazine, metoclopramide, methyldopa, phenothiazine and estrogen
	Pathological	Pituitary adenoma, hypothalamic and pituitary stalk lesions, ectopic prolactin secretion, hypothyroidism, CRF

5. **Black discharge :** Old blood looks black; and black discharge is seen in case of ductal carcinoma & duct papilloma.

6. **Thick creamy discharge :** is seen in mammary duct ectasia.

7. **Pus :** In acute mastitis & breast abscess.

Management of Nipple Discharge

1. Discharge from one duct, serous in nature (not bloody)

Mammography should be performed in all patient above 30 years. Exclude carcinoma by the help of various test, then all that is required is reassurance, but when discharge continues even after 3 months and is disturbing normal life of patient; *microdochectomy* is done. (*for microdochectomy = read on page 349.

2. Multifocal and serous discharge

Mammography is done to exclude carcinoma The usual cause is duct ectasia Broad spectrum antibiotics, with anaerobic coverage is recommended.

3. Bloody discharge from one duct

Mammography is performed in all patient over 30 years. Antibiotic are given and situation is observed; now read this flow chart for better understing:-

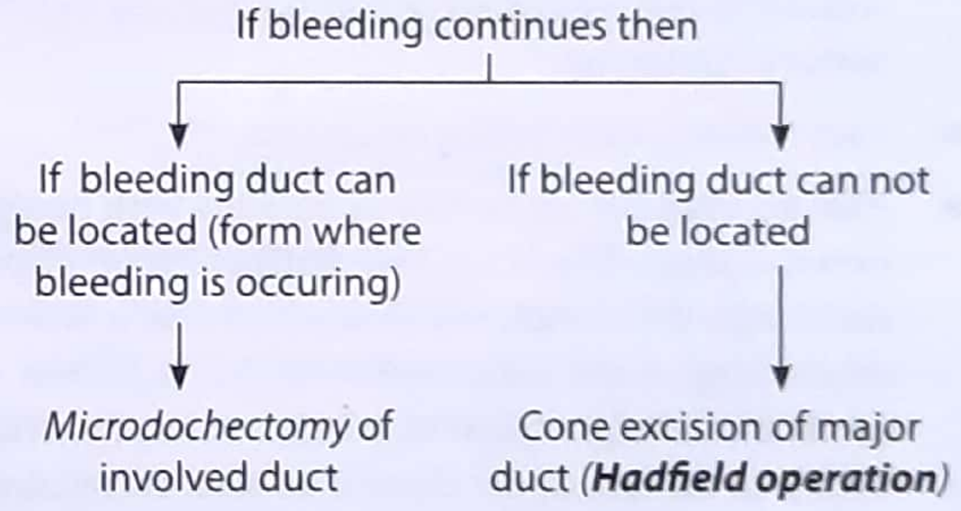

4. Multifocal and blood stained discharge

Mammography is performed. Many cases may be due to duct ectasia for which microdochectomy. In other cases duct excision (hadfield operation) should be done.

KEY BOX 25.3
Cause of nipple discharge
• Physical cause; pregnancy & lactation
• Galactorrhoea
• Duct ectasia
• Fibrocystic disease
• Duct papilloma
• Unknown cause (Idiopathic)

KEY BOX 25.4
Manifestations of Breast disease
• Breast lump • Nipple discharge • Pain (mastalgia) • Skin changes

RECAP: *Till now we have discussed Breast lump and Nipple discharge, now we will discuss other two conditions; painful breast (mastalgia) and skin changes of breast. See key box 25.4.*

3. PAIN (MASTALGIA)

- Diffuse mild pain in the breast occurs commonly during menstrual phase is many woman.
- A painful mass usually denotes an inflammatory condition, but may rarely occur in advanced inflammatory carcinoma.
- Pain is rare is early breast carcinoma, *(IMP. POINT)*
- Pain account for up to 50% of patients with benign breast disease. These are **two distinct** group of patients with this symptoms. One which *bear a definite relationship to the menstrual cycle* this is known as **cyclical mastalgia** (pain in relation with menstrual cycle). In the remainder there is no such correlation, and is termed as **noncyclical mastalgia.**
- Cyclic mastalgia will be discussed under the topic ANDI; (later in this chapter)
- Noncyclical mastalgia is less understood than its cyclical counterpart. It is more chronic (present from a long time) unilateral and located in medial quadrant and in peri-areolar region. The pain is noncyclical mastalgia is moderate in severity and is burning in nature rather than 'heaviness' as in cyclical mastalgia, It is important to note that in most cases with noncyclical mastalgia pain does not arise from the breast itself, but from the surrounding musculoskeletal structure. This topic has been discussed in detail later in this chapter.

RECAP: *Friends till now we have discussed 3 important features of breast disease ie. lump, nipple discharge & painful breast. Now; lets discuss skin changes in breast disease, please See box 25.4 once again*

4. SKIN CHANGES

May be due to underlying advanced cancer or due to inflammatory condition of breast.

1. **Erythema (redness)** - found in
   - Acute mastitis (Fig. 25.7a)
   - Inflammatory carcinoma

2. **Peud d' orange**

Lymphedema in advanced breast carcinoma produces skin thickening and pitted appearance and is known as "Peud d' orange" = Orange skin appearance (Fig 25.7b and 25.7a).*(UP 05, MANY PGME)* . Which is most conspicuous sign of breast cancer.*(AIIMS NOV. 18)* Also see figure 25.8, next page.

Figure 25.7a : Erythema of Breast

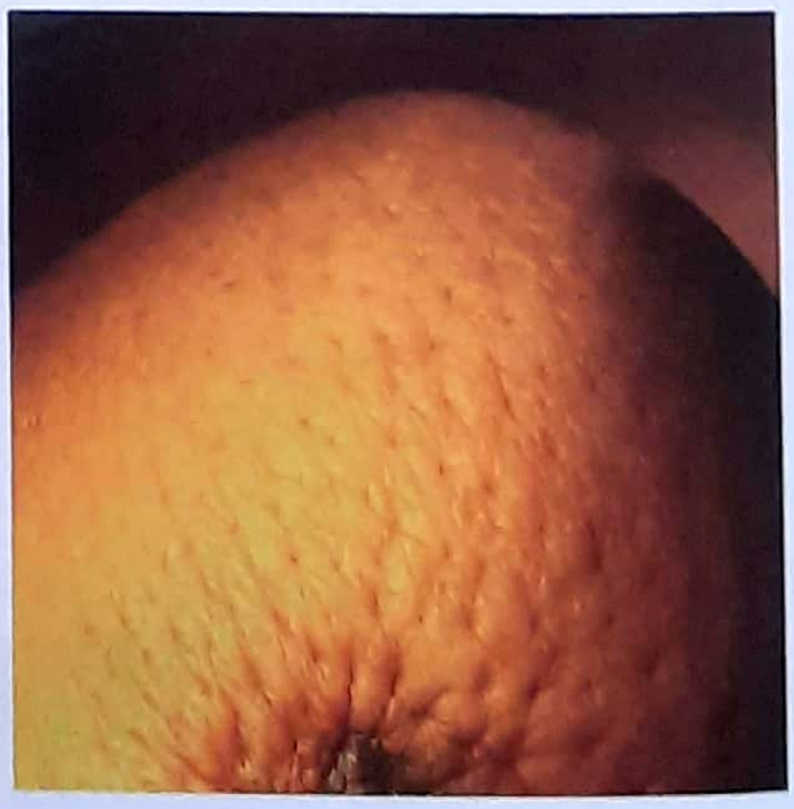

Figure 25.7b : Peud d' orange

Figure 25.7c : Cancer-en-Cuirasse

Figure 25.7d : Slit shaped nipple

Figure 25.7e : Nipple retraction

3. **Cancer-en-Cuirasse**

In advanced Carcinoma of breast there may occur frank ulceration and fixation of breast to chest wall (fixation to underlying pectoralis muscle).

4. **Skin changes in Paget's disease**

Eczema like appearance of over lying breast skin.

5. Nipple invasion occurs due to involvement of subdermal lymphatics.

6. Slit shaped nipple is seen in duct ectasia.

7. Nipple retraction in Carcinoma Breast due to infiltration of lactiferous ducts.

******

Now we will discuss relevant investigations related with breast diseases.

INVESTIGATION OF BREAST DISEASE

- Mammography
- Ultrasonography of breast
- MRI
- FNAC
- BIOPSY
- USG of abdomen in case of metastasis
- Bone scan to know bony metastasis.

Now lets discuss them one by one

1. Mammography *(AIIMS 99, 03, PGI 99, 04)*

- *X-ray of the soft tissue of breast is called as mammagraphy*
- The film used is ultrasensitive film and X-ray exposure used is very low voltage and high amplitude X-rays. Dose of radiation is ***very low (IcGY), hence safe*** *(NEET)* and has very little chances of causing carcinoma.
- **Two images** are obtained; at **right angle to each other**. *(NEET)*
  (1) Cranial caudal
  (2) Mediolateral oblique (MLO)

  ↓

  Maximum breast tissue
- Mammography is *most useful when the breasts contain little dense glandular tissue and are composed mainly of fat*. Therefore; it is less accurate and reliable in younger women; because they have firm breast.

Figure 25.8: Advanced carcinoma breast: Growth is seen on lower part of the breast and there is typical Peau-d'-orange (orange peel) effect on the breast skin

- Mammography is capable of showing breast cancer at a stage before it is palpable. (UP 2000)
- In general mammography is reserved for women *over the age of 40 years.* (AIIMS MAY 15) It *should be carried out in younger women if there is suspicion of cancer.* (NEET) Only 5% of breast cancers are missed by population based mammographic screening program.
- *Routine screening mammography is done after 40 years of age.* (NEET)
- *RCT have demonstrated a 30% reduction in breast Ca mortality in women 50-69 yr who are screened annually with mammography.* (NEET)

Mammographic Appearance of Fibroadenoma (INICET)

Fibroadenoma produces popcorn calcification *on mammography* (MANY PGME) . See box 25.5.

Mammographic feature of malignancy (MANY PGME)

1. *Micro-calcification*: (<5mm) comprising multiple (about 3) particles of *irregular shape* and calcification.
2. Soft tissue opacity with *irregular* or *speculated* margin
3. Area of distortion of breast architecture
4. Presence of large tentacles [like that of hydra] Tentaculation. Please see figure 25.9 & box 25.5.

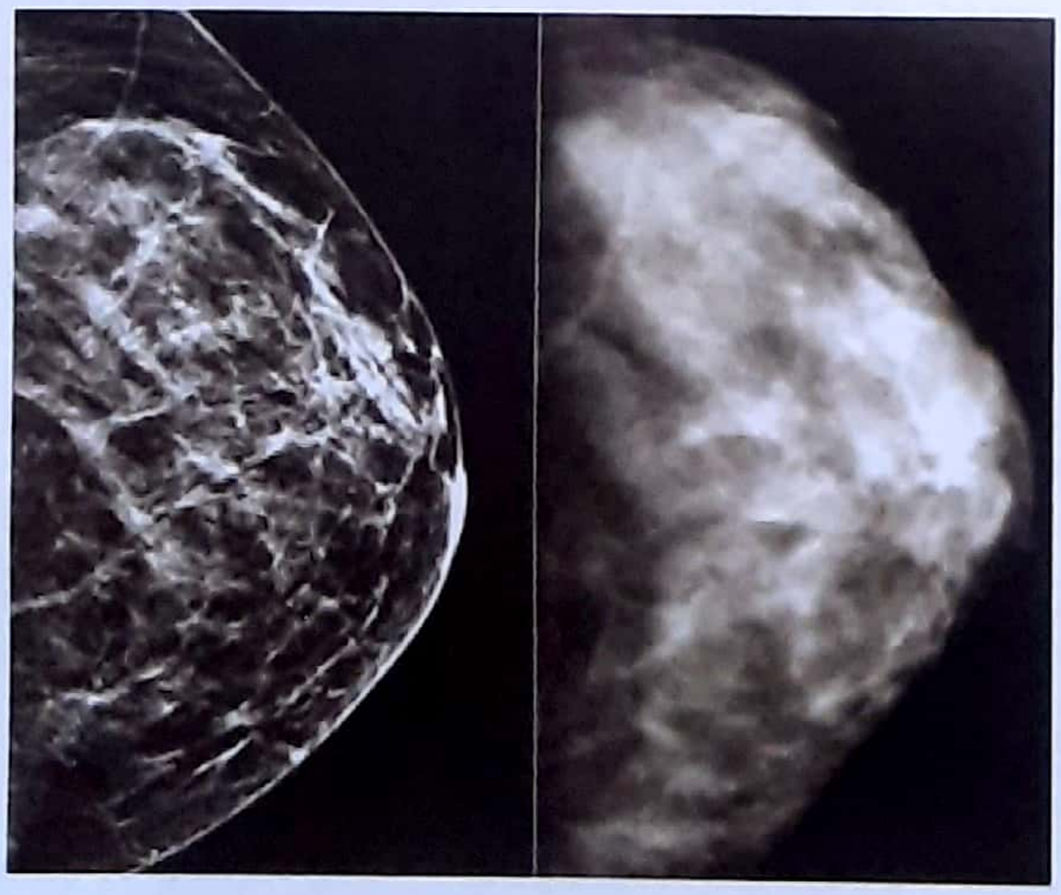

Figure 25.9: Mammographic feature of CA breast

KEY BOX 25.5

Distinguishing Feature Between Benign and Malignant Lesion on Mammogram (PGME-MANY TIMES)

Feature	Benign	Malignant
Opacity (PGI DEC 99)	Smooth margin (Homogeneous Irregular)	Ill defined, Spiculated margins
Calcification	Macrocalcification (> 5 mm) (AIIMS 03)	microcalcification (<5 mm)
Parenchyma	Normal architecture	Distorted architecture
Skin	Normal	Thickened
Ducts	Normal	Focal dilation
Cooper's ligaments	Normal	Thickened

2. Ultasonography

Ultrasound examination is useful in *patient who are* ***under 40 years*** *and has relatively dense breast,* in whom mammography is less accurate, USG also helps in distinguishing cystic and solid lesions. ***USG is first investigation in women under 40 yrs.***(NEET PATTERN)

3. Magnetic Resonance imaging (MRI)

- It is useful in diagnosing local recurrence of breast cancer after conservative breast surgery.
- Management of axillary lymph node in breast cancer.
- It is done in **high risk** (NEET) cases.

Indication of MRI -

1. To distinguish scar from recurrence in women who have had previous BCS, for cancer.
2. To assess multifocality & multicentricity in lobular cancer & to assess the extend of high grade DCIS.
3. Best imaging modality for breast of women with implants.
4. Screening tool in high risk women (because of family history).

BCS = Breast Conservative Surgery

4. Aspiration and FNAC (PGI 03, AI 01, VERY IMP.)

Aspiration is done by using a wide bore needle and is performed is case of a cystic lump, which is thought to be benign; but if the aspirated fluid is blood stained and if mass does not completely disappear on aspiration, or if the cyst refills rapidly even after two aspirations, this may be a malignancy, and excisional biopsy should be considered to confirm the nature of lump. Aspirated fluid should be sent for cytological examination to a pathologist.

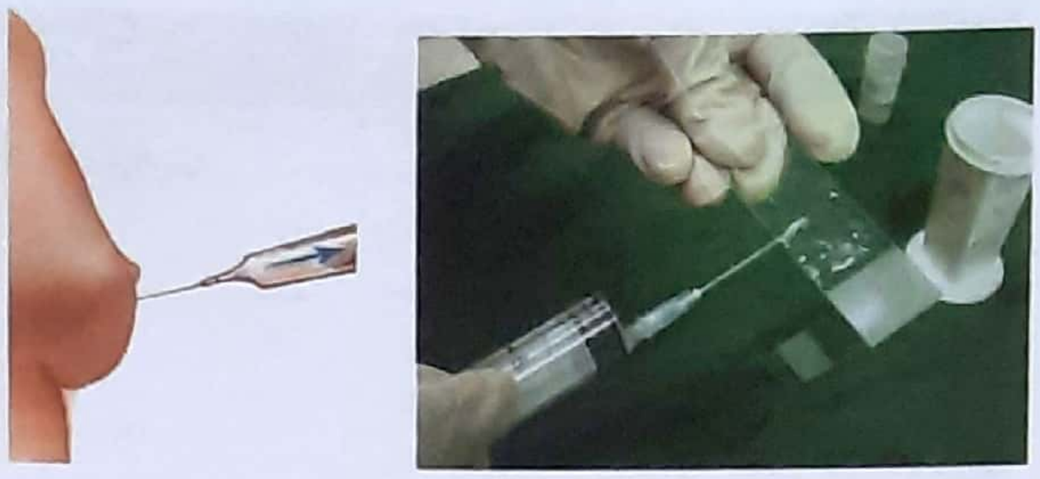

Figure 25.10 : Method of performing FNAC

FNAC (Fine needle Aspiration Cytology)

It has become an almost routine practice in investigation of breast lump. **What is it ?** As the name suggest FINE NEEDLE ASPIRATION CYTOLOGY; - With a fine needle (usually 21 gauge) the suspected lump in the breast is aspirated many times (4-5 times), in several direction after making negative suction pressure by a syringe, and the aspirated material is smeared on a glass slide. This material is sent for cytological examination to a histopathologist (figure 25.10).

FNAC is a next investigation in pregnant female with breast lump if USG comes normal. (NEET)

Advantage

- About 90% of malignant breast lump can be diagnosed
- This can be performed in OPD & is relatively cheap.
- Relatively less traumatic (only a fine needle of 21 gauge is introduced in breast)

Disadvantage

- It requires expert histo-pathologist for accurate cytological interpretation.
- Can not differentiate between in-situ and invasive cancer, (can not differentiate between ductal and lobular carcinoma). (NEET PATTERN)
- False negative results can be in as many as 15% mainly due to missing the tumour at the time of aspiration.

5. Biopsy

Best and definitive investigation of breast lump is by biopsy. (INICET MANY PGME)

(a) True-cut or core biopsy

If FNAC is equivocal or negative; a core biopsy is obtained using true cut needle; which removes a core of breast tissue, for histopathological examination.

(b) Open Biopsy

It is indicated if the core biopsy report is negative and there is strong suspicion of cancer. Open biopsy is of two type:

(i) *Incisional Biopsy*

(ii) *Excisional Biopsy*

The most reliable diagnostic test for breast cancer is open excisional biopsy (AIIMS NOV. 01)

? What is Biopsy : This is done by obtaining tissue sample for microscopic examination, usually to establish diagnosis. The tissue may be obtain surgically or through needle and syringe. The procedure can be guided by CT, MRI, USG and named upon the same.

Excisional biopsy? Removal of the *whole mass* which may become a part of the treatment also.

Incisional biopsy? Removal of a ***piece or small pieces*** from the lesion, after making a small incision on tissue.

Triple Assessment

As the name suggest, assessment of breast disease by using three procedure. Key box 25.6. (MANY PGME)

1. Clinical assessment
2. Radiological imaging
3. Tissue sample taken for either cytological or histological analysis.

KEY BOX 25.6

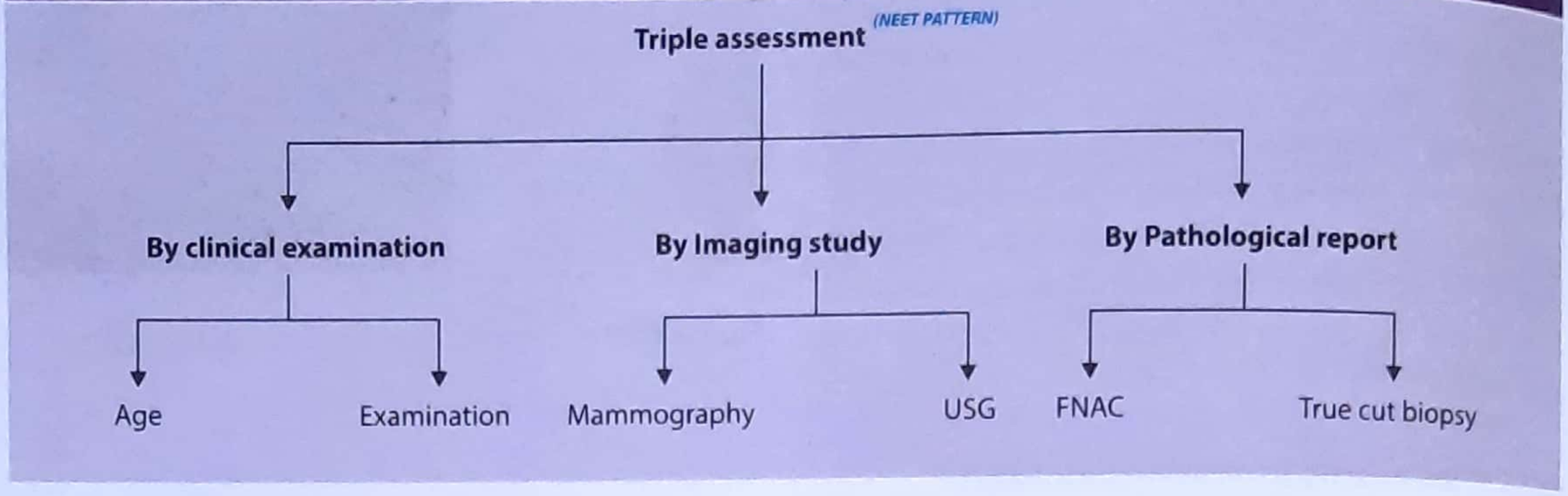

With the use of triple assessment diagnosis of breast lump *can be made accurately in about 99% cases.*

BIRADS

BIRADS stands for **B**reast **I**maging **R**eporting **A**nd **D**ata **S**ystem.

It is based on imagig finding i.e., Mammography, USG, MRI.

BI-RADS CATEGORIES

Category	Definition	Follow-up
0	Incomplete assessment	Additional imaging evaluation
1	Negative	Annual screnning
2	Benign	Annual screening
3	Probably Benign	6 monthly mammogram for next 2 yr.
4	Suspecious abnormal (2% - 95%)	Biopsy
4a	2% - 10%	
4b	10%-50%	
4c	50%-95%	
5.	Highly suggestive of malignancy (>15%)	Appropriate action s/b treatment
6.	Known Biopsy proven malignancy	Appropriate treatment

Friends; till now we were discussing investigation part related with the breast disease; now we will discuss diseases related to breast.

MASTALGIA (BREAST PAIN)

Breast pain is a one of the most common complaint in female patients attending breast clinic. There are two groups of patients with these symptoms:

Types

1. Cyclical mastalgia

In this group, *patient bear a definite relationship of pain to menstrual cycle*. Cyclical mastalgia usually, affect younger women between twenties and thirties and symptoms last up to menopause. This is often a bilateral condition; ie; affecting both breast.

The mastalgia is related to menstrual cycle and there occurs *fullness, heaviness and discomfort with mild to moderate pain experienced few day before each menstrual cycle* (AIIMS 98) . Pain usually vanishes with the onset of menstruation.

2. Non cyclical Mastalgia

Noncyclical mastalgia occurs in older age group around mid forties and is not related to menstrual cycle. Pain may occur continuously; though patient may have pain-less intervals. Non cyclic pain may be due to:

(a) Trigger point of pain

(b) Trauma to breast

(c) Costo-chondritis-Teitze's syndrome

(d) Mondor's disease

(e) Idiopathic causes

- Trigger point pain is well localized pain in breast and there is constant tenderness on palpating breast.
- Old trauma whether direct, mechanical or surgical trauma may be a cause of noncyclic mastalgia.
- ***Teitze's syndrome:*** Costochondritis of 2nd rib may cause breast pain
- **Mondor's disease:** This is *thrombophlebitis of the superficial vein of the lateral thoracic wall* (PGME). This is a rare cause of breast pain. On careful inspection of chest wall, a cord like structure can be seen; which is nothing but a thrombosed superficial vein on breast (AI 96, PGI 02).

Management of Mastalgia

A careful history must be taken and should correlate the pain with menstrual cycle to differentiate with cyclic mastalgia and noncyclic mastalgia. Only about 10% of patients with breast carcinoma present with pain.

Investigation that may be required are breast imaging (mammography/USG) and FNAC (discussed above).

KEY BOX 25.7

Mastalgia

Cyclical	Non cyclical
• Pain precedes the menstrual cycle • Associated with premenstrual nodulariry and breast discomfort	• No relationship with menstrual cycle • Pain may *be* due to "Trigger spot" - Trauma to breast - Costo-chondritis - Mondor's disease
• Patients are usually between 20-30 year	• Usually above 35 year.
Treatment	
• Reassurance • Drug-evening primrose oil • Bromocriptine • Exclude caffeine from diet	• NSAID are beneficial • Injection with local anesthetic at trigger point

(a) Treatment of Cyclic mastalgia

In about 90% of patient cyclic mastalgia require no treatment, other than simple assurance. They should be advised to *wear firm bra during day hours and soft bra during night*. About 5-10% of female however will continue to have pain; they should be advised to exclude caffeine and should be prescribed following drugs:

Drugs used

1. Evening primrose oil (Tab. Primosa)
2. Danazol
3. Bromocriptine
4. Tamoxifen citrate-not recommended now.

(b) Treatment of Non-Cyclical mastalgia

For noncyclic mastalgia it is important to exclude ex- tramammary cause. Treatment of underlying cause is carried out. Well supported bra can relieve pain to some extent. Constant wearing of bra is recommended. Paracetamol is effective for treatment of severe pain and Injection therapy with local anesthetic with steroid on a "trigger spot" can be considered in some severe cases. Kindly revise mastalgia from key box 25.7.

****

ABERRATIONS OF NORMAL DEVELOPMENT AND INVOLUTION (ANDI)

[A+ND+I]; *Aberration - means deviation from normal.*

As the name itself suggests that there is aberration in normal development of breast (during proliferation phase) and it's involution. What are these aberration in normal development and it's involution, will be discussed below.

Many names has been proposed over the years for this disorder; ***cystic disease, mammary dysplasia, chronic interstitial cystitis, FIBROADENOSIS, and fibrocystic disease*** but none of them is entirely satisfactory.

It should be noted that the disorder in younger age group ie; proliferative phase (phase of normal development or cyclic change) and disorder in older age group ie; the phase of involution (disorder of involution) have different characteristic.

Etiology

Probable etiological factor for ANDI are (though not well established)

1. Sprinters (athletes)
2. Menstrual irregularity
3. **Estrogen excess, imbalance or therapy** (NEET)
4. Multiparous women who have not fed their babies.

Changes in breast

1. Multiple changes occur in breast in various combination. Gradually the fat and supporting tissue of breast is replaced by fibrous tissue which form dense white fibrous trabeculae.
2. The **basic changes are:** (VERY IMPORTANT)
   (i) ***Cyst formation*** - Usually very small cyst
   (ii) ***Fibrosis***
   (iii) ***Ductal and lobular epithelial hyperplasia***
   (iv) ***Papillomatosis*** - This is as a result of over growth of epithelium.
3. Other change are apocrine metaplasia, calcification, chronic inflammation, sclerosing ductal lesions.
4. Cysts and fibrosis are almost constant features. It is evident from the above discussion the aberration from normal process include cyst formation, fibrosis and epithelial hyperplasia.

****

INFLAMMATORY AND RELATED LESION OF BREAST

1. Acute breast abscess (Acute mastitis)
2. Chronic breast abscess
3. Subareolar mastitis
4. Chronic subareolar mastitis
5. Retro mammary abscess
6. Tuberculosis of the breast
7. Mondor's disease

Each conditions will be discussed here one by one.

1. Acute Breast Abscess (Acute Mastitis)

Acute breast abscess are more common in developing world like India and is more common in lactating women, but about 30% patients are non lactating.

Etiology

(i) **Bacteria**
- **Staphylococcus aureus** [M/C] (NEET, UP 97)
- Staphylococcus epidermidis
- Streptococci
- Anaerobic bacteria

(ii) Blockage of lactiferous duct with epithelial debris,

(iii) Stasis in some part of lactiferous duct,

(iv) *Retracted nipple*

(v) *Cracked nipple.*

Clinical feature

As this is an acute inflammatory condition the clinical feature are that of acute inflammation.

1. Affected breast is extremely painful
2. **Redness, edema, tenderness of affected breast** (NEET)
3. Systemic features of inflammation, eg; **fever** (NEET)

Treatment

As else where in the body, an abscess must be Incised and Drained (I & D), for allowing the pus to come out from an abscess cavity (UP 94). It is very important to note that fluctuation te5t is very difficult to be elicited in breast abscess, so surgeon should not wait for this test to be positive and I&D should be done, once the diagnosis is certain, (also see box 25.8 A & B)

Post operative management include:

1. Continuous administration of proper antibiotic after culture sensitivity.
2. Breast support to relieve pain
3. Daily dressing to be done
4. Express the milk with help of breast pump or manually.

KEY BOX 25.8.A
Abscess with no fluctuation
1. Ischiorectal abscess
2. Breast abscess
3. Parotid abscess
4. Prostatic abscess
5. Midpalmar abscess

Important Points To Remember

1. Breast feeding from opposite (non-diseased) breast should be continued in lactating women.
2. The milk from affected breast may be pumped out, boiled for 5 minutes and can be given to the infant.
3. Weaning or stopping milk formation is not usually required. It may be required if:
   (a) Milk can not be expressed due to much pain.
   (b) Abscess is not healing properly. Note: milk is a good culture media for bacterial growth.
   (c) Formation of milk fistula due to injury to milk duct.

- Weaning (supression of milk formation) is achieved by stilboestrol tablet 10 mg, TDS or bromocriptine.

2. Chronic breast abscess (Antibioma)

This usually results due to inadequate drainage of acute breast abscess or when a breast abscess is not drained: instead is treated by antibiotic only.

The abscess wall becomes fibrous and pus within it turns thick and sterile and forms a hand tender lump. This condition is known as Antibioma. Clinically this closely resembles a malignancy. The management of chronic abscess or antibioma is ***excision** of breast cavity.

{Excision: Cutting away or taking out (surgically) the whole mass/lump.}

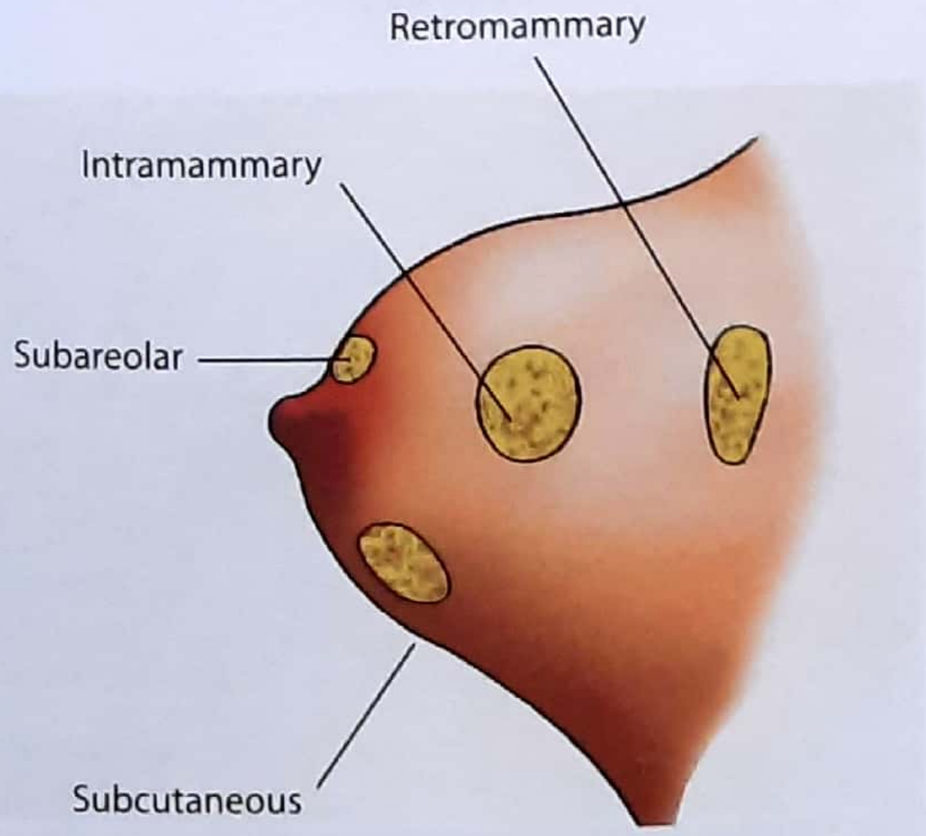

Figure 25.11: Site of various breast abscess

KEY BOX 25.8.B

Acute-breast abscess

- More common in lactating women
- M/C organism-*Staphylococcus* (MANY POME)
- In Non lactating M/C organism is anaerobes
- Very-very painful condition
- Do not wait for fluctuation test to be positive.
- Incision and drainage is treatment of choice with proper antibiotic coverage
- **Drag of choice**
  - Augmentin(co-amoxyclav)
  - Metrogyl (in case of anaerobic infection)

Kindly read key box 25.8; before concluding this topic

3. Subareolar abscess

This condition is not a true mastitis. This *result from an in- fected sebaceous gland of montogomery of areola.* The mammary glands itself are not involved. It presents as a small but very painful lump on or around the areola.

Treatment is by incision and drainage with antibiotics.

Note - Chronic subareolar abscess is also known as Zuska's disease.

4. Chronic subareolar mastitis

They are usually less painful than breast abscess and usually restricted to a single obstructed duct system. This may be an important aspect of duct ectasia (dilatation of a duct). If this abscess is formed and bursts out side spontaneously, it gives rise to *milk fistula or a mammary fistula.* (Please see fig. 25.12)

Treatment

Simple fistulectomy is performed is a case of milk fistula and track is laid open, which heals by granulation tissue. In intractable cases major duct excision should be performed.

5. Retro-mammary abscess

As the name suggests; there is an abscess formation in submammary space (behind the breast, fig 29.11). Infection may arise from tissue deep to the breast.

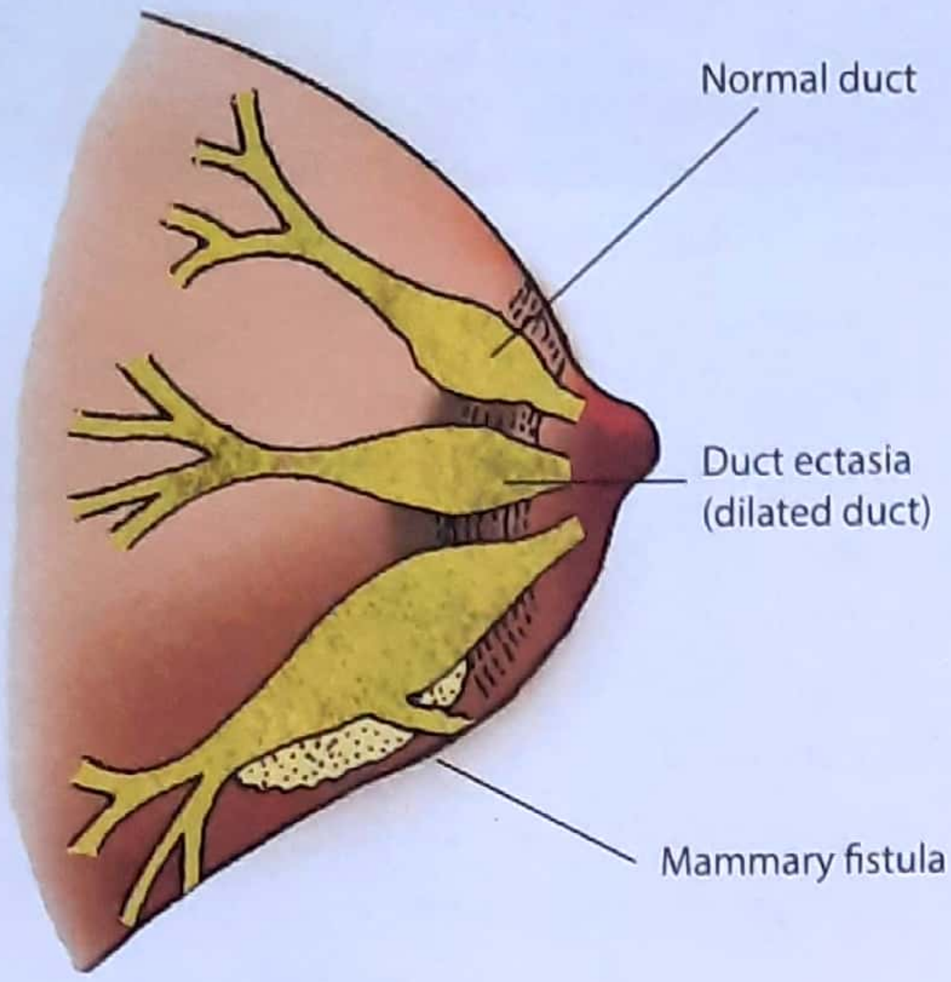

Figure 25.12: Duct ectasia & mammary fistula

Causes

1. Infected hematoma
2. Empyema necessitans
3. Tuberculosis of rib and spine
4. Osteomyelitis of rib

Clinical features

1. Mass with or without puckering of skin
2. Retracted nipple
3. Multiple discharging sinus (in connection to tuberculosis)

Treatment

As it is an abscess it has to be incised & drained. It is drained through submammary incision, also known as *Gaillard Thomas incision*.

6. Tuberculosis of breast

Infection usually reaches the breast by lymphatic spread from axillary, mediastinal or cervical lymph nodes. Hematogenous spread from the primary focus in the lung is very uncommon.

Treatment is by complete course of antitubercular treatment.

7. Mondor's disease

Thrombophlebitis of superficial veins of breast(NEET).

Now lets discuss on more topic,- which is very important; both for final year exams and PGME

Mammary Duct Ectasia

[*Ectasia, mean dilatation*; Figure 25.12 & 25.13]

Mammary duct ectasia is dilatation of mammary duct. It is also known as *plasma cell mastitis / periductal mastitis. It is much more common in smokers*(NEET).

Etiopathogenesis

Chronic inflammation around the major ducts, possibly due to ***autoimmune basis*** may be the first event, leading eventually to ductal dilatation. One other mechanism may be duct blockage.

- Duct ectasia is more common in parous women, who are breast feeding their baby, than in nulliparous or parous who are not feeding their baby.
- Inverted nipple may also cause duct blockage and subsequent duct ectasia.

Clinical feature

- Usually a disease of middle aged woman.
- Due to dilatation of duct there occurs stasis of contents.

Figure 25.13 : Mammary Duct Ectasia

- The retained epithelial debris, serous fluid form a *thick creamy paste like material*, which may discharge per nipple (PGME MANY TIMES).
- It may present with a lump in the breast or as a slit like retraction of nipple.

Treatment

As the condition closely mimics carcinoma, hence it must be excluded as this often present with a mass or discharge per nipple or nipple retraction, which are also common features of carcinoma. This is done by mammography or FNAC. If still doubt persists, the lesion should be excised and send for biopsy .

When carcinoma is excluded, antibiotic therapy may be tried. DOC is flucloxacillin along with metronidazole.

Hadfields operation is done in duct ectasia (excesion of all lactiferous-duct under the nipple)(NEET).

GALACTOCELE

Accumulation of milk & epithelial debris due to blockage of a main duct gives rise to this condition. Discharge from nipple; initially milky & later greenish is quite diagnos- tic. Affected breast may become enormously enlarged.

Treatment

Excision of affected duct is treatment of choice, because infection and abscess formation in galactocele is not uncommon.

****

NEOPLASM OF BREAST

BENIGN NEOPLASM

1. Fibroadenoma
2. Duct papilloma
3. Phylloid tumour

Now lets discuss them one by one

1. Fibroadenoma

Fibroadenoma is the **commonest benign tumour of the breast**(NEET). They are most often seen in women **under the age of 35 years**(NEET). In older woman particularly after the menopause they are quite uncommon.

Cause

Fibroadenoma may be caused by an increased sensitivity to estrogen in a localized part of the breast.

Clinical feature

1. Peak incidence is ***between 20-30 years***(NEET).
2. Patient presents with ***painless lump***(NEET) in breast of about 3-5 cm in diameter.
3. They are usually single but in 20% *cases they are multiple in the same breast or bilateral*. (TN 89)
4. The lump is smooth, round, firm to hard in consistency *with well defined margin*.
5. Fibroadenoma is *encapsulated*, ie; tumour is surrounded by a capsule.
6. They are ***freely mobile*** in the breast and due to is free movement, it is known as **"breast mouse"** (NEET, MANY PGME)
7. There is **no nipple change** in fibroadenoma, neither any discharge form it.

Figure 25.14 : Fibroadenoma

Types

1. Peri canalicular- In this type fibrosis is more.
2. Intra canalicular- In this type fibrosis is less.

Often both types are seen in the same lesion and the distinction between peri and intra canalicular fibroadenoma is no longer considered clinically important.

Management

It has been suggested that **triple assessment** [clinical examination, mammography. and FNAC or biopsy] confirms the diagnosis. On *mammography*, it gives *popcorn calcification* *(AIIMS 02, MANY PGME)*

- Once the diagnosis is confirmed the patient is told that it is not cancer, as many of them are often much concerned about it.
- **About 5-10% of fibroadenoma will regress with time. When it does not regresses or enlarges in size; surgical treatment is done** *(NEET)*.

Treatment

Excision/enucleation *(PGME MANY TIMES)* of the lump is treatment of choice. The mass should be send for histopathological examination to exclude cancer.

Carcinoma arising in a fibroadenoma is very rare and incidence is about 0.01% and it's prognosis is excellent.

NOTE: Do not confuse Fibroadenoma with fibroadenosis(ANDI). Fibroadenosis, has been discussed earlier in this chapter on page no 343. I have given a box on next page, please see key box 25.9.

Giant Fibroadenoma

When a fibroadenoma attains size of 5 cm diameter or more it is known as giant fibroadenoma. Giant fibroadenomas are more common in certain African countries. They usually occur between 10-20 year of age. The management is same as that of fibroadenoma.

2. Duct papilloma

NOTE: Papilla-means nipple like (in shape)

What is Papilloma? Nipple like benign epithelial tumour.

- Duct papilloma is benign epithelial tumour arising in
- They are usually single and unilateral.
- Middle aged women are affected and presents with bleeding per nipple. *(AI 08)*

KEY BOX 25.9

Difference Between Fibroadenoma & Fibroadenosis

Features	Fibro adenoma	Fibroadenosis
Incidence	Less common	More common Aberration in normal
Nature	Benign tumour of one lobe	development & involution
Location	Usually unilateral	Often bilateral
Pain	Not a feature	Usually present
Lump	Well defined, firm to hard & freely mobile in the breast tissue (known as breast mouse)	Irregular, ill defined & tender lump
Capsule	Well defined	No capsule
Treatment	Mainly surgical excision/enucleation of Fibroadenoma	Mainly conservative - Drugs - Evening primrose oil - Danazol - Bromocriptine

- It presents as a small swelling just beneath the areola, palpation of which results in **bloody discharge**. *(MANY PGME)*
- It is a ***premalignanf condition*** *(MANY PGME)*

Treatment

Treatment is excision of involved duct; an operation called as ***microdochectomy**** *(NEET, AI 96, 98, 08)*

Microdochectomy? (NEET)

A tennis racket incision can be made to encompass the entire duct. The nipple flap is then dissected to reach the duct, the duct is identified & then excised. A papilloma is nearly always situated with in 4-5 cm of nipple orifice.

3. Phylloid tumour (Cystosarcoma phyllodes)

(MANY PGME)

- This is also known as Serocystic disease of brodie or ***cystosarcoma phyllodes***. It is an uncommon tumour.
- It is most common sarcoma of breast.
- They may occur in any age group, the median age is 45 years.
- Though it is a benign tumour, they are known to **attain massive size** and **recurs locally after surgery** *(NEET)*.
- **It is associated with calcification** *(NEET)*.

Clinical feature

- It is a very rapidly growing tumour.
- Red, dilated vessels over the lump can be seen.
- It has a bosselated surface. [Bosselated = consider it as moving your hand over bunch of grapes].
- Warm to touch.
- In about 10-20% of cases, it behaves like a high grade neoplasm metastasizing to distant sites mainly the lung. *(PGME)*
- As it is quite rapidly growing and attains large size in short term follow up (3-6 months). It has to be differentiated clinically from malignancy.
- The ***differentiating features from malignancy*** are:
  1. Not fixed to overlying skin of breast.
  2. Not fixed to chest wall (pectoralis muscles)
  3. Lymph nodes are usually not involved (only in <10%).
  4. No nipple retraction is seen.

Figure 25.15 : Cystosarcoma phylloides

IMPORTANT POINT

1. Tumour undergoes necrosis due to pressure at various places resulting in **cystic areas** with in the breast. It discharge serous fluid hence it is also known as serocystic disease of Brodie.
2. Histopathologically it gives leaf like branching pattern *"phyllus"* hence the name *phylloides* tumour.

KEY BOX 25.10
Causes of massive enlargement of Breast [CSF in GB.]
C-Colloid carcinoma
S-Sarcoma
F-Filarial elephantiasis
G-Giant fibroadenoma
B-Brodie's disease
• Benign hypertrophy
• Varginial hypertrophy (usually B/L and presents at puberty

Treatment

- Young woman -Enucleation
- Older patient-Wide excision with 1 cm margin of normal breast tissue.
- For very rapidly growing large tumours, Quadrantectomy (Quadrant + ectomy = removal of affected quadrant of breast) or even **simple mastectomy**(NEET) may be required.(AIIMS 93)

Please also go through key box 25.10 & figure 25.15.

****

MALIGNANT NEOPLASMS OF THE BREAST

This is a very important topic you will definitely get questions on it in about all exams; MBBS-FINAL professional theory examination, or in viva exams, or after that your PGME examination.

So you must read it very carefully, understanding the subject, I have tried to make the literature simple, for better and easy understanding.

Various terminologies will be used while discussing the carcinoma of breast. I would first like to narrate them; as to make things simpler.

Introduction

Architecture of female breast

- An adult normal breast consist of 15-20 segments or lobes. Each lobe has a separate duct. All mammary duct (around 15-20 in number) converge towards the nipple; where they open.
- Each lobe consist of lobule, the number of which is variable.
- Each lobule is a collection of several acini.
- Each acini is a sphere of cell capable of milk secretion draining into a terminal duct, which gives rise to a segmental duct. The segmental duct which are just below nipple dilate to form lactiferous duct which is some what dilated, and known as lactiferous sinus.
- The lactiferous sinus open on nipple via a collecting duct, (please see figure 25.3, 25.4 & 25.16). This flow chart will help you in understanding;

Sphere of cells (acini) capable of milk secretion

↓

Collection of several acini Form

↓

Lobule

↓

Several lobule

↓

Lobe

↓

Lobule draining nipple by terminal duct

↓

Sub segmental duct

↓

Segmental duct

↓

Lactiferous duct & sinus

↓

Collecting duct

↓

Nipple

Kindly go through figure 25.3, 25.4 and 25.16 for better understanding.

Now i will discuss and we will try to understand certain terminologies, which will be discussed in this topic.

Carcinoma in situ

Malignant cell changes in epithelial tissue, that do not extend beyond the basement membrane*.

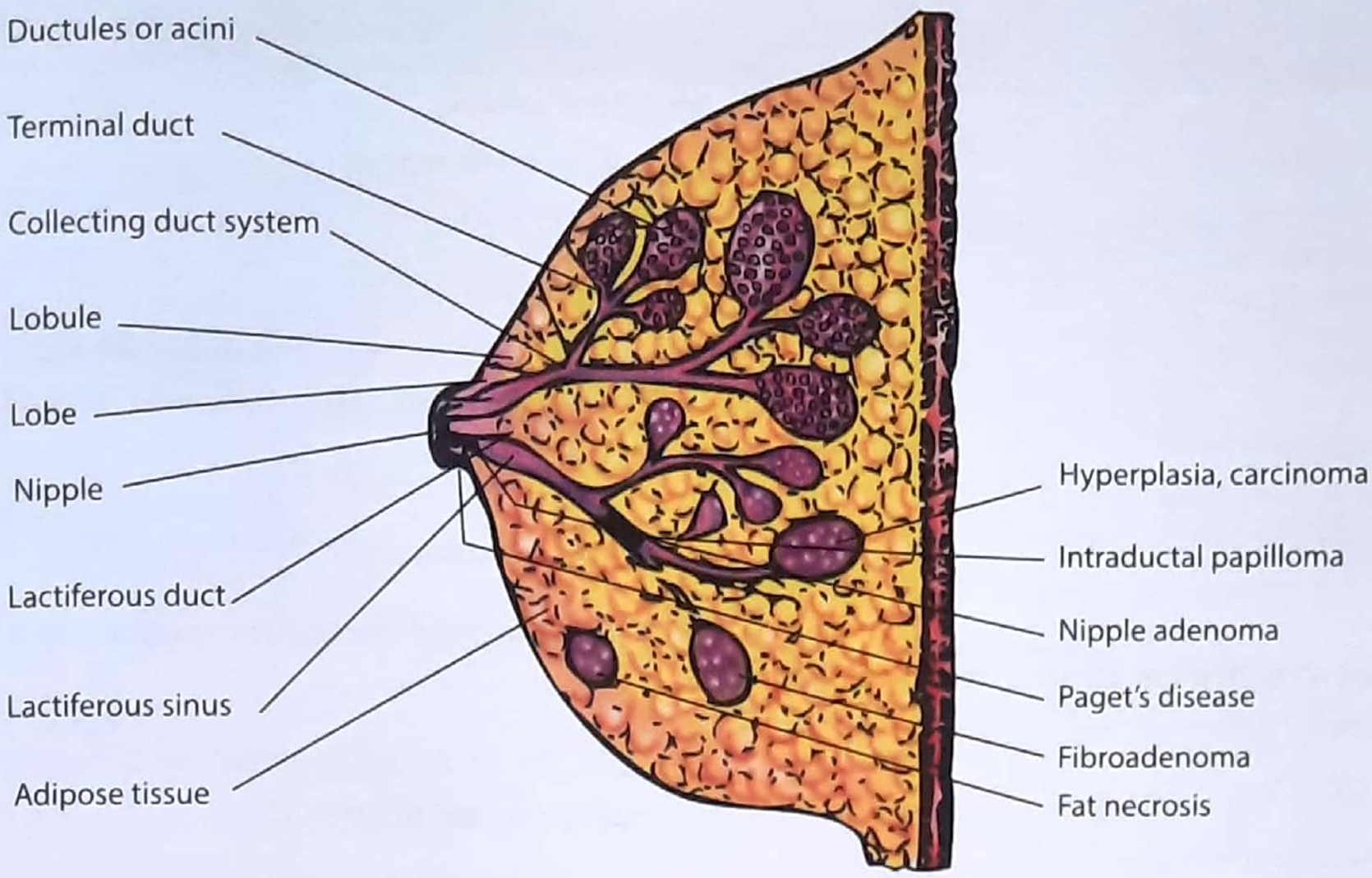

Figure 25.16: Microanatomy of breast and major lesion at various sites

What is *basement membrane?

It is a thin layer of *delicate* ***noncellular*** *material* of fine filament texture underlying epithelium. The principle component is collagen.

Infiltrative (Invasive) carcinoma

Malignancy **extending *beyond the basement membrane***, and in it stromal invasion is present.

Lobular carcinoma

It is neoplastic proliferation of *lobular* epithelial cell.

Ductal carcinoma

It is neoplastic proliferation of ductal epithelial cells.

Now lets come to the point....

CARCINOMA OF THE BREAST

Before going into details of this topic, you are strongly advised to go through the introduction, discussed on page 288. The breast is one of the commonest site of ma- lignancy in woman. Breast cancer is rare below the age of 30 years and there after the incidence goes up as the age increases. **Ca breast is most common in upper outer quadrant & least common in lower inner quadrant**(neet).

Epidemiology: There are high incidence in northern and western Europe, and in most countries of Africa, Latin America and Asia.

Breast Cancer Risk

(AIIMS, 93,98,02, PGI03, UP 94, 97, PG196,01)

Increase in risk	Decrease in risk
1. Positive family history(NEET)	1. Late menarche
2. Benign breast disorder(Q) (epitheliosis)	2. Early menopause
3. Early menarche(NEET)	3. Early pregnancy
4. Late menopause(NEET)	4. Multiparity
5. Nuliipara(NEET)	5. Breast feeding
6. Late age at first pregnancy	6. Low fat died
7. High socioeconomic status (NEET)	7. Low socioeconomic status
8. Prolonged dose of high(Q) dose estrogen exposure	8. Early marriage
9. Radiation therapy for any other malignancy on chest (Hodgkins lymphoma) (NEET)	

Increase in risk

10. Absence of breast feeding[(Q)]
11. Occurrence of carcinoma in one breast increases the risk of the carcinoma in other breast about six fold.
12. Unmarried
13. Ovarian malignancy[(NEET)]
14. High fat diet[(Q)]
15. Atypical hyperplasia

1. Risk of invasive breast cancer with benign breast lesion [(MANY Q)]

No increased risk :

- Adenosis, sclerosing or fluid
- Apocrine metaplasia
- Cysts, macro &/or micro
- Duct ectasia
- Fibroadenoma
- Fibrosis
- Hyperplasia
- Mastitis
- Periductal mastitis
- Squamous metaplasia

Slightly increased risk (1.5-2 times)

- Hyperplasia, moderate or florid, solid or papillary.
- Papilloma with fibrovascular core.

Moderately increased risk (5 times)

- Atypical hyperplasia (ductal or lobular)

Insufficiant data to assign risk

- Solitary papilloma of lactiferous sinus
- Radial scar lesion

2. Breast cancer risk models

It is for determining whether a patient is in an increased risk group for breast cancer, and helpful in optinizing strategy for screening & clinical management.

a) **Gail model**
   - Most widely used risk assessment model.

b) **Claus model**

c) **BRCA PRO-model**

Etiology

The cause of breast cancer in unknown but is probably ***multifactorial*** [(PGME)]. The following factors have be proposed.

1. Genetic factors [(EACH POINT IS VERY IMPORTANT FOR PGME)]

- Vast majority of the breast cancer are sporadic; with no family history.
- About 5% of all breast cancer result from the **autosomal dominant** inheritance.
- A family history should be present; and first degree relative (mother, sister or daughter) with breast cancer and the age at which they developed cancer.
- Lie Fraumeni syndrome (abnormal predisposition to cancer) is due to germ line mutation of one allele of p53, leads to an increase incidence of Ca breast.
- **BRCA gene** - Recently the **BReast CAncer** gene (BRCA 1) Which is found on long arm of chromosome 17 (17q) in woman is implicated in approximately 4% of all breast cancer. A second BRCA2 has been identified on long arm of chromosome 13 (13q) and is associated with slightly lower risk of breast cancer [(AIIMS PGI NOV. 10)].

Kindly go through key box 25.10(a), next page.

2. Hormonal factor

Prolonged exposure to estrogen increases the risk of breast cancer. Conditions associated with prolonged exposure of estrogen are:-

- Early menarche
- Late menopause
- Nulliparity
- Delayed first pregnancy
- Prolonged high dose estrogen treatment.

KEY BOX 25.10 (a)

	BRCA-1	BRCA-2
Location	17q	13q
Differentiation	Poorly differentiated	Well-differentiated
Hormone receptor status	ER/PR (-) HER 2 (-) → Triple Negative	ER/PR (+)
Associated cancer	Breast, ovarian, Colon, Prostate, Cancer	Breast, Ovarian, Colon, Prostate, Pancrease, Stomach melanoma, Gall bladder
Male breast Ca	Low association	Increased risk
Fanconis anemia	Associated	Associated
Medullary Ca	Associated	No association

Fanconis anemia* is a rare inherited bone marrow disease. It results in decrease production of all type of blood cells. This is most common form of aplastic anemia.

3. Obesity

Obesity is associated with increased risk of breast cancer in post menopausal women. The mechanism may be hormonal, due to enhanced synthesis of estrogen.

4. Diet

High fat diet have a higher incidence of breast cancer.

Pathological Type of Breast Cancer

The breast cancer arises from ductal system or from lobule [see architecture of breast for better understanding], and is named upon the same, ie; Ductal carcinoma and Lobular carcinoma.

Carcinoma

To begin with, it is a non-invasive or in-situ, that is when it does not extend beyond basement membrane*. Sooner or later it infiltrate the basement membrane, and goes beyond the basement membrane, and then it is called as infiltrative or invasive carcinoma. Please see key box 25.11.

BASEMENT MEMBRANE? It is a thin layer of *delicate non-cellular material* of fine filament texture underlying epithelium. The principle component is collagen.

- Most common site of carcinoma breast is upper outer quadrant of breast. *(MANY PGME, UP 01)*

Now lets come to the point, ie; pathological types

KEY BOX 25.11

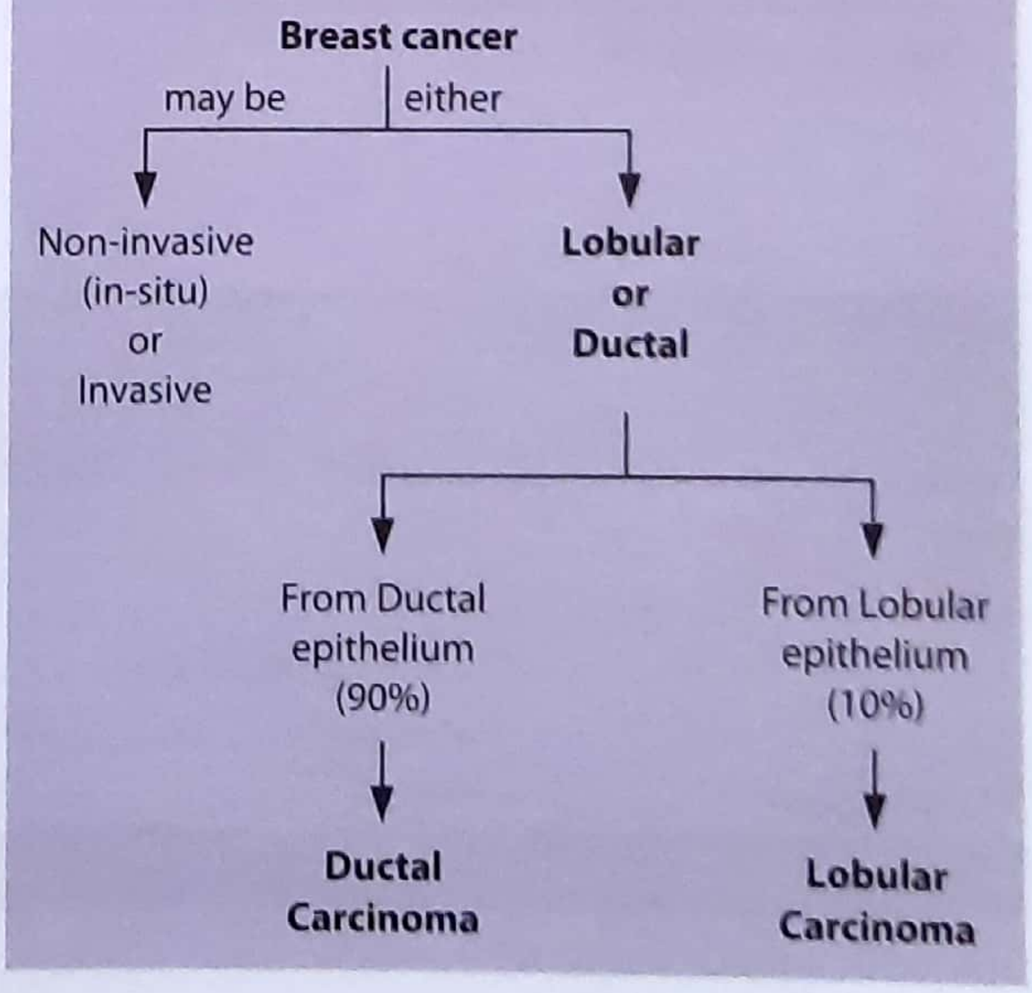

A In-situ (Non-invasive) Carcinoma

1. Lobular carcinoma in-situ (LCIS)

It is a neoplastic proliferation of lobular epithelial cells, confined within the basement membrane, that fill and distend at least one complete lobular unit.

- The basement membrane is intact ie; no invasion of basement membrane occurs. *(PGI 89)*
- Lobular carcinoma tend to be multifocal & bilateral *(AIIMS 94)*

NOTE: *It is a very frequently asked PGME question, catch; Lo**B**ular- **B** for **B**ilateral, while d**U**ctal carcinoma is usually **U**nilateral.*

- Lobular carcinoma in-situ does not produce a palpable lesion, and is not apparent on mammography.
- It is usually an incidental pathological finding in a patient, who has had breast tissue removed for some other reason.
- The presence of LCIS increases the risk of future development of invasive carcinoma breast by 10 to 12 folds and both breasts are at risk.

Treatments of LCIS

The management of LCIS is highly controversial and recommended treatment ranges from careful follow-up to bilateral simple mastectomy, because of increased risk of breast carcinoma in both breast.

2. Ductal Carcinoma in-situ (DCIS)

- It is neoplastic proliferation of ductal epithelial cell confined with in the basement membrane. Pure DCIS does not metastasize.
- Grossly DCIS may produce a hard lump, (cf; LCIS does not produce a breast lump).
- On mammography calcification can be observed, [cf; LCIS not apparent on mammography]
- *Central necrosis* is a common feature of DCIS and produces cystic lesion-called as ***Comedo carcinoma***. *(PGI 89, DELHI 79, 93, KAR. 06)*

Management of DCIS

(I) Surgery

(a) BCS with Radiotherapy

This is consmetically better but recurrence rate is more.

BCS - Breast conservative surgery

(b) Mastectomy - It is associated with least loco-regional recurrence.

- It is recommended in -
  - i) Widespread disease (multicentric & multifocal)
  - ii) In high risk for recurrence
  - iii) Size >4 cm
  - iv) Comedo appearance on histology
  - v) Estrogen receptor negative ER (-) Ductal carcinoma in-situ (DCIS)
  - vi) High grade tumor

(II) Hormonal therapy - only if ER/PR (+) [Estrogen receptor / progesterone receptor positive]

Axillary lymph node dissection is not indicated, if there is no invasion, particularly in lesion less than 2.5 cm.

- Please go through key box 25.12.

KEY BOX 25.11 (a)

Van Nuys Prognostic Index (VNPI)

Prediction	1	2	3
Age	>60 y	40-60 y	<40 y
DCIS	≤1.5 cm	1.5 - 4 cm	>4 cm
Histological grade	Nuclear grade 1 & 2 No necrosis	Nuclear grade 1 & 2 Necrosis	Nuclear grade 3 witha or without Necrosis
Margin width	≥10 mm	1-9 mm	< 1 mm

- After adding together the score from each of these factors, patients are classified into three categories

KEY BOX 25.11 (b)	
VNPI scores	**Treatment suggested**
4, 5 or 6 Low risk	Excision only is sufficient
7, 8 or 9 Intermediate risk	Radiotherapy after the BCT or reexcision if margin width is less than 10 mm and cosmetically feasible
10, 11 or 12 High risk	Mastectomy

- **Van Nuys prognostic index** *(NEET)*.

B. Infiltrative (invasive) carcinoma

1. Invasive (infiltrative) ductal carcinoma

- This is **most common** type of breast cancer, comprising more than 80% of all cases of breast cancer. *(MANY PGME)*
- A large number of different morphological type of invasive duct cancer is apparent, which is described below:

Morphological types

(i) Scirrhous carcinoma

The literary meaning of scirrhous is woody. It account for 70% of all invasive breast cancer. It is gritty, woody hard mass. Hardness of the mass is due to extensive fibrosis in the cancer.

KEY BOX 25.12 *(MANY PGME)*		
Characterstic	**LCIS**	**DCIS**
Clinical findings	None	Lump, breast discharge
Mamographic signs	None	Calcification
Premenopausal (%)	70-90%	30-35%
Synchronous-invasive cancer	5%	20-40%
Multicentricity	60-90%	25-40%
Bilaterality	50-90%	<5%
Axillary metastasis	<1%	1-2%
Subsequent carcinoma development		
Average incidence	10-15%	35-40%
Laterality	Bilateral	Unilateral

(ii) Medullary carcinoma

(Medullary means brain like) They are about 6-12% of all breast carcinoma. As the name suggest they are soft in consistency. They are large, and well circumscribed. Prognosis is usually good. *(UP 99)*

(iii) Tubular carcinoma

They account for about 3% of all breast carcinoma. They are well differentiated and their prognosis is good. Often seen in younger age group. Long term survival appreciates to 100%.

(iv) Mucinous (colloid) carcinoma

It is an uncommon cancer and constitutes only 2% of breast cancer. It is named so because of the presence

KEY BOX 25.13		
Scirrhous (M/C)	70%	• woody hard • extensive fibrosis
Medullary	6-12	• Brain matter like soft • well circumscribed, often large; prognosis good
Tubular	3-5%	• Well differentiated, • in younger age group • prognosis is good
Mutinous (colloid)	2%	• older age group • extremely soft due to presence of mucin • prognosis is excellent
Papillary	1%	• Elderly (Ago 65 years.) • Usually small (2-3 cm) • Rarely involve lymph nodes • Prognosis is best

of extracellular mucin, with in which aggregates of low grade tumour cell appear to float. **Prognosis is excellent.** (NEET, UP 99). 5 & 10 year survival are 73% & 59% test.

(v) ***Papillary carcinoma***

- This carcinoma is uncommon and account about 1% of all breast carcinoma.
- Generally seen in old women (above 65 years)
- Typically this is a small tumour and hardly attain size greater than 2-3 cm.
- This tumour has lowest frequency of lymph node involvement and prognosis is the best among all other carcinoma. (IMP. POINT) Please see key box 25.13.

2. Infiltrative (invasive) lobular carcinoma

Most common presentation is breast mass. Infiltrating lobular carcinoma constitute 5-10% of all breast carcinoma. They are similar to infiltrating ductal carcinoma except. (MANY PGME)

(i) Different histological pattern of infiltration

(ii) Higher incidence of **bilaterality & multicentricity** (NEET), hence biopsy of both breast is recommended. (MANY PGME)

(iii) Greater frequency of estrogen receptor positivity.

RECAP: *Friends till now we were discussing etiology and pathological type of Ca breast, now we will discuss clinical features, diagnosis, staging and treatment part of Ca breast*

Clinical Presentation

Clinically breast cancer may present as:

1.	Breast mass (painless)	66%
2.	Breast mass (painful)	11%
3.	Nipple discharge	9%
4.	Nipple retraction	5%
5.	Local edema & inflammation	4%
6.	Metastasis to lymph node, bone, brain, lung & pleura	5%

Metastatic disease

(i) Examination of opposite axilla and opposite breast,

(ii) *Bony tenderness* should be looked for - M/C site **lumbar vertebrae**, thoracic vertebrae, long bones and skull, (MANY PGME)

(iii) *Examination of abdomen for*

- Secondaries in liver (as hard hepatomegaly)
- Ascites
- ***Krukenbergs tumour.*** It is secondary carcinoma of ovary due to metastasis from breast. Ovaries are enlarged in size, but their shape in maintained.
  - Usually both ovaries are involved
  - PR & PV examination for metastatic deposits.

Diagnosis and assessment

- Diagnosis of a breast lump has been discussed earlier in of this chapter.
- Histological examination by, biopsy of the mass is the definitive diagnostic method.
- Receptor status (see later in this chapter) is currently established by bioassay, for which a specimen from the tumour must be removed after excision. Hematogenous spread is most commonly to bone followed by lung, pleura and liver in that order. Most common bony structure involved is lumbar vertebrae fol- lowed by long bone (usually femur) and skull. They are generally osteolytic.

Molecular classification of Breast cancer

- This is a recent classification.
- Based on gene expression profiling, the following subtypes have been identified:

I. **Luminal A :** This subtype is most common.
  - It have best prognosis of all breast cancer subtypes.
  - These are - ER (+), PR (+) and HER 2 neu (-)
  - Low expression of Ki - 67 (proliferation index master)

II. **Luminal B :** Majority of this subtype are triple positive i.e. ER (+), PR (+), HER2 neu (+), and minority are ER (+), PR (+), HER2 neu (-).
  - Variable expression of Ki-67.

III. **Triple-negative/basal like** : This subtype is most aggressive type:
  - Worst prognosis of all subtype.
  - These are triple negative i.e. ER (-), PR (-), HER2 neu (-).
  - Cytokeratin 5/6 (+).

IV. **HER 2 - enriched/positive type :** HER 2 neu enriched characterized by :

- High expression of HER 2 neu
- Low expression of luminal & basal gene clusters.
- These tumors are often ER (-), PR (-)

V. **Normal like :** This variety closely resembles luminal A. These are ER (-), PR (-), HER 2 neu (-), High Ki-67, but cytokeratin 5/6 (-).

- Most common used method of detecting HER2 neu are :
  - IHC and / or FISH.
  - In HER2 neu, IHC stains membrane brown, empty nucleus.
  - And in ER, PR, it stains nucleus brown.

What is IHC ?

IHC (**I**mmuno **H**isto **C**hemistry) : Staining of cancerous breast cells

FISH - (**F**luorescent **I**n **S**itu **H**ybridization)

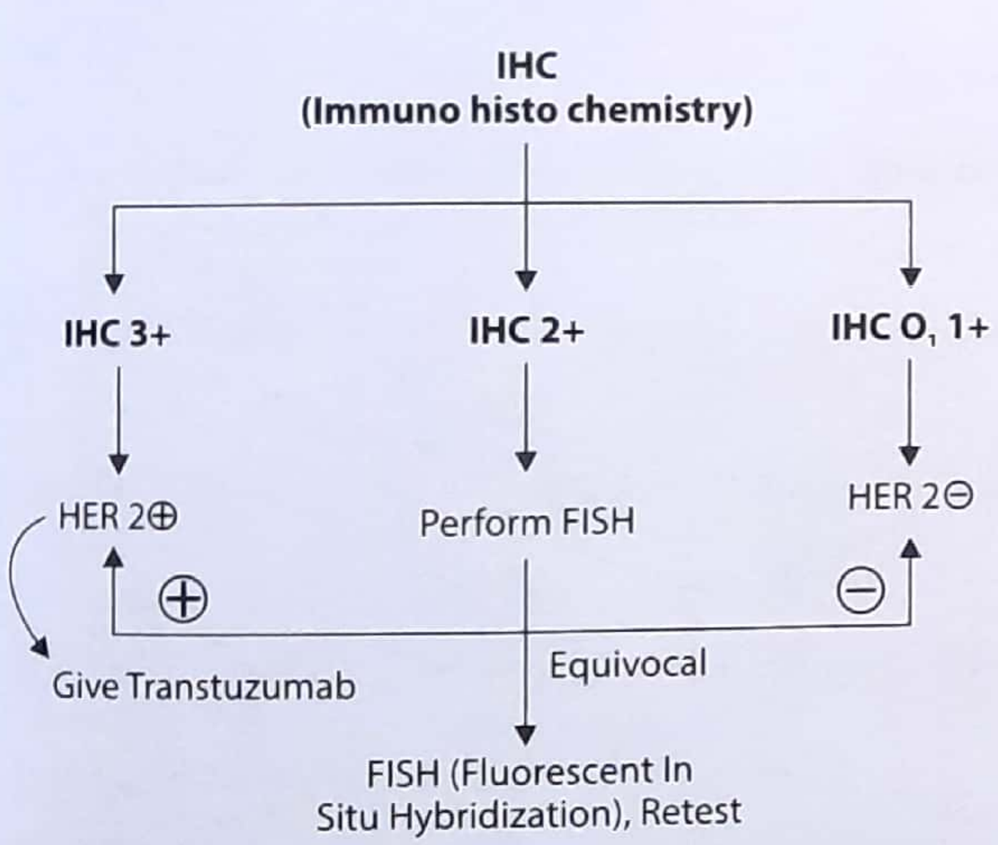

HER 2
HER/NEU

HER-2 is so name because it has a similar structure of **H**uman **E**pidermal growth factor **R**eceptor. **N**eu is so named because it was derived from rodent glioblastoma cell line, a type of **N**eural tumor.

Spread of Carcinoma Breast

1. Local spread

Infiltration of skin resulting in ulceration, bleeding, foul smelling discharge (mainly due to infection), later on it involves pectoral muscle and chest wall. Muscles (intercostal muscles, senatus art)(NEET).

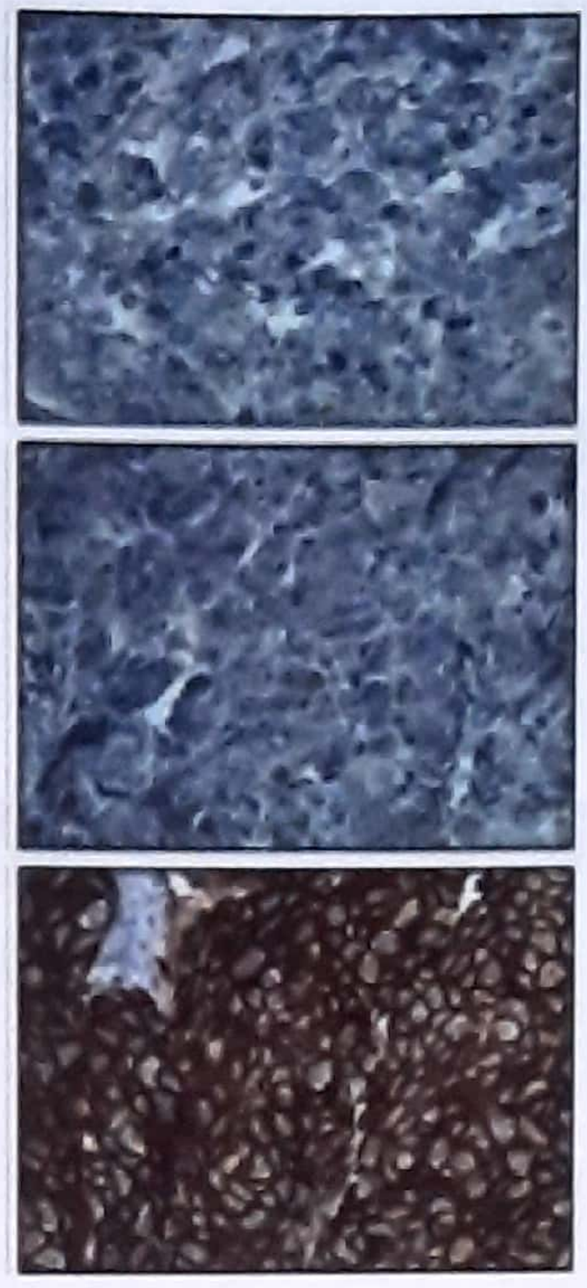

ER
(Estrogen receptor)

PR
(Progesterone receptor)

HER 2
(Human epidermal growth factor)

Figure 25.17: Various receptors related to breast cancer

2. Lymphatic spread

The *axillary lymph node are the primary node group affected*. The internal mammary group of nodes may be involved in carcinomas located in the medial half of the breast.

Axillary lymph nodes are involved in 80% of cancer, while internal mammary in 20% (PGI 05) . Spread beyond the axillary nodes into supraclavicular and cervical node is evidence of advanced disease.

Peau d' orange - This is orange skin covering (santarey ke chilkey) like appearance of breast skin due to dermal lymphatic obstruction(PGME). It occurs in extensive axillary lymph node involvement. It indicates advanced breast cancer. (Figure 25.76 page 338)

3. Blood stream spread

Bony metastasis are most common (M/C) site (NEET), followed by lung, pleura, liver in that order.

Most *common bony structure involved is lumbar vertebrae* (NEET, UP 01) followed by long bones (femur), skull, they are generally osteolytic. (MANY PGME)

Major route of hematogenous spread are :

1) ***Axillary vein*** (NEET)
2) ***Internal mammary V.*** (NEET)
3) ***Intercostal V.*** (NEET)
4. ***Batson venous plexus (To vertebrae)*** (NEET)

- Metastasis may also occur to following organs, and result in:

Liver - Hard hepatomegaly

Lung - Pleural effusion (M/C *cause of death due to breast cancer due to secondary deposit*)

Peritoneum - Ascites

Ovary - Krukenberg tumour.

Peritoneal deposits: in rectovesical pouch.

TNM & staging grouping

T staging	
TX	Primary tumor cannot be assessed
T0	No evidence of primary tumor
Tis	DCIS & Paget's disease
T1	Tumor < 20 mm in greatest dimension
T1mi	Tumor ≤ 1 mm in greatest dimension
T1a	Tumor >1 mm but ≤ 5 mm in greatest dimension
T1b	Tumor >5 mm but ≤ 10 mm in greatest dimension
T1c	Tumor >10 mm but ≤ 20 mm in greatest dimension
T2	Tumor >20 mm but ≤ 50 mm in greatest dimension
T3	Tumor >50 mm in greatest dimension
T4	Tumor of any size with direct extension to chest wall and/or to the skin
T4a	Extension to chest wall (pectoralis muscle not included)
T4b (NICET 2020)	Ulceration and/or ipsilateral macroscopic satellite nodules and/or edema (peau d'orange) of the skin
T4c	T4a and T4b
T4d	Inflammatory carcinoma
Regional Lymph Nodes (N)	
NX	Regional lymph nodes cannot be assessed
N0	No regional lymph node metastases
N1	Metastases to movable ipsilateral level I, II axillary lymph node(s)
N2	Metastases to ipsilateral level fixed axillary lymph node or internal mammary nodes
N2a	Metastases in ipsilateral level I, II axillary lymph nodes fixed to one another (matted) or to other structures
N2b	Metastases only in clinically detected ipsilateral internal mammary nodes and in the absence of clinically evident level I, II axillary lymph node metastases

N3	Metastases in ipsilateral infraclavicular (level III axillary) lymph node(s) with or without level I, II axillary lymph node involvement; or in clinically detected ipsilateral internal mammary lymph node(s) with clinically evident level I, II axillary lymph node metastases; or metastases in ipsilateral supraclavicular lymph node(s) with or without axillary or internal mammary lymph node involvement
N3a	Metastases in ipsilateral infraclavicular lymph node(s)
N3b	Metastases in ipsilateral internal mammary lymph node(s) and axillary lymph node(s)
N3c	Metastases in ipsilateral supraclavicular lymph node(s)
M	
M0	No clinical or radiographic evidence of distant metastasis.
M1	Distant metastasis (C/L supraclavicular lymph node)

Staging of breast cancer is most important factor in its prognosis. *(IMP. POINT)*

Stage grouping

Anatomic Stage/Prognostic Groups			
Stage 0	Tis	N0	M0
Stage IA	T1*	N0	M0
Stage IB	T0	N1	M0
	T1*	N1	M0
Stage IIA	T0	N1**	M0
	T1*	N1**	
	T2	N0	
Stage IIB	T2	N1	M0
	T3	N0	
Stage IIIA	T0	N2	M0
	T1*	N2	
	T2	N2	
	T3	N1	
	T3	N2	
Stage IIIB	T4	N0	M0
	T4	N1	
	T4	N2	
Stage IIIC	Any T	N3	M0
Stage IV	Any T	Any N	M1

Manchester Classification

Though this classification is no longer used, but is discussed here, because you may get questions on it is various PGME examinations, while solving questions. Some times you may be asked questions in viva, if you get breast cancer as a long case in prof examination

Stage I

Growth confined to breast, skin involvement indirect conti- nuity with tumour and is smaller than the tumour size.

Stage II

Stage I + palpable mobile axillary lymph node

Stage III

Growth extend beyond breast and may be present with:

(a) Skin involvement more than tumour area

(b) Fixity to deep structure like pectoralis minor

(c) Axillary lymph node are fixed, supraclavicular lymph node palpable

Stage IV

Growth extending beyond breast, with:

(i) Fixation to chest wall

(ii) Involvement of opposite breast and axilla

(iii) Distant metastasis to bone, liver, lung.

KEY BOX 25.14

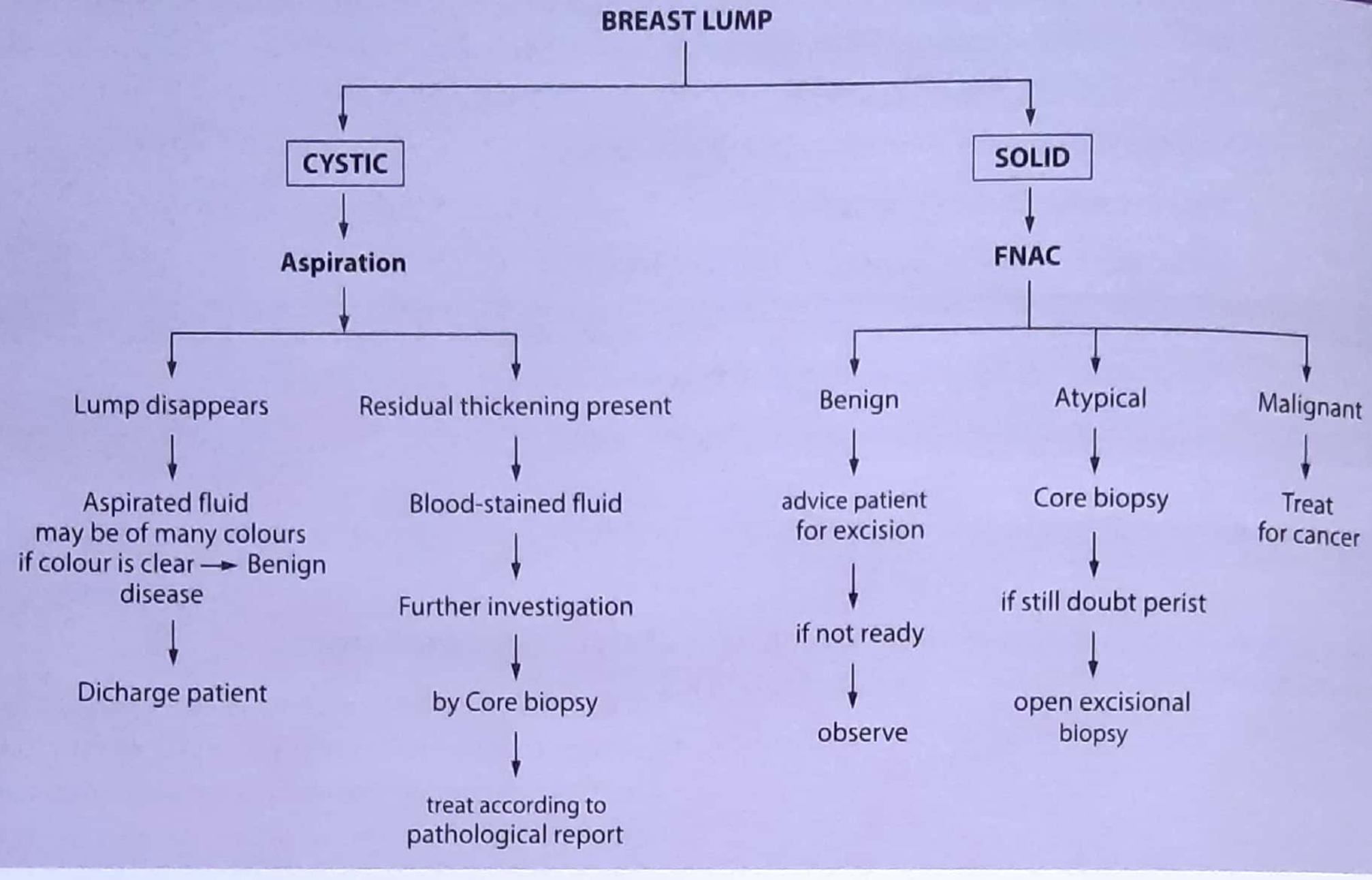

TREATMENT OF BREAST CANCER

Before discussing different definitive breast surgical proce- dures, I will like to give you an over views of different type of mastectomy procedure which are often asked in Various PGME, and final professional examination. Various operative procedures are:

1. Breast conservative therapy (BCT)

In this; whole of the breast is not removed; instead only lumpectomy, or partial mastectomy or WLE is done. Radiotherapy is mandatory in all cases of BCT.

Indication for BCT (AIIMS 03)

- Small tumours of size less than 4 cm (T_1 & T_2)
- No extensive nodal involvement (NO & N1)
- No metastasis
- No age limit has been given for BCT, an elderly fit patient are treated in the same way as younger patient.

Contraindication for BCT (PGI 01)

- Tumour size more than 4 cm [T4] (Q)
- Extensive nodal metastasis [N2, N3]
- Distant metastasis (MI)
- Fixity of tumour to underlying pectoralis and over lying skin.
- Pregnancy (NEET)
- Differ microcalcifications
- Central lesion (Q)
- Multifocality or multicentric (ie; in lobular carcinoma) (Q, UP 2000, AL 06)
- Poorly differentiated* (see below)
- Large breast
- Ductal carcinoma
- Previous Radiation to chest.
- Involved surgical margins.
- Multicentric disease.
- Scleroderma/Lupus erythematosus.

NOTE:

It is quite commonly used with malignancy that this tumour is well differentiated, or that is poorly differentiated. What does it actually mean * "Degree of differentiation denotes the degree to which a neoplastic cell resembles the normal cell of the tissue in question". So-poorly differentiated tumour means very poorly resembling the normal cell of that organ ie; more malignant is the tumour.

See this for better understanding Breast Conservation Surgery

Resection of Primary breast Cancer with 1mm to 10 mm cancer free margin ie; *(NEET)*

(Segmeatal Mastectomy/Lumpectomy/Partial Mastectomy/Wide Local excision/Tylectomy)

+

Assessment of regional lymph nodes

(Sentinal lymph node biopsy)

↓

if positive

↓

Axillary dissection

+

Adjuvent Radiotherapy

- BCS is standard treatment for stage 0, I and II.
- Sentinal lymph node dissection is now preferred staging procedure with a clinically node negative axilla.
- **For DCIS** → Resection of Primary CA + Adjuvant Radiotherapy (regional Lymph node assessment is not needed)

Breast conservative surgery is also known as segmental mastectomy, lumpectomy, partial mastectomy, wide local excision, and tylectomy.

- **Tylectomy :** Excision of lump
- **Simple mastectomy :** Palpable extent of breast + Nipple areola complex + overlying skin.
- **Subcutaneous mastectomy:** Palpable extent of breast without overlying skin.
- **Total mastectomy :** All breast tissue + Nipple-areola complex + skin.
- **Extended simple mastectomy :** Simple mastectomy + removal of level I axillary lymph nodes.

2. Radical (halsted) mastectomy *(AIIMS 92, MANY PGME)*

In this classical operation, in this operation:-

Structures, that are removed

1. The whole breast
2. The portion of skin overlying tumour, which should always include nipple.
3. Subcutaneous fat and deep fascia
4. *Pectoralis major and minor*, along with clavi-pectoral fascia.
5. All fatty and loose areolar tissue along with all groups of lymph node of axilla.

Structures to be saved (A+B+C) *(NEET)*

A - Axillary vein

B - Bell nerve (Long thoracic nerve) ie; nerve to serratus anterior.

C - Cephalic vein

Just to remember : Nerve supply of lady ie; Lat. dorsi can be sacrificed. *(Lady is sacrificed)* *(MANY PGME)*

- **Modified radical mastectomy (MRM) :** Entire breast tissue + Nipple-areola complex + skin + Axillary lymph nodes (Levels I + II ± III)
  - **Patey's :** Pectoralis minor is removed
  - **Scanlon's :** Pectoralis minor incised
  - **Auchincloss :** Pectoralis minor only retracted
- **Extended radical (Urban) :** Halsted's + Internal mammary lymph nodes
- **Extended radical (Dahl-Iversion) mastectomy:** Halsted's + Internal mammary + Supraclavicular lymph nodes
- **Super radical mastectomy :** Halsted's + Internal mammary+ Supraclavicular + Mediastinal lymph nodes

Treatment plan

Treatment plan is divided in two groups.

A. For early carcinoma breast

Stage I

Stage II

B. Late advanced Carcinoma breast

Stage III - T3, T4 and N2, N3 and M0

Stage IV - Metastasis

KEY BOX 24.15		
Haggensen's Criteria of In operability of CA-Breast [Mnemonic DESI]		
D	-	Distant metastasis
E	-	Extensive edema (in breast/arm)
S	-	Satellite nodules of carcinoma Supraclavicular nodes metastasis
I	-	Internal mammary node involvement Inflammatory CA.

Now lets take them, one by one :-

A. Treatment of Early Carcinoma Breast (Stage I & II) *(PGI 02, 96, AIIMS MAY 08)*

Early breast carcinoma is operable*.

NOTE: Operability or inoperability of breast carcinoma is decided by Haagensen's criteria. Breast cancer should be considered inoperable when there is:- Distant metastasis, extensive edema of arm/breast, supraclavicular and/or Internal mammary lymph node involvement. Kindly see box 24.15 on next page.

1. Surgery

If tumour size is less than 4 cm, conservative breast surgery is advocated ie; (lumpectomy, wide local excision or quadrantectomy)

For tumours more than 4cm in size; modified (Patey's) radical mastectomy with axillary dissection for lymph node is done.

2. Post operative radiotherapy

Surgery and radiotherapy are often complimentary in early breast cancer.

- Dose of RT = 4500 - 5000 Rad.

Indication

1. Post BCS
2. (+) LN
3. LABC
4. Size >5cm

NOTE: That postoperative irradiation (radiotherapy) reduces the incidence of local recurrence.

3. Adjuvant chemotherapy/Hormone therapy

Hormone and chemotherapy are now being used as adjuvant treatment for patients with operable breast cancer (early, ie;- stage I & II)

Objective of adjuvant therapy - is to eliminate the occult metastasis responsible for recurrence. It may be in form of hormone therapy & chemotherapy.

(i) Hormone therapy

In patients with positive node and **estrogen receptor positive tumours, tamoxifen** *(NEET)* is used both in pre and post menopausal women. Aromatase inhibitors have been found to be more beneficial in post menopausal women (less likely to cause endometrial cancer).

- Neoadjuvant Endocrine therapy is used in elderly patients unfit for surgery or chemotherapy.
- For Stage IV cancers → Tamoxifen for premenopausal patients. Aromatase inhibitor for postmenopausal patients.
- Antiestrogen Therapy — **Tamoxifen 20 mg** *(NEET)*/day or Raloxifan 60 my/day for 5 years. Raloxifan has **low risk for uterine cancer** *(NEET)*, thromboembolism and cataract → given to all ER/PR positive patients.
- Ablative Endocrine therapy — Oopherectomy
- Anti HER-2/neu antibody therapy — Trastuzumab

(ii) Chemotherapy

- It is of minimal benefit to women with negative nodes and cancers ≤ 0.5 cm is size (not recommended)
- If cancer is hormone receptor (ER/PR) positive then antiestrogen therapy is to be added.
- For operable advanced local regional breast cancer;
  - (Stage IIIA) - Preoperative (Neoadjuvant) chemotherapy taxane containing or Doxorubicin (Adriamycin) containing regimen followed by MRM or Segmental Mastectomy + axillary dissection followed by adjuvant radiation therapy.
  - For **inoperable stage IIIA and stage IIIB - neoadjuvant chemotherapy** *(NEET)* is used to decrease cancer burden this may then permit MRM or RM followed by - adjuvant radiation therapy.

Chemotherapy Regimens

1. C – Cyclophosphamide
   A – Adriamcycin (doxorubicin)
   F – 5 Fluorouracil

2. C – Cyclophosphamide
   E – Epinebicin
   F – 5-Flurouracil
3. T – Taxane (Docetaxel/Paclitaxel)
   A – Adriamycin
   C – Cyclophosphamide
4. **CMF** regimen *(AIIMS 96, PGI 96)*
   C – Cyclophosphamide
   M – Methotrexate (Mtx)
   F – 5 Fu (S- Flurouracil)

For Her2/Neu positive

1. *AC followed by paclitaxel + Trastuzumab.
2. Docetaxel + Trastuzumab — CEF*
3. T – Docetaxel
   C – Carboplatin followed by Trastuzumab.
   H – Trastuzumab

*AC: Adriamycin (also called as doxorubicin) + cyclophosphamide).

*CEF: Cyclophosphamide, Epirubicin, Fluorouracil.

B. Treatment of Advanced Breast Cancer (Stage III And Stage IV)

Stage III: (locally advanced breast carcinoma) *(NEET)*

(Any T & N_2, N_3 but M_0)

Most patients in our country report to clinics in this stage. There is gross skin and/or pectoral muscle involvement, or chest wall involvement. Though they are not curable (only 5-10%› in this stage are curable) good palliation in major group of patient and cure in small group can be achieved.

Two principle object for the management of locally advanced breast cancer **(Stage III)**.

1. Achieve local control
2. To prevent or delay distant metastasis.

Most T3 cancer can be treated by local mastectomy plus radiotherapy to chest wall and all surrounding nodal drainage area. Toilet mastectomy may be needed to be performed for foul smelling, fungating mass.

At times, chemotherapy using CMF or CAP may be prescribed for a large bulky tumour. This may produce regression in the size of the mass (ie; down staging of tumour) and the residual tumour may later be irradiated or excised.

Stage IV: Metastatic carcinoma

- Treatment is mainly palliative.*(PGME)*
- It involves a multi-disciplinary approach which, include *hormonal manipulation, systemic chemotherapy & local radiotherapy.*
- The treatment of individual organ involvement or systemic involvement is mainly symptomatic.*
- The prognosis in metastatic breast carcinoma upon estrogen receptor status. Receptor positive has better prognosis than receptor negative. *(IMP. POINT)*

NOTE: **Prognosis in metastatic breast carcinoma does not depend on lymph node status, it depends on hormone receptor status** *(IMP-POINT -PGME)* **Estrogen receptor positive has better prognosis.** *(NEET)*

Newer chemotherapeutic drugs

Treatment of metastatic breast cancer by targeting Pl3k/AKT/mTOR pathways has led to newer chemotherapeutic drugs, which are as follows:

Cyclin-dependent kinase 4/6 inhibitor

- **Palbociclib** : Approved for use with aromatase inhibitor (Letrozole) or SERD (Fulvestrant)
- Ribociclib: Approved for use with aromatase inhibitor (Letrozole)
- Abemaciclib: Approved for use with SERO (Fulvestrant)

mTOR pathway inhibitors

- **Everolimus** : Approved for treatment of advanced/metastatic hormone receptor-positive, HER-2-negative breast cancer

Phophatidyl-inositol 3 kinase (Pl3k) inhibitors

- **Buparlisib** - Not approved, but trials are underway for treatment of metastatic breast carcinoma.

AKT (Protein kinase B) inhibitors

- **Ipatasertib:** Not approved, but found beneficial for metastatic triple-negative breast cancer.

Quick revision (treatment of Ca breast)

Treatment for Breast Cancer

Stage O (In situ)

LCIS — It is a marker for increased risk for invasive cancer treatment options are:

- Observation
- Tamoxifen
- B/L Mastectromy (Least preferred)

DCIS —

if < 4 cm — Lumpectomy (BCS) +/- Radiation

if > 4 cm — Mastectomy + Radiation

Followed by Tamoxifen 20 mg/day for 5 yrs.

Stage I and II (Early invasive Cancer)

BCT (breast conservative therapy) + Sentinal LN Biopsy (Axillary LN dissection, if positive) + Radiation + **Adjuvant chemotherapy (given if)** -

1. Axiallary nodes are positive
2. > 1 cm tumor
3. Node negative cancer with adverse prognostic features: Blood vessel/Lymphatic invasion/high nuclear grade/high histologic grade/HER-2 over expression/ ER/PR negative cancer.

Stage III A and III B (Advanced regional cancer)

Neoaduvant chemotherapy + **MRM** (NEET) followed by adjuvant radiation

Stage IV (Distant Metastasis)

- Mainly Palliation
- Hormonal therapy is preferred

- **All breast Ca patient in follow-up should have history & physical exam every 3-6 month for 1st 3 year after primary therapy with annual mammography**(NEET).

Prognosis

Stage	5 yr survival
I	100%
II A	92%
II B	81%
III A	67%
III B	54%
IV	18%

- Prognostic factors of carcinoma breast has been given in key box 25. 16. (VERY IMP. FOR PGME) , however not so important for prof, examination)

Adverse Prognostic Factors for High Risk of Recurrence of CA breast

1. Blood vessel or lymph vessel invasion
2. High nuclear grade.
3. High histologic grade.
4. HER-2/neu overexpression
5. Negative hormone receptor status

Figure 25.18: Advanced carcinoma breast (ulcerative growth)

Figure 25.19 : Ultrasonographic assessment of axillary lymph node involvement in Ca breast

KEY BOX 25.16			
Prognostic Factors Of Carcinoma Breast *(AI 89, UP 01)*			
Factor		**Favorable**	**Unfavourable**
History related factors			
Age		> 50 years	< 50 years >
Menopausal status		Post menopausal	Premenopausal
Inflammatory response		Present	Absent
Adjacent in-situ disease		Absent	Present
Tumour related factors			
Size		Small	Large
Histological grade		I	III
Histological type		Mucinous, papillary, tubular, medullary	Inflammatory, metaplastic carcino-sarcoma
Nodal Involvement	Axillary	–	+
	Internal mammary	–	+
	Number of axillary nodes	<3	4 or more
Hormone receptor status	Estrogen receptor	+ *(NEET, UP 01)*	–
	Progesterone receptors	+	–
Lymphatic or vascular		–	+
Molecular markers			
Mitotic index		Low	High
S phase fraction		Low	High
Ploidy		Diploid	Aneuploidy *(UP 01)*
Thymidine labeling index		Low	High
HER-2/Neu(C-erbB-2)		Absent	Present *(NEET, UP 01)*
P_{53} mutation		Absent	Present *(NEET)*
KI67		Low	High
PCN 4/cyclins		Low	High *(NEET)*
Urokinase plasminogen activation		Low	High High

SOME IMPORTANT POINTS RELATED WITH CA BREAST

Sentinel (Guard) LN Biopsy (sentinal means guard)

- Sentinal LN — First site of drainage from lymphatic vessels of primary tumor.
- Primarily used in **clinically node negative** *(NEET)* early breast cancers.

Gene Search Breast lymph Node Assay :

- Real time rt-PCR detects tumor cell metastasis in LN by identifying gene expression markers of Mammoglobin and cytokeratin 19.
- Not recommended for Palpable axiallary LN prior axillary/ breast surgery; Neoadjuvant chemotherapy; DCIS
- Sentinal LN is identified by Combination of intropestive gamma probe detection of radioactive colloid and visualisation of Isosulfan blue dy (lymphazurin).
- 10 sec in vivo and 10 sec ex vivo radioactivity counts are compared (>10% of exvivo counts → excision of LN)

Factors for increased risk for local recurrence:

1. Cancer at surgical margins — high risk.
2. Metastatic disease involving 4 or more axillary Lymphnodes Premenopausal women with metastatic disease involving 1 to 3 lymphnodes.
3. Advanced local-regional breast cancer (Stage III A or B)

Effect of Lymphatic Obstruction Due to Carcinoma of Breast

1. **Peau d' orange** *(PGI 88)* : Orange skin (covering) appearance of breast ***due to obstruction of subdermal lymphatics*** *in* case of advanced carcinoma. *(NEET, PGI 05, 89, AIIMS 93, UP 05)* **Note: Peau d' orange is pronounced as "Peau d orane" "g" is silent**. See figure 25.21.
2. **Elephantiasis chirurgens:** This is a complication of radical mastectomy, when all the node in axilla are removed. Due to removal of lymph nodes the arm becomes edematous and skin is thickened as in elephantiasis.
3. **Lymphangiosarcoma:** It is rare complication after radical mastectomy and arises from lymphedematous limb *(NEET)*.

Paget's Disease of the nipple *(AP 97)*

- It is an external presentation of now-invasive **intraductal carcinoma** *(NEET)* **of breast**. *(KERALA 89)*
- There is reddening, excoriation or scaling of the skin of the nipple.
- Clinically it presents as an eczematous change in the nipple and surrounding skin.
- Microscopically, Paget's disease is characterised by large avoid cells with abundant clear pale staining cytoplasm in malpighian layer.

Figure 25.20 : Lymphangiosarcoma

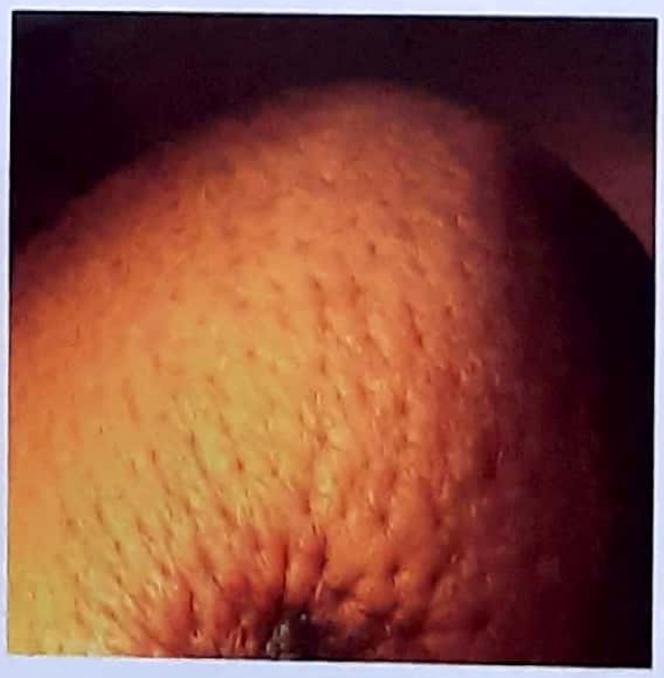

Figure 25.21 : Peud d' orange

Figure 25.22 : Inflammatory carcinoma

- *Treatment* is simple mastectomy; once the diagnosis is confirmed by biopsy. **Prognosis is good**. (NEET, AI 95)

Inflammatory carcinoma

It is rapidly growing malignant tumour, fortunately accounting only about 1-2% of all carcinoma breast. There is redness of skin, pain and other signs of inflammation and clinical picture closely resembles to that of breast abscess, hence has also called as mastitis carcinomatosa, but systemic feature like fever is absent. It is so fatal that, if not treated early it will kill in less than 6 months.

Now a days adriamycin containing therapeutic regimen has shown some promise in regressing the tumour in 75% case and after that surgery and radiotherapy is advocated. Please see figure 25.22

CARCINOMA OF MALE BREAST

Carcinoma of male breast account for about 1-2% of all cases of breast cancer. The known predisposing cause include gynecomastia and excess endogenous or exogenous estrogen, Klinefelter's syndrome and positive family history and **undescended testis** (NEET).

- *Breast cancer in male has a worse prognosis than that in the female due to early infiltration of chest mall due to less amount of fatty tissue in male breast.* (IMP. POINT)
- Infiltrating ductal carcinoma is more common than the scirrhous variety. Note in female breast carcinoma scirrhous variety is most common; accounting for about 70% of all breast cancer.
- The investigation and management is more or less same as that of female breast carcinoma. Bilateral orchidectomy is done to control the disease.
- Incidence high in North americans, Jews and african american males.
- Preceded in 20% cases by **gynecomastia** (NEET).
- Associted with:
  - Radiation exposure
  - Estrogen therapy
  - Testicular Feminizing Syndromes
  - Klinefelter's Syndrome (XXY)
- Peak incidence in Sixth decade of life.
- Among all male breast cancer <15% are ductal carcinoma in-situ; **and >85% are infiltrating ductal carcinoma** (NEET).
- **80% are hormone receptor positive** (NEET).
- Staging and survival rates are same as female breast cancer.
- Usually diagnosed at advanced stage (III or IV) — so, prognosis is worse.
- Treatment is surgical (most commonly MRM)
  - + Tamoxiten (if hormone receptor positive – 80%)
  - ± Chemotherapy (if hormone receptor negative)
  - ± Adjuvant radiation therapy (if high risk for local-regional recurrence)

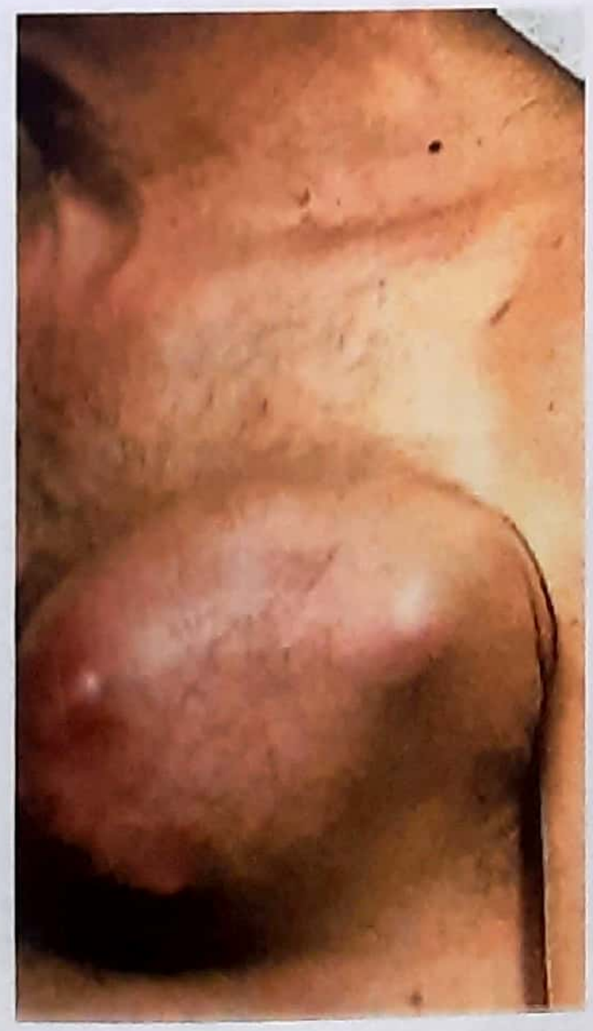

Figure 25.23: Carcinoma of male breast

****

BREAST RECONSTRUCTION/ ONCOPLASTIC SURGERY

Indicated when:

1. Significant area of breast skin is resected along with specimen to achieve tumour negative margins.
2. Large volume of breast parenchyma is resected resulting in significant defect.
3. Tumor is located between nipple and inframammary fold.
4. Excision may result in malpositioning of nipple.

BREAST RECONSTRUCTION

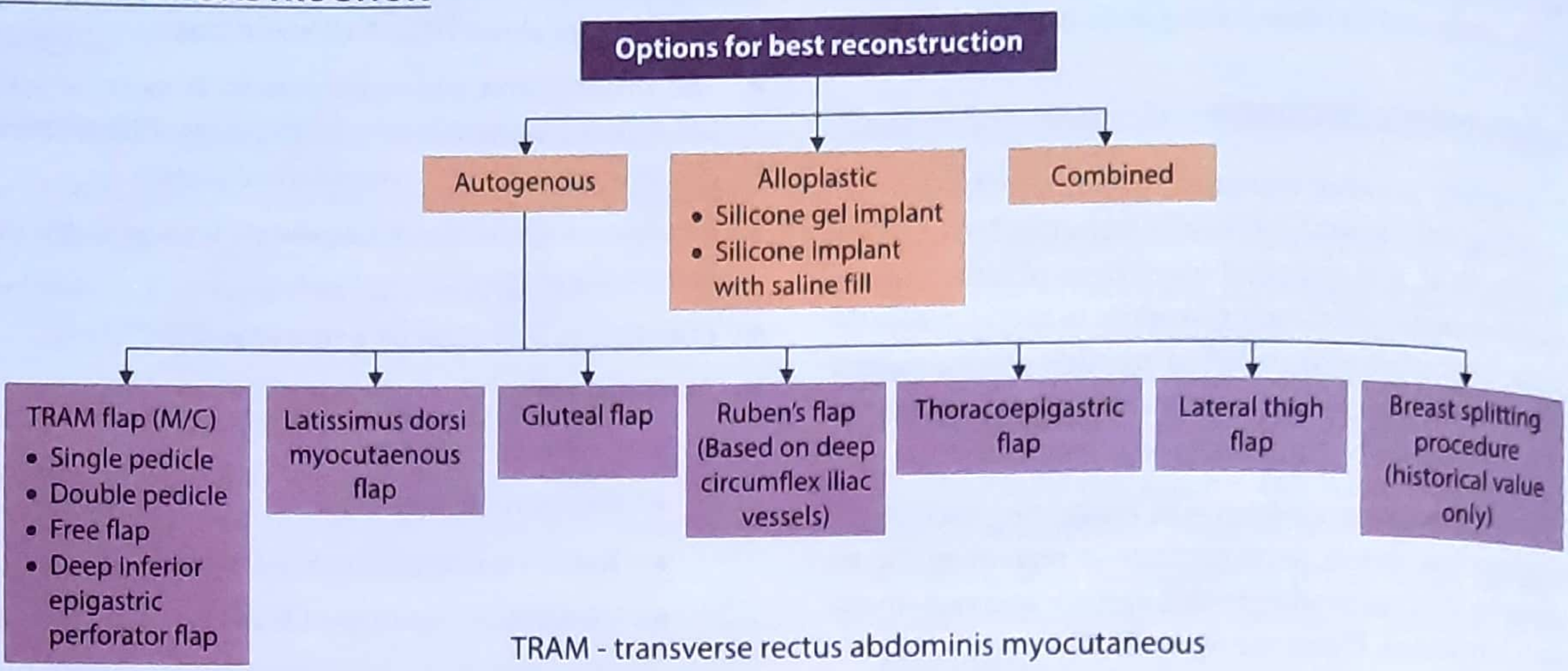

TRAM - transverse rectus abdominis myocutaneous

Breast reconstruction with the implant or a prosthesis is usually feasible after radical mastectomy or modified radical mastectomy. Options of breast reconstruction are mentioned in above flow chart.

****

GYNECOMASTIA

Hypertrophy of male breast is called as gynecomastia.

Simson's Classification of Gynecomastia

Group I- Minor but visible breast enlargement without skin redundancy.

Group IIa- Moderate breast enlargement without skin redundancy

Group IIb- Above with minor skin redundancy

Group III- Gross breast enlargement with skin redundancy that look's like a female breast.

Cause of Gynecomastia *(AI 98, UPSC 88)*

(i) Estrogen excess

- Testicular tumour
- Adrenal-cortical tumour
- Choriocarcinoma
- Carcinoma lung
- Hepatocellular carcinoma
- Hyperthyroidism
- Hypothyroidism
- Cirrhosis of liver

(II) Androgen deficiency

- Klinefelter syndrome (XXY)
- Kallman syndrome
- Congenital anorchia (Eunuchs)

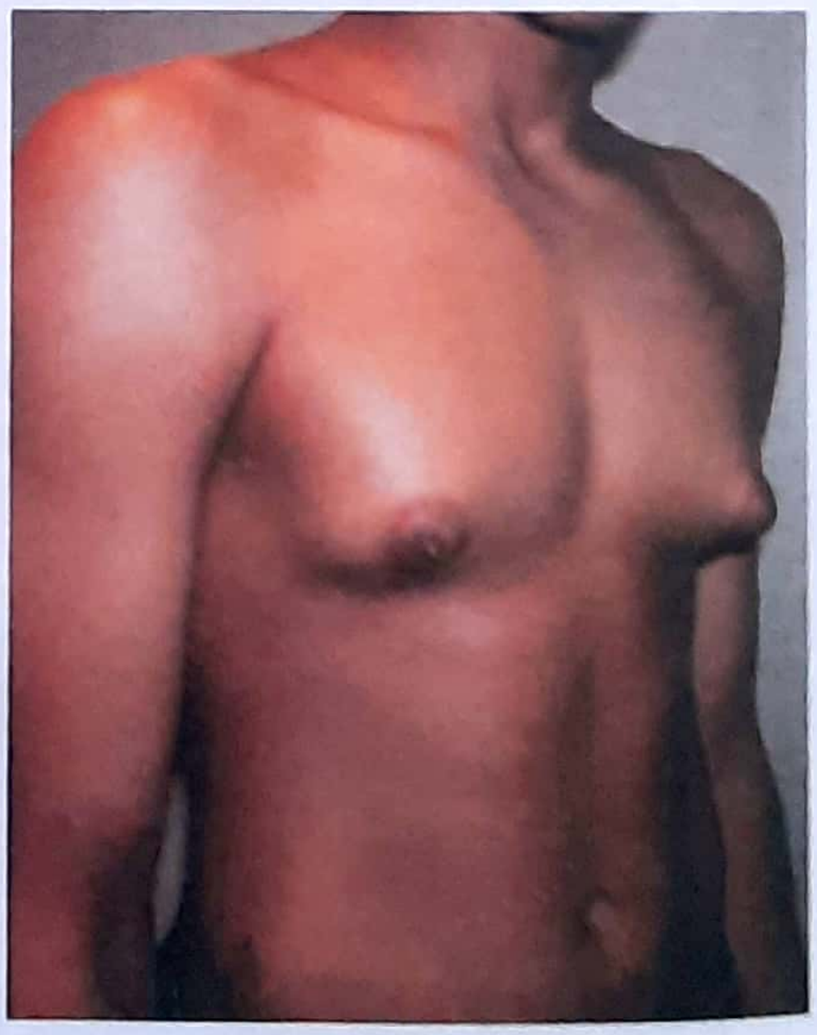

Figure 25.24: Gynecomastia

(III) Secondary Testicular failure

- Trauma
- Orchitis
- Cryptorchidism
- Radiation to testis
- Renal failure
- Varicocele.

(IV) Drugs

Estrogen

- Digitalis
- Anabolic steroid

Enhancing estrogen synthesis

- Reserpine
- Theophylline
- Fursemide

Inhibiting synthesis of Testosterone

- Cemetidine
- Phenytoin
- Spironolactone
- Diazepam

Treatment

Provided the patient is healthy and comparatively young, reassurance and attaining drug history, and sloping drugs that cause gynecomastia; may be sufficient. If these fail then, subcutaneous mastectomy with preservation of areola and nipple can be performed. *(AI 07)*

****

Sample Questions for Prof Examination

NOTE: **You may get questions from this chapter in the following form in theory paper, So be prepared in advance.**

1. Discuss the etiology, pathology, clinical features and management of carcinoma of the breast
2. Discuss differential diagnosis of a lump in breast. Discuss treatment of carcinoma of breast stage II.
3. Discuss differential diagnosis of a lump in breast. Give treatment of carcinoma of breast stage III.
4. Discuss the differential diagnosis of benign breast disease and the management of a case of fibroadenosis.
5. A 30 years old lady , mother of a son aged 10 , noticed a painful slowly growing lump in her right breast two months ago. The lump is 2 cm in diameter, mobile and free from skin and deep structure.
   - Write down the differential diagnosis.
   - What diagnostic procedures would you arrange ?
   - Out line the treatment plan.
6. Describe the staging of cancer breast. Discuss in brief the detection and management of early breast cancer.
7. Describe etiology, pathology and clinical features of breast abscess.
8. Write short notes on following:
   - Fibroadenoma of the breast
   - Cystosarcoma phylloides
   - Male carcinoma breast
   - Fibroadenosis
   - Breast abscess
   - Discuss early breast cancer
   - Triple assessment
   - Antibioma breast

26 The Esophagus

Contents

- Surgical anatomy
- Esophageal perforation
- Corrosive stricture of esophagus
- Achalasia cardia (cardio-spasm)
- Plummer-Vinson syndrome
- Mallory- weiss syndrome
- Dysphagia lusoria
- Schatzki's ring
- Gastro-esophageal reflux disease
- Hiatus hernia
- Neoplasm of esophagus
- Esophageal diverticula

SURGICAL ANATOMY

- The esophagus is a muscular coat which serves as conduit for passage of food and fluid from pharynx to stomach. Esophagus enters the abdomen through the esophageal hiatus of the diaphragm. It lies up to 2 cm below the diaphragm.
- The **length** of esophagus as measured from upper incisor tooth to the gastroesophageal junction is approximately 40 cm. *(many PGME)*

Constriction of Esophagus *(neet, pgi 86)*

Four anatomic areas of narrowing occur in esophagus.

Please see figure 26.1

(i) At the pharyngo-esophageal sphincter-at 15 cms → Narrowest sphincter.

(ii) At the crossing of arch of aorta- at 22 cms

(iii) At compression by *aortic arch and the left main bronchus*- at 27 cms

(iv) At the gastroesophageal junction- at 40 cms.

Muscle layer

The *mucosal lining of esophagus is Squamous except for lower 2 cm, which is lined by columnar epithelium.* *There is no serosal layer in esophagus.* Esophagus has inner circular layer and outer longitudinal layer.

- *Upper 1/3 of esophagus contain:* Skeletal muscle fibers (voluntary)
- *Lower 2/3 of esophagus contain:* Smooth muscle fibers (Involuntary)

Nerve Supply

Parasympathetic nerve supply is mediated by vagus nerve, which has synaptic connections to myenteric (Auerbach) plexus. *Meissner's submucosal plexus is absent in esophagus.*

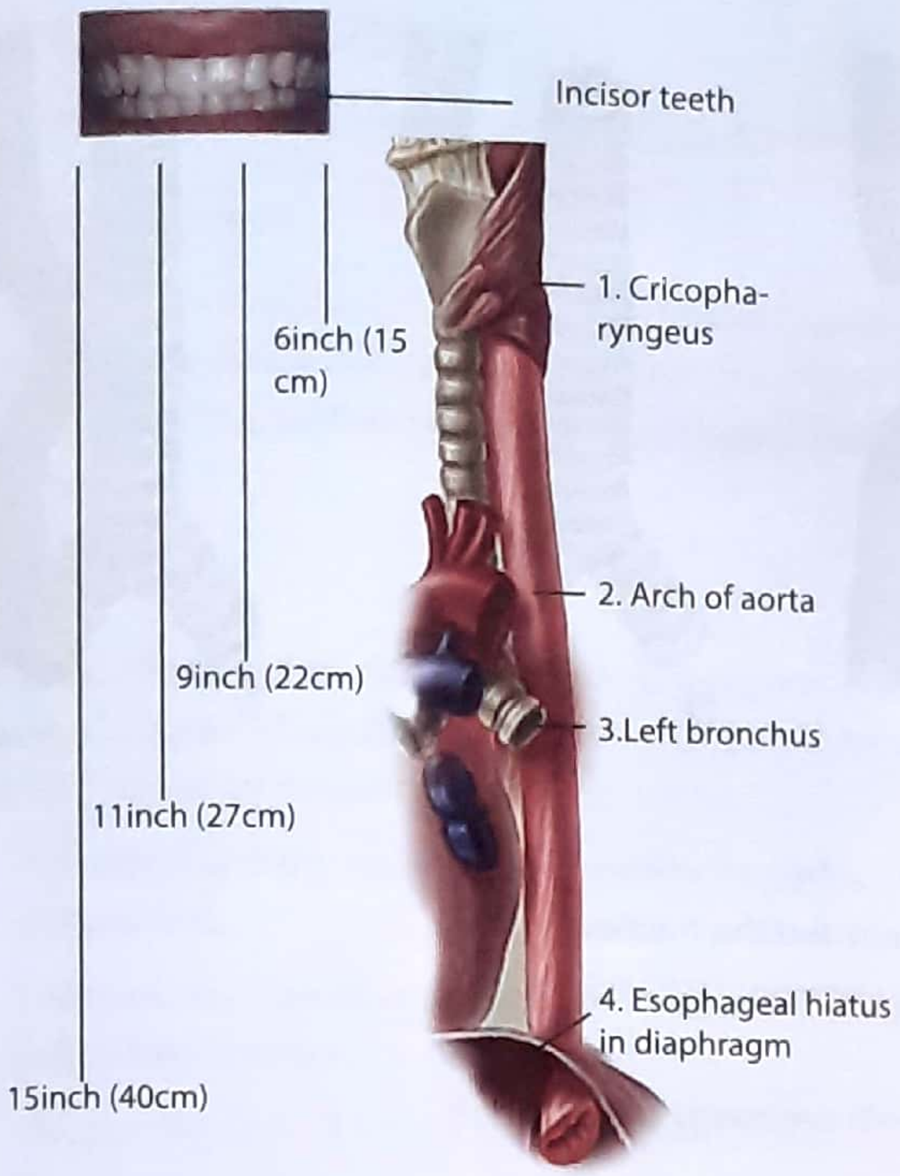

Figure 26.1: Constrictions in the esophagus. On the left side, distance of these sites from the incisior teeth are given.

Blood Supply

Arterial Supply

- Upper part (Cervical part) is supplied by inferior thyroid artery.
- Middle part (Thoracic) is supplied by the branches from the bronchial arteries and esophageal branches, arising directly from aorta.
- Lower part (Diaphragmatic and abdominal segment) is supplied by:-
- Left inferior phrenic artery
- Esophageal branches of left gastric artery

Venous Return

- Upper part (Cervical part): by Inferior thyroid vein
- Middle part (Thoracic Part): Azygous and hemi-azygous vein.
- Lower part (Abdominal Part): Left gastric vein

Esophageal Sphincter

- There are two sphincters **upper and lower**.
- The **upper sphincter** is made up of powerful striated (voluntary) muscle.
- At the lower end there is a physiological sphincter, which prevents reflux of gastric acid or bile into esophagus and is known as lower esophageal sphincter (LES).
- The upper esophageal sphincter is normally closed at rest and serves to protect regurgitation of esophageal contents into respiratory passage (trachea).
- The **lower oesophageal sphincter** prevents regurgitation (reflux) of gastric contents into lower esophagus.

RECAP: *Till now we were discussing brief surgical anatomy of esophagus, now we will discuss diseases related to esophagus.*

****

CONGENITAL ESOPHAGEAL ATRESIA AND TRACHEOESOPHAGEAL FISTULA

Atresia

Congenital absence or closure of a normal body opening or tubular structure.

Fistula

Abnormal tube like connection between a normal cavity, or tube to another cavity or tube.

Esophageal atresia is varying degree of developmental failure. Tracheoesophageal fistula is the commonest congenital anomaly of esophagus. Several clinical types exist, associated with varying degrees of esophageal atresia of the esophagus.

Types of Tracheo esophageal Fistula

(i) Atresia of esophagus with fistula *between the trachea and the distal segment of esophagus* - M/C type (85%) *(PGI June 99, many times)*. Figure 26.C

(ii) Atresia of esophagus without tracheoesophageal fistula (about 8%). Figure 26.D.

(iii) Atresia of the esophagus with fistula between the blind upper segment and the trachea (1%). Figure 26.B.

(iv) Esophageal atresia with fistulous communication between both segment and trachea (about 1%). Figure 26.E

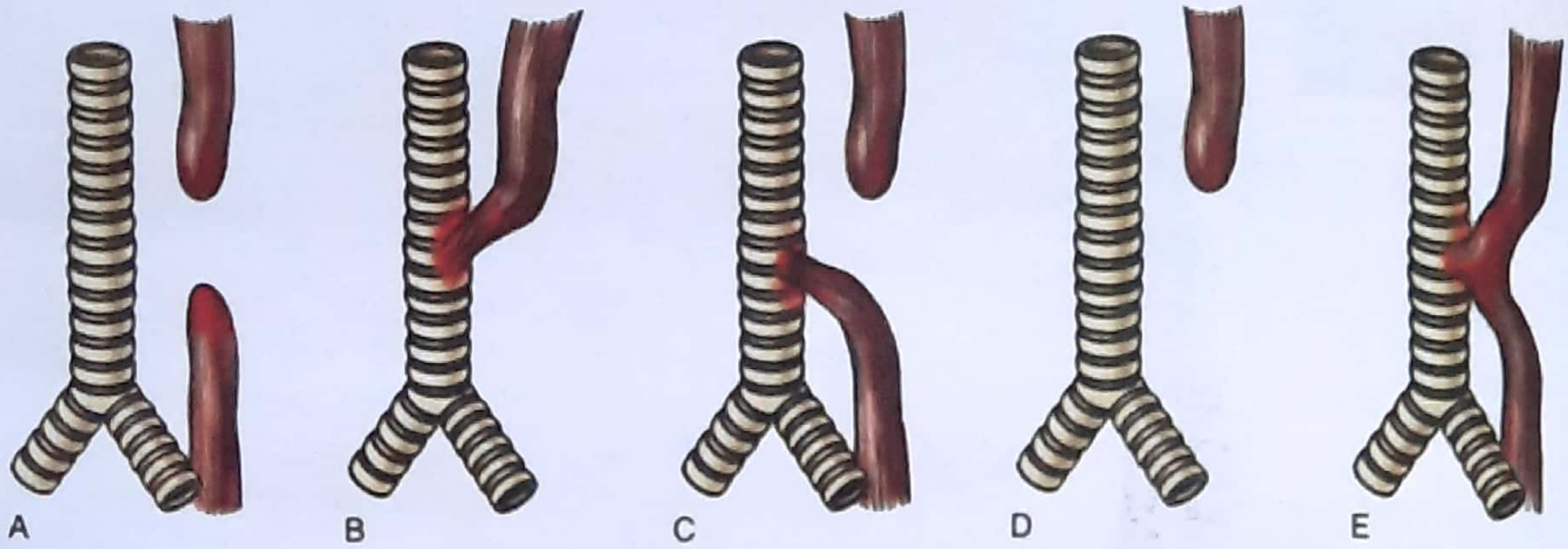

Figure 26.2: Tracheoesophageal fistula

(A) Atresia of esophagus with out Tracheoesophageal fistula

(B) Atresia of esophagus with fistula between blind upper segment and the trachea

(C) Atresia of esophagus with fistula between trachea and distal segment (M/G-85%)

(D) Atresia of esophagus without fistulous communication

(E) Esophageal atresia with fistulous communication between both segments and trachea

(v) Fistula between normal esophagus and the trachea (about 5%)

- The most dangerous type of fistula are, those in which swallowed material (the first milk meal of a new born) passes into trachea, causing severe acute respiratory distress with cyanosis and aspiration pneumonia.
- There is slight male predominance.
- Most of these infants are premature.
- In 40-50% of the cases, there are other associated anomaly- VACTERAL

  V - Vertebral defect

  A - Anal atresia (imperforate anus)

  C - Cardiovascular abnormality (M/C-TOF)

  TE - Tracheo Esophageal Fistula

  RA - Renal Agenesis

  L - Limb hypoplasia

A *history of Hydramnios** is *present is majority of mothers* because fetus is not able to swallow and absorb the amniotic fluid due to atresia. (PGME)

** Hydramnios?*

An excess of amniotic fluid, which leads to over distention of uterus. The normal amount is 500-1000 ml, but may be more than 3000 ml in hydramnios.

Clinical feature

- Tracheoesophageal fistula is commonest congenital anomaly of esophagus.
- It is important to recognize this anomaly early.
- *High index of suspicion should be kept in mind for a baby born to a mother with Hydramnios.* (PGME)
- *Earliest and most important clinical feature of esophageal atresia is* ***regurgitation*** *(outpouring) of saliva at its first and subsequent feed.* (UP 93,98, ahms, many PGME)
- *There is continuous out pouring of saliva from the mouth.*
- *Persistence of feeding may produce* ***aspiration, choking, cyanosis, and respiratory distress.*** (NEET, PGME)

Diagnosis

The diagnosis is confirmed by introducing a soft rubber catheter (infant feeding tube)

↓

If it can not advance for more than 10 cm from the lip

↓

Confirms the diagnosis

Radiological Examination

Radiological confirmation: By contrast X-ray study.

X-ray of abdomen

Gas in stomach confirms that lower end of esophagus has communication with the trachea. Absence of air in stomach usually means that distal tracheoesophageal fistula is not present.

Management

The only treatment to this condition is surgery. Before surgery the general condition of newborn should be improved. Following measures are undertaken.

1. Nursing the baby is head up position to reduce regurgitation.
2. Frequent suction of oral cavity to reduce trickling of saliva into trachea.
3. Administration of broad spectrum antibiotics.
4. Correction of fluid and electrolyte imbalance, if present.

Operation

Right sided thoracotomy (opening of thorax) is done, then:-

- The fistulous connection between trachea and esophagus is identified and divided (Cut down). Now end to end anastomosis (between two ends of esophagus) is performed between the proximal and distal segment of esophagus.

ANASTOMOSIS?- an operative union of two hollow or tubular structures.

Complication

1. Leakage at the anastomosis is the most common complication.
2. Mediastinitis.
3. Septicemia

****

ESOPHAGEAL PERFORATION

- The absence of serosa in the oesophagus makes it more likely to rupture. The causes of perforation are:-

1. Inexpert *instrumentation* (Most common cause) eg. esophagoscopy *(PGI87)*
2. Penetrating injury to neck and thorax
3. Spontaneous perforation

Cause

1. Inexpert instrumentation

This is **most common cause** *(NEET)* of esophageal perforation and the most *common site being the posterior wall just above the cricopharyngeal sphincter* in cervical esophagus and next most common site is just above the cardia. *(Imp. point)*

2. Penetrating injury

Penetrating injuries are now gradually becoming commoner. This may result from penetrating injury (like by a sharp knife) to neck, chest and upper abdomen.

3. Spontaneous Perforation (Boerhaave's Syndrome) *(UP 07, UPSC 08, COMED 07)*

Spontaneous perforation occurs mainly in men after alcoholic excess or in association with **severe vomiting** *(NEET)*. *The rupture is more common in* ***distal*** *part of esophagus and usually involves* ***all layers*** *(NEET) of the esophageal wall (PGME)*

Most common location of rupture in left poterolateral aspect 3-5cm above GE junction.

Symptoms

Symptoms of Esophageal Perforation are:-

1. **Severe pain in the neck, chest or upper abdomen.** *(NEET 20)*
2. **Nausea, hematemesis, dyspnea, tachycardia and hypotension are common feature.** *(NEET 20, UP 2000)*
3. Large perforations may cause shock and **pleural effusion** *(NEET 20)*

Management

Investigation

Plain X-ray of the chest is investigation of choice *(NEET)* which will show features of pneumo-mediastinum; ie; air in the mediastinum.

Treatment

- The principles of management after diagnosis include (1) treatment of contamination, (2) wide local drainage, (3) source control, and (4) enteral feeding access.

- Recently, endoscopic vacuum therapy (EVT) has emerged as an option for surgeons in the management of esophageal perforation
- Most perforations of esophagus are best treated by immediate surgical exploration, repair and drainage after initial resuscitation.
- The **mortality rate rises many times**, if the perforation is treated surgically beyond 24 hours. If should be noted that the mortality rate is higher in intrathoracic perforation than cervical perforation. For intrathoracic esophageal perforation, the repair within 24 hours has mortality rate of around 10%. If the treatment is delayed beyond 24 hours, the mortality rises to 50% due to associated mediastinitis & toxaemia. Non-operative management can be considered in patients with very poor general condition or in cases with very small perforation.
- Non-operative management includes nil orally, IV. antibiotic therapy, nasogastric, aspiration, parenteral nutrition and ICD.
- Mortality rate is higher than mallory weiss tear.

CORROSIVE STRICTURE OF ESOPHAGUS

Ingestion of strong acid or strong alkali
(Hydrocyanic acid, nitric acid) cause

↓

Edema, congestion, inflammation of mucosa and submucosa of oesophagus
(In acute phase)

↓

Acute phase last for 2-3 weeks

↓

Acute phase passes off & healing occurs with stricture formation

NOTE: Corrosive stricture of esophagus usually involves the lower segment of esophagus and stricture may be multiple in number, where as stricture due to carcinoma of esophagus in usually single and is in mid esophagus.

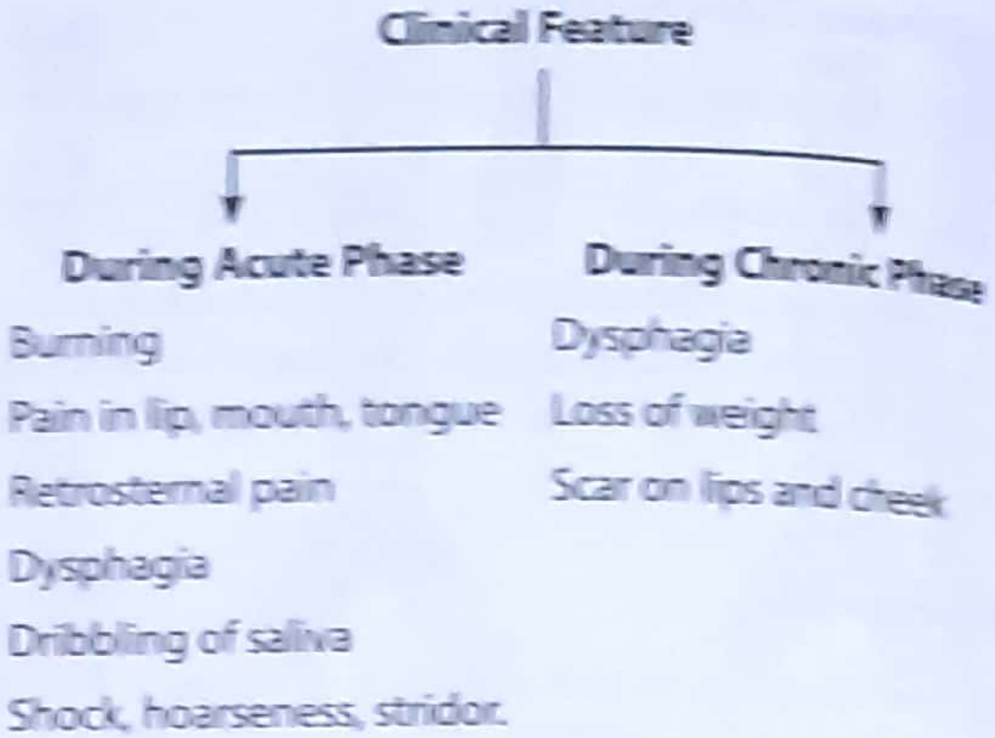

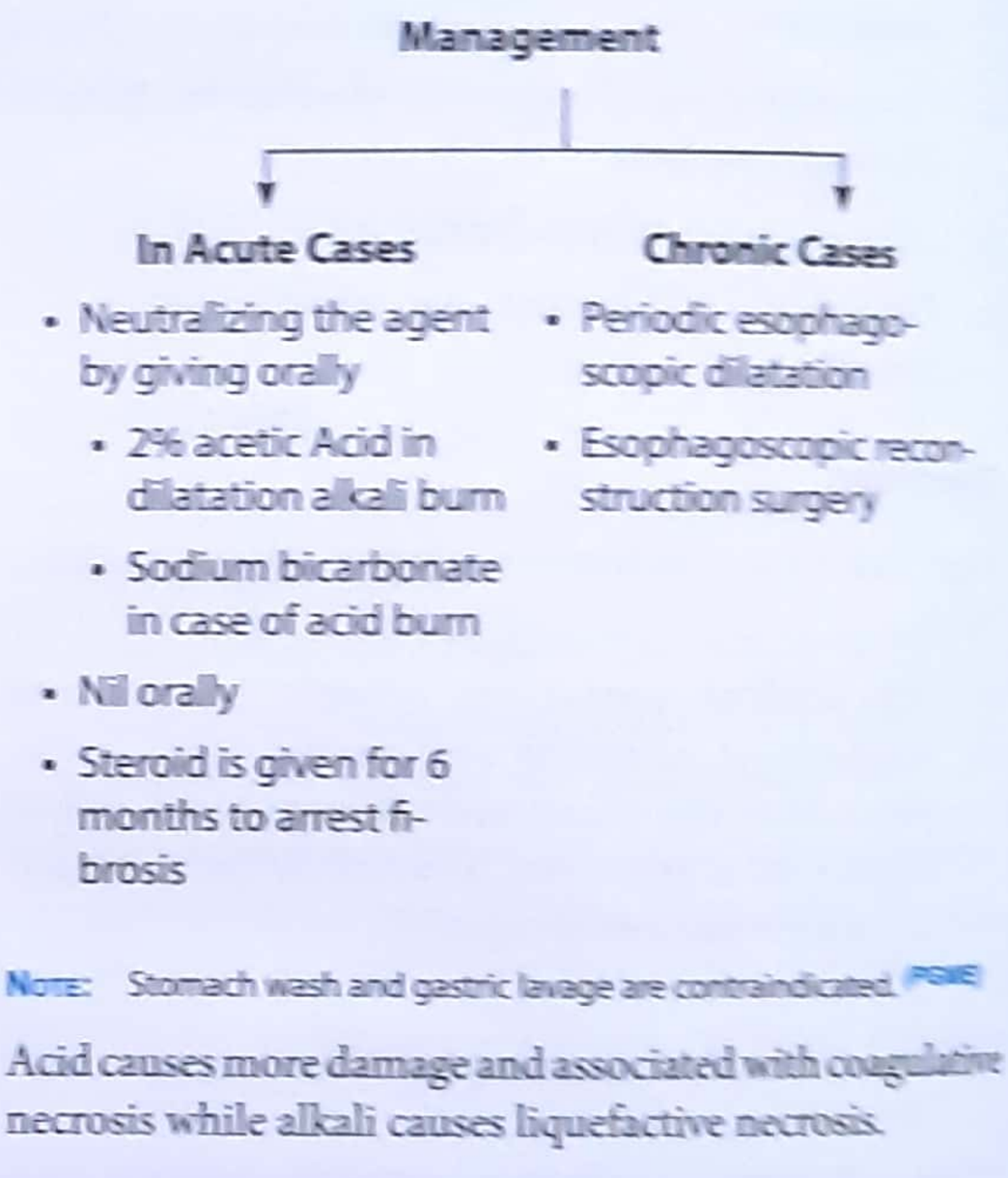

NOTE: Stomach wash and gastric lavage are contraindicated. PGME

Acid causes more damage and associated with coagulative necrosis while alkali causes liquefactive necrosis.

Other cause of benign esophageal stricture

- Tuberculosis
- Syphilis
- Herpes
- Radiation
- Secondary to reflux esophagitis
- Crohn's disease
- Schatzki's ring
- Plummer Vinson Syndrome

KEY BOK 26.0	
Classification scheme for caustic ingestion	
ENDOSCOPIC FINDING	**GRADE**
Normal	0
Superficial edema/erythema	1
Mucosal/submucosal ulceration	2
Superficial edema/erythema	2A
Deep or circumferential	2B
Transmural ulcerations with necrosis	3
Focal necrosis	3A
Extensive necrosis	3B
Perforation	4

ACHALASIA CARDIA (CARDIO SPASM)

Achalasia-a Greek word which mean failure of relaxation. In this condition there is **failure of relaxation of the lower esophageal sphincter** due to loss of ganglion cells in body of esophagus.

↓

Results in failure of peristalsis

↓

Dilatation, tortuosity and hypertrophy of the esophgus above the sphincter

↓

Dysphagia (Difficulty in swallowing)

In fact it is a motility disorder, in which peristalsis is either absent of much feeble in the body of esophagus.

Lower sphincter fails to relax during swallowing, resulting in dilatation, tortuosity and hypertrophy of the esophagus above the sphincter.

Types of Achalasia

IRP = Integrated relaxation pressure

DCI = Distal contractile integral

DL = Distal latency

Etiology

1. **Absence (1°) or degeneration (2°) of Auerbach's plexus through out the body of esophagus.** (NEET)
2. Emotional stress.
3. **Chaga's disease** (NEET) caused by *trypanosoma cruzi.* Which causes **destruction of ganglion cell of Auerbach's plexus**.

Clinical Feature

Though it occur at any age, It is more often seen between the age of 30-35 years, with **female to male ratio being 3:2.** (NEET) *Patients usually present with 3 main features:*

(a) Dysphagia

Patient mainly complains of obstruction in swallowing at the low retrosternal area. (NEET) *Patient feels obstruction particularly in case of liquid food, where as solid food seems to pass more easily.* This is only one condition where swelling of solid is easier than liquid, in all over conditions of dysphagia, liquids are more easily swallowed than solids.

In each type, there is impaired EGJ relaxation

Type I (classic)

- 1RP > 15 mmHg cm^2
- 100% failed peristalsis

Type II

- IRP > 15mmHg cm^2
- Panesophageal pressurisation with ≥20% of swallows

Type III (spastic)

- IRP > 15mmHg cm^2
- Premature contractions with ≥ 20% of swallows (premature contraction are - with)
  DL < 4.5 sec &
  DCI >450 mmHg cm^2

Reason

Solid Food

↓

Forms a bolus and is heavy

↓

Produce more gravity action

↓

Opens up the lower oesophageal sphincter

↓

Passage of food

Where as liquid, which is lighter than solid food, is unable to produce more gravity action and hence can not be passed easily. Dysphagia more for liquid than solid. *(PGME)*

(b) Regurgitation:

There is regurgitation of food obvious at night when patient is recumbent. Regurgitation may lead to aspiration of contents in trachea and development of pulmonary complication.

(c) Weight Loss:

Investigation *(aiims 79, pgi 78)*

1. Barium Study

(i) Shows *"Bird's beak" or "Parrot Beak" appearance, ie;* dilated esophagus with tapering narrowing in the terminal end of esophagus. *(UP 03)* (Figure 26.5)

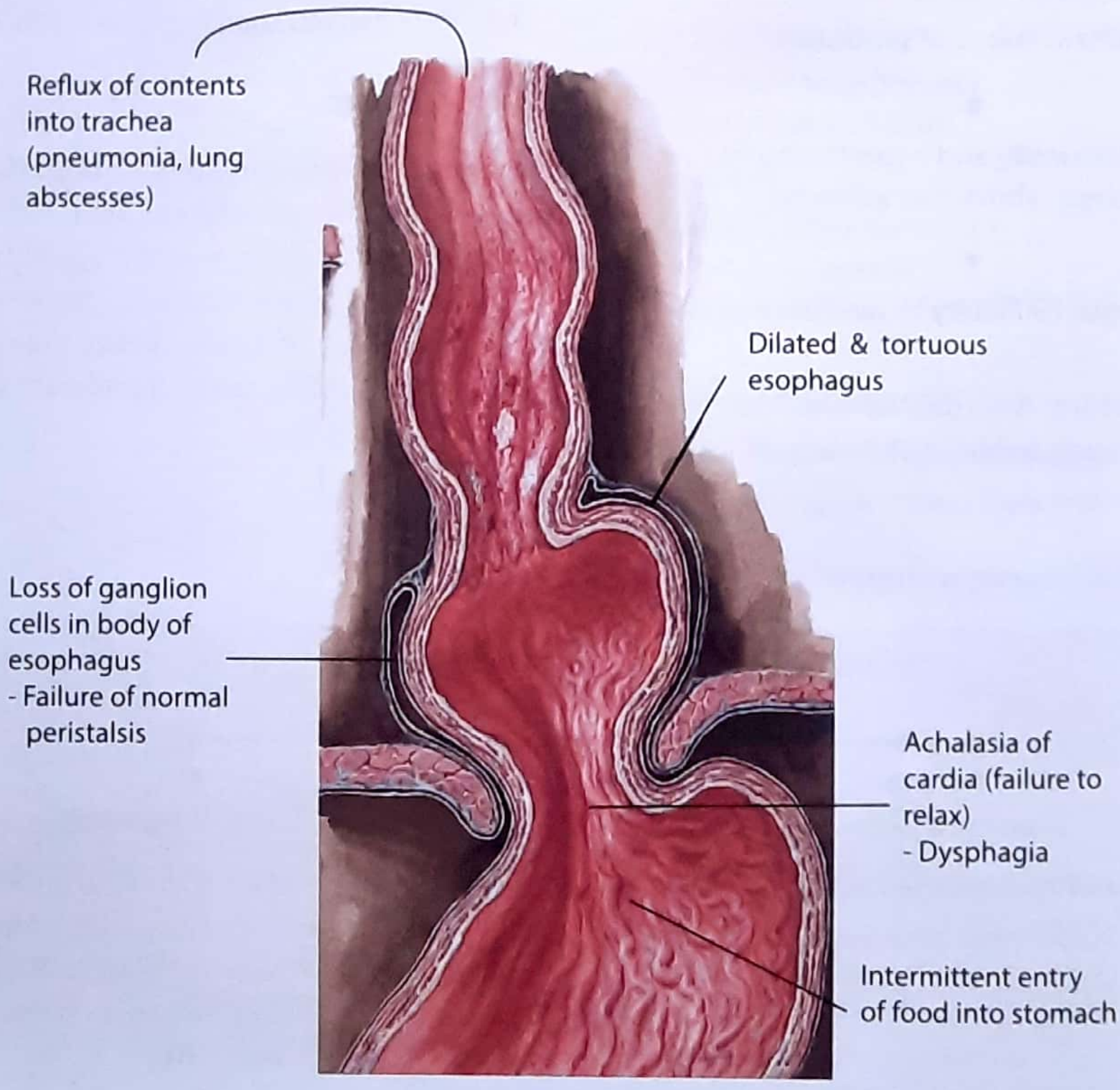

Figure 26.3: Achlasia of the cardia. The primary defect is a failure of normal peristalsis due to loss of ganglion cells in the body of the esophagus, this leads to failure of relaxation (achalasia) of the lower esophageal sphincter (cardia)

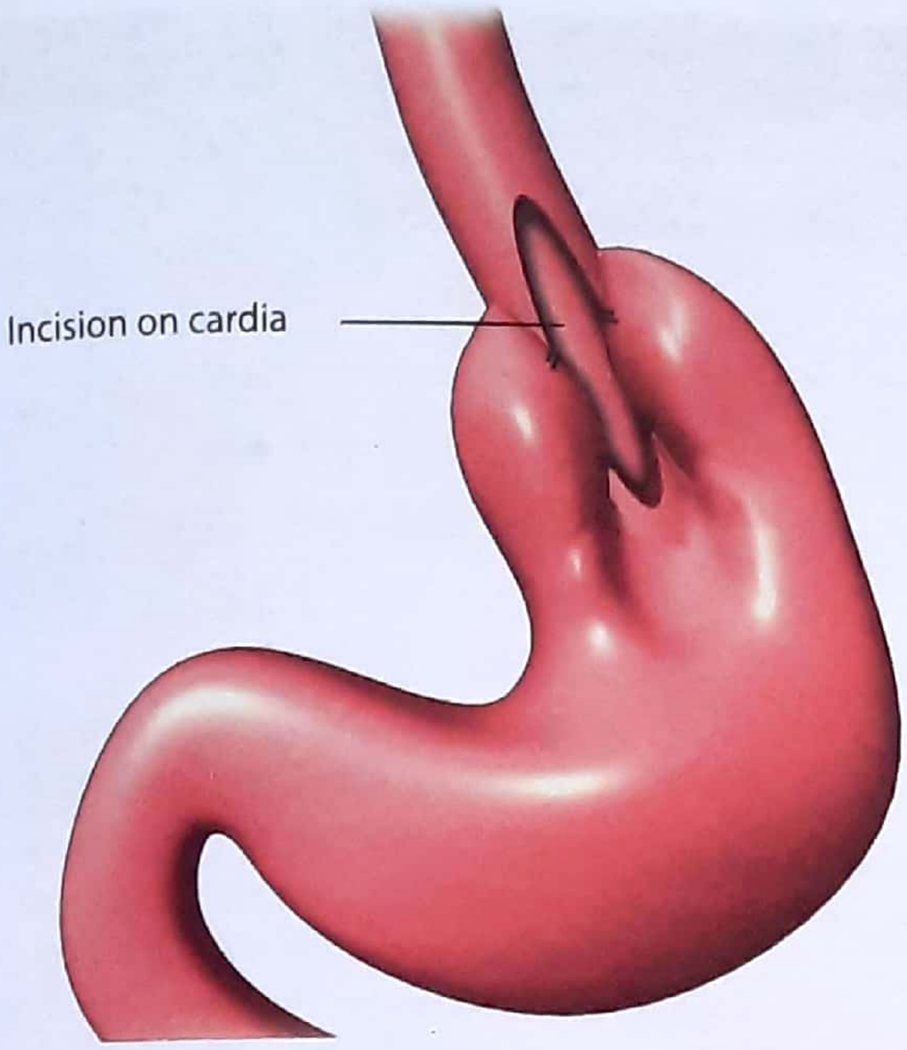

Figure 26.4: Heller's cadiomyotomy

Figure 26.5: Achalasia: Bird's beak or Rat tail appearance in Barium Swallow

(ii) **Absence of gas bubble in stomach** *(NEET)*

(iii) *Sigmoid esophagus,* esophagus takes shape of sigmoid.

(iv) Barium study should be 1st investigation in patient with dysphagia.

2. Esophagoscopy

This will reveal grossly dilated esophagus, and helps to rule out any malignant growth in esophagus.

3. X-ray Chest

(a) Dilated esophagus produces a picture like that in a tumour (Pseudo tumour)

(b) Retro cardiac air fluid level in lateral view.

4. Pressure study (esophageal manometry)

The normal pressure at LES is 13.8-14.6 mm of Hg. In achalasia it is **often more than 2 times the normal value**. *(nEET)* This is ***gold standard*** *(nEET)* ***investment for achalasia cardia***. *(INICET NOV 20, UP 99, many PGME)*

Treatment *(please see flow chart 26-1 on back page)*

The aim of treatment is to relieve the obstruction at cardia. This can be achieved by either dilating forcefully the constricted part (Pneumatic force full dilatation) or by the cutting (dividing) the muscles, that are responsible for obstruction (Myotomy-myo; means muscle + otomy means cut. See flow chart, in key box 26.1 on next page & Fig. 26.4)

Per oral endoscopic myotomy (POEM) is a new approach done in achlasia.

Esophagectomy is considered in any symptomatic patient with a tortuous dilated esophagus (megaesophagus), sigmoid esophagus, failure of more than one myotomy, or reflux stricture that is not amenable to dilatation.

Complication

As a result of stasis and chronic irritation, metaplasia of mid and lower esophagus occurs, which may *predispose to* ***Squamous cell carcinoma*** *(NEET, PGME)*. Aspiration of the content of the dilated esophagus into trachea may lead to aspiration pneumonia.

****

MISCELLANEOUS ESOPHAGEAL LESION

Plummer-Vinson syndrome (Patterson-Brown-Kelly syndrome/Sideropenic dysphagia)

(pgi June 2000, many PGME)

This disease is commonly seen in

KEY BOX 26.1 (PGI 08)

Treatment options of achalasia cardia

(Basic pathology is failure in relaxation of lower esophageal sphincter)

Dilatation

↓

Dilatation of the lower esophageal sphincter complex is done using

↓

A pneumatic balloon

(Balloon filled with air)

↓

Causes disruption of muscle

↓

Makes it less competent to constrict

↓

Relieves obstruction

↓

- Chief complication is perforation- when a large balloon is used

Heller's Myotomy (AIIMS 03, UP 98)

↓

Cutting the muscle of the lower esophagus and cardia

This can be done through two routs

(i) trans-abdominal route

(ii) trans-thoracic route

(iii) Laparoscopie approach is more favoured these days

Others

↓

(i) **Botulinum toxin** injection into cardio- esophageal sphincter:- It acts by binding to presynaptic cholinergic nerve endings and produce paralysis &£ sphincter within hours. Problem with this treatment is its high recurrence rate (AI 02)

(ii) **Calcium channel** blockers (Nifidipine)-

Causes relaxation of LES.

↓

Decreases Pressure in cardio-esophageal sphincter

↓

Relieves obstruction at LES

(iii) Motility improving agents

- A women between 35-45 years
- Patient presets with
  1. Glossitis (inflammation of tongue)
  2. Brittle nail (often spoon shaped)
  3. Dysphagia
  4. Iron deficiency anemia (Key box 26.2)
- *Dysphagia:* is often associated with upper esophageal stricture with fibrous ***web*** -*(Post-cricoid web)* (UP 05)
- *Associated with koilonychia, glossitis, cheilitis and splenomegaly.*

KEY BOX 26.2
C/F of Plummer vinson, Patterson Kelly Syndrome
[Mnemonic : K.G. WARD]
K- Koilonychia (brittle nail)
G- Glossitis & atrophic oral mucosa
W- Esophageal **W**eb, in **W**omen (UP 05)
A- Anemia (Chronic Iron deficiency)
R- Round about 40 years of age of patient
D- Dysphagia

KEY BOX 26.3	
Intermittent dysphagia	**Progressive dysphagia**
• Diffused esophageal spasm • Reflux esophagitis • Esophageai diverticula • Schatzki's ring (esophageal web)	• Achalasia cardia • CA esophagus • Esophageal-stricture

- *Dietary vitamin deficiency has been established as a cause.* (many PGME)

Treatment

- Improving anemia
- Forceful dilatation of the web.

NOTE: *Plummer Vinson syndrome is a premalignant* condition. (many PGME) increased risk for squamous cell CA of esophagus has been observed.

****

MALLORY-WEISS SYNDROME (UPSC 08)

- Forceful vomiting may produce a **longitudinal** (NEET) ***mucosal*** **tear at cardia, rather than a full thickness perforation** of esophagus. (PGME) {Mind the word mucosal, because tear occurs only in mucosa}.
- Majority of patients are alcoholics. (UP 04)
- NOTE: In ***Boerriaave's syndrome*** *(page 373)* vomiting occurs against a closed glottis and pressure builds up in the body of esophagus and resulting esophageal tear is **usually full thickness,** while in Mallory- Weiss syndrome vigorous vomiting produce a vertical split in ***gastric mucosa*** at cardia in about 90% cases. In only 10% cases, tear is in lower esophagus. The **disruption is usually limited to mucosa,** and does not extent into muscularis mucosa or beyond.

Treatment

Patient is treated conservatively. Surgery is rarely required.

****

Dysphagia Lusoria (PGI 97, 2000, AIIMS 03)

Several vascular anomalies may produce dysphagia by compression of the esophagus eg; by a **vascular ring** such as double aortic arch, **aberrant right subclavian artery** (NEET) etc. (Figure 26.7)

Schatzki's Ring (pgi Dec 98, PGI 2010)

It is a *esophageal web* in its lower most past. This web appears at the squamo-columnar junction within l-2 cm above **gastroesophageal junctions**. In majority of cases the condition is asymptomatic. Dysphagia occurs only

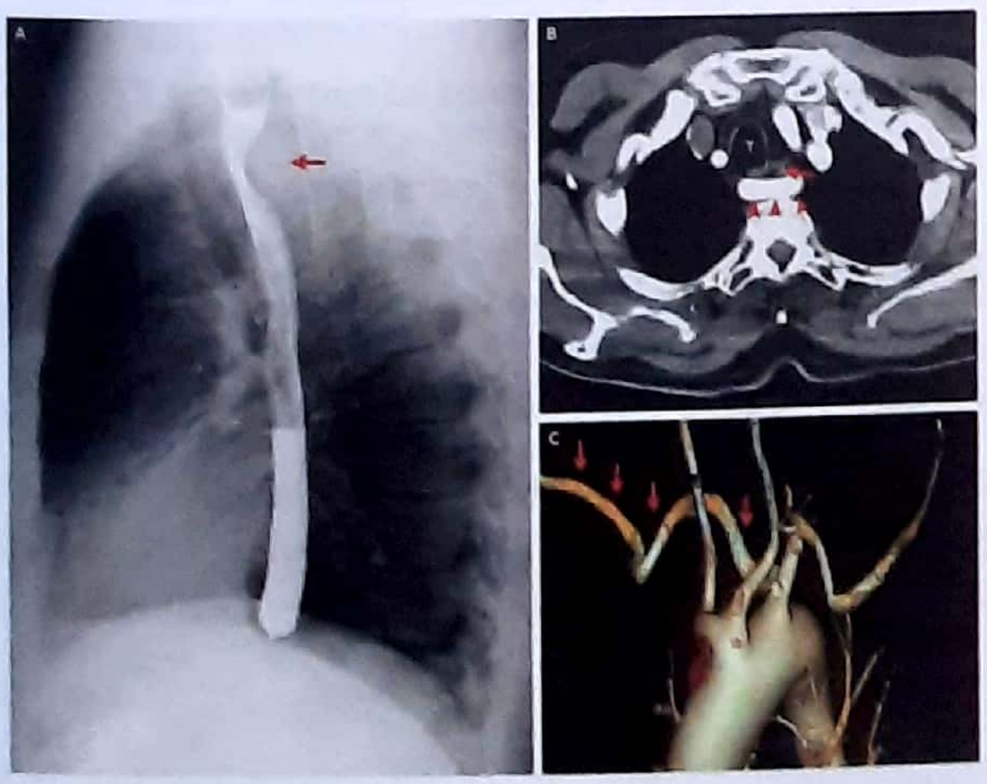

Figure 26.7: Dysphagia Lusoria

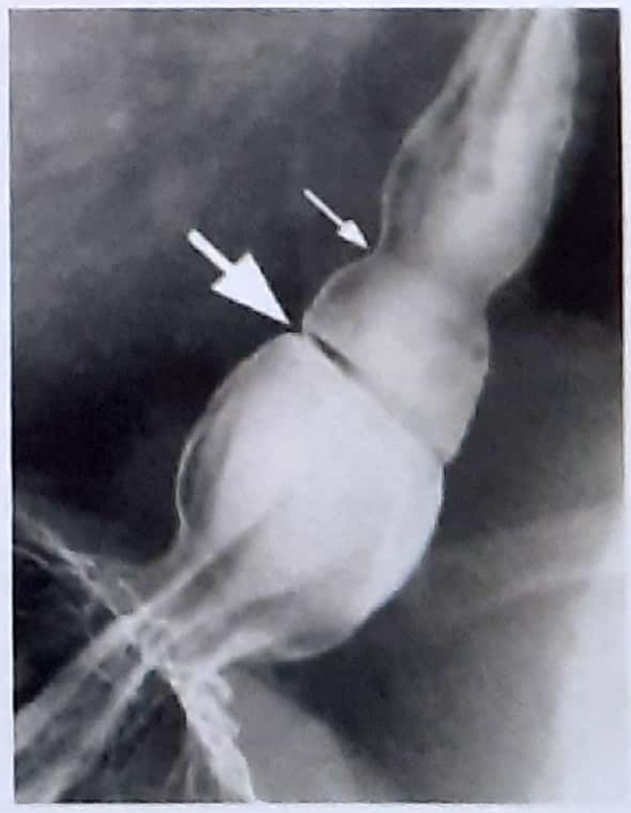

Figure 26.8: Schatzki ring: In Barium swallow Large arrow points to the Schatzki ring or B ring, and the small arrow points to the A ring.

Figure 26.9: Barium swallow showing 'cork screw appearance' in Diffuse esophageal spasm

when the internal diameter of esophagus becomes less than 15 mm. Episodic dysphagia to solids only remaining same for years. (Figure 26.8)

Treatment

Intermittent esophageal bougie dilatation.

Diffused Esophageal Spasm (Corkscrew Esophagus) *(al 02, pgi 97)*

- This disease is almost always associated with some psychic problem.
- This condition is more common in female.
- Pain and **dysphagia are the two main symptoms.** Pain is usually located in retro-sternal area and is severe.
- Dysphagia is not progressive.
- Pain often resembles to the pain of angina pectoris.

Diagnosis

ECG - EGG is done to rule out coronary artery disease

Barium Meal : A typical abnormality is curling or **cock screw** is observed.

Treatment

- Medical treatment with nitroglycerine may be tried, but before starting treatment with nitroglycerine, one must be sure of diagnosis, because nitroglycerine exacerbate angina.
- Bougie dilatation may be required to relieve pain.
- One more condition **feline esophagus** is seen in eosinophilic esophagitis & GERD.

****

GASTO-ESOPHAGEAL REFLUX DISEASE

(Reflux means return or back ward flow. In this disease there is return or backward flow (reflux) of gastric content into esophagus; hence named as gastro-esophageal reflux disease)

- Normal competence of gastoesophageal junction in maintained by the lower esophageal sphincter.

What does a competent gastroesophageal junction mean?

The lower esophageal sphincter (LES) remains closed during rest to prevent reflux of gastric content into the esophagus. The normal resting pressure of LES is 20 mm Hg; when this pressure becomes abnormally low the content from the stomach is refluxed into esophagus; causing reflux esophagitis.

The *esophagogastric functional area of the cardia is so designed that it normally does not allow gastric content to regurgitate into esophagus.* The cardia is assisted by the following for its better performance.

Please see figure 26.10 next page.

1. Intra-abdominal segment of esophagus *(PGI 01)*

An adequate length of the intra abdominal esophagus provides the physiological sphincteric role and plays an important role in the prevention of reflux.

2. Phreno esophageal ligament

It has an important supporting role. Due to laxity of this ligament in old age the true gastroesophageal junction slides up and may favour gastroesophageal reflux.

3. Angulation of esophagogastric junction

4. Sling fibers of the cardia

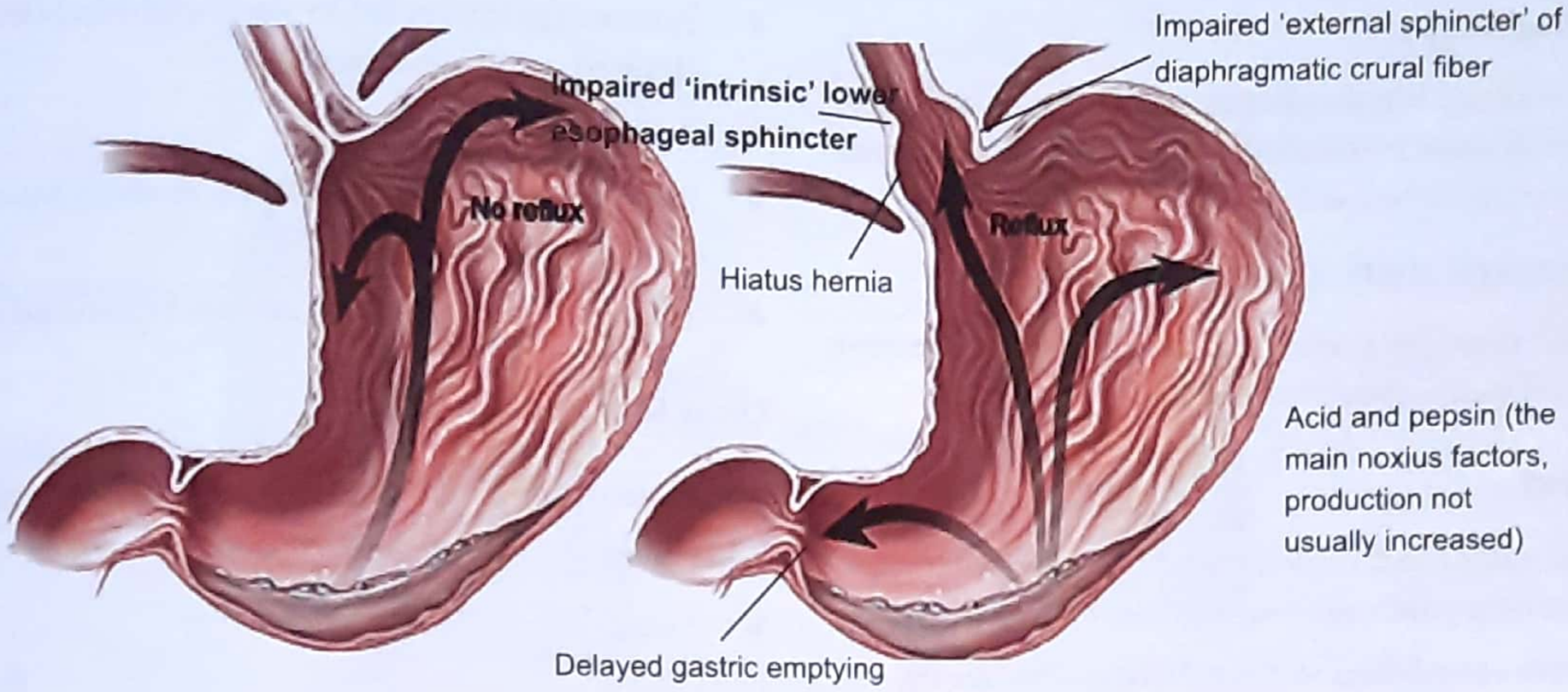

Figure 26.10: Factors associated with GORD

5. **Crura of diaphragm:** Mainly by arching fibres of right crus of diaphragm.

6. **Mucosal rosette**

Under normal circumstances the mucosa of the lower end of esophagus forms a water tight plug which helps in preventing reflux.

Clinical Feature

1. **Heartburn**

The main symptom of reflux esophagitis is heartburn. It is burning sensation that is localized behind the lower part of sternum

2. **Retro sternal Pain**

Retro sternal pain may be present. It mimics pain of peptic ulcer, cholelithiasis, pancreatitis, angina.

3. **Water brash**

Reflux of sour material up to the mouth is most common symptom. This may occur spontaneously or on bending forward.

4. **Dysphagia**

Transient difficulty in swallowing results from spasm due to inflammation of lower end of esophagus, or fibrosis (in late cases).

5. **Hematemesis and melena**

The mucosal ulceration in the lower esophagus may bleed causing hematemesis and melena.

Investigation

1. **24 hour PH recording**

It is *gold standard in diagnosis of GORD* (PGI 98). Decrease in **PH to less than 4** (NEET) in considered to be direct proof of presence of gastroesophageal reflux.

2. **Barium Meal**

Barium meal is given in Trendelenburg position (head low position). It will show reverse flow of barium.

KEY BOX 26.4

LES is relaxed by (resulting in reflux)	Increase LES pressure (protecting reflux)
• Drugs - Nitrates - CCBs - Dopamine - Anti cholinergics - diazepams • Coffee and tea • Alcohol • Obesity and fatty food • Smoking • Pregnancy	• Drugs - Antacids - Domperidone - cholinergics - Metoclopramide

3. Esophagoscopy

(Seeing inside of the esophagus with help of an endoscope). It will show evidence of esophagitis. Muscles look red and one can detect ulceration and erosion.

4. Manometric study (pressure study)

This study measures pressure at cardia. In incompetent LES, (i.e. relaxed) lower pressure may be recorded.

Treatment

- Avoid spicy food, coffee, tea, citrus fruits, chocolate. Please help your self from key box 26.4.
- Patients are advised to sleep 2 hours after meals.
- Patients are instructed to sleep with head end of bed elevated on 6 inches block.
- Reduction of weight.
- Patient must take small meals at short intervals (6 small meals than 3 meals)
- Tilting the bed is also efficacious (Head end up).

Drug Therapy

- **Protein pump inhibitor*** (PPI) decreases acid secretion
- H2 receptor antagonist
- Antacids :- neutralize acid

KEY BOX 26.5

PATHOPHYSIOLOGY OF GORD

Incompetent LES

↓

Reflux of acidic gastric content into lower esophagus

↓

Reflux esophagitis

↓

Diffused ulcerating and inflammation of lower esophagus

↓

Severe longitudinal Muscle spasm as a result of esophagitis	In long standing cases
↓	↓
Pulling up of esophagus	Fibrosis of lower esophagus
↓	↓
Resulting in displacement of cardia of stomach in thorax	Shortening of esophagus
↓	↓
Increased regurgitation, heartburn and retrosteraal pain	Pulling up of stomach in the thorax, resulting injiiatus hernia

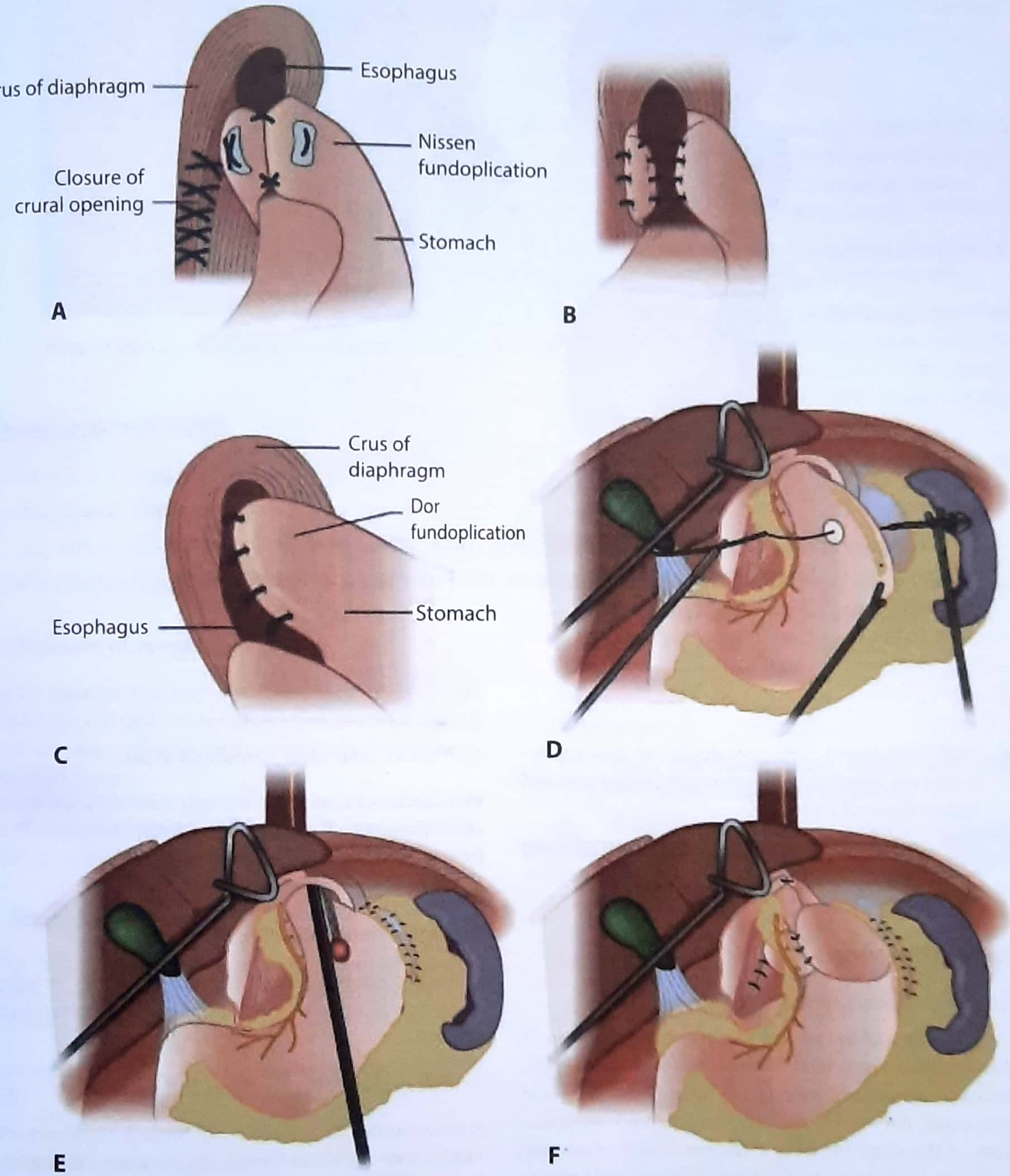

Figure 26.11: (A) Nissen fundoplication ; (B) Toupet fundoplication ; (C) Dor fundoplication; (D-F) Collis gastroplasty

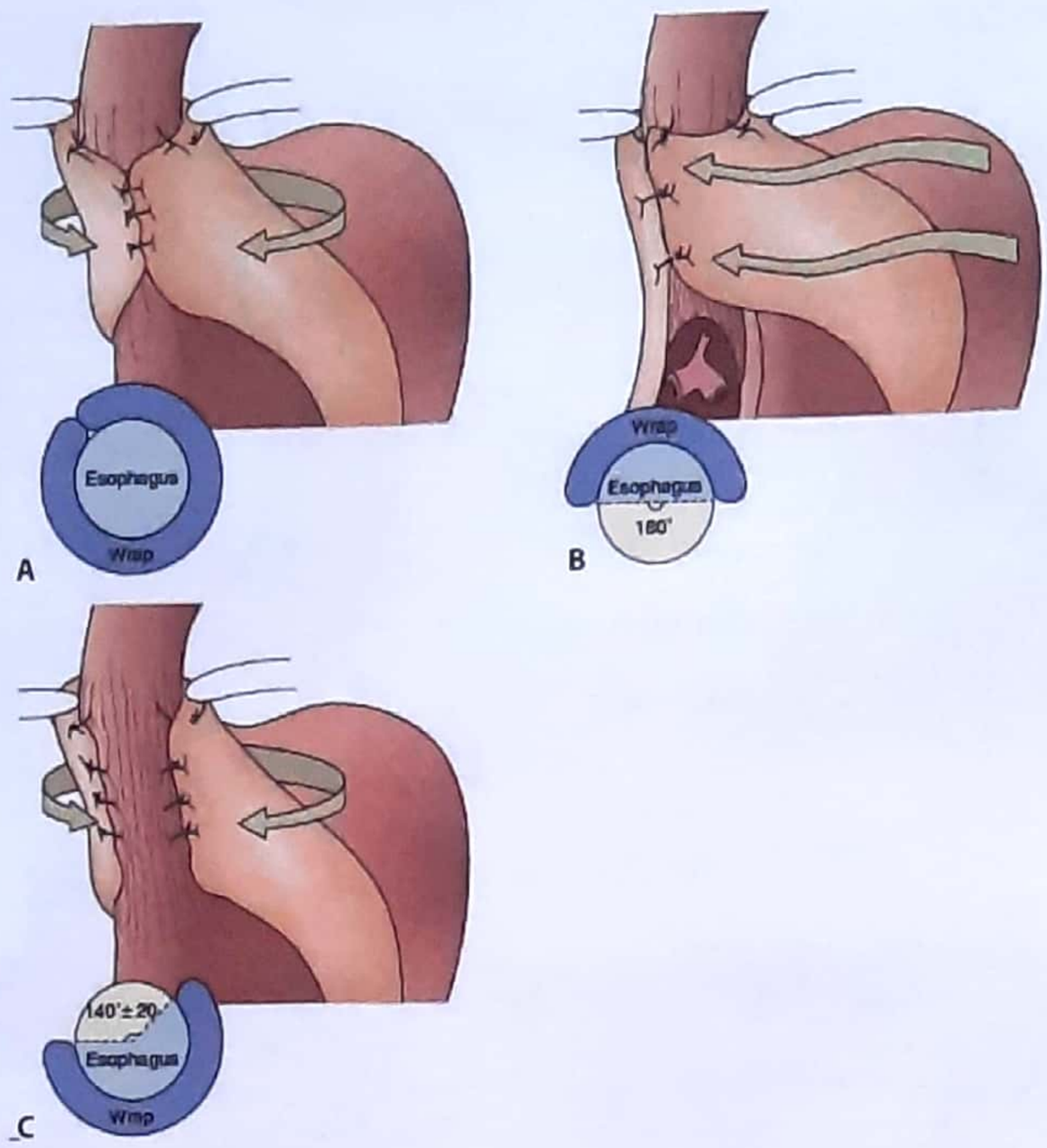

Figure 26.12: Three types of fundoplication : (A) A 360-degreee fundoplication. (B) Partial anterior fundoplication. (C) Partial posterior fundoplication

- Prokinetic agents-metoclopramide has shown to increase the amplitude of esophageal contraction and improve gastric emptying.
- **PPI :** (omeprazole, pentaprazole) are ***most effective medication*** (neet) for severe GORD. 8 wks is recommended.

Surgical Treatment

Surgical treatments are described below

Regardless of the procedure chosen, the basic tenets of antireflux surgery remain constant: (1) preserve natural tissue planes and linings, (2) identify and preserve both vagus nerves, (3) identify the true EGJ for placement of the wrap, (4) have sufficient length of intraabdominal esophagus, and (5) reestablish the angle of His.

Various anti-reflux operation are done, known as fundoplication. What is fundoplication (Fundus + Plication): Means - Fundus (parts of stomach) is plicated. Plication means stitching a fold to an organ wall.

1. *Nissen's total (360°) fundoplication* (NEET)

In it fundus of stomach is brought behind the lower end of esophagus and wrapped completely (hence 360°) in front of esophagus,- then fundus of stomach is stitched to the posterior wall of esophagus.

2. *Partial Fundoplication (Toupet)*

In this procedure fundus of stomach is not fully wrapped. It is wrapped up to the lateral wall of the esophagus and stitched.

3. *Belsey mark IV operation; Hill's repair*

A newer device named LINX can be used in patients with minimal or no hiatal hernia. It is a series of magnetic beads that are placed around the EGJ that will stretch with slight pressure in the esophagus, thereby mimicking the natural LES.

Postoperative dysphagia is a major cause of reoperation in Nissen patients.

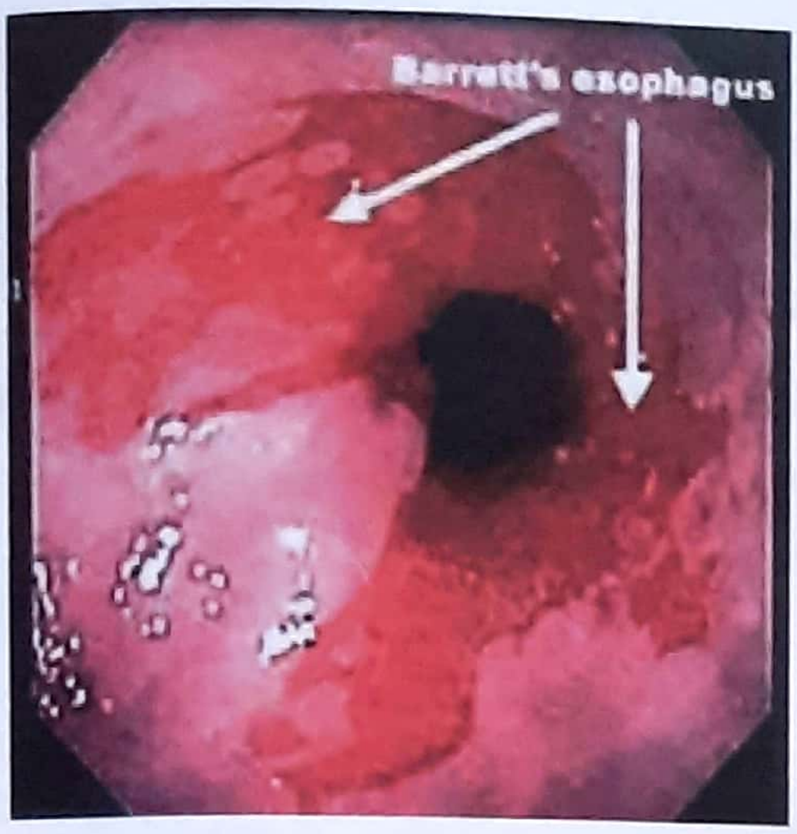

Figure 26.13: Barrett's esophagus

Complications of GORD

1. Stricture of esophagus
2. Esophageal shorting
3. Barrett's esophagus

Now lets discuss, them one by one:

1. Stricture of esophagus

Reflux induced stricture are common, usually in late middle age and in the elderly. It is important to distiguish a benign reflux induced stricture from a malignant stricture of esophagus.

Treatment is dilatation and long term treatment with PPI (omeprazole, pentaprazole, rabiprazole).

2. Esophageal shorting

With long standing reflux esophagitis, the esophagus has tendency to contract longitudinally and pull lower end of esophagus in thorax, producing a secondary hiatus hernia.

Treatment: Collis - Nissen operation. (figure 26.11) D-F

3. Barrett's esophagus *(very important topic for PGME)*

- The mucosal lining of lower part of esophagus is (non keratinized stratified) squamous epithelium.
- As a result of long standing reflux esophagitis ***metaplasia*** *occurs, and the normal* ***S****quamous epithelium is replaced by* ***C****olumnar epithelium which is, then called as barrett's esophagus* *(NEET, AI 02, AIIMS 93)*.
- Diagnosis is made if any length of columnar mucosa is found in esophagus on endoscopy that shows **intestinal metaplasia on biopsy** *(NEET)* (Hallmark is presence of intestinal goblet cells)*(AIIMS 06, 10)*

To Remember: S is turned to C ie; S → C

- Several type of gastric mucosa (or intestinal mucosa) may be found in the lower esophagus and if a peptic stricture occurs in Barrett's esophagus, it *always occurs at new squamous columnar junction* *(AIIMS 98)*
- *Barrett's esophagus is a* ***premalignant condition*** *for adenocarcinoma of esophagus* *(AIIMS 97, many PGME)*
- *Barrette's esophagus is a premalignant condition and there is an increased risk of adenocarcinoma of the esophagus in order of 25 times that in the general population.* The condition is more common in men than women.
- **Barrett's ulcer** *(JIPMER93)*: *It is an ulcer in columnar lined portion of a Barrett's esophagus.*

Management

1. *Regular endoscopic screening with multiple biopsies* It should be done at least once in year to known about any dysplastic change or carcinoma in situ. If cancer is detected, resection is done. Malignancy in Barrett's esophagus is curable if detected in an early stage.
2. *Treatment*
   (a) **Treat underlying reflux disease with PPI** *(NEET)* (omeprazole or pentaprazole)
   (b) *Ablation:* (ablation means removal or destruction), of columnar cell lined barrett's mucosa by laser or photodynamic therapy or argon.

****

HIATUS HERNIA

Hiatus

Means an opening/aperture

Hernia

The protrusion or projection of an organ or a part of organ, through the wall of the cavity which normally contains it.

Hiatus hernia is herniation of stomach and/or gastro esophageal junction into the thorax, through esophageal hiatus in the diaphragm.

Types of Hiatus Hernia

There are three types of hiatus hernia:

1. Sliding or axial hiatus hernia
2. Para- esophageal or rolling hernia
3. Mixed type (consisting of both type)

Now lets discuss, one by one:-

1. Sliding or Axial Hiatus Hernia

This is the **commonest type** *(NEET)*, consisting of more than 80% of all cases of hiatus hernia. There is no typical hernia sac; hence it is not a true hernia.

As can be seen is figure 26.14 and 26.15, the stomach slides above the esophageal hiatus - hence known as sliding hernia. In fact there occurs upward dislocation of the cardioesophageal junction.

The condition may be asymptomatic, but symptoms appear when there is associated gastroesophageal reflux.

Causes of Sliding hernia

1. In obese individual- fatty tissue get deposited around esophageal hiatus, causing weakening of hiatus.
2. Muscular degeneration with advancing age
3. Pregnancy
4. ***Saints Triad;*** which includes *(many PGME)*
   a. Gall Stone
   b. Diverticulosis
   c. Hiatus hernia (Mnemonic: Stone Diverts Hernia)

Clinical Feature

Sliding hernia produces symptoms like (GORD). eg;

- Retrosternal pain (pain behind sternum).
- Retrosternal burning
- Dyspepsia (indigestion)
- Hematemesis and melena

Investigation: See under topic GORD on page 380-381.

On X-ray, retrocardiac lucency with air fluid level is seen

Treatment *(TN89)*

Conservative (medical) treatment: has been discussed in detail under topic GORD which includes PPI, H_1 blocker and antacids.

Surgical Treatment

The indication of surgical treatment are:

1. When symptoms are not controlled by medical therapy.
2. It the symptoms recur soon after stopping medical therapy.

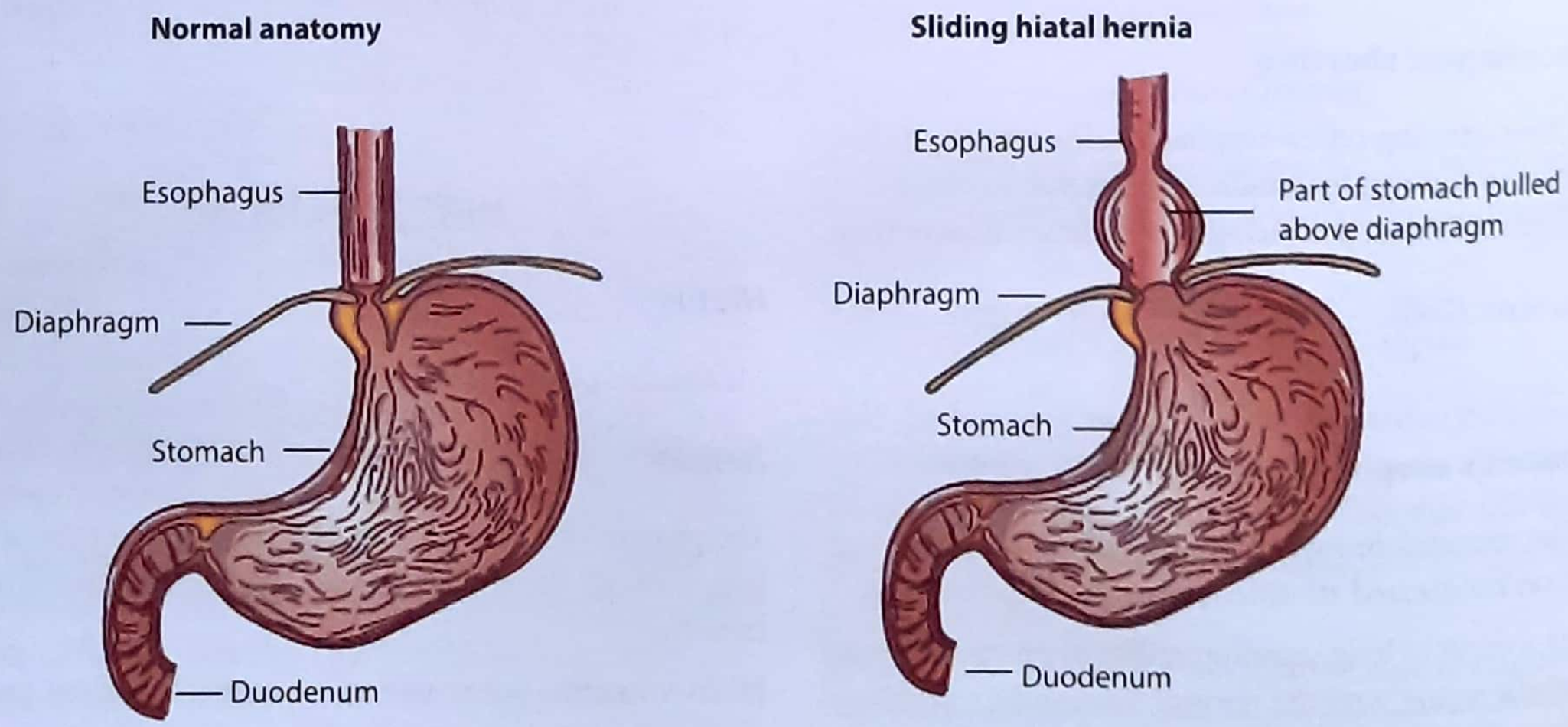

Figure 26.14: Sliding hiatus hernia

3. Esophagitis is intractable
4. Ulceration or stricture formation.
5. Higher grade dysplasia or metaplasia to columnar epithelium. When indication for surgical treatment are clear, the operation performed is known as anti reflux operation.
6. The aim of operation is directed towards restoration of intraabdominal segment of esophagus, and reducing (closing) the hernial defect.

- Various fundoplication operations has been discussed earlier in this chapter.

Complication of Sliding Hernia

- *Esophagitis (due to reflux):-* is the most common complication (AI 05)
- *Barrett's esophagus and Adenocarcinoma.* (many pgme)
- Aspiration and pneumonia
- Esophageal stricture

2. Para-esophageal or Rolling Hernia

In this type there is herniation of stomach in to thorax through esophageal hiatus, while cardioesophageal junction is at its normal place (*note:* there is no upward displacement of cardioesophageal junction, which occurs in sliding hernia)

- There is a true hernial sac:- hence it is a true hernia.
- Herniation of stomach usually occurs at the left anterolateral of the esophageal hiatus.(see figure 26.15 E1)
- Fundus of stomach enters into the thorax through esophageal hiatus.
- Often this hernia acquires large size without causing any symptom.

Clinical Feature

In *large number of cases this hernia may be asymptomatic.* If the symptom do occur they are:

1. Because of large part of stomach is herniated in the thorax the effective capacity of stomach is reduced which causes:-
   (i) Early satiety
   (ii) Fullness after meals
   (iii) Post meal vomiting
2. When large, hernia presses on the distal esophagus causing dysphagia.
3. Incarceration of gastric mucosa.
4. Large hernia may lead to gastric volvulus.
5. There is no retrosternal burning or pain (which is present is sliding type of hiatus hernia.

Please see figure 26.14, 26.15 & 26.16 and understand different types of hiatus hernia

Diagnosis

Plain X-ray chest

Shows an air fluid level in thorax, due to presence of stomach in thorax. (PGME)

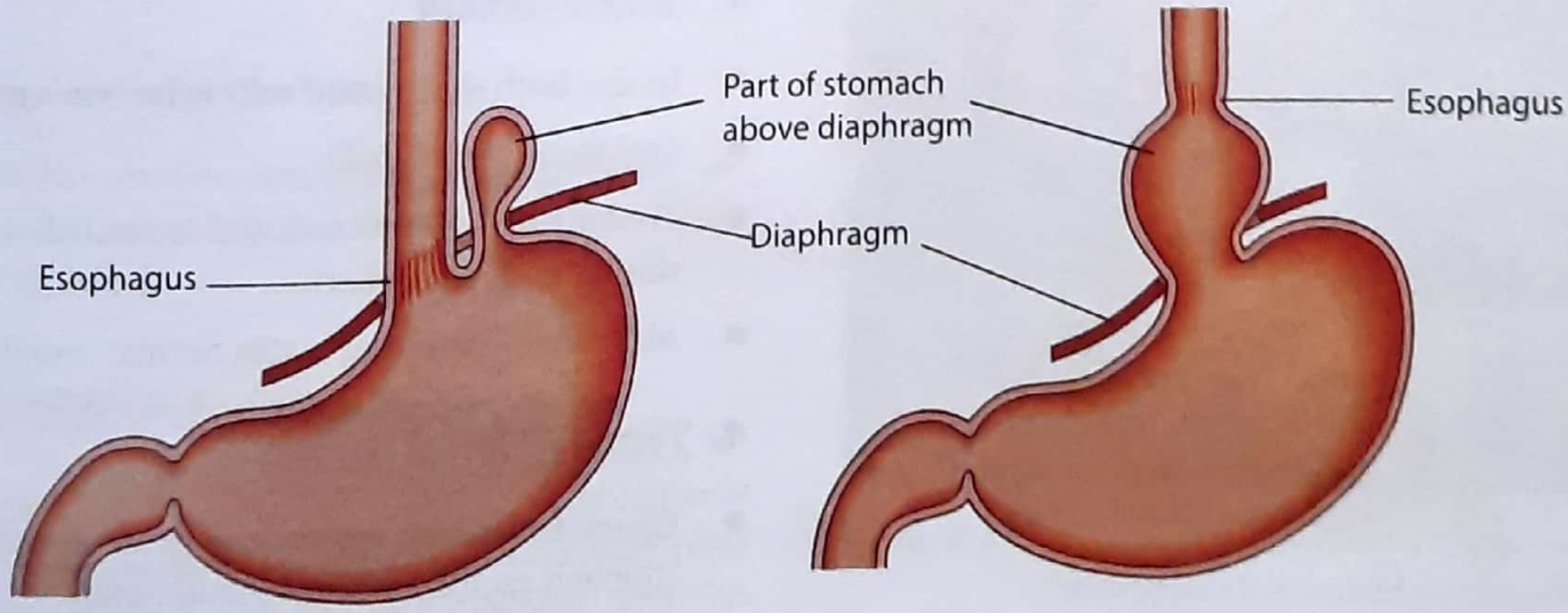

Figure 26.15 E1: Para-esophageal/Rolling Hernia

Figure 26.15 E2: Sliding/Axial Hernia

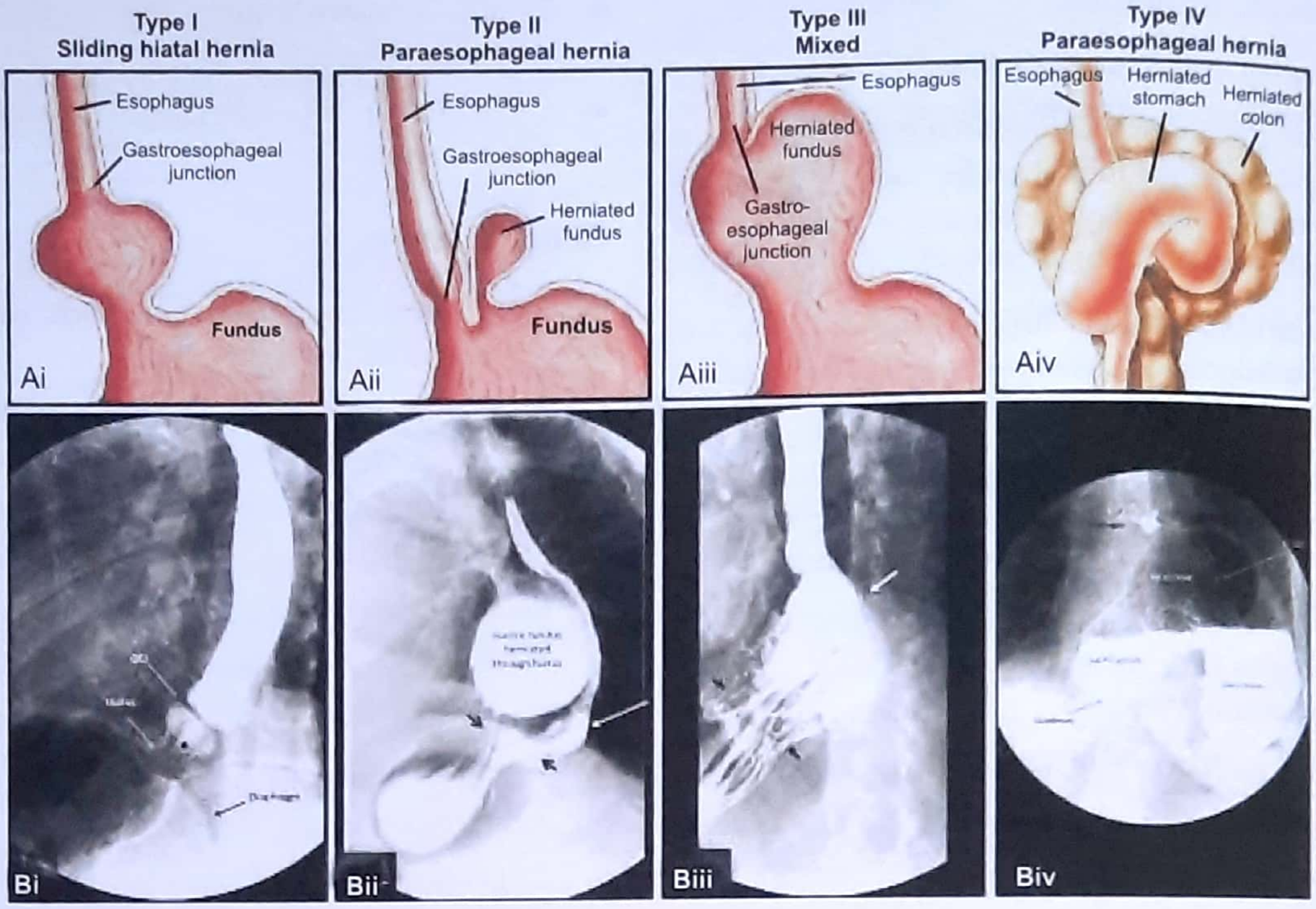

Figure 26.16: Various types of hiatus hernia.

Barium meal: Shows part of stomach in thorax.

Treatment

- There is no place of medical treatment for this condition.

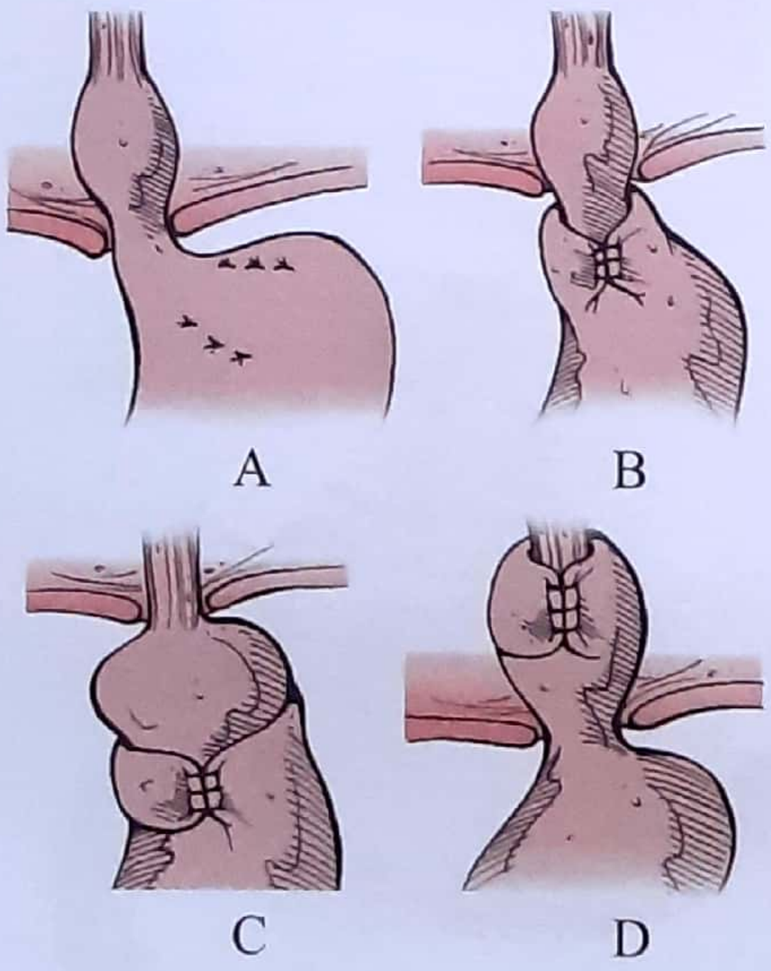

Figure 26.17: Types of hiatus hernia surgery (A). Sliding type (B). Rolling type (C). Mixed type

- All rolling type (para-esophageal) hernia should be surgically repaired as soon as diagnosis is established. The *principle of operation* are: (PGI JUNE 08)
  1. Reduction of sac
  2. Bring back the part of stomach hi abdominal cavity.
  3. Repair of large opening in the hiatus
  4. Anti reflux operation to reduce post operative reflux disease.

3. Mixed Hernia

- In this both sliding and rolling hernia is present.
- Symptoms are mixed.
- Treatment is also mixed, and is carried out for both sliding and rolling hernia.
- M/C complication of hiatus hernia - esophagitis.

4. Type IV Hiatal Hernia

- Characterised by presence of structures other than stomach such as colon or small bowel.
- It is least common subtype.

****

KEY BOX 26.6	
Comparison B/W Sliding and Rolling Hernia	
Sliding Hernia	**Rolling Hernia**
• Most common type (90%) • It is not a true hernia (because no sac is found) • Upward pull of cardio-esophageal Junction • Produces symptom like:-Reflux esophagitis, Epigastric (or retrostemal) pain Heartburn	• Only 10% • It is a true hernia, (true sac is found) • No upward pull of cardioesophageal Junction, (which remains at its original place), instead part of stomach Is rolled into the thorax • Presents as early satiety, post meal fullness, vomiting (NOTE: no retrostemal pain or burning is present in rolling hernia)
Treatment: Mainly medical with PPI ↑ if fails Fundoplication	**Treatment:** Only surgical by repair of hernial defect
Complication:w • Esophagitis • Barrett's esophagus • Adenocarcinoma	**Complication:** • Hemorrhage • Incarceration and • Strangulation • Dyspnea from compression of lung • Volvulus of stomich

NEOPLASM OF ESOPHAGUS

Benign tumour: Benign tumors of esophagus are rare. *The most common is Leiomyoma (MC symptom-dysphagia)* (PGI 88) and even large Leiomyoma produce mild symptoms. It appears like an ovoid intramural mass with smooth outline on CT. It is treated by enucleation.

Please see understand figure 26.18.

Malignant Tumor: Sarcoma of the esophagus is exceedingly rare, but leiomyosarcoma and rhabdomyosar-coma have been reported.

CARCINOMA OF ESOPHAGUS

Cancer of the esophagus is ninth most common cancer is the world. It is a disease of adulthood, with a **very poor survival rate**. Only 5-10% of those diagnose with this disease will survive for 5 year.

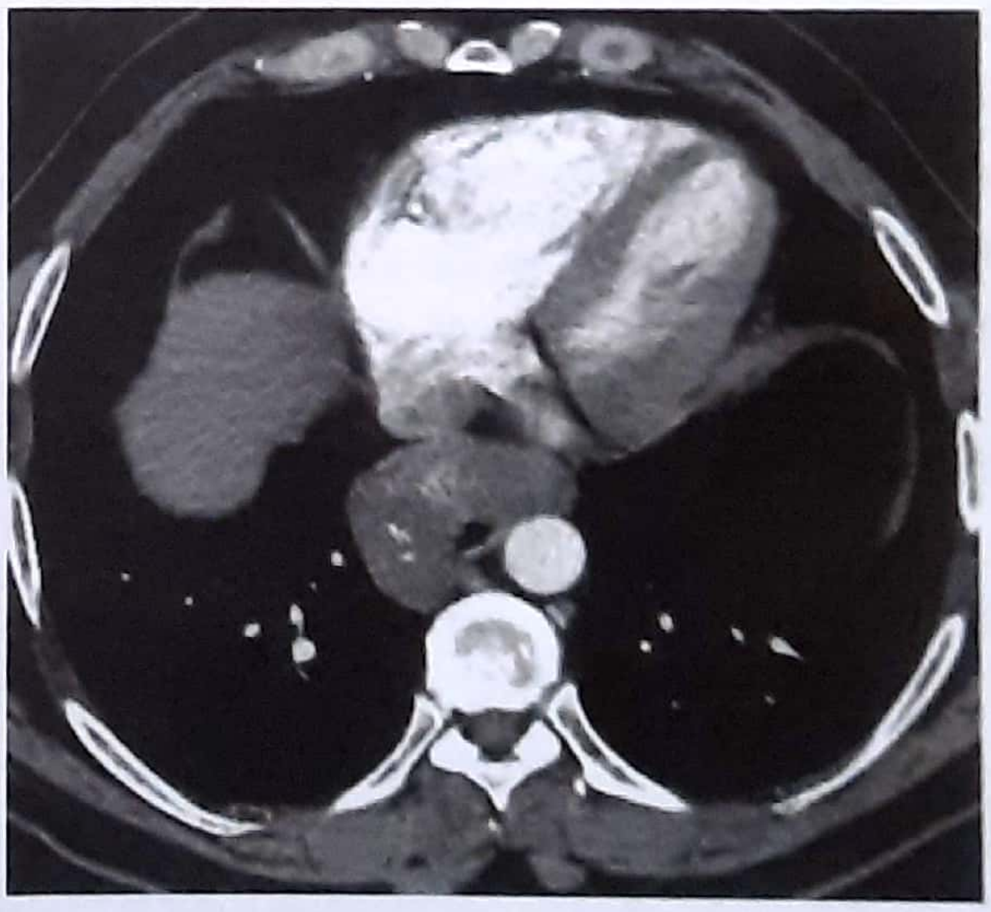

Figure 26.18: Computed tomography image of an B-cm leiomyoma that was causing dysphagia. The lesion was enucleated thoracoscopically, and the patient's dysphagia resolved.

Pathological Type *(many PGME)*:

Esophageal carcinoma is of two common histological type:

1. Squamous cell carcinoma
2. Adenocarcinoma

Now lets discuss them one by one

1. Squamous cell carcinoma

It is *most common (about 90% of all carcinoma of esophagus) type (middle 1/3rd of esophagus is mc location).* *(Many PGME)*

2. Adenocarcinoma

Its incidence is about 10%. Its incidence is rapidly increasing in western world. It is now the most common carcinoma is USA.

- 80-90% *of esophageal carcinoma in India are squamous cell carcinoma, while adenocarcinoma constitutes for only 10-20%. (imp. point)*
- *Friends- this is a very important question for* *PGME examination*. *If you get this question in your exams then Sq. cell carcinoma is the best option.*

Location

The esophagus is traditionally divided is upper, middle and lower thirds.

Distribution of Squamous cell carcinoma

- Upper 1/3 -10%
- Middle 1/3 - **60% (M/C site)** *(NEET, AIIMS 97, AI 01)*
- Lower 1/3 - 30%
- *Adenocarcinoma is mainly located in lower 1/3 of esophagus, near cardioesophageal junction.* *(UP 04)*

Three type of **tumour patterns** are observed: (Fig. 26.19)

1. Fungating growth
2. Ulcerating lesion
3. Diffused infiltrating type

Spread

- Poor prognosis of a esophageal cancer is due to it's ability of spread very rapidly, due to lack of serosal layer.
- This may be locoregional or systemic.

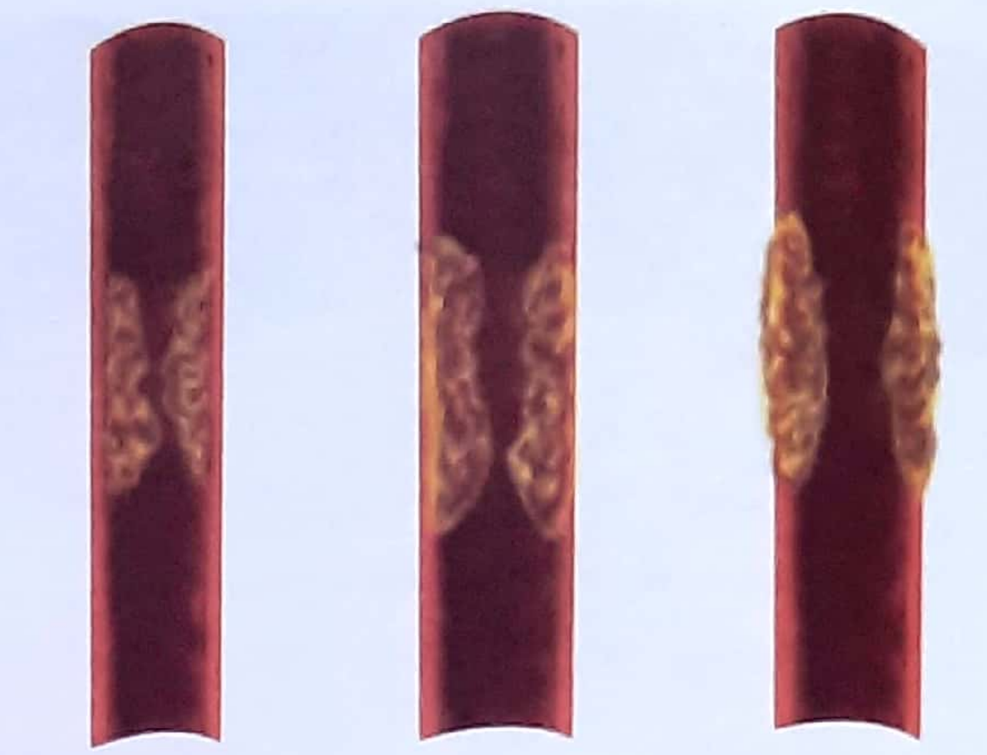

Figure 26.19: Types of Ca Esophagus

- Locoregional spread occurs through the wall of esophagus into adjacent structure.
- It should be remembered that musculature of esophagus is devoid of serosa, (which serves as a barrier for spread), hence the spread through the wall is early.
- Locoregional spread is discontinuous ie; distant regional lymph nodes may be invaded, even when local nodes are free of tumour. Local mediastinal structures especially the bronchi and trachea are often invaded giving rise to fistula.

Predisposing Factors for CA Esophagus

(PGI 95,99,2000,02)

For Squamous cell carcinoma

- Alcohol
- Cigarette
- Mucosal damage by physical agents
- Hot tea and coffee
- Lye ingestion
- Radiation
- Chronic achalasia;-
- Other ingested carcinogen
  - Nitrates
  - Smoked food
  - Fungal toxins
- Plummer Vinson syndrome
- Tylosis palmaris (congenital hyperkeratosis and pitting of palms and sole)

- Deficiency of vit A and vit C
- Deficiency of Molybdenum and Zinc.
- Celiac sprue.

For Adenocarcinoma

- *Chronic gastroesophageal reflux* (Barrett's esophagus) *(AI 98, AI 02, AIIMS 96, 2000)*

Clinical Feature

- The disease is commoner is male, with male to female ratio being 3:2.
- Patient between 50-60 years are affected most.
- Nearly all patients who present, are in advanced stage (stage III or IV). The usual presenting symptoms are:

1. Dysphagia

This is the usual presenting feature and is generally a sign of advanced disease. Dysphagia is progressive first to solid food and then to liquid as well *(PGI 03)*.

Grades of Dysphagia (May be asked in viva exam)

I	Eating normally
II	Needs Liquids with meals
III	Able to take Semi solids
IV	Liquids only
V	Unable to take liquids able to swallow saliva
VI	Unable to swallow saliva

2. **Loss of weight:** As a result of decreased food intake and cancer cachexia.
3. **Pain:** Pain is usually not a feature of malignancy, but in esophageal malignancy pain is a striking feature.
4. **Dyspeptic symptoms** may be present in early disease.
5. **Hoarseness:** Due to recurrent laryngeal nerve involvement, it is a sign of advanced case and incurable disease.
6. **Hiccup:** Due to phrenic nerve involvement.

Investigation

1. Barium Swallow

This will show

- Irregular mucosal filling defect (figure 26.20)

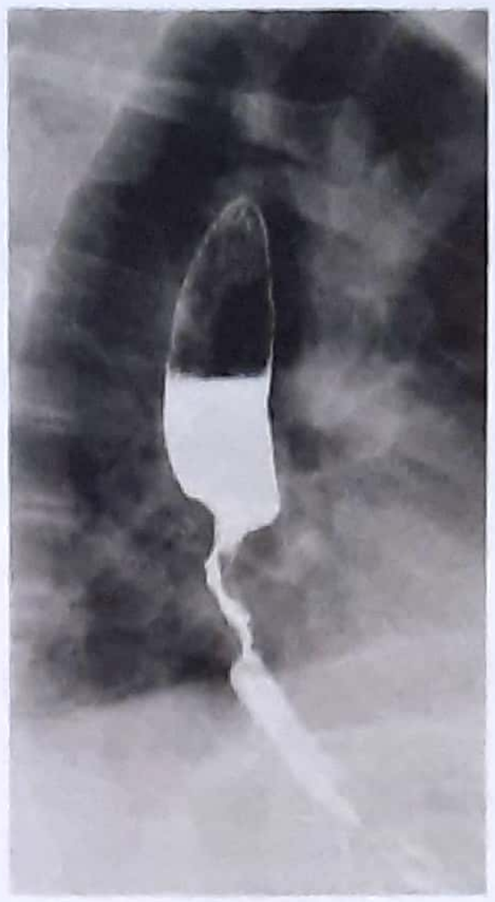

Figure 26.20: Barium esophagram demonstrating advanced carcinoma with abrupt, irregular narrowing in the distal esophagus with more proximal dilatation and air-fluid level.

- Distortion of esophageal lumen.
- Annular stricture
- Irregular rat tail filling defect of the distal esophagus. (Rat *tail deformity)* *(PGME)*
- Produces irregular stricture with "shouldered-margin".

NOTE: Barium swallow? Radiographic visualization of the esophagus during and after introduction (swallowing) of a contrast medium consisting of barium sulfate. Structural abnormalities of the esophagus and vessels, such as esophageal varices may be diagnosed by the use of this technique, which will produce filling defect. (Please read this topic in chapter 55)

2. Endoscopy and Biopsy

This is best and most diagnostic investigation for diagnosing Ca esophagus, *(Imp. point)*

3. Ultrasonography: For liver and other organ involvement

4. CT Scan: The purpose of CT scan is to assess the primary lesion and exclude metastatic disease from the lung and liver.

5. Endoscopic ultrasound: In this new imaging technique the transducer is applied directly to target organ, with the help of an endoscope. It is ***more accurate than***

CT in assessing the depth of tumour invasion and lymph node involvement **ie; (staging the tumor)** *[NEET, imp.point-may be future PGMEEQ]*

6. Laparoscopy: It is particularly helpful in assessing carcinoma of lower esophagus, transperitoneal spread and liver metastasis.

Laparoscopy is endoscopic visualization of abdominal cavity; after passing an endoscope (laparoscope) in the abdominal cavity; after making small hole on anterior abdominal wall

STAGES OF ESOPHAGEAL CARCINOMA

Primary tumor (T)

TX - Tumor connot be assessed

T0 - No evidence of tumor

Tis - High-grade dysplasia

T1a - Tumor invades the lamina propria or muscularis mucosa

T1b - Tumor invades the submucosa

T2 - Tumor invades into but beyond the muscularis propria

T3 - Tumor invades the adventitia

T4a - Tumor invades adjacent structures that are usually resectable (diaphragm, pleura, azygos vein, peritoneum, or pericardium)

T4b - Tumor invades structures that are usually unresectable (aorta, vertebral body, or trachea)

Regional Lymph nodes (N)

NX - Regional lymph nodes cannot be assessed

N0 - No regional lymph node metastasis

N1 - Metastasis in 1-2 regional lymph nodes

N2 - Metastasis in 3- 6 regional lymph nodes

N3 - Metastasis in ≥ 7 regional lymph nodes

Distant metastasis (M)

M0 - No distant metastasis

M1 - Distant metastasis

Histologic grade (G)

GX - Grade cannot be assessed

G1 - Well differentiated

G2 - Moderately differentiated

G3 - Poorly differentiated or undifferentiated

Location (L) - Applicable to squamous cell carcinoma only

LX - Location unknown

Upper - Cervical esophagus to lower border of azygos vein

Middle - Lower border of azygos vein to lower border of inferior pulmonary vein

Lower - Lower border of inferior pulmonary vein to stomach, including esophagogastric junction

Figure 26.21: Histopathology of various esophageal diseases

Treatment

The treatment option available as following.

1. Surgical resection
2. Radiotherapy
3. Chemotherapy
4. Laser treatment
5. Intubation

1. Surgical resection

(A) For carcinoma in upper 1/3 of esophagus

(i) If the growth is small and mobile

Total esophagectomy followed by gastric pull up and pharyngogastric anastomosis in the neck.

(ii) If the growth is large and metastatic

Radiotherapy should be given. The dose of radiotherapy is 5000-6000 cGy. Note most of the upper esophageal cancer are squamous cell carcinoma

NOTE: **Squamous cell carcinoma is highly radioSensitive tumour.** {It is a very frequently asked PGME question}

B. For carcinoma of middle 1/3 of esophagus

Carcinoma of middle 1/3 of esophagus may not be diagnosed until late. When it is diagnosed, it is already adherent to aorta, azygous vein or left main bronchus. In most of the cases curative resection is not possible and treatment is by *radiotherapy + chemotherapy.*

C. Carcinoma of lower 1/3 of esophagus

Esophagectomy

1. **Thoraco-abdominal approach**
2. Two stages **Ivor-Lewis (or Lewis-Tanner) approach;** where in initial Laparotomy is done for construction of a gastric tube followed by right thoracotomy to excise tumor and esophagogastric anastomosis is done. It is done for lower 1/3 carcinoma.
3. Three stage **McKeown approach:** in this a third incision is given in neck to complete cervical anastomosis. *(PGME, AIIMS)*

- Radical esophagogastrectomy.
- *Palliative bypass*
  - Fashioning reverse gastric tube.
  - Colonic bypass
  - Feeding jejunostomy

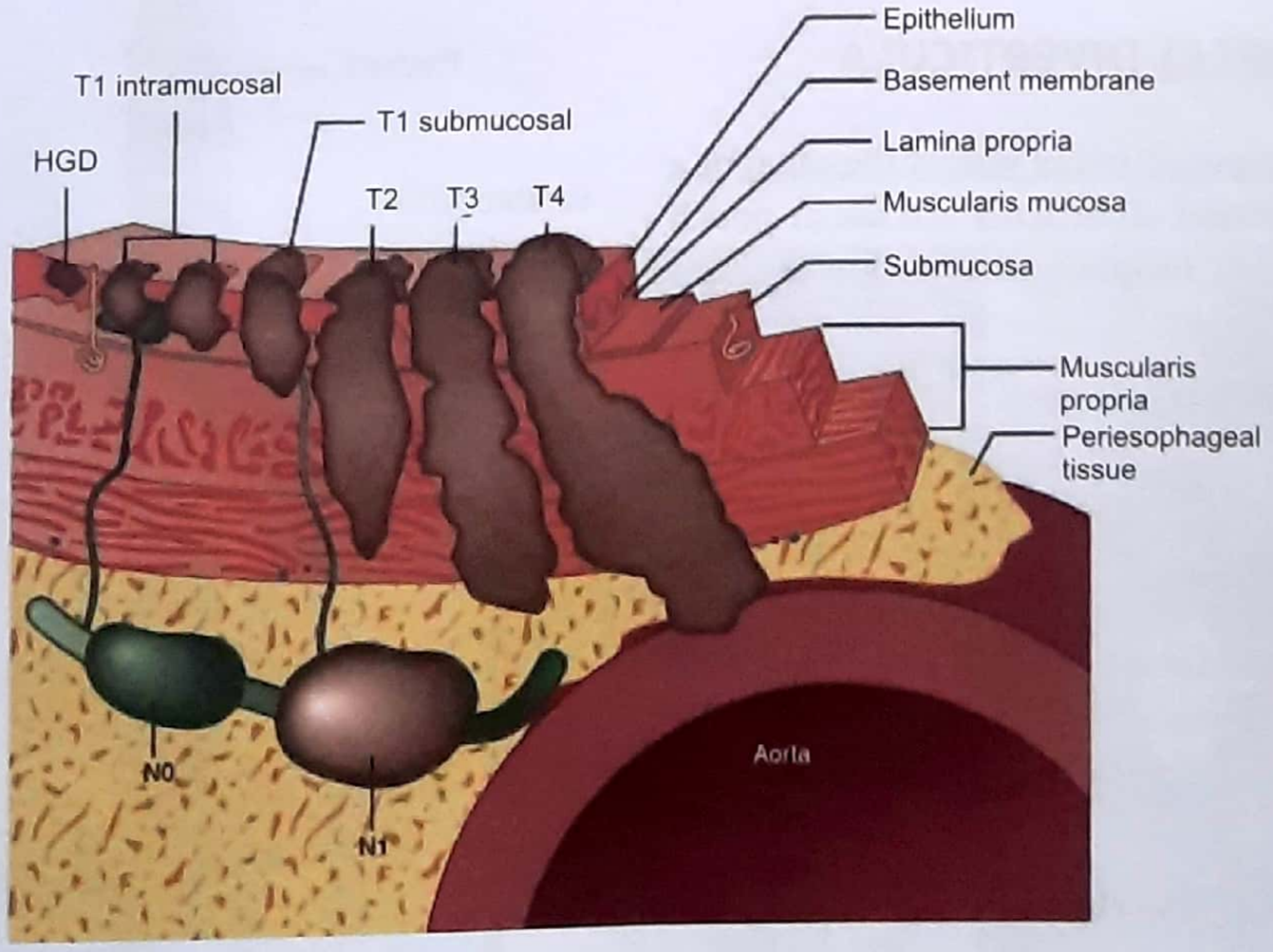

Figure 26.22: Tumor classification for esophageal carcinoma as defined by depth of invasion. HGD, High-gradia dysplasia

NOTE: Feeding gastrostomy (ie; making a hole in stomach and placing a feeding tube in it) should never tried.

NOTE: In carcinoma of esophagus, the stomach is used, in preference to the small bowel (jejunum) and colon to replace the resected esophagus. *(AI 96, AIIMS 97, PGI 95)*

2. Radiotherapy

It has been tried for squamous cell carcinoma of esophagus. The dose is 5000-6000 cGy.

3. Chemotherapy (Cisplatin based, with 5FU)

With advent of regimens containing **cis-Platin** *(NEET, AI96, AIIMS 97)*, chemotherapy for esophageal carcinoma has improved considerably. Chemotherapy never cures the disease, but it can produce shrinkage of disease in up to 60% cases.

The chemotherapeutic agents used are cisplatin, 5-FU, vinblastine, paclitaxel & vinorelbine.

4. Laser

Endoscopic laser therapy relieves obstruction and bleeding.

5. Endoscopic Therapy-(Endoscopic Mucosal Resection)

This is favoured for Stage 1 disease invading Lamina propria (T1 mucosal) or Submucosa (T1 Submucosal) without regional or distant metastasis.

****

ESOPHAGEAL DIVERTICULA

Diverticula is a sac or pouch in the wall of the canal or a tubular organ. Esophageal. diverticula is a sac or pouch in the wall of esophagus. **Esophageal diverticula can be divided as:**

1. Pulsion (90%) (M/C type)
2. Traction (10%)

1. Pulsion diverticula

- They are not true diverticula and develop due to pressure (chronic pressure against an obstruction)

Example

- *Zenker's diverticula* (pharyngeal pouch):- presents in upper part of esophagus.
- *Epiphrenic diverticula:-* in lower part of esophagus.

2. Traction diverticula

- They are **true diverticula** *(NEET)* and develop due to *traction on the esophageal wall from out side.*
- Traction may be as a consequence of fibrosis in a tracheobronchial lymph node due to tuberculosis, atypical mycobacteria or histoplasmosis resulting in out pouching of small conical pouching of esophageal wall.

Example

- ***Para-bronchial diverticula*** *(NEET)* (In middle part of esophagus).

Now lets discuss them one by one

1. Zenker's diverticulum (Pharyngeal pouch)

- As the name; pharyngeal pouch it self suggest, it is an *out pouching of pharynx mucosa.*
- Because it does not arise from the wall of esophagus; it is not a true esophageal diverticula

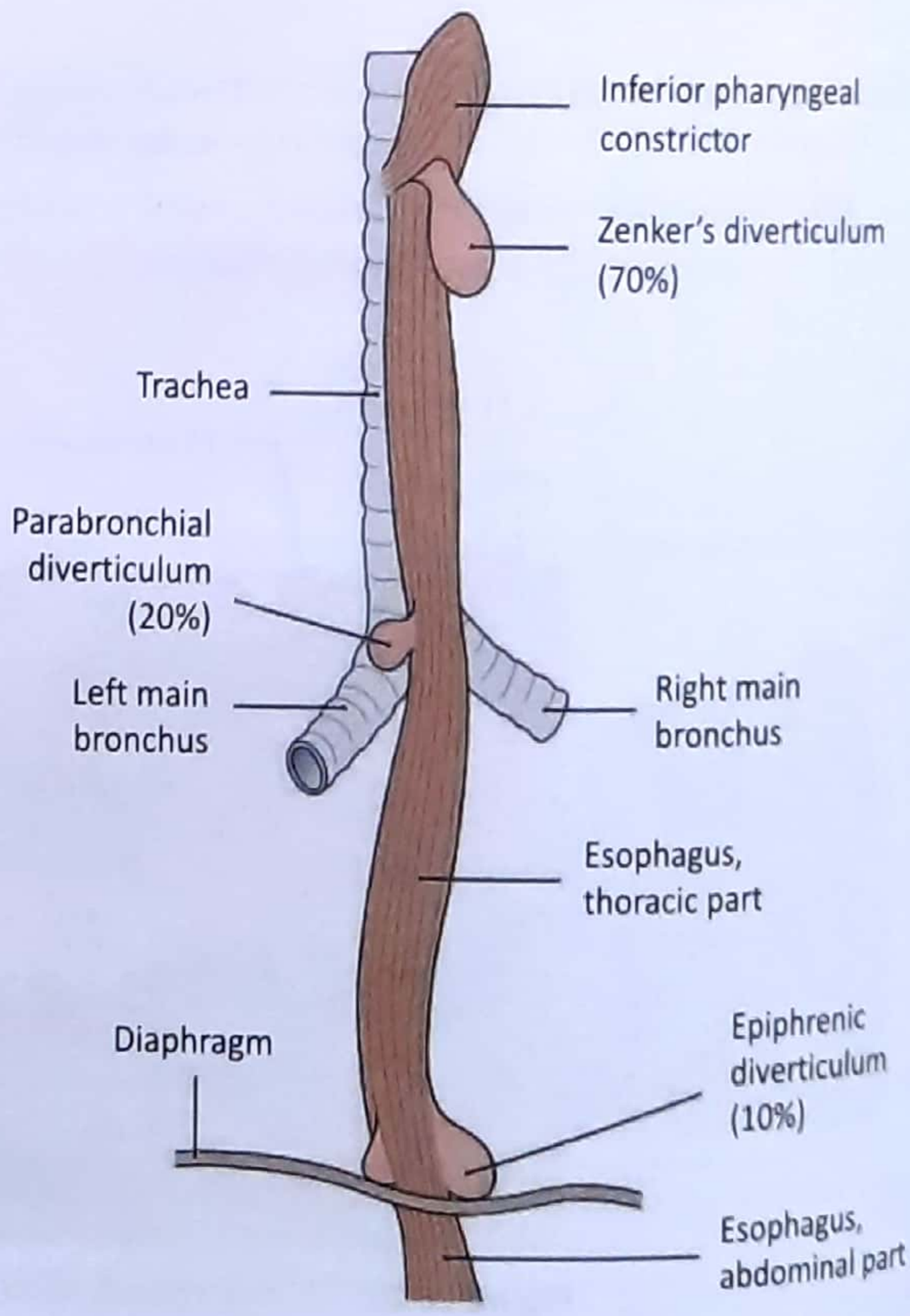

Figure 26.23: Esophageal diverticula

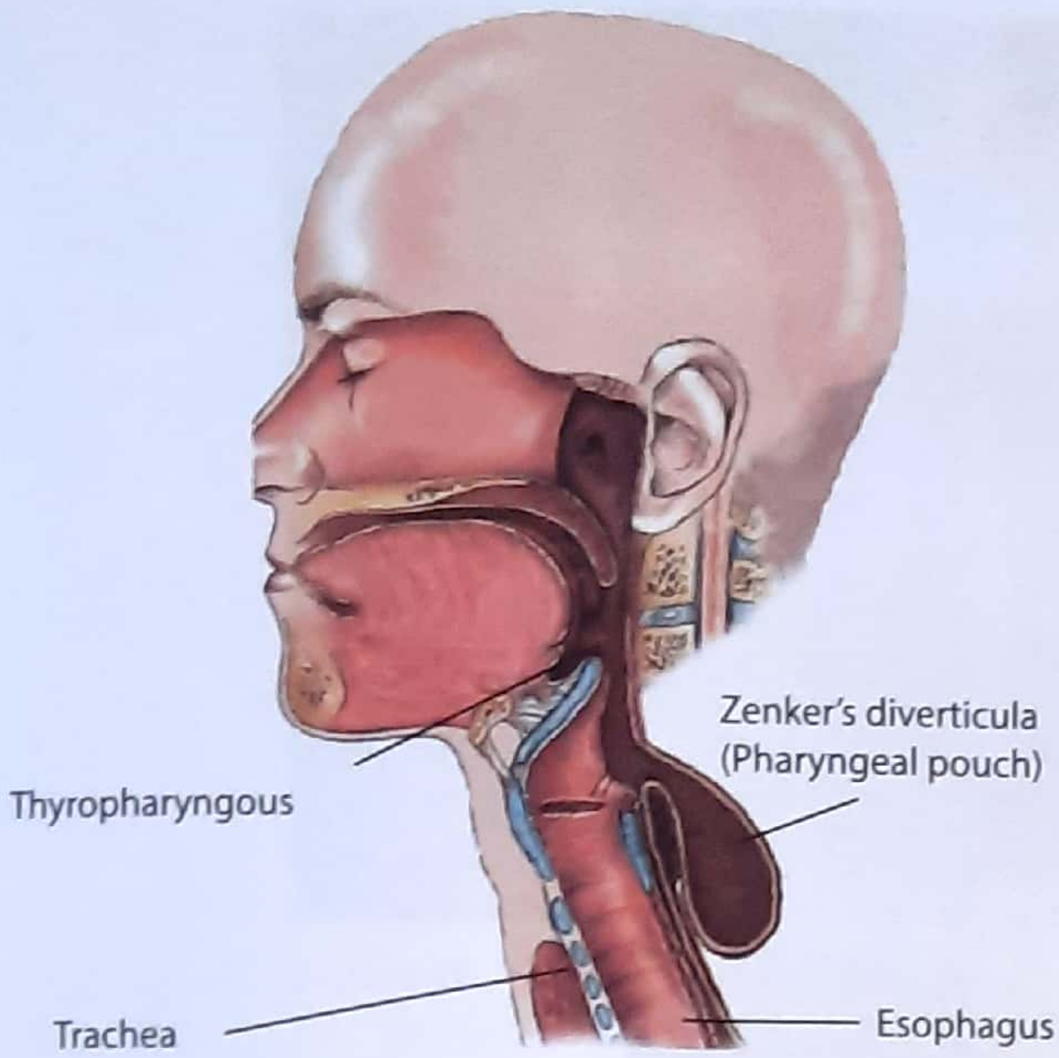

Figure 26.24: Zenker's diverticula

- In fact it is the most common diverticulum affecting the region of esophagus (Note: that; in region of esophagus but not from esophagus itself).
- The junction of **Cricopharyngeus** (NEET) and thyropharyngeus is weak at the posterior part which is called as: *Killian's dehiscence*. See figure 26.24, 26.25. (AI 09)

- Normally cricopharyngeal sphincter (upper esophageal sphincter) is closed to prevent
  1. Regurgitation of esophageal content into respiratory tract (trachea).
  2. Entry of air into esophagus.

When there is incoordination, the sphincter fails to relax which increases pressure above the cricopharyngeal sphincter and a pharyngeal diverticula develops through the *Killian's dehiscence;* known as Zenker's diverticula.

- Diagnosis is made on Barium Swallow. (Fig. 26.25)

Clinical feature

- Middle aged men (40-60) are usually affected.
- **Dysphagia is most** common symptom (NEET). Others are reguritation, neck swelling, halitosis, sour metallic taste.
- Complication due to regurgitation and aspiration of food leads to, ***recurrent respiratory tract infection,*** *pneumothorax,* ***lung abscess may occur.*** (NEET, AI 95)
- Investigation of choice: **Barium swallow** (NEET).

Treatment (NEET, AI 95)

Crico-pharyngeal myotomy with or without diverticulectomy is most effective treatment for this condition.

Modern treatment is by endoscopic linear cutting staple gun. (Diverticulo-esophagostomy with Linear Cutting Staple gun — **Dohlman Procedure** (NEET))

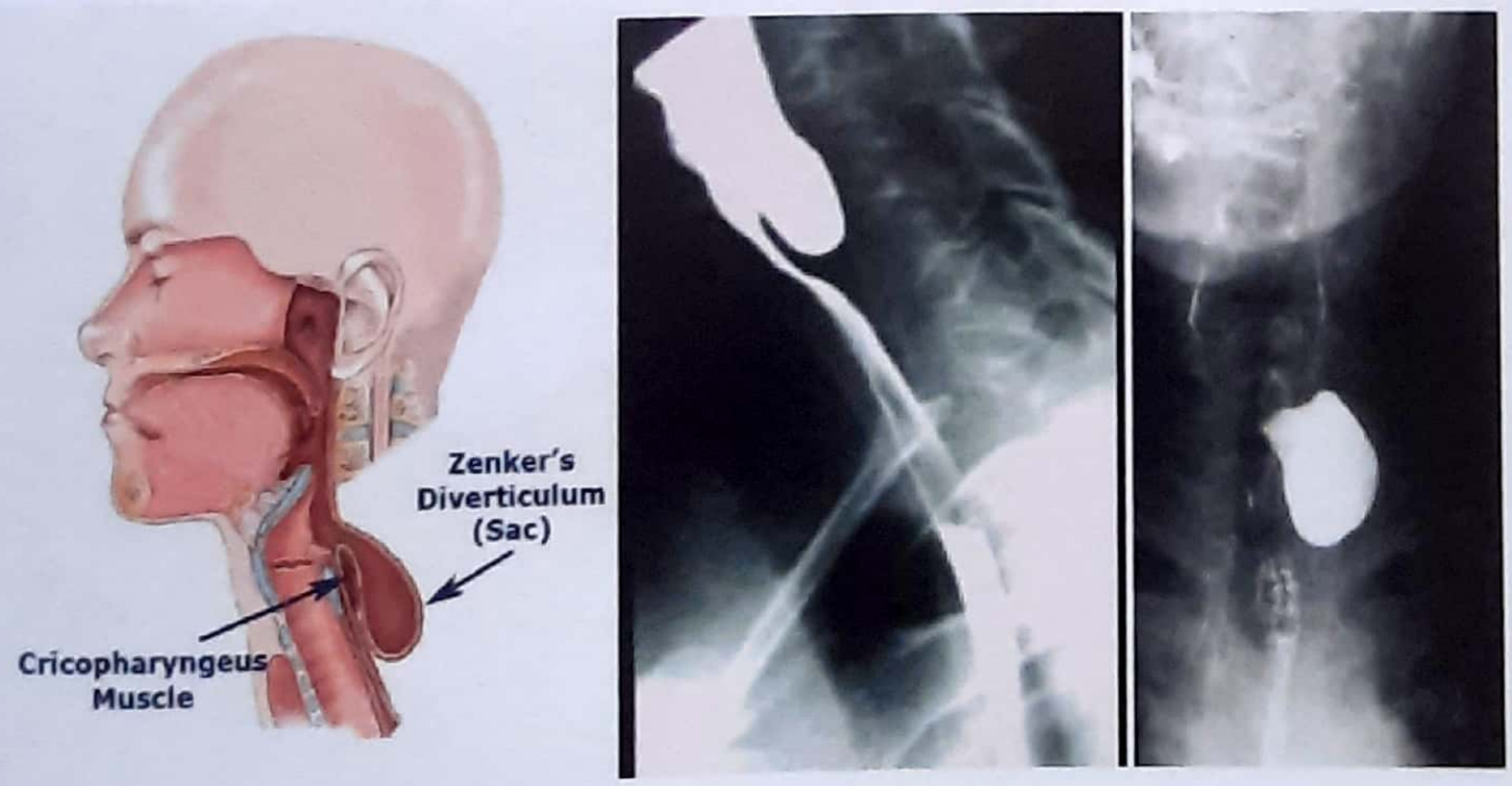

Figure 26.25: Lateral and AP view of Barium Swallow: Zenker's diverticulum

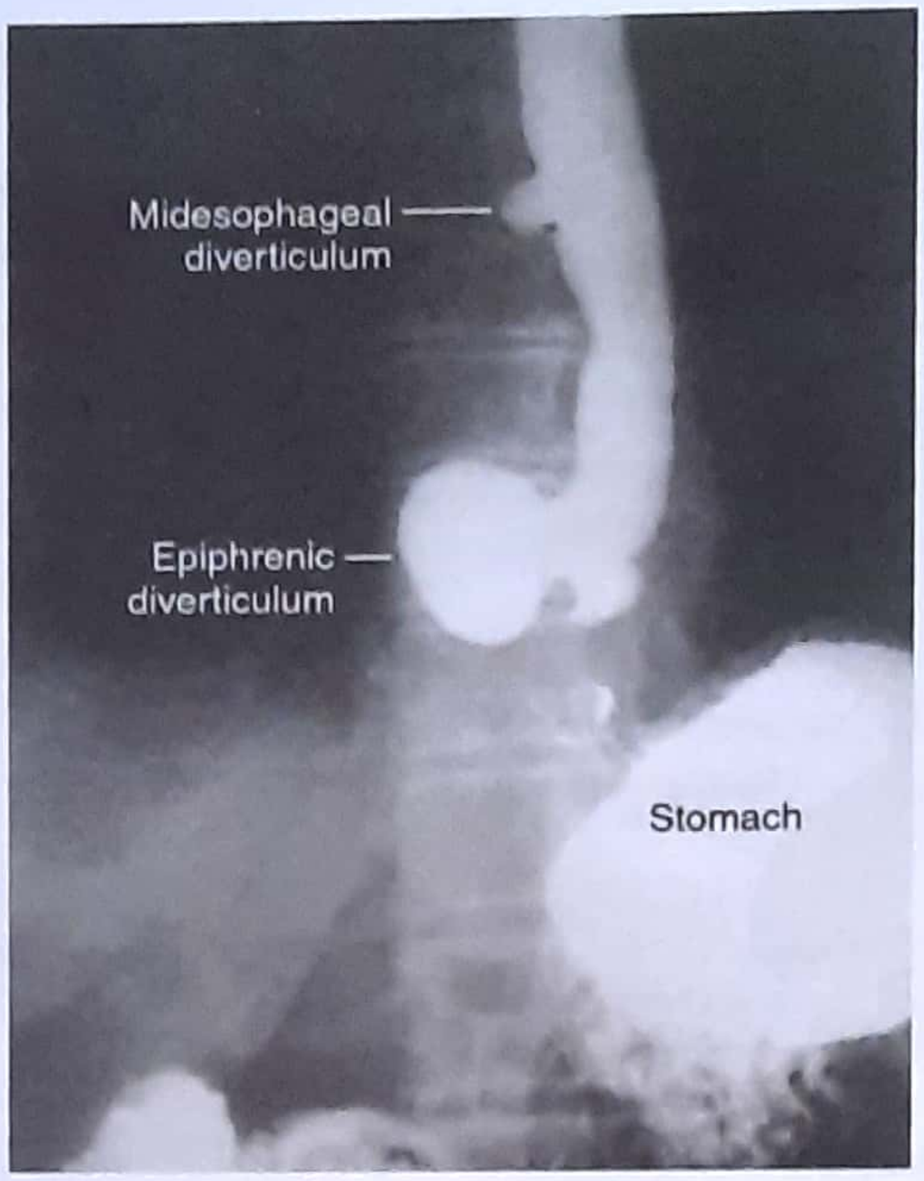

Figure 26.26: Barium swallow showing mid and distal esophageal diverticula.

2. Epiphrenic diverticulum

It occurs mostly in distal esophagus (lower third). It is protrusion of mucosa or submucosa through esophageal musculature. It is due to esophageal motility disturbance and may be associated with diffused spasm, achalasia or stricture.

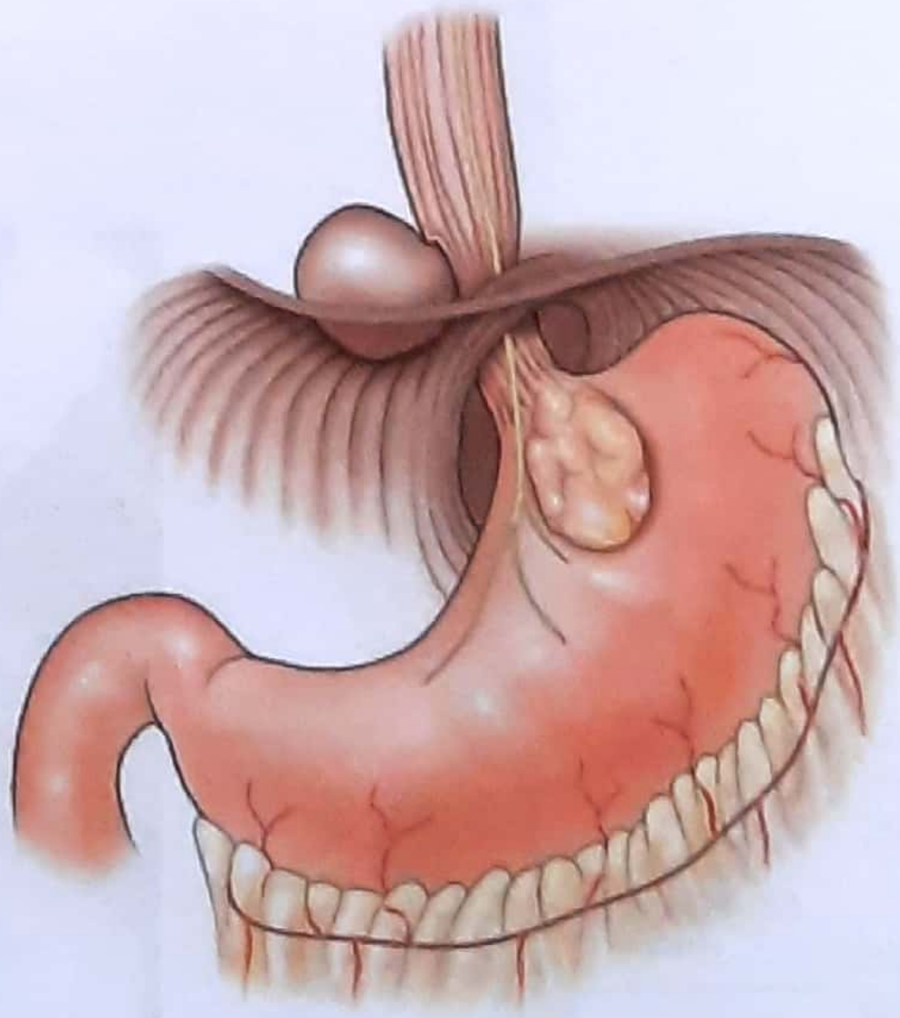

Figure 26.27: Epiphrenic diverticulum

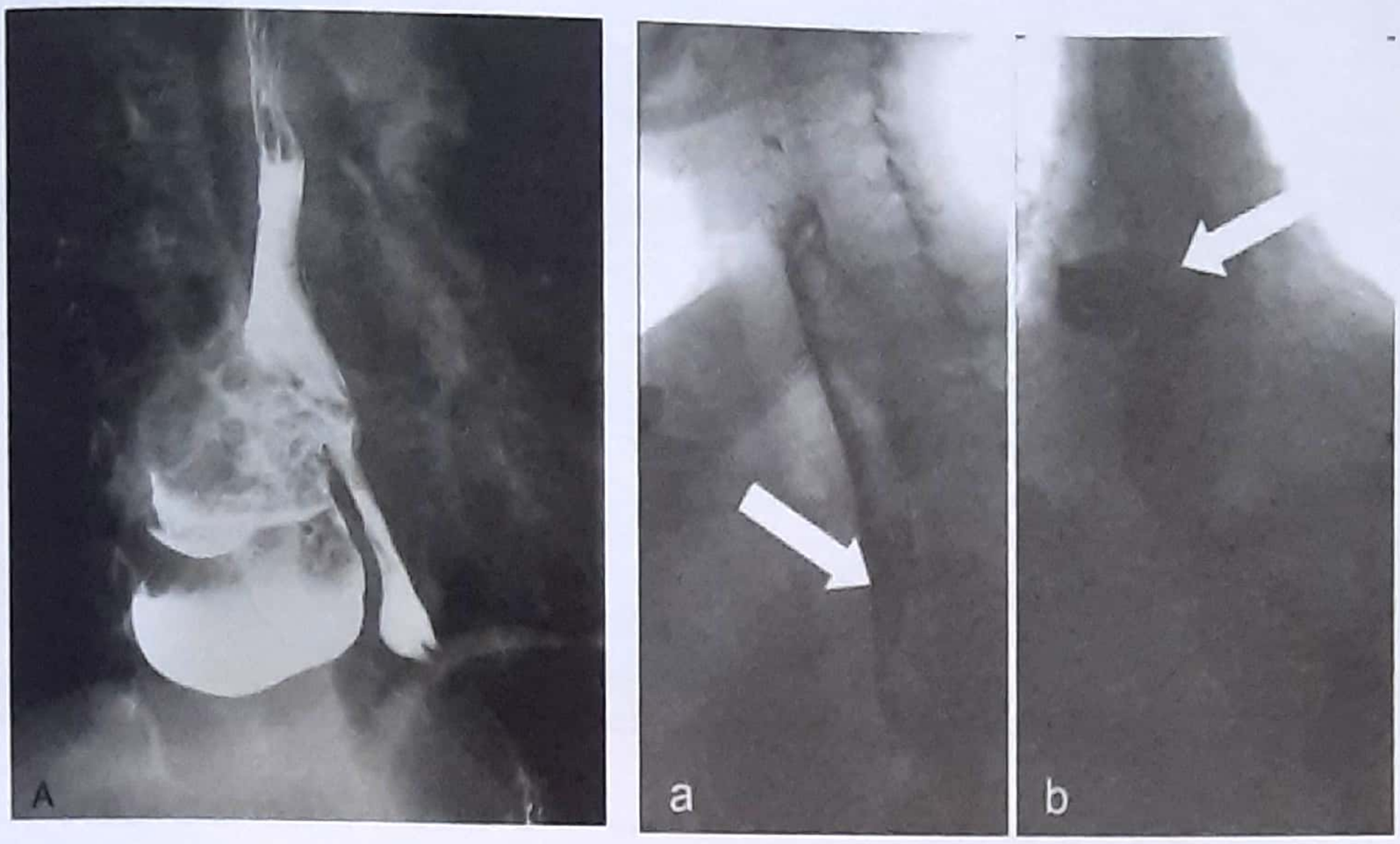

Figure 26.28: Parabronchial (Mid esophageal) diverticulum

3. Parabronchial (Mid esophageal) diverticulum

It is least common type of all the three diverticula. It typically occurs near the bifurcation of the trachea, yet it can occur any where particularly in the middle third of esophagus. This is always associated with granulomatous infection of mediastinal lymph node. Tuberculosis is most commonly associated with this type of diverticula. (figure 26.28)

****

KEY BOX 26.7	
Esophageal diverticiila can be divided as	
Pulsion (90%) M/C type	**Traction (10%)**
• Develop due to pressure (chronic pressure against *m* obstruction) **Example:** (i) Zenker's diverticala (pharyngeal pouch; present in upper part of esophagus. (ii) Epiphrenic diverticula (Lower part of esophagus)	Develop due to traction on the esophageal wall from out side • Traction may be as a consequence of fibrosis in a tracheo bronchial lymph node due to tuberculosis, Atypical mycobacteria or histoplasmosis. Fibrotic healing of lymph node exerts traction on esophageal wall causing out pouching that is usually small and has conical shape Example: Para bronchial diverticula (In middle part of esophagus)

NOTES :

Sample Questions for Prof Examination

Write short notes on:

1. Tracheoesophageal fistula
2. Discuss causes of dysphagia. Give symptoms/sign and treateeat of achalasia
3. Discuss congenital esophageal atresia.
4. Management of a patient with hernatemesis.
5. Write short notes on achalasia cardia
6. Tracheoesophageal fistula (TOP)
7. Discuss GORD.

27 The Diaphragm

Contents

- Diaphragmatic Hernia
  - Hiatus Hernia
  - Para sternal hernia
  - Bochdalek hernia
  - Traumatic diaphragmatic hernia
- Eventration of diaphragm

The diaphragm is a large muscle separating the thoracic and abdominal cavities and serves an important function in normal respiration.

In diaphragm the muscle fibres form, the periphery and arise from the circumference of the thoracic outlet and are inserted into a central tendon.

The normal diaphragm develops from fusion of several component. Septum transversum play a major role in it's formation. This septum is formed in neck, derives nerve supply locally and migrates caudally along with its nerve supply, hence the nerve supply of diaphragm is C_{3-5} *(PGME)*

Attachment of diaphragm

- Anteriorly : Lower sternum
- Laterally : Costal margin
- Posterior : First lumbar vertebrae

****

DIAPHRAGMATIC HERNIA

It is due to herniation of abdominal viscera through a congenital or acquired gap in the diaphragm. 95% of all diaphragmatic hernia are the esophageal hiatus hernia. Figure 27.1.

1. Hiatus Hernia

This is **most common** (95%) of all diaphragmatic hernia. It has been discussed in previous chapter.

2. Hernia through the foramen of Morgagni (Parasternal hernia)

- This is due to congenital defect in fusion of sternal (ventral) and costal (lateral) part of diaphragm
- Through present since birth, majority of defects are detected in adulthood, and 90% of them are on *right anterior side.* *(AI 07, AIIMS NOV 06, AIIMS MAY 10).*
- Omentum or transverse colon are two most common structure that usually herniate through it. (figure 27.2)

Treatment

When a definitive diagnosis is established repair of the hernial defect is advocated, even if there are minimal symptoms.

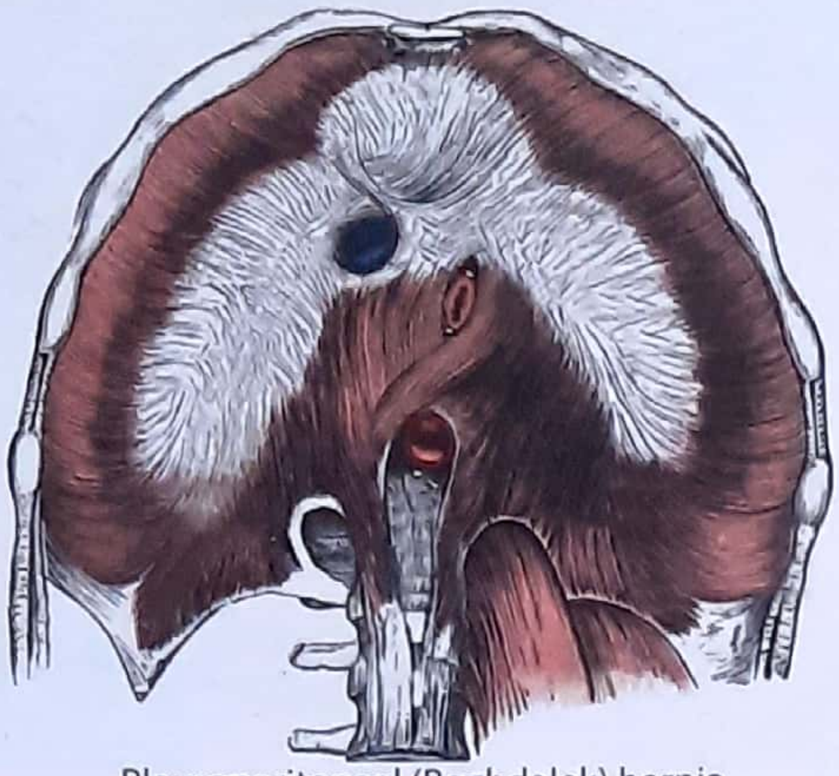

Figure 27.1: Sites of congenital hernia

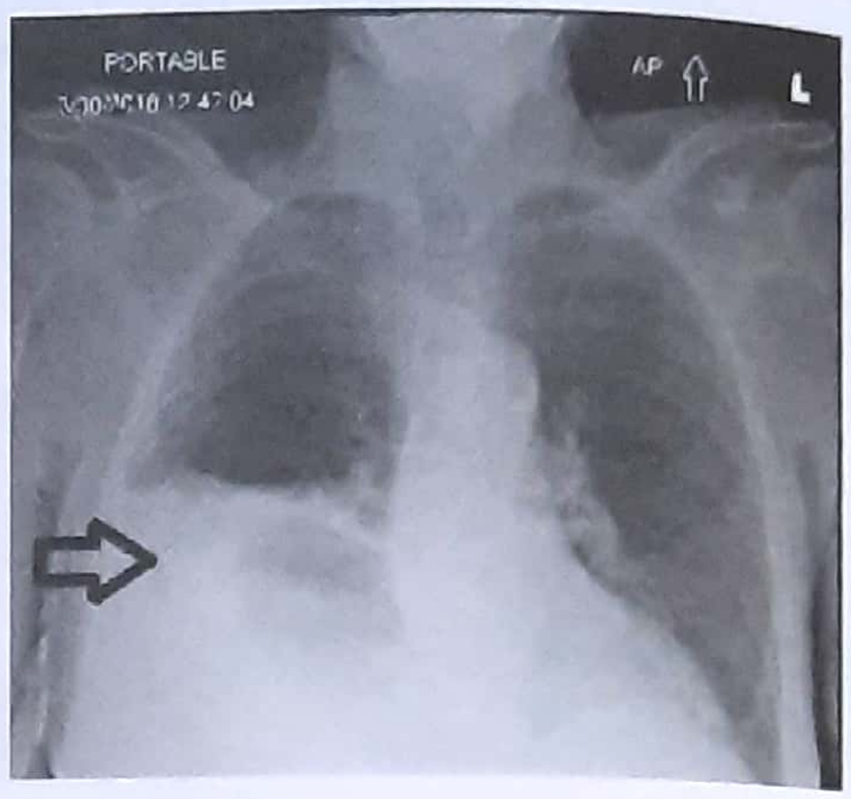

Figure 27.2: Morgagni hernia

Operation

Abdomen is opened by upper mid line incision (or right para median incision) → viscera is reduced (ie; brought back in abdominal cavity) → Peritoneal sac in identified → and the peritoneal sac is excised → closure of the defect-by approximating to diaphragmatic edges, with non-absorbable interrupted suture (proline) is done.

- If the defect in too large then -> closure is done with a synthetic mesh.

Summary of Treatment

Reduction of herniated organs from thorax into abdomen*

(1) If the defect is small

Closure of defect using non absorbable interrupted suture (Proline)

(2) If the defect is large

Closure of defect using prosthetic material (mesh)

Reduction = Process of bringing back the herniated organ to it's normal position.

3. Hernia through the foramen of Bochdalek (Pleuro-peritoneal hernia) (NEET)

- This may result due to failure of fusion, between the dorsal and ventrolateral parts of developing diaphragm.
- It is the **most common type of all congenital hernia** (NEET) (figure 27.3)
- **More common on left side** (NEET) Posterolateral [Left to Right ratio = 8 : l, also see key box 27.1]
- Because major part of the thorax is filled with herniated abdominal organs (stomach, small intestine, transverse colon) there occurs hypoplasia of respiratory system ie; decrease in size and number of bronchi and alveoli, resulting in respiratory distress and abnormal development of pulmonary vasculature (leading to **pulmonary hypolasia and pulmonary hypotension**). (AIIMS NOV 09) Which is most imp. prognostic factor. Please see figure 27.4.

Figure 27.3: Bochdalek hernia

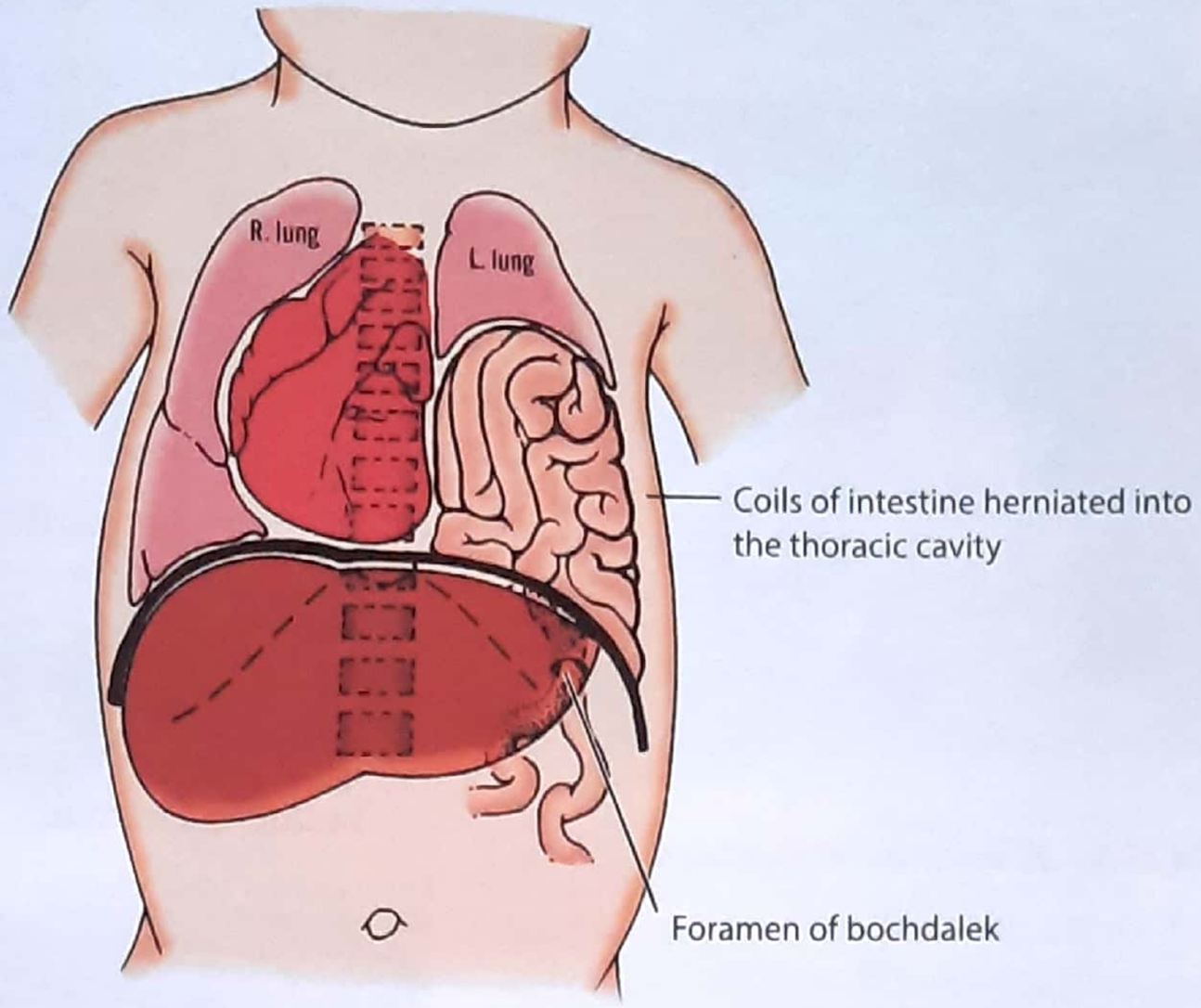

Figure 27.4: Hernia through the foramen of Bochdalek (Pleuro-peritoneal hernia)

Clinical feature

Triad

- Cyanosis
- Dyspnea
- Cardia dextroposition

Physical examination reveals scaphoid abdomen, *decreased breath sound and presence of bowel sound in the chest.*

Diagnosis

Plain X-ray chest: An AP view shows *mediastinal shift and air filled intestinal loops in chest,* (MANY PGME)

Treatment

- Only surgical treatment will be beneficial. Laparotomy (Opening of the abdominal cavity) is done and hernial defect is identified and reduced. Abdominal contents are brought back in abdominal cavity and hernial defect is repaired.
- There is high mortality even after satisfactory repair, because of existing congenital pulmonary hypoplasia.

4. Traumatic Hernia

- Traumatic diaphragmatic hernia can occur as a result of penetrating injury (stab or gun shot injury) or blunt injury to upper abdomen and thorax.

KEY BOX 27.1	
Common on left side (B. B. C. D. E)	**Common on right (ICU) side**
• Bochdalek hernia • Bag of worm (Varicocele) • Cleft lip • Duplication of ureter • Ectopic kidney	• Indirect inguinal hernia • Cervical rib • Undescended testis

****

EVENTRATION OF DIAPHRAGM

This is a condition in which muscle mass in the **left half of diaphragm is absent,** which is often replaced by fibrous tissue. It may be due to:-

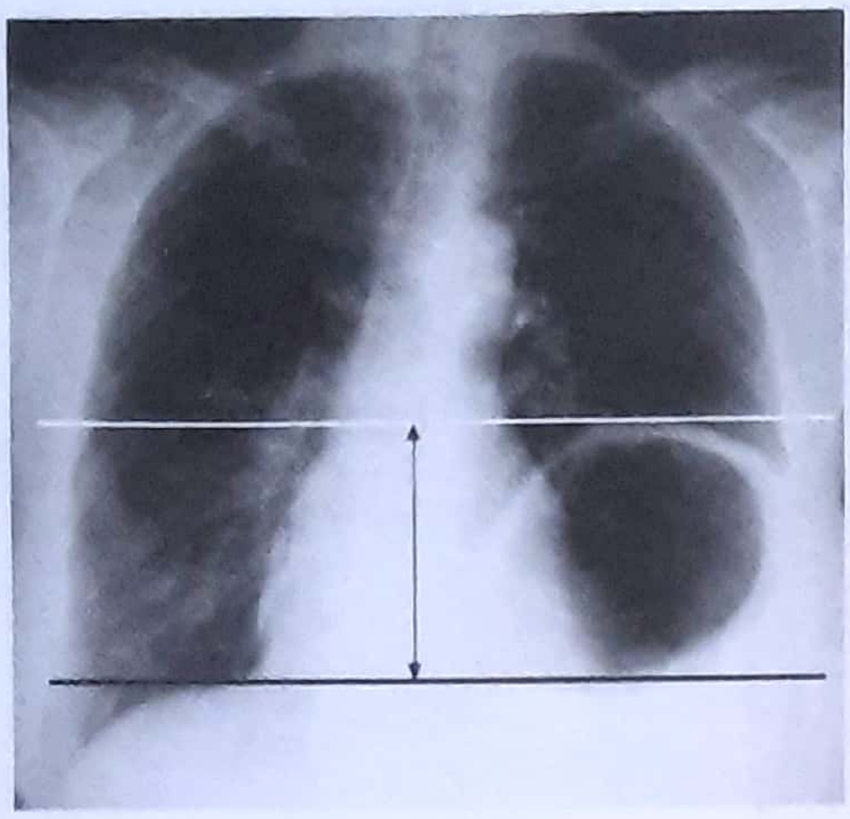

Figure 27.5: Eventration of diaphragm

- Anomalous development of diaphragm
- Birth injury to phrenic nerve

- There is usually no symptoms, but occasionally respiratory difficulties may be complained of.
- Often it is classified as hernia; but it is not a true hernia because gut lies below the level of the diaphragm
- X-ray will show abnormally high lying left side diaphragm which is immobile with respiration.
- ***Treatment:*** surgical correction by placement of diaphragm to its normal position.

Note :

(1) Most common impacted foreign body in esophagus in children in coin.

(2) Globus pharyngeus is feeling of lump in throat but no difficulty in swallowing.

****

Sample Questions for Prof Examination

1. Hernia through the foramen of morgagni.
2. Diaphragmatic hernia.
3. Bochdalek hernia (Pleuro-peritoneal hernia).

28 The Stomach and Duodenum

Contents

- Surgical anatomy
- Physiology
- Investigation
- Hypertrophic pyloric stenosis of infancy
- Duodenal atresia and stenosis
- Acute erosive gastropathy
- Chronic gastritis
- Menetrier's disease (Hypertrophic gastritis)
- Eosinophilic gastritis
- Peptic ulcer
  - Gastric ulcer
  - Duodenal ulcer
- Carcinoma of stomach
- Other Gastric tumours
  - Gastric stromal tumours
  - Gastric carcinoid
  - Gastric lymphoma
- Duodenal tumour
- Acute gastric dilatation
- Volvulus of stomach
- Dieulafoy's disease
- Gastric diverticula
- Hypertrophic pyloric stenosis of adult
- Bariatric surgery

Stomach is a muscular bag, forming the *widest and most distensible part of the digestive tract.* It is connected above to the lower end of the esophagus, and below to the duodenum. It acts as a reservoir of food and helps in digestion of protein and fat.

The shape of the stomach depends upon the degree of its distension. When empty the stomach is some what J shaped (vertical); when partially distended it becomes piriform in shape. In obese person it is more horizontal **(steer horn stomach).**

****

SURGICAL ANATOMY OF STOMACH

Stomach is subdivided into cardia, fundus, body, pyloric antrum and pyloric canal (Figure 28.1).

Interior of Stomach

The stomach wall consist of (from outer to inner side)

- Serosa
- Muscular coat } Longitudinal, Circular layer
- Submucous coat
- Mucous coat

The mucus membrane of the stomach is thick and when the stomach is empty; is thrown into numerous **longitudinal folds called 'rugae'** (fig. 28.4) However, when the stomach is distended they are not seen. *The mucous membrane is covered by a very thick mucus, which is protective in nature* (AI 97).

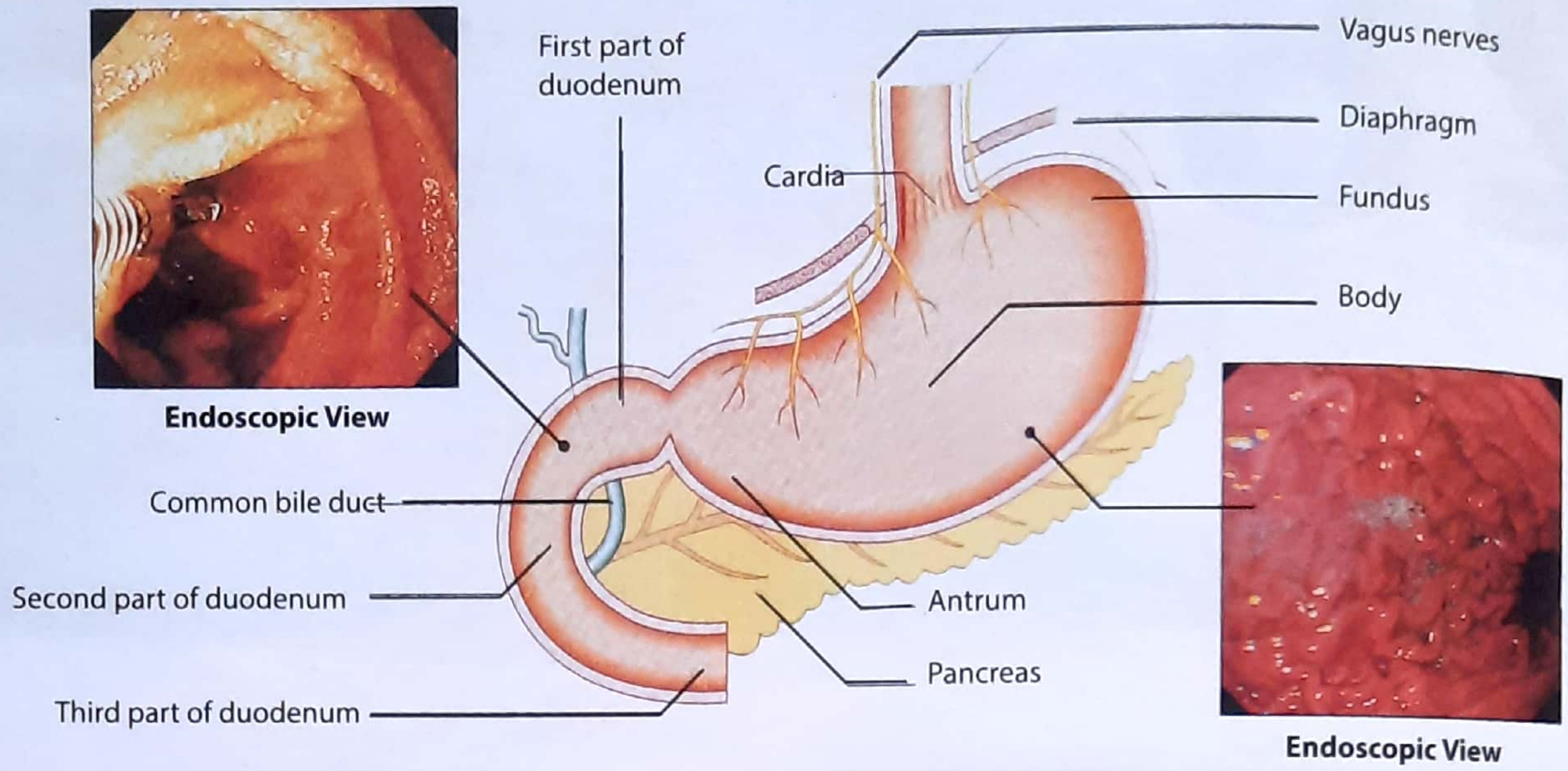

Figure 28.1: Parts of stomach with close relations with endoscopic view

Blood Supply

The stomach is supplied by

1. *The left gastric artery-a branch of celiac trunk.* (PGME).
2. *The right gastric artery, a branch of common hepatic artery.* (MANY PGME)
3. *The right gastroepiploic* artery a branch of gastro duodenal artery.
4. *Left gastroepiploc* artery, branch of the splenic artery.
5. *Short gastric arteries*, which are the branches of the splenic artery.

The **veins** of the stomach drain into portal, superior mesenteric and splenic veins. (figure 28.2)

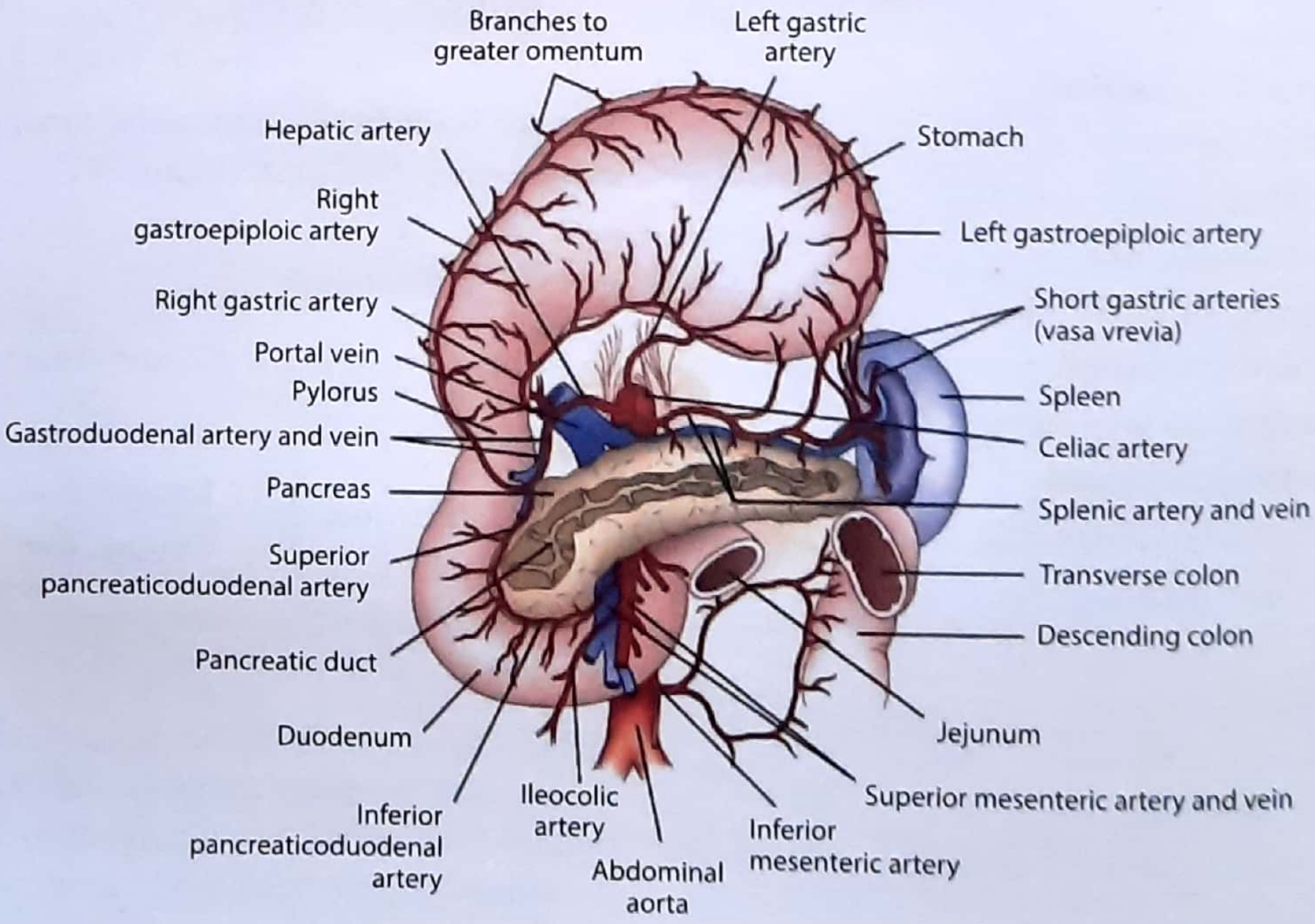

Figure 28.2: Blood supply to the stomach and duodenum showing anatomic relationships to the spleen and pancreas.

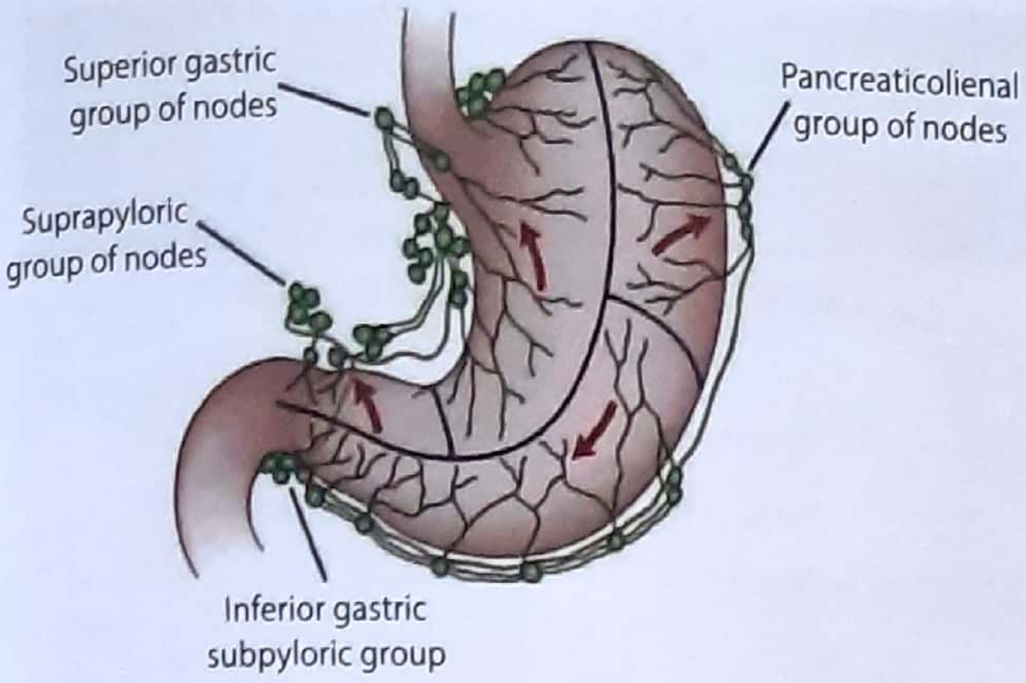

Figure 28.3: Lymphatic drainage of the stomach

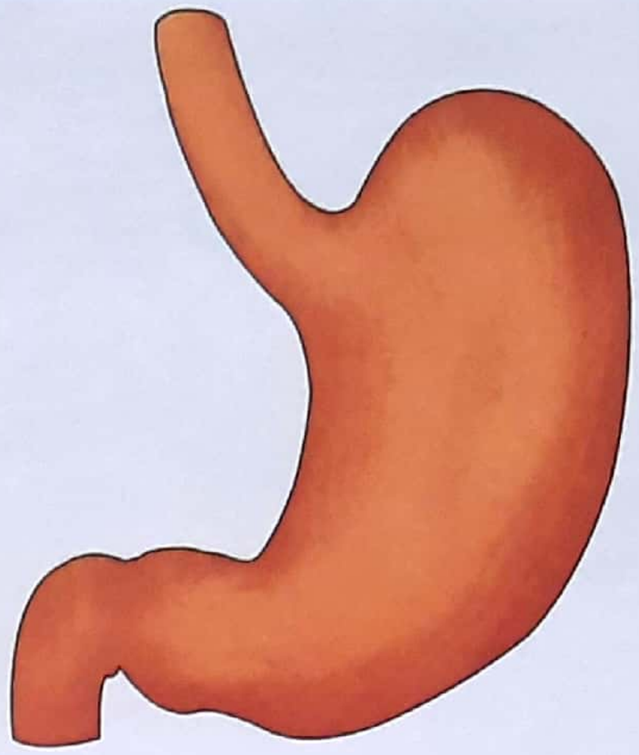

Figure 28.5: Stomach pyloric antrum

Lymphatic Drainage

Generally speaking, the gastric lymphatics parallel the blood vessels.

The main lymph nodes draining the stomach are:

1. Right gastric nodes
2. Left gastric nodes
3. Sub pyloric nodes
4. Splenic nodes
5. Right gastro epiploic nodes

NOTE that lymph from all area of the stomach ultimately reaches the celiac nodes from there it passes through the intestinal lymph trunk to reach cisterna chyli.

Till now we were discussing brief surgical anatomy of stomach now lets discuss physiology in brief; before discussing diseases related with stomach.

****

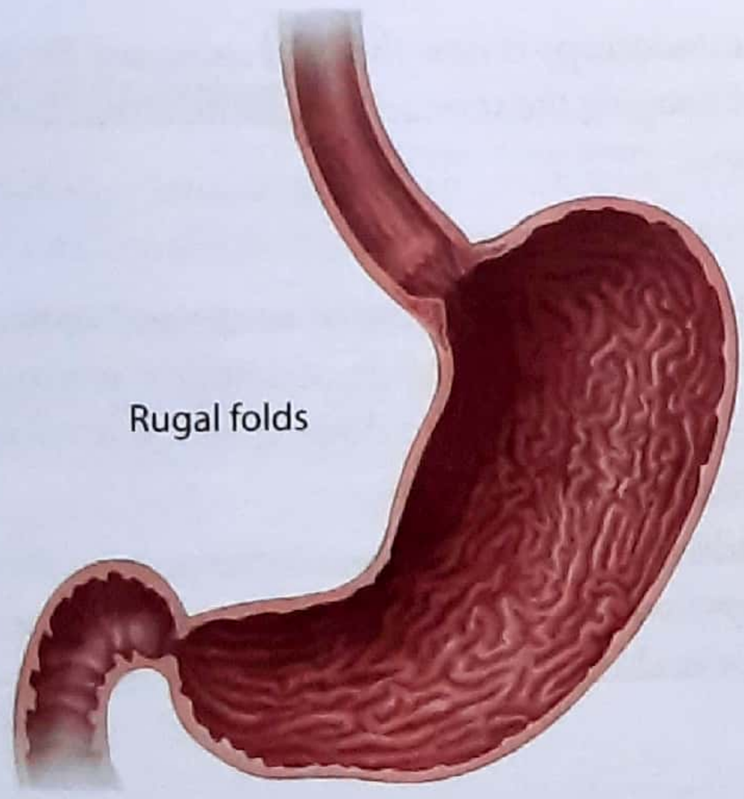

Figure 28.4: Interior of stomach

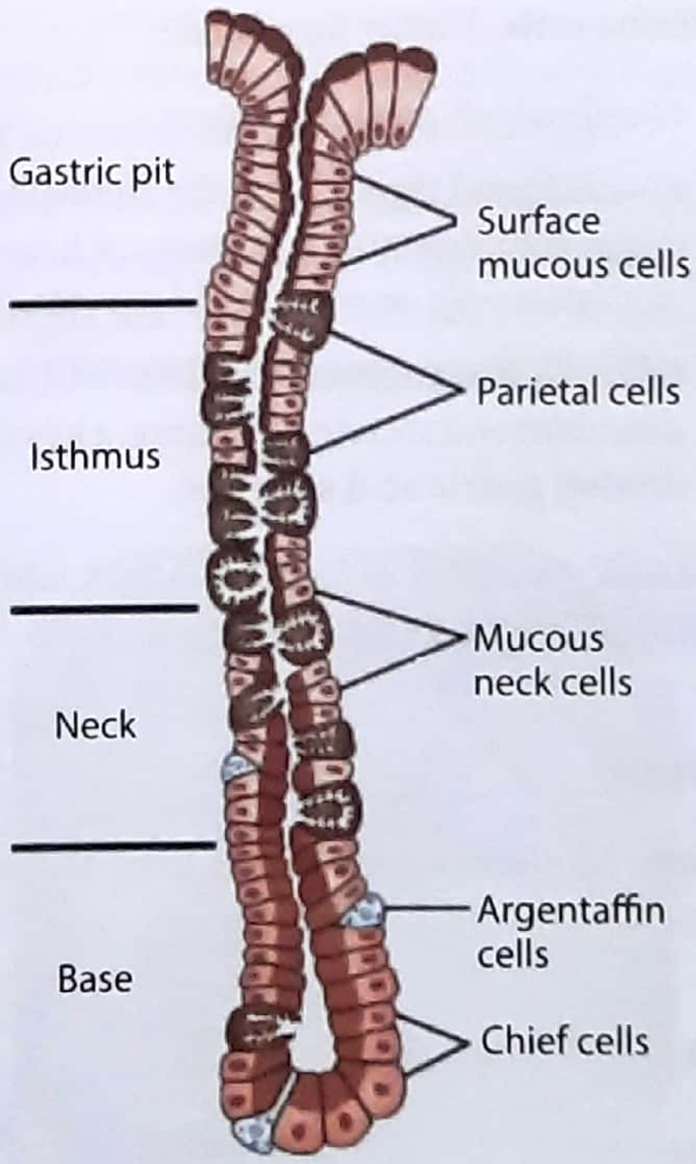

Figure 28.6: Cells residing within a gastric gland

KEY BOX 28.0		
Gastric cell types, location and function		
CELL TYPE	**LOCATION**	**FUNCTION**
Parietal	Body	Secretion of acid and intrinsic factor
Mucus	Body, antrum	Mucus
Chief	Body	Pepsin
Surface epithelial	Diffuse	Mucus, bicarbonate, prostaglandins
Enterochromaffin- like	Body	Histamine
G	Antrum	Gastrin
D	Body, antrum	Somatostatin
Gastric mucosal interneurons	Body, antrum	Gastrin-releasing peptide
Enteric neurons	Diffuse	Calcitonin gene-related peptide, others
Endocrine	Body	Ghrelin (hunger hormone)

PHYSIOLOGY OF STOMACH

There are numerous glands in stomach called gastric glands. The gastric glands are named as follows: (Fig. 28.6)

(a) **Parietal (oxyntic) cell**: Secretes hydrochloric acid, intrinsic factor and soluble mucin.

(b) **Chief (Zmyogen, peptic) cells** which secretes pepsinogen.

(c) **Endocrine cells:** Mainly three types:

(i) *G-cells* which produce gastrin

(ii) *D-cells* found through out the stomach and secretes somatostatin *"somatostatin has negative regulatory role on gastric acid secretion".* (AI 93)

(iii) *ECL cells* Enterochromaffin like (ECL) cells are abundant and secrete histamine; a key factor in driving gastric acid secretion.

Of these G cells are found at pyloric antrum, and D cells and ECL cells are found through out the stomach. (TN 91)

Nerve Supply

Parasympathetic nerve supply comes from the vagi and sympathetic supply from coeliac plexus.

Regulation of Gastric Section

For convenience the physiological regulation of gastric secretion is usually discussed in terms of cephalic, gastric, and intestinal influence, although they over lap.

(i) *Cephalic influence:* These are vagally mediated response induced by activity of CNS.

(ii) *Gastric influence:* These are primarily local reflex response (due to distension of stomach) and is under the influence of gastrin.

(iii) *Intestinal influence:* These are the reflex and hormonal feed back effects on gastric secretion initiated from mucosa of the small intestine.

****

INVESTIGATION OF THE STOMACH AND DUODENUM

1. Flexible Endoscopy

Flexible endoscopy is now the 'gold standard' for investigating and imaging the stomach, duodenum and lower part of esophagus. (PGME MANY TIMES)

What is an endoscope ?

It is a device, consisting of a tube and optical system lens for observing the inside of a hollow organ or cavity. This observation may be done through a natural body opening or a small incision.

Endoscopic examination of stomach is called as **gastroscopy;** where in an endoscope is passed in stomach through oral cavity for visualization of interior of stomach.

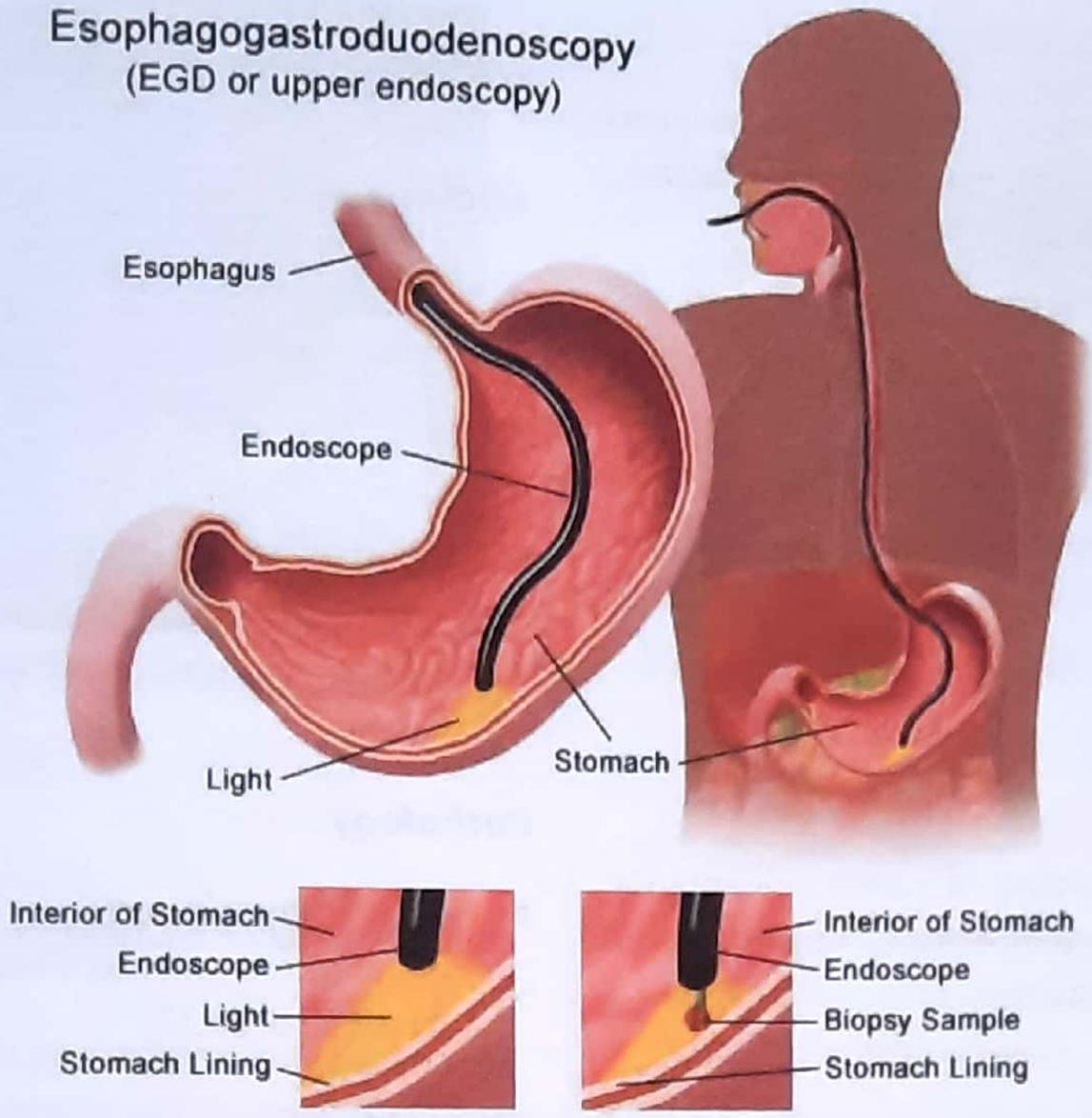

Figure 28.7: Flexible Endoscopy

- Although in Japan *double contrast barium* meal performed by very experienced radiologist are able to detect quite small gastric cancer, *endoscopy is superior at most centers and also allows biopsies to be taken at the same time.*
- With the help of endoscope we can see the interior of stomach, duodenum and esophagus and any growth or ulcer if present.

Please see figure 28.7.

2. Contrast Radiology

- (It is X-ray visualization of stomach using a contrast medium, usually Barium)

  What is a contrast medium and contrast X-ray
- In radiology, the use of a foreign substance to provide a difference in density (contrast) so that tissue or organ is better visualized. When swallowed, barium sulfate is more dense than the intestinal tract and create enough contrast to successfully image the organ, when X ray film is obtained. (For details; please read this topic in chapter 55)
- Upper gastrointestinal radiology is now not used as much as in previous years, because endoscopy is a more sensitive investigation for most gastric problems
- However in number of circumstances contrast enhanced radiography (Ba meal) is still of great value. These conditions include large hiatus hernia of rolling type, and chronic gastric volvulus.
- Linitis plastica may be missed by even relatively experienced endoscopist, as the mucosal aspect of the stomach may not look particularly abnormal. In this case contrast radiography is much helpful.

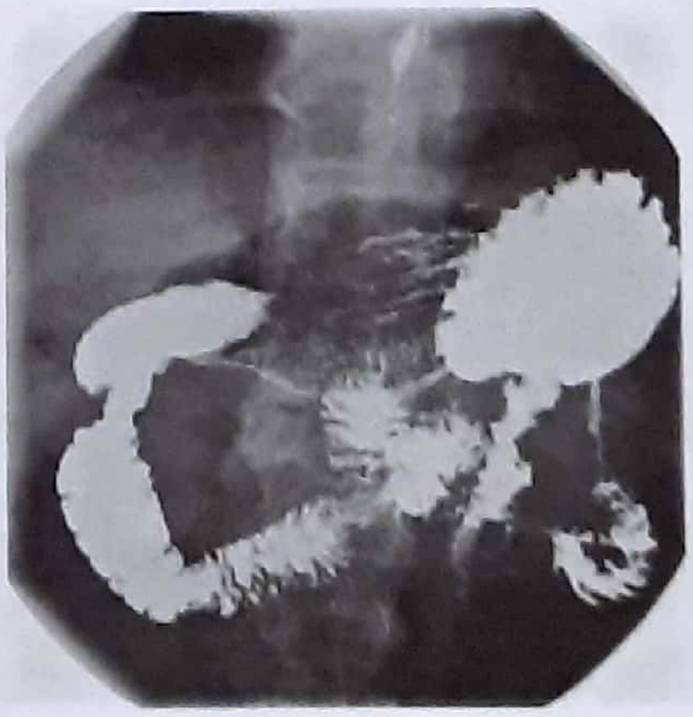

Figure 28.8: Contrast Radiology

3. Ultrasonography

- Standard ultrasound imaging (using a high frequency probe) can be used to investigate the stomach, particularly in patients with gastric cancer.
- In case of malignancy, thickening of gastric wall, enlarged lymph node, local invasion, metastasis to liver and peritoneal deposits can be observed.
- In contrast to simple ultrasound, endo-luminal ultrasound and laparoscopic ultrasound are more appropriate techniques in staging the gastric cancer, *(IMP. POINT)*

4. CT and MRI

- Particularly useful in staging of gastric malignancy and knowing the lymph node status. Even small liver metastasis can be detected by CT.

5. Laparoscopy

(Examination/exploration of abdominal cavity by using an endoscope)

- Laparoscopy detects peritoneal spread that is difficult to be detected by any other method. Laparoscopic assisted ultrasound, (laparoscopic ultrasound) is significantly more accurate than conventional ultrasound or CT scan in assessment of the primary gastric malignancy and the lymph node status.

****

Now we will discuss diseases related with stomach.

HYPERTROPHIC PYLORIC STENOSIS OF INFANCY *(AI93,01,02,03, AIMS 93,97,99,2000 PGI 01,02,03)*

Etiology

- The incidence is approximately 3/1000 birth.
- *Male, female ratio is 4:1 and the patient is generally first born male child.* *(MANY PGME)*
- The etiology is not well understood.
- Heredity is an important factor as pyloric stenosis is more common in children born of parents who had suffered with this condition in their infancy.

Pathology

- There is *gross hypertrophy* of musculature of pylorus and adjacent antrum. Please help your self with figure 28.12 & 28.13.

Clinical feature

- The *condition is most commonly seen 4 weeks after birth, ranging from third week,* *(MANY PGME)*
- One to two weeks after birth *projectile vomiting starts.* As obstruction is at pylorus, ***there is no bile in vomitus.*** *(NEET, PGI 89, UP 93, 01, MANY PGME)*

NOTE: If obstruction is distal to 2nd part of duodenum (where in bile duct opens) the vomitus will contain bile, but in this case obstruction is at pylorus; hence vomitus does not contain bile (non-bilious vomiting)

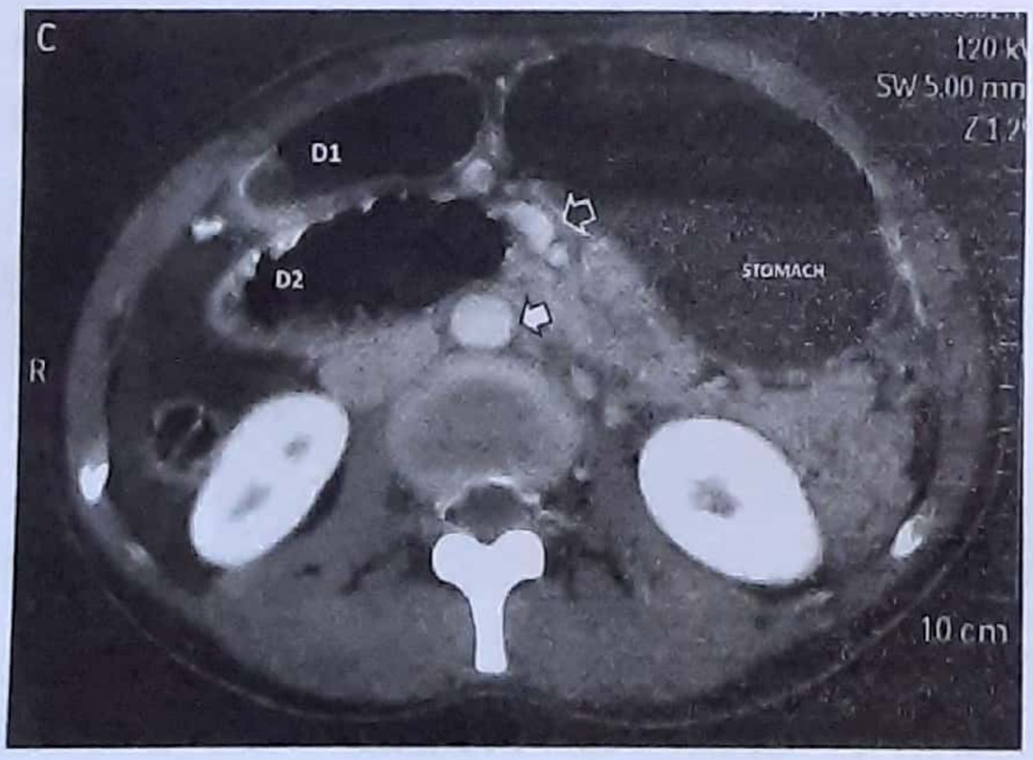

Figure 28.9: CT and MRI

Figure 28.10: Observe lump in right hypochondrium

Figure 28.11: USG finding of hypertrophic pyloric stenosis of infancy

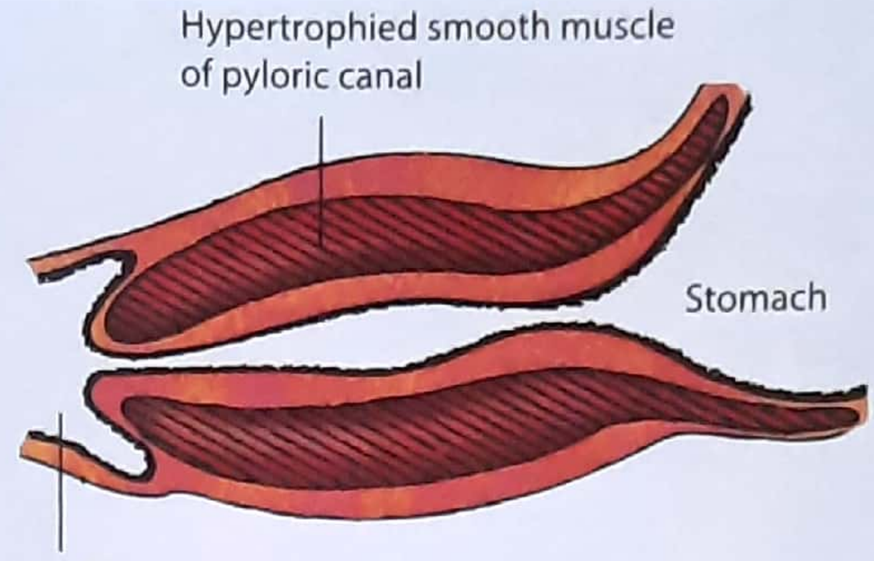

Figure 28.13: Cross section through pyloric canal

- Often a *hard lump is palpable in right hypochondrium. Figure 28.10*
- When the infant is fed a peristaltic wave may be seen *from left to right* in epigastric region during feeding. *(NEET, IMP. POINT)*
- Weight loss is a striking feature and the infant rapidly becomes emaciated and dehydrated.
- Metabolic abnormalities due to HPS is **hypochloremic hypokalenic metabolic alkalosis with paradoxical aciduria**. *(NEET, INICET NOV. 20, AIIMS 09, 10, AI 02)*

Diagnosis

- Can usually be made by a **test meal,** *and observing the peristaltic wave moving across the abdomen from left to right.* *(PGI 06)*

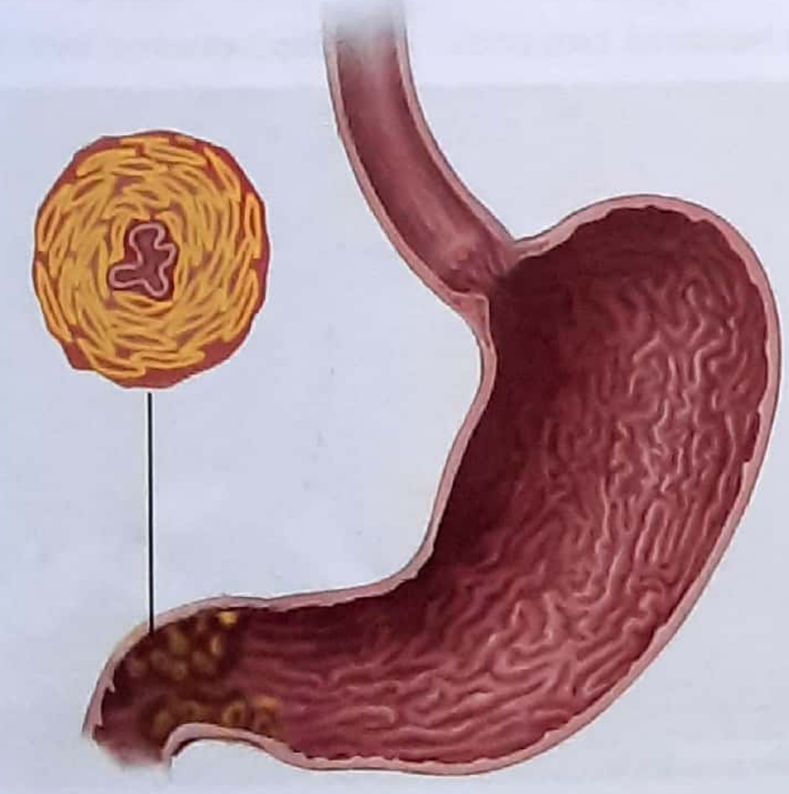

Figure 28.12: Hypertropic pyloric stenosis

- **Imaging:** ***Ultrasonography is the investigation of choice*** *(NEET, AIIMS 99)*, which detects the classical feature of the pyloric canal.
- USG Diagnostic criteria for HPS
  - Channel length > 16 mm
  - Pyloric thickness > 4 mm
- *Gastrograffin study* will give shouldering sign *(IMP. POINT)*.
- String sign on a barium meal : In which contrast appear as thin stripes within luman that looks like a string.

Treatment

- First concern is to correct the metabolic abnormalities eg; *hypokalemic, hypochloremic metabolic alkalosis due to gastric outlet obstruction and consequent vomiting.* *(PGI 89, UP 95, MANY PGME)*
- Ideal replacement fluid for correction of electrolyte abnormalities is normal saline (NS) *(UP 98)*
- Conservative treatment has little place in management of condition. The main stay of treatment is surgical.

Operation

Ramstedt's pyloromyotomy
(Fredet-Ramstedt's Procedure)

(AIIMS87, TN 04, PGI 97, UP 2000)

- Pyloromyotomy : Pyloro + myo + otomy = Pylorus + Muscle + cutting (incision)

- Pylorus muscle in incised and mucous membrane of pyloric canal comes out bulging.
- Results of surgery are excellent and most infants are discharged with in 3rd postoperative day.

****

DUODENAL ATRESIA AND STENOSIS

- If the obstruction is complete the condition is known as atresia and when it is incomplete it is called stenosis.
- In more than 80% cases the atresia is distal to ampulla of vater-hence vomitus is bilious.
- Annular pancreas is almost always associated with hypoplasia at the level of duodenum.
- Please see figure 28.15 for type of atresia.

Associated condition - Down syndrome, Polyhydramnios, Malrotation, Biliary atresia, annular pancreas, Prematurity

Figure 28.14: Duodenal atresia or duodenal showing double bubble sign

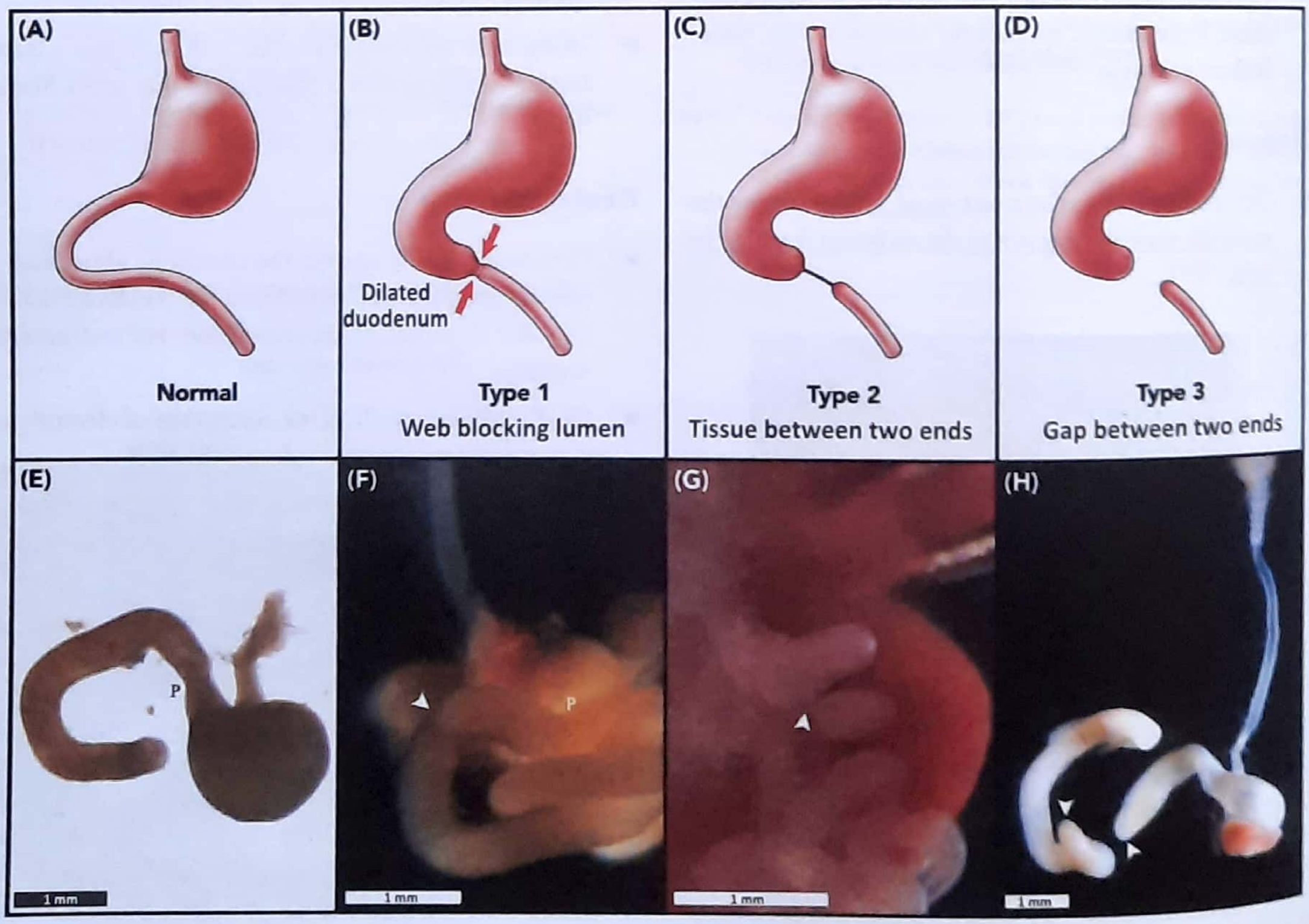

Figure 28.15: Duodenal atresia types

Diagnosis

- X-ray of the abdomen shows distended stomach and distended proximal duodenum-***Double bubble sign*** *(NEET, PGI 97, AIIMS 09)*. Distended stomach and distended duodenum gives a picture resembling two bubbles. Figure 28.14

Treatment

- *Duodeno-duodenostomy* ***is operation of choice.*** *(PGME)*
- Duodeno-jejunostomy can also be done.
- If *annular pancreas* is present it should be left as such and a bypass procedure such as duodeno duodenostomy is done. *(PGME, IMP. POINT)*

? Duodeno-duodenostomy

It is surgical creation of passage, *between* the first part of duodenum and third (or fourth) part of duodenum, *bypassing the second part*, where in most of the atresia or stenosis is present. After creation of this; food will enter directly into third (or fourth part) of duodenum bypassing the second part, so intestinal continuity is maintained.

? Duodeno-jejunostomy

It is surgical creation of passage between the duodenum and jejunum.

****

ACUTE EROSIVE GASTROPATHY (ACUTE GASTRITIS)

Acute erosive gastropathy is a relatively common condition. This condition is characterized by diffused hyperemia of the mucosa, with small superficial erosions and ulceration.

An erosion is a denudation (bare area) of surface epithelium with deep part of the mucosa remaining intact, where as in an ulcer full thickness of the mucosa is involved. (See figure 28.20; page 419) Microscopically, there is surface epithelial injury and necrosis of superficial gland. Hemorrhage may be 'present in lamina propria (acute hemorrhagic gastritis).

Hyperemia/Congestion= Unusual large amount of blood in a part/organ.

Etiology

1. Drugs

- Drugs are the most common cause of acute gastritis. NSAIDs and corticosteroids are most potent agents in causing acute gastritis. Please see key box 28.1.
- These probably act by inhibiting prostaglandin synthesis in the mucosa- (Note: that prostaglandins are responsible for synthesis of mucus, which lines the mucosa and have protective role.), thus making it more susceptible to gastric acid.

Figure 28.16: Endoscopic view of acute erosive gastropathy

KEY BOX 28.1

Cause of Acute Erosive Gastropathy

1. **NSAIDS**
   - Aspirin
   - Ibuprofen
   - Corticosteroids
2. **Directly acting luminal chemical**
   - Ethyl alcohol
   - Bile reflux
   - Corrosive ingestion
3. **Stress**
   - Severe burn (curling's ulcer)
   - Intracranial lesion (cushing's ulcer)
   - Post MI
4. **Shock**
   - Shock
   - Portal hypertension
5. **Chemotherapy**
6. **Sepsis**

- Cigarette smoking also inhibits prostaglandin synthesis and tends to aggravate all forms of ulceration.

2. Directly acting luminal chemicals

Ethyl alcohol, bile reflux in stomach (in post gastrectomy patient) and corrosive ingestion cause mucosal injury and causes acute erosive gastropathy.

3. Stress

- Stress plays an important role in acute gastritis.
- *Severe burns [curling ulcer], myocardial infarction, intracranial lesion (cushing's ulcer) play important role in causing gastric erosion.* (MANY PGME)
- Neurosurgical procedures and intracranial lesions cause increased acid or pepsin secretion, possibly caused by direct pressure on the vagal nuclei.
- Stress ulcer may also result following trauma, surgery, sepsis, myocardial infarction and respiratory failure. Mucosal *ischemia appears to be the important factor.*

4. Chemotherapy

Chemotherapy particular in hepatic arterial infusion of cytotoxic drugs, may cause direct mucosal injury.

IMPORTANT POINT: Ulcers in acute erosive gastropathy tend to be small (<1 cm) multiple and distributed through out the stomach. Where as chronic gastric ulcers are large solitary and usually found on the lesser curvature.

Clinical feature

- Mild cases are asymptomatic or associated with mild dyspepsia*.[Dyspepsia = *Symptoms of indigestion*].
- In moderate to severe cases epigastric pain, nausea and vomiting may occurs.
- In very severe cases; hematemesis and melena is the most significant symptom.

Treatment

- Withdrawal of etiological factor.
- H_2 antagonist, antacids and PPI are used.

****

CHRONIC GASTRITIS

- Chronic gastritis is defined histologically as an increase in number of lymphocyte and plasma cell in gastric mucosa.
- The mildest degree of chronic gastritis is chronic superficial gastritis, which involves the subepithelial region around the gastric pit*. More severe cases involves the glands in deeper mucosa, and is commonly associated with gland atrophy (chronic atrophic gastritis) and intestinal metaplasia. Most cases of chronic gastritis are of **two types** (Figure 28.17)

?Gastric pit: Several fundic gland open through a common opening; called gastric pits. Figure 28.6 page 405.

1. Type A

which is an Autoimmune gastritis that primarily *involves the body* and is usually associated with pernicious Anemia. (A=Autoimmune Anemia) (PGME) {mind: A}

2. Type B

Which primarily *involves the antrum* and is associated with Helicobacter Pylori Bacteria infection. (B=Bacteria ie; H. Pylori). (PGME) {mind: **B in the text**}

JUST TO REMEMBER in respect to site of stomach involved: Type 'A' involves 'B' that is **Body** of stomach; while type 'B' involves 'A' that is **Antrum.** Please see figure 28-17.

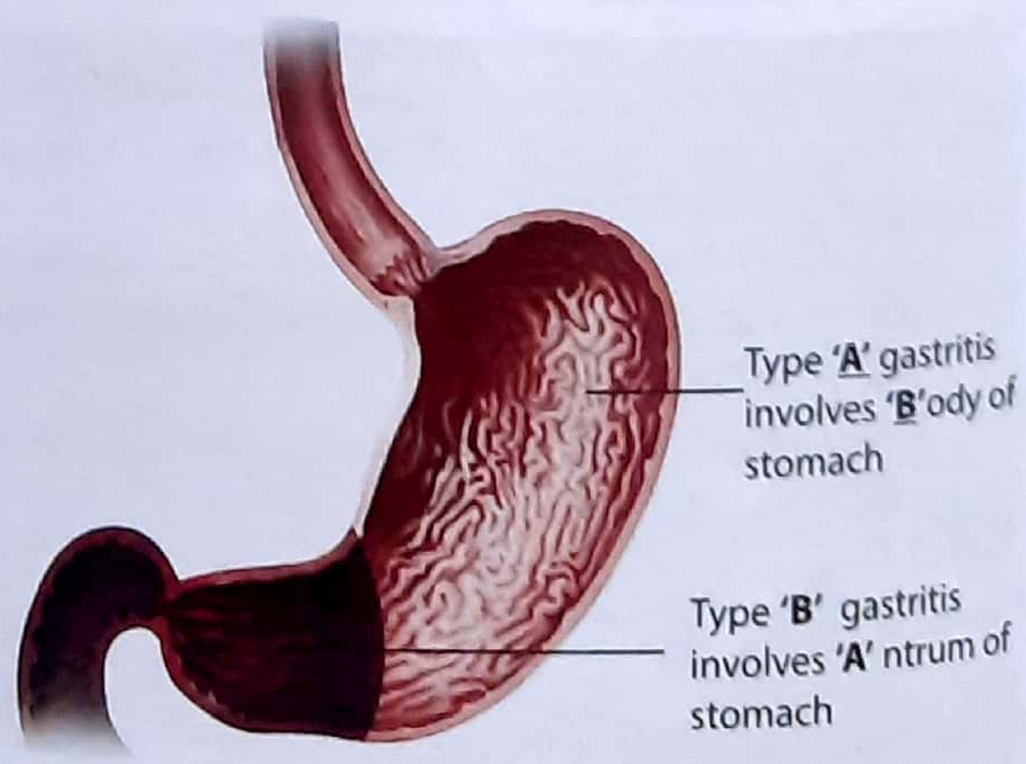

Figure 28.17: Primary sites for involvement in Gastritis

Now lets discuss them one by one:

1. Type A chonic gastritis (Auto immune type associated with Pernicious Anemia)

This is an autoimmune condition in which there is circulating ***auto-antibodies to parietal cell,*** which are found is **body and fundus** of the stomach. Now I will like to describe this condition by a flow chart for easy understanding. Parietal cells present in body and fundus of stomach secretes HCl and intrinsic factor. In this condition:-

Auto antibody directed to Parietal cell (oxyntic cells)

↓

Causes destruction of Parietal cell

↓

Decreased secretion of

HCl and Intrinsic factor

↓ ↓

Hypochlorhydria

Failure in absorption of Vit B_{12} → pernicious anemia

As a response to hypochlorhydria; ECL cell & G-cell (present in **antrum,** and hence not involves in this condition.

↓

Increase Gastrin secretion

↓

Hypergastrinemia

↓ **& also**

There occurs hypertrophy of ECL cells, as a result of chronic hypochlorhydria

↓

microadenoma development in ECL cells as a result of hypertrophy

↓

may rarely turn malignant

- G-cells (Gastrin secretin cells) and ECL cells (Entro-Chromaffm Like cell-responsible for histamine release) are key endocrinal factors in producing gastric acid secretion.
- ECL cells are found through out body of stomach while G-cells are found only in antrum *(TN-91)*

2. Type B chronic gastritis (Chronic antral gastritis, Helicobacter pylori Bacteria gastritis)

- This condition is also known as environmental gastritis
- Type B chronic gastritis has a strong association with H. pylori, which is found in approximately 30-90% patients with type B gastritis. It is an infective condition, which maximally involves the **antrum**.

Understand the pathological process by this flow chart:

H. Pylori

↓

Infects Antral mucosa

↓

As a result of active infection, infiltration of neutrophil occurs in antral mucosal glands

↓

Progression of lesion (if not treated)

↓

Extension of inflammation, to involve deep mucosa as well as the body of stomach

↓

Leading to destruction of antral mucus glands and intestinal metaplasias

↓

Result in chronic atrophic gastritis, leading to decrease acid secretion

- *If severe metaplasia occurs; it man lead to adenocarcinoma of stomach.* *(MANY PGME)*

Before concluding this topic kindly read key box No 28.2. next page.

****

KEY BOX 28.2

Comparison between Type A and Type B gastritis

	Type A	Type B
1. Etiology	Auto immune (typeA=* Autoimmune)	H. pylori Type B. Bacteria (H. pylori)
2. Region most commonly involved	Body and fundus	Pyloric antrum
3. Mucosal atrophy	Present	Present
4. Intestinal metaplasia	+	+
5. Cancer risk	++	+
6. Association with cancer	High	Low
7. Acid secretion	Decreased or nil	Usually normal but may be increased or decreased
8. Serum gastrin	Elevated	Normal
9. Endocrine cell hyper plasia (EC1 cell and G cell)	Present	Not present
10. Serum auto-antibodies	+ (in 90%)	—
11. H, pylori infection	Not present	Present in 80-90 % of cases
12. Association with peptic ulcer	Ulcers do not occur (Remember there is either hypochlorhy-dria or aehlorhy-dria- hence ulcer do not occur.)	High
13. Serum B_{12}	Low	Normal
14. Pernicious anemia	Present	Not so

Eosinophilic Gastritis

This is rare disease believed to be due to immunological hyper-sensitivity. The gastric and intestinal mucosa is infiltrated by chronic inflammatory cells and numerous eosinophils

Lymphocytic Gastritis

This type of gastritis is very rare. It is characterized by infiltration of gastric mucosa by T cell and is probably associated with H.pylori infection.

Varioliform Gastritis

Characterised by nodules, thickened rugal folds & erasion.

Diagnosed by endoscopy.

****

MENETRIER'S DISEASE (HYPERTROPHIC GASTRITIS)

Menetrier's disease is a rare condition of unknown etiology. Patients are usually in their fifth decade of life.

Pathology

There is *hyperplasia and dilatation of mucus gland* together with proliferation of smooth muscles of muscularis mucosa. Now see this flow chart:.

Hyperplasia of mucus gland
(Basic pathology)

↓

Increased production of mucus

↓

Increased loss of protein in the stool
(because mucus is very rich in protein)

↓

That is why this condition is also known as
protein losing enteropathy (PGME)

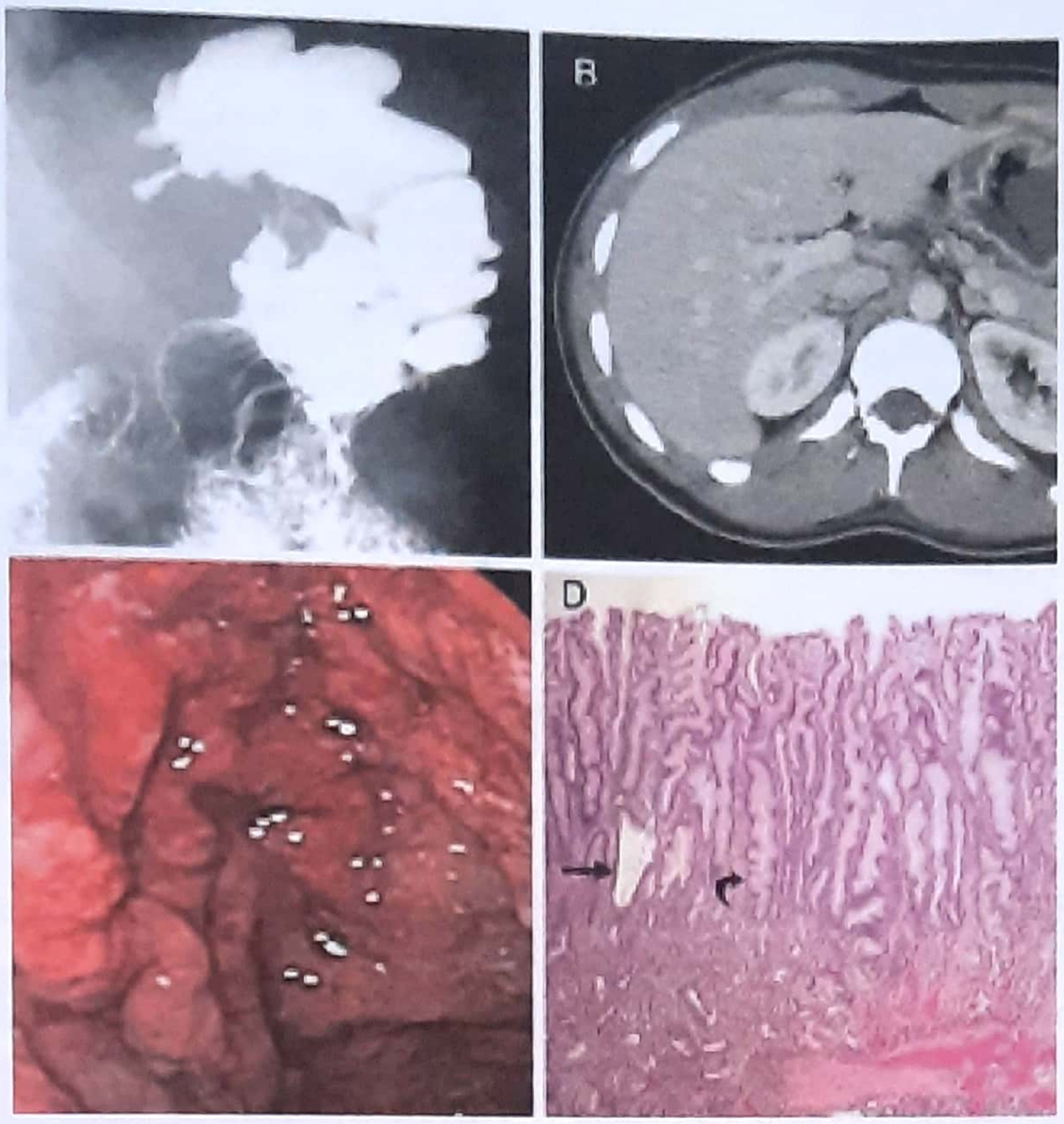

Figure 28.18: Menetrier disease

Other Features

- This disease is characterized by ***greatly thickened rugal fold***. *(NEET, PGI 03, VERY IMP. POINT)*
- It is a ***premalignant condition*** *(NEET, MANY PGME).*
- This disease presents as *hypoproteinemia* (due to protein loss) and anemia.
- The disease seems to be caused by over expression of transforming growth factor (TGF α).
- *There is no treatment of this disease other than gastrectomy.* *(IMP. POINT)*

****

PEPTIC ULCER

- Peptic ulcers, are ulcers occurring in any part of the gastro intestinal tract, exposed to action of acidic gastric juice.
- They occurs principally in duodenum (duodenal ucer) and stomach (gastric ulcer).
- Duodenal ulcer, is 3-4 times more frequent in males.
- Duodenal ulcers occur at all ages; the most common age being, between 20-40 years.

KEY BOX 28.3

Sites At Which Peptic Ulcer Occur

Duodenum	75% of peptic ulcer (**M/C** site) *AL 99, AIIMS 04, UP 2002*
Stomach	20% of peptic ulcer, mainly at lesser curvature and antrum
Lower esophagus	Associated with reflux esophagitis
Stomal ulcer	At the stoma of Gastro-enterostomy
Meckel's diverticulum	Associated with the presence of hetrotrophic gastric mucosa
Distal duodenum and jejunum	Rare
Ileum and colon	Very rare, associated with presence of heterotrophic gastric Mucosa

- A familial tendency exists for duodenal ulcers, but no familial tendency has been seen with gastric ulcer. There in a high incidence of du**O**denal ulcers in a patient with blood group **O**.

NOTE: (In c**A** of stomach = association with blood group **A** has been observed)

Pathology

1. Hyper secretion of Acid

Acid is necessary for peptic ulcer to form, and ulcer does not occur in achlorhydric state.

However, the exact causal role played by the acid is uncertain. Patients with duodenal ulcer have increased acid secretion, but patients with gastric ulcer frequently have normal or low acid production. A marked increase in acid secretion occurs in patients with Zollinger-Ellison syndrome, caused by a gastrin-producing neoplasm of pancreas. This high gastrin level causes increased stimulation of parietal cells to produce acid. As a result of which severe intractable (non-healing) peptic ulcers occur affecting stomach, duodenum and jejunum.

2. Decreased mucosal resistance to acid

- *Decreased resistance of mucosa to acid is believed to be the **primary cause** for most gastric ulcers.* Mucosal resistance to acid is mainly due to prostaglandin.
- PGE2 markedly reduces acid secretion in the stomach. Volume of Juice and pepsin content are also decreased. PGE2 acts directly on intestinal mucosa and increased water, electrolyte and mucus secretion.

NOTE : mucus is protective to gastric mucosa against acid.

- On the other hand prostaglandin PGI_2 also inhibits gastric secretions, but is less potent. PGI_2 is also involved in the regulation of gastric mucosal blood flow. *(IMPORTANT FACT)*

Summary

Prostaglandins are responsible for increased mucus production and mucosal blood flow in stomach, ie; antiulcerogenic, while smoking, corticosteroids & NSAIDS inhibit prostaglandin synthesis, hence they are ulcerogenic.

3. Helicobacter pylori infection

H.pylori infection, is present in nearly all cases with chronic duodenal ulcer, and approximately 75% patients with chronic gastric ulcer.

NOTE: *Though H.pylori can been associated in almost all case of duodenal ulcer and about 75% cases of gastric ulcer, it does not mean that all patients colonised with H. pylori will develop peptic ulcer disease. In fact only 15-20% of patients colonized with H.pylori will develop peptic ulcer disease over their lifetime.*

4. Abnormal gastric emptying

Patients with duodenal ulcer show increased rate of gastric emptying. The rapid entry of gastric content may exceed the ability of duodenum to neutralize the acidic content of stomach leading to duodenal ulceration.

Etiology of Peptic Ulcer *(AIIMS 97,95,04,93,2000, AI99)*

Discussed here one by one:-

A. Acute peptic Ulcer

(i) *NSAIDS Ingestion*

(ii) *Stress*

- *Cushing ulcer after cerebral trauma* (NEET)
- *Curling ulcer after burn injury and other kind of shock (most common - First part of duodenum).*

(iii) *Sepsis* - Undrained pus may be responsible form acute ulcer.

(iv) *Steroids*

(v) Ulcers in association wih Z-E syndrome

B. Chronic Gastric ulcer

(i) *NSAIDs Ingestion*

- NSAIDs **disrupt the prostaglandin driven support** of the mucosal barrier and cause ulceration.
- Prostaglandins are responsible for the production of mucosal gel layer in the stomach, which provides protective barrier to the gastric and duodenal lining, so disruption of this mucosal barrier allows even minimum amount of acid to cause ulceration.

Peptic Ulcer Disease :
Pathogenesis and Clinical Findings

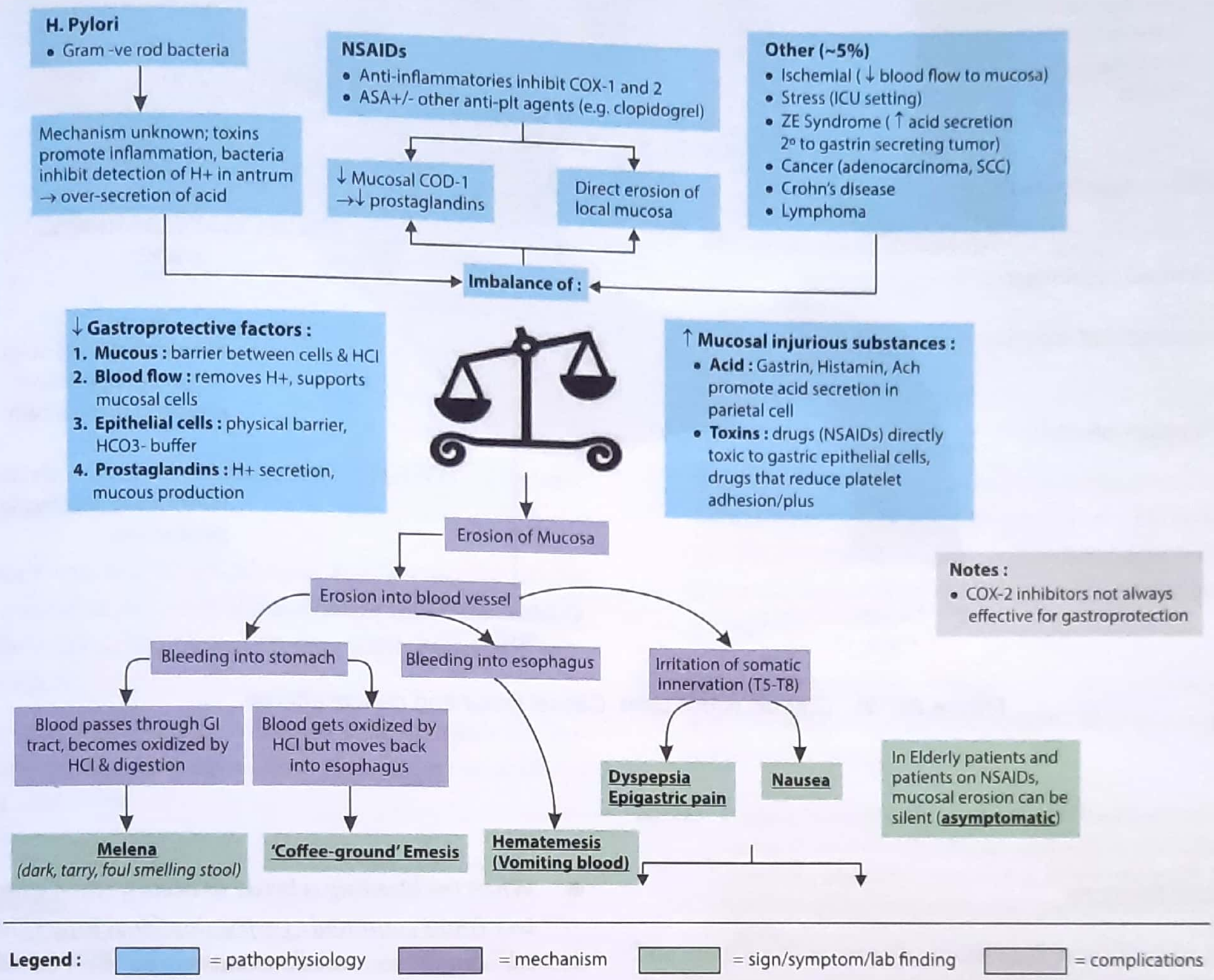

(ii) *Heliobacter pylori:* H.Pylori is seen in almost 90% of cases of duodenal ulcer and 75% of cases of gastric ulcer.

(iii) *Pyloro-duodenal reflux:* Regurgitated bile & other duodenal juices in stomach.

(iv) *Mucosal trauma*: By mechanical effect of food

(v) *Diet and Smoking*: Irregular diet, spicy food excessive, drinking of tea & coffee, alcohol, cigarette smoking has a definite relation with both gastric & duodenal ulcer.

(vi) *Emotional factors:* Anxiety, stress & strain.

(vii) *Liver disease*

- Ulceration of both stomach and duodenum have coexisted with disease of the liver particularly cirrhosis.
- It may be due to increase in blood supply to the gastric mucosa and overproduction of histamine in the stomach wall to stimulate the parietal cell.

C. Chronic Duodenal ulcer

(i) *Acid hypersecretion*

(ii) *Genetic factors*

(iii) *Endocrinal disorders*

- Zollinger Ellison syndrome (ZES)
- Hyperparathyroidism
- Cushing syndrome (high level of endogenous steroid)

(iv) *Chronic liver diseases*

(v) *Chronic lung disease*

(vi) *Chronic pancreatitis*

(vii) *Emotional factor*

(viii) *Diet & smoking*

(ix) *H.pylori*

(x) *Decrease in bicarbonate production*

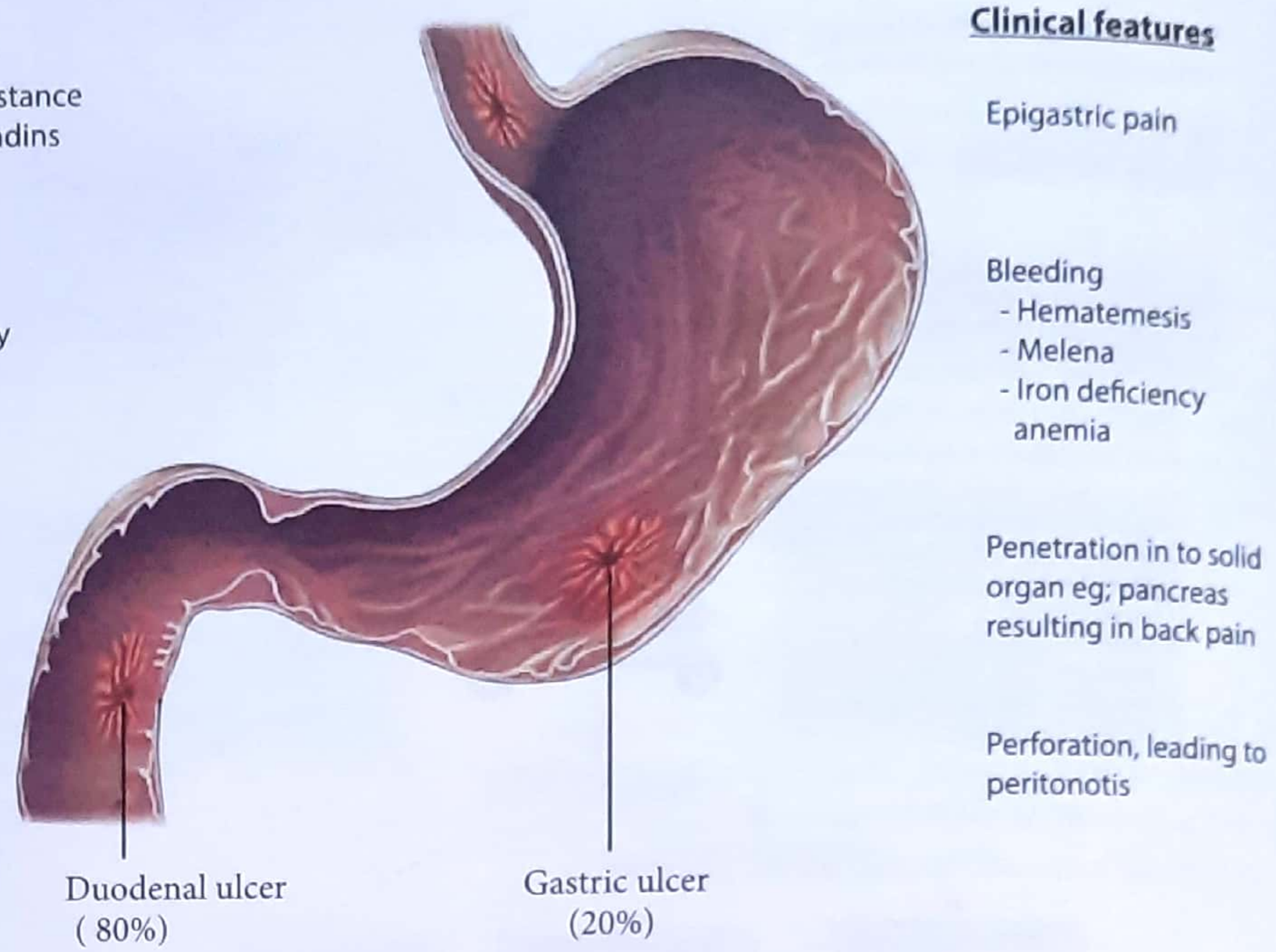

Figure 28.19: Chronic peptic ulcer. Causal factor and clinical effects

Clinical feature

Peptic ulcer disease is a chronic disease with relapses and remission of symptoms.

- Relapse may be precipitated by emotional stress, drugs such as steroids, aspirin and Ibuprofen and by cigarette smoking.
- *Epigastric pain* is the most constant symptom. Pain is often related to meals.
- The diagnosis is best established by endoscopy and biopsy; to rule out carcinoma is case of a gastric ulcer.

Complication of Peptic Ulcer

1. Bleeding

- Bleeding is as a result of erosion of a blood vessel by ulcer can occurs in about 30% of patients with peptic ulcer disease.
- *Peptic ulcer disease is commonest cause of hemetemesis.* (MANY PGME)
- If bleeding is minor; there occurs occult (hidden) blood loss in feces and in long standing cases; which may lead to Iron deficiency anemia.
- *When the bleeding is brisk, as occurs, when a large artery (most commonly gastro-duodenal artery) is eroded, hematemesis and melena results.* (UP, MANY PGME)
- Hematemesis is responsible for about 10% of death from peptic ulcer disease.

2. Perforation

- *Perforation* occurs in about 5% of peptic ulcer patients, being *most common with an anterior duodenal ulcer* (MANY PGME). The entry of gastric juice into peritoneal cavity results in peritonitis (chemical peritonitis).
- Perforation of an ulcer is responsible for about 60% of deaths due to peptic ulcer. (MC *cause of death due to peptic ulcer disease)* (PGME)

3. Penetration of adjacent organs

Ulceration process may involve the full thickness of stomach or duodenal wall and may penetrate in the adjacent organ without perforation. A posterior duodenal ulcer may penetrate into pancreatic tissue, which may cause pancreatitis. In this situation patient will have constant back pain.

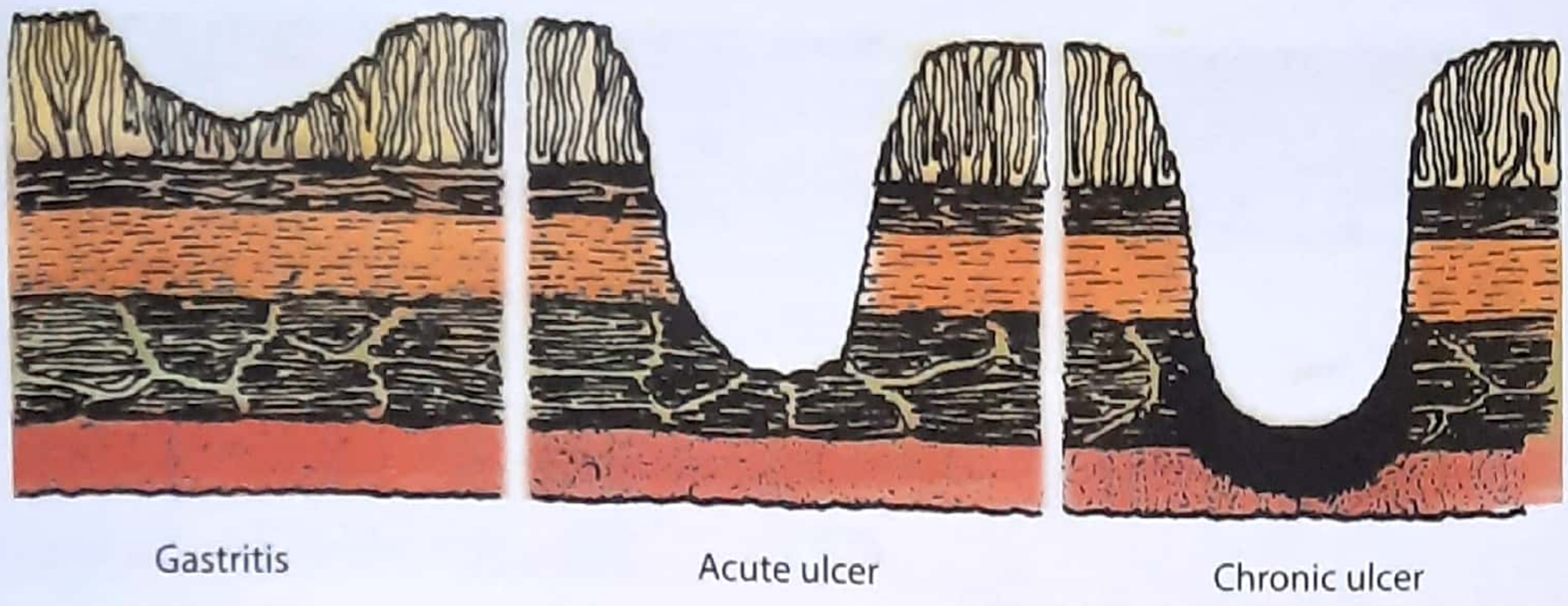

Figure 28.20: Note depth of invasion in Gastritis, acute & chronic ulcer.

4. ***Gastric outlet obstruction (GOO) (Pyloric stenosis)***

Fibrosis associated with healing of an ulcer situated in the pyloric canal or first part of duodenum causes narrowing of pyloric canal, which results in gastric outlet obstruction (GOO).

Severe vomiting, dehydration and *hypokalemic hypochloremic metabolic alkalosis with paradoxical aciduria results.* (MANY PGME)

Treatment

1. **Dietary adjustment**: Small frequent meals [6 small meals in place of 3]. Avoidance of spicy and fatty food.
2. **Avoidance of Cigarettes:** Intake of tobacco in any form, coffee and alcohol should be stopped .
3. **Drug therapy**
   - *Antacids* - To neutralize hyperacidity.
   - H_2 receptor blockers: Like cementidine and rantidine.
   - Proton pump inhibitors (*PPI): Omeprazole and pantoprozole (see below)
4. **Drugs for H.pylori eradication**: H.pylori is associated with almost 100% cases of duodenal ulcer and 75% cases of peptic ulcer. So it has to be eradicated.
   - The **drugs** used these days are 3 drug combo pack (namely omeprazole, amoxicillin and Tinidazole) (PGME)

PROTON PUMP INHIBITORS (PPI): The parietal cells of the stomach are responsible for production of hydrogen ions to form hypochlorous acid. The hydrogen ion are actively pumped by proton pump, a hydrogen-potassium ATPase, which exchange intramural K^+ ion for Hydrogen ion. PPI inhibits this pump - and reduces acid secretion. Drugs commonly used are Rabeprazole, Pantoprazole & Esmaprazole.

5. **Surgical procedure**: The aim of surgical procedure is to reduce gastric acid secretion. They are; vagotomy or antrectomy.

NOTE: If a gastric ulcer does not heal with medical treatment. It must be examined by an endoscope and biopsied, because ulcerative carcinoma of the stomach mimic both in symptoms and gross appearance to a peptic ulcer.

- Biopsy of a duodenal ulcer, which is slow in healing is not essential because carcinomas are rare in them.

Friends, we were discussing peptic ulcer disease as a whole; now we will discuss gastric ulcer and duodenal ulcer one-by-one

****

GASTRIC ULCER

[Major part has been discussed in previous topic, i.e; peptic ulcer. Here I will outline some important facts only]

Incidence

- As with duodenal ulceration, H.pylori and NSAIDs are the most important etiological factor.
- Gastric ulcer is far less common than duodenal ulcer.
- Males are affected more commonly by both gastric and duodenal ulcer.
- Gastric ulcer is a *disease of elderly male*. Peak incidence is at 50 years.

- Gastric ulcer has been viewed as a disease of weakened mucosal defence (PGME), where as duodenal ulcer has typically been thought to be a disease due to increased peptic acid secretion on the duodenal mucosa. (PGME)
- In fact in gastric ulcers, there may be normal acidity or even low acidity (hypochlorhydria).

Etiology

It has been discussed in detail, earlier under topic peptic ulcer on page number 416.

Pathology

Gastric ulcer is large is size than a duodenal ulcer. It is round or ovoid is shape with sharp edges. *About more than* ***90% ulcers are on lesser curvature,*** (NEET) *rest are on pylorus.* (MANY PGME)

Modified Johnson Classification of Gastric Ulcers

In comparison **gastric ulcers are of 5 types:**

Type I *M/C type (60-70%)*

Typically located at lesser curvature at or proximal to the incisura, near the junction of the oxyntic and antral mucosa. Most of them are associated with diffused antral gastritis or multifocal atrophic gastritis.

Type II (About 15%)

The location of this type of ulcers are same as that of Type I, but are associated with either active or chronic duodenal ulcer disease.

Type III

They account for about 20% and are typically located with in 2 cm of the pylorus.

Type IV

They constitute about 1-5% of all gastric ulcers and are located in the proximal stomach or in the gastric cardia and at gastro-esophageal junction.

Type V

They are found anywhere in the stomach. They are usually drug induced.

NOTE: Type II and Type III gastric ulcers appear to behave more like duodenal ulcers and are associated with excess acid, where as type I & IV are not, more over a gastric cancer may ulcerate and resemble to a gastric ulcer.

NOTE: Larger the size of a gastric ulcer-large the chance of it, to be malignant ulcer. Please see figure 28.20 and note the depth of invasion in gastritis, acute ulcer and chronic ulcer.

Please see figure 28.21, and read key box 28.3.1

Clinical feature

- **Pain is the** (NEET) most common presenting symptom, which is usually felt in epigastrium, (see fig 28.22)
- Pain appears almost immediately or any time up to 1-2 hour after a meal.
- Food aggravate pain due to irritation of ulcer by food.
- There may be 'pain free' period of varying interval.
- In about 50% of cases **vomiting is a notable** (NEET) feature. Vomiting frequently follows a meal, and may occasionally be self induced as it relieves pain.
- *Initially appetite is good,* but the **patient is afraid of eating, because it will initiate pain.** (NEET, UP 93)
- There is **loss of weight** (NEET) and anemia.

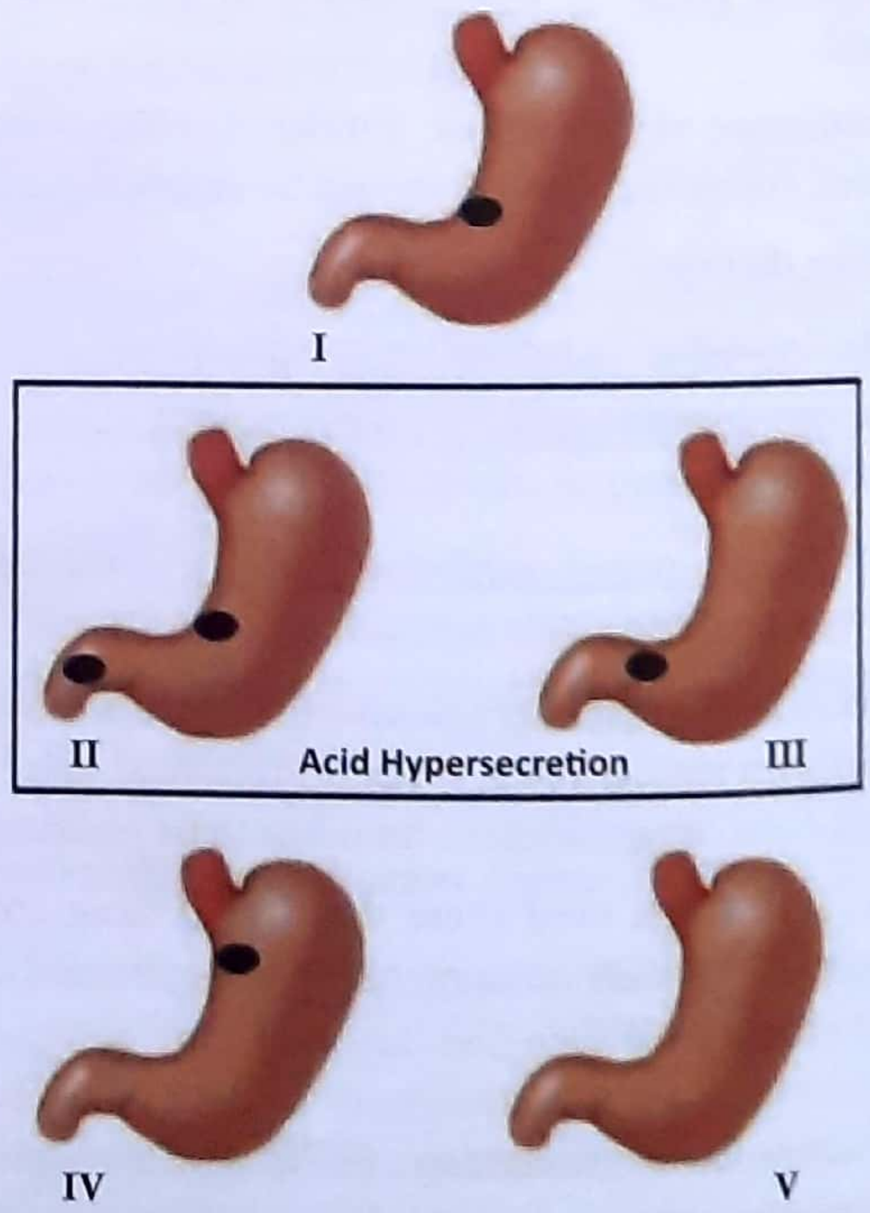

Figure 28.21: Modified Johnson classification of gastric ulcer

KEY BOX 28.3.1

Gastric ulcer types

TYPE	LOCATION	ACID LEVEL
I	Lesser curve at incisura	Low to normal
II	Gastric body with duodenal ulcer	Increased
III	Prepyloric	Increased
IV	High on lesser curve	Normal
V	Anywhere	Normal, NSAID-induced

- Hematemesis is more common than melena.

Now I will discuss Incidence, Etiology, Pathology and clinical features of duodenal ulcer. Management and complication part of a Gastric ulcer will be discussed later with duodenal ulcer, because the management for both condition is almost the same.

****

DUODENAL ULCER

Incidence

Duodenal ulcer is far more common in India than gastric ulcer. *The ratio of duodenal to gastric ulcer is approximately 20:1.* (IMP. POINT)

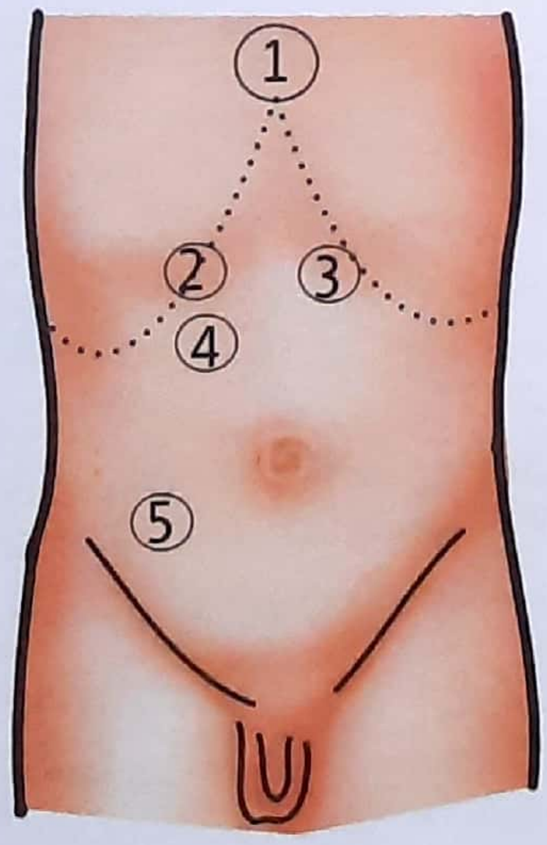

1. Hiatus hernia, reflux esophagitis
2. Cholecystitis
3. Gastric ulcer
4. Duodenal ulcer
5. Appendicitis

Figure 28.22: Typical site of pain

Males are more commonly affected than the females. The peak age of incidence of a duodenal ulcer is between 20-35 years. [10 to 15 years less than that of gastric ulcer]

Etiology

The important etiological factor are following.

1. *Elevated acid secretion:* This may occur due to:
   - Large parietal (oxyntic) cell mass than normal.
   - Excessive vagal or gastrin mediated secretion of acid.
2. *H.pylori:*
   It is now well accepted that H.pylori is a major ulcerogenic. (UPSC 07)
3. *Genetic factors:*
   Persons of blood group '**O**' are three times more likely to develop du**O**denal ulcer, than those belonging to other blood groups.
4. *Stress:*
   Emotional or physiological stress play an important role in development of ulcer.
5. *Smoking*
6. *Endocrine factor*
7. *Chronic liver diseases*
8. *Chronic lung disease*
9. *Chronic pancreatitis*
10. *Emotional factor*
11. *Diet & smoking*
12. *Decrease in bicarbonate production.*

Pathology

- In the duodenum, *the ulcer is almost always situated in the first part and most commonly on the anterior wall of duodenum* (MANY PGME). Chronic duodenal ulcer are usually smaller than chronic gastric ulcers.
- Average size is about 1 cm in diameter. These ulcer vary in shape. They may be circular, oval or cresentric.
- Multiple duodenal ulcer occur in 10% of cases. These are usually seen an. anterior and posterior surface wall facing each other, also known as *"Kissing ulcer"*. These kissing ulcers may produce considerable scarring and distortion of first part of duodenum, resulting in gastric outlet obstruction (GOO).
- Duodenal perforation, a life threatening condition, occurs *most frequently due to perforation of an ulcer situated on anterior wall of duodenum,* (MANY PGME) where as *bleeding is more common with ulcers on posterior wall of duodenum.* (MANY PGME)

KEY BOX 28.4

Comparison Of Gastric Ulcer and Duodenal Ulcer

Gastric ulcer	Duodenal ulcer
1. Age Usually around 50 years	• Patient usaaly between 20-35 years.
2. Incidence - Less common	• More common than gastric ulcer (ratio being 20:1)
3. No specific blood group	• More common in patient with blood group 'O'.
4. Periodicity - is less marked.	• Periodicity is more marked.
5. Pain : Pain is usually moderate, boring in nature Site: Mainly is epigastric region	• Pain is more severe and spasmodic in nature • Site : 'Duodenal point' (One inch below and medial to trans pyloric plane) (figure 28.22)
Relation with food :	
• Pain occurs almost immediately or any time up to 1.5 hours taking food after meal as food irritate ulcer	• Pain usually starts 2-2.5 hours after taking food
• Pain is not felt in empty stomach	• Pain is, very much felt in empty stomach- "hunger pain".
• Food does not relieve pain, infact it aggravates pains	• Food relieves pain.
6. Vomiting • Vomiting is present in about 50% of case	• Vomiting is rare
7. Appetite; is good, but patient is afraid to eat, because food irritates ulcer and increases pain	• Appetite is quite good and he eats frequently to avoid pain, as food acts as buffering agent and minimises pain
8. Weight loss (as patient avoids eating)	• Some gain in weight is expected, as the patient eats frequently to relieve hunger pains.
9. Hemorrhage- is less common than duodenal ulcer	• Hemorrhage is more common than in gastric ulcer
10. Hematemesis - is more common than melena	• Melena is more common than hematemesis
11. More likely to be malignant	• **They are rarely malignant** (NEET)
12. **Site of ulcer**	
Most commonly on lesser curvature.	• First part of duodenum (on anterior wall)

Clinical feature

1. Periodicity

Attacks usually last for several weeks with pain free interval of about 2-6 months. Attack usually appears in the spring and autumn.

2. Pain

(i) ***Site*** **:** In patients of duodenal ulcer the pain is usually present at "duodenal point". (see figure 28.22)

- Duodenal point: One inch below and right to the transpyloric plane in midclavicular line,

(ii) ***Relation with food:*** *Pain usually starts 2 to 2.5 hours after intake of food, when the food reaches the first part of duodenum* (Pain occurs of night).

(iii) ***Hunger pain:*** Pain is very much felt in empty stomach, because excess of acid is not being neutralized by food. Food may relieve pain, because it acts as buffering agent, hence *patient eats frequently and* may gains weight. *(UP 93)*

3. Vomiting

Vomiting is rare; unless pyloric stenosis/GOO complicates the process.

4. Appetite

Appetite is good and patients eat frequently to avoid pain.

5. Weight gain

As patient eat frequently, gain of weight is expected.

6. Hemorrhage

Hemorrhage is more common than in gastric ulcer. Melena is more common than hematemesis.

Investigation

1. Occult blood in stool

Occult blood in stomach can be detectable in almost all cases of active ulcer disease due to oozing of blood from the ulcer. In case of melena, the stool becomes black and tarry, as the blood, during its passage through the intestine, becomes digested and altered under the effect of digestive juice. *Tests for occult blood in stool should be able to detect amount between 10 to 50ml/day.* *(PGME)*

2. Tests for Gastric acidity

Test for gastric analysis is being disfavoured these days, because it lacks precise correlation with disease. Tests are also uncomfortable for the patients. The only indications for gastric analysis in a surgical patient are:-

(a) Post vagotomy:- To evaluate the success of operation

(b) To diagnose Zollinger - Ellison (ZE) syndrome

(c) To determine, whether the patient with an ulcer has achlorhydria.

Gastric acid analysis includes

- Basal acid out (BAO)
- Maximal acid output (MAO)
- Hollander's insulin test

Basal acid output (BAO)

Basal acid output is measurement of acid production by the resting (unstimulated) stomach under basal fasting condition. The basal acid output is raised considerably in duodenal ulcers.

Maximal acid output (MAO)

This is measure of gastric acid after stimulating the parietal cell by injecting pentagastrin (subcutaneous or intramuscular). 15 minutes samples are collected during subsequent hours.

NOTE: Histamine can be also used in place of pentagastrin

Hollandar's insulin test

The principle of this test is based on the fact that hypoglycemia caused by insulin induce direct vagal stimulus on the parietal cell mass. Insulin given to a patient who has had a vagotomy performed should result in no increase in acid production. So this test is of more value to assess the completeness of vagotomy done for peptic ulcer.

3. Radiological investigation

Barium meal X-ray is often diagnostic in peptic ulcer

- In case of a gastric ulcer a *niche or ulcer crater* *(PGME)* will be seen projecting from the smooth out line of the stomach. Ulcer niche is found on lesser curvature and a notch can be seen in greater curvature. The notch on greater curvature is as a result of spasm of smooth muscle of stomach. See fig 28.23.

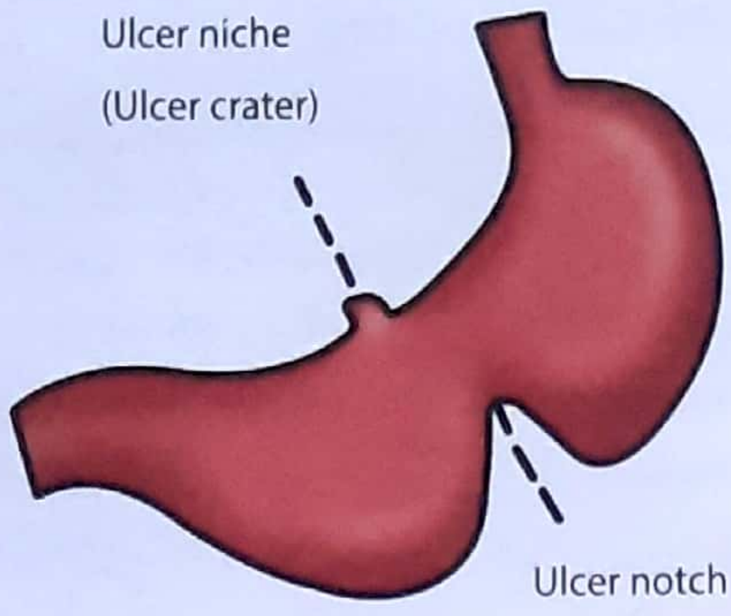

Figure 28.23: Ulcer niche/crater and Ulcer notch

- *Barium meal x-ray* also helps in differentiating between benign gastric ulcer (due to acid peptic disease) and malignant ulcer (carcinomatous ulcer). In benign ulcer a depression in lesser curvature is observed where as in a malignant ulcer filling defect that protrude in the stomach is detectable. (Please read details of this test in chapter 55; Diagnostic modalities) Figure 28.24

Crater means a large bowl shaped hollow (in stomach).

- In 75-80% cases, a duodenal ulcer can be diagnosed with accuracy by *Barium meal x-ray findings, most characteristic features are:*
  - (i) Duodenal bulb becomes rounded and full. *(PGME)*
  - (ii) Appearance of pylori stenosis and hour glass deformity of stomach are also evidence of presence of chronic duodenal ulcer and chronic gastric ulcer respectively. *(PGME)*
- Hour glass stomach deformity? See figure 28.38; page 439.

4. Esophago gastro duodenoscopy (OGD)

With the advent of an endoscope, OGD *has become investigation of choice for peptic ulcer disease. This investigation has greatly improved the diagnosis of peptic ulcer disease,* *(MANY PGME)*

A fibreoptic endoscope is passed in stomach through mouth to visualise in side of stomach, after spraying local anaesthetic to the pharynx.

Indication

(i) To diagnose a gastric or duodenal ulcer

(ii) Undiagnosed dyspepsia

(iii) To differentiate between a chronic peptic ulcer from a malignant ulcer

(iv) Erosive gastritis

(v) Esophageal varices, reflux esophagitis

(vi) For taking biopsy - To confirm the nature of ulcer, ie; (To differentiate between a benign and malignant ulcer).

5. Tests for H.Pylori

Test	Sensitivity/specificity (%)
Rapid urease	80-90/95-100
Histology	80-907 > 95
Culture	
Non invasive test	
Serology	> 80 / > 90
Urea breath test	> 90 / > 90
PCR	> 95

Figure 28.24: A large, benign-appearing gastric ulcer protrudes medially from the lesser curvature of the stomach (*arrow*), just above the gastric incisura

TREATMENT OF PEPTIC ULCER

Here we will discuss surgical treatments only. Medical treatment has been discussed earlier, those are:

- H_2 antagonist
- Antacids
- PPI

Among these drugs; PPI are the only option to reduce mortality in last decade in duodenal ulcer. PPI (Omeprazol and Pantoprozole) are most potent drugs. They should be taken 1-2 fours before meals.

A. Operations For Gastric Ulcer

Vast majority of peptic ulcers are treated medically, which has been discussed earlier in this chapter. Surgical treatment of uncomplicated peptic ulceration has decreased markedly since 1960 and now rarely performed; however description of operations used in treatment of peptic ulcer in still necessary because surgery is commonly performed for complicated non-healing ulcers.

Principle

In contrast with duodenal ulcer surgery, where in the main objective is to reduce duodenal acid exposure, in gastric ulcer surgery; the diseased tissue (part of stomach) is usually removed. It has the added advantage that malignancy can then be confidently excised as about 5-10% of all gastric ulcers are malignant.

Although levels of gastric acid secretion are not abnormally high in a gastric ulcer; yet acid is still a prerequisite and hence operations are aimed to lower acid secretion.

We can make a conclusion from above discussion that surgery for gastric ulcer can be broadly divided in 2 groups.

See and *understand flow chart in key box 28.5 and figure 28.25.*

1. Billroth I gastrectomy (PGME)

In case of benign gastric ulcer *Billroth I gastrectomy is still the operation of choice* (UP 94). In this operation partial gastrectomy is done including removal of the ulcer followed by gasto-duodenal anastomosis.

2. Billroth II gastrectomy

This is done when the ulcer is high and is situated at lesser curvature, and anastomosis between stomach and duodenum (gasto-duodenal anastomosis) is technically difficult.

In it, anastomosis is done between stomach and a jejunal loop (gastro-jejunal anastomosis). Duodenal end is closed by sutures (Fig. 28.25 and 28.29) This loop remains as a closed loop often known as blind loop (or afferent loop).

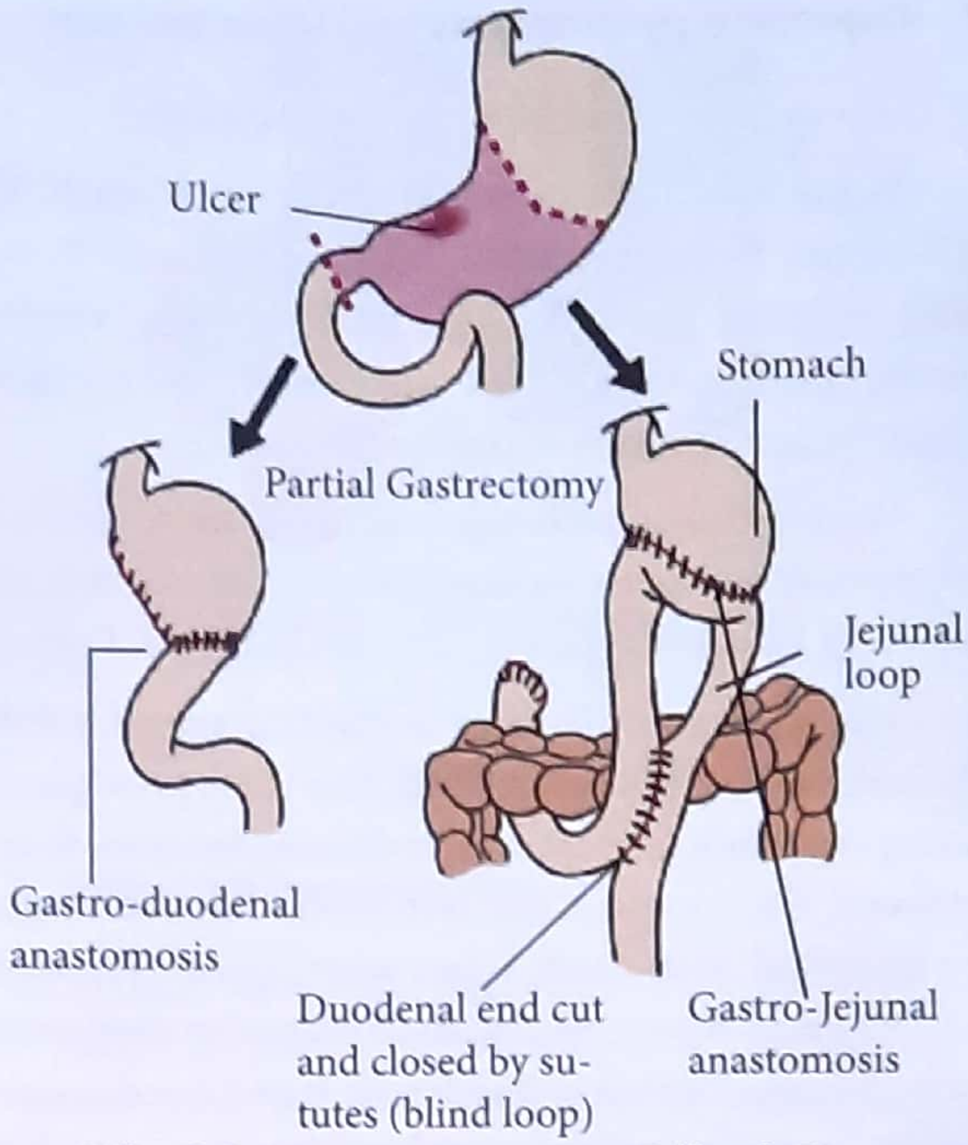

Figure 28.25: Types of Billroth gastrectomy (Note - pink shaded area is excised)

KEY BOX 28.5

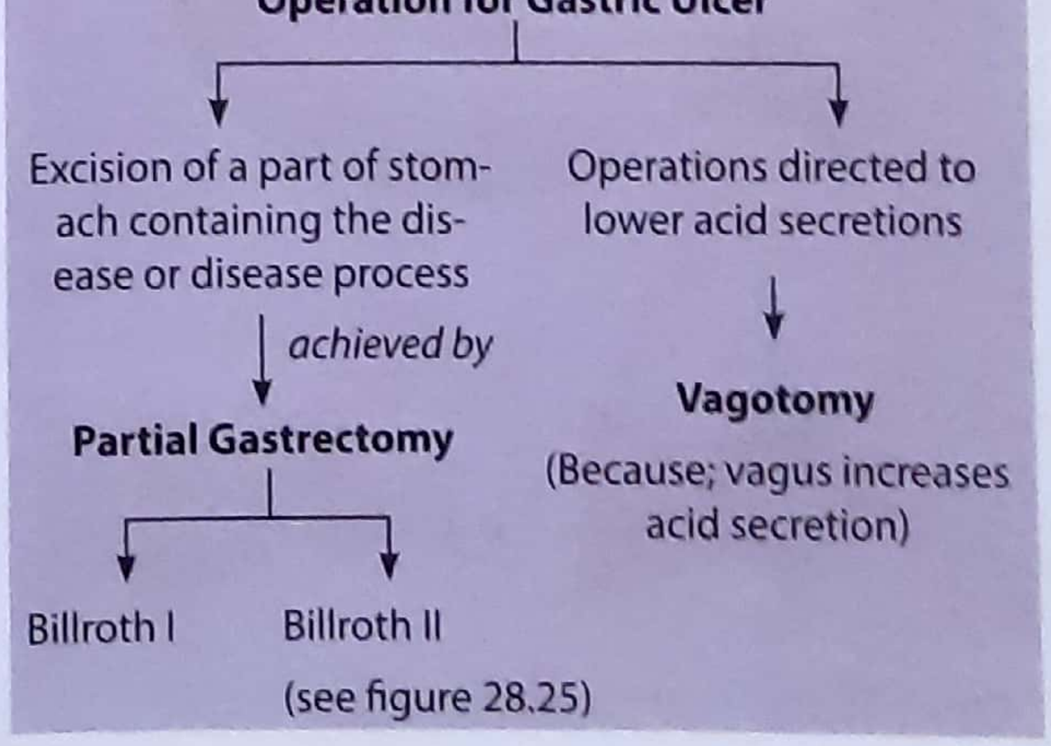

3. Vagotomy, pyloroplasty and Ulcer excision

Why is vagotomy done for peptic ulcer disease?

Vagus is the main nerve supplying the stomach. Vagus carries para-sympathetic fibers to stomach. It supplies stomach through *two trunks,* namely; anterior trunk, (anterior vagus or *left* vagus nerve) and posterior trunk (posterior vagus or *right* vagus nerve).

Vagus (parasympathetic) is secretomotor to stomach. It's stimulation causes increased motility of stomach and increased secretion of gastric juice rich in HCl and pepsin.

When vagotomy (cutting or dividing vagus) is done the secretion of HCl is decreased. This is the principle for doing vagotomy for peptic ulcer disease, but there is one problem, that;- vagus is also responsible for motor activity (motility) of stomach, hence after vagotomy motility of stomach is lost and gastric stasis occurs; so the passage of food from stomach to duodenum is decreased considerably. *For this a drainage procedure (operations) [to drain the food from stomach to forwards, commonly to jejunum] is done.* (Please read box 28.5 & see figure 28.31 on page no. 425 and 428 respectively).

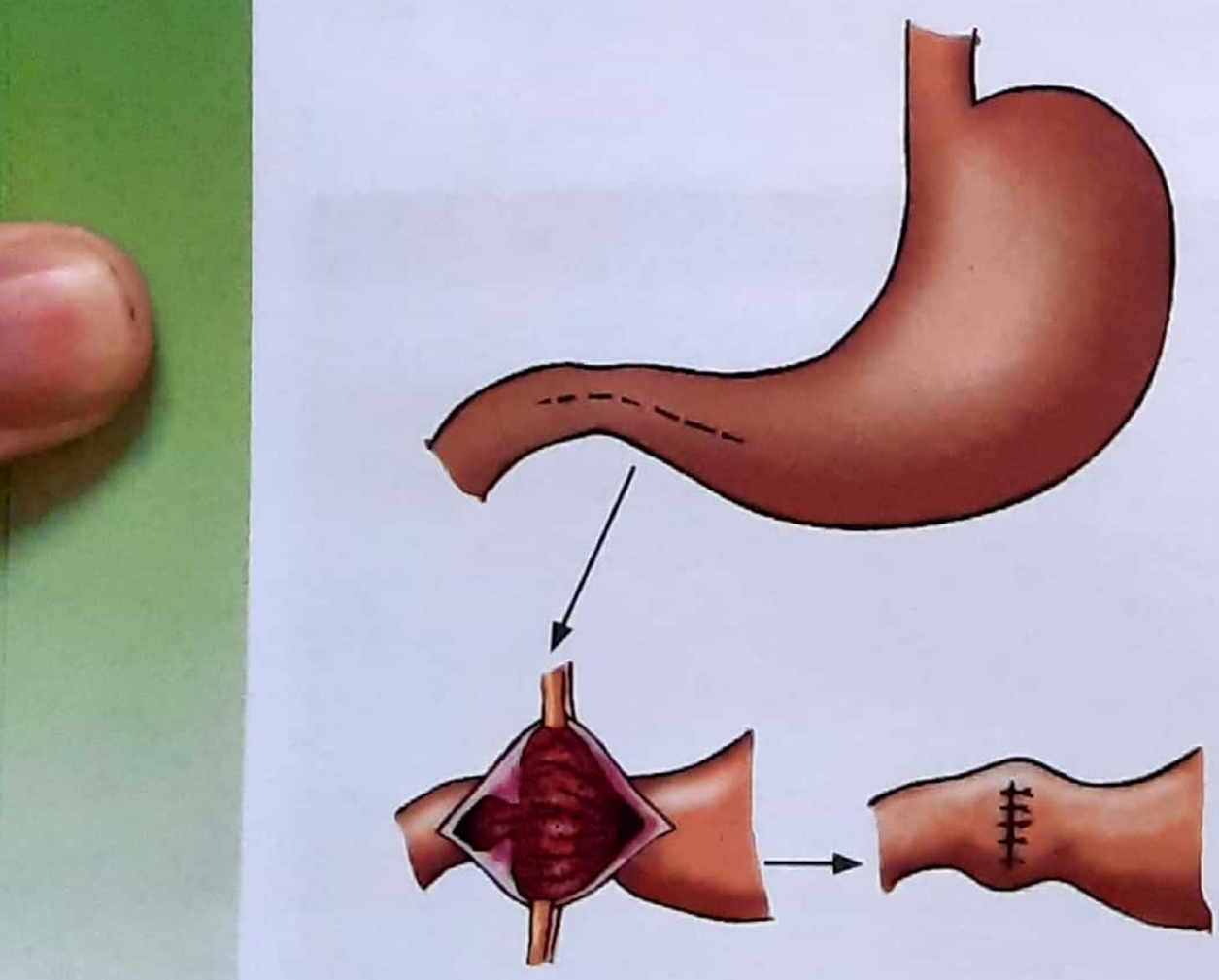

Figure 28.26: Heineke-mikulicz Pyloroplasty

Various drainage procedures

(a) Gastrojejunostomy

Posterior gastro-Jejunostomy* (ie; anastomosis between posterior surface of stomach and jejunum) is preferred because it provides dependent drainage of food content due to gravity action. Please see figure 28.50. page 449.

In gastrojejunostomy a small hole is made in stomach and also in jejunum; and cut ends of both is stitched side to side, hence providing direct connection between stomach and jejunum for drainage of food (gastro-Jejunostomy)

(b) Pyloroplasty

[Plasty means reconstruction] Pyloroplasty is widening of pyloric canal in order to facilitate free drainage of food. This can be achieved by dividing pyloric ring. This can be done by two methods:

(i) Heinke - Mikulicz's pyloroplasty

(ii) Finney's pyloroplasty

(i) ***Heineke-mikulicz pyloroplasty***: In this a longitudinal incision is made across the pylorus, which is then closed transversely. See fig: 28.26

(ii) ***Finney's pyloroplasty:*** In this procedure adjacent antrum and duodenum is approximated and an inverted 'U' incision is made, which is then sutured to give a wide gastro-duodenal anastomosis. See fig: 28.27. If you are unable to understand this then do not worry, there is all possibility that you would not be asked about this in exams.

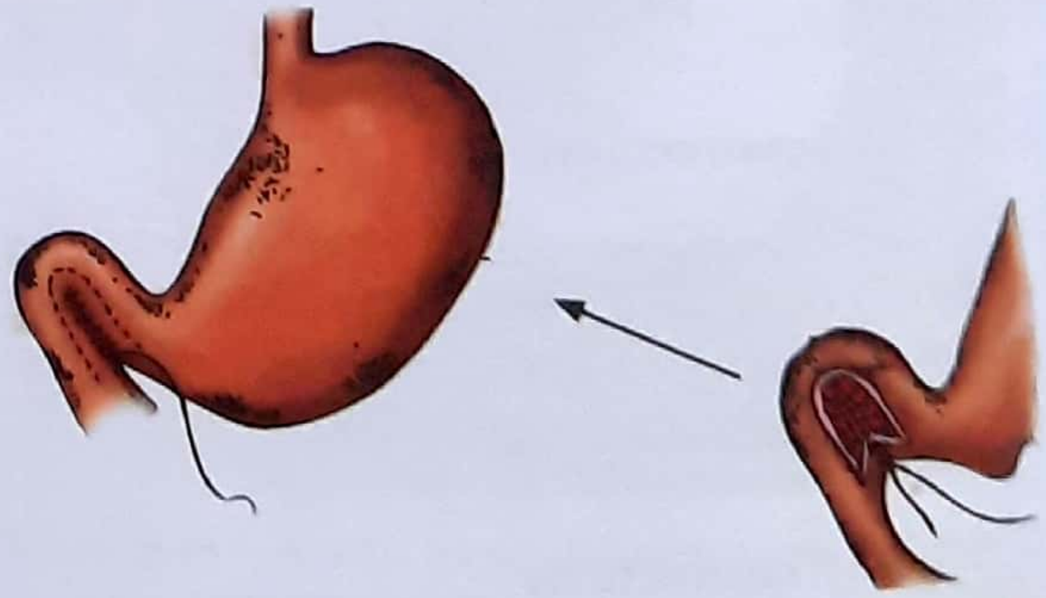

Figure 28.27: Finney's Pyloroplasty

(c) Truncal vagotomy and antrectomy

In this both the main trunk of vagus is divided [cut] and antrum of stomach is excised.

The *recurrence rate for ulceration after truncal vagotomy and antrectomy is very low and probably represents the gold standard with regard to recurrence* (AIIMS, UP 2002). This procedure causes maximal reduction in gastric acid secretion. (UPPGME, PGI 96).

(d) Highly selective vagotomy

(Discussed later) and gastric excision has similar rationale, but side effects are less with these procedure than truncal vagotomy and drainage.

Most operations for uncomplicated gastric ulcers are now of historical significance, because with the advent of potent pharmacological agents like PPI and H_2- antagonist, most of the gastric ulcers are treated conservatively (medically ie; by drugs only).

B. Operations For Duodenal Ulcer

Principle

Procedures devised for the treatment of duodenal ulcer have the common aim of excluding the damaging effect of acid to duodenum. This can be achieved by either diverting flow of acid away from the duodenum and/or reducing the secretion of acid from stomach.

AIM OF DUODENAL ULCER SURGERY

Diversion of gastric secretion (acid) away from duodenum	By reducing acidic secretion from stomach
Procedures	**Procedures**
• Billroth II gastrectomy • Gastro-jejunostomy	• Vagotomy and drainage procedure • Highly selective-vagotomy • Truncal vagotomy-and antrectomy

Now lets take above procedures one by one:

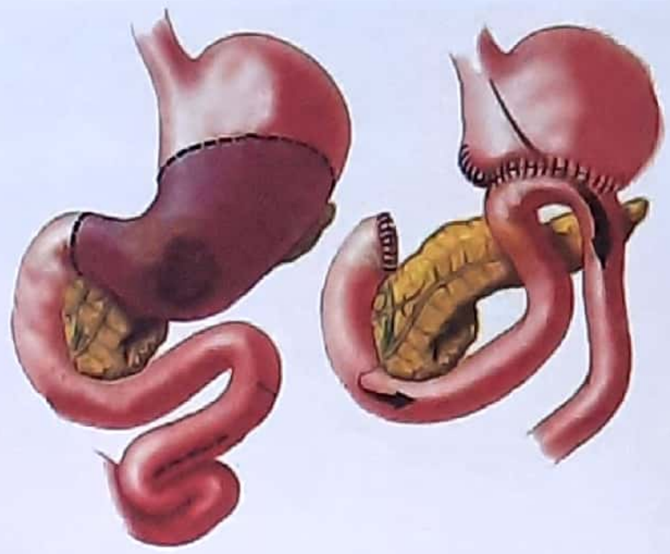

Figure 28.29: Billorth II gastrectomy

1. Billroth II gastrectomy

In this operation distal stomach and the duodenal bulb (which is the most common site) is excised and anastomosis is made, between stomach and jejunum (ie; Gastro jejunostomy) and duodenum is closed-by suturing. [Fig. 28.29] note dark red area is excised.

Recurrence of ulcer at stoma is uncommon but can occur, especially as this procedure is traditionally not combined with vagotomy.

Duodenal blow out occurs after Biliroth gastrectomy occurs most commonly on 4th day treated by Transcutaneous peritoneal drainage.(PGME)

2. Gastrojejunostomy

Gastrectomy is a major operative procedure anti morbidity and mortality associated with gastrectomy is significant, the use of Gastrojejunostomy alone in the treatment of duodenal ulcer was developed. In this procedure anas-

KEY BOX 28.6
Post gastrectomy complication [Mnemonic: ABCD VRS]
A-Anemia
B-Bile reflux
Bone diseases (vit. D metabolism affected)
C-Calcium deficiency
D-Dumping syndrome & Diarrhea
V-Vit deficiency (A, D, E, K, B_{12})
R- Roux-y Syndrome
S- Steatorrhea, gastric Stasis, gall Stones

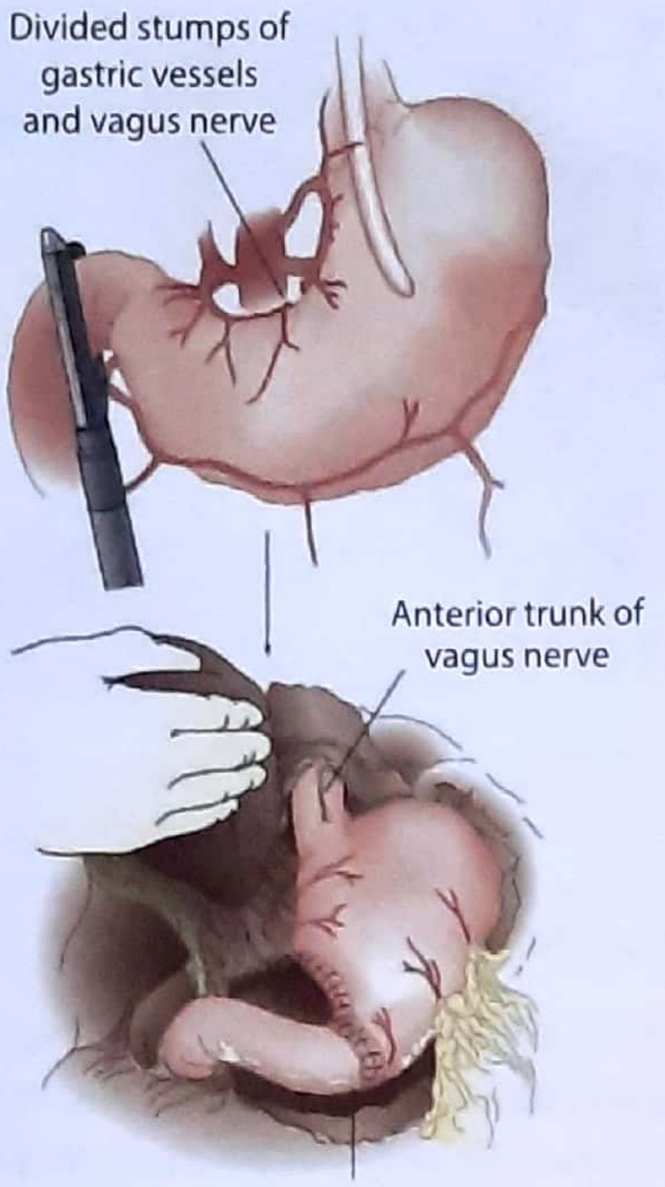

Figure 28.30: Hemigastrectomy with a Billroth I

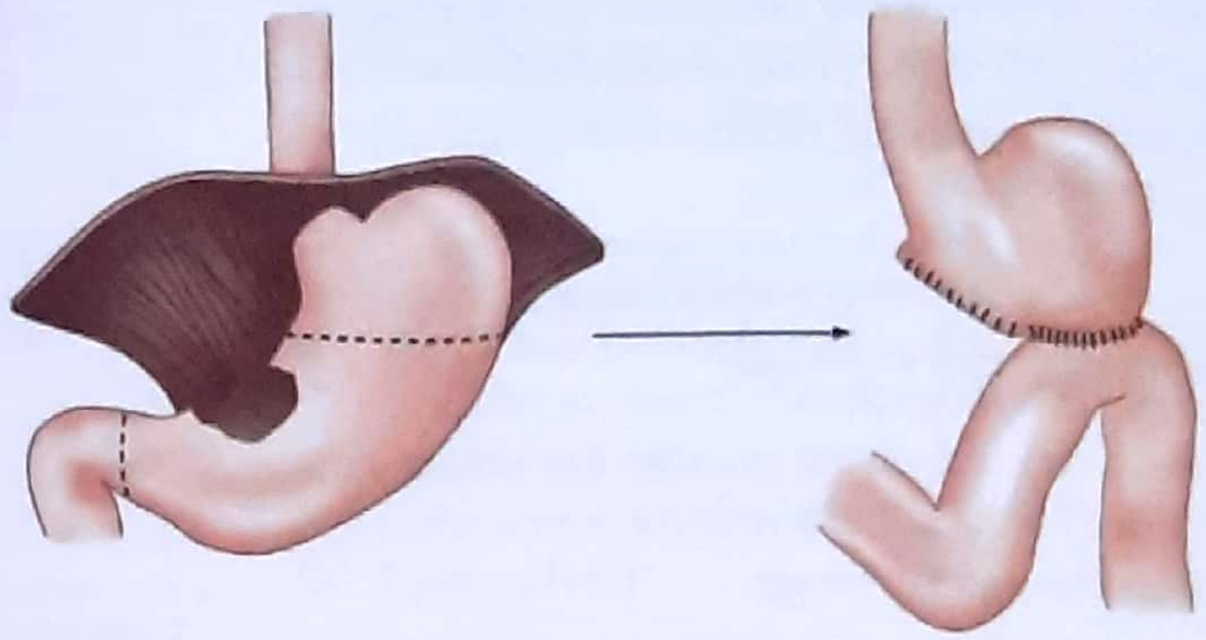

Figure 28.30.1: Subtotal gastrectomy with a Billroth II. Area between broken line in figure excised.

tomosis between stomach and jejunum is performed, which by passes the acid from going into duodenum (fig: 28.14). Reflux of alkali from small bowel (jejunal loop) into stomach reduces duodenal acid exposure and is often helpful in healing the ulcer.

3. Truncal vagotomy and drainage

Truncal vagotomy and drainage procedure has been discussed earlier in this chapter under the topic surgical treatment of gastric ulcer, (page 427)

- The operation of truncal vagotomy and drainage is substantially safer than gastrectomy.

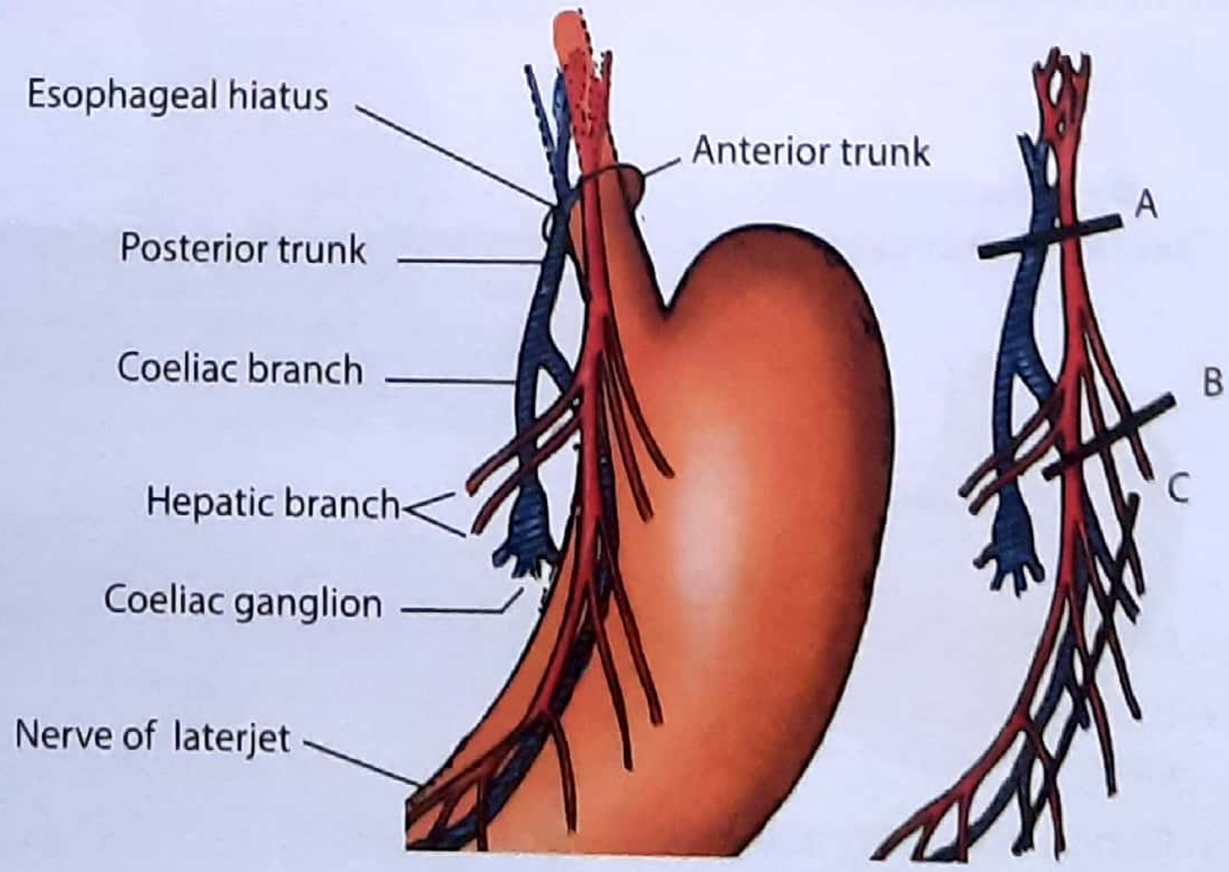

Figure 28.31: Vagal innervation of stomach. The three bars A, B, C indicate the level of transection in different vagotomy. A-truncal vagotomy; B - Selective vagotomy; C- Highly selective vagotomy

4. Highly selective vagotomy *(Parietal cell vagotomy)* (AI)

- This operation; *only denervates the parietal cell area of stomach,* which is responsible for acid secretion.
- In this operation **nerve of laterjet is identified and preserved,** (NEET) but all the fibres supplying proximal two-thirds of the stomach (parietal cell area) are divided. Please see figure 28.31 for understanding.
- Since Pyloric innervation is preserved due to preservation of nerve of laterjet, *gastric emptying is relatively unimpaired* and a drainage procedure is unnecessary. Hence chances of dumping syndrome is lowest . (UP 97)
- The recurrent ulceration rate is higher than that with truncal vagotomy.

5. Truncal vagotomy and antrectomy

In this operation in addition to a truncal vagotomy, the antrum of the stomach is removed, thus removing the source of gastrin production, remaining part of stomach is joined (anastomosed) to duodenum.

- The recurrence rate after this procedure is lowest among all (AIIMS 04, AI 02). Please see key box 28.7.

KEY BOX 28.7

Operation	Operative mortality (%)	Significant side-effects (%)	Recurrent ulceration (%)
Gastrectomy	1-2	20-40	1-4
Gastroenterostomy alone	<1	10-20	50
Truncal vagotomy & drainage	<1	10-20	2-7
Selective vagotomy & drainage	<1	10-20	5-10
Highly selective vagotomy	<0.2	<5	2-10
Truncal vagotomy & antrectomy	1	10-20	1

Comparison of various surgical procedure used for peptic ulcer disease.

RECAP: *We were discussing peptic ulcer surgery, but as every surgery is associated with some complication and after effects, we will now discuss it. ie; sequel of peptic ulcer surgery.*

*****

SEQUEL OF PEPTIC ULCER SURGERY

There are a number of sequel of peptic ulcer surgery, which include recurrent ulceration, small stomach syndrome, bilious vomiting, early and late dumping, diarrhea and malignant transformation.

These sequel principally follow from more destructive procedures that are, usually not done these days. Approximately 30% of patients, suffer a degree of dysfunction following peptic ulcer surgery and in about 5% of such patients the symptoms are severe. These are:

1. Recurrent ulceration

Recurrence of ulceration can occur after surgery, which is treated by PPI (Omeprazol) or H_2 antagonists (Ranitidine).

2. Gastro-jejuno-colic fistula

This may occur as a result of recurrent ulceration, when these ulcer penetrates and erode the transverse colon, (which lie very close to the gastrojejunal anastomosis made earlier for a peptic ulcer disease) Gastro-jejuno-colic fistula results.

Patient suffer from *diarrhoea* that is severe and follow every meal (TN 95). The fecal content of transverse colon can come in jejunum causing foul breath and patient may vomit formed feces. The chief factor in rapid deterioration of the patients condition is fouling of jejunum by colonic content; which disturbs the absorption of fluid and electrolytes resulting in dehydration and electrolyte imbalance.

Diagnosis is established by Barium enema (J & K 2001)

Treatment is operative after correcting the fluid and electrolyte imbalance, the fistula is resected, the colon is repaired and a high partial gastrectomy is performed.

3. Small stomach syndrome

Early satiety occurs in most of the patients, who have undergone surgery for peptic ulcer disease.

4. Alkaline reflux gastritis & Bilious vomiting

In a small number of patients following partial gastrectomy, reflux (backflow) of alkaline content in to stomach can occur (due to loss of pyloric sphincter), causing severe continuous burning pain. Vomiting is quite common.

Bile vomiting can occur, after any form of operation for peptic ulcer. Commonly the patient presents with vomiting of a mixture of food and bile, and sometimes only bile after a meal.

5. Dumping Syndrome (Cibal Syndrome)

NOTE: Dumping means rapid emptying

This is a condition; marked by sweating and weakness after eating, occurring in a patient who have **had gastric resection for peptic ulcer disease**. (NEET) There are two types of dumping syndrome. *Early dumping syndrome in which symptoms are presents as early as 20-30 minutes after a meal. In late dumping syndrome, symptoms appear* 2-3 *hours after a meal.* The exact cause of dumping syndrome is unknown, but *rapid emptying (dumping) of stomach content into small intestine is associated with clinical symptoms.* (NEET)

(a) Early dumping (Early Post-cibal syndrome)

- This form of dumping syndrome usually occurs with in 20-30 minutes after taking meal.
- It is more common after partial gastrectomy with Billroth II reconstruction (in which stomach content directly goes into jejunum).
- It occurs *because of rapid passage of food of high osmolarity, from stomach into jejunum.* (AI 99, UP 2000)
- Clinical feature include diarrhoea, vomiting.

Treatment

1. Dietary adjustment:- **small frequent food without liquids**. (NEET)
2. Long acting somatostatin analogue:- Octreotide has been shown to be highly effective. (PGME)
3. In <1% of cases, who fail to respond conservative therapy, operative intervention may become necessary.

(b) Late dumping (Late post-cibal syndrome)

- This form of dumping syndrome usually occurs 2-3 hours after a meal.
- The basic defect in this disorder is also rapid gastric emptying. However; it is related specifically to carbohydrate which is delivered rapidly into proximal intestine resulting in rapid hyperglycemia.
- Hyperglycemia triggers the release of large amount of insulin to control the rising blood sugar.
- As a result of large amount of insulin release profound hypoglycemia occurs and results in symptoms. This is known as late dumping syndrome.

Treatment

These patients should be advised to ingest frequent small meals and to reduce their carbohydrate intake. Please help your self with key box 28.8.

6. Nutritional consequences and metabolic disturbances (PGI 97)

- The *most common metabolic defect appearing following gastrectomy is anemia.*
- Anemia is greater in Billroth II resection, than Billroth-I resection. (PGI 81, AMU 85)
- Iron deficiency anemia is more common than vit. B deficiency anemia (megaloblastic anemia)

KEY BOX 28.8

Features early and late dumping

	Early	Late
• Incidence	5-10%	5%
• Relation of meals	Almost immediate (20-30 minutes)	2-3 hours after meal
• Duration of attack	30-40 minutes	30-40 minutes
• Relief	Lying down	Food intake
• Aggravated by	More food	Exercise
• Precipitating factor	Food, especially carbohydrate rich and liquid	As early dumping
• Major symptoms	Epigastric fullness, sweating, light headedness, tachycardia, colic, sometimes diarrhea	Tremor, faintness prostration

- This is seen principally after gastrectomy and mainly in women.
- Many patients develop steatorrhea.

7. Gall Stone formation

The development of gall stone is strongly associated with truncal vagotomy. Following truncal vagotomy the biliary tree, **as well** as the stomach is denervated leading to stasis of bile, and hence stone formation.

8. Post vagotomy syndrome

This include

- ***Post vagotomy diarrhea:*** Most patients following gastrectomy will complain of loose stool or increased bowel habit, but in most cases symptoms resolve over time. Best drug treatment is by octreotide (a somatostatin analogue).
- ***Post vagotomy gastric atony:*** This may cause gastric outlet obstruction and gastroparesis.
- ***Incomplete vagal transection:*** Either of the vagus nerve may be incompletely transected during truncal vagotomy, although the right vagus nerve is more commonly transected inadequately than the left. This predisposes the patient to the possible development of recurrent ulcer formation.

9. Intestinal obstruction

Two types of intestinal obstruction can occur following gastric operation:

(i) Due to internal herniation

(ii) Bolus (food) obstruction.

10. Malignant transformation

It has been confirmed from various studies that, there is a greater chances of formation of a carcinoma in gastric remnant following partial gastrectomy than normal individuals. *Such carcinoma may develop 10-15 years after partial gastrectomy.* (PGME)

11. Afferent and efferent loop syndrome

(i) Afferent loop syndrome

This may present acutely in the early post operative period following Billroth II gastrectomy. The closed loop (duodenal loop) is at imminent risk of perforation, the condition known as *duodenal stump blow out.* This can occur between 2-7 days after operation, but most frequently on 4th days. (AIIMS 87, AP 97, AIIMS 93).

(ii) Efferent Loop Syndrome

This is less common and usually occurs secondary to adhesion or internal herniation. Patients present with symptoms of proximal small bowel obstruction.

*****

COMPLICATIONS DUE TO PEPTIC ULCER DISEASE

A. Acute complications

- **Perforated peptic ulcer** (NEET) (2nd M/C complication)
- **Hematemesis and/or Melena** (NEET) (M/C complication of peptic ulcer disease)

B. Sub acute complication

- Sub-acute perforation
- Subphrenic abscess

C. Chronic complication

- **GOO (Gastric outlet obstruction)** (NEET) also known as pyloric stenosis
- Penetration in to neighbouring viscera, viz; pancreas leading to pancreatitis.
- Tea-pot stomach
- Hour-glass contracture of the stomach
- CA stomach

Now lets take each of them one by one.

A. Acute complications (of peptic ulcer)

1. Perforated peptic ulcer

Both duodenal and gastric ulcers can perforate. Perforation of a peptic ulcer is most acute complication of peptic ulcer. The *duodenal perforation is nine times more common than gastric perforation.* In India men are much more often affected than female. In western country female are affected more.

Site of Perforation

Perforation occurs most commonly, ***when an anteriorly placed duodenal ulcer*** (NEET, PGME, UP 01) erodes through the full thickness of the wall of duodenum, which result in spillage of peritoneal cavity by acid peptic secretion, bile and pancreatic juice. *Perforated duodenal ulcer is almost always situate on anterior wall of .first part of duodenum.* (NEET, AI 86, KERELA 86, MANY PGME)

Much less frequently, ulcer on the anterior surface of stomach usually near the lesser curvature of the pyloric antrum may perforate. A perforated gastric ulcer is mostly a malignant ulcer. *It is rare for a benign gastric ulcer to perforate.* (IMP. POINT)

Pathology

I. Stage of Peritonism

When a peptic ulcer perforates, acid peptic juice, bile and pancreatic juice leaks through a perforated ulcer and enters into general peritoneal cavity. This results in peritoneal irritation due to chemical peritonitis. Pain in this stage is very severe and patient often cries out of pain. *This stage lasts for 1-2 hours.*

II. Stage of reaction

Peritoneum reacts to this by secreting large amount of fluid, which dilutes the gastric juice, bile and pancreatic juice. As a result of which there occurs relief in pain for a short period. *This stage lasts for 4-12 hours.*

III. Stage of Peritonitis

At this stage, invasion of bacteria occurs resulting in diffused bacterial peritonitis. *This stage starts after 12 hours.*

Clinical feature

- Almost always the patient is a middle aged male.
- Acute perforation sometimes develop in a patient who is taking steroids or NSAIDs for arthritis. (MANY PGME)
- Soon after perforation, there occurs severe pain in epigastrium.
- On examination patient look pale and anxious.
- Skin is cold & clammy, *[clammy* means: wet & damp}
- Abdomen is distended and patient lies quietly in the bed.
- There is generalized tenderness with passage of time (ie;-pain all over the abdomen on palpating abdomen).
- There is board like rigidity on palpating abdomen (Board = wooden block, compare this with carom board)
- Liver dullness is masked, (escaping gas get collected under the diaphragm ie; highest point of abdominal cavity and masks liver dullness on percussion and on percussion; resonant percussion note is elicited..
- There is rise in pulse rate, temperature and gradual fall in blood pressure due to hypovolemic shock; secondary to 3rd space fluid loss.

Investigation

Diagnosis is made mainly on the basis of clinical examination. This can be confirmed by:

- *X-ray abdomen in erect posture; which shows gas under the diaphragm in most of the cases (80%).* (KERELA 94, MANY PGME)
- If the patient is too ill to stand, or due to some other reason cannot stand, a left lateral X-ray film is taken.
- It is important to note that, absence of gas under diaphragm on erect X-ray dose not rule out perforation. In *fact in about 20% cases no gas under diaphragm is seen on erect abdomen X-ray.*

Treatment

When ever a perforated ulcer is suspected, a nagogastric tube (Ryle's tube, fig: 28-32) is passed in stomach through nose and gastric contents aspirated. This reduces further contamination of the peritoneal cavity.

Figure 28.32: Ryle's tube

- After initial resuscitation, immediate exploration and repair of the perforation is the treatment in all most all the cases.

Operative procedure

(Graham's patch repair) (NEET)

The abdomen is opened with an upper paramedian/midline incision. All fluid, acidic secretion, bile & pancreatic juice is sucked by a suction machine, which is connected to a bottle via a tube. Abdominal cavity is washed by normal saline solution. The site of perforation is identified. The perforation is closed with interrupted sutures along with an *omental patch (Grahm's patch)* (KAR 05, SGPGI 05). In case of a gastric ulcer biopsy must be taken; as there is always a risk of malignancy. Now a days some surgeons are repairing duodenal perforation laparoscopically.

Please see figure 28.33.

2. Hematemesis and Melena

First of all, know some important term:-

Hematemesis : Vomiting mixed with blood, the origin of blood is from GIT.

Hemoptysis : Vomiting of blood, the origin of which is other than from GIT. ie; from trachea, lung, larynx (respiratory tract).

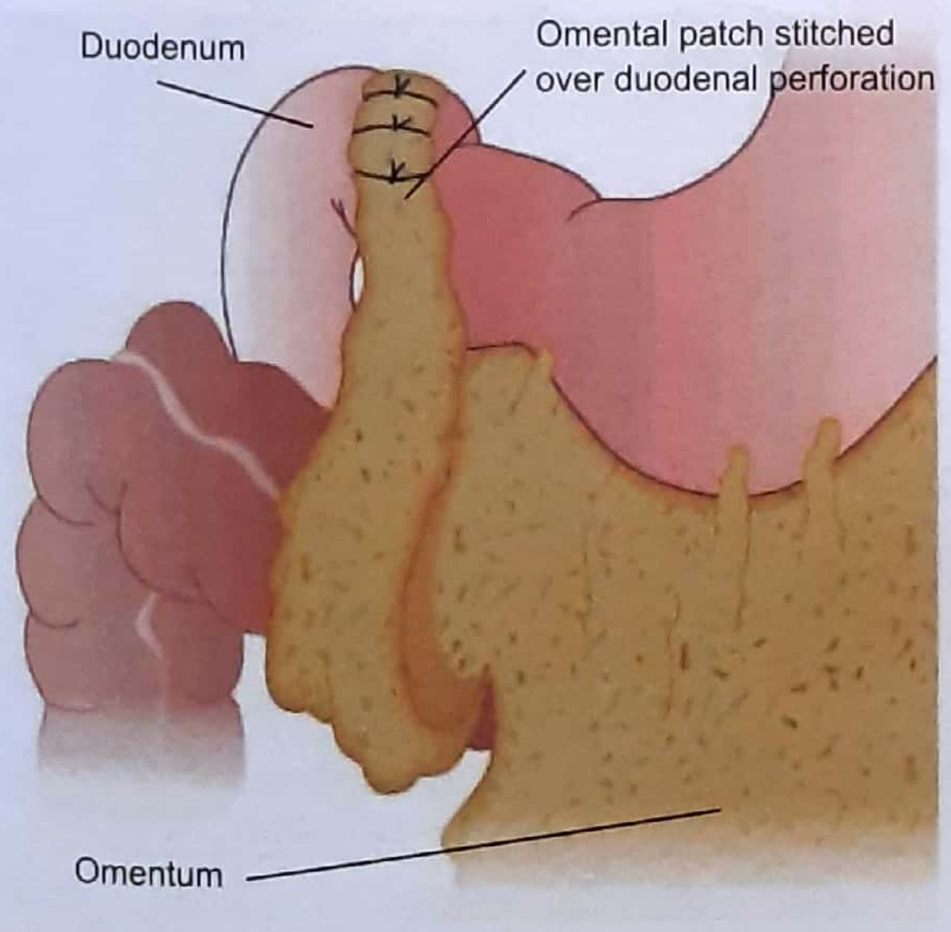

Figure 28.33: Graham's patch repair

If massive hemoptysis correction options are - (1) Lobectomy (2) Bronchoscopic laser cauterization (3) Bronchial artery embolization. (AIIMS MAY 17)

Melena : Passage of black or tarry coloured sticky stool with mucus because during the passage through the GIT, blood is digested and altered under the effect of digestive juice. *At least 50-100ml of blood is required to produce melena* (PGL 76, AIIMS 79).

Hematochezia : Passage of stools containing red ***fresh*** blood rather than tarry or black stool, cf. melena

- *Bleeding peptic ulcer is most common cause of Hematemesis,* followed by gastric erosion and esop-hageal varices (Please see key box 28.9 and figure 28.34; next page).
- Despite improvement in diagnosis and treatment modalities, an in hospital mortality of 5% can be excepted.
- Duodenal ulcer accounts for 33% of all upper GI bleed, where as for gastric ulcer this figure is 21%. Please once again see box 28.9.
- Hemorrhage is most common complication, in patients with peptic ulcer disease. (AI 90)
- In *case of gastric ulcer, bleeding* usually occurs from chronic ulcer near lesser curvature. A moderate size vessel often a branch of *left or right gastric artery* may be involved. It leads to abscess formation in lesser sac.
- In case of a bleeding duodenal ulcer the ulcer is often situated on the posterior wall and bleeding occurs *most commonly from a branch of gastro duodenal artery.* [NEET, PGL 88, 99, 2000, AL 99, UP 96, 04]

Investigation

Endoscopy is most useful method to diagnose upper G.I. bleeds. (JPGME MANY TIMES) *and is investigation of choice* (PGL 97) in diagnosing upper gastro intestinal bleeding. A fibre-optic endoscope is passed into stomach through mouth. By the help of this instrument, lower esophagus, whole stomach and duodenum is visualized. Fibre optic endoscopy helps to exclude bleeding from esophageal varices. If there is much blood present in the lumen of stomach. It can be aspirated through the lumen of endoscope.

Acute ulceration, erosion or Mallory-weiss tear may be detected by an endoscope. If blood is seen coming back in stomach through pylorus, duodenal ulcer is likely the cause and with the help of endoscope we can exactly locate the bleeding point and any bleeder, if present.

Management of hematemesis

(bleeding peptic ulcer)

Most patients (75%), with bleeding peptic ulcer can be successfully managed by medical means alone. Initial therapeutic efforts usually halt the bleeding. H blocker and proton pump inhibitor decrease the further risk of bleeding, *but have no effect on active bleeding.*

The **ABCDE** approach is first followed. *(AIIMS NOV. 16)*

ABCDE = Airway, Breathing, Circulation, Disability, Exposure

1. Blood should be transfused as early as possible.
2. Ryle's tube should be passed and cold saline stomach wash is started. It causes vasoconstriction and minimizes the bleeding.

Further management is discussed here:-

(1) Endoscopic therapy

Treatment administered through the endoscope can stop active bleeding or prevent rebleeding. Effective methods include:-

KEY BOX 28.9	
Cause of upper GI bleed	**%**
Ulcers	60
Esophageal	6
Gastric	21
Duodenal (M/C) *[AL 90]*	33
Erosion	26
Esophageal	13
Gastric	9
Duodenal	4
Mallory-weiss tear	4
Esophageal varices	4
Gastric carcinoma	0.5 mc tumor to present with UGIB
Dieulafoy's lesion	0.5
Others	5

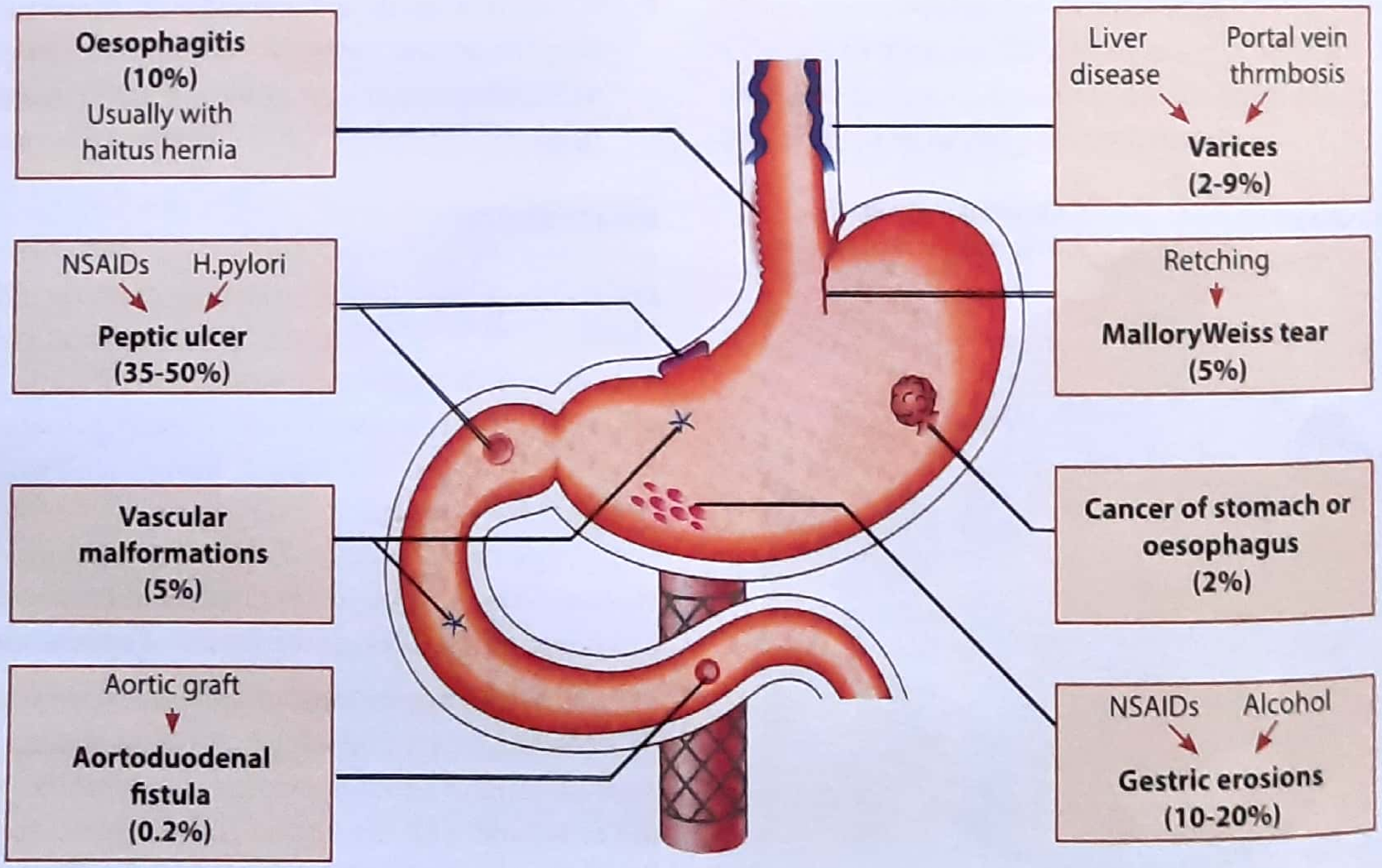

Figure 28.34: Causes of Hematemesis, read text for details

(i) Sclero therapy

Epinephrine is a potent vasoconstrictor, injecting 1 : 1000 epinephrine stops bleeding. Epinephrine may be combined with polidocanol (a sclerosing agent).

- Sclerotherapy is very popular method and success rate is about 80-90%. It is inexpensive and easy procedure.

Complication of endoscopic sclero therapy (PGME, PGI 98)

- Esophageal perforation
- Fibrosis
- Stricture
- Mediastinitis
- Pleural effusion
- Pulmonary stricture

(ii) Electro coagulation

This can be done by using a monopolar electro cautery.

(iii) Nd -YAG Laser

A circumferential coagulation of the ulcer base is carried' out. Laser does not require tissue contact. Laser device produce energy, which is absorbed by tissue causing coagulation of protein and tissue contraction. Risk of perforation of gut wall is about 1%. The major disadvantage of laser is that, it is costly and non portable, {for details on Nd-yag laser please read chapter 52}

(iv) Heater probe

(v) Clips

- Endoscopic therapy decreases blood transfusion requirement by about 50% and the rate of rebleed by about 75%.

(2) Surgical treatment of bleeding peptic ulcer

Indiation

1. Failure of endoscopic homeostasis/Recurrent hematemesis.
2. Patients with visible vessel at ulcer base on endoscopy.
3. Elderly patients with atherosclerosis.
4. A patient who requires more than six units of blood transfusion.

(Do you know one unit ie; bottle in lay man language of blood = 350ml of blood)

Surgical procedures

After laparotomy, first step is to make a pyloroplasty incision (incision on pyloric antrum), if preoperative endoscopic diagnosis of a duodenal ulcer is confirm, further treatment depends upon the location of ulcer:-

KEY BOX 28.9.1

Forrest classification of stigmata of recent hemorrhage on endoscopic examination of peptic ulcers and relative prevalence

STIGMATA OF RECENT HEMORRHAGE	FORREST CLASSIFICATION	PREVALENCE	RISK OF REBLEEDING
Active bleeding			
Active spurting	IA	10%	90%
Active oozing	IB	10%	10%-20%
Recent hemorrhage			
Nonbleeding, visible vessel	IIA	25%	50%
Adherent clot	IIB	10%	25%-30%
Flat pigmented spot	IIC	10	5%-10%
No signs of hemorrhage			
Clean-based ulcer	III	35%	3%-5%

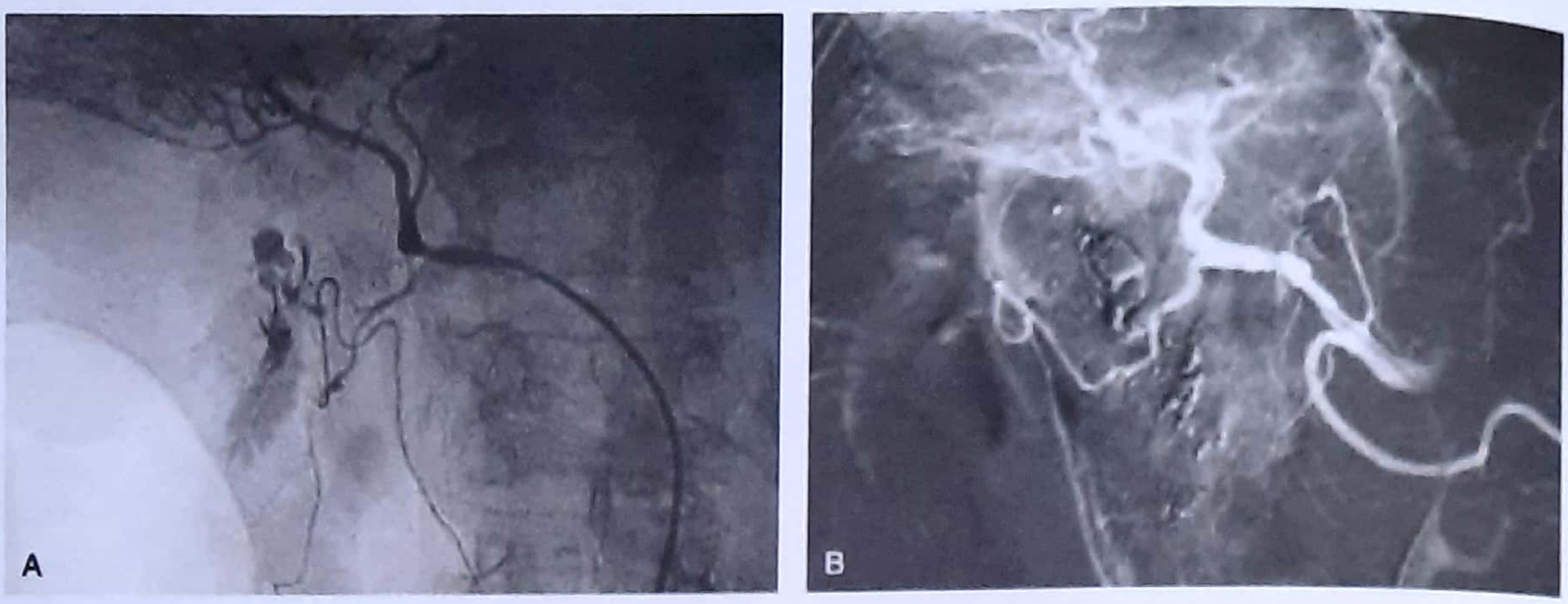

Figure 28.35: Endovascular control of a bleeding duodenal ulcer. (A) An angiogram is obtained, which shows extravasation from a branch off of the gastroduodenal artery. (B) A completion angiogram after glue embolization of the vessel shows resolution of the bleed with preservation of flow through the gastroduodenal artery.

(i) For ulcer located on anterior wall of duodenum

- If on inspection after, opening the stomach and duodenum (by pyloroplasty incision), a duodenal ulcer is found, the bleeding vessel is suture ligated (tied by a suture; to stop bleeding) and duodenum and antrum is inspected for additional ulcers.
- The pyloroplasty incision is then closed and a truncal vagotomy is done. Vagotomy is done to reduce the secretion of acid.

(ii) For ulcer located on posterior wall of duodenum

- Billroth II gastrectomy is performed, since this uncommon ulcer is especially prone to re-bleed.

(iii) For Gastric ulcer

- These should be dealt with either *gastrectomy or vagotomy + pyloroplasy.*
- If a bleeding vessel is identified on opening stomach it should be under run by sutures.

Here we finish acute complications of peptic ulcer disease, now lets discuss sub-acute and chronic complications of peptic ulcer disease respectively.

B. Sub acute complication (of peptic ulcer)

1. Sub-acute perforation

If a duodenal perforation is very small and if it occurs when the stomach is empty; the peritoneal irritation & reaction are localized with mild feature of general peritoneal irritation.

A small amount of fluid may track down the right paracolic gutter, producing pain and tenderness in right iliac fossa simulating appendicitis.

2. Residual Abscess (sub-phrenic abscess)

Subacute perforation or leaking perforation or chronic perforation may cause residual abscess formation. Most common site being subphrenic space.

RECAP: *Till now we have discuss Acute & Sub-acute complications of peptic ulcer disease. Now lets discuss chronic complications due to peptic ulcer disease*

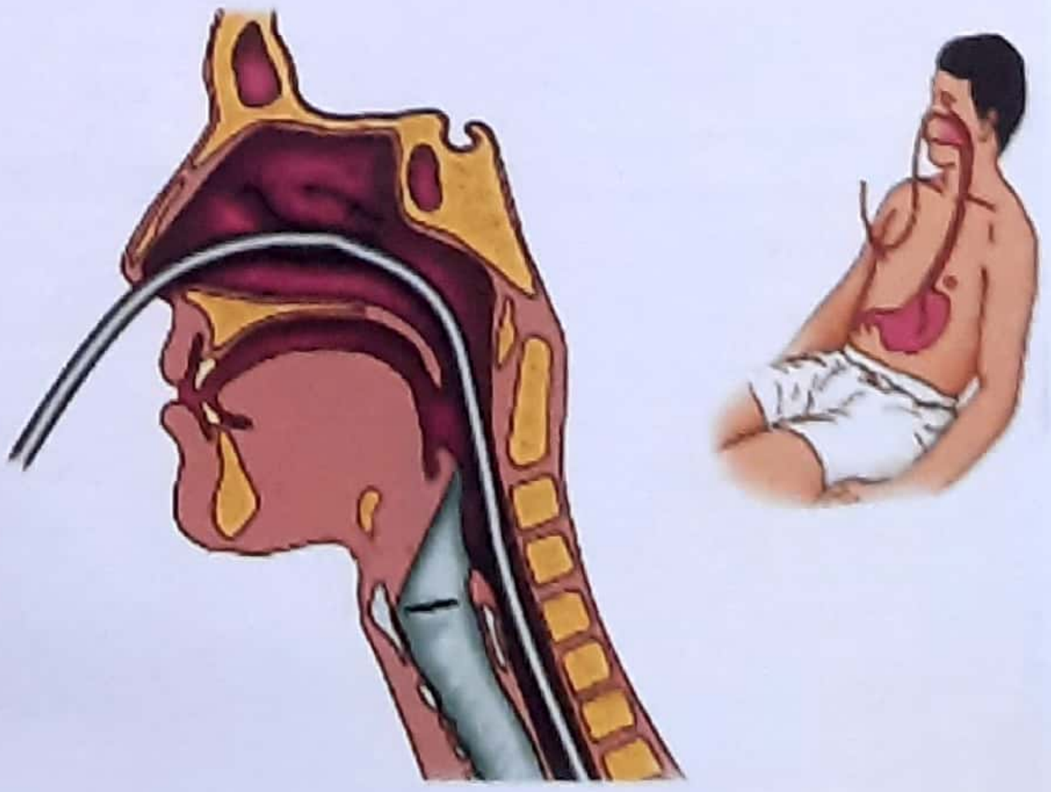

Figure 28.36: Ryle's tube placement

C. Chronic Complication (of peptic ulcer)

1. Gastric Outlet Obstruction (GOO) [Pyloric stenosis]

As the name suggests there is obstruction at the outlet of the stomach (ie; at pylorus). The two common cause of gastric outlet obstruction;- are gastric cancer and pyloric stenosis secondary to chronic peptic ulceration.

- Now with the decrease in incidence of chronic peptic ulceration, due to advent of potent medical treatment, such 'as proton pump inhibitors (PPI) and H2 antagonist; *gastric malignancy is the most common cause of* ***GOO.*** *(PGME MANY TIMES)*
- The term pyloric stenosis is a misnomer. The stenosis is seldom at pylorus. *Actually it is duodenal stenosis, in the first part of the duodenum* *(AIMS 93, AI 02)* caused by extensive fibrosis of the duodenal wall due to a chronic peptic ulcer disease.
- Most common cause of duedenal obstruction in adults is Ca. pancreas.

Clinical feature

1. *Vomiting*

Because food can not passed beyond first part of duodenum (due to pyloric stenosis), vomiting is an important feature. It is;

(i) Projectile

(ii) Copious (large amount)

(iii) Totally lacking of bile, because obstruction is above proximal to 2nd part of duodenum, where common bile duct opens.

(iv) It often contains food stuffs often taken several days back.

2. *Abdominal distension*

There occurs distention in the upper part of abdomen. Abdominal distension disappears after copious vomiting. Patient often complains of sensation of fullness in abdomen.

3. *Pain*

There is certain change in characteristics of pain of pre-existing ulcer. It looses periodicity. It looses its definite relationship with food. The intensity of pain is also diminished.

Examination (of abdomen)

1. *Visible Peristaltic* waves passing from left to right can be observed.
2. *A Succussion splash* is often heard on shaking the patient and by keeping the clinician's ear very near to patient's abdomen. This is due to presence of retained fluid and gas with in stomach.

* One other clinical condition, where succussion splash is found; is hydro-thorax.

Metabolic effects of GOO *(AIIMS 84, BHU 88, AIIMS 98, UP 04)*

- Hypochloremia
- Hyponatremia
- Hypokalemia
- Metabolic alkalosis
- Paradoxical aciduria
- Alkalosis lead to a lowering of circulating ionized calcium, and tetany can occur.

FLOW CHART OF EFFECT OF GOO

Gastric out let obstruction
(due to chronic duodenal ulcer)
↓
Vomiting
Loss of H^+ and Cl^- ion
↓
Hypochloremic metabolic alkalosis
↓
Loss of HCl with Na^+
↓
Hyponatremia and dehydration
↓
In order to retain Na^+; the K^+ and H^+ ion are excreted in preference

↓	↓
Loss of K^+	Loss of H^+ in urine
↓	↓
Hypokalemia *(BHU 88)*	*Aciduria (Paradoxical)*

- However is recent years the most common cause of gastric outlet obstruction is gastric cancer. In this circumstances the metabolic changes are different from those of GOO caused by chronic duodenal ulcer, because of relative hypochlorhydria found in patient with gastric cancer.

Investigation

1. Saline Loading test

This is a easy test. After passing Ryle's tube in stomach the gastric contents are aspirated. Now the stomach is loaded, by pushing 750 ml of normal saline through Ryle's tube. After 45 minutes saline is aspirated, If the aspirated amount is more than 450 ml, it is suggestive of GOO.

2. Barium-meal X-ray

(a) Largely dilated stomach can be seen. (In long standing cases with GOO, the stomach may enlarge and may reach up to left iliac fossa)

(b) Presence of barium in stomach even after 6 hours of a Ba meal is suggestive of GOO, because normally Ba disappears from stomach within 2½ to 3 hours after a Barium meal. This delay in evacuation of Barium strongly suggests GOO.

Please see figure 28.37.

3. Gastroscopy

(It is visualization of stomach by an endoscope)

- In case of GOO, an endoscope will not enter into the duodenum due to pyloric stenosis.
- It is also helpful is detecting malignancy of stomach. and taking biopsy at the same time. (Figure 28.46, page 447)

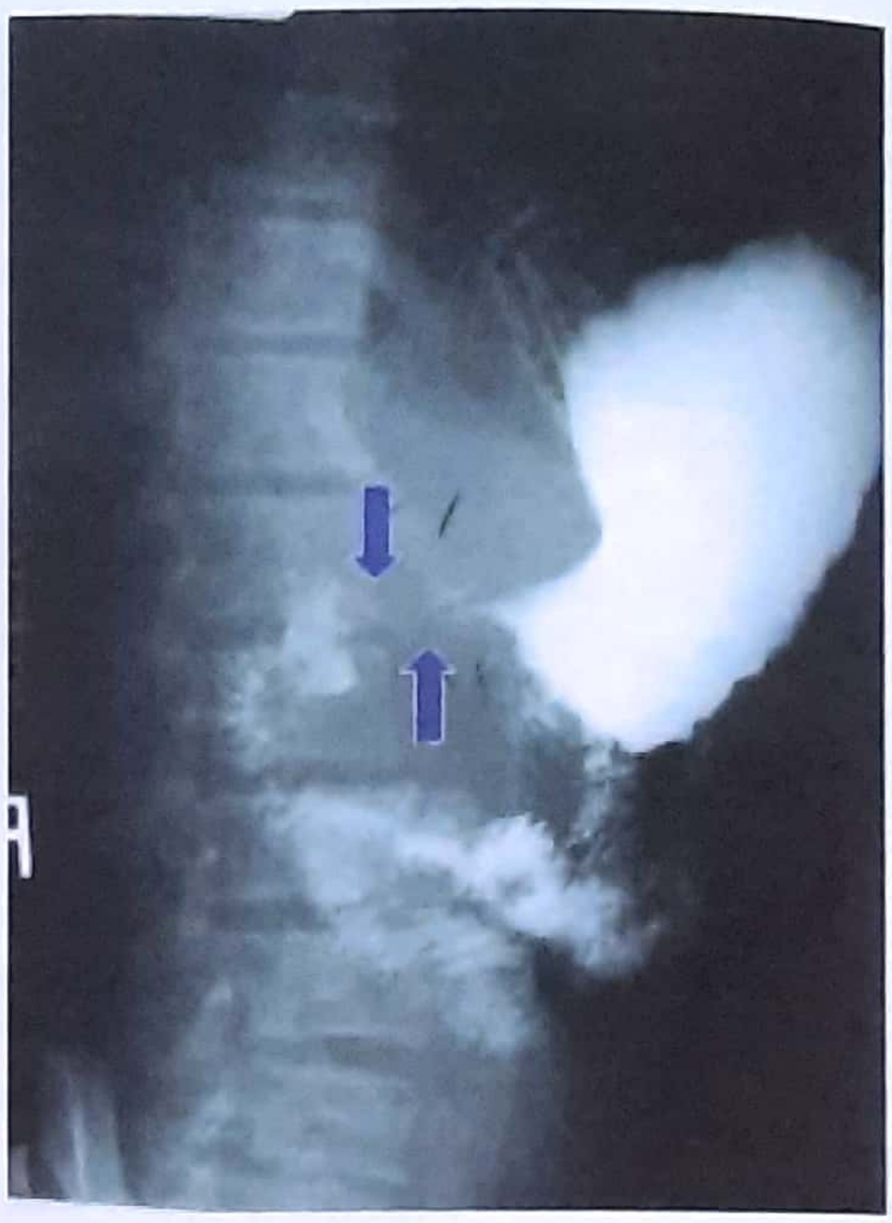

Figure 28.37: Gastric outlet obstruction

Treatment

Steps are described

1. *Correction of dehydration and electrolyte imbalance:* Patients with gastric outlet obstruction are often dehydrated and their electrolytes are depleted. Treatment involves replacement of water and NaCl by infusing isotonic saline (normal saline) solution. KC1 supplementation is then started.
2. *Blood transfusion:* In anemic patients, blood should be transfused.
3. *Drugs:*. PPI and H, blocker should be given
4. ***Surgical treatment***

   - Early cases may benefited by conservative treatment, which includes Ryle's tube aspiration of gastric content for 5-7 days. See fig. 28.32.
   - Traditionally, severe cases are treated surgically
   - *Surgical treatment may consist of a truncal vagotomy or highly selective vagotomy with a drainage procedure* [Posterior Gastro-jejunostomy] (KERELA 89).
   - If cause of *GOO is due to gastric cancer, then high anterior gastro-jejunostomy should be done.*

NOTE: Though pylorus is greatly fibrosed and scarred, hence pyloroplasty is not recommended, and there is all chances of failure of procedure (because of marked fibrosis).

5. *Endoscopic treatment:* Endoscopic treatment with balloon dilatation of narrowed pyloric canal and first part of duodenum can be tried in early cases. The main complication to this is perforation in case of over dilatation.

RECAP: *We were discussing GOO -an important chronic complication of peptic ulcer disease, now we will discuss an other chronic complication-that is penetration into neighbouring viscera, Tea pot stomach, Hour glass deformity & CA of Stomach.*

2. Penetration into neighbouring viscera

Penetration to pancreas from a posteriorly placed gastric or duodenal ulcer may take place, which may lead to pancreatitis. In this situation pain changes it's character. Pain often radiates to back.

3. Tea pot stomach (hand bag deformity)

A long standing gastric ulcer at lesser curvature, causes shorting of the lesser curvature due to fibrosis. Such stomach resembles a tea pot or a hand bag. This produces stagnation of food and may mimic in many ways the symptoms of pyloric stenosis.

Treatment

Billroth I gastrectomy with gastroduodenal anastomosis.

4. Hour-glass Stomach

Hour glass stomach occurs due to cicatricial contracture around a saddle shaped lesser curvature ulcer. In extreme cases the stomach is divided into two compartments connected through a narrow channel (Figure 28.38).

Barium meal X-ray is quite characteristic and diagnostic. It may be confused with pyloric stenosis when second pouch of stomach fails to fill with barium.

Treatment

Billroth I gastroduodenal anastomosis.

5. Carcinoma

Incidence of malignant change in gastric ulcer is not definitely known. An incidence of about 2% has been estimated. *(AIIMS 91)*

****

CARCINOMA OF THE STOMACH

The stomach is a common site for cancer. Carcinoma of stomach is a major cause of cancer mortality world wide.

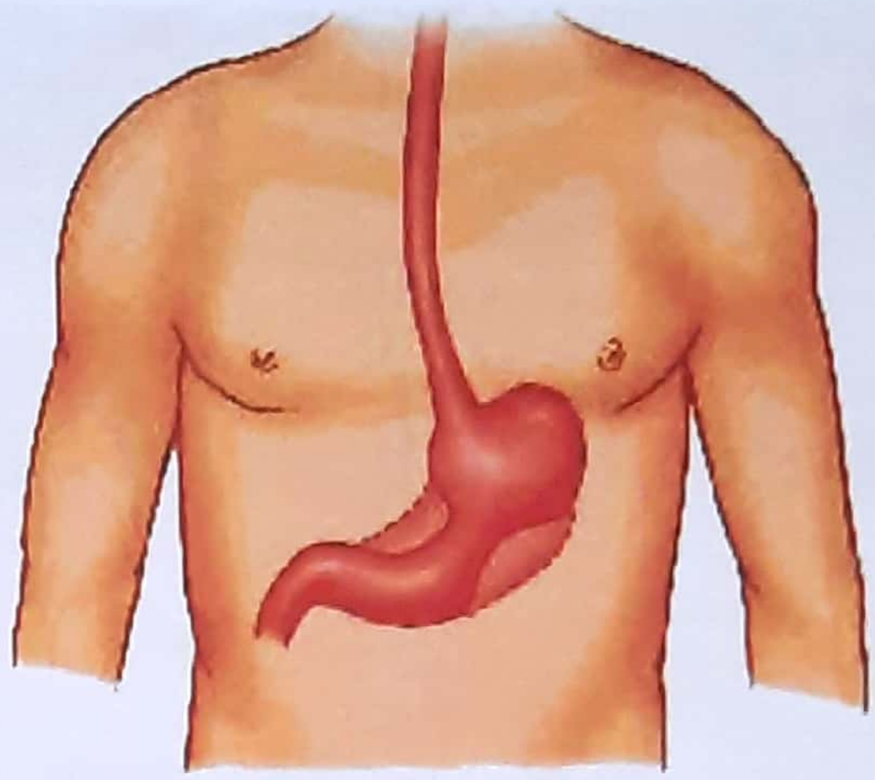

Figure 28.38: Hour glass stomach

Its prognosis is poor, and cure rate is only 5-10% at the time of presentation. Gastric cancer is thought to be an environmental disease and is actually a curable disease, if diagnosed early and treated adequately.

Incidence

There is marked variations in the incidence of stomach cancer world wide. It is widely prevalent in countries like China, Japan, Chile. The incidence of gastric cancer is continuing to fall in UK and USA. Though this decrease is mostly for carcinoma located is body and distal stomach, while an increase in the incidence of proximal gastric carcinoma (esophago-gastric junction) has been observed; however overall there is decrease in it's incidence world wide.

Carcinoma of distal stomach and body of the stomach is most common in low socioeconomic groups, *(NEET)* where as the increase in proximal gastric cancer seems to affect primarily higher socioeconomic group.

Etiology

Friends this is a very important PGMEE topic, have a closely look on it, now (ie. in final Prof.) So that, it will become easier, while preparing it for PGMEE, next year.

1. Environmental and dietary factors

- Risk increases with a diet low in animal fat & protein.

KEY BOX 28.10
Decreased risk of gastric cancer is seen with
• Aspirin intake
• Diet rich in fresh food, and green vegetables
• Animal fat and protein
• Vit C and E-antioxidant

- Nitrites derived from nitrates in drinking water, food and food preservatives may form nitrosamine and nitrosamides (aromatic aminocompounds).
- Smoked and salted food, spirit (alcohol), smoking and dust ingestion increase risk of gastric cancer.

NOTE: Increased intake of fresh fruits, vegetables Vit C, Vit E & antioxidants, animal fat are protective agents. (Key box 28.10)

2. Pre cancerous conditions

(AI90, KERALA 04, PGI97, PGI2000, PG01, AI 02, 95, AIIMS 97

Atrophic Gastritis

Both type A (Autoimmune) and type B (associated with H.pylori Bacteria) gastritis are associated with increased risk for gastric cancer.

Gastric polyps

Risk of malignant transformation is high in adenomatous polyp (38%). Familial *adenomatous polyposis is* 10 times more likely to develop adenocarcinoma.

Please see figure 28.39.

Pernicious anemia

Patients with pernicious anemia has increased risk of about 4-6 folds of developing gastric carcinoma, when compared to general population. Cancer involves usually fundus in this case.

Hypogammaglobulinemia : It has 50 folds increased risk of developing gastric carcinoma.

Intestinal metaplasia and dysplasia

Menetrier's disease

Gastric ulcer : Incidence of malignancy is about 2%.

H. Pylori infection

As mentioned earlier H. Pylori seems to be principally associated with carcinoma of body, stomach and distal stomach rather than proximal stomach.

Because H.Pylori is associated with gastritis, gastric atrophy and intestinal metaplasia hence association with malignancy is not surprising. *(TN 03, PGME)*

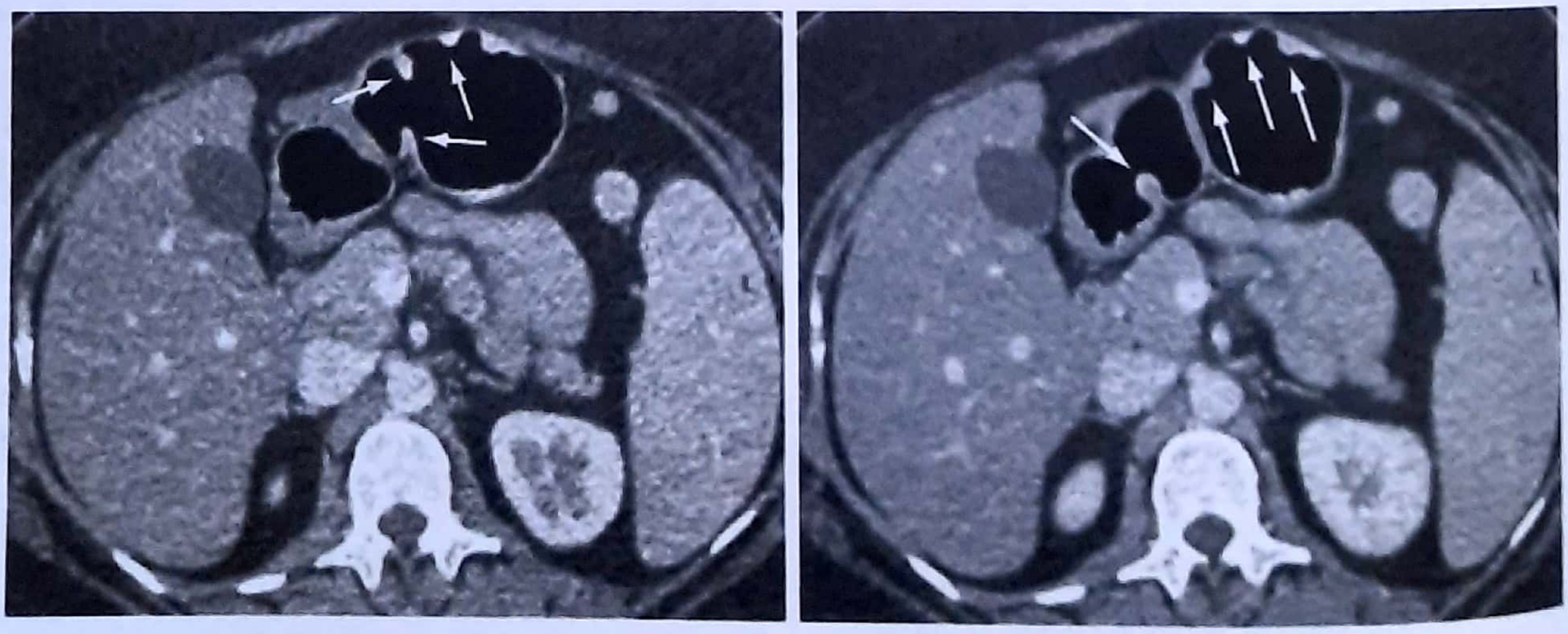

Figure 28.39: Computed tomography scan of fundic gland polyps

KEY BOX 28.11
Risk factor for CA-Stomach : [ABCD ef GGGHI]
A-Atrophic gastritis
Anemia (pernicious anaemia) *(NEET)*
B- Blood group A
C- Cigarette smoking
D- Dust ingestion
G-Gastric ulcer/ Gastric polyp
Genetic factor
Gastrectomy (partial)
H-H.Pylori
I- Intestinal metaplasia
Ingestion of spirit & nitrite

KEY BOX 28.11.1
Factors associated with increased risk for developing stomach cancer
Nutritional
Low fat or protein consumption
Salted meat or fish
High nitrate consumption
Obesity
High complex carbohydrate consumption
Environmental
Poor food preparation (smoked, salted)
Lack of refrigeration
Poor drinking water (e.g., contaminated well water)
Smoking and alcohol
Social
Low socioeconomic class
Medical
Prior gastric surgery
Helicobacter pylori and Epstein-Barr virus infection
Hereditary predisposition
Prior abdominal irradiation
Atrophic gastritis
Adenomatous polyps
Other
Male sex

KEY BOX 28.11.2	
Lauren classification system for gastric cancer	
INTESTINAL	**DIFFUSE**
Environmental	Familial
Gastric atrophy, intestinal metaplasia	Blood type A
Men > women	Women > men
Increasing incidence with age	Younger age group
Gland formation	Poorly differentiated, signet ring cells
Hematogenous spread	Transmural, lymphatic spread
Microsatellite instability	Decreased E-cadherin
APC gene mutations	
p53, p16 inactivation	*p53, p16* inactivation
APC, Adenomatous polyposis coli	

3. Genetic and familial factor

- First degree relatives of patients with gastric carcinoma has two to three fold increased risk of developing the disease.
- *Genetic factors:* Most commonly associated genetic abnormality seen with gastric carcinoma are :
- **Deletion or suppression of P^{53} gene.** *(NEET)*
- Over expression of COX-2.
- AKT1 amplification *(NEET)*
- Patients with blood group '**A**' have more chances of developing c'**A**'rcinoma stomach [remember blood group 'O' associated with increased incidence of du 'O' denal ulcer *(UP 2002)*. Please see box 28.11 & 28.11.1.

Pathology

Most common type is adenocarcinoma *(AI 2011,MANY PGME)*

The most *useful classification of gastric cancer is Lauren's classification.*

LAUREN'S CLASSIFICATION

This classification divides gastric cancer principally in following forms:

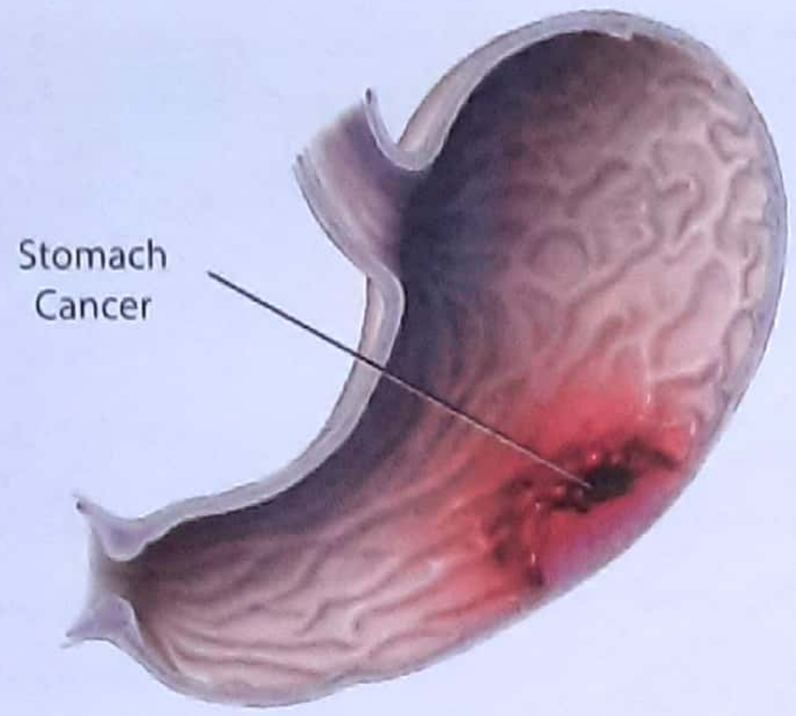

Figure 28.40: Carcinoma of stomach

1. Intestinal gastric cancer

This usually arises from an area of intestinal metaplasia. This type of gastric cancer is polypoidal tumours or ulcer.

NOTE: polypoidal means polyp like i.e.; tennis racket like figure 28.40.

2. Diffused gastric cancer

Infiltrates deeply into stomach without forming obvious mass lesion. It spreads widely is stomach wall. This has a much worse prognosis.

3. Mixed lesion

A small proportion of gastric cancers are of mixed morphology.

Further more; gastric cancer can be divided into early gastric cancer (EGC) and advanced gastric cancer. (AGO)

(a) Early gastric cancer

Early gastric cancer is defined as cancer limited to ***mucosa and submucosa*** *(NEET) with or without lymph node involvement (AIIMS 97, AI 02).*

In Japan approximately one third of gastric carcinoma are diagnosed at this stage - making prognosis better, even if there is lymph node involvement.

Japanese classification is used to classify early gastric cancer *(MANY PGME)*. It can be either **protruding, superficial, or excavated (deep)**.

Japanese classification of early gastric caner (EGC)

Protruding	→	Type I
Superficial	→	Type IIa, IIb
Excavated (deep)	→	Type III and IIc

Please help your self with figure 28.40.1, below.

(b) Advanced gastric cancer

A tumour, which has involved the muscularis propria of stomach wall is an advanced gastric cancer; and accounts for most of the cases diagnosed in India. In most of them; the lymph node spread has occurred. Metastasis to liver and peritoneum *is* present at the time of presentation.

Macroscopic appearance of advanced gastric cancer has be classified **by Bormann into four types:**

Bormann's classification of AGC

Type I

Polypoidal (growth; extending outside lumen of stomach)

Type II

Ulcerative, circumscribed with everted margin.

Type III

Ulcerative, non circumscribed with ill defined margins.

Type IV

Diffused infiltrating type.

Please see figure 28.41 (a&b) for better understanding.

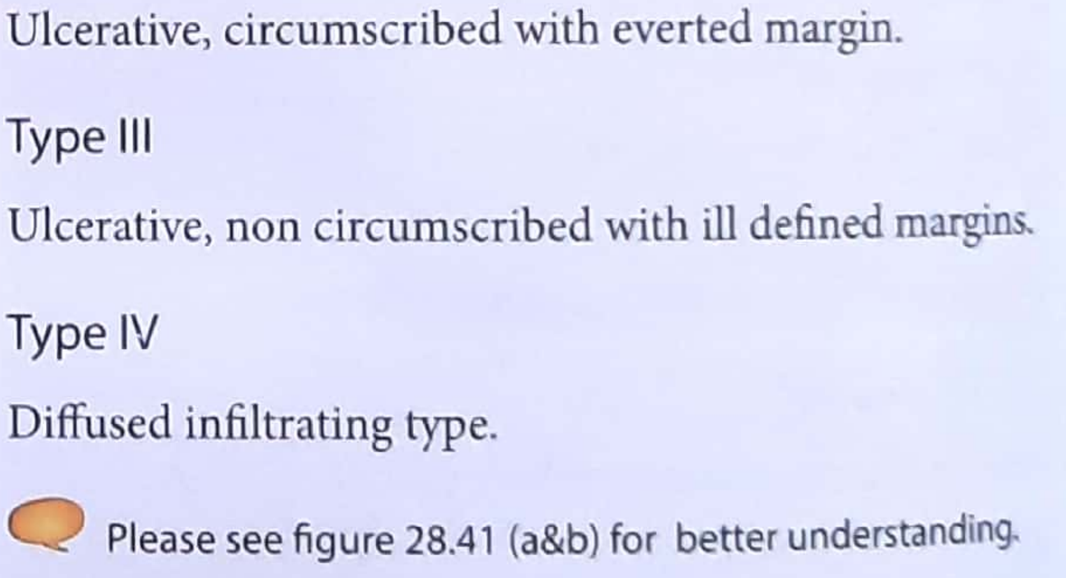

Figure 28.40.1: Japanese's classification of early gastric carcinoma

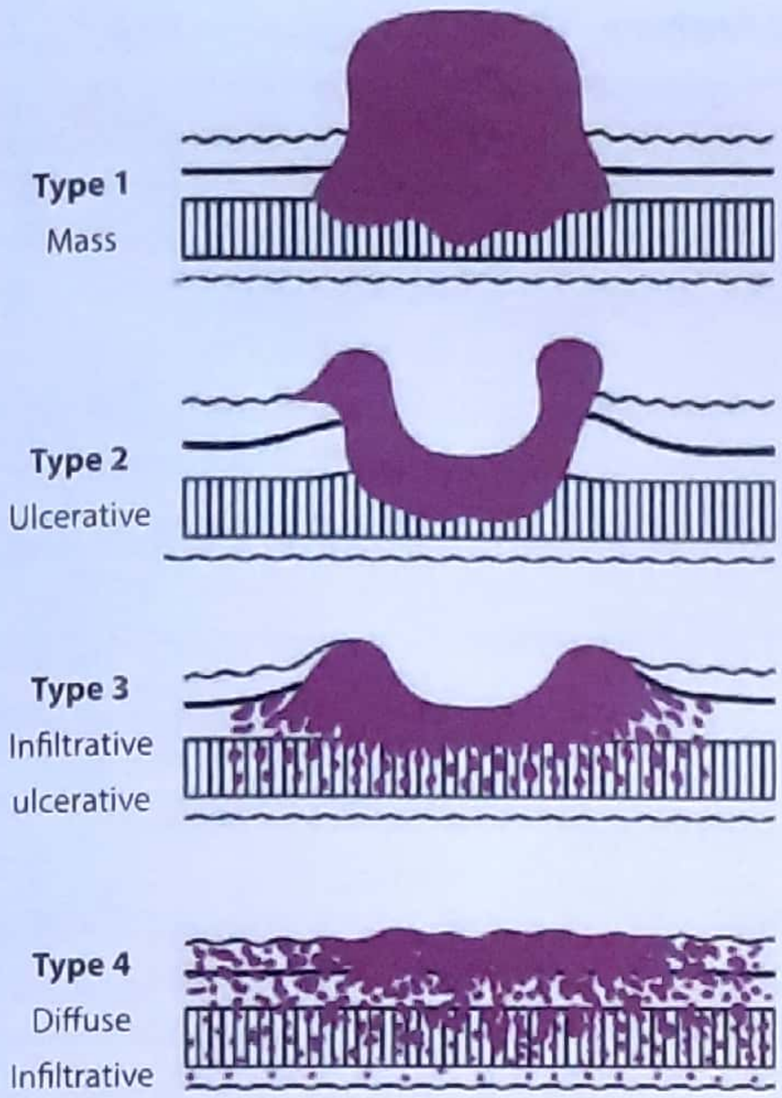

Figure 28.41(a): Borrmann's classification of gastric carcinoma

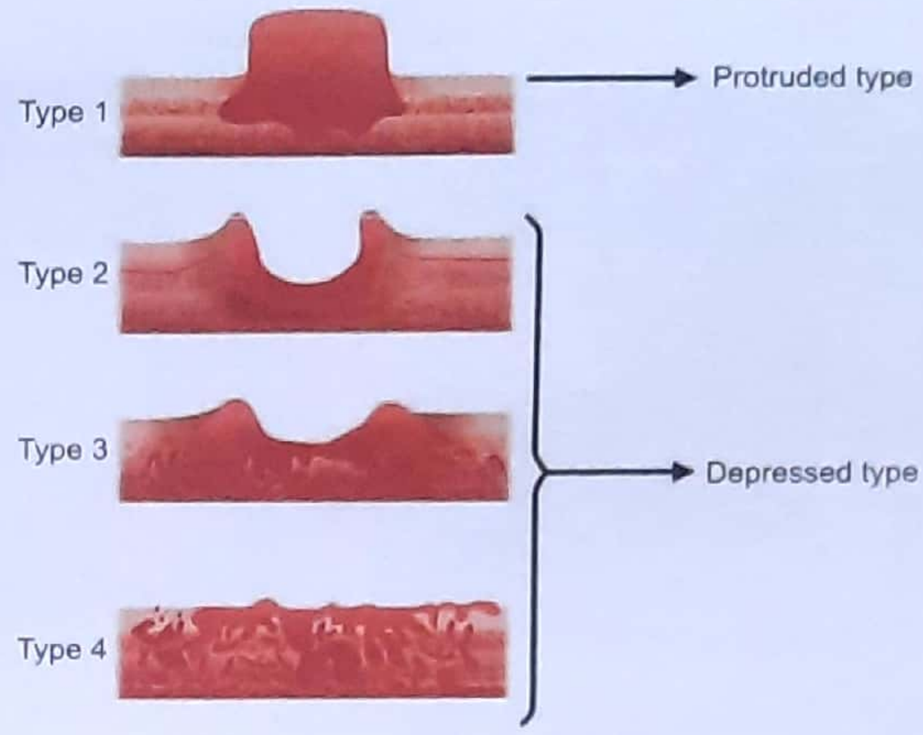

Figure 28.41(b): Borrmann classification of gastric carcinoma

Morphological Subdivision of Gastric Carcinoma (AI 95)

1. **Ulcerating carcinoma** (25%) - This consist of a deep, penetrating ulcer tumour that extend through all layer of stomach. Please see figure 28.41a & 28.41b.

2. **Polypoidal carcinoma** (25%): These are large, polyp like growth hanging inside the lumen of stomach. Metastases is late and prognosis is best among all type.

3. **Superficial spreading carcinoma** (15%): This is also known as early gastric cancer (EGC). It is confined only to mucosa & submucosa. Prognosis is good. (AI 95)

4. **Linitis plastica*(10%)**: (NEET) Involves all layers of stomach wall. Prognosis is poor. (Figure 28.42)

5. **Advanced carcinoma** (35%): This category contains large tumours that has extra-gastric extension, prognosis is worse.

Linitis plastica? : This variety of spreading tumour involves all layer of stomach with *marked desmoplastic* reaction in it. Stomach loose it pliability. Diagnosis: is usually made by contrast X-ray (Barium meal). Endoscopy may show normal mucosa and is not useful. Cure is rare because of early spread.

Spread

1. Direct spread

Direct spread in stomach wall occurs early. The neighbouring mesocolon is often involved. Other organs commonly involved are pancreas, colon and liver.

2. Lymphatic spread

- *From proximal half of stomach* → Left gastric and splenic lymph node → Left, middle and right superior pancreatic lymph node.
- *From Antrum* → Right gastric lymph node superiorly, and right gastroepiploic node and subpyloric lymph node inferiorly.
- *From pylorus* → Suprapyloric nodes superiorly and subpyloric lymph nodes inferiorly.

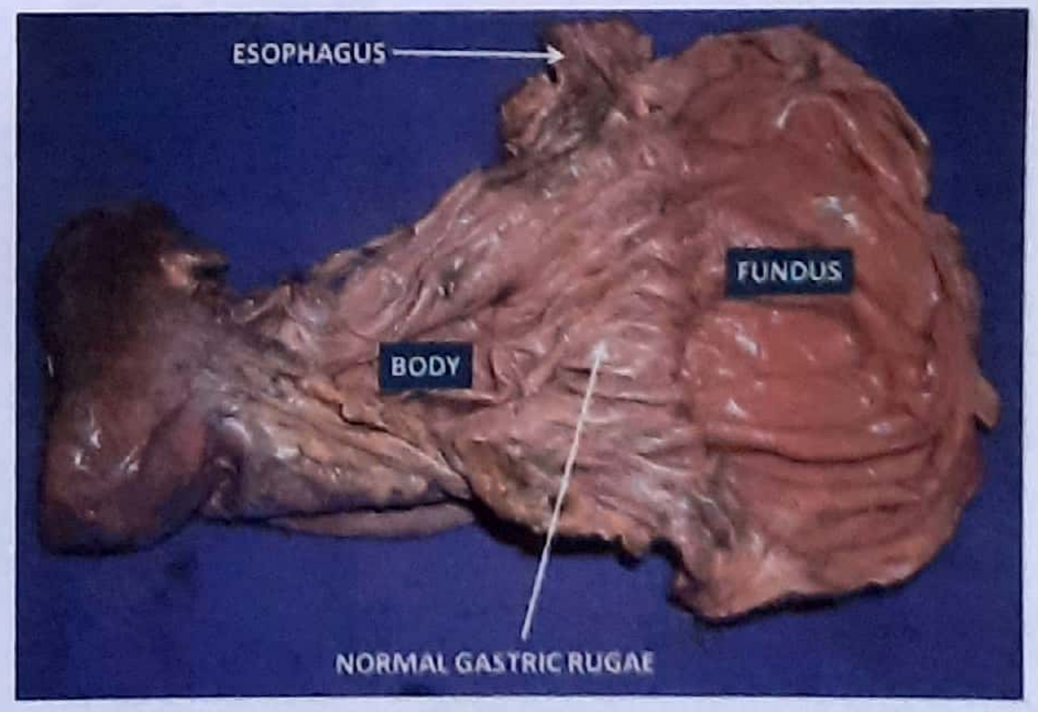

Figure 28.42: Linitis plastica

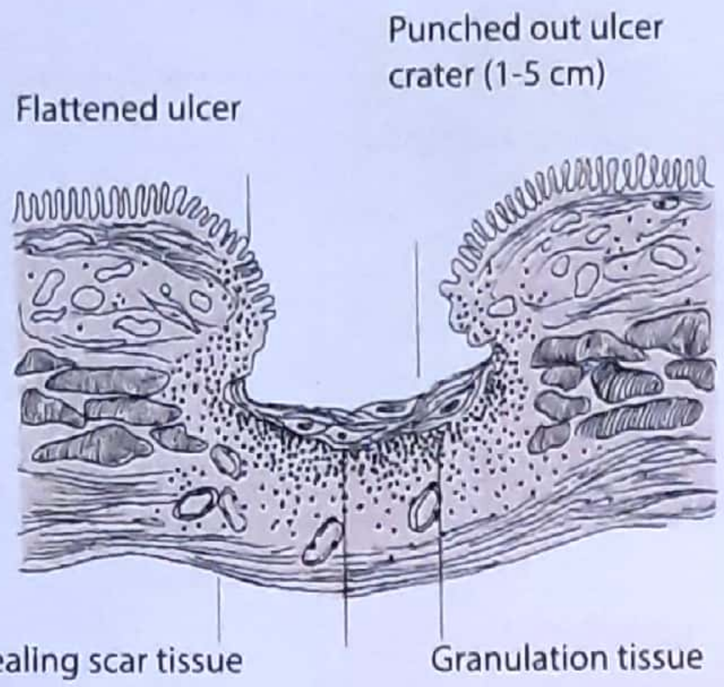

(A) Peptic ulcer

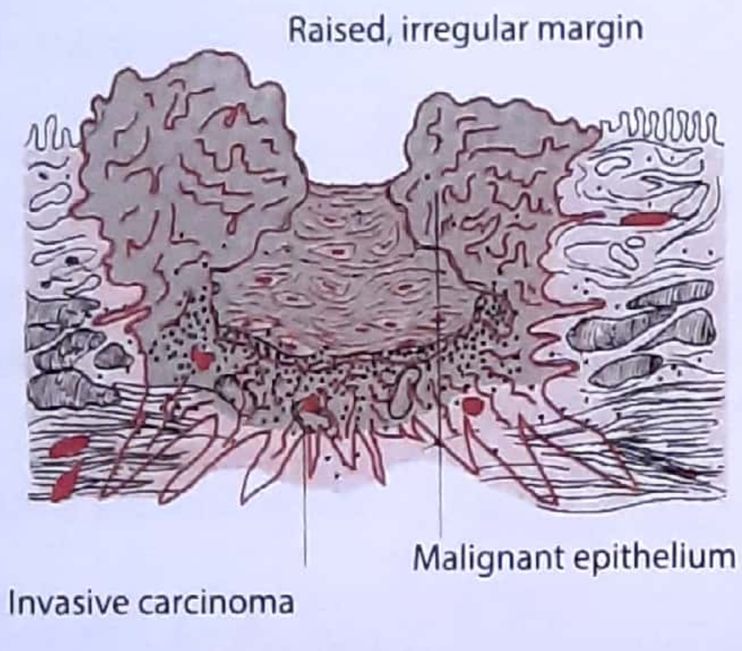

(B) Malignant gastric ulcer (Ulcerative carcinoma)

Figure 28.43: Comparative feature of benign versus malignant gastric ulcer

3. Blood born metastases

This occur first to the liver and subsequently to other organs including lung and bone.

4. Trans-peritoneal spread

This is a common mode of spread, and represent that the tumour has reached serosal layer of stomach. Tumour can manifest anywhere in peritoneal cavity, but most commonly give rise to malignant ascites. Other manifestation may be:

(a) ***Krukenberg's tumour:*** B/L involvement of ovary

(b) ***Sister Joseph nodules:*** *nodules* around periumbilical region

(c) ***Blummer's shelf:*** Rectro-vesical pouch deposits.

(d) ***Hepatomegaly and jaundice***

Clinical feature

Gastric carcinoma is 5 times more common in men than women. Although few cases of gastric carcinoma has been reported at 20 years of age, but the peak age of incidence is 50 years.

- Latent period of this disease is long, and often the disease in diagnosed at stage IV. On the basis of symptomatology, patients have been placed in seven groups:-

1. Silent or latent type

The cancer grows silently, without causing any symptom.

2. Dyspeptic type

This is most common group. Loss of weight and appetite are most common feature (PGI). Dyspepsia (Indigestion) is an important feature of early gastric carcinoma.

3. Hematemesis/Malena-Hematochezia

Gastric carcinoma accounts for only about 3% of all causes of upper G.I. hemorrhage. An ulcerative growth may present with hematemesis. Chronic occult blood loss is common and presents as Iron deficiency anemia/ hematochezia. (PGI 09)

4. Obstructive manifestations

Gastric carcinoma is now, the *most common cause of gastric outlet obstruction,* (MANY PGME)

NOTE: This has been discussed in detail under heading complications of peptic ulcer, earlier in this chapter].

5. Epigastric lump

In case of a advanced gastric carcinoma a hard, irregular lump, situated in epigastrium (sometime is right hypochondrium is palpable.)

6. Acute abdomen

About 2-5% of patient with gastric cancer present as acute abdomen. This is due to perforation of a malignant ulcer, which causes peritonitis.

7. Metastatic manifestations

Metastatic manifestation are

- *Ascites:-* due to peritoneal deposits
- *Blummer shelf:-* Rectovesical deposit

Staging (TNM staging)

Tumor, node, metastasis classification of carcinoma of the stomach	
PRIMARY TUMOR (T)	
TX	Primary tumor cannot be assessed
T0	No evidence of primary tumor
Tis	Carcinoma in situ; intraepithelial tumor without invasion of the lamina propria, high-grade dysplasia
T1	Tumor invades lamina propria, muscularis mucosae, or submucosa
T1a	Tumor invades lamina propria or muscularis mucosae
T1b	Tumor invades submucosa
T2	Tumor invades muscularis propria*
T3	Tumor penetrates subserosal connective tissue without invasion of visceral peritoneum or adjacent structures
T4	Tumor invades serosa (visceral peritoneum) or adjacent structures
T4a	Tumor invades serosa (visceral peritoneum)
T4b	Tumor invades adjacent structures
REGIONAL LYMPH NODES (N)	
NX	Regional lymph node(s) cannot be assessed
N0	No regional lymph node metastasis
N1	Metastasis in 1- 2 regional lymph nodes
N2	Metastasis in 3- 6 regional lymph nodes
N3	Metastasis in 7 or more regional lymph nodes
N3a	Metastasis in 7-15 regional lymph nodes
N3b	Metastasis in 16 or more regional lymph nodes
DISTANT METASTASIS (M)	
M0	No distant metastasis
M1	Distant metastasis

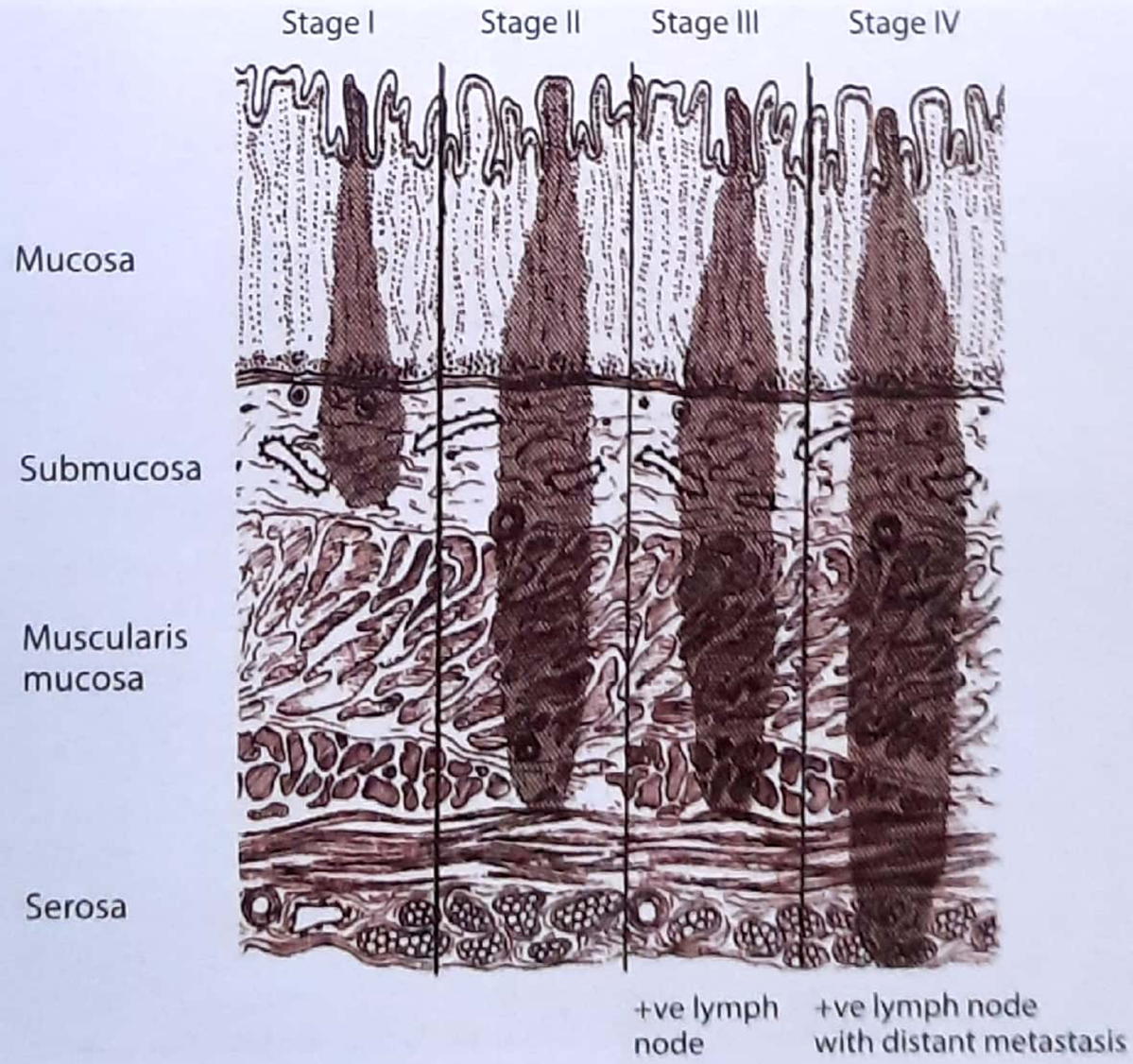

Figure 28.44: Staging system for gastric carcinoma. The darkly shaded area represents different depth of mucosal invasion

- *Sister Mary Joseph's nodule:-* around umbilicus (AIIMS 09, 10)
- *Left supra clavicular lymphadenopathy'.* (AP 96) (Trosier's sign)
- *Jaundice and hepatomegaly:-due* to liver metastases.
- *Krukenberg's tumour* - Involvement of ovary (B/L)

Investigation

1. **Stool examination**: Occult blood in stool in about 80-90% cases. (AI 2011)
2. **Anemia** is present in about 40%
3. **CEA (Carcino embryonic antigen)**: CEA level is elevated in about 65% cases with advanced carcinoma.
4. **Ba Meal X-ray:** Small flat growth are liable to be missed, but a large poly-poidal growth will produce a filling defect. Barium meal is especially useful in cases of linitis plastica (leather bottle stomach) where mucosa may be normal and endoscopic diagnosis can not be made.

Please see figure 28.45.

5. **Endoscopy (gastroscopy)**: Endoscopy makes possible visualization of gastric mucosa without much difficulty and will give **information about nature and extent of the growth**. (NEET) All lesions, (whether polypoidal or ulcerative) should be examined, by taking multiple biopsy and a minimum of six biopsies are necessary for greater accuracy. *In Japan regular endoscopic examination is done in patients over 40 years to detect early gastric carcinoma* (AIIMS 97). See figure 28.46 and 28.47 - for better understanding.

KEY BOX 28.12

Clinical Feature of Ca Stomach

Mnemonic: Patient has LOAADS due to Ca stomach.

L-Loss of weight
O-Obstruction (GOO)
A-Acute abdomen (perforated malignant ulcer)
A-Anorexia & Asthenia
D-Dyspeptic symptom
S-Secondaries to liver, lung

Figure 28.45: Ba meal study in gastric carcinoma

Simplest investigation in suspected case of gastric cancer is CT.

Endoscopy visualizes only inner layer (mucosa) of stomach.

6. **Ultrasound, CT Scan and MRI**: This will give information **about metastasis of gastric carcinoma to liver by CT**, (NEET) ovary or rectovesical pouch. Ascites can be demonstrated.
7. **Gastric acid analysis**: About 20% of the patients with gastric carcinoma are achlorhydric after maximal stimulation, where as hypochlorhydria is present in almost all the cases of gastric carcinoma.

Treatment

(Read very carefully)

In carcinoma of stomach the only chance of cure is when a carcinoma is detected early & surgically removed. The curative resection is possible only when the growth is con-fined to stomach and has extended only to regional lymph nodes (N_1).

For discussion purpose we can broadly divide, treatment of CA stomach in to 3 groups.

Treatment of CA Stomach

- **Curative resections**
- **Palliative surgery**
- **Chemotherapy**

NOTE: Gastric adenocarinomes are relatively radioresistant (AI 2011)

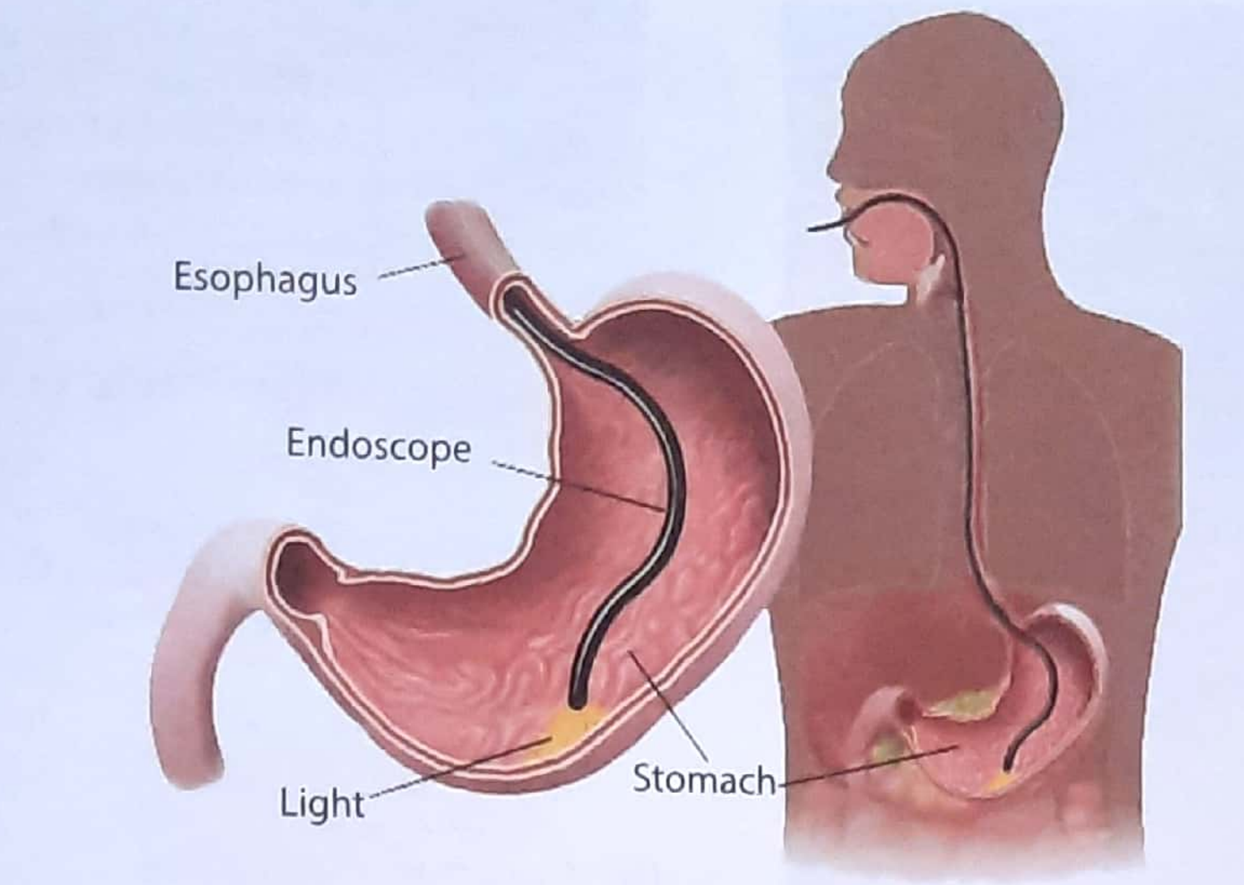

Figure 28.46 and 28.47 a & b : Endoscopic visualization of stomach (Gastroscopy)

<u>Now lets take them one by one</u>

1. Curative resection

[i.e. Expecting cure from the disease]

- Curative resection is only possible for early gastric carcinoma, in which growth is confined to stomach, and when there is no evidence of any metastatic disease, and lymph node status is N_0 or N_1.

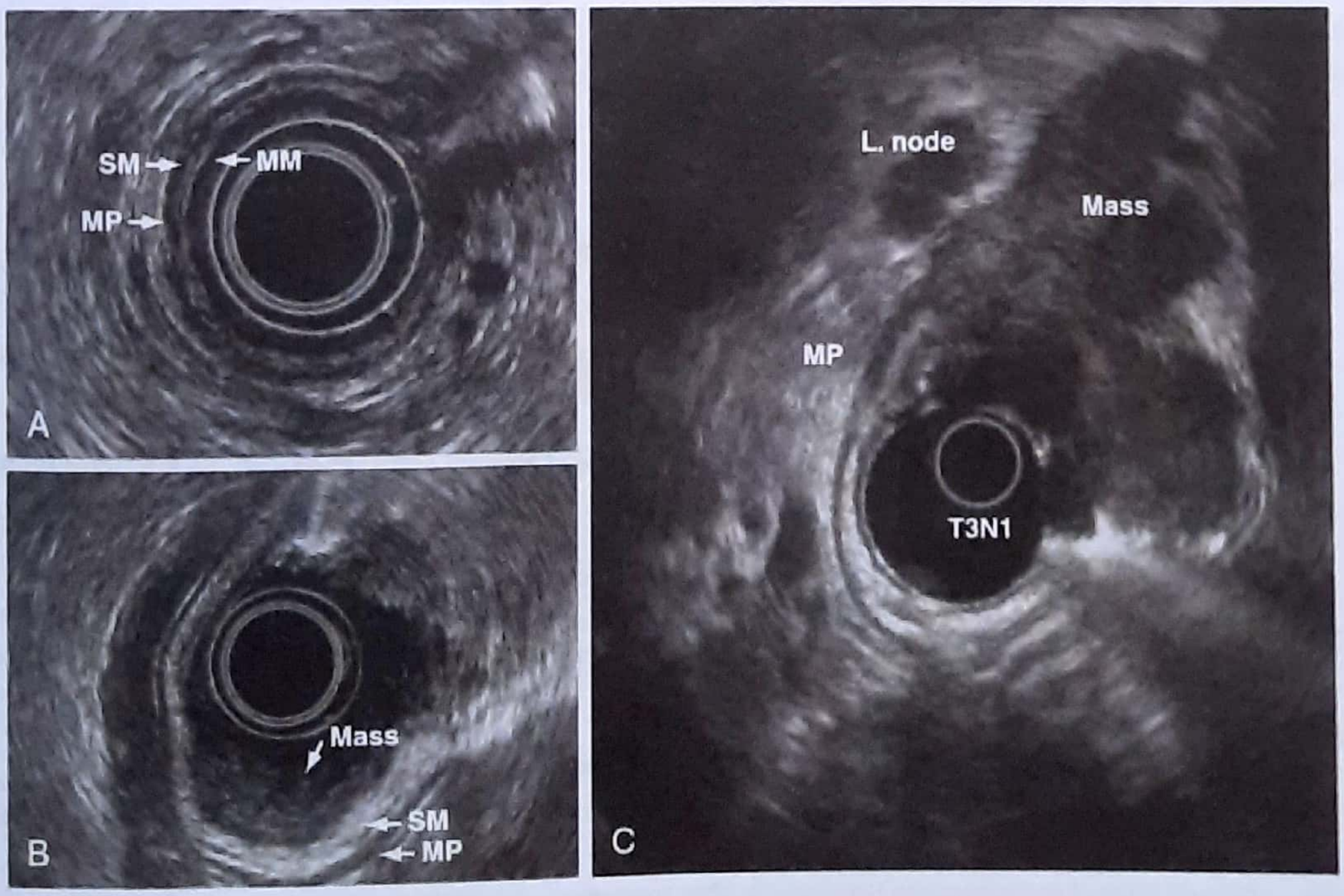

Figure 28.48.1: Endoscopic ultrasound views of normal stomach (A), TIN0 gastric cancer (B), and T3N1 gastric cancer (C)

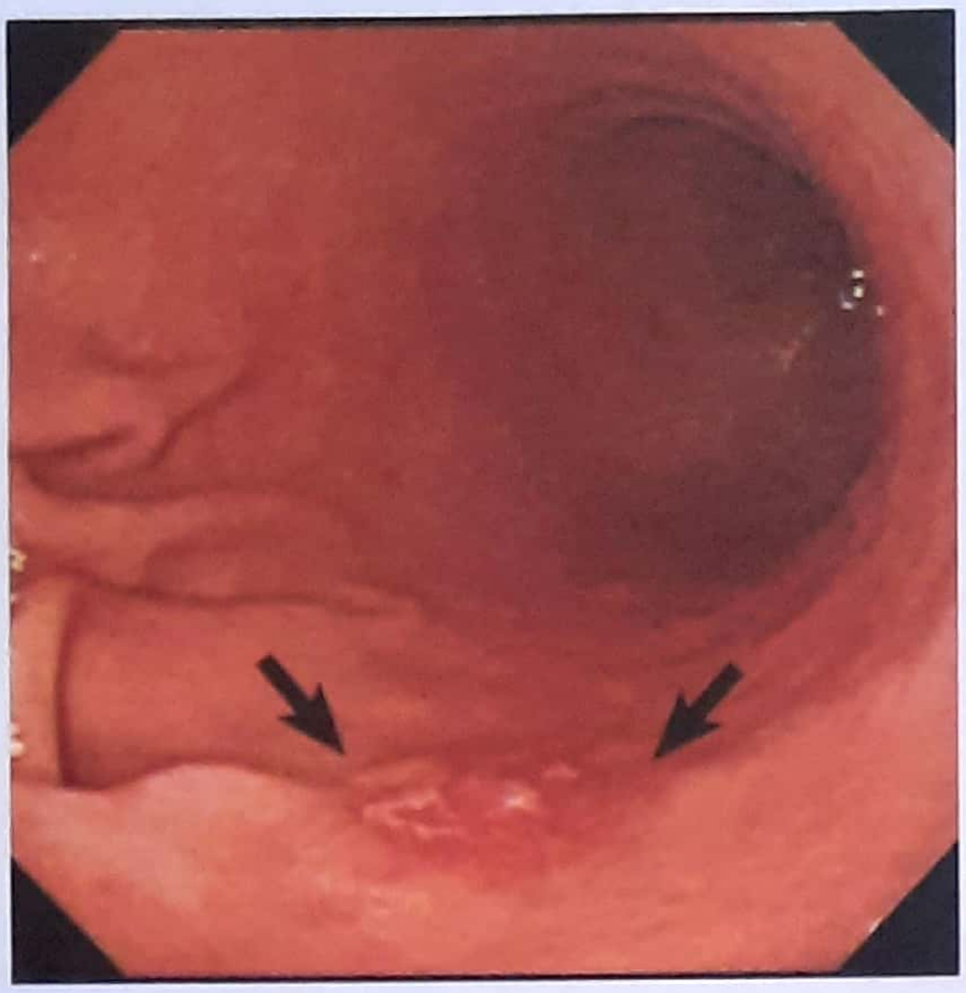

Figure 28.48.2: Ca stomach as seen on endoscopy

- Surgical procedure is decided, according to the location of the cancer, as described below-

(a) Carcinoma situated at pyloric antrum and/or body of stomach

- Distal gastrectomy with omentectomy + 3 to 4 cm of proximal duodenectomy + enlarged lymph node removal.
- Reconstruction of intestinal continuity after partial gastric resection may be achieved either by Billroth I or Billroth II procedure. Please see figure # 28-49b.

KEY BOX 28.13

Standard criteria for endoscopic resection of gastric adenocarcinoma

- Intestinal-type adenocarcinoma
- Tumor confined to the mucosa
- Absence of lymphovascular invasion
- Nonulcerated tumor
- Less than 2 cm in diameter

(b) Carcinoma of fundus

- Removal of upper half of the stomach + lower end of esophagus along with enlarged lymph node + spleen.
- *Splenectomy is done* as splenic lymph node are often involved in case of carcinoma of fundus. *(IMP. POINT)*
- Reconstruction is done by making esophago-gas-tric anastomosis or esophago-jejunal anastomosis. (Rou-en-Y anastomosis). Figure # 28.49.c.

(c) Carcinoma of cardia

- Removal of upper 1/3 of stomach + lower 1/3 of esophagus + splenectomy + Removal of enlarged re-gional lymph node, followed by *intra thoracic* esoph-ago-gastric anastomosis.
- Total gastrectomy in preferred in proximal gastric cancer.

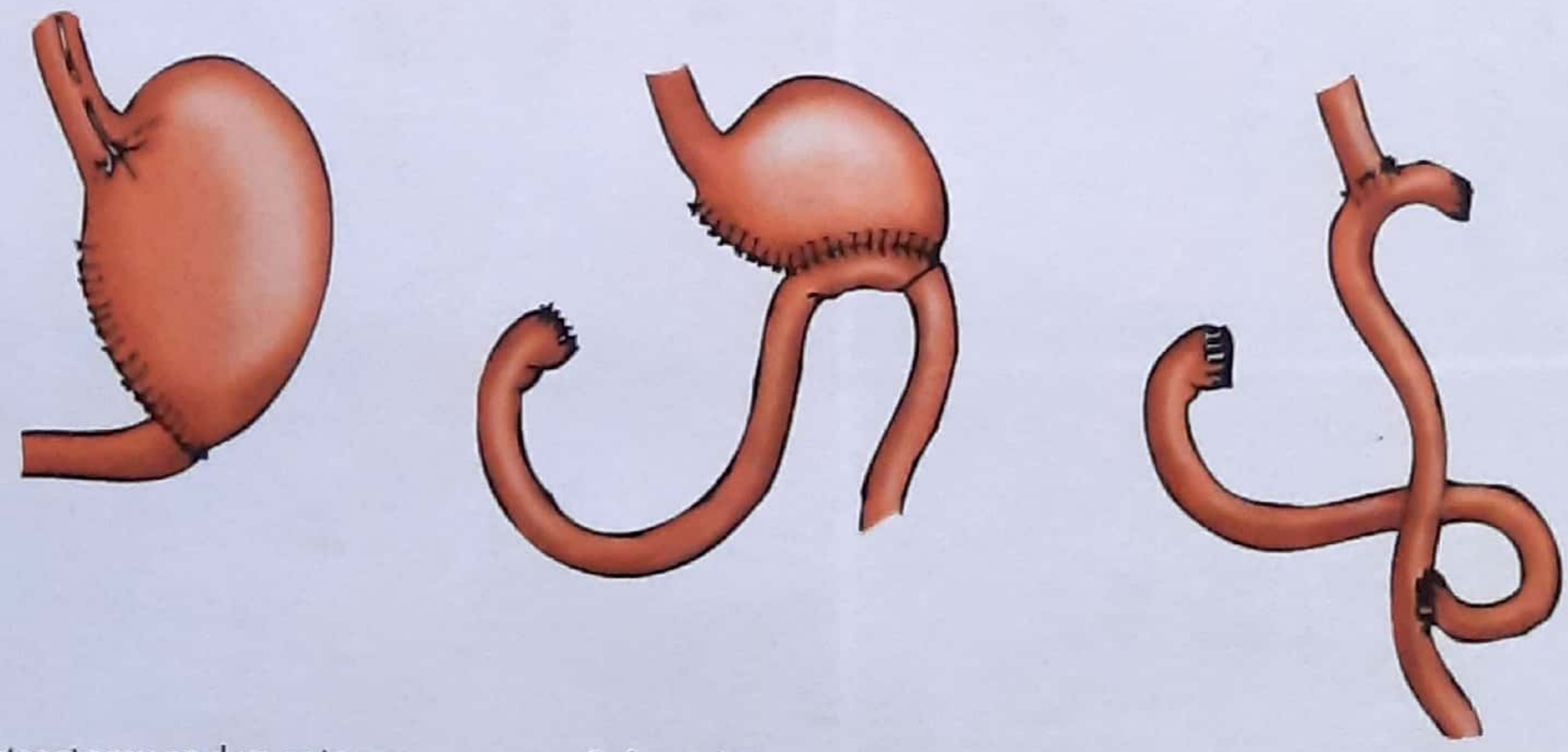

Antrectomy and vagotomy (Billroth I) (a)

Subtotal Gastrectomy (Billroth II) (b)

Total gastrectomy (Rouxen-y anastomosis) (c)

Figure 28.49: Various type of recostruction procedure after resection of gastric cancer (note : the choice depends up on the site and stage of cancer, see text for details.

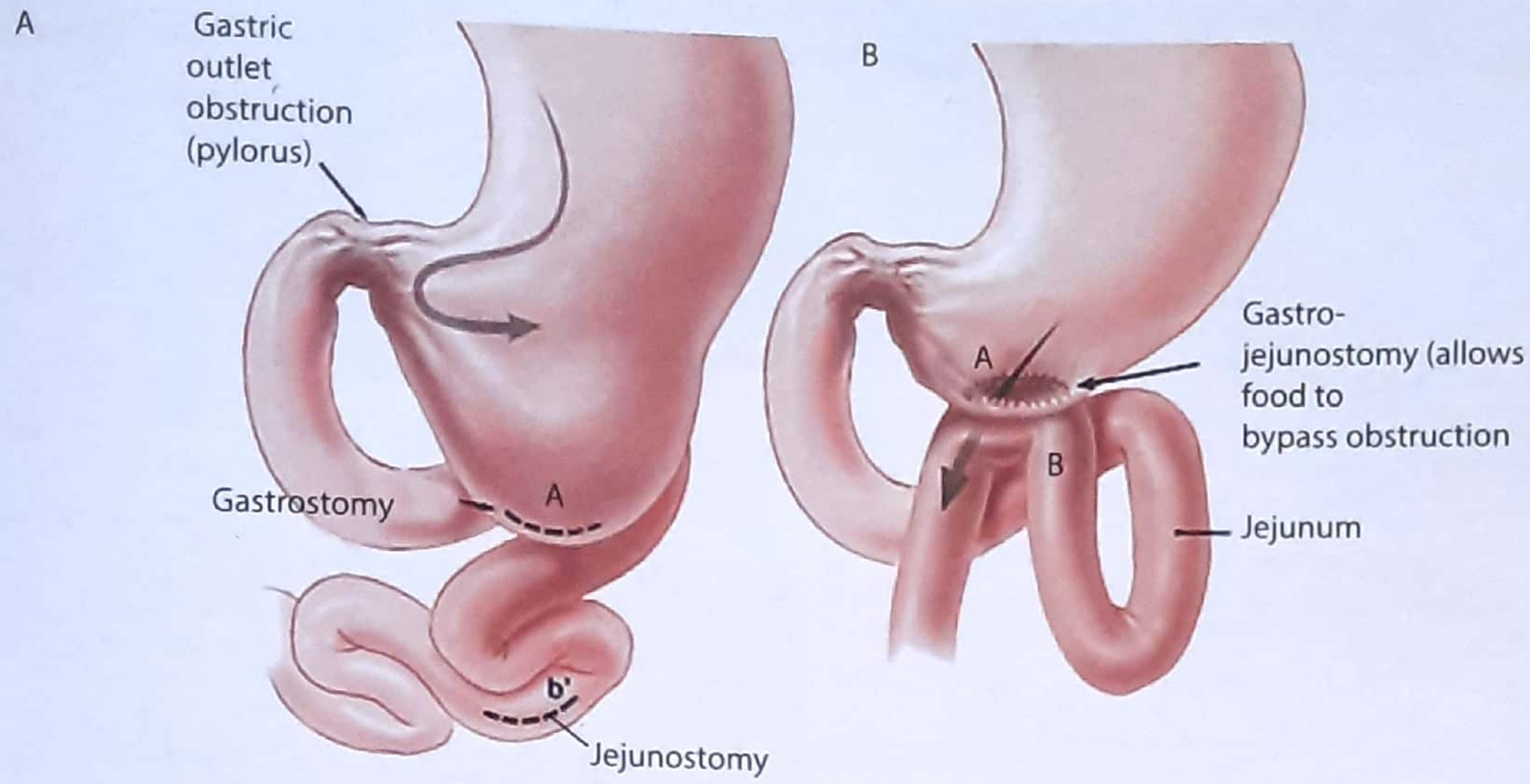

Figure 28.50: Gastro-jejunostomy

(d) Diffused growth

- **Radical total gastrectomy** followed by roux-en Y esophago-jejunostomy. (fig. 28.49.c)
- Most common deficiency in these patients is Iron.

2. Palliative surgery

- *Palliation means relieving or making disease less severe, without curing the disease.*
- The aim of palliative surgery is relieving or alleviating the symptoms of patients, so that he can live comfortably, till he is alive.
- Palliation for an incurable lesion is usually to remove an area of obstruction or bleeding.
- In advanced gastric carcinoma, choice of surgery is palliative only.
- When ever possible palliative gastrectomy can be done, but if this is not technically possible then an ***anterior* gastro-jejunostomy** is done to relieve vomiting. *(IMP POINT)*

NOTE: A posterior gastro jejunostom is not done, because it may get blocked sooner by the growth because extension of the growth usually extends posteriorly.

NOTE: Posterior GJ is done as a drainage procedure for peptic ulcer disease. *(PGME)*

3. Chemotherapy

ECF regimen

Gastric cancer may respond well to combination cytotoxic therapy. Best results are currently obtained by using a combination of Epirubacin, cis-platinum and 5-Fluorouracil (5-FU). A significant proportion of patient will respond to this regimen.

Please go through key box 28.14 before concluding this topic.

****

OTHER GASTRIC TUMOURS

Most common benign tumour of stomach is adenoma.

1. Gastro-intestinal Stromed Tumors (GIST)

- Previously known as leiomyoma or leiomyosarcoma
- **Stomach is involved in almost 70% cases with GST** *(NEET)* *(Stomach is M/C site for GST)* *(MANY PGME)*

KEY BOX 28.14

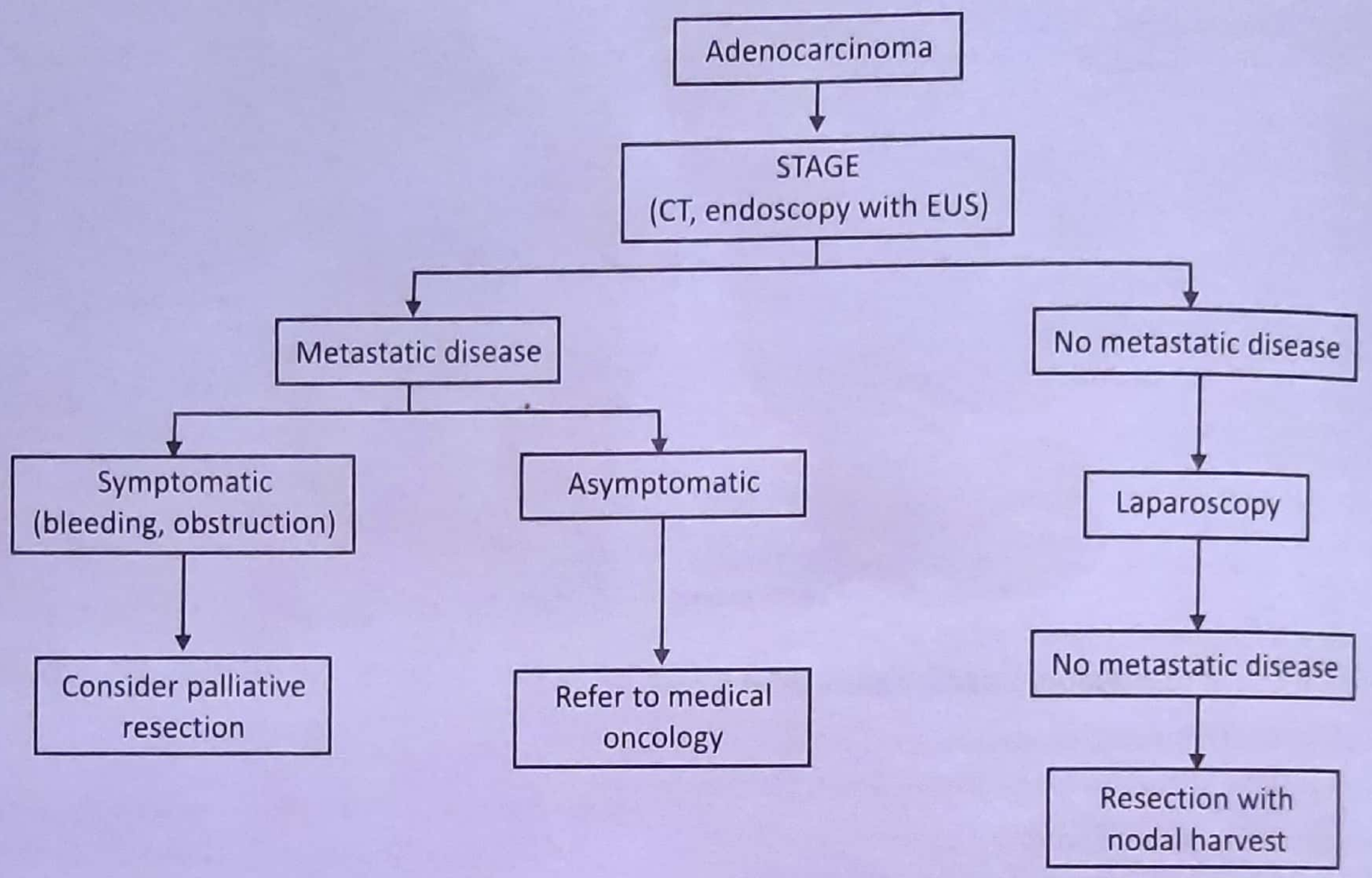

- Leiomyoma is most common benign gastric tumour.
- Bleeding is most common manifestation and presents with hematemesis. Leiomyosarcomas of stomach are most common tumour of stomach which bleed *(PGI)*
- In most of the cases tumour arises from proximal stomach. *It is considered to arise from Interstitial cells of cajal.*
- It may grow into gastric lumen, or remains entirely on the surface, or even become pedunculated with in abdominal cavity.
- Spread occurs early by direct invasion or blood borne metastasis.
- GIST express CD117 (c-KIT) or related PDGFRA and CD 34. *(AIIMS 09, 11)*
- Leiomyoma should be removed by enucleation or wedge resection, but often more radical resection is required for leiomyosarcoma. The 5 year survival rate is 20%.
- CHEMOTHERAPY - Imatinib mesylate (gleevec) is an effective systemic agent.

Please read key box 28.15 carefully.

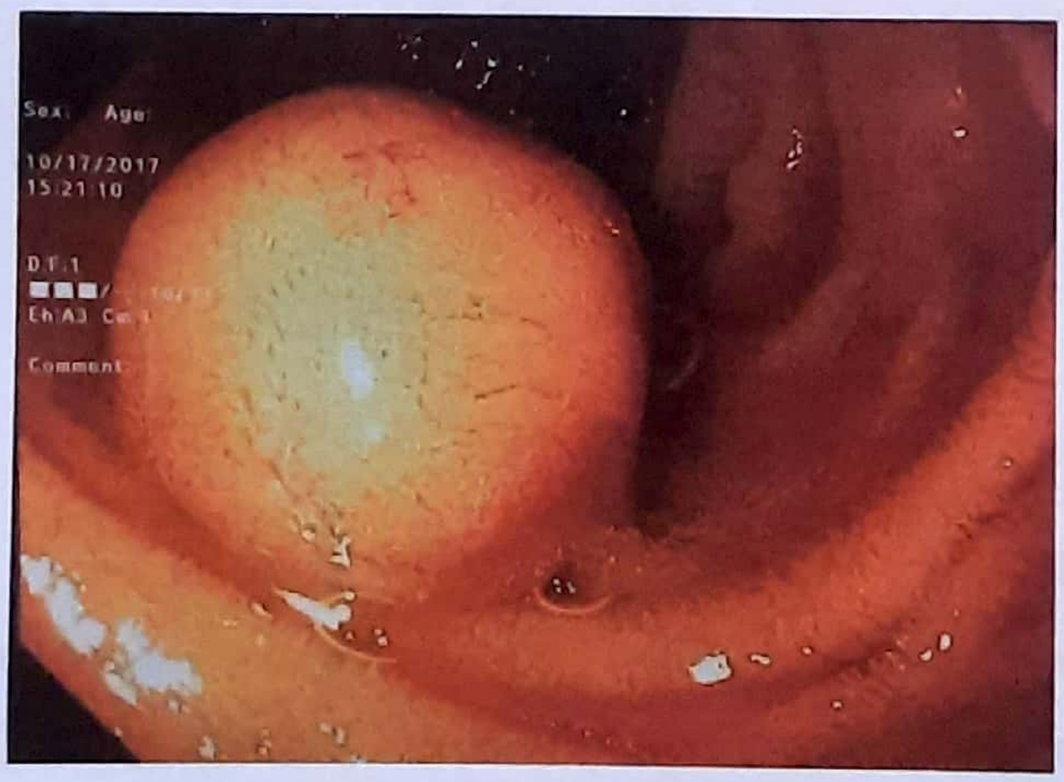

Figure 28.51: GIST

2. Gastric Carcinoid

They appear as well defined tumour and are confined to mucosa and submucosa. On endoscopy, they may appear as gastric polyp. The rate of growth of tumour is very slow. They may give rise to carcinoid syndrome.

Please read key box 28.16 carefully (next page).

KEY BOX 28.15

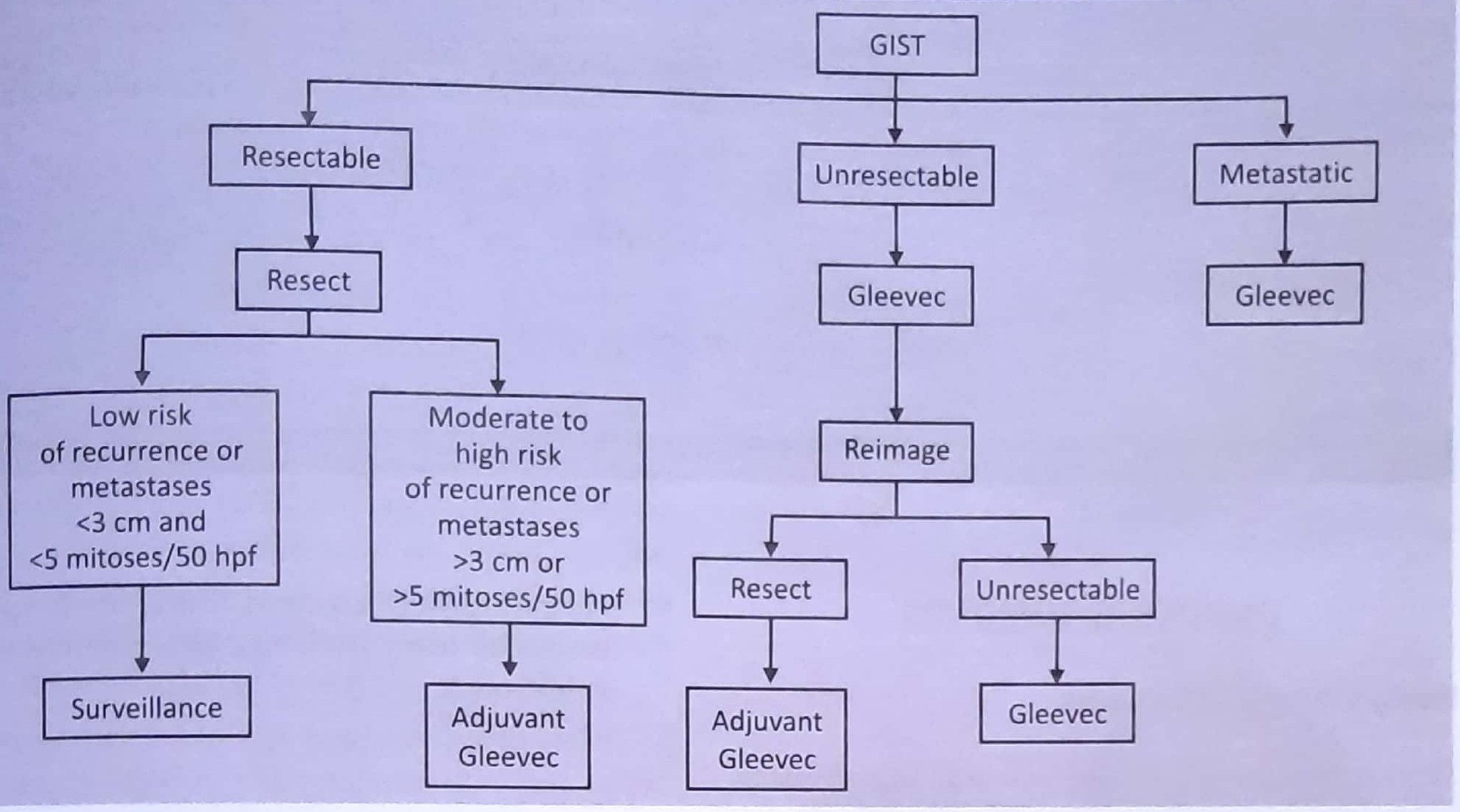

Figure 28.52: A 6cm×5cm, polypoidal mass (carcinoid) in the gastric body with central ulcerations (arrows) seen during upper GI endoscopy

3. Gastric Lymphoma *(COMED 07)*

- Stomach is commonest site for lymphoma in GIT.
- The incidence of primary gastric lymphoma is increasing. They accounts for approximately 5% of all gastric neoplasm.
- Gastric lymphoma is most common in sixth decade and mimics closely to gastric carcinoma, as far as clinical presentation is concerned.
- Primary gastric lymphoma are Non Hodgkin's-B Cell lymphomas. *(IMP.POINT)*
- Secondary lymphomas usually arises from mucosa associated lymphoid tissue (MALT) associated with **H. pylori infection.** *(NEET)*
- Lymph node involvement is often late.
- At an early stage, the disease takes the form of diffused mucosal thickening, which may ulcerate.
- Diagnosis is made by endoscopic biopsy, and seldom on the basis of endoscopic features alone.

Treatment

Low grade early lymphoma: It consist of long term chemotherapy with cyclophosphamide.

High grade lymphoma: Surgical resection with total abdominal radiotherapy.

It has been shown that early gastric lymphoma are found in association with H. Pylori infection and may regress or even disappear when H. Pylori infection is eradicated. This fact, it is strongly suggests that gastric lymphoma may have infective etiology *(PGME, COMED 06)*

****

KEY BOX 28.16

Gastric carcinoid types

	TYPE 1	TYPE 2	TYPE 3
Percentage of gastric NETs	70%-80%	5%-10%	10%-15%
Associated pathology	Pernicious anemia	ZES, MEN1	n/a
Location	Fundus or body	Fundus, body, antrum	Fundus or antrum
Acid level	Low	High	Normal
Gastrin level	High	High	Normal
Prognosis	Excellent	Good	Poor

MEN, Multiple endocrine neoplasia; *n/a*, not applicable; *NETs*, neuroendocrine tumors; ZES, Zollinger-Ellison syndrome.

DUODENAL TUMOURS

Benign duodenal tumours

Most common benign duodenal tumour is villous adenomas, which occur primarily in periampullary region. Though they are generally uncommon, but are most commonly found in patients with familial adenomatous polyposis.

Duodenal Adenocarcinoma [PGI 04]

- Although malignant tumours of small intestine are uncommon, duodenum is most common site for adenocarcinoma arising in small bowel. (PGME)
- Most tumours, originate in the periampullary region and commonly arise from a pre-existing villous adenoma.
- Patient usually presents with anemia, intestinal obstruction and obstructive Jaundice. Obstructive jaundice in as a result of direct involvement of ampulla.
- Curative surgical treatment is pancreaticoduodenectomy (whipple's procedure)

Duodenal Obstruction

- Most common cause of duodenal obstruction in adult is usually due to malignancy and carcinoma of head pancreas is the most common cause.
- Treatment is usually a bypass procedure i.e. gastrojejunostomy.
- Annular pancreas may rarely cause duodenal obstruction. Obstruction usually follow an attack of pancreatitis.
- One rare cause of duodenal obstruction is superior mesenteric artery syndrome, (described else where in this book).

****

OTHER GASTRIC CONDITIONS

Acute Gastric Dilatation

The pathogenesis of this disorder is not well understood, but seems due to inhibition of intrinsic electrical pacemaker activity. It can follow any abdominal surgery, without nasogastric suction and after splenectomy. The stomach which is usually atonic in postoperative period dilates enormously. Often the patient is dehydrated and has electrolyte disturbances. Failure to recognize the condition early may result in sudden massive vomiting & aspiration pneumonia.

Treatment

Nil oral, nasogastric suction, with a large bore Ryle's tube, fluid replacement and correction of electrolyte imbalance. (PGI 88, AIIMS 97)

Trichobezoar & Phytobezoar

(AIIMS 89, AMU 89)

(Tricho- means hair, **phytoz= vegetable** (NEET)). Bezoars are foreign body in stomach. Trichobezoar (hair ball) is a rare condition and is usually found in a psychiatric female patient, who are often adolescent [HPU 2001, MAN/PA/ 06]. (Figure 28.53)

Patient has habit of ingesting hair, which remains undigested in stomach causing ulceration, GI bleeding, perforation and obstruction. Diagnosis can be made easily by endoscopy.

Treatment is removal of bezoars by gastrotomy. Gastric bezoars can also be broken up and dispersed by endoscopy. Phytobezoar are made of undigested vegetable matter, seeds and found principally in patients who have gastric stasis, often after gastric surgery & vagotomy.

Volvulus of The Stomach (Torsion of Stomach)

Rotation of stomach usually occurs around the axis and between two fixed points ie;- cardia and pylorus. Rotation of stomach can occur in horizontal and vertical direction but horizontal rotation is more common and is usually associated with a large para-esophageal (rolling) hernia. *(PGME)*. Please see figure 28.54 (a & b).

Acute gastric volvulus produces severe abdominal pain accompanied by a diagnostic triad, called as Borchardt's triad, which include:

Borchardt's Triad

(i) Vomiting followed by retching

(ii) Epigastric distension

(iii) Inability of passing a Ryle's tube into stomach *(PGME)*

The diagnosis can be made by barium meals. Endoscopy is not helpful.

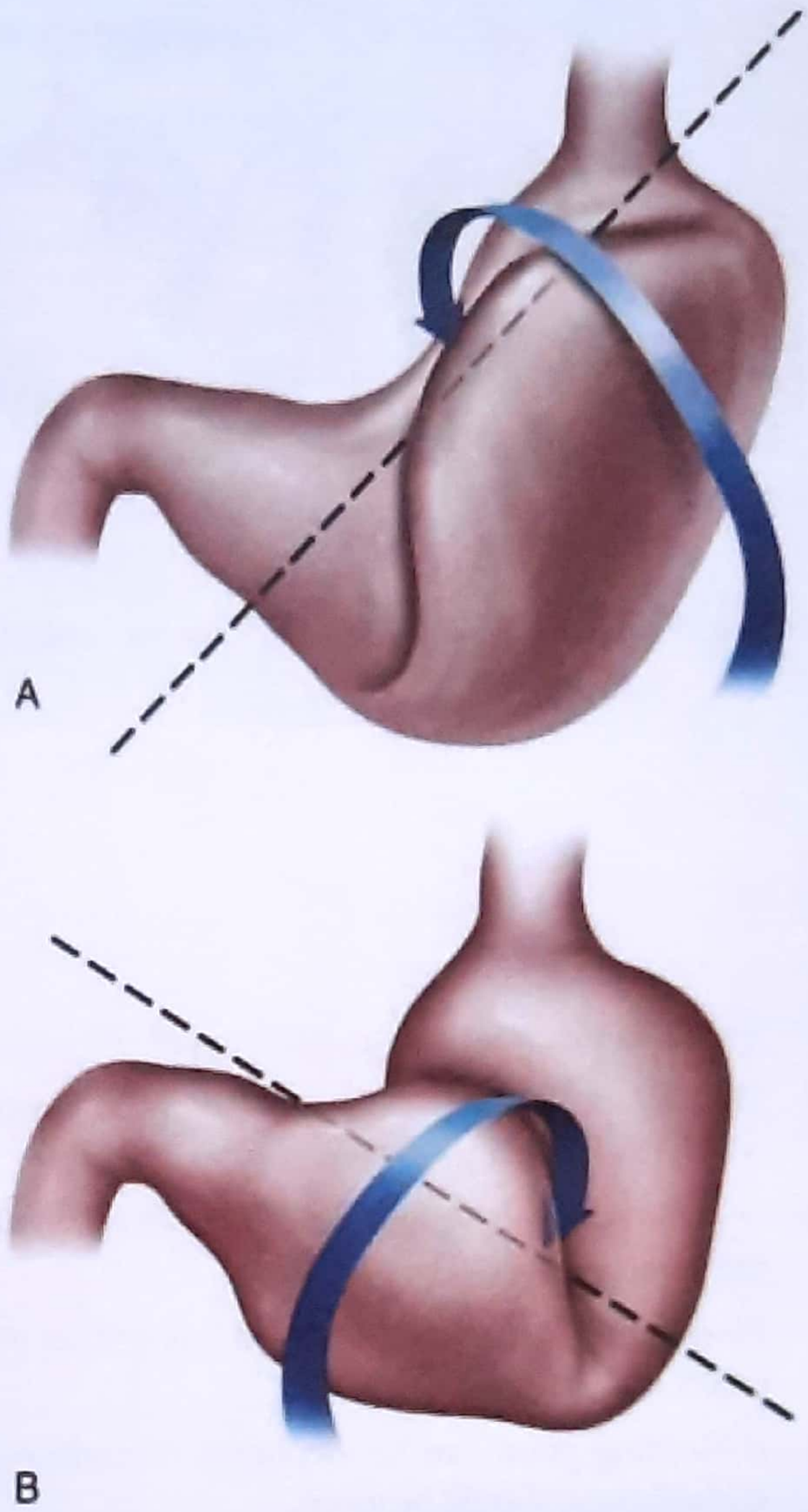

Figure 28.54 (a): Torsion of Stomach

Figure 28.53: Trichobezoar

Treatment

The treatment is by detorsion of stomach and anterior gastropexy (fixing the anterior abdominal wall of stomach to inner side of anterior abdominal wall).

If the condition is associated with diaphragmatic hernia (rolling type), then reduction of hernia is done, with repair of hernial defect, followed by detorsion and anterior gastropexy. In rare cases, where strangulation has occurred, the compromised segment of stomach is resected.

Dieulafoy's Disease

- This is a arteriovenous malformation.

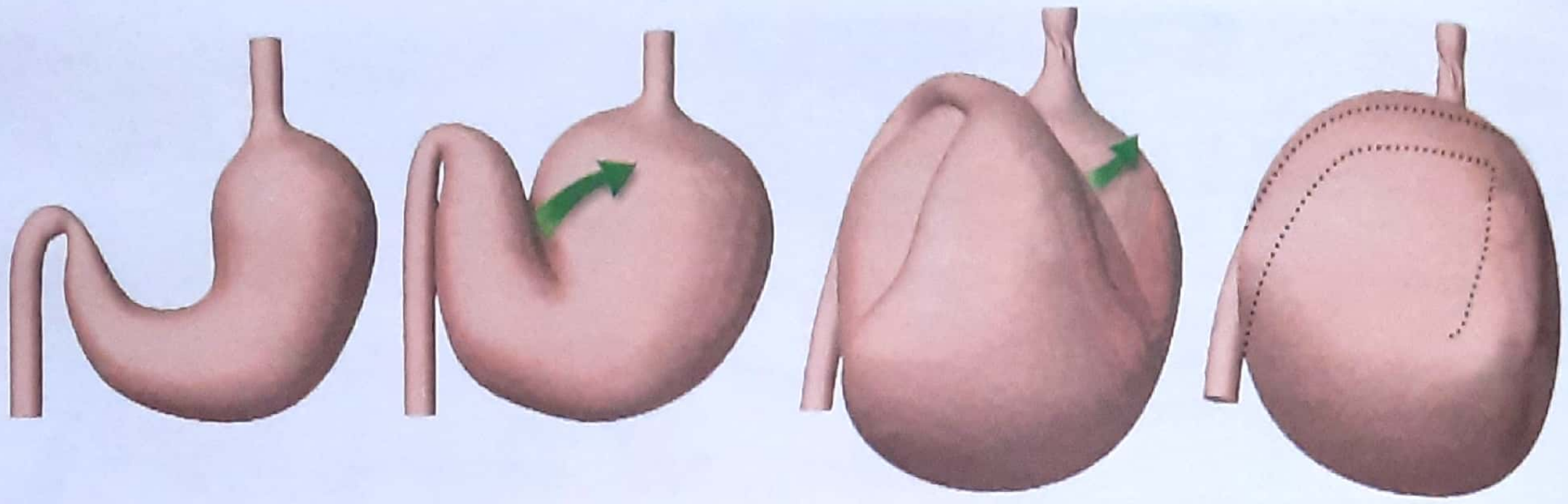

Figure 28.54 (b): Gastric volvulous (note the rotation)

- It account for about 0.5% cause of upper GI bleeding.
- The AV malformation is situated in submucosa which is covered by mucosa.
- On endoscopy the lesion is not detectable, because the lesion is covered by mucosa.
- Bleeding due to this malformation is one of the most difficult situation to treat.
- If bleeding point can be identified, an endoscopic sclerotherapy should be given.
- If it is **identified at surgery (gastrotomy), then wide local excision of the lesion is necessary.** (NEET)
- Occasionally a lesion is only identified after gastrectomy and sometime not even then.

Gastric Diverticula

- *Gastric diverticula are uncommon and are usually asymptomatic.* (AIIMS 81, PGI 82)
- Most of them are pulsion* diverticula, consisting of mucosa and submucosa only.

  * Pulsion= produced due to increased intraluminal pressure in stomach.
- They are most commonly located on lesser curvature with in a few centimeters of gastroesophageal junction near cardia, on the posterior surface.
- Diverticula are present at prepyloric region; generally possess all layers of stomach wall and are more likely to be symptomatic.
- If at all symptomatic; most common symptom are from hemorrhage, or inflammation within a diverticula.
- Radiologically they may be confused with a gastric ulcer.

Hypertrophic Pyloric Stenosis of Adult

This is a rare condition and its relationship to the childhood condition is unclear, although some patients have a long history of problems with gastric emptying. *It is commonly treated by pyloroplasty.* (JIPMER 81)

NOTE: *Hypertrophic pyloric stenosis of infancy is treated by pyloromyotomy-Ramstedt pyloromyotomy* (ALLMS 80)

****

Bariatric Surgery

Surgical treatment of morbid obesity is known as bariatric surgery.

Morbid obesity → BMI ≥ 40 kg/m² without comorbidity
Morbid obesity → BMI ≥ 35 kg/m² with comorbidity

Procedure

Restrictive
- Vertical banded gastroplasty.
- Laparoscopic adjustable gastric banding.

Largely restrictive - Roux-en-Y gastric bypass. Most common performed procedure. *(AIIMS MAY 13)*

Largely Malabsortion - BPD - max weight reduction Duodenal switch. *(NEET)*

Indication *(NEET)*

1. BMI ≥ 40 kg/m^2 with or without comobidity.
2. BMI ≥ 35 kg/m^2 with comobidity.

   +
3. Has failed attempt at medically supervised diet.
4. Be Psychiatrically stable

Contraindication

- Inability to change lifestyle.
- Drug, alcohol or addiction.
- Eating disorder.
- Psychologically unstable
- Mentally incompetent to understand procedure
- Medical condition making anesthesia risky.

****

Sample Questions for Prof Examination

1. Classify the causes of hematemesis. Give in detail its management.
2. Discuss treatment and complications of chronic duodenal ulcer.
3. Discuss the differential diagnosis of a lump in the epigastrium. Briefly outline the management of carcinoma stomach.
4. What are the complications of peptic ulcer ? Indicate briefly the line of treatment of each complications.
5. Describe various complication of chronic duodenal ulcer. Discuss the clinical features, diagnosis and treatment of a patient with pyloric stenosis.

29 The Liver

Contents

- Surgical anatomy
- Investigation of Liver disease
- Liver trauma
- Hemobila
- Liver abscess
- Cyst of liver
- Neoplasm
- Benign
  - Liver cell adenoma
  - Focal nodular hyperplasia
  - Hemangioma
- Malignant
  - Hepatocellular carcinoma
- Portal hypertension

SURGICAL ANATOMY

Liver is the largest organ is body weighing about 1.6 kgs in men & 1.3 kgs is women. Liver is divided anatomically into a large right lobe and small left lobe. Right lobe constitutes about three quarter of the liver parenchyma, while left lobe constitute about one fourth of the liver parenchyma. The liver occupies whole of the right hypochondrium, the greater part of epigastrium and extends into left hypochondrium. (Figure 29.1)

The liver is suspended from the diaphragm, by the right and left triangular ligament, the anterior extension of which forms the falciform ligament. *Falciform ligament divides* the liver **morphologically** into two lobes:- *bigger right lobe* and *smaller left lobe,* (Figure 29.2)

The portion of the right lobe of liver in front of the porta hepatis is called **quadrate lobe**. The portion of liver between the porta hepatis (anteriorly) and the inferior vena cava (posteriorly) is called **caudate lobe**.

Hepatic Lobules

Liver parenchyma is divided into *functional* unit called lobules. Each lobule is 1-2 mm in diameter and is made up of maize (bhutta) like arrangement of inter connected plates of hepatocytes, separated by endothelium lined sinusoids, (see figure 29.5 & 29.6)

The liver plate cells are arranged radially around the central vein; the liver cells that surround a portal tract comprise the limiting plate. Liver cell plates are normally one hepatocyte in thickness.

Figure 29.1: Location of liver in abdomen

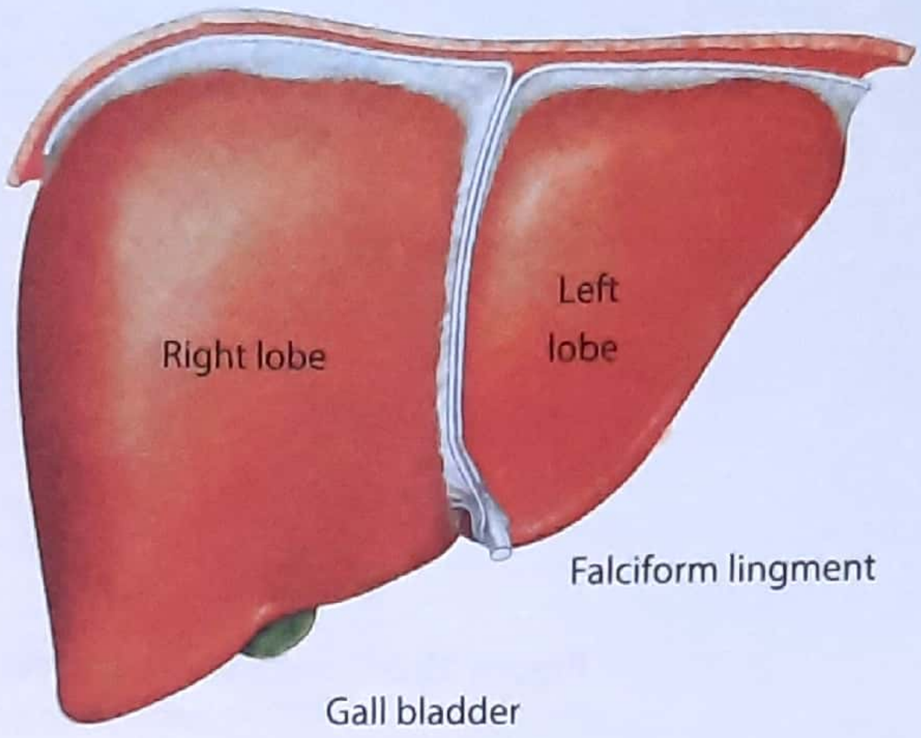

Figure 29.2: Anatomical division of liver

Liver cells are separated from the sinusoids by a narrow space (space of Disse) that contains connective tissue.

Specialized cells of the macrophage system (kupffer cells) are present in the sinusoids scattered among the endothelial cells. *(MANY PGME)*

The biliary system begins, at the biliary canaliculi. The biliary canaliculi form the intralobular bile ductules which drains in the portal triad. (Fig. 29.5 and 29.6)

- Bare area of liver - It is large triangular surface of liver devoid of peritoneal covering.
- It is a site of portacaval anastomosis
- It is site from where infection can spread from abdomianl to thoracic cavity.
- Still covered by glisson's & fibrous capsule.

Segmental (Functional anatomy)

The division of the liver; into ***eight*** different segments **functionally by Couinaud based on portal veins & hepatic vein** *(NEET)* is useful for carrying out segmental resection of the liver. (Please see figure 29.4)

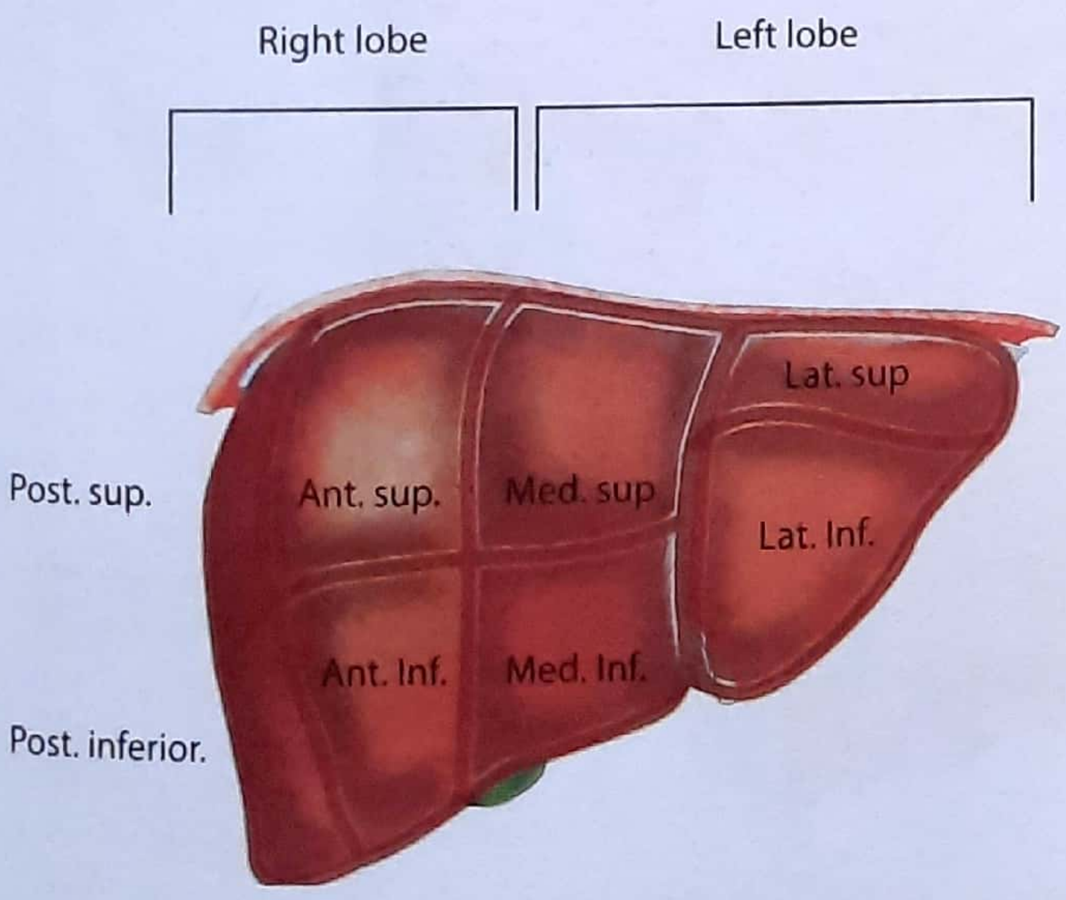

Figure 29.3: Segmental (Functional) division, Right & left lobe and its division

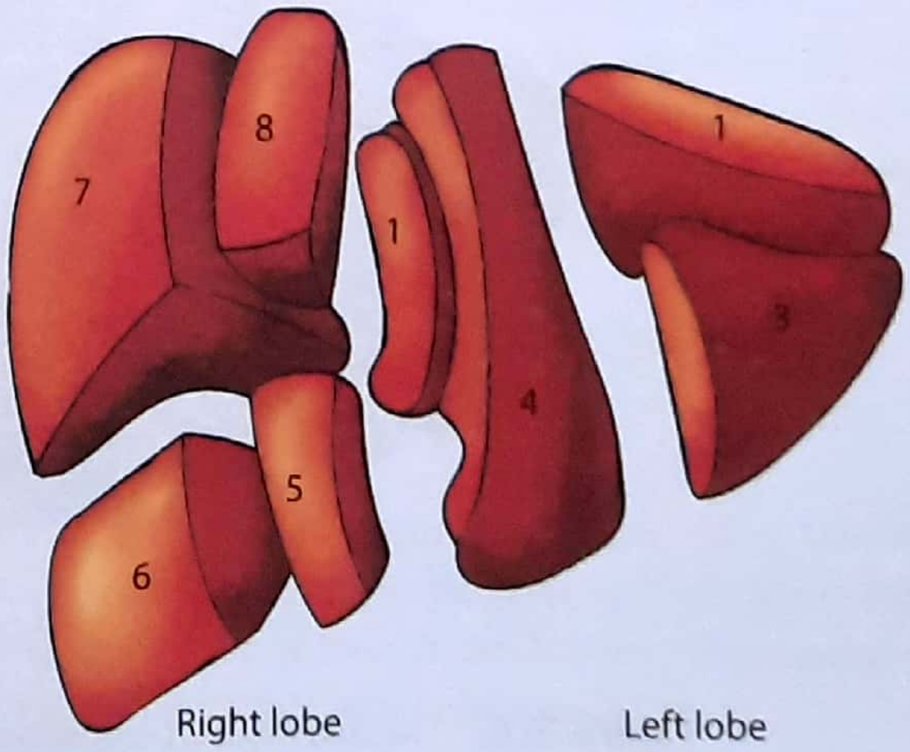

Figure 29.4: Functional anatomy of liver *(AI 08, 11)*

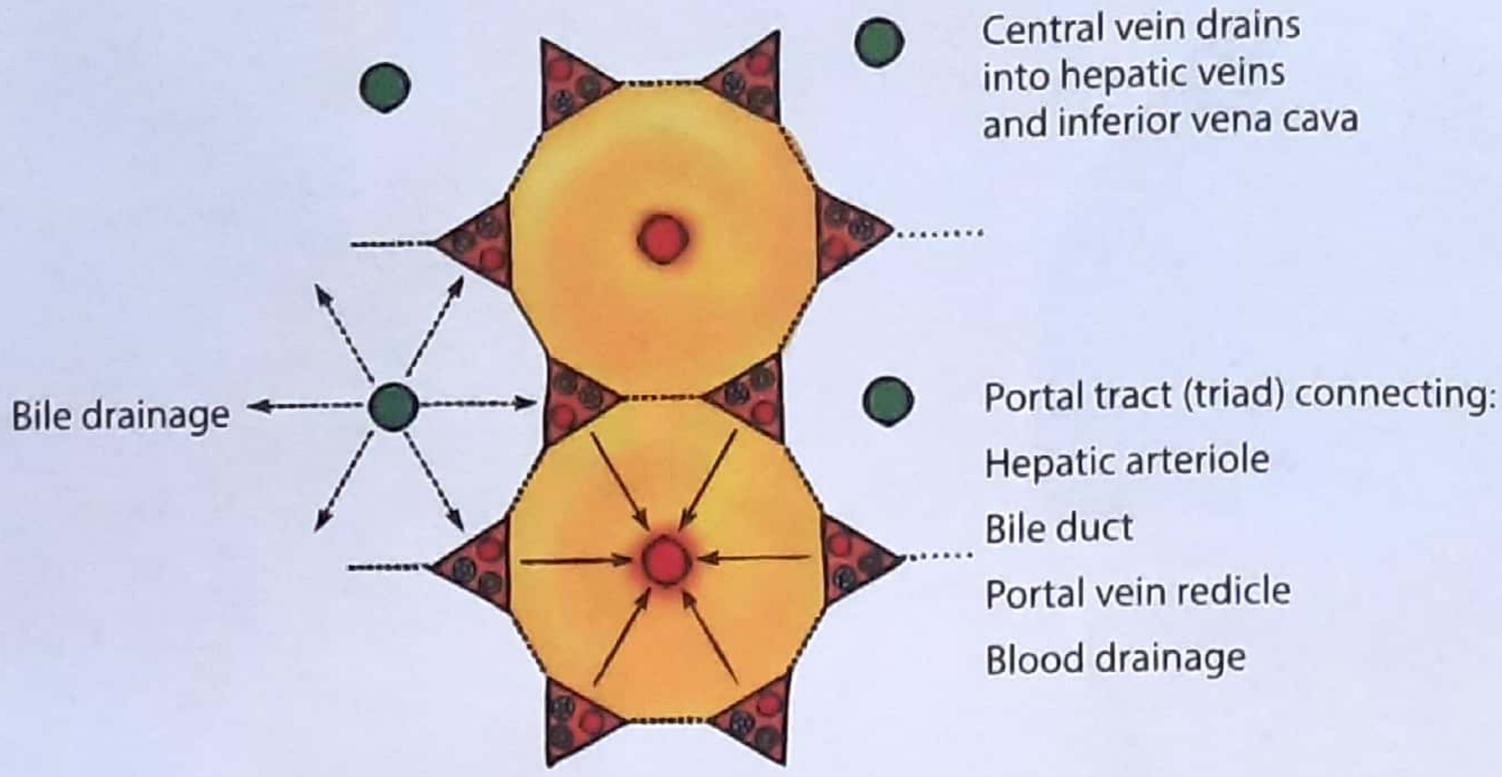

Figure 29.5: Liver lobule architecture, showing blood and bile flow

The **liver is functionally divided into right and left lobe by the principal *plane which is marked by a line*** *(Cantlie's line)* ***drawn between the bed of gall bladder (Gall bladder fossa) anteroinferiorly and inferior vena cava; posteriorly*** *(NEET, AIIMS 85, 87)*. This imaginary line divides the liver in (Cholecysto-caval line) two functional lobes: right lobe and left lobe. Please see fig. 29.7 and 30.6B.

The two lobes are supplied by corresponding right and left branches of hepatic artery, portal vein and drained by corresponding bile ducts. Each lobe is consist of four segments; supplied by the segmental vessels and drained by biliary duct.

Liver is devided into four portal sectors by branches of portal vein.

- Right lateral, Right medial, Left anterior, Left Posterior. *(AIIMS 15 MAY)*

Liver has 3 major (main, left & right portal) fissure & minor (umblical, venous & fissure of Gans) fissure.

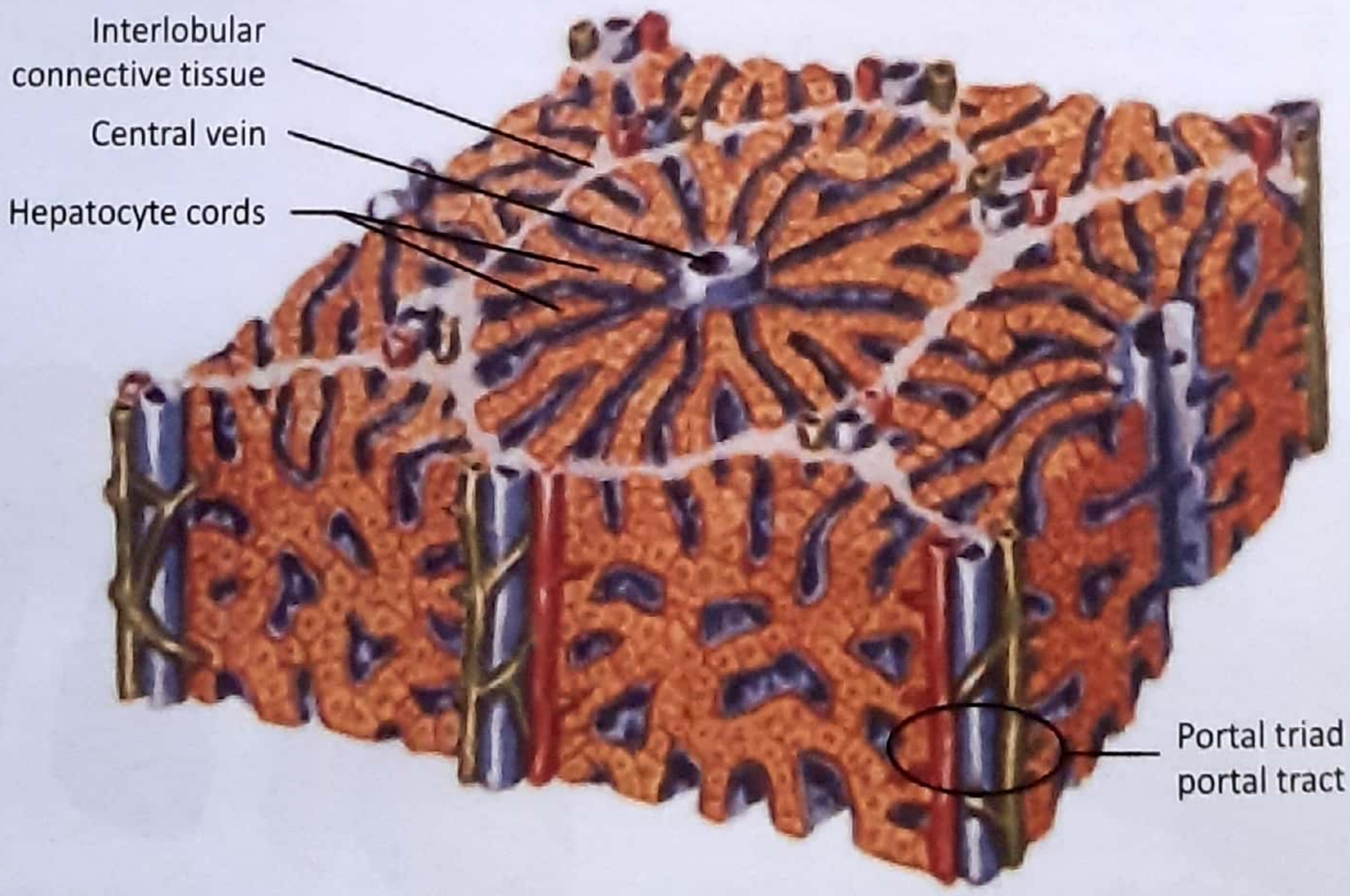

Figure 29.6: Hepatic lobule. Liver arranged as series of hexagonal lobules, each composed of series of hepatocyte cords (plates) interspersed with sinusoids. Each lobule surrounds a central vein and is bounded by 6 peripheral portal triads (low magnification)

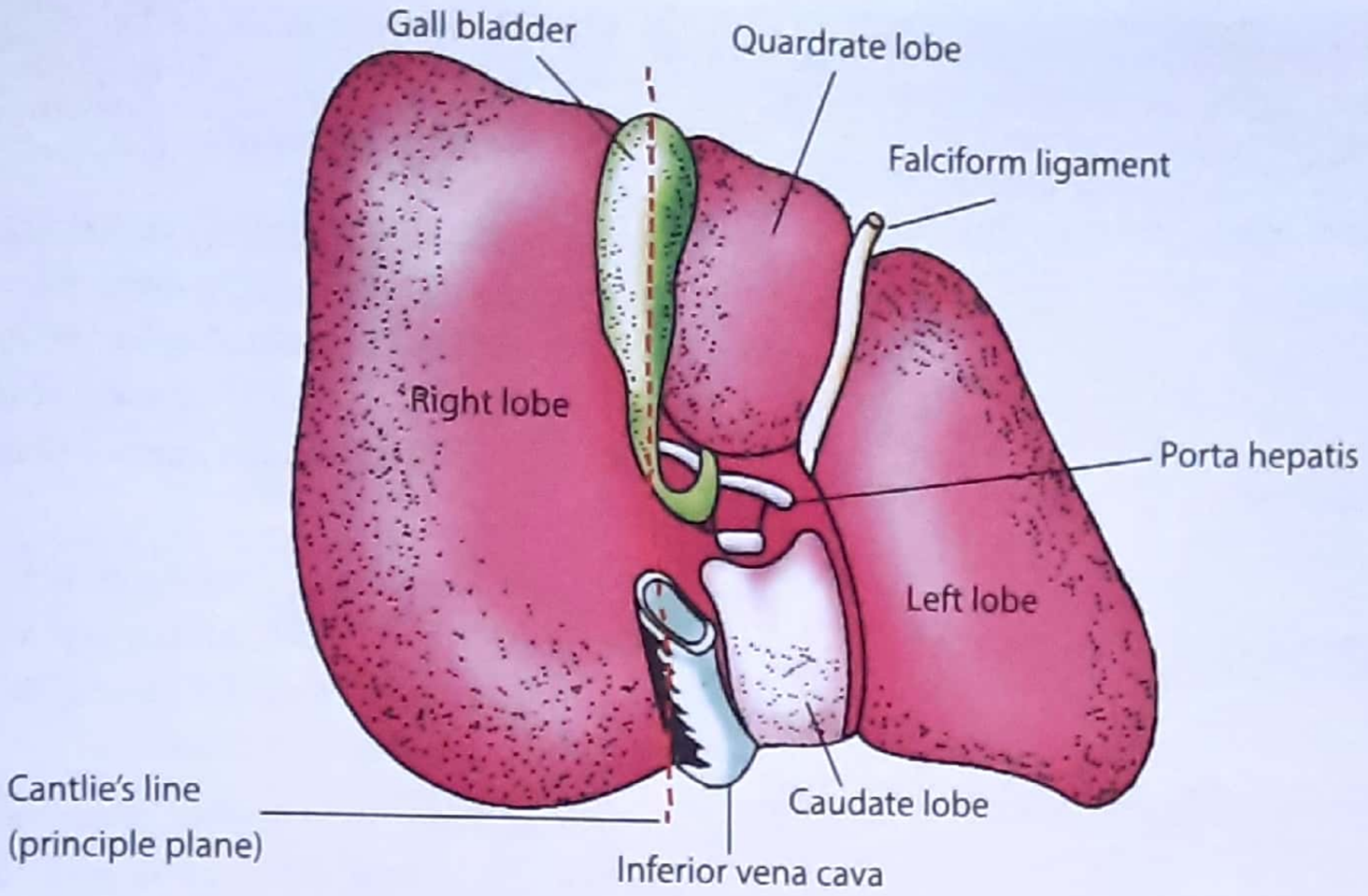

Figure 29.7: Surgical lobe of liver

Left lobe (I - IV)- [See figure* 29-4]

I - Caudate lobe (posteriorly)

II - Upper portion of left lobe

III - Lower portion of left lobe

IV - Quadrate lobe (interiorly) (AIIMS 07)

*The segment **I** is considered as **autonomous**. It is also called as spigelian lobe or caudate lobe. It has direct venous drainage to JVC.* (PGME)

Right lobe (V-VIII)

V, VI } Inferior portion of right lobe

VII, VIII } Superior portion of Right lobe

Left Lobe of Liver (Segment II, III and IV) are drained by Left hepatic duct.

Right lobe of Liver (Segment V, VI, VII and VIII) are drained by right hepatic duct.

Where as caudate lobe (Segment I) has its own biliary drainage which is through both right + left systems.

Blood supply

In an adult, liver receives about 40 percent of the cardiac output and gets 1500 ml of blood per minutes. About 80% of this supply comes through the portal vein (PGME) *at a pressure of 8-12 mm Hg.* This blood; though low in oxygen is rich is products of digestion and also contains the endocrine secretions from the stomach, pancreas and intestine. *The remaining (20%) blood supply comes from the hepatic artery, which is rich in oxygen and has a pressure 10-15 times higher than portal pressure (ie;-100-150 mm Hg).* (MANY PGME)

KEY BOX 29.1 (important)	
• **Blood supply of liver**	80% by Portal vein 20% by Hepatic artery
• **Pressure in**	Portal vein: 8-12 mm Hg Hepatic artery: 100-150 mm Hg Hepatic vein: 1-4 mm Hg

Porta-hepatis

This is also called as hilum of liver. It is a deep transverse fissure about *2* inch long, situated on the inferior surface of the right lobe of liver. It lies between the caudate lobe above and quadrate lobe below and in front.

The portal vein, the hepatic artery and the hepatic plexus of nerve enter the liver through porta hepatis,

while the right and left hepatic ducts and a few lymphatics leave it. *The relation with in the porta hepatis from posterior to anterior is "PAD".* (MANY PGME)

- Portal Vein (note: Portal vein is Posterior most structure)
- Hepatic Artery
- Bile Ducts

****

INVESTIGATION OF LIVER DISEASE

Before going in details, please go through flow chart given in key box 29.2 ; below.

Now lets take them one by one:-

A. Liver Function Test (LFT)

1. Test for liver secretion

The two substances commonly measured are plasma bilirubin & serum alkaline phosphatase. An excess of conjugated bilirubin indicate extrahepatic obstruction (eg; CBD stone, malignancy of CBD). Excess of unconjugated bilirubin implies failure of liver cells to take up & conjugate the bilirubin.

In urine, excess of conjugated bilirubin signifies extra or intrahepatic obstruction, and excess of urobilinogen indicates increased bile secretion in the gut, as in hemolysis or in liver cell failure.

An increase in Alkaline phosphatase activity may indicate cholestasis (stagnation of biliary excretion) of either extra or intra-hepatic origin.

Key Box29.2

Investigation of Liver disease

- (A) Liver function test (Biochemical tests)
  1. Test for Liver secretions
     - Serum Bilirubin
     - Serum Alkaline phosphates
  2. Test for liver cell synthesis
     - Serum Albumin
     - Prothrombin time
  3. Test for liver inflammation (injury)
     - Transaminase level
       (i) AST (SGOT)
       (ii) ALT (SGPT)
     - GGT(Gama glutamyl transpeptidase)
- (B) Imaging tests of Liver
  - Ultrasound
  - CT Scan
  - MRI
  - ERCP
  - PTC
  - Isotope scanning
  - Laparoscopy and laparoscopic USG
- (C) Biopsy

KEY BOX 29.3

Liver function tests: Normal values and changes in two types of jaundice.

Tests	Normal Values	Hepatocellular Jaundice	Uncomplicated obstructive jaundice
Bilirubin	0.3-1.0 mg/dL	Increased	Increased
Direct	0.1-0.3 mg/dL	Increased	Increased
Indirect	0.2-0.7 mg/dL		
Urine bilirubin	None	Increased	Increased
Serum albumin/total protein	Albumin, 3.5-5.5 g/dL Total protein, 6.5-8.4 g/dL	Albumin decreased	Unchanged
Alkaline phosphatase	30-115 units/L	Increased (+)	Increased (++++)
Prothrombin time	12-16 seconds	Prolonged if damage severe and does not respond to parenteral vitamin K	Prolonged if obstruction marked, but responds to parenteral vitamin K
ALT, AST	ALT, 5-35 units/L; AST, 5-40 units/L	Increased in hepatocellular damage, viral hepatitis	Minimally increased

2. Test for liver cell synthesis

The synthetic functions of liver are reflected by ability to synthesize protein (albumin level) and clotting factor. (MANY PGME)

In case of liver dysfunction, a decrease in serum albumin (ie; hypoalbuminemia) and decrease in clotting factors occurs. As a result of decreased synthesis of clotting factors, prothrombin time (PT) is increased.

3. Test for liver cell inflammation (injury)

Transaminase levels

Aspartate transaminase (AST) also called as Serum glutamic oxaloacetic transaminase (SGOT) and Alanine transaminase (ALT) also called as serum glutamic pyruvate transaminase (SGPT) reflects hepatocellular damage, as does Gamma glutamyl transpeptidase (GGT).

There level increases rapidly with hepatocellular injury. ALT is more specific for Liver disease than AST. (To remember ALT has L-Specific for Liver disease)

Alkaline phosphatase elevation of hepatic rather than bone, intestinal or placental origin are suggested by concomitant elevation of gama glutamyl transpeptidase.

Kindly go through key box 29.2 once again key box 29.3 above.

B. Imaging of The Liver

1. Ultrasound

- Ultrasound has now become *first line investigation* because of its safety and availability. It is used for determining.
  - Bile duct dilatation
  - Presence of gall stone
  - Presence of mass lesions (liver tumour, liver cyst)

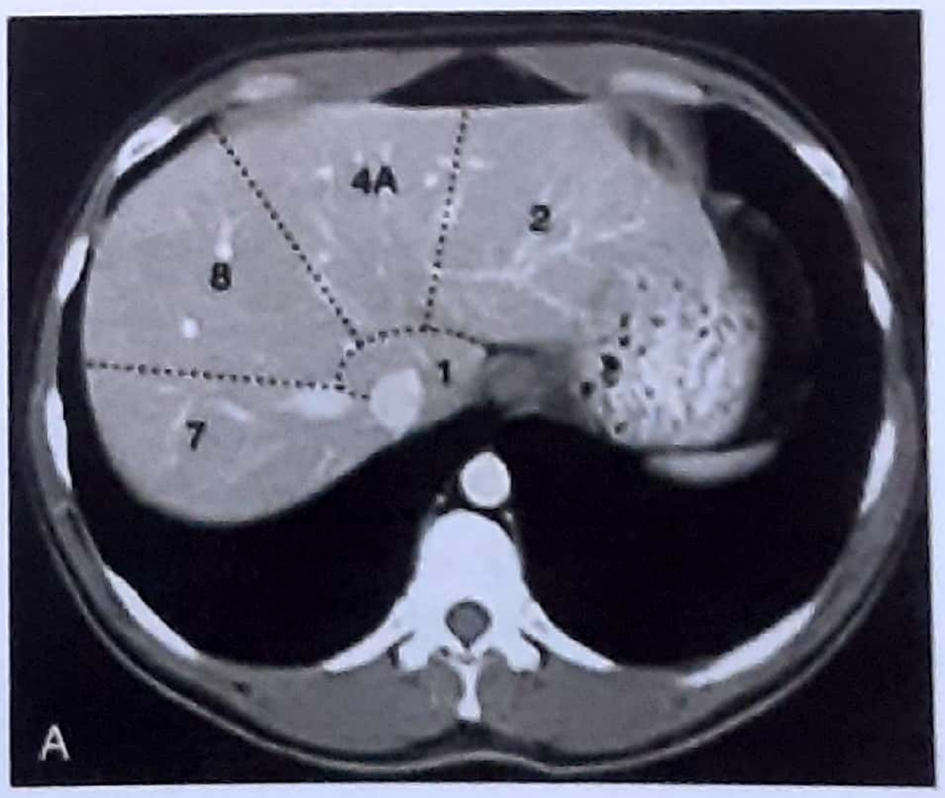

Figure 29.8 : CT Scan of liver

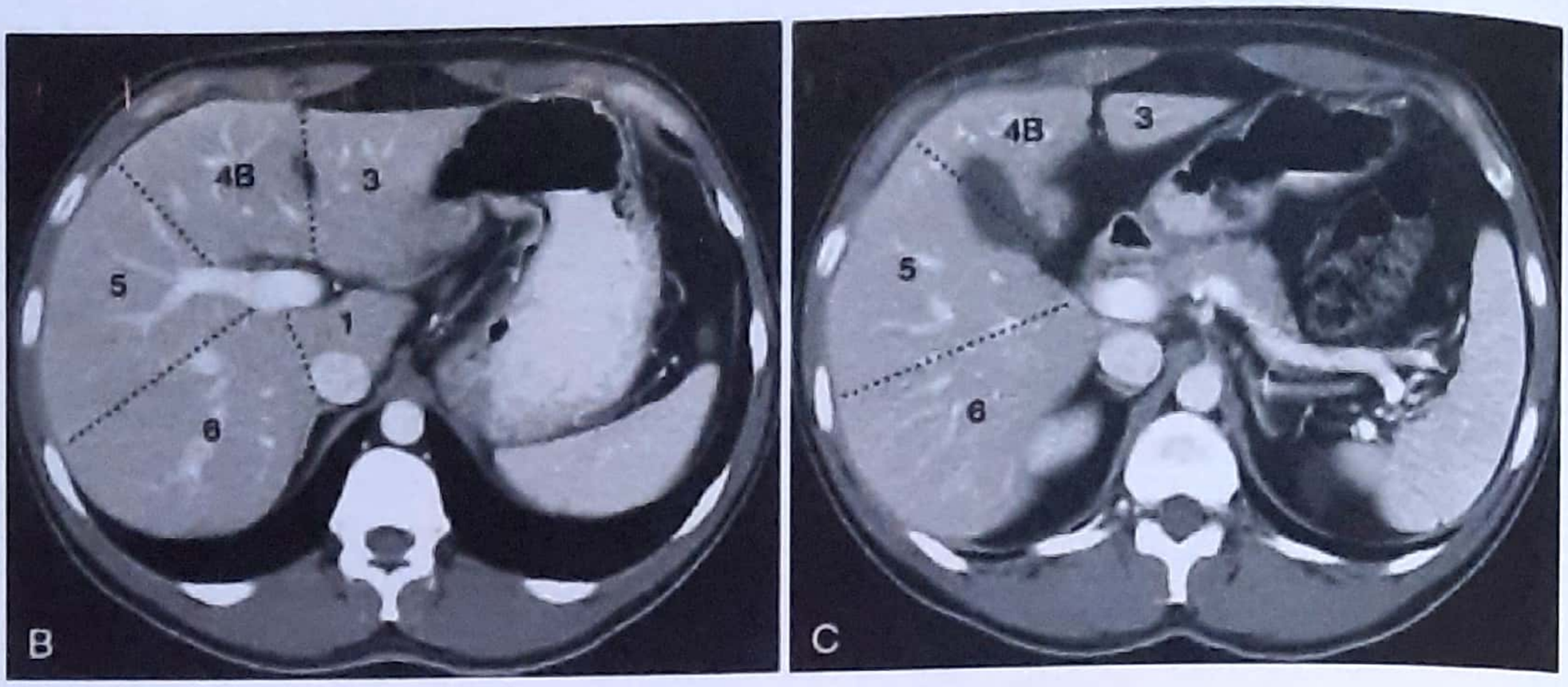

Figure 29.9 : CT Scan

- Doppler ultrasound allows flow in the portal vein, hepatic vein and hepatic artery to be assessed.
- Ultrasound can also be used to guide the placement of needle in aspiration of pus in liver abscess and obtaining liver biopsy.

2. CT Scan

Spiral CT Scan is currently *"Gold standard" investigation for liver imaging.* (IMP. POINT)

3. MRI (Magnetic Resonance imaging)

MRI is as effective as CT scan and has an added advantage over CT that it can be used in patients who have history of allergy to Iodine.

NOTE: Iodine is used as a contrast medium in triple phase spiral CT scan

- Magnetic resonance cholangiopancreatography (MRCP) can give excellent imaging of biliary tree noninvasively.
- Magnetic resonance angiography (MRA) provides high quality images of hepatic artery, and portal vein non invasively.

4. Endoscopic Retrograde Cholangio Pancreatography (ERCP)

Split the word

[Endoscopic + retrograde + cholangio + Pancreato + graphy.]

It is a radiography of cholangio (biliary duct system) and pancreatic duct system, by using an endoscope. The word "retrograde" used here means that the contrast, injected fills the biliary and pancreatic system is in retrograde manner.

Procedure

- Pre- procedure check of coagulation is essential.
- An endoscope is passed up to duodenum through oral cavity, stomach and duodenum to reach sphincter of oddi which is cannulated.

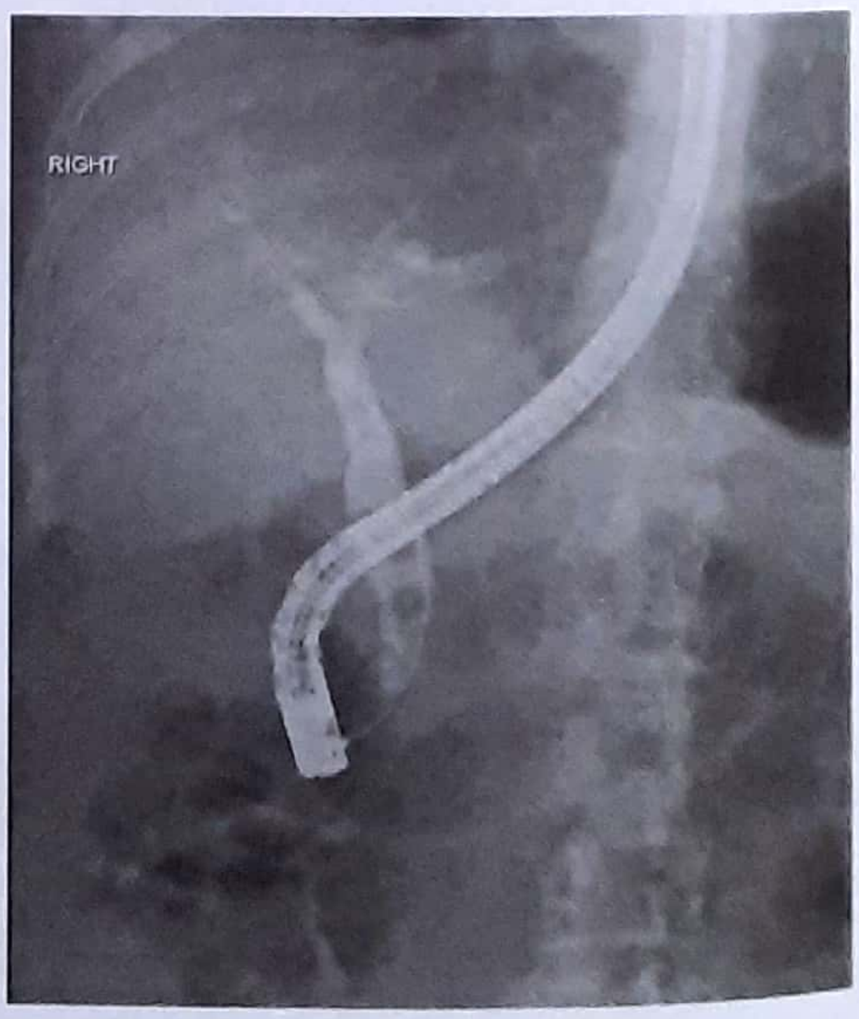

Figure 29.10 : Endoscopic Retrograde Cholangio Pancreatography (ERCP)

- A contrast media (usually 25% Hypaque) is introduced through this canula under fluoroscopic control.
- Both biliary & pancreatic ductal system fill by contrast
- Then a X-ray is obtained which provides beautiful image of pancreticobiliary system.

Interpretation

1. Stone if present in CBD will produce a filling defect (fillings defect means - defect in filling; meaning thereby-that portion of CBD will not be filled by injected contrast dye]
2. *Chronic pancreatitis may show the dilated main pancreatic duct and stones in pancreatic duct "Chain of lake" appearance.* (MANY PGME)
3. Periampullary carcinoma give rise to an irregular filling defect.

Therapeutic uses of ERCP

1. If stone in the CBD is found on ERCP, then it can be extracted at the same time by the endoscope.
2. Sphincterotomy (incising sphincter of oddi) can be done to make the passage wide, which facilitate the extrusion of small stone.
3. If any strictures *is* found in CBD - then balloon dilatation of stricture can be done.
4. Stenting of biliary duct stricture and pancreatic duct stricture.
5. Brush cytology of tumours to provide a tissue diagnosis
6. Endoluminal ultrasound of the biliary tract in possible using a 'baby' scope

Complication of ERCP

1. Acute pancreatitis (most common) (AIIMS 07)
2. Cholangitis (hence, prophylactic antibiotics are always used with the procedure)
3. Bleeding or perforations of duodenum related to sphincterotomy.

5. Percutaneous Transhepatic Cholangiography (PTC)

What is it ? split the word

Percutaneous + Transhepatic + Cholangiography

Percutaneous - effected through the skin

Transhepatic - Done through the liver

Cholangiography -radiography of bile duct system

- That means: Obtaining a radiograph of bile duct system, after injecting a contrast dye through the skin of right chest wall in the liver.

Procedure

- A fine calibre (23 gauge) needle is introduced into intrahepatic bile duct through skin of right lower rib cage. A contrast medium is injected through this needle into liver. Contrast medium is excreted by liver into bile duct, which reach CBD - a X ray is then obtained, which will tell about the biliary system anatomy.
- This test is often required when ERCP is failed or impossible such as - after Billroth II gastrectomy.
- **PTC** is more useful in visualizing Proximal biliary tree.{Note : ERCP is used to visualize End part, ie; distal part of biliary tree- that is distal CBD}

Please help yourself with figure 29.11

6. Angiography

Angio + graphy

=

Blood vessel + X-ray

Angiography may provide useful information of the blood supply and architecture of the liver.

It should be noted, that angiograhy is done after injecting a contrast medium in the blood vessel.

Figure 29.11: Percutaneous Transhepatic Cholangio-raphy (PTC)

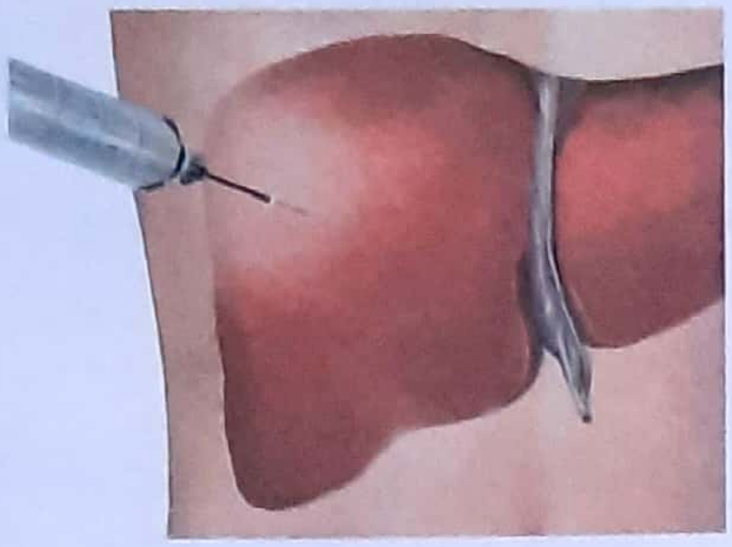

Figure 29.12 : Liver biopsy

7. Isotope Scanning

Technetium 99 labelled radio nuclide is administered intravenously. It is taken by the liver cells and is excreted in bile and this can be monitored by Gamma camera. Normally the scan outlines the liver and extrahepatic biliary tract include the gall bladder and shows the nuclide flowing into the upper small intestine as well.

8. Laparoscopy and Laparoscopic Ultrasound

This allows the direct visualization of liver. Laparoscopy is useful for staging of hepatopancreatobiliary cancers. Laparoscopic ultrasound may increase this figure and provides additional information with liver tumours.

Kindly go through key box 29.2 once again on page no. 460.

C. Liver Biopsy

Liver biopsy is a relatively safe method of obtaining tissue for histological examination. Blind biopsy using a cutting needle is indicated for diffused lesion of liver such as cirrhosis. Radiologically directed fine needle aspiration biopsy (FNAB) is indicated when it is necessary to examine a localized lesion. Figure 29.12.

RECAP: *Till now we were discussing surgical anatomy, and investigation part of liver diseases. Now lets discuss; diseases related to liver.*

****

LIVER TRAUMA

Liver injuries are fortunately uncommon, because of it's position under the diaphragm, protected by the right rib cage. Liver trauma can be divided as:- blunt traumatic injury or penetrating injuries (Please see key box 29.4).

KEY BOX 29.4

Liver Trauma

Blunt Trauma such as	Penetrating trauma such as:
- Road traffic accident	- Gun shot injury
- Fall from a height	- Stab injury

A blunt trauma can produce laceration, contusion or avulsion injury to liver.

Clinical feature

The liver is an extremely well vascularized organ and blood loss is therefore the major early complication of liver injury.

- The patient presents with the clinical features of massive intra-abdominal hemorrhage.
- Patient is pale, the pulse rate is high and there is marked hypotension.
- Urine out put is often decreased, due to hypovolemia.
- In a conscious patient, there is tenderness in right hypochondrium.
- Bowel sounds are sluggish or absent.
- If there is massive blood loss, abdomen may be distended due to collection of blood in peritoneal cavity.

Investigation

USG whole abdomen

An ultrasound may show presence of intraperitoneal blood, but USG does not help to clearly define the injury.

CT Scan

CT Scan is the investigation of choice in most hemodynamically stable patients having liver injury. The scan demonstrates the extent of the injury and provide a rough estimate of the amount of blood loss.

Abdominal paracentesis*

It is done in four quadrants of the abdomen. A blood stained fluid will confirm hemoperitoneum, but would not indicates the organ involved.

* *Paracentesis : Puncturing a cavity by needle and aspirating fluid*

Laparoscopy may help to demonstrate injury and an associated diaphragmatic rupture.

Management

Resuscitation is of primary importance as for any trauma, which includes intra venous fluid, blood transfusion, broad spectrum antibiotics, respiratory support and assessment of other organ injuries. Patients with stable minor injuries, can be managed conservatively ie;- nonoperatively, unless symptoms and sings of bleeding appears.

Indication for surgery in hepatic injury is persistent intraperitoneal bleed, and falling vital signs.

- Exploratory laparotomy is performed on all patients with a gun shot wound of the abdomen. On the other hand; selective non operative management (SNOM) is pursued for stab injuries to lower thorax & abdomen.
- In either case surgery is performed when there are signs of active intra peritoneal bleed - like rising pulse rate and persistent hypotension.

Surgery

- On laparotomy (opening up of the abdominal cavity), active bleeding should be managed by clipping or direct suturing of identifiable vessel.
- Temporary occlusion of the **hepatic artery and portal vein** can be done quickly by placing a vascular clamp around the **entire hepatoduodenal ligament**. This is known as **pringle's maneuver.** This can be done for period of 15-20 minutes and reduces the hemorrhage sufficiently to permit more accurate ligation of bleeding vessels. However with a major hepatic venous injuries; pringle's maneuver has a little role and precise repair of the injury may not be possible.
- In many cases when bleeding is difficult to control and especially other injuries are be addressed, the best strategy is to pack the liver with sponges [small sterile towels used during surgery], to achieve hemostasis. The packs are generally left in place for 48-72 hours, during which time the patient is kept

KEY BOX 29.5 (A)

Operative Management of Liver Trauma

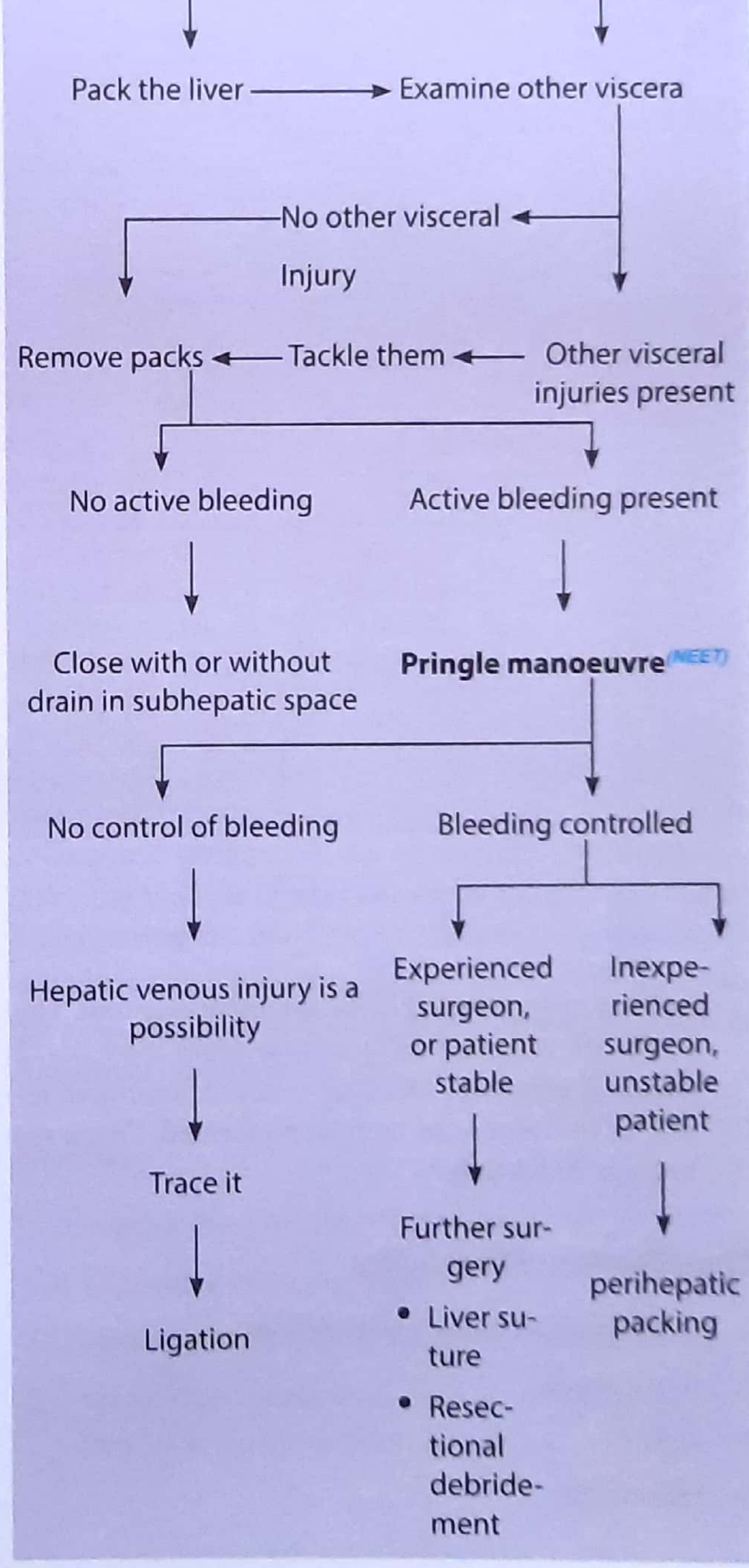

KEY BOX 29.5 (B)

Algorithm for the operative management of liver injuries.

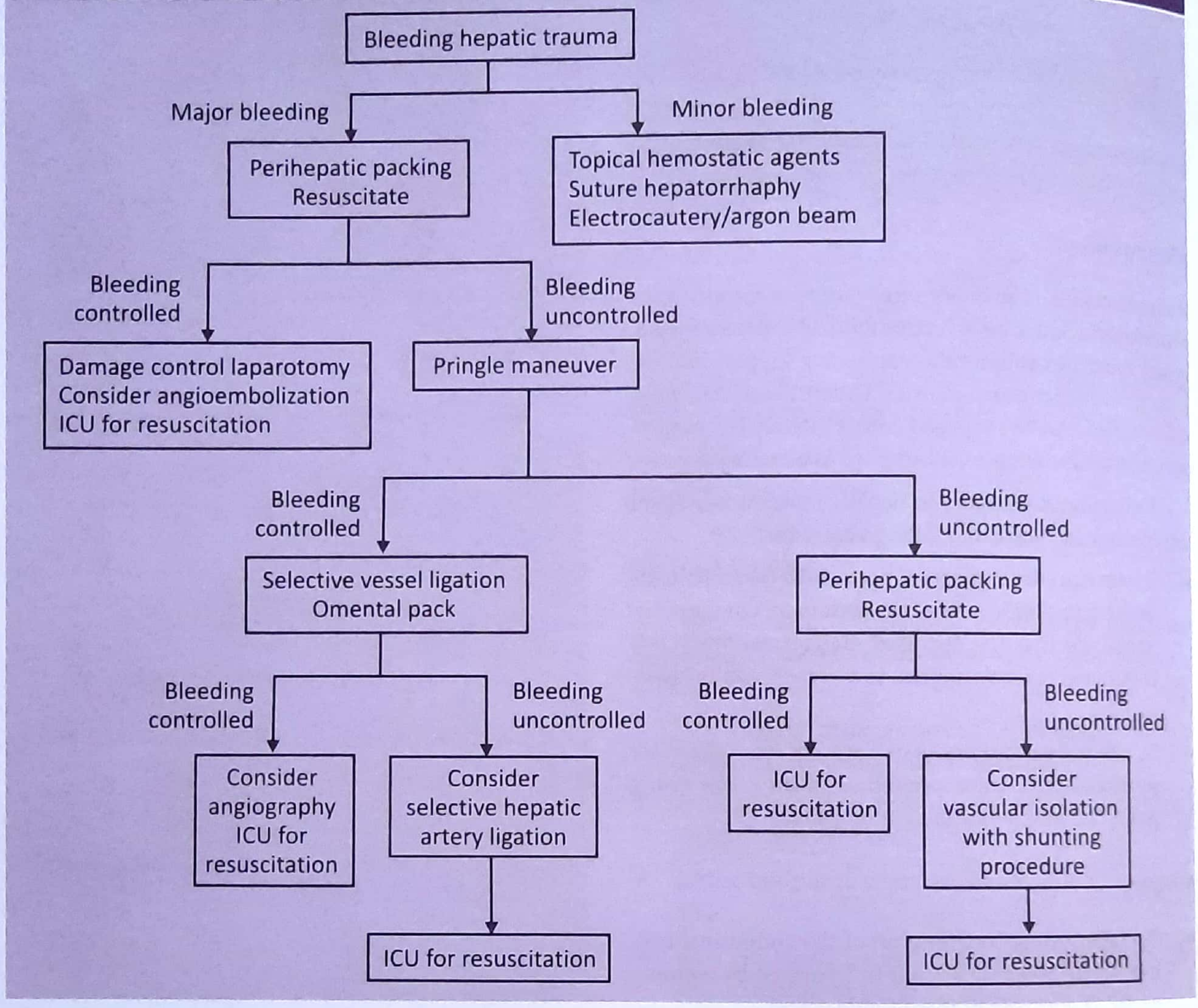

sedated and intubated in the intensive care unit. The packs are removed in operating room after 48-72 hours. If persistent bleeding is noted, definitive repair of the injury can then be performed. Please see key box 29.5A & B.

Complication of liver injury

1. Primary or secondary hemorrhage
2. Bile leakage
3. Sepsis
4. Hemobilia
5. Disseminated intravascular coagulation
6. Subphrenic abscess

****

HEMOBILIA *(AI 2000, AHMS 2000, 93, PGI 93)*

Hemobilia is rare, but when it occurs, it usually follows trauma to liver.

- It is caused by connection between a blood vessel (usually an artery) and a bile duct, ***most commonly after a traumatic injury to liver.*** *(NEET, UP 93)*

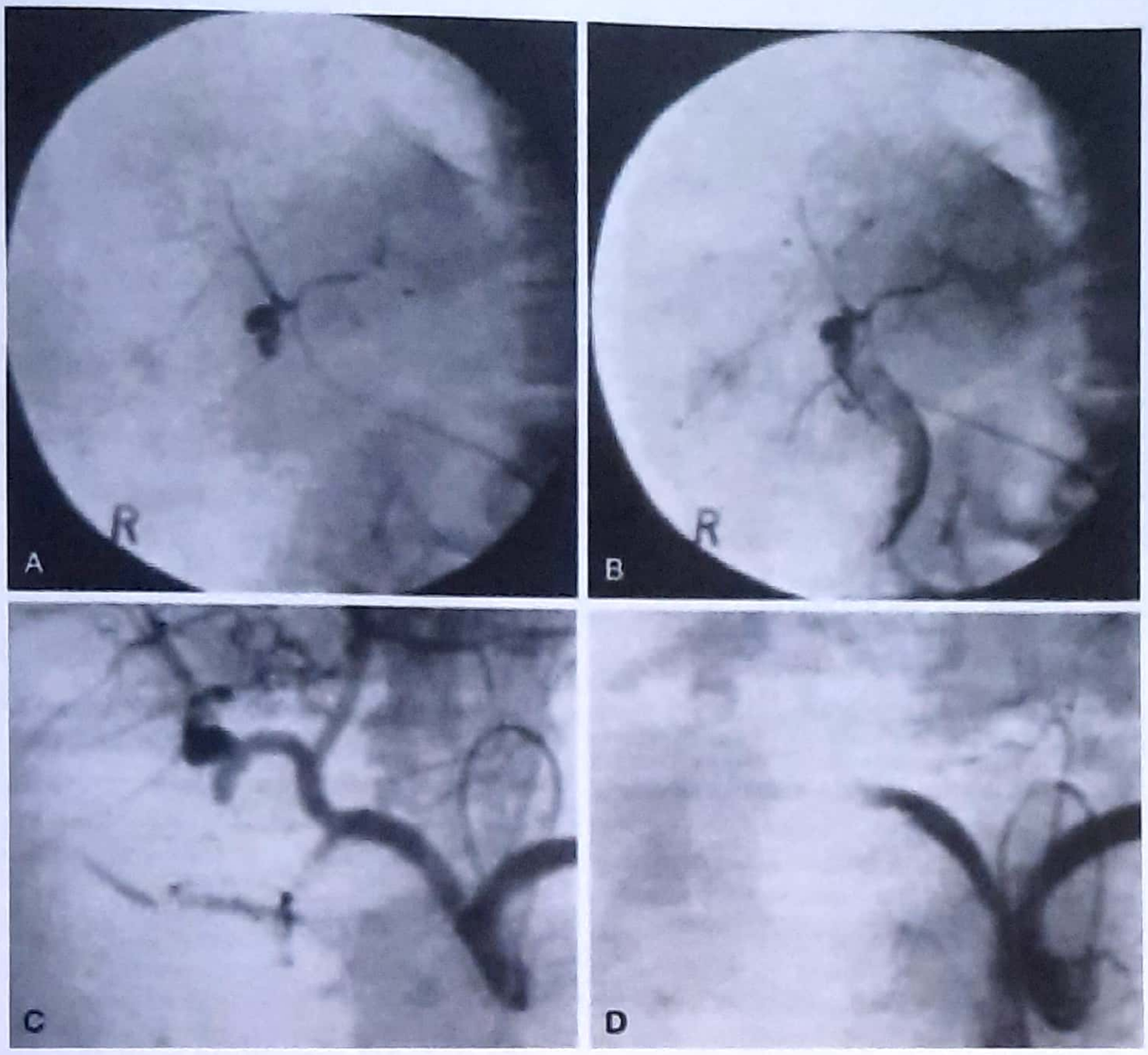

Figure 29.13 : Classic findings of hemobilia

- *Hemobilia presents with the triad of* ***biliary colic, obstructive jaundice, and occult or gross intestinal bleeding.*** *(NEET, AI 2000, UP 97)*
- In oriental countries hemobilia usually follows ductal parasitism (Ascaris lumbricoides) or oriental cholangio-hepatitis. Other rare causes are hepatic neoplasm, rupture of a hepatic artery aneurysm, hepatic abscess and choledocholithiasis.

Figure : 29.13

****

LIVER ABSCESSES

The liver is the organ most commonly subjected to the development of the visceral abscesses. Liver abscesses make upto 18% of all visceral abscesses. They may originate from bacteria (pyogenic), parasitic, or fungal pathogens.

In this section we will discuss Pyogenic liver abscess and Amebic liver abscess; one by one.

1. Pyogenic Liver Abscesses

Incidence

The pyogenic liver abscesses are present in 36% of autopsies and remain .constant for last 100 years. Ochsner and associates in their review reported a peak incidence of "bacterial abscesses in the 3rd and 4th decades of life, reflecting the role of appendicitis as the primary site of origin during this era. Presently, however the elderly are at highest risk for developing a pyogenic abscesses with the peak incidence of disease in the 7th decade. There is no predilection for either sex.

Etiology

The pyogenic liver abscesses results from:

(i) Ascending biliary infection.

(ii) Hematogenous spread via portal venous system.

(iii) Generalized septicemia with involvement of liver by way of hepatic arterial circulation.

Figure 29.14 : Liver abscesses, as shown on CT scan

(iv) Direct extension from intraperitoneal infection (sub-hepatic and subdiaphragmatic abscess).

(v) Traumatic

(vi) Cryptogenic

Pathogenesis

Pyogenic liver abscess, show the three main routes of bacterial infection, via (1) the bile duct (2) the portal vein (3) and the systemic circulation, etc.

Now let us take them one by one-

(i) Ascending biliary infection

Although the portal venous route was the most common etiology, before the wide spread use of antibiotics, *biliary disease now produce more pyogenic abscess than any other categories.* (MANY PGME)

Disease of the biliary system (CBD stone, stricture) currently account for more than 40% of pyogenic liver abscess and are the most common cause (NEET, AIIMS 95, 96, 98).

Most cases involve a partial or complete obstruction of the biliary tract with ascending cholangitis occurring in one third of these cases.

Benign conditions like acute cholecystitis, choledocholithiasis, benign stricture may lead to liver abscess.

Malignant biliary obstruction owing to pancreatic carcinoma, Cholangiocarcinoma and metastatic adenocarcinoma account for 20-40% of patients.

Other causes are biliary manipulation eg; Cholangiography, PTC, biliary stenting can well produce pyogenic liver abscess.

(ii) Hematogenous spread via portal vein

A portal venous source arising from intestinal pathology is found in 20% of patients with pyogenic liver abscesses (2nd most common cause).

(iii) Generalized septicemia

Direct extension and suppurative invasion of liver tissue by a subphrenic abscesses, perforated peptic ulcers and gangrenous cholecystitis are the antecedent processes in 6% of pyogenic liver abscesses.

(iv) Embolization

Embolization of bacteria, via the hepatic artery produces approximately 12% of pyogenic liver abscesses.

(v) Traumatic injury

Approximately 4-10% of pyogenic liver abscesses results from traumatic injuries to liver.

(vi) Idiopathic

The patients presenting with the cryptogenic abscesses ie; those of unknown etiology has remained constant for decade, despite improvement in diagnosis. Most series found that 20% of patient with a pyogenic liver abscesses will have no definable source of their disease. Typically patient with cryptogenic abscesses have coexisting disease (DM, malignancy, Immunocompromised). The majority of abscesses are solitary and contain a single species of anaerobic organism.

Other rare bacterial liver abscesses etiologies include superinfection of amebic or hydatid cyst of the liver.

Predisposing Factors

Co-morbid conditions associated with pyogenic liver abscesses differ by age groups.

In children: Chronic granulomatous disease, complement deficiencies, leukemia and other malignancy, sickle cell anemia, polycystic liver disease, endocarditis.

In adult: DM, cirrhosis, chronic pancreatitis peptic ulcer disease, Inflammatory bowel disease, jaundice, malignancy, chemotherapy, steroids, AIDS are common diseases.

Pathology

Generally liver abscesses are solitary and large, but pyogenic liver abscess may be multiple, while amebic liver abscess are usually solitary. (PGI 01). Overall pyogenic liver

abscesses localized to right hepatic lobe in 65% of cases, left hepatic lobe in 12% cases, while 23% have bilateral abscesses. Fungal hepatic abscesses are most often multiple, bilateral and miliary in nature.

Bacteriology

Gram -ve bacteria including *E. coli, Klebsiella, Enterobacteria, Proteus* species are isolated from 50-75% of liver abscesses. Most common organism being *E. coli and Klebsiella.* Anaerobic bacteria such as *Bacteroids, Fusobacterium, Clostridium and Peptostreptococcus* can culture from 40-50% of liver abscesses.

Gram +ve bacteria such as *Staphylococcus* and *Streptococcus* species occur in 30% of liver abscess & are commonly seen in children, diabetics, I.V. drug users, trauma victims and immunocompromised patients. Fungal species currently are being isolated at an increased frequency approximately 25% of liver abscesses, usually arises in patients with leukemia and lymphoma and other malignancy receiving chemotherapy.

Clinical Presentation

Symptoms and signs of liver abscess, are frequently vague and nonspecific. Most patients manifest symptoms for less than 2 weeks, but a more indolent course occur in approximately one third of patients.

Symptom

Fever is the most common symptom (more than 80%), chills with profuse sweating, weight loss, malaise, nausea, vomiting, right upper quadrant pain (> 50%). Anorexia, pruritus secondary to obstructive Jaundice may occur in as much as 15% cases.

Signs

Hepatomegaly is present in 40%, right upper quadrant abdominal tenderness or right costo vertebral angle tenderness in 50%, right hypochondrium lump, ascites, jaundice, right pleural effusion is present in 20%.

Investigation

Laboratory evaluation

There is no specific test that can invariably diagnose the disease. Leukocytosis (70%), anemia (>50%) are quite common. LFT (liver function tests) are not diagnostic. An increase in serum alkaline phosphatase (>90%), hypoalbuminemia (in>50%), Hyperbilirubinemia (in about 20%) are observed.

Radiology

USG/CT Scan: The diagnosis of liver abscesses in most patients is based on non invasive radiologic imaging studies, such as:- USG/CT. These studies are used in not only imaging the liver lesion, but also for guided aspiration of the abscess cavity, which greatly improves the diagnosis and management of these lesions. Finally these are useful in documenting abscess resolution during therapy. CT is better than ultrasound in diagnosing hepatic abscess.

Plain Chest X-ray is abnormal in 50% of patients. Findings are right pleural effusion, atelectasis, elevated hemidiaphragm, right upper quadrant gas, air fluid levels within the abscess cavity.

Confirmation of the diagnosis is done by aspiration of abscesses, *(IMP. POINT)*

Management

It involves elimination of both the abscess and underlying source. The corner stone for management of pyogenic liver abscess is:

(A) Appropriate antibiotic, therapy and

(B) Prompt drainage of purulent collection (Pus).

(A) Antibiotics : Antibiotics are used for about 4 to 6 weeks, 2 week I.V. then one month oral.

(B) Drainage/Methods of drainage

1. Aspiration : Provide valuable diagnostic and bacteriological data.

2. Ultrasound/CT guided percutaneous drainage

It is more useful in young solitary unseptate abscess, with 70-90% success rate. Absolute contraindication for aspiration; are associated biliary or intra-abdominal pathology, coagulopathy, anatomically inaccessibility.

Relative contraindications are multiple or multiloculated abscess, generalized ascites. Complications are sepsis, hemorrhage, bowel perforation, contamination of pleural and peritoneal spaces.

3. Surgical drainage

This is preferred less frequently than in the past. Indications are delineating intra-abdominal pathology, and provide concurrent treatment of both the abscess and its sources (viz; biliary stone, strictures).

Complication

40% of patient with liver abscess, develop complication which increases both morbidity and mortality rate.

- Generalized sepsis: Most common (85%).
- Pulmonary complication: Pleural effusion, empyema, pneumonia.
- **Rupture** - It is related to size and location of the liver abscess. The larger is the size; it is more prone to rupture and left lateral segment region abscess are more likely to rupture than right lobe region.

.....

2. AMEBIC LIVER ABSCESSES

Amebic infection of colon, liver and other organ are common in areas of poor sanitation and particularly in developing nation with contaminated water supply and poor public hygiene. ***Hepatic abscess is the most common (3-20%) extra-intestinal manifestations of amebiasis.*** (NEET) *Amebic abscess exceeds pyogenic abscess in frequency.* (PGME)

Etiopathogenesis

Amebic abscess is caused by the parasite *E. histolytica*, which travels from the bowel to liver, via the portal venous system. An asymptomatic individual sheds trophozoites and cyst in their stool.

Cyst are the infective form of amebic disease, surviving in the feces, soil or even in the chlorinated water supply. Infection of this organism usually occur after ingestion of contaminated water or vegetables. After ingestion of cyst, the small intestine digest the cyst wall, releasing immature trophozoites. *Adult trophozoites resides in the large intestine predominantly in the cecum* (MANY PGME).

Most trophozoites are small and non-invasive, and infected individuals may be asymptomatic or may proceed to develop amebic dysentery. Certain strain (large) of trophozoites can invade the colonic wall and cause desentery and colitis.

- Locally invasive amebiasis can cause, colonic hemorrhage, perforation, fistula and/or appendicitis.
- Distant sites of invasive amebic infection includes liver, brain & lung abscesses.
- Liver abscesses may arise from invasion of the portal venous system, mesenteric lymphatic channels or by intraperitoneal spread of microorganisms: Once organism reach in the liver parenchyma; microscopic sites of thrombosis, cytolysis and liquefaction develop, a process termed amebic hepatitis, when these sites coalesce an amebic abscess is formed. Understand with this flow chart.

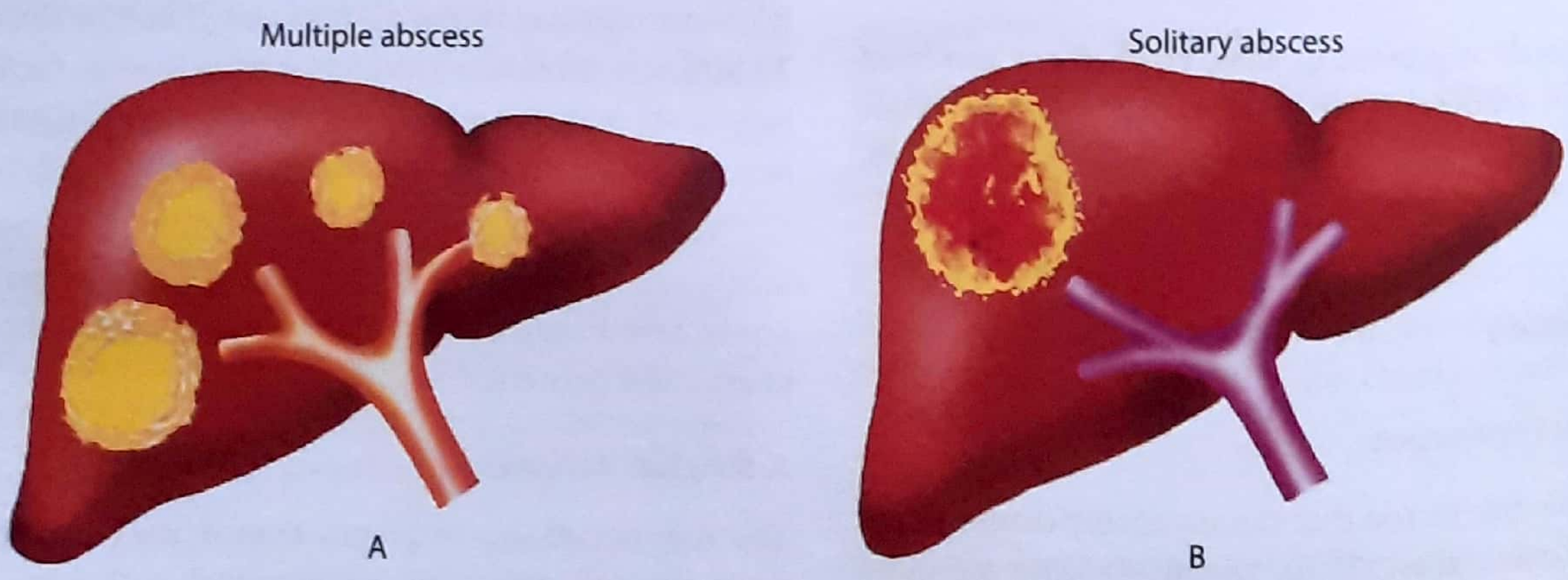

Figure 29.15 : Liver abscesses (A) Pyogenic liver abscess (B) Amebic Liver abscess

Cyst ingestion

↓

Release of trophozoites

↓

Invasive trophozoites

↓

Reach portal circulation

↓

To liver

↓

Liquefaction necrosis of liver parenchyma (Note: biliary radicals and blood vessels are spared)

↓

Amebic liver abscess

incidence

The incidence of amebiasis and amebic liver abscess has remained stable in the tropic and subtropical area. Amebic liver abscess occur more commonly in individuals from lower socioeconomic status because of poor sanitation, military personnel, immigration population.

- Only 7 percent of patients with amebiasis develop hepatic abscesses.
- It occur most frequently during the third and fourth decades of life.
- Although men and women develop amebic dysentery in equal number, but amebic liver abscess predominate in male with M/F ratio 9:1.

Pathology

The structure of an amebic liver abscess, consist of a fluid interior, an inner wall (it is ill defined layer of necrotic liver tissue and trophozoites, a biopsy of this layer often can confirm the diagnosis), and a connective tissue capsule (formed by host fibroblast cells). Classically, abscess fluid resembles **"anchovy sauce"** which is reddish brown in colour, a result of digested liver tissue and RBCs. (MANY MANY PGME)

Unlike bacterial abscess, amebic abscess fluid is typically sterile and odourless. *Amebic liver abscess more often* ***are located in right lobe of the liver (80%)*** (NEET, PGI 2000, ICS 05) *and often superficial and solitary (85%).* (MANY PGME, PGI 2010) Please see figure 29.15 & 29.16 & 29.17.

NOTE: **Anchovy is a small fish with a strong flavour, usually consumed as sauce in Europe.*

Diagnosis

Diagnosis of the amebic abscess is by isolation of the parasite from the liver lesion or from the stool, and confirming its nature by microscopy. Careful history, including epidemiological data, as well as certain radiological findings may suggest an amebic liver abscess. Serology is the corner stone for differentiating between the pyogenic and amebic liver abscess.

Clinical presentation

The most patients have symptoms similar, but mild than pyogenic liver abscess, history of antecedent diarrhea, pulmonary symptom and hepatomegaly are also more common with amebic liver abscess than pyogenic liver abscess.

Fever, jaundice and anemia are less frequent than pyogenic liver abscess. The **chief complaints** are upper abdominal pain (88%), fever with chills and sweating (75%), tenderness over the right lower intercostal space, there may be associated bulging and pitting edema of subcutaneous tissue.-Other common symptoms are nausea & vomiting (85%), anorexia (50%), weight loss (45%), diarrhea (40%).

Investigation

1. **Radiography :** Plain chest X-ray are abnormal in two third patient, findings are pleural effusion, pulmonary infiltration, elevated diaphragm.

2. **Ultrasound :** It detects 90-95% amebic liver abscesses. It *is initial investigation of choice.* (UP 2003)

3. **CT :** The sensitivity of CT is approximately 100%. *It can even differentiate between amebic and pyogenic abscess, with rim enhancement in the latter.* (MANY PGME)

4. **Serology :** It is necessary to confirm the presence of amebic disease and differentiate it from pyogenic liver abscess. *Serological methods are indirect hemagglutination, gel effusion precipitation, ELISA etc.* Indirect hemagglutination (IHA) test is the *most sensitive and specific test for non-invasive amebiasis.* (PGME)

5. **Diagnostic aspiration :** This remain valuable when the diagnosis of an amebic abscess is questionable or if

Figure 29.16: Computed tomography scan of amebic abscess

complication arise. Amebic trophozoites are demonstrated in the aspirated fluid in less than 1/3 of patient.

Treatment (PGI 08)

***Amebicidal agents are the treatment of choice* for amebic liver abscesses.** (NEET) Amebicidal agents commonly used are, imidazole (eg; Metronidazole), Emetine, Dihydroemetine and chloroquine(MAHE 07, PGI 2010).

Symptomatic improvement occurs within 2-3 days and imaging studies reveals a decrease in abscess size within 7-10 days.

If there is no improvement in clinical symptom within 48 hours of beginning of antibiotic, a complicated amebic abscess (due to secondary infection, rupture etc.) must be considered, for such cases percutaneous drainage, aspiration, or surgical drainage may be considered. These have been discussed below:-

1. USG guided needle aspiration

- It is indicated in case of liver abscess. It serves both diagnostic and therapeutic purpose. It reduces the tension in the abscess cavity,.so that tissue amebicidal have better effect.
- USG guided aspiration is the treatment of choice, where metronidazole is contraindicated, as in 1st trimester of pregnancy, **(imp. point)**

2. Surgical drainage

Indications are:

- Failure to respond to conservative therapy.
- Life threatening hemorrhage with or without concomitant abscess rupture.
- When amebic abscess erode adjacent viscus.
- Patient with septicemia, from secondary infected amebic abscess particularly if percutaneous drainage is unsuccessful.

Complication

About 10% of patient will develop complication. (PGI 2000)

(i) *Rupture :* may result in:

Lung as - Empyema, Lung abscess, pneumonia, pleural effusion.

Peritoneum - Peritonitis.

Pericardium - Pericardial effusion *(most serious complication)*

Right lobe lesion are more likely to rupture intra peritoneally, whereas left lobe lesion are more likely to rupture to pericardium or pleural space.

(ii) *Secondary infection*

(iii) *Erode into other surrounding structure*

Prognosis

Mortality rate is lower than the pyogenic abscess ie; 2-3%. Prognosis depends on the relative virulence of the organism and the resistance of host, the stage of infection, the multiplicity of the abscess and the presence of complication.

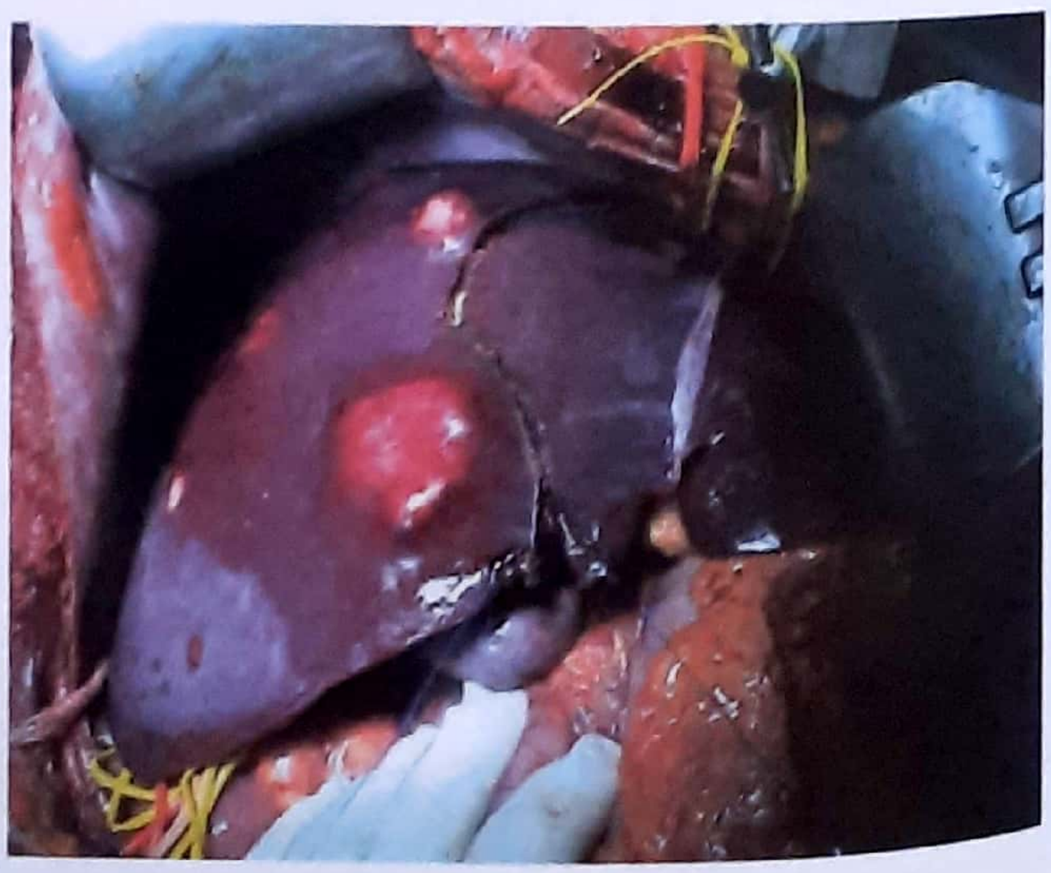

Figure 29.17 : On table photograph of liver abscess

In uncomplicated cases, mortality rate is less than 5%, where as in complicated cases mortality rate is up to 40%.

Differential Diagnosis

- Making the distinction between an amebic and a pyogenic abscess is essential. Most of the clinical features of both the disease are similar, but often the severity of symptoms appears to be mild in patients with amebic abscess than pyogenic liver abscess.
- Compared with amebic abscess, pyogenic liver abscesses are seen more often in patients older than 50 years and are associated with jaundice, pruritus, sepsis, a palpable abdominal lump, and elevated bilirubin and alkaline phosphatase level.
- Right quadrant pain is more common in amebic than pyogenic abscess. Patients with amebic liver abscess have past history of chronic amebic dysentery.
- Decreased breath sound at the right lung base, a right sided pleural effusion or a bronco pleural fistula are indicative of an amebic liver abscess, rather than a pyogenic abscess.
- However; it is very difficult to establish a diagnosis of pyogenic or amebic liver abscess clinically.
- *Serogical tests are definitive in establishing the diagnosis of amebic abscess* (PGME).

****

CYSTIC DISEASE OF LIVER

Please go through box 29.6, then only proceed

Poly Cystic Liver Disease

- Liver cysts are commonly seen in patients with autosomal **D**ominant inherited adult polycystic kidney disease (APK**D**) (MANY PGME)
- When liver cysts are present in patient with adult polycystic kidney disease, they are always multiple.
- *Despite the large number of liver cysts, hepatic parenchyma and function are usually well preserved.* (MANY PGME)
- *Results of liver function tests are almost always normal* (MAY BE A FUTURE PGMEE Q)
- Liver cysts are always preceded by kidney cyst and prevalence of liver cysts in adult polycystic kidney disease increases with age.
- *Liver cysts are generally asymptomatic, but in few patients large numerous cyst may cause abdominal pain and abdominal distension.*
- Rare complication can occur which include infection or intracystic bleeding.

KEY BOX 29.6

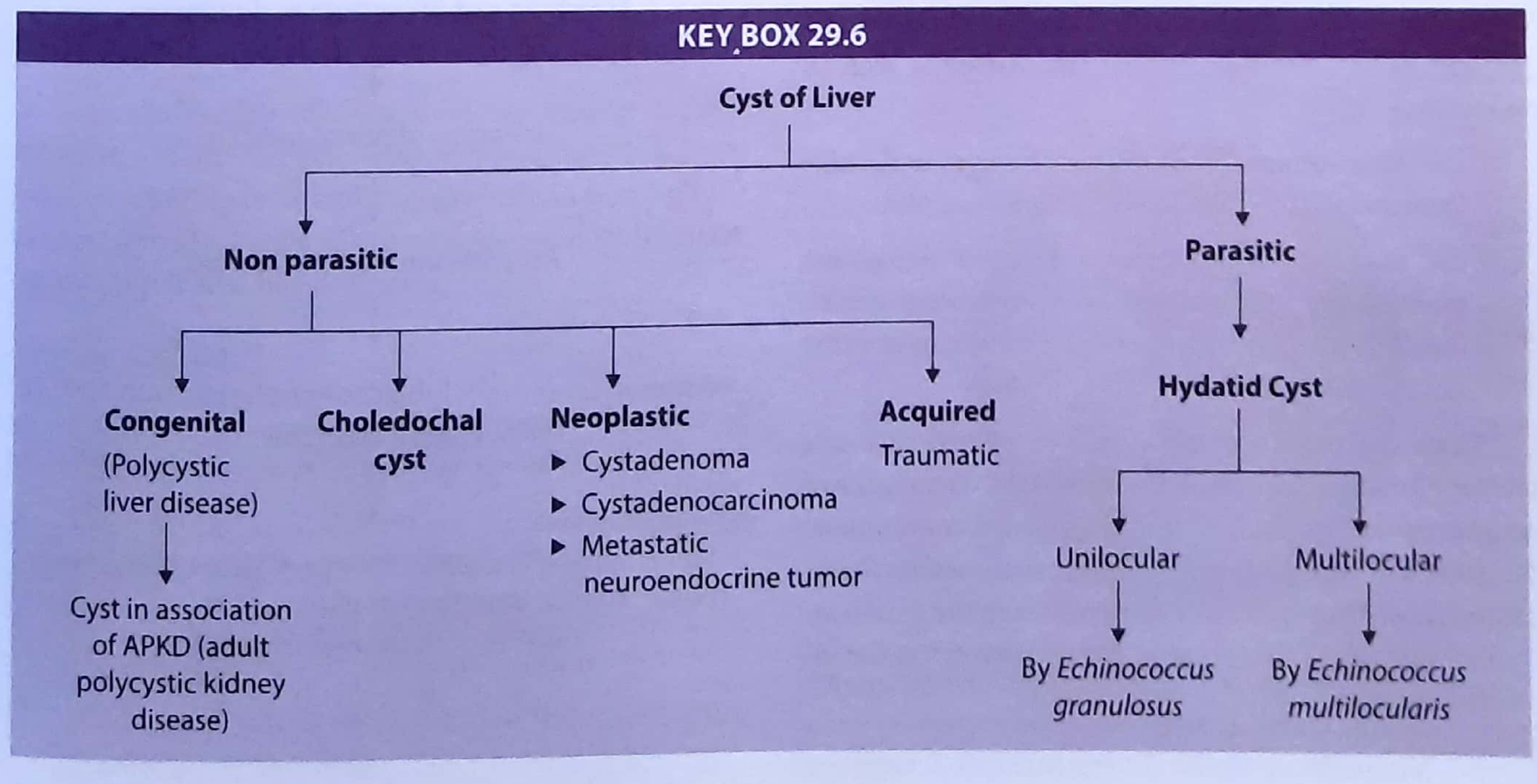

Treatment

- Treatment of polycystic liver disease is reserved for severe symptoms related to large cyst & complication.
- Treatment is by percutaneous aspiration with or with out sclerotherapy.
- Other treatment may include fenestration, hepatic resection or liver transplantation.
- Small & asymptomatic cyst does not require treatment. (IMP. POINT)

Neoplastic Cyst

- Cystadenoma of the liver is a rare neoplasm that usually present as a large cystic mass (usually 10-20 cm).
- Cystadenoma of liver mainly affect women older than 40 years.
- Cystadenoma tend to grow very slowly but can eventually progress to their malignant counter part; cystadenocarcinoma.

Traumatic Cyst (Acquired Cyst)

Injury to liver may be bile filled, solitary and have no epithelial lining. Cysts containing clear fluid can be unroofed, so that they drain into peritoneal cavity.

Choledochal cyst: This will be described in next chapter, The biliary system.

Hydatid Disease

This condition is caused by a parasite **called *Echinococcus granulosus*** (NEET, PGI 04, MANY PGME). The disease is seen in two forms:-

(i) the more common and relatively benign, *unilocular* form caused by *Echinococcus granulosus*, and

(ii) the uncommon; but potentially more dangerous *multilocular* form caused by *Echinococcus multilocularis* also (wrongly) called as malignant echinococcosis.

Dogs and other canines (foxes & wolves) acts as a primary host and harbour the adult worm. Thousands of hexacanth embryos released in dog's feces, contaminate the grass and vegetation and if this is consumed by sheep, cattle, camel, they (parasites embryo) reach the gastro intestinal mucosa of sheep, cattle, camel, who act as the intermediate host.

Human is an "accidental" intermediate host (MANY PGME)

Human can get infected by:

1. By taking uncooked vegetables contaminated with infected canine feces.
2. By direct handling of infected dog.
3. By allowing the dog to feed from the same dish. When ingested by human being, the hexacanth embryo hatches out in the duodenum. The embryos bore their ways through the intestinal wall, and enter the portal vein. The embryos are carried to liver by portal vein and are arrested in the sinusoidal capillaries *(First filter)* in more than 80% cases, and is lodged in liver, most commonly (about 90%) in right lobe. (MANY PGME)

In a small percentage (about 5-10%), the liver filter is by passed, to let the embryo lodge at distinct sites- like lungs, spleen, kidney, urinary bladder, bone etc. Where ever the embryo settles, it forms the hydatid cyst.

Summary

Infected dog (definitive host)

↓

Releases hexacanth embryo in feces

↓

Ingested by intermediate host (sheep, cattle) and *accidental intermediate host* [HUMAN] (PGME)

↓

Hatching out of embryo in duodenum

↓

Invasion of portal radicals

↓

Ascends through portal vein

↓

Lodges in Liver (right lobe commonly) in about 80% → *Liver hydatid cyst*

↓

Some bypass, liver and lodge at distant site like lung, spleen, kidney, or urinary bladder and result in hydatid disease of the respective organ.

Site of E. granulosus Cyst

Liver (M/C) *(MANY PGME)*	-	52-77%
Lung	-	8.5-44%
Abdominal cavity	-	8%
Kidney	-	7%
Central nervous system	-	2-4%
Bone	-	1-2

In this section we will discuss Hydatid cyst of Liver

****

HYDATID CYST OF LIVER

The cyst is formed by the embryo and a mature cyst consisting of 3 layer.

1. Outer - Adventitial layer
2. Intermediate - Laminated membrane or ectocyst
3. Inner - Inner germinal layer or endocyst

- The outer most adventitial layer consist of fibrous tissue and is grey in colour. See figure 29.18.
- Intermediate or ectocyst is formed- by parasitic cells.
- Inner of germinal layer (endocyst) is very thin. It is the vital layer of cyst and gives rise to
  - Brood capsule with scolices
  - Secretes hydatid fluid
  - Outer layer

Hydatid Fluid

It is clear colourless alkaline fluid. It contains sodium chloride, sodium sulphate, sodium phosphate. It is highly antigen, highly toxic and may give rise to anaphylactic reaction. Hydatid sand is granular deposits of liberated brood capsule and free scolices.

Clinical feature

- Hydatid cysts are diagnosed in equal numbers of men and women at an average age of 45 years.
- *About* **80% *of hydatid cyst are located in right lobe of liver and are single,*** *(NEET, MANY PGME)*
- *The clinical presentation of a hydatid cyst is* ***largely asymptomatic,*** until complication occur *(NEET, PGME)*.
- When *symptoms* develop, they are abdominal pain, dyspepsia and vomiting.
- The most frequent sign is hepatomegaly.
- Jaundice and fever occur only in only about 8% cases.
- Infection in a hydatid cyst can occur and then the patient presents like a pyogenic abscess.
- Rupture of the cyst into biliary tree or bronchial tree or free rupture into peritoneal, pleural and pericardial cavities can occur.
- Free rupture can result in disseminated echinococcosis and can produce potentially fatal anaphylactic reaction.
- *On examination:* Liver is often enlarged, has a smooth surface, round borders and is non-tender.

Special investigation

1. **Blood examination: will reveal eosinophilia.**
2. **Serological tests**: The ELISA, indirect hemagglutination test, casoni's test and complement fixation tests, which will be positive.

Casoni's Test

Intradermal injection of 0.2 ml of fresh sterile hydatid fluid produces a wheal of 5 cm in diameter. The sensitivity and specificity of this test is low, hence no long used these days.

3. **Ultrasound**: Is *most commonly used* world wide for the diagnosis of echinococcosis, because of its availability, affordability and accuracy.
4. **Plain X-ray abdomen**: May demonstrate *speckled calcification* in about 50% cases, calcified cysts may well be dead.

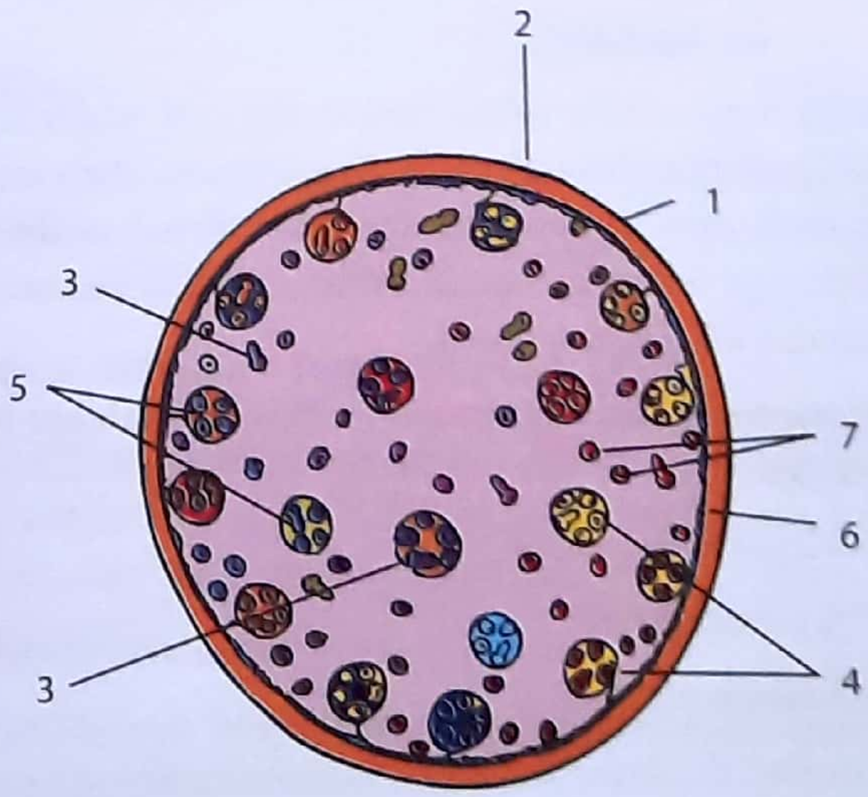

Figure 29.18: Hydatid cyst; 1. Outer gelatenous layer 2. Inner germinal layer 3. Gemmule 4. Brood capsule 5. Proc-to-scolex 6. Ectocyst layer 7. Sterile daughter cyst

5. **CT scan and MRI**: These studies can also help in evaluating extra hepatic disease, and demonstrate detailed hepatic anatomic relationship of the cyst.
6. **ERCP and PTC**: Is useful in patients with suspected biliary involvement of hydatid cyst.

Treatment

1. Medical Treatment

Though surgery has traditionally been the principal definitive method of treatment, but those patients who are poor candidates for surgery and with disseminated hydatid cyst, long duration of Albendazole is the mainstay of treatment. The dose of Albendazole is 10-15 mg/kg /day (equivalent to 400 mg twice daily for an adult) for three month without interruption. Most serious complication of long term albendazole treatment is *neutropenia.*

2. Surgical treatment

Currently ***PAIR is the preferred method of treatment is managing hydatid cyst in more than 75%.*** *(NEET, PGI 05)*

(i) PAIR - Percutaneous Aspiration, Infusion of scolicidal agents and Reaspiration.

This can be done under CT or ultrasound guidance.

P - Percutaneous

A - Aspiration (&)

I - Infusion of scolicidal agent (then)

R - Re-aspiration

A large bore needle is inserted in the cyst under CT or USG guidance through skin. The fluid in the cavity is aspirated, then a scolicidal agent is infused in the cavity through the same needle. After about 20 minutes the infused fluid is re-aspirated.

Various scolicidal agent used in Hydatid disease treatment are:-

- 20% hypertonic saline
- 0.5% silver nitrate
- 95% sterile ethanol
- Absolute alcohol
- Chlorhexidine
- Povidine iodine

NOTE: Formaldehyde should be not used as a scolicidal agent.

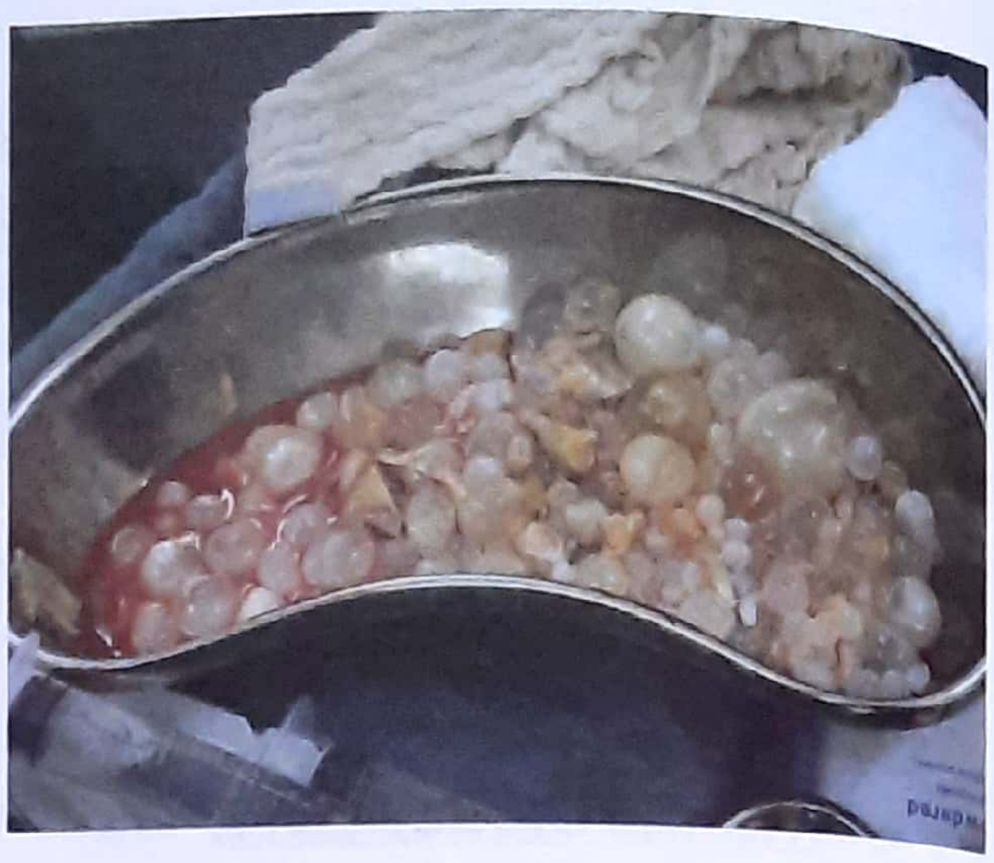

Figure 29.19: Hydatid cyst

Contraindication of PAIR

- Inaccessible or hazardous location of cyst
- Superficially located cyst (because of potential danger of rupture)
- Multiple septal divisions
- When there is direct communication between cyst and the biliary tree. [Because scolicidal agents injected in the cyst may come in contact with the biliary tree and cause sclerosing cholangitis].
- Dead or inactive cyst.

Figure 29.20 : (A) Peripheral hydatid cyst of the left liver (B) Intact specimen after pericystectomy.

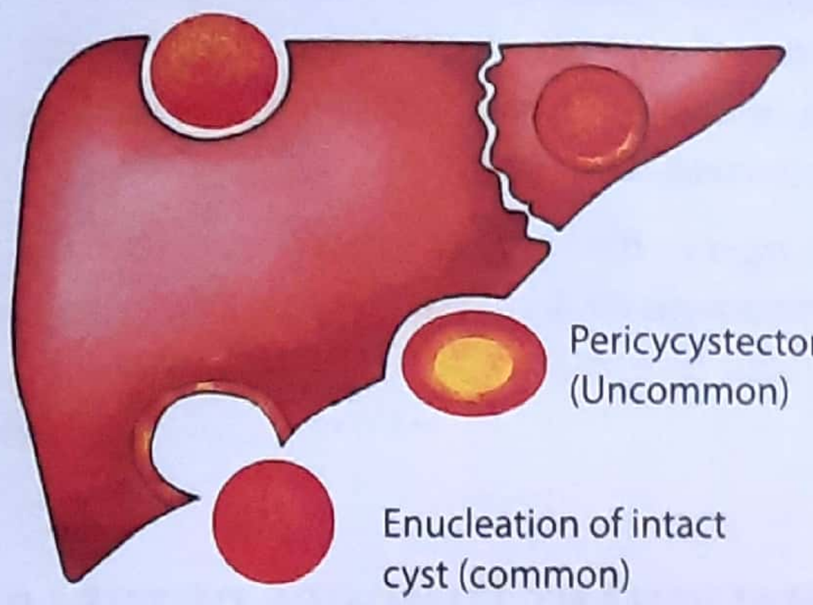

Figure 29.21: Surgical techniques for excision of Hydatid cyst of liver

(ii) Open surgical procedures

1. Cystotomy/partial cystectomy with drainage
2. De-roofing plus tube drainage.
3. Capitonnage : Obliterating the cavity by infolding the redundant cyst wall into cyst cavity and suturing, thus reducing the cavity.
4. Omentoplasty- After evacuation of the contents; the cavity is packed with greater omentum.
5. Hepatic resection. Please see figure 29.21.

Important Points

- Contamination of the peritoneal cavity, at the time of surgery with active hydatid cysts should be avoided by continuing preoperative drug therapy with albendazole and preoperative praziquantel.
- This should be combined with packing of the peritoneal cavity, with hypertonic saline soaked pack and instilling hypertonic saline into the cyst before opening the cyst.
- Albendazole should be continued in post operative period to prevent recurrence.

****

NEOPLASM OF LIVER

BENIGN NEOPLASM

1. Liver cell adenoma (LCA)
2. Focal nodular hyperplasia (FNH)
3. **Hemangioma (M/C benign neoplasm)** (NEET)

Now lets take them one by one:-

1. Liver cell adenoma

- It is a solid benign neoplasm.
- It is predominantly found in young women, between 20-40 years.
- *Chronic oral contraceptive use dramatically increases the incidence of this tumour.* (PGME)
- Female to male ratio is approximately 11:1.
- Liver cell adenoma are usually singular, but multiple lesions have been reported in about 10% of cases.
- The presence of more than 10 adenomas is termed as adenomatosis and interestingly cases with multiple adenomas are not associated with oral contraceptive use and do not have female preponderance.
- CT demonstrates a well circumscribed vascular mass.
- Two major risk for Liver cell adenoma are: (MANY PGME)

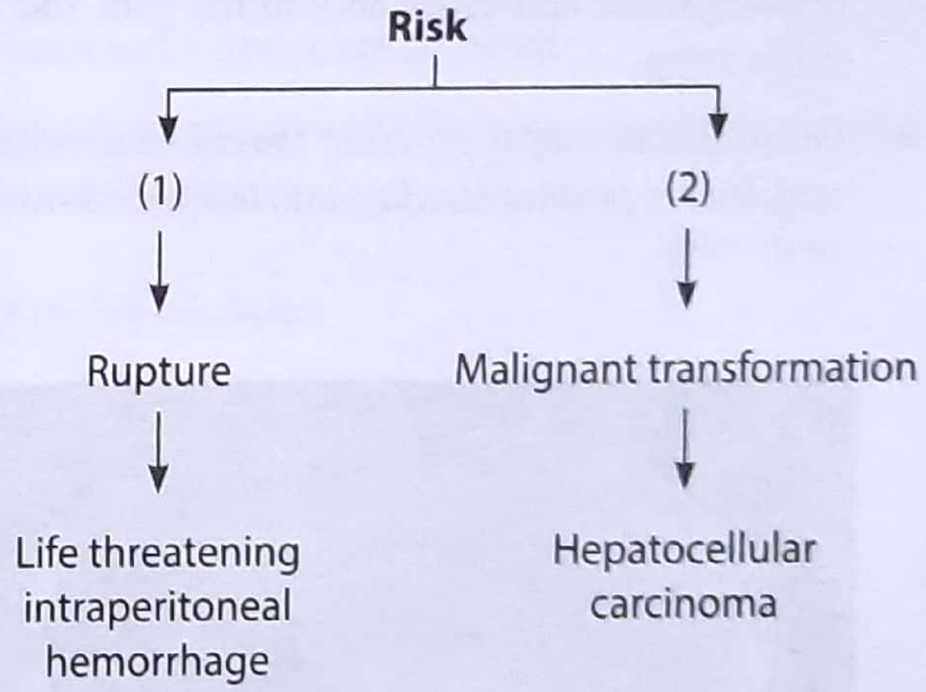

Treatment

Because the tumour has malignant potential, resection is advisable.

2. Focal nodular hyperplasia (FNH)

- This is an unusual benign condition, in which there is a *focal over growth* of functional liver tissue, supported by fibrous stroma.
- Patients are usually young women.
- The etiology of FNH is not well understood, but the most popular theory is that FNH is related to *developmental vascular malformation.*
- Female hormone and oral contraceptive agents have been implicated in the development & growth of FNH.

- The majority of nodules are *asymptomatic*, and are incidently found at laparotomy or autopsy.
- USG shows solid tumour mass.
- Malignant transformation of FNH has never been reported. (PGME)

3. Hemangioma

- *Hemangioma are the most common benign tumour of the liver.* (PGI 87, KAR 94, MANY PGME)
- It occurs in women more commonly than men. Female to male ratio being 3:1 and mean age being 45 years.
- Histologically, hepatic hemangiomas are of cavernous type, rather than capillary type.
- Most of them are small solitary growth that are found incidentally, during laparotomy or autopsy or an imaging (USG, CT)
- Rarely hemangioma grow to very large site (giant hemangioma) and cause abdominal pain and a palpable lump.
- *Percutaneous biopsy of lesion should be avoided as it may lead to profuse bleeding into the peritoneal cavity.* (MANY PGME)
- Most of them are *asymptomatic.* (PGME)
- The only reason to resect hemangioma is for symptom most commonly pain. Symptomatic hemangioma should be excised by hepatic lobectomy or enucleation.
- Surgery for asymptomatic hemangioma is not recommended.

****

MALIGNANT TUMOURS OF THE LIVER

HEPATOCELLULAR CARCINOMA (HCC)

(Some time inappropriately called **hepatoma**).

Liver malignancy may arise from hepatocyte (hepatocellular carcinoma, the most common) or from biliary epithelial cells (intrahepatic cholangiocarcinoma).

Neonates may also develop a variant of hepato cellular carcinoma; called hepatoblastoma because it is morphologically similar to fetal liver.

Etiology of HCC

[Mnemonic"ABCDD"]

1. **Aflatoxin consumption Aflatoxin is a fungal** metabolite and is present in staple food (eg; ground nuts and grain) in some parts of Africa, where hepatoma are common.

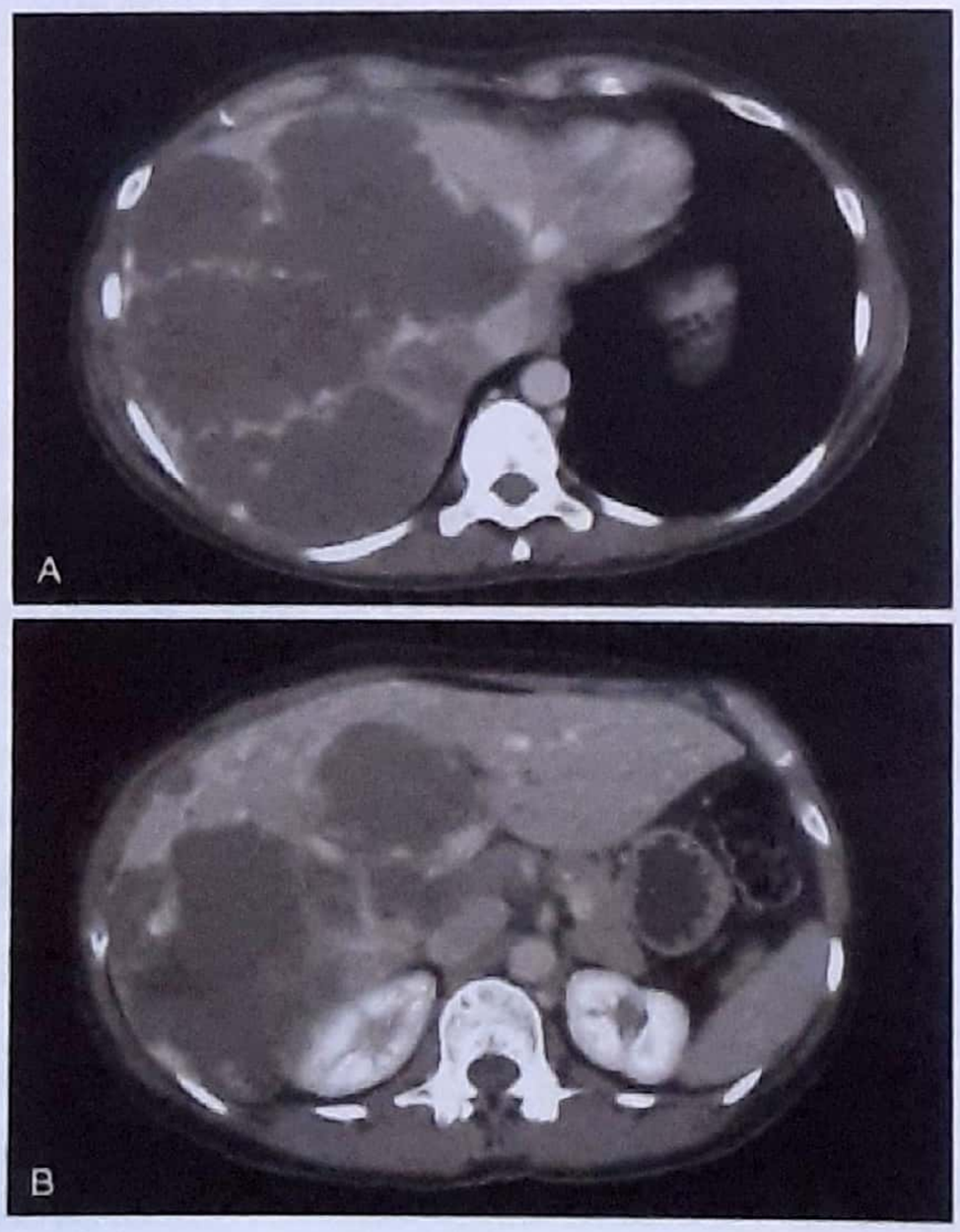

Figure 29.22 : Computed tomography scans of a large cavernous hemangioma showing displacement of left and middle hepatic veins and abutment of the left portal vein.

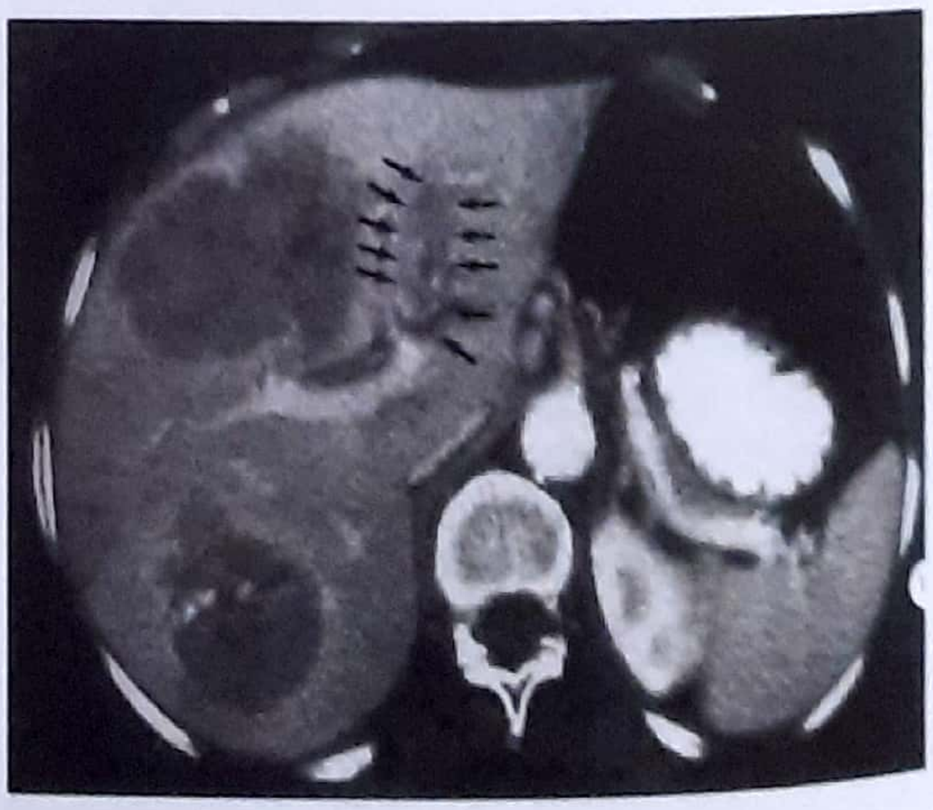

Figure 29.23 : Contrast-enhanced computed tomography scan demonstrating multifocal hepatocellular carcinoma. The left portal vein is invaded and expanded by tumor (arrow).

2. Chronic **Hepatitis B** and **C** virus infection is the principal etiological factor world wide for hepatocellular carcinoma *(PGI 97)*.
3. **Cirrhosis** from almost any cause- eg, alcoholism, hemochromatosis, α_1 antitrypsin deficiency or primary biliary cirrhosis may cause HCC.
4. **Oral contraceptive pills (Drugs)** - are known to cause adenoma and there is a chance of adenoma turning into HCC.
5. Dietary factors

Clinical features

- *Hepatocellular carcinoma constitute about 85% of primary hepatic cancer.*
- Hepatocellular carcinoma should be suspected when a patient with known cirrhosis presents with a new symptom such as pain, weight loss, hepatomegaly, fever and rapidly increasing ascites.
- *Jaundice is rare* (<5%) in cases with HCC. *(AI 94)*
- Most patients are male in their sixth decade of life
- **Symptoms as a result of paraneoplastic syndrome**
  - Hypoglycemia d/t insulin like polypeptide
  - Polycythemia d/t erythropoietin (d/t = due to)
  - Hypercalcemia d/t PTH like polypeptide.

Tumor Markers for HCC:

1. Alpha feto protein (AFP) and AFP-L3
2. desgamma-carboxy prothombin (DCP) aka PIV-KA-2
3. Glycipan-3 (GPC 3) aka MXR7

also, Neurotensin and vit B_{12} binding globulin are markers for fibrolamellar variant of HCC.

aka = also called as

Investigation

1. Liver function test

The results of LFT are usually abnormal; with reversal of Albumin/globulin ratio.

2. Alpha - Fetoprotein

It is a protein made by embryonal hepatocytes, and is elevated in 70-90% of cases of HCC. *(PGI 03)*

3. ***Hepatic Ultrasound, CT Scan, MRI, angioportography*** are the most reliable studies for determining the presence and operability of lesions. These studies are positive in up to 90% of cases and can detect lesion as small as 1cm in diameter.

4. Liver biopsy

The diagnosis can be *established* by percutaneous core biopsy or fine needle aspirations biopsy; which can be done under USG guidance *(PGI 02)*.

Coagulopathy is main contraindication for Liver biopsy. *(NEET)*

Spread

1. ***Direct infiltration*** to diaphragm, may result in persistent hiccups due to involvement of phrenic nerve.
2. ***Lymphatic spread***: The first and most commonly involved lymph nodes are at porta hepatis (hilar lymph nodes), later mediastinal nodes and left supraclavicular nodes are involved.
3. ***Hematogenous spread***: To lung causing malignant pleural effusion.

4. TNM classification

Primary Tumor (T)

TX	Primary tumor cannot be assessed
T0	No evidence of tumor
T1	Solitary tumor without vascular invasion
T2	Solitary tumor with vascular invasion or multiple tumors none more than 5 cm.
T3a	Multiple tumors more than 5 cm.
T3b	Single tumor or multiple tumors of any size involving a major branch of the portal or hepatic vein.
T4	Tumor(s) with direct invasion of adjacent organs other than the gallbladder or with perforation of visceral peritoneum.

Regional Lymph Nodes (N)

NX	Regional lymph nodes cannot be assessed
N0	No regional lymph node metastasis
N1	Regional lymph node metastasis

Distant Metastasis (M)

M0	No distant metastasis
M1	Distant metastasis

Anatomic Stage/Prognostic Groups			
Stage I	T1	N0	M0
Stage II	T2	N0	M0
Stage IIIA	T3a	N0	M0
Stage IIIB	T3b	N0	M0
Stage IIIC	T4	N0	M0
Stage IVA	Any T	N1	M0
Stage IVB	Any T	Any N	M1

Treatment

1. Partial hepatectomy :

It is the most effective therapy for HCC. Up to 7/8 of the liver can be resected. Rest of the liver will be enough to maintain life provided the remaining liver is healthy (non-cirrhotic).

2. Liver transplantation :

Hepatocellular carcinoma is the only solid neoplasm for which transplantation plays a significant role. Liver transplantation has the advantage of not only treating the malignant disease; but also underlying cirrhosis.

3. Ethanol Injection

Using ultrasound or CT guidance, 95% ethanol (5-20 ml) is directly injected through a 22-gauge needle in tumour. This approach can achieve complete necrosis in 90-100% of tumours <2cm, but its efficacy declines with increase in the tumour size. Ethanol injection is cheapest, easiest and least morbid ablative technique.

4. Radio frequency ablation :

"Ablation means removal"

In this, under USG or CT guidance, a percutaneous needle is used to access the lesion (tumour), this needle is attached to a radiofrequency generator, that generates thermal energy to bring about tumour destruction.

5. Arterial embolization

It is done by introducing a gel foam into a branch of hepatic artery. The feeding artery to tumor is embolized, which results in regression of tumour.

Key box 29.7.1
Treatment options for hepatocellular carcinoma
Surgical
Resection
Orthotopic liver transplantation
Ablative
Ethanol injection
Acetic acid injection
Thermal ablation (cryotherapy, radiofrequency ablation, microwave)
Transarterial
Embolization
Chemoembolization
Radiotherapy
Combination transarterial and ablative: external beam radiation
Systemic
Chemotherapy
Hormonal
Immunotherapy

6. Chemotherapy

Chemotherapy has been ineffective when given systemically, but administration of drug into hepatic artery has given some promising results.

7. Cryotherapy

****

FIBRO LAMELLAR HEPATO CELLULAR CARCINOMA

- Fibrolamellar HCC is a variant of HCC, but with remarkably different clinical features.
- Male to female ratio is 1:1.
- This tumour generally occurs in younger patients (AI 01) ***without*** *a history of cirrhosis.* Median age is about 25 years, (ie; in younger age group) (PGME)
- The tumour is well circumscribed, encapsulated and may have a central fibrotic area.

KEY BOX 29.7.2		
Comparison of (HCC) and fibrolamellar hepatocellular carcinoma (FHCC) *[PGI2000,02,93, AI 01]*		
Characteristic	**HCC**	**FHCC** *(AI01)*
Male : Female ratio	3 : 1	1 : 1
Median age (years)	55	25
Tumour	Invasive	Well circumscribed
Resectability	<25%	50-75%
Cirrhosis	Present in 90%	Not so
AFP positive	80%	not positive
Hepatitis B virus	65%	Rarely

- Fibrolamellar hepato cellular carcinoma does not produce Alpha feto protein. Please go through key box 29.7-2.
- In general FHCC has a *better prognosis than* HCC.
- This is likely due to high resectability rates (50-75% of this tumour).

****

INTRA HEPATIC CHOLANGIO CARCINOMA

- Cholangiocarcinoma make about 15% of primary liver cancer. It is an intrahepatic malignant tumour made up of cells that resemble biliary epithelium.
- *It is an adenocarcinoma and produce mucin.*
- Cholangiocarcinoma is infrequently associated with cirrhosis.

Predisposing Factors

- Primary sclerosing cholangitis
- Liver fluke *(Clonorchiasis sinensis)* infection
- Intrahepatic stone
- Ulcerative colitis
- Choledochal cyst
- Recurrent pyogenic cholangitis

Clinical feature

The clinical features are similar to that of HCC.

- The most common symptoms are right upper abdominal pain and weight loss.
- Jaundice is present in about 25% cases.

Diagnosis

- Diagnosis is usually made by USG or CT scan.
- Unlike in HCC; the AFP level is normal.

Treatment

Complete resection is the treatment of choice for IHC.

****

METASTATIC TUMOUR OF THE LIVER (LIVER SECONDARIES)

They are much *more common than primary tumours (ratio 20:1)* **(PGME MANY TIMES)**

The liver is the second most common site of metastasis (exceeded only by regional lymph nodes) for all primary cancers of the abdominal viscera. Over two thirds of all colorectal cancers ultimately involve the liver and up to 50% of cancers outside the abdomen metastasize to the liver. (Figure 29.24)

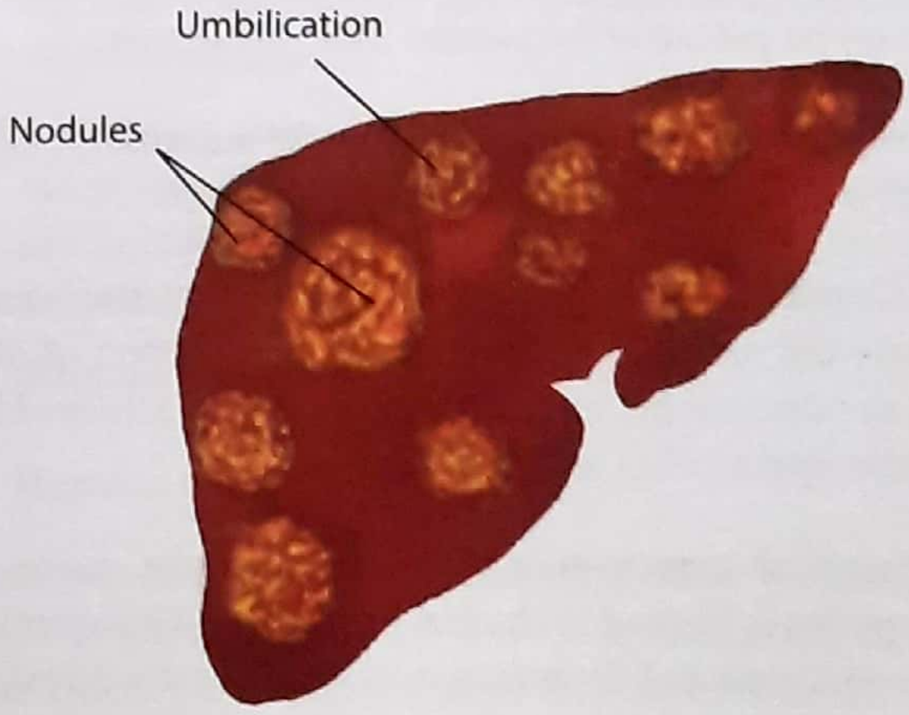

Figure 29.24: Secondaries liver

Diagnosis

It may often be difficult to make diagnosis of liver secondaries; because *liver metastases are often asymptomatic.*

(a) Laboratory studies

In a recent National Cancer Institute study, no single laboratory blood test could predict liver metastases in more than 65% of patients with subclinical disease. This percentage can only be increased by using imaging techniques.

(b) Imaging techniques

1. CT scan is the most accurate imaging technique, but it is expensive as a screening test.
2. Ultrasonography is almost as reliable as a CT scan, and it provides a reasonable screening test.

Treatment

Treatment for metastatic disease to the liver depends on the type of primary tumour. Because colorectal cancer has generated the most reliable statistics, those figures are cited here.

(a) Chemotherapy

For liver metastasis, particularly from colorectal cancer has been disappointing. Various agents used are:

1. Systemic 5-fluorouracil therapy has resulted in a response rate of 10%-30% and a median survival of 30-60 weeks.
2. Hepatic arterial infusion of floxuridine has shown an increase in response rate but little or no improvement in patient survival.

(b) Radiation therapy is poorly tolerated by the liver but may be palliative for painful liver metastases.

(c) Hepatic artery ligation may cause a dramatic shrinkage in tumor size, but this is only transient.

(d) Cryoablation or local freezing of the metastasis may palliate the symptoms and slow the progression of disease in unresectable metastases. This can be achieved by cryotherapy, alcohol and radiofrequency.

(e) Surgical resection is the most effective mode of therapy but is limited to the few patients who have unilobar liver lesion and no evidence of extrahepatic disease.

****

PORTAL HYPERTENSION

This a very important topic. You are strongly advised to read it carefully. I have tried to make things easier.

Before going into details of portal hypertension, one should know portal circulation, portal vein and normal portal pressure

Portal Circulation?

"Hepatic circulation in which blood from the abdominal organs passes through liver before returing to heart (right atrium)". Portal vein is formed by joining superior mesenteric vein and Splenic vein behind the neck of pancreas at L-2 (Please see figure 29.25, 29.26 A & B)

The veins of abdominal organs (superior mesenteric vein + splenic vein) unite to form portal vein, which takes the blood to liver → to sinusoids → to central vein of lobule and → eventually to hepatic vein, which empty into inferior vena cava and finally to right atrium.

The purpose of this pathway is to permit the liver to regulate the blood level of nutrients and other materials and detoxification of toxins present in blood.

Portal Vein

It is a large vein which is formed by **union of the superior mesenteric and splenic veins** *behind the neck of the pancreas, at the level of L2 vertebra* (MANY PGME). Please see figure 29.25.

Portal vein is about 8cm long and 1.2 cm in diameter. The vein ends by dividing into right and left branches which enter the liver.

Portal Hypertension

Portal hypertension is defined as an increase in portal vein pressure above the normal level. The **normal pressure in portal vein is 5-10 mm Hg.** In an established cases of portal hypertension, the pressure in the portal vein may be elevated to 15mm Hg or even more.

KEY BOX [IMPORTANT]	
• **Blood supply of liver**	80% by Portal vein 20% by Hepatic artery
• **Pressure in**	Portal vein: 5-10 mm Hg (NEET) Hepatic artery: 100-150 mmHg Hepatic vein: 1-4 mmHg

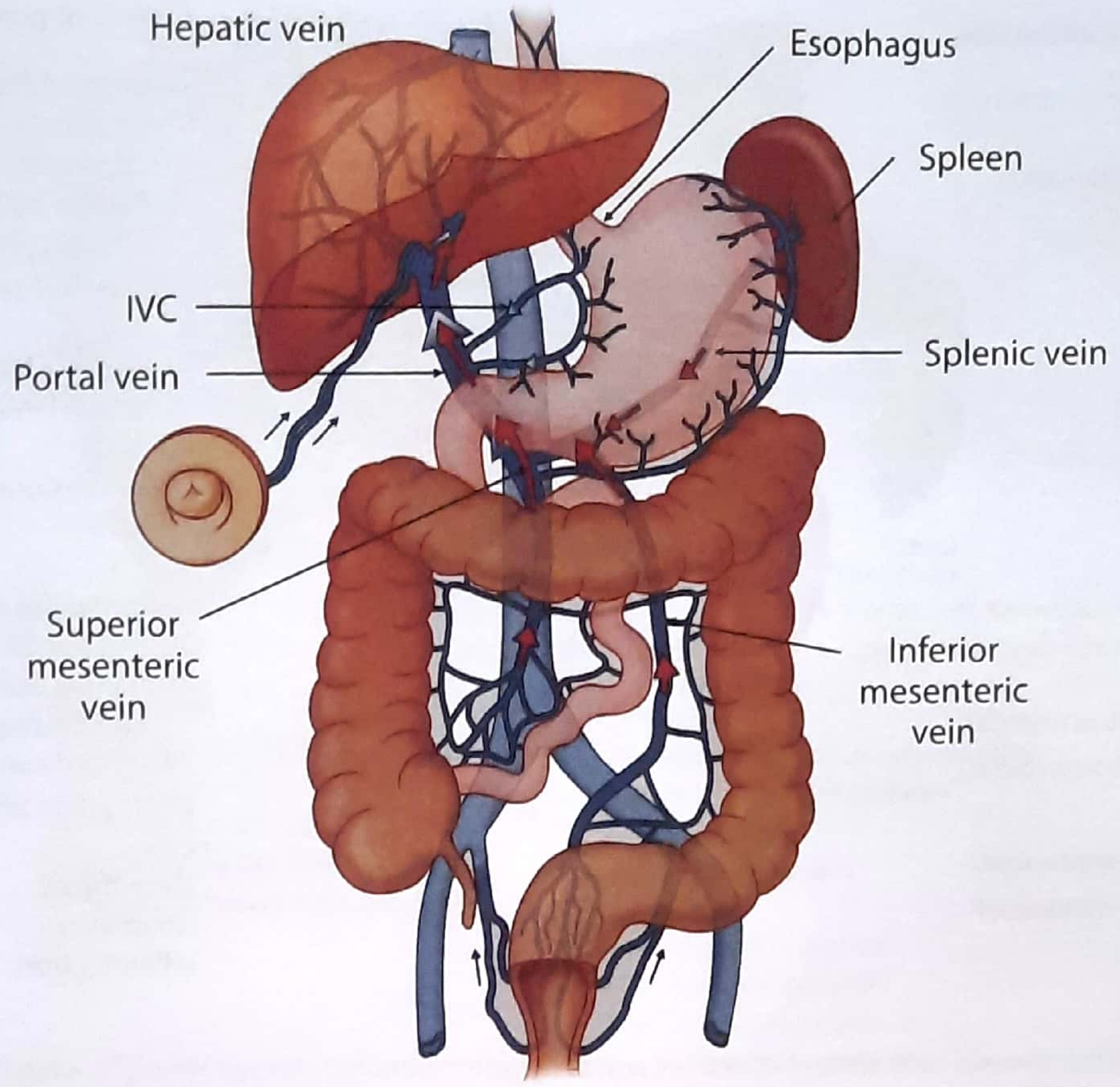

Figure 29.25: Hepatic portal system; note the path of blood flow in portal system (mind the arrow)

Etiology

Various cause of portal hypertension can be classified into :

1. Prehepatic or Presinusoidal : **20%**
2. Hepatic or sinusoidal : **80%** *(UP 03)*
3. Post-hepatic or post-sinusoidal : Rare

Effects of Portal Hypertension

In chronic cases; obstruction to hepatic venous system results in:

A. Splenomegaly

Venous drainage of spleen in obstructed as a result of obstruction in portal venous system, which leads in passive venous congestion of spleen, resulting in splenic enlargement.

B. Collateral Circulation

(Development of portosystemic venous anastomosis) When there is obstruction in portal vein, nature tries to reduce portal pressure by diverting blood from portal system to systemic system through few known channels; such as:

1. Collateral around the lower end of the esophagus between esophageal branch of left gastric vein (portal system) and the lower esophageal vein which drain into azygous and hemiazygous vein (systemic system). Dilatation and tortuosity of these collaterals are called "esophageal varices". Rupture of these may cause hematemesis.
2. Collaterals around the lower third of anal canal between superior hemorrhoidal vein (portal system) and middle and inferior hemorrhoidal vein (systemic system) causing hemorrhoids. Please see box 29.8.
3. Around umbilicus- 'Caput medusae'.

C. Hepatic encephalopathy

Portal venous system contains many toxic substances, which is carried to liver, where detoxification occur. When there is obstruction in portal venous flow, the toxic metabolites (like ammonia) bypasses liver and enters systemic circulation and in turn reaches central nervous

Effects of Portal hypertension

Increased portal venous pressure
-Splenomegaly
-Gastroesophageal varices
-Caput medusae
Ascites

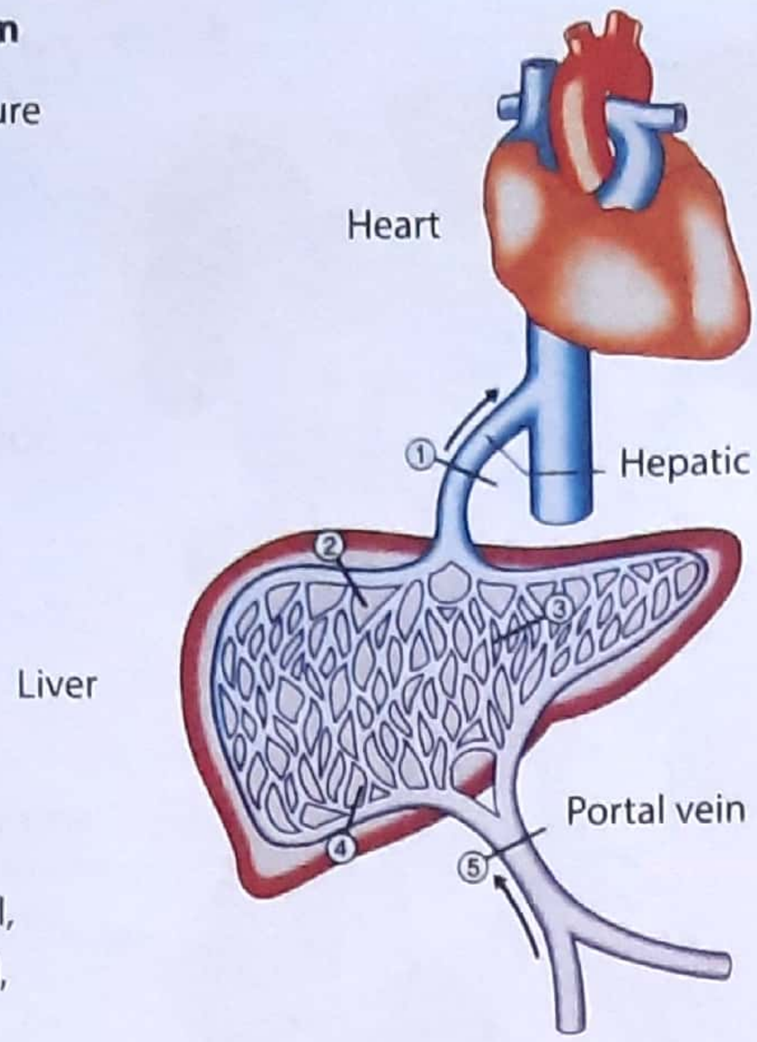

1. Extrahepatic post-sinusoidal,
2. Intrahepatic post-sinusoidal,
3. Sinusoidal,
4. Intrahepatic pre-sinusoidal,
5. Extrahepatic pre-sinusoidal

Causes of portal hypertension

Postsinusoidal (post hepatic)
- Thrombosis (including Budd-
- Chiari syndrome
- Neoplasm (HCC)
- Right heart failure
- Constrictive pericarditis

Sinusoidal (Hepatic)
- Fibrosis & Distortion of Sinusoids
- Arteriovenous anastomosis
Cirrhosis

Presinusoidal (Pre hepatic)
-Obstruction of intrahepatic portal veins Schistosomiasis
- Congenital hepatic fibrosis
- Biliary cirrhosis
- Obstruction of extrahepatic portal veins
- Thrombosis
- Neoplasm
- Inflammation

Figure 29.26 (A) : Pathogenesis and clinical effects of portal hypertension

system, resulting in impaired consciousness, impaired speech, confusion, drowsiness, stupor and coma, the condition known as hepatic encephalopathy.

D. Ascites

Ascites occurs due to increased transudation of fluid across the peritoneal membrane; particularly over the surface of liver.

Investigation

1. Liver function tests

2. Barium swallow

Esophageal varices show a filling defect at lower end of esophagus, [**Note** - esophageal varices are the most common sequelae of portal hypertension].

KEY BOX 29.8		
Sites of portosystemic Anastomosis		
Site of Anastomosis	**Portal Veins**	**Systemic Veins**
1. Lower esophagus	Left gastric vein	Azygos vein
2. Around umbilicus	Paraumbilical veins	Inferior epigastric
3. Rectum (lower third anal canal)	Superior hemorrhoidal vein	Middle & inferior hemorrhoidal veins
4. Extraperitoneal surface of abdominal organs	Tributaries of superior and inferior mesenteric veins	Subdiaphragmatic and retroperitoneal lumbar
5. Bare area of liver	Intrahepatic portal veins	Diaphragmatic veins

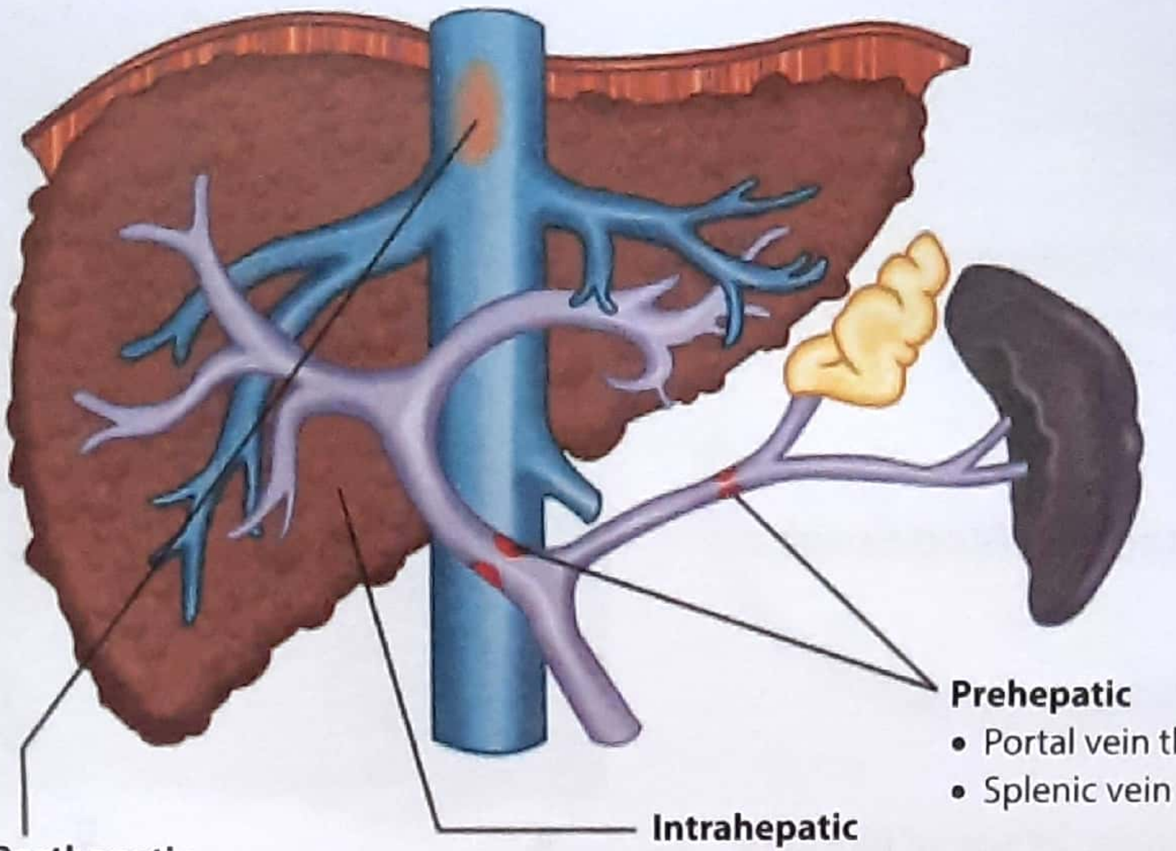

Posthepatic
- Budd-Chiari syndrome
- Constrictive pericarditis
- Inferior vena caval obstruction
- Right-sided heart failure
- Severe tricuspid regurgitation

Intrahepatic

Presinusoidal
- Idiopathic portal hypertension
- Primary biliary cirrhosis
- Sarcoidosis
- Schistosomiasis

Sinusoidal
- Alcoholic cirrhosis
- Alcoholic hepatitis
- Cryptogenic cirrhosis
- Postnecrotic cirrhosis

Postsinusoidal
- Sinusoidal obstruction syndrome

Prehepatic
- Portal vein thrombosis
- Splenic vein thrombosis

Figure 29.26 (B) : Types of portal hypertension depending on blockage

3. Upper Gl endoscopy

This is most useful procedure for diagnosing bleeding varices. Varices appear as large, tortuous submucosal bluish vessel running longitudinally in the lower esophagus.

4. Ultrasonography

Abnormalities of liver and spleen size; especially left lobe enlargement of liver, splenic and portal vein diameters can be assessed. They are likely to be dilated in a patient with portal hypertension. USG will also tell the status of liver (cirrhosis).

5. Spleno-Porto-venography (SPV)

This is radiography of splenic and portal vein.

How is it done?

A fine lumbar puncture needle is passed into spleen through the ninth space in left mid axillary line.

- A radio opaque dye is injected directory into spleen which fills up the entire portal system.
- Now a X-ray is taken, which will visualize the whole portal system.

Findings:

- It will tell about the configuration of portal system.
- To locate exact site of obstruction
- To assess the diameter of splenic vein.
- If a needle is connected to a manometer, splenic pulp pressure can be recorded (It should be increased in portal hypertension).

6. Duplex Doppler

This is done for measurement of portal blood flow.

Clinical feature

The average age of patients with intrahepatic obstruction is between 30-40 years. The patients with extrahepatic obstruction are even younger.

Three clinical syndrome can be attributed to portal hypertension. *(AIIMS NOV 06)*

(i) **Hypersplenism,**
(ii) **Ascites and**
(iii) **Esophageal varices**

Hypersplenism and ascites has been discussed else where in this book. Esophageal varices will be discussed here in detail.

Treatment of Portal hypertension (and Esophageal varices)

I. Prophylaxis

The aim is to reduce portal pressure by use of blockers

II. Treatment of Bleeding Esophageal Varices

(i) Resuscitation

IV fluids and blood transfusion to correct hypovolemia in a patient with massive hematemesis.

(ii) Pharmacological agents

Used are inj. Vasopressin inj. Octreotide (a somatostatin analogue)

(iii) Endoscopic therapy

Options are:-

(a) ***Variceal banding (ligation)***: *It is now the gold standard treatment for esophageal varices* (MANY PGME). This technique is similar to rubber band ligation of anorectal hemorrhoids. Chances of rebleeding is only 5-10%. (Figure 29.27)

(b) ***Sclerotherapy***: Via fiber-optic endoscope 1-3 ml of sclerosing agent is injected in the lumen of each varix, causing it to become thrombosed (box 29.9). Endoscopy is usually repeated with in 48 hours and then once or twice again at weekly internal.

Sclerotherapy controls acute bleeding in about 80-90% of patients and rebleeding during the same hospitalization is in about 25%.

Disadvantage of Sclerotherapy

- Chances of rebleeding is high (>25%), hence repeated injections are necessary.

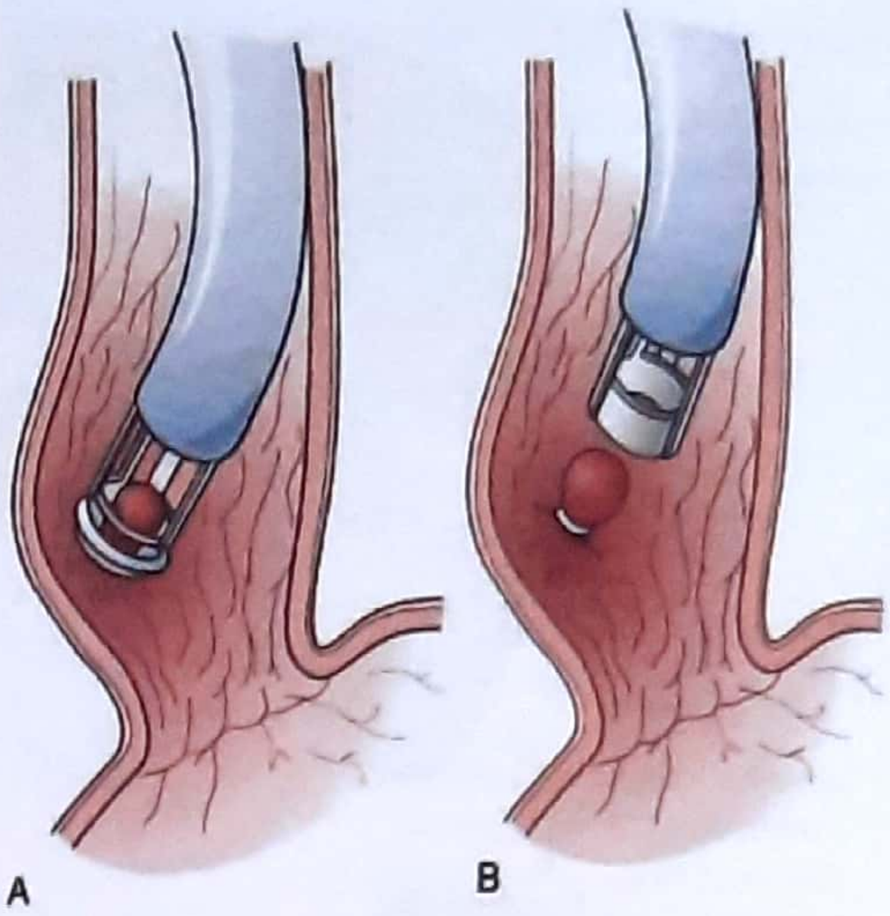

Figure 29.27 : Endoscopic ligation of esophageal varices. (A) The varix is drawn into the ligator by suction. (B) An O ring is applied.

- Multiple esophageal ulcer can develop at injection site.
- Mediastinitis and pleural effusion.
- Gastric varices can not be managed by Sclerotherapy.
- Esophageal stricture; due to post injection fibrosis.

Sclerosant used in esophageal varices

P-Polidocanal & Phenol

E-Ethalonamide oleate

S-Sodium tetradecyle sulphate

A-Absolute alcohal

B-n-Butyl cyanoacrylate

[Mnemonic: PESAB]

(iv) Balloon tamponade

It is compression of bleeding point by inflating a balloon over it; against esophageal and gastric wall.

- For this special type of balloons are used, namely *Sengstaken Blakemore tube*. It has three balloon: one is esophageal balloon, second is gastric balloon and third for aspirating gastric contents and blood, if present, in stomach. Please see figure 29.29A and figure 29.29B. A new Minnesota tube has four lumen.

Figure 29.28 : Images of Minnesota tube & Upper GI endoscope

- After passing the tube into stomach the gastric balloon is inflated up to 250-300 ml of air and esophageal balloon is inflated up to 50-60 ml of air to get a pressure of about 40 mmHg *(JIPMER 87)* and tube is left in place for 12 hours. (Figure 29.29 A & B)
- Tube can not be left inflated for more than 24 hours, as it can cause pressure necrosis of esophageal wall.
- The most common and serious complication is aspiration of pharyngeal secretions and pneumonitis.
- Occasionally esophageal rupture can occur due to over inflation of esophageal balloon.
- Chance of rebleeding is about 50%.
- A new *Minnesota tube* has four lumen.

(v) TIPSS [Transjuglar Intrahepatic porto-systemic stent shunt] *(PGI 98)*

- TIPSS is a procedure by which lowering of portal pressure is done.
  - In this; we create a connection *between hepatic vein, and a major branch of portal vein* so that high pressure flow in portal vein is directed towards hepatic vein, thus reducing pressure in portal vein, *(KAR 06)* (Figure 29.30 on the page number 491)

Surgical Procedure

A. Devascularization procedure

1. **Esophageal transection:-** This operation aims at complete interruption of varices. The esophageal musculature is incised longitudinally and the mucosa and sub mucosa are isolated as a tube. They are now divided across completely. There after, repair of the tube is done by a continuous catgut suture and this obliterates all varicose veins (varices).

2. **Sugiura and Futugawa operation**

B. Porto-systemic shunt

It is a common operation for decreasing bleeding varices of oesophagus.

[Shunt means divert, An artificially constructed passage to divert flow from one main route to other bypass route]

It is *creation of an anastomosis between portal and systemic venous system.* Variety of shunt operations have been described. The best result are seen in patients with compensated liver disease.

Child's criteria are useful guide for deciding the suitability of a patient for shunt surgery and prognosis. Please see key box 29.11 for details.

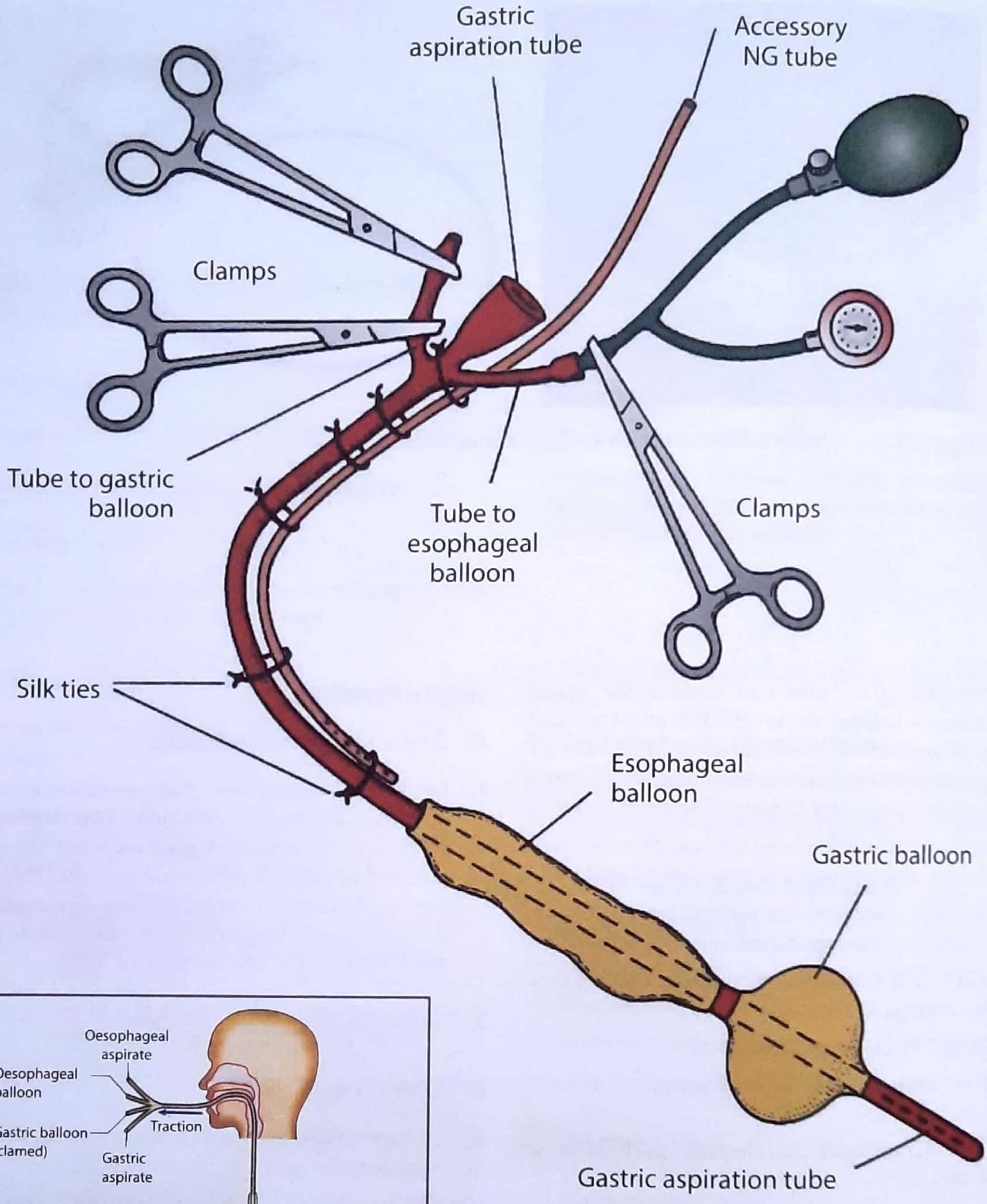

Figure 29.29 (A) : Modified Sengstaken-Blakemore tube.

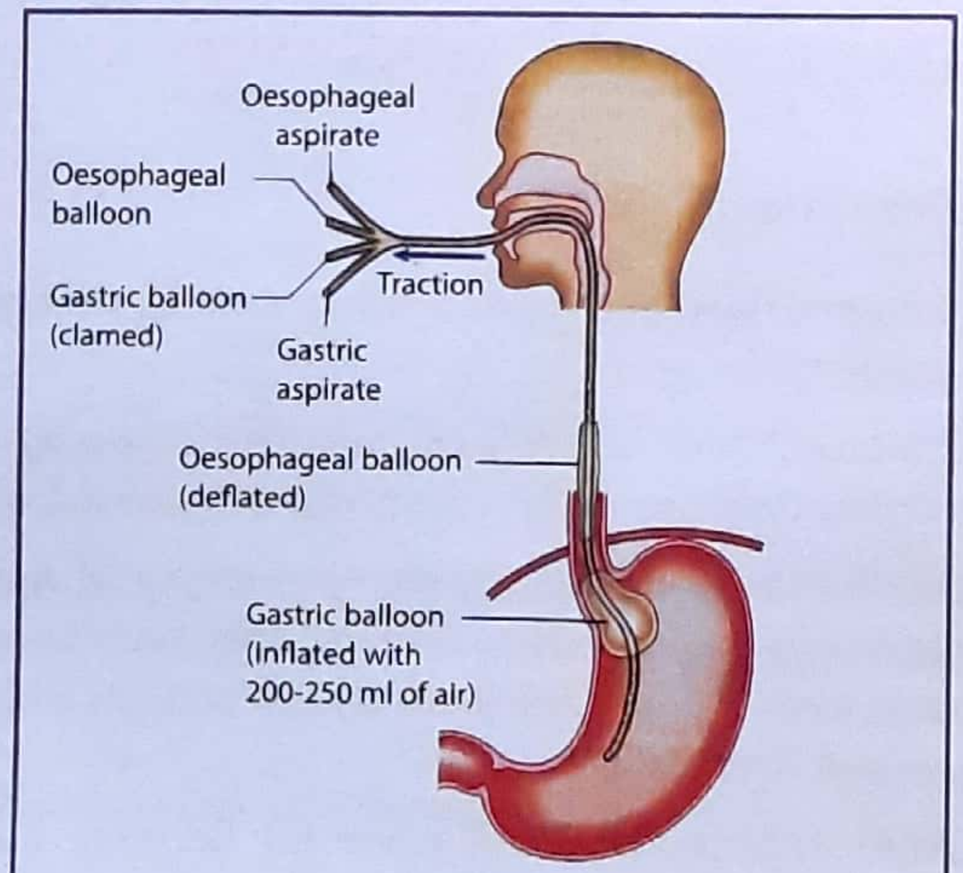

Figure 29.29 (B): Patients with inflated Sengstaken-Blakemore tube

KEY BOX 29.9

Management of acute variceal bleeding

Acute hemorrhage

↓

Fluid resuscitation and gastric lavage

↓

Endoscopy

↓

Bleeding oesophageal varices

↓

Emergency endoscopic sclerotherapy/Endoscopic band ligation

Bleeding stops

↓

definitive management

Bleeding persists or recurs

↓

repeat sclerotherapy

↓

bleeding persists

↓

Balloon tamponade
(plus pharmacotherapy for
temporary control)

Good risk patient

↓

Portacaval shunt

or

Distal splenorenal shunt

or

Esophageal transection and
reanastomosis

Poor risk patient or transplant candidates

↓

TIPSS

(Trans jugular intrahepatic porto-caval shunt)

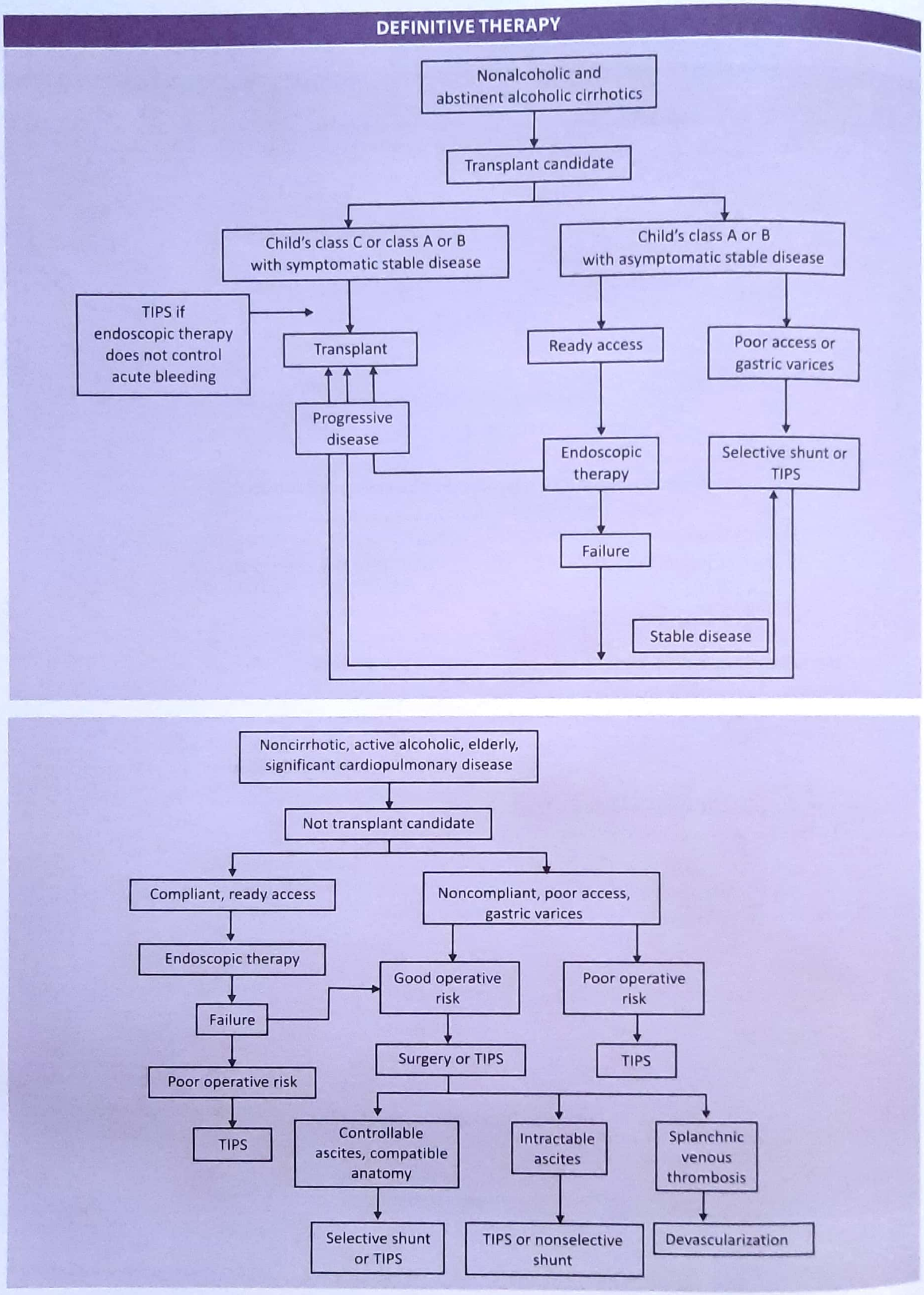
DEFINITIVE THERAPY
Nonalcoholic and abstinent alcoholic cirrhotics
Transplant candidate
Child's class C or class A or B with symptomatic stable disease
Child's class A or B with asymptomatic stable disease
TIPS if endoscopic therapy does not control acute bleeding
Transplant
Ready access
Poor access or gastric varices
Progressive disease
Endoscopic therapy
Selective shunt or TIPS
Failure
Stable disease
Noncirrhotic, active alcoholic, elderly, significant cardiopulmonary disease
Not transplant candidate
Compliant, ready access
Noncompliant, poor access, gastric varices
Endoscopic therapy
Good operative risk
Poor operative risk
Failure
Surgery or TIPS
TIPS
Poor operative risk
TIPS
Controllable ascites, compatible anatomy
Intractable ascites
Splanchnic venous thrombosis
Selective shunt or TIPS
TIPS or nonselective shunt
Devascularization

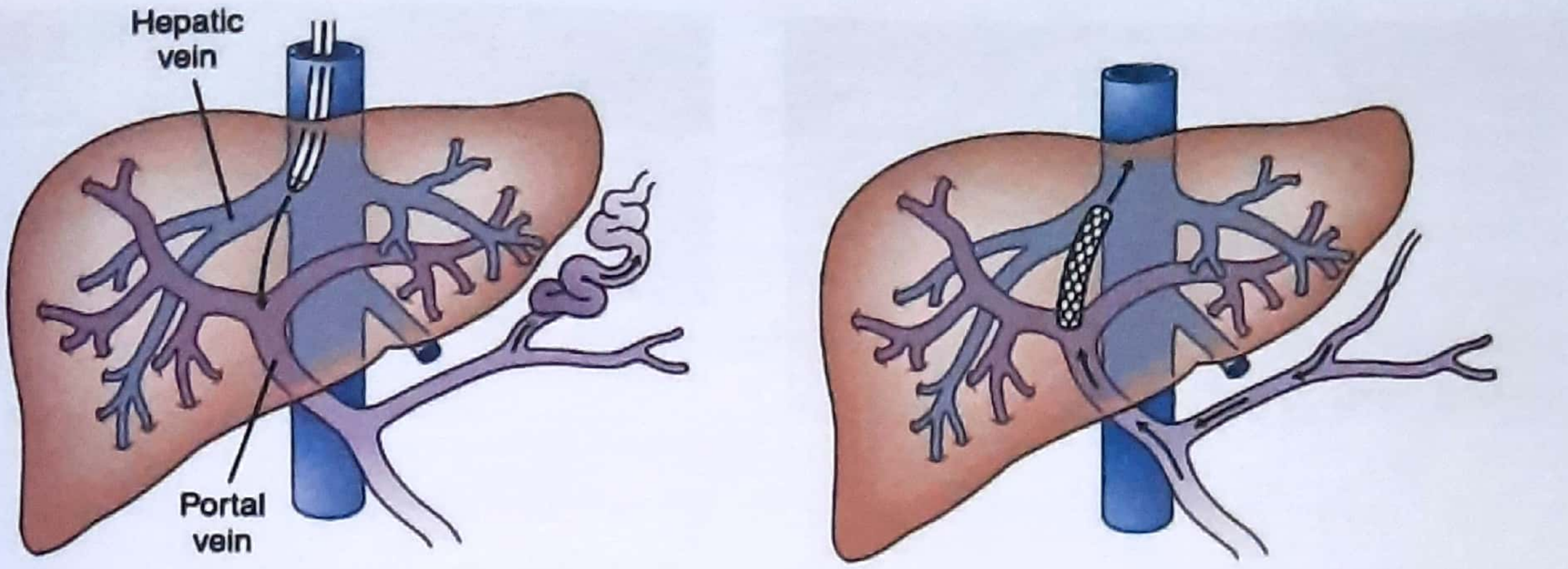

Figure 29.30 : Transjugular intrahepatic portosystemic shunt placement (TIPSS).

Various shunt operation are:

1. End to side porta caval* shunt (fig 29.32)
2. Side to side porta caval shunt
3. Proximal spleno-renal shunt
4. **Distal spleno-renal shunts** (NEET) → Preferred in patient with portal HTN having acceptable operative risk & adequate liver function. (Figure 29.31)
5. Mesenterico-caval shunt

Caval-refers to inferior vena cava Please see flow chart in key box 29.9.

Treatment of Ascites Due to Portal Hypertension

- Ascites is due to increased transudation of fluid across the peritoneal membrane, particularly over the surface of liver.
- It can be troublesome and refractory to medical treatment.
- Diagnosis in often confirmed by ultrasonography, aspiration or laparoscopy. Treatment modalities are:
  1. Diuretics - K^+ sparing diuretics such as spironolactone.
  2. Restriction of salt intake (Lo-Na salt)
  3. Peritoneovenous shunt operation (Leveen shunt, **Denver shunt**) (NEET)

****

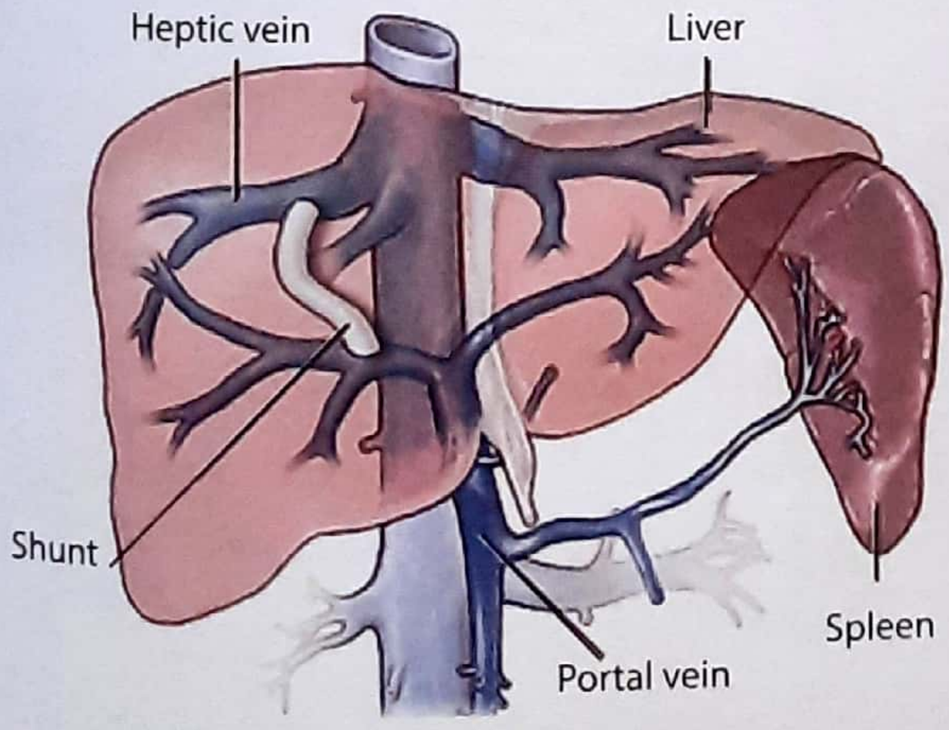

Figure 29.31: Porta-hepatic shunt

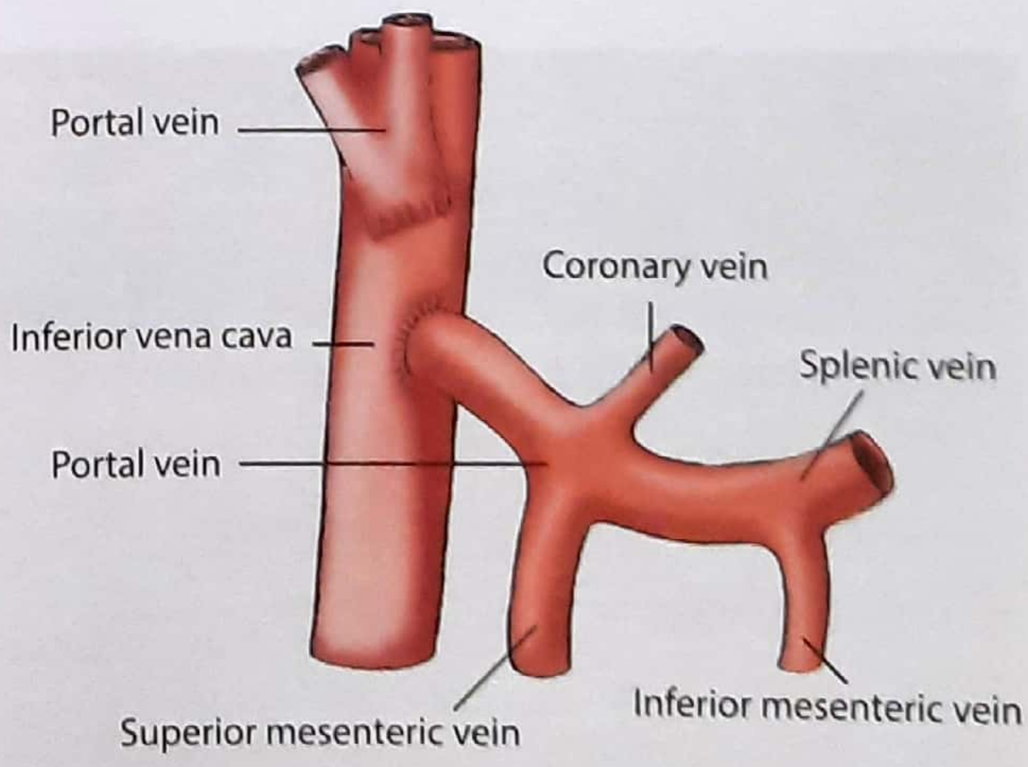

Figure 29.32 : End-to-side portacaval shunt

KEY BOX 29.10
Sclerosant used to esophageal varices [PESAB]
P-Polidocanal & Phenol
E-Ethalonamide oleate
S-Sodium tetradecyle sulphate
A-Absolute alcohal
B-n-Butyl eyanoacrylate

KEY BOX 29.11	
Total numerical score	**Child Pugh class**
A	5-6
B	7-9
C	10-15

BUDD-CHIARI SYNDROME

Budd-chiari syndrome is a rare disorder resulting from obstruction in hepatic vein flow. *(KERALA 87, AP 86, KAR 89, PGI 88)*

Causes: 7 C

- Clotting disorder - Polycythemia vera
- Contraceptive pills
- Cancer (Hepato cellular carcinoma)
- Crotalaria juncia (a plant extract)
- Congenital web in suprahepatic IVC
- Constrictive pericarditis
- Conception (Pregnancy)
- **Myeloproliferative disorder** *(NEET)*

Clinical feature

Symptoms usually begin with a mild prodrome, consisting of vague right upper abdominal pain, post prandial bloating, and anorexia. After weeks or months, a more florid picture develops **consisting of gross ascites,** *(NEET)* hepatomegaly and hepatic failure.

Treatment

For fulminant liver failure; the treatment of choice is probably liver transplantation. For those in whom cirrhosis is not established, portacaval shunt or mesoatrial shunt may be considered.

Friends I have not discussed topics, like cirrhosis and viral hepatitis, because,they are more a medical topic, you must read these from medicine books.

****

KEY BOX 29.12			
Child Turcotte Pugh Classification			
Parameter	**A**	**B**	**C**
1. Serum bilirubin, mg/dL	Below 2.0	2-3	Over 3.0
2. Serum albumin, g/dL	Over 3.5	3.0-3.5	Below 3.0
3. Ascites	None	Easily controlled	Poorly controlled
4. Encephalopathy	None	Minimal	Advanced
5. INR	<1·7	1·7 - 2·2	>2·2
CTPA = 5-6 points, CTPB = 7-9 points, CTPC = 10-15 points			
* Child Pugh classification for cirrhosis has 5 parameters each one has been given one numerical score (Box 29.12).			

NOTES :

Sample Questions for Prof Examination

1. Describe the etiopathogenesis, clinical features and management of portal hypertension.
2. Describe the life cycle of Echinococcus granulosus. Describe the pathology, clinical features and management of a case of hydatid cyst of the liver.
3. Discuss management of a patient with hematemesis.
4. Discuss in detail, liver abscess and it's management.
5. Describe the etiopathogenesis, clinical features and management of esophageal varices.
6. Discuss the pathogenesis, clinical features and management of amebic liver abscess.
7. Write short note on ECRP.

30 The Gall Bladder and Bile Duct

Contents

- Surgical anatomy
- Investigation of biliary tract
- Congenital conditions of the biliary tree
- Extra hepatic biliary atresia
- Choledochal cyst
- Gall stone disease
- Choledocholithiasis
- Cholangitis
- Obstructive jaundice
- Sclerosing cholangitis
- Bile duct stricture
- Parasitic infection of the bile duct
- Carcinoma of gall bladder
- Cholangiocarcinoma
- Klatskin's tumours

The extrahepatic biliary system is composed of bile ducts and gall bladder. In 70% of patients, the common bile duct and pancreatic duct open separately.

The common bile duct has a luminal diameter of 0.5-0.7cm in the adults and 8cm in length. (Note: *Length of portal vein is also 8cm*)

The biliary system stores and delivers the bile secreted by liver into duodenum. The gall bladder acts as a reservoir in which the bile is stored and concentrated from about *1000 ml/day down to 50 ml/day* (PGI 88).

Bile is an alkaline fluid and contains excretory bilirubin pigments, bile acids, bile salts, cholesterol, inorganic ions and mucus.

Cholesterol which is insoluble in water, is maintained in solution by formation of complexes with hydrophilic salts & lecithin.

SURGICAL ANATOMY

The gall bladder is pear shaped, 7.5-12cm long, with normal capacity of about 5ml, but is capable of considerable distension in certain pathological conditions.

The **anatomical divisions** are: Fundus, body and neck that terminates in narrow infundibulum.

The posteromedial wall of neck, is dilated outward to form a pouch (Hartmann's pouch). Gall stones may lodge in this pouch. (Fig 30.1 & 30.2)

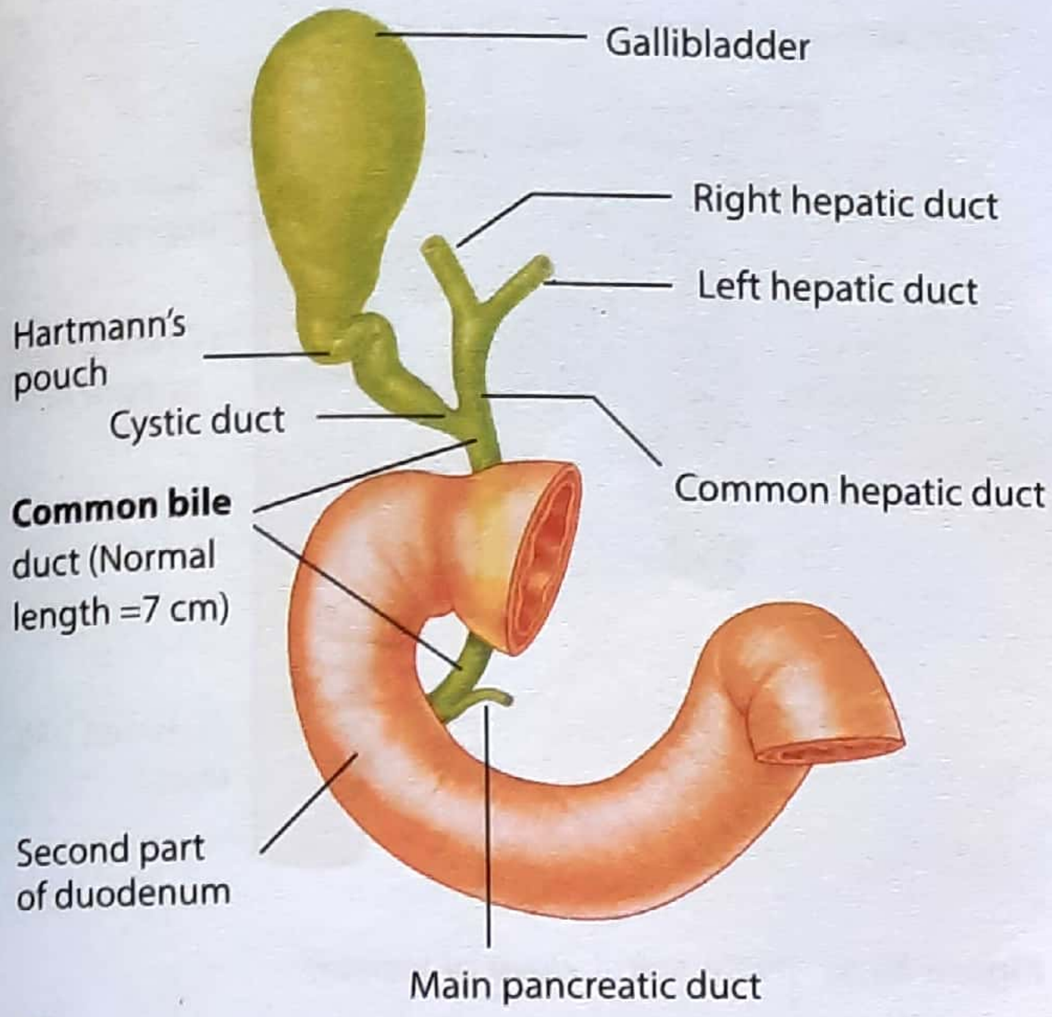

Figure 30.1: Anatomy of biliary system

Cystic duct

The cystic duct is about 3cm in length and 1-3 mm in diameter. It begins at the neck of gall bladder and ends by joining the common hepatic duct at an acute angle to form the common bile duct. The mucus membrane of cystic duct forms a series of 5-12 folds, arranged spirally to form the so called "spiral valve of heister" (Please see figure 30.5). It is not a true valve.

Ampulla of Vater

The union of common bile duct and pancreatic duct forms a small ampulla called ampulla of vater. *Common bile duct stone most commonly get impacted in this part* (JIPMER 87)

The terminal part of both pancreatic duct and common bile duct are surrounded by circular muscle, known as *Sphincter of oddi.*

Arterial Supply

Gall bladder is supplied by cystic artery, which is a branch of right hepatic artery(MANY PGME). Occasionally an accessory cystic artery may arise from gastroduodenal artery.

Caterpillar turn or Moynihan's hump It is most dangerous anomaly in arterial supply of gall bladder, where in a hepatic artery takes tortuous course on the front of the origin of the cystic duct. This tortuosity is known as 'caterpillar turn' or **moynihan's hump.** This variation is a cause of many problem during cholecystectomy.

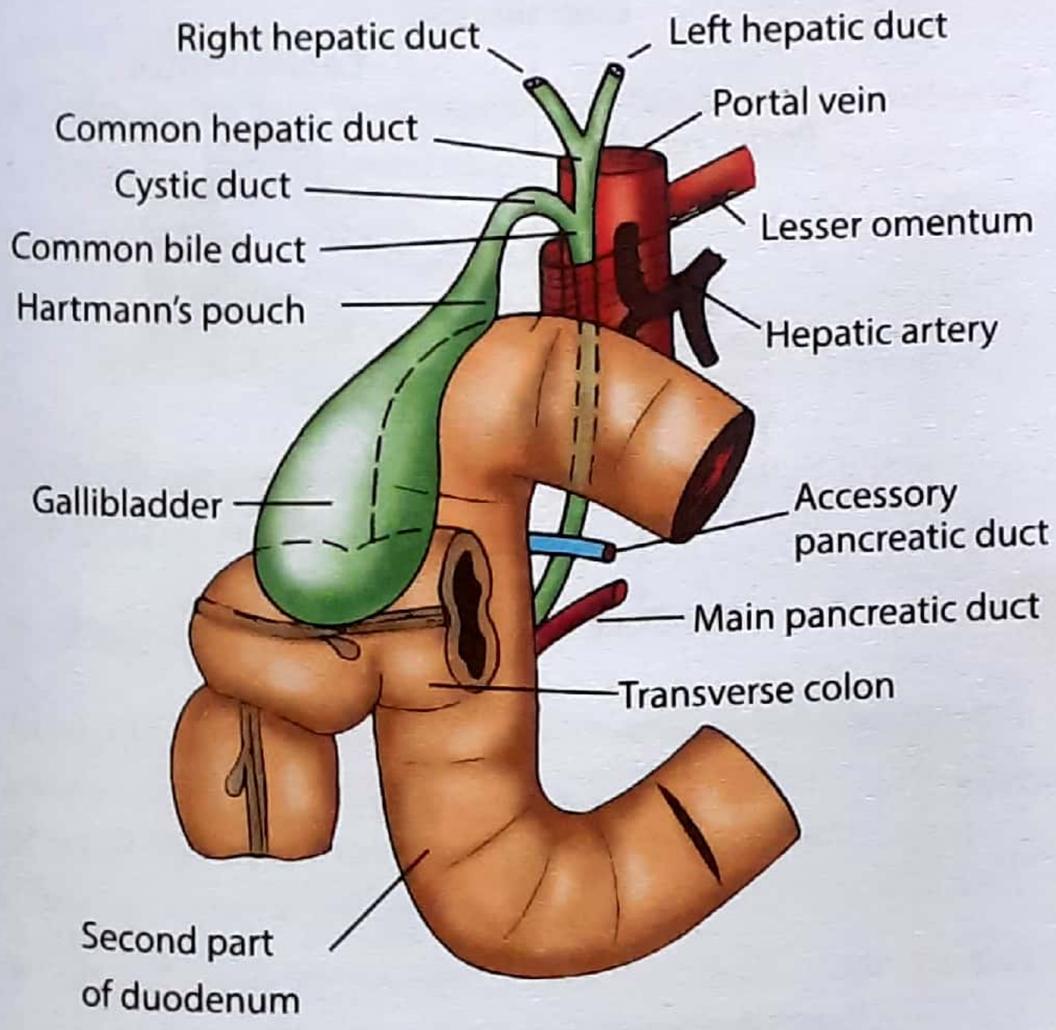

Figure 30.2: Extrahepatic biliary system

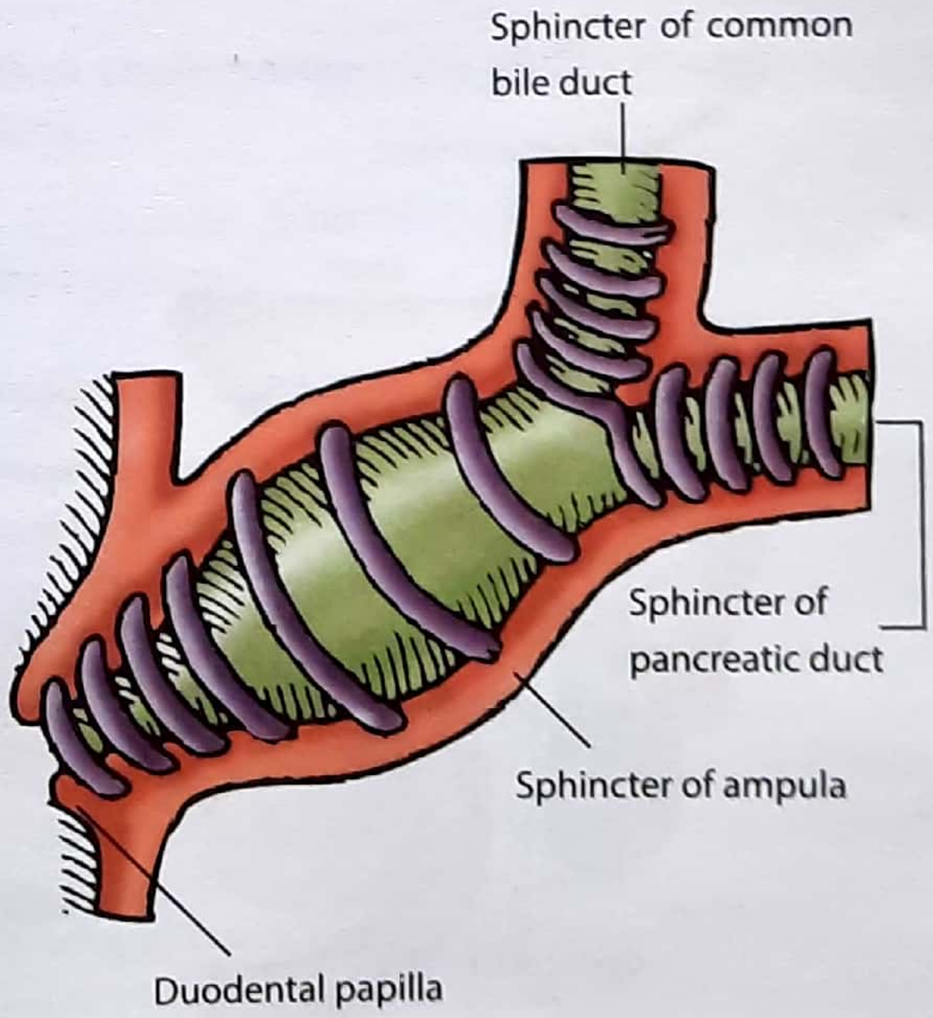

Figure 30.3: Anatomy of biliary sphincters

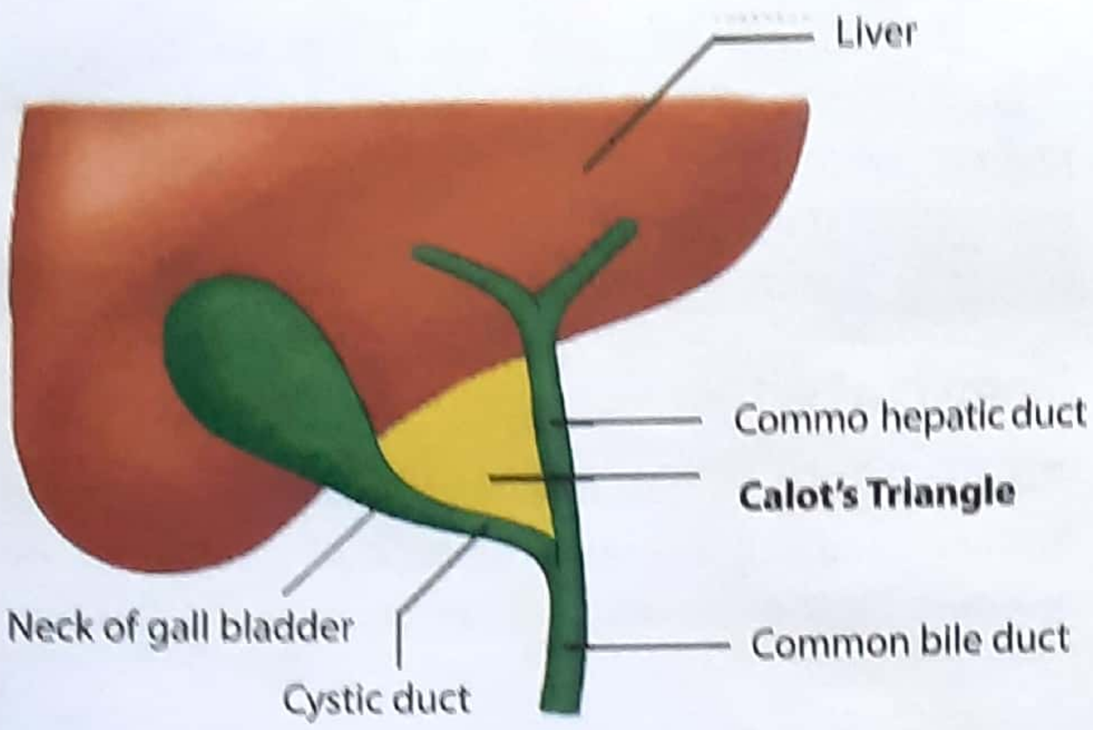

Figure 30.4: Note the boundaries of Calot's triangle

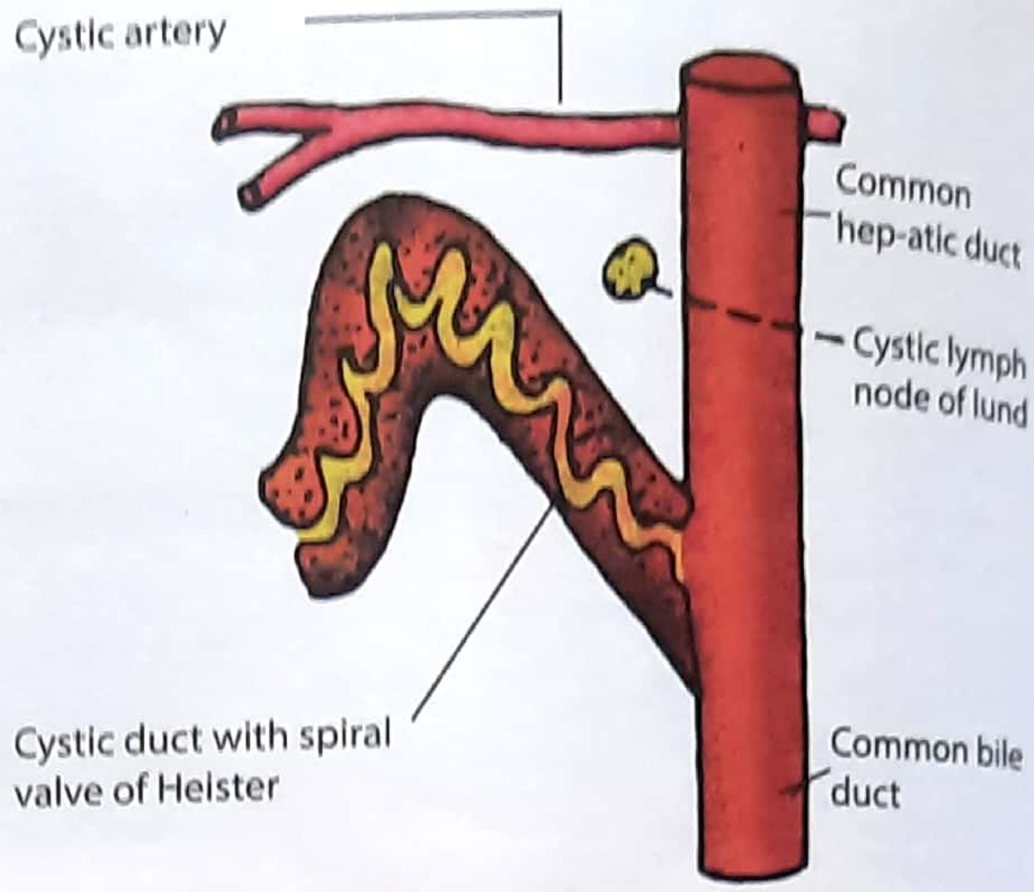

Figure 30.5: Note spiral valve of Heister

Lymphatics

The lymphatic vessels of the *gall bladder drain into the cystic lymph node of lund.* The cystic lymph node lies at the angle between the cystic duct and common hepatic duct.

Also Note (NEET) **:**

Virchow nodes - Left supraclavicular fossa.

Irish node - Left axilla

Sister Mary Joseph node - Umbilicus

Rotter's node - b/w pectoral muscle

Calot's Triangle

It is an area bound by **common hepatic duct (medially), cystic duct and gall bladder (laterally), and cystic artery margin (superiorly).** (NEET) This is a very important land mark during cholecystectomy. Please see figure 30.4.

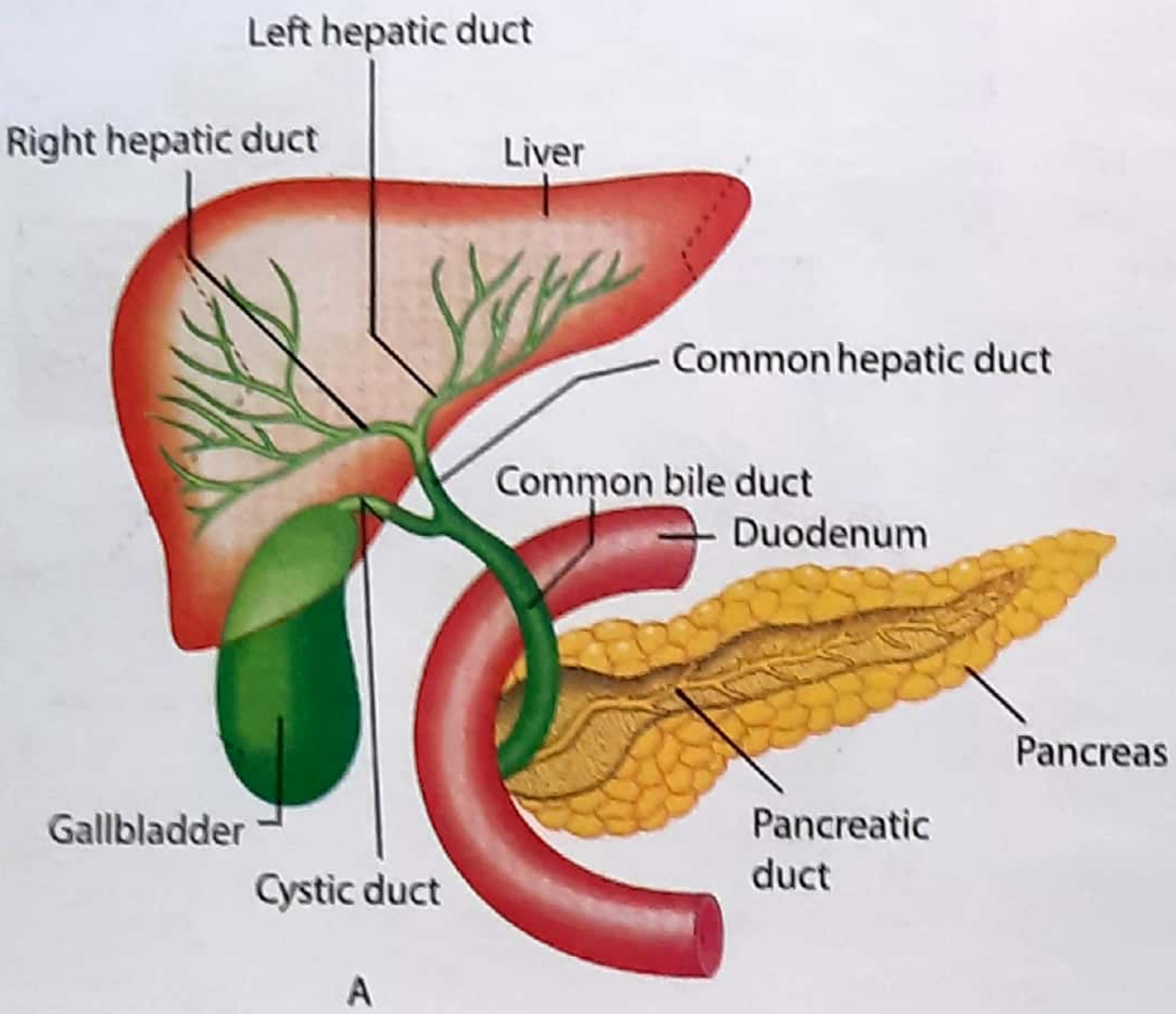

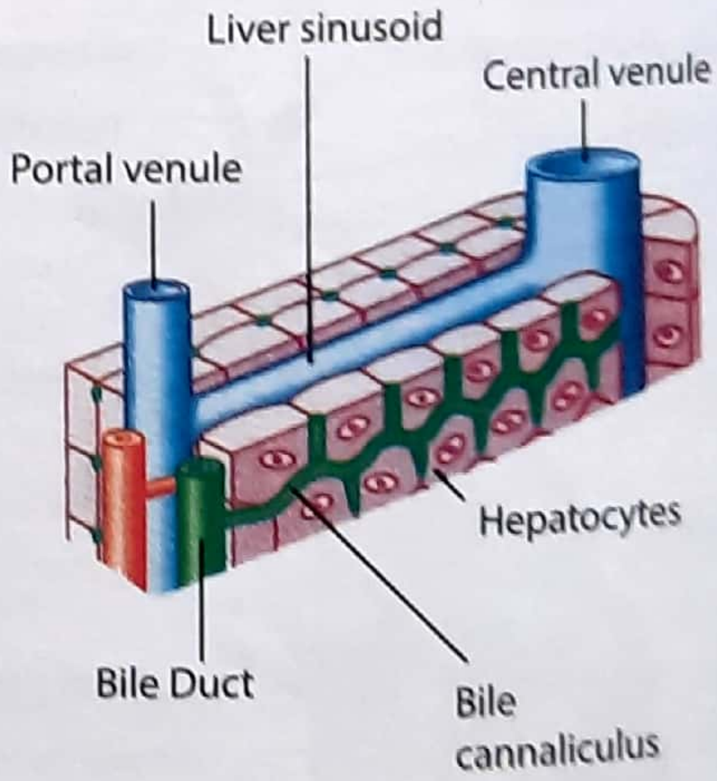

Figure 30.6: Relation of gall bladder, pancreas and duodenum

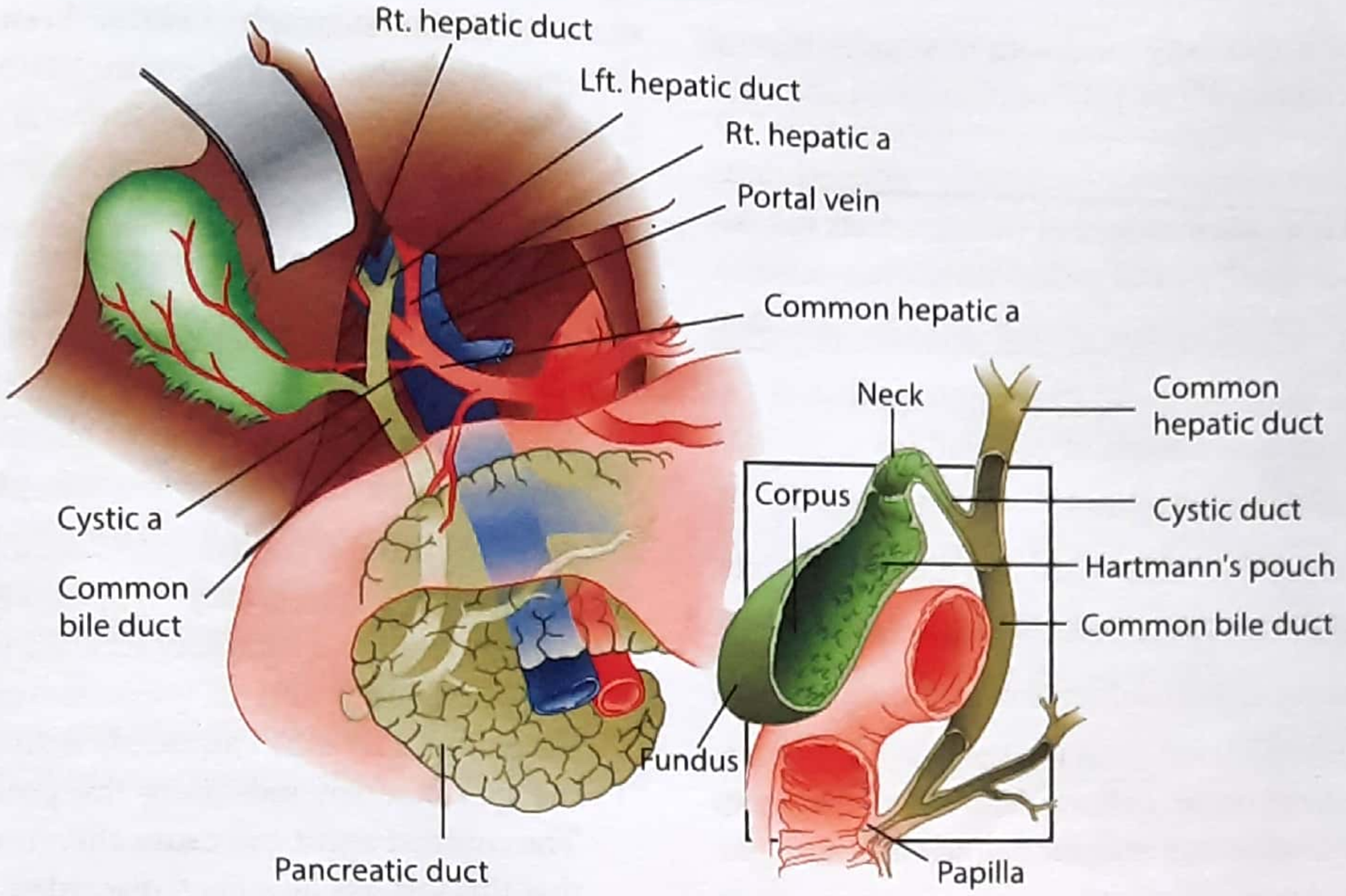

Figure 30.7: Hepato-biliary system

Function of gall bladder

- Storage of bile & it's release into the duodenum when required.
- Absorption of water, and concentration of bile is done by gall bladder. Bile may be concentrated as much as ten times, with a corresponding increase in the portion of bile salt, bile pigments, cholesterol and calcium.
- An important function of gall bladder is secretion of mucus and approximately 20ml is produced per day.

****

INVESTIGATION OF BILIARY TRACT

Through the list is long but read patiently; it will take only one hour or so.

1. Plain radiograph

Plain radiograph of gall bladder will show radiopaque gallstone in only 10% patients. (JIPMER 86) (Note: only 10% of renal stones are radio lucent & 90% are radio opaque) ('Just opposite to gallstones')

- It will also show rare cases of calcification of gall bladder wall, so called as *'Porcelain' gall bladder. *[Porcelain is a form of ceramic]*
- *Porcelain gall bladder is a premalignant condition and is an indication for prophylactic cholecystectomy.* (MANY PGME)
- *Gas in the wall of gall bladder wall, (a condition called as emphysematous cholecystitis) can be detected on plain X-ray.*

2. Oral cholecystography (OCG) (Graham-cole's Test)

This is obtaining X-ray of the gall bladder after using contrast medium.

Procedure

Telepaque (lopanoic acid) is the contrast medium most commonly *used.* (PGI 87, KERELA 88).

The patient takes light dinner of non fatty meal between 8-9 pm on the evening before the radiological examination. Patient ingests 6 tablets of telepaque, one tablet at a time with water, after dinner until bed time. On the following morning nothing is given by mouth to the patient till the X-ray films are taken. After taking 2-3 films (control films), the patient is given fatty food which will cause contraction of gall bladder. 20-40 minutes later again films are taken to demonstrate contraction of the gall bladder, after stimulus due to fatty meal. Normal gall

bladder contracts after fatty meal with in 40 minutes and it's size is reduced to 1/3rd or 1/4rd of it's normal size (due to contraction).

- It will also indicate presence of filling defects for calculi, tumours, polyps and gall bladder diverticula.
- *Successful visualization of gall bladder depends upon.* (AIMS 95, AL 97)
  - (i) Normal functioning of gall bladder
  - (ii) Blood flow to the liver.
  - (iii) Ability of liver cells to excrete the dye into bile.
  - (iv) Patency of hepatic and cystic duct system.
  - (v) Capacity of gall bladder to concentrate excreted dye by liver.
- *Non visualization of gall bladder usually suggests that gall bladder is diseased and has lost the concentration ability of dye.*
- Non visualization of gall bladder may also be caused by failure of absorption of oral contrast medium, eg. in pyloric stenosis, excessive vomiting, diarrhea, hepatic dysfunction, hepatic or cystic duct obstruction.
- **Oral cholecystography** can not be helpful in diagnosis and hence **should not be used in:**
  - (i) Acute cholecystitis
  - (ii) If the patient is jaundiced, with plasma bilirubin level more than 3mg/100ml.
  - (iii) When renal function is impaired
- Oral cholecystography has now been replaced by ultrasonography as initial investigation of gall bladder disease, because ultrasonography is convenient and more informative than oral cholecystography.

3. Intra venous cholangiography

- This is obtaining a X-ray picture of biliary tree after giving an intravenous contrast. This is indicated when patient cannot retain or absorb the telepaque tablet or cholecystectomy (done in past).
- **20** ml of **biligraffin dye** (M/C used dye) (MANY PGME) is injected intravenously very slowly. The dye gets concentrated and is rapidly secreted by the liver into the biliary tree and is visualized on radiography. Careful radiography can clearly define the ducts and the gall bladder, indicating the presence of stone. The contrast agent can cause allergic reactions, such that this test has now been discarded.

4. Ultrasonography

- *Ultrasonography is non invasive, and now investigation of choice for a patient suspected of having a gallstone, and is also the prime investigation for patient presenting with Jaundice and in differentiating between surgical (obstructive) and medical jaundice (non-obstructive) jaundice.*
- It will demonstrate biliary calculi, the size of gall bladder, the thickness of gall bladder wall, presence of inflammation around gall bladder, pericystic fluid

Figure 30.8: Ultrasound image of a gallstone in the gallbladder neck.

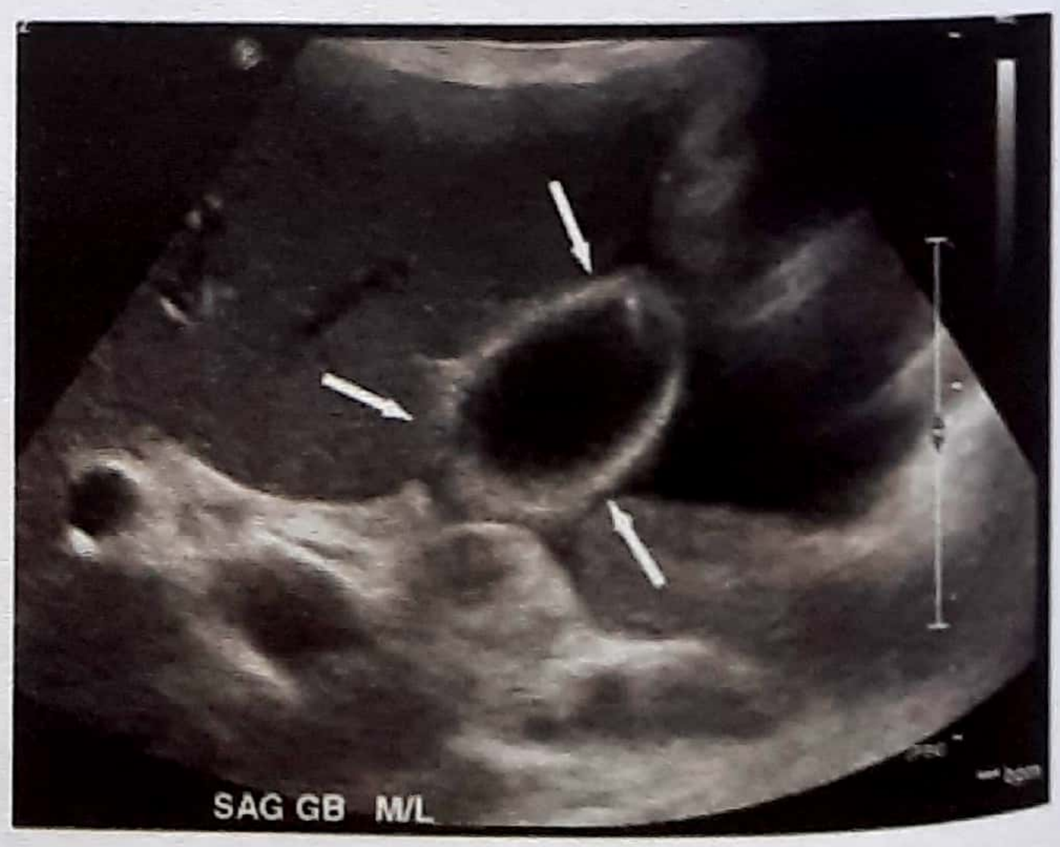

Figure 30.9: Ultrasound image with acute cholecystitis and thickened gallbladder wall (*arrows*)

collection, size and diameter of common bile duct and occasionally presence of stone with in the biliary tree. It may even show a carcinoma at the head of pancreas; occluding the common bile duct.

- **It is least useful in biliary dyskinesia.** *(AIIMS JUNE 20)*

Please help your self with figure 30.8 & 30.9

5. Radio isotope scanning

Technetium-99m (99m TC)-labelled derivatives of iminodiacetic acid [HIDA, IODIDA] are excreted in bile and are used to visualize the biliary tree. Following IV injection of the radionuclide, imaging of the bile duct and gall bladder normally appear with in 15-30 minutes and in the small intestine in about 45-60 minutes. *In acute cholecystitis, the gall bladder is not visualized on radio-isotope scanning.*

Reason?

Acute cholecystitis is almost always due to blockage of cystic duct by a gallstone, how can dye pass through a blockage to reach gall bladder? Non visualization of gall bladder even after 4 hours is diagnostic for acute cholecystitis.

6. CT Scan

CT scan is not a very useful imaging technique of biliary tree. The only value of it is in the investigation of patient; who is suspected to have a malignancy of gall bladder or biliary duct. CT can define the extent of malignancy, involvement of lymph node and presence of metastasis.

7. **MRI and MRCP :** Chapter 29, page 462

8. **Endoscopic Retrograde Cholangiopancreatography (ERCP) :** Chapter 29, page 462

9. **Percutaneous Transhepatic Cholangiography (PTC) :** Chapter 29, page 463

Above 3 investigations have been discussed in previous chapter (liver). Please revise it again, because they are very important investigations, you will definitely get questions on it.

Please help your self with figure 30.10, 30.11, 30.12, 30.13.

10. Peroperative Cholangiography

During cholecystectomy, a catheter* can be placed in the cystic duct and contrast medium is injected. This will

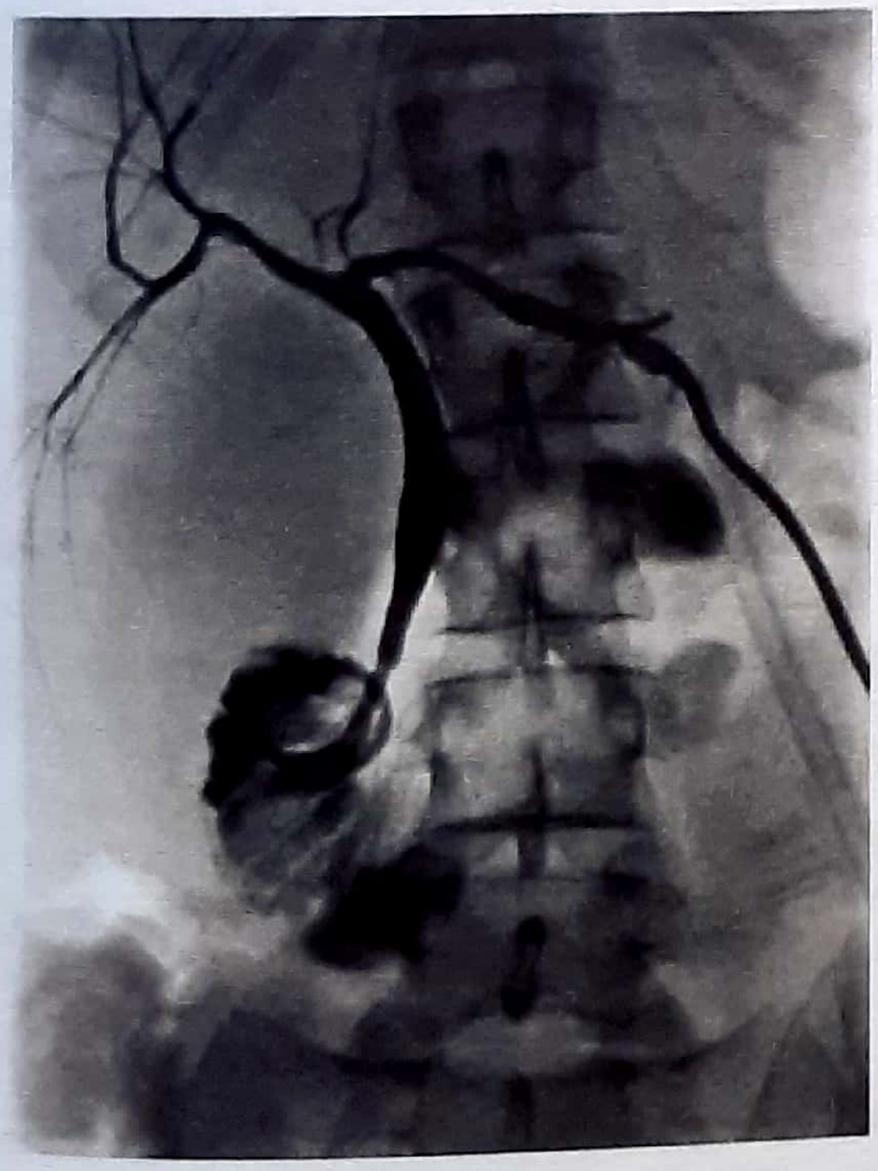

Figure 30.10: Percutaneous transhepatic cholangiography image of hepatic biliary anatomy

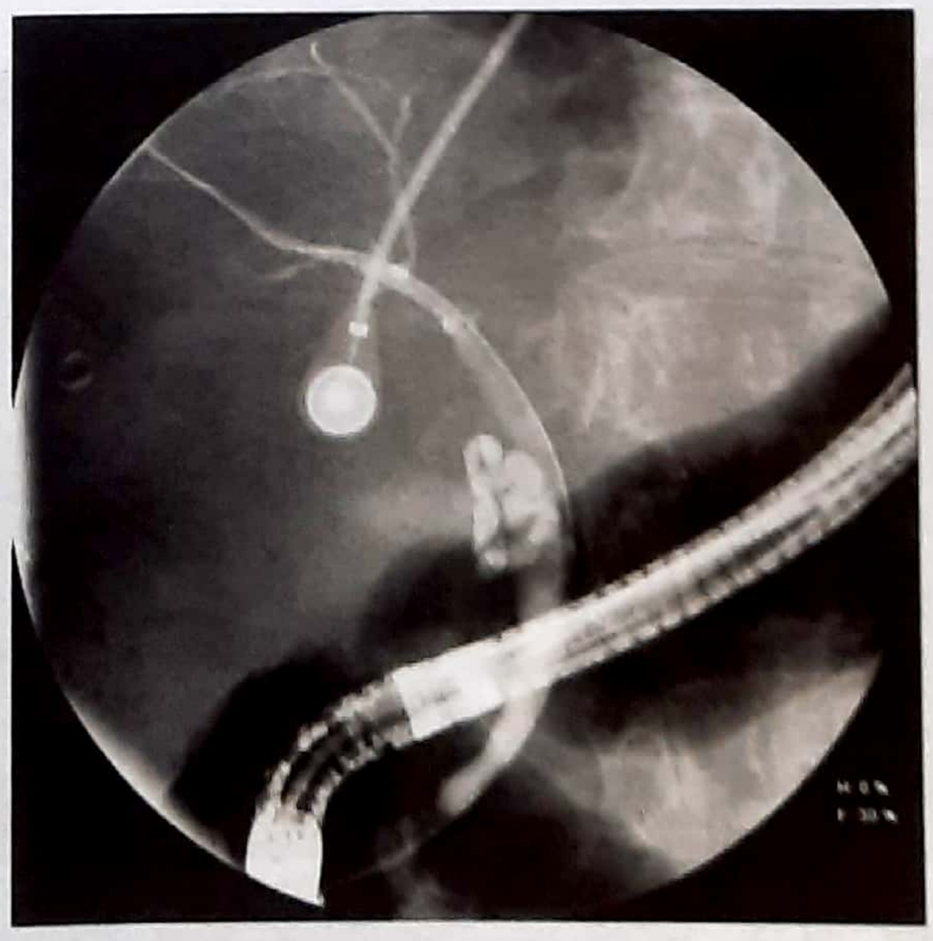

Figure 30.11: Normal endoscopic retrograde cholangiopancreatography image

Figure 30.12: Normal magnetic resonance cholangiopancreato-graphy image

give a picture of bile duct and duodenum. If the contrast fails to reach duodenum, it strongly suggests obstruction in the CBD and then the CBD should be explored (opened) for removal of stone.

NOTE: Catheter - a plastic tube

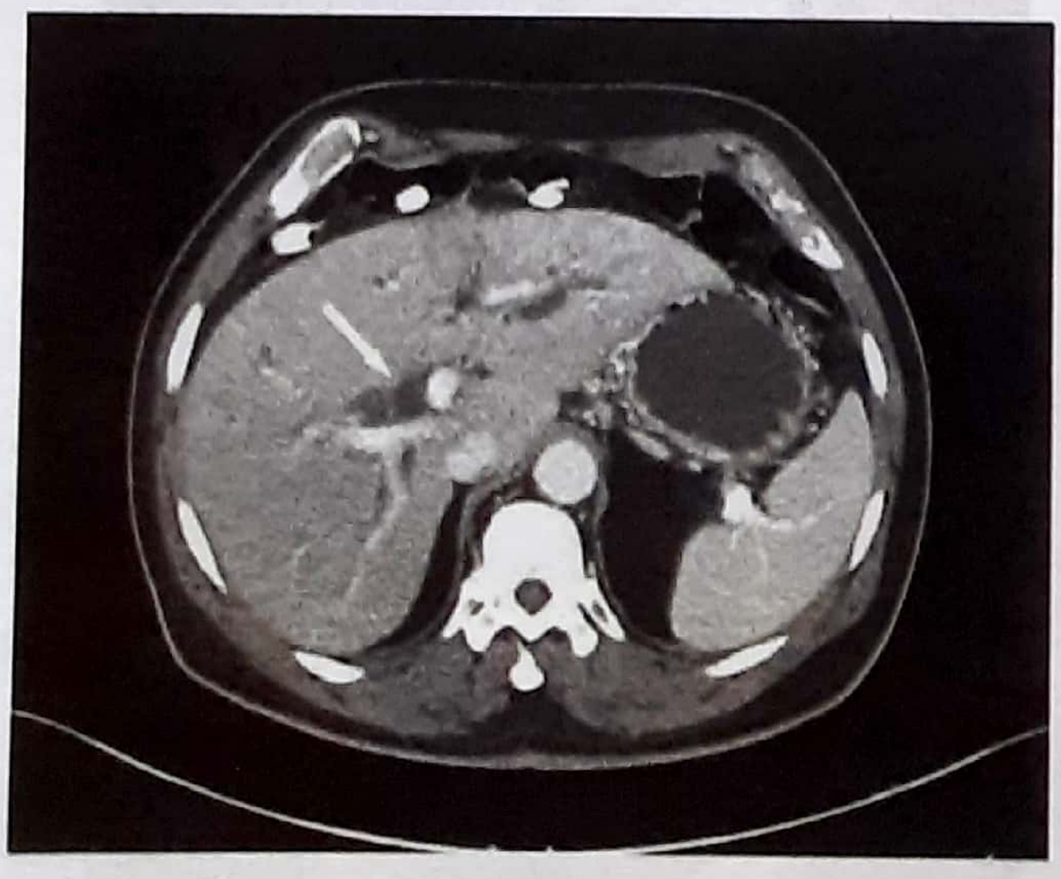

Figure 30.13: Computed tomography scan showing dilated biliary tree (*arrow*) at the portal confluence. This dilation continued down to the head of the pancreas

11. Biliary endoscopy (choledochoscopy)

At operation, a flexible fiber-optic endoscope can be passed down the cystic duct into the common bile duct helping stone identification and removal under direct vision.

It was bit boring however, till now, we have discussed surgical anatomy and investigations of biliary tract, now we will discuss diseases related to biliary tract.

****

Now lets come to disease part.

CONGENITAL CONDITIONS OF THE BILIARY TREE

1. **Absence of gall bladder:** is a very-very rare condition.

2. **Double gall bladder**

Rarely, the gall bladder is twinned. One of the gall bladder may be intrahepatic.

3. **Floating gall bladder**:

Floating gall bladder may result due to long mesentery. It may cause torsion of gall bladder, which may a rare cause of recurrent upper abdominal pain.

4. **Absence of cystic duct**:

This is usually a pathological condition. The main danger associated with this condition at surgery is damage to the common bile duct.

5. **Phrygian cap deformity**:

This deformity is present in 2-6% of cholecystogram. Phrygian cap refers to a hat worn by the people of phrygian, an ancient Asian country- Mangolia. In this deformity fundus becomes folded on itself, taking shape of pharygian cap. Please see figure 30.14, next page.

6. **Low insertion of cystic duct**:

In this; cystic duct may be quite long and its union with common hepatic duct may be as low as just above the duodenum or in some cases may join the common hepatic duct behind the duodenum.

7. **Accessory cholecystohepatic duct:** Ducts passing from liver into gall bladder (directly) do occur and are present in about 5% patients.

Figure 30.14: Phrygian cap deformity

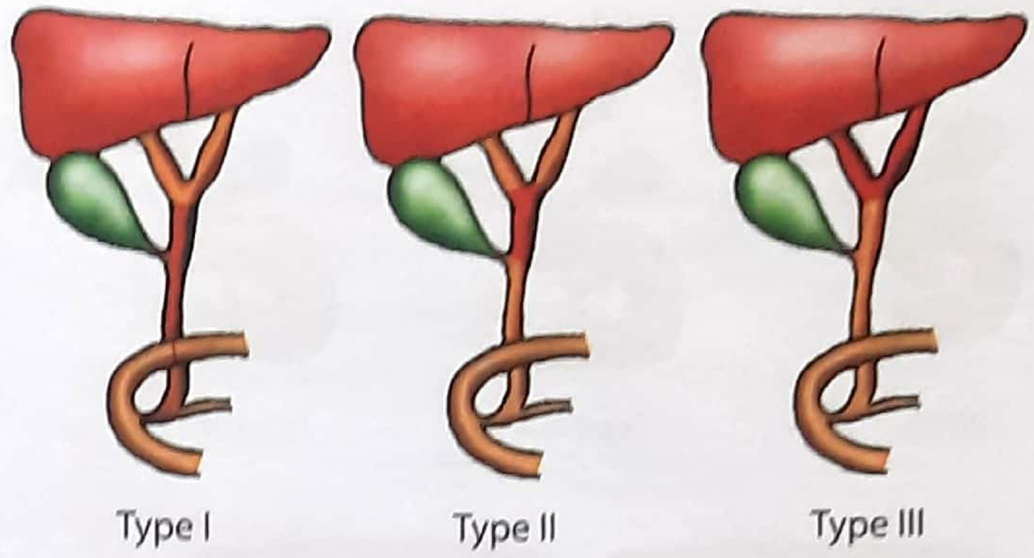

Figure 30.15: Congenital biliary atresia, Dark red indicate portion of bile duct; in which atresia is present

8. Extrahepatic biliary atresia

Etiology and pathology

Extrahepatic biliary atresia is present in 1 per 14000 live births and affects male and female equally. The extra hepatic bile ducts are progressively destroyed by an inflammatory process, which starts around the time of birth. Intra hepatic changes also occur and eventually result in cirrhosis and portal hypertension. Untreated child usually dies before the age of 3 years, because of liver failure or hemorrhage.

The inflammatory destruction of bile ducts has been classified in three main types. Please see figure 30.15.

- **Type I :** Atresia limited to the CBD
- **Type II** : Atresia of common hepatic duct
- **Type III** : Atresia of right and left hepatic duct.

Clinical feature

- About 1/3 patients are jaundiced at birth.
- In all infants jaundice is present by the end of first week and deepens progressively.
- Meconium is bile stained.
- Pruritus is present and is often severe.

Association : Malrotation of gut, Polysplenia, Hepatic artery anomalies.

Treatment

***Type* I:** Direct Roux-en-Y anastomosis between the patient proximal CBD and duodenal or jejunal loop.

***Type* II and *Type* II**: KASAI procedure, in which radical excision of all atretic bile duct tissue up to capsule of liver is performed, then a loop of jejunum is brought up and anastomosed to exposed area of liver capsule.

9. Choledochal cyst

- *Choledochal cyst is a rare* ***congenital*** *(NEET) dilatation of ext-rahepatic and/or intra hepatic biliary tract.* Though *it is a congenital condition,* most patients frequently present in infancy/childhood. The disease is more commonly diagnosed in adult *(UP 93)*.
- The incidence of choledochal cyst is 1 in 100,000.
- Choledochal cysts are three to eight time more common in women than men.
- Associated with anomalous junction of bliliary & pancreatic duct.

Classification of choledochal cyst

(Remember this with figure given with text, other wise it will be difficult) See figure 30.16 and key box 30.1.

Type I- (50%) (MC) fusiform or cystic dilatation of the extra hepatic bile duct (solitary cyst) *(AIIMS 09)*

Type II- Saccular diverticulum in extrahepatic bile duct.

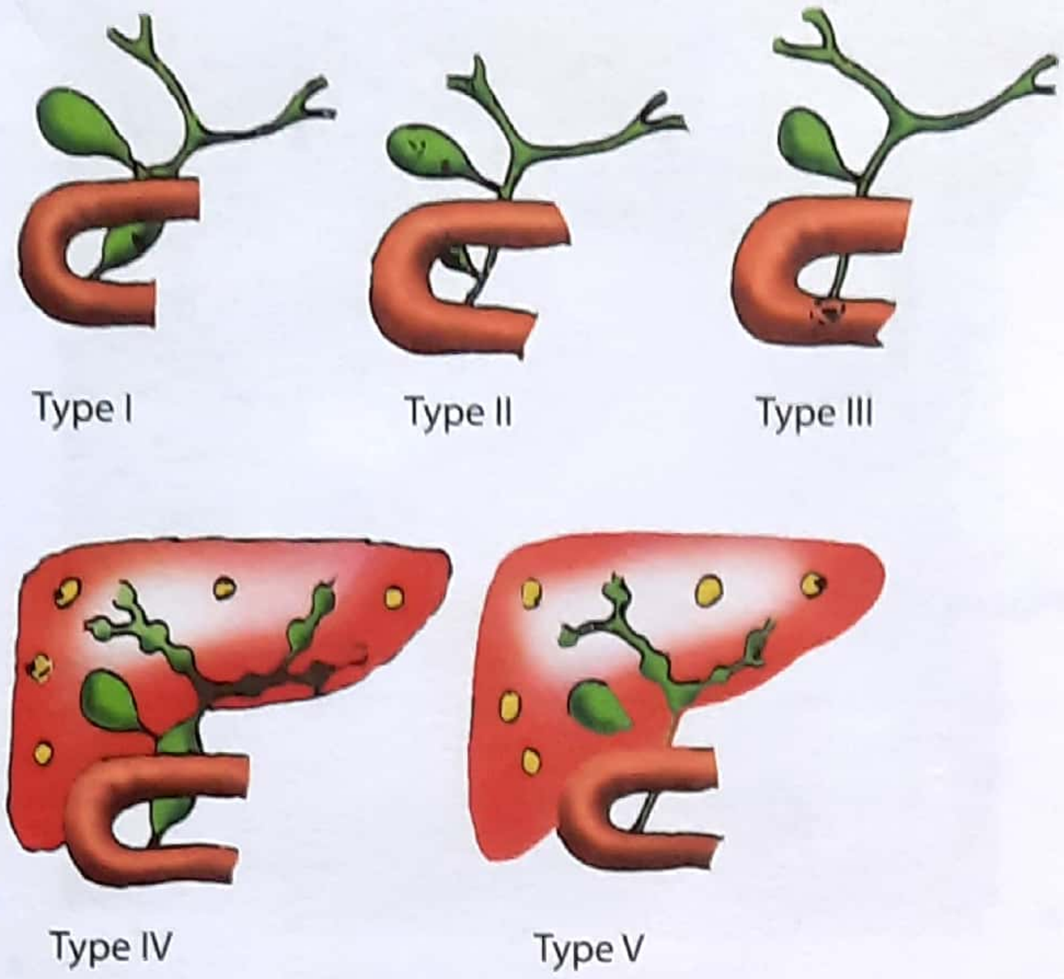

Figure 30.16: Choledochal cyst (classification)

Type III- Bile duct dilatation with in the wall of duodenum (choledochocele)

Type IV- (35%)

IVa - Fusiform intrahepatic and extrahepatic cyst.

IVb - Multiple extra hepatic cyst.

Type V- (10%)- Multiple intrahepatic cysts ***(caroli's disease)***

Clinical feature

The classical symptom **triad** consist of: *(PGME)*

1. Abdominal pain
2. Abdominal mass (epigastric lump)
3. Jaundice

However this triad is actually encountered in only 50%.

Mnemonic: JAL: Jaundice, **A**bdominal pain & **L**ump in abdomen

Investigation

USG may reveal a cystic structure arising from biliary tree. CT scan confirms the diagnosis.

- ERCP is the most reliable investigation but is invasive.
- MRCP is the best non-invasive investigation

Radiologicsal Features in Caroli's disease

1. X ray abdomen: may show hepatic calculi, if present
2. USG:
   - Dilated intrahepatic bile ducts

KEY BOX 30.1

Type	Findings	Type	Findings
I 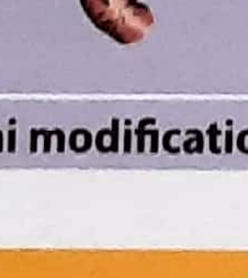	• Solitary fusiform extrahepatic cysts	IVA 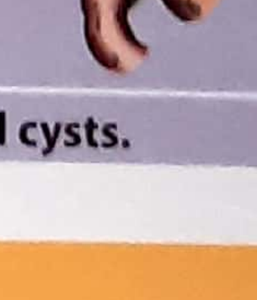	• Fusiform extra - and intrahepatic cyst
II	• Extrahepatic supraduodenal diverticulum	IVB	• Multiple extrahepatic cysts
III	• Intraduodenal diverticulum; (choledochocele)	V	• Multiple intrahepatic cysts; (Caroli's disease)

Todani modification of Alonso-Lej classification of choledochal cysts.

- Intraductual bridging (septa traversing bile duct lumen)
- Small portal venous branches partially or completely surrounded by dilated bile ducts.
- Intraducted calculi

3. CT Scan: "Central dot" sign — enhancing dots within dilated intrahepatic bile ducts (AIIMS NOV 08)
4. MRI: T1 — hepointense dilation of IHBD
   T2 — hyperintense dilation of IHBD
   (Contrast) C + Gd — enhancement of central portal radicals with in dilated IHBD.

Complications of choledochal cyst

- Cholangitis
- Gall stone/hepatic stones
- Cholecystitis
- Pancreatitis
- Cirrhosis with portal hypertension
- Malignancy
- Biliary peritonitis on rupture

Treatment

This will depend upon the location of cyst (see diagram and locate the cyst), ***however excision of the cyst with reconstruction of the biliary tract is treatment of choice.*** (NEET, AIIMS SEP 96, UP 97).

Type I and II - Cholecystectomy + resection of extra hepatic biliary tract + Roux-en-Y hepatico-jejunostomy (anastomosis between common hepatic duct and jejunum).

Type III (Choledochocele) - A duodenal approach is preferred, and transduodenal sphincteroplasty or sphincterectomy is done.

Type IV- Extra hepatic bile duct excision + Hepatic lobectomy

Type V (Caroli's disease) - The condition, when restricted to one segment or to one lobe; a segmental resection or lobectomy may be necessary. If the intrahepatic cysts are diffused; only effective treatment is liver transplantation.

Friends! The treatment written above is not very tough to remember, it will become very easy, if you understand the site of lesion (Locate it from figure 30.16 and key box 30.1)

A cystojejunostomy (anastomosis between cyst and jejunum) is not indicated because this leads to

(i) Recurrent cholangitis and
(ii) Development of biliary tract malignancy (AIIMS 01)

****

GALLSTONE DISEASE (CHOLELITHIASIS)

Gall stone disease is one of the most common problem affecting the digestive tract. The prevalence of gall stones is related to many factors, including age, gender and ethnic background.

Certain factors **predispose to the development of gallstone.** *Obesity, pregnancy, dietary factors, crohn's disease, terminal ileal resection, gastric surgery, hereditary spherocytosis, sickle cell disease and thalassemia are all associated with increased risk of developing gallstones.*

Before adolescence, men and women seems to be equally effected, there after the disease is more prevalent in women (PGL 02).

Women are three time more likely to develop gallstone than men, and first-degree relatives of patient with gall stones have a two fold greater prevalence.

Types

Gall stone form as a result of solid setting out of solution. Gall stone are classified by their cholesterol content as either cholesterol stone or pigment stone. Pigment stones can be further classified as either black or brown. ***About 70-80% of all gall stones are cholesterol gall stone*** (NEET, MANY POME). Please see key box 30.2.

KEY BOX 30.2

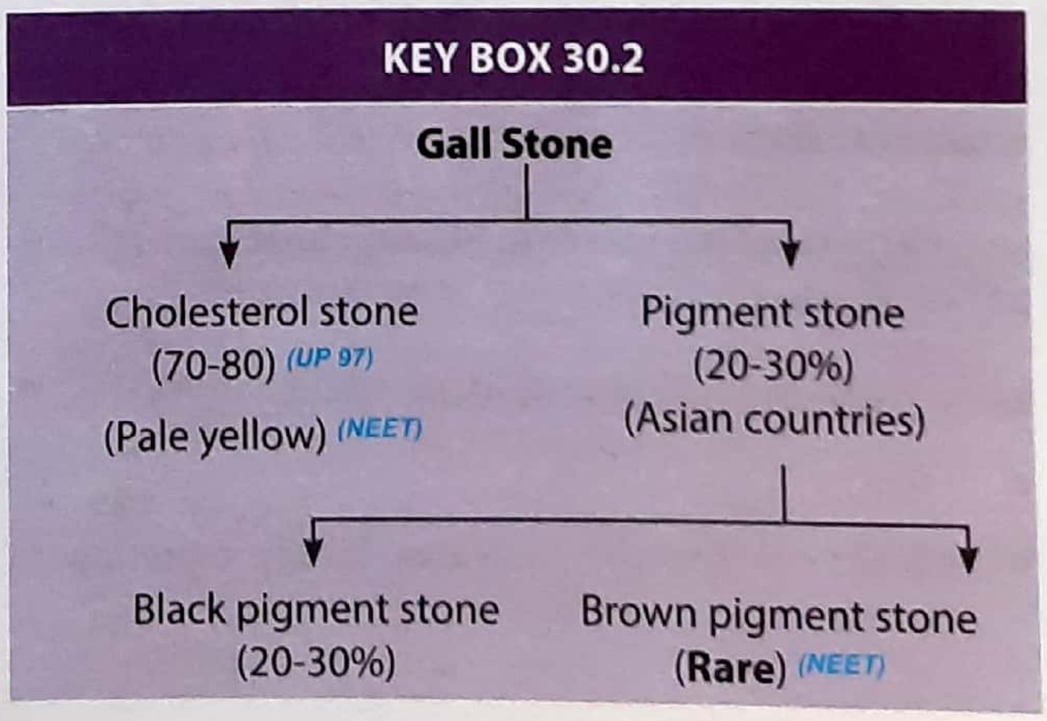

Mechanism of Gall stone formation

1. Cholesterol stones

Cholesterol is insoluble in water, and is kept in solution by bile acids and phospholipid (lecithin). Bile acid and lecithin act as solvent for cholesterol.

The pathogenesis of cholesterol gall stone can be compared to preparation of **"sharbat"** by adding sugar to water.

In gall stone formation, cholesterol is "sugar" and bile acid (& lecithin) is water, ie; solvent.

If the amount of added "sugar" increases (from a certain saturation level) in a glass of "water" sugar will precipitate at the bottom of glass, or if added water to the sugar is very less, again sugar will precipitate at the bottom of glass.

Compare it with cholesterol and bile acids. Normal ratio of bile acid ("water") to cholesterol ("sugar") is 25:1 as to keep cholesterol in solution and does not allow cholesterol to precipitate and hence stone does not form.

When cholesterol level ("sugar") increases in bile or level of bile acid ("water") decreases, this ratio drops down, and when the ratio drops down to 13:1; called as critical ratio at which the cholesterol get precipitated and formation of stone takes place. This concentrated bile is called as "super saturated bile" or "lithogenic bile".

Second factor in pathogenesis of cholesterol gall stone is stasis (hypomotility) of gall bladder.

Now consider that, if the supersaturated "sharbat" is kept on table for some time, what will happen? The "sugar" will slowly settle down at bottom, and if this glass of "sharbat" is shaken for some time the "sugar" will disappear from the bottom.

In the same way, if the bile in gall bladder is stagnant due to stasis or hypomotility of gall bladder. It will lead to gall stone formation.

By under standing these facts, you can easily make out your self the etiological factors of cholesterol gall stone formation.

(a) Factors which increase biliary cholesterol ("sugar" of sharbat) *(AI 96, 98, AIIMS 93, 94. PGI 99, JIPMER 95)*

- Cholesterol rich diet and high calorie.
- Obesity
- Clofibrate therapy (increases biliary secretion of cholesterol)
- Estrogen - increases uptake of dietary cholesterol and increases biliary cholesterol secretion
- Oral contraceptives:-decreases conversion of cholesterol to cholestrylesters, hence increases cholesterol.
- Rapid weight loss: In rapid weight loss mobilization of tissue cholesterol leads to increased biliary cholesterol.
- Diabetes mellitus.
- Rapid weight loss.

(b) Factors which decreases bile acid, lecithin ("water" in sharbat)

- Primary biliary cirrhosis - (↓ bile acid secretion)
- Oral contraceptive pills.
- Genetic factors-mutation of CYP 7A1 gene.
- Ileal resection, gastric resection (gastrectomy) *(UP 03)*
- Ileal disease (Crohn's disease)
- Enterostomy fistula (fecal fistula).

NOTE: Last three factors decrease enterohepatic circulation of bile acids and hence decrease bile acid pool.

(c) Bile Stasis or gall bladder hypomotility

- Prolonged parenteral nutrition, (no food in stomach, no contraction of bile in gall bladder)
- Fasting (again no food in stomach no contraction of gallbladder)
- Truncal vagotomy (reason has been discussed in chapter no 28, on page no.428-429).
- Drugs such as Octreotide
- Surgery, Burn
- Pregnancy
- Cystic fibrosis (results in impairment of bile flow)
- *Nucleation:* This is a process by which cholesterol mono hydrate crystals, unite to become macroscopic crystals. The most common cause responsible for this seems to be infective organism such as *E.coli, Proteus, Anaerobes* that reach gallbladder through the blood stream (portal vein) and forms a focus/ nidus around which cholesterol and bile stone get precipitated.
- Please see key box 30.3 and remember the causes of cholesterol gall stone formation with help of this box. Note: the mnemonic CHOWMEIN (Key Box 30.3).

KEY BOX 30.3
Predisposing factor for cholesterol gall stone [Chowmein]
C-Clofibrate therapy, Cholestyraaiine
H-Hyper elimenetation, High calory, High fats
O-Obesity, OCP, Octeotide
W-Weight loss
M-Mutation (MDR-3, $CYP_7 A_1$)
E-Estrogen
I-Ileal resection, Increased age
N-Total parenteral Nutrition (TPN)

2. Pigment (Bilirubin) stone

Pigment stone may be pure or consist of calcium bilirubinate. They account for about 20% of all gall bladder stone. Pure pigment stones are black or brown in colour and are found exclusively in gall bladder ***Black are associated with excessive hemolysis*** *viz; Hereditary spherocytosis, sickle Cell disease and Thalassemia.* (MANY PGME , UP 93)

Pathogenesis

Unconjugated bilirubin is much less soluble than conjugated bilirubin in bile. In hemolytic state; there occurs an increased rate of production of unconjugated bilirubin; which is excreted in bile and ultimately form pigment stone in the gall bladder

- In oriental countries, Clonorchis sinensis (Chinese liver fluke) infestation can cause stone in biliary tree. The ova of this parasite form a nidus for pigment stone.
- Ascaris lumbricoid in the biliary tree also increases chances for pigment gall stones formation.

The diseases related to gall bladder is mainly due to gall stones in the gall bladder, before going in to text please go through flow chart in Key box 30.4 on next page.

EFFECTS OF GALL STONE IN GALL BLADDER

1. Asymptomatic gall stone

It is estimated that 85-90% patients, who have gall stone remain asymptomatic, and gall stones are frequently found incidently at radiological examination; carried out for some other disease. *The presence of asymptomatic gall stone is not an indication for surgical removal of gall bladder* (cholecystectomy) (AI 97), however some surgeon advocate prophylactic cholecystectomy, because there is risk of development of malignancy of gall bladder in about 1% cases with gall stone.

2. ACUTE CHOLECYSTITIS

It is acute inflammatory condition of gall bladder. In about 95% of the case, acute cholecystitis results from obstruction of cystic duct or by an impacted stone in hartmann's pouch (obstructing cystic duct). This lead to stasis of bile in gall bladder. Residual bile in gall bladder becomes highly concentrated and cause a chemical acute inflammation.

The gall bladder shows congestion, thickening of the gall bladder wall due to edema, mucosal ulceration and exudation. The damaged gall bladder, then becomes susceptible to infection, mainly by bacteria *E.coli* and other gram negative bacilli, which are cultured from the bile in about 90% cases.

- In severe cases, gall bladder may become filled with pus; a condition known as **Empyema of gall bladder.**
- In more severe cases, necrosis of the gall bladder wall occurs with greenish black discoloration, then this condition is known as **gangrenous cholecystitis.**
- The wall of gall bladder at point of gangrene, becomes very weak and may perforate (**Gall bladder perforation),** which may lead to local abscess formation or generalized biliary peritonitis.
- An impacted stone in cystic duct will result in, what is called as **mucocele (Hydrops) of the Gall bladder.** In this condition the bile gets absorbed, but the gall bladder epithelium continues to secrete mucus and hence the gall bladder becomes grossly distended and filled with mucus.
- In some cases, gall bladder may become adherent to adjacent hollow viscus, most commonly to duodenum, followed by transverse colon and stomach, (PGME) and fistula formation may occur, leading to **cholecysto-enteric fistula.**
- Please see figure 30.17 & read key box 30.4 & 30.5 carefully. Figure 30.17 (on page 507) is very good one.

KEY BOX 30.4

Pathological Effects Due to Gallstone

(This flow chart will help you in remebering):

In the gall bladder	In common bile duct	In Pancreas	In small intestine
• Asymptomatic galls stone • Acute cholecystitis • Chronic cholecystitis • Mucocele gall bladder (Hydrops of gall bladder) • Empyema gall bladder • Gangrenous cholecystitis • Gall bladder perforation • Cholecysto-enteric fistula • Carcinoma of gall bladder	• CBD stone (obstructive jaundice) • Cholangitis	• Acute pancreatic • Chronic pancreatitis	• Gall stone ileus

Each condition will be discussed one by one in the text.

Clinical Feature

- *A fat, fertile, flatulent, female of forty* [Note 5 '*f*'] is the classical sufferer from symptomatic gall stone.
- Patient often presents with severe upper abdominal pain, most commonly on the right side of upper abdomen. Pain does not subside, it is unremitting and may persist for several days.
- Nausea and vomiting are important symptom and are seen in about 70% cases.
- Fever is often of mild grade.
- Jaundice is present in only 10% cases.
- *Murphy sign;* During deep palpation of the right upper abdomen, patient is asked to take deep breath. Patient complains of severe pain during deep inspiration with inspiratory arrest; because the tender enlarged gall bladder comes down (with inspiration and comes in contact of palpating finger) (PGME) *Boss's sign* :If present is diagnostic of acute cholecystitis. *This is an area of hyperaesthesia between the 9th and 11th rib posteriorly on the right side.* (NEET, PGME)
- Pain radiates to shoulder through irritating C3-C5 nerve root.
- A gall bladder lump in right hypochondrium is palpable in about 40% of cases.

Investigation

Hematologic

- Leucocyte count is often elevated to 12,000-15000/ uL.
- Mild elevation in serum bilirubin.

Ultrasonography

It has become now-the **first line investigation** for gall bladder disease. (MANY PGME)

- Ultrasound scan shows gallstone, sludge (mud) and thickening of gall bladder wall.
- Ultrasound will also inform about pericystic collection (collection of fluid around gall bladder secondary to inflammation)
- USG is now investigation of choice for gall stone disease.

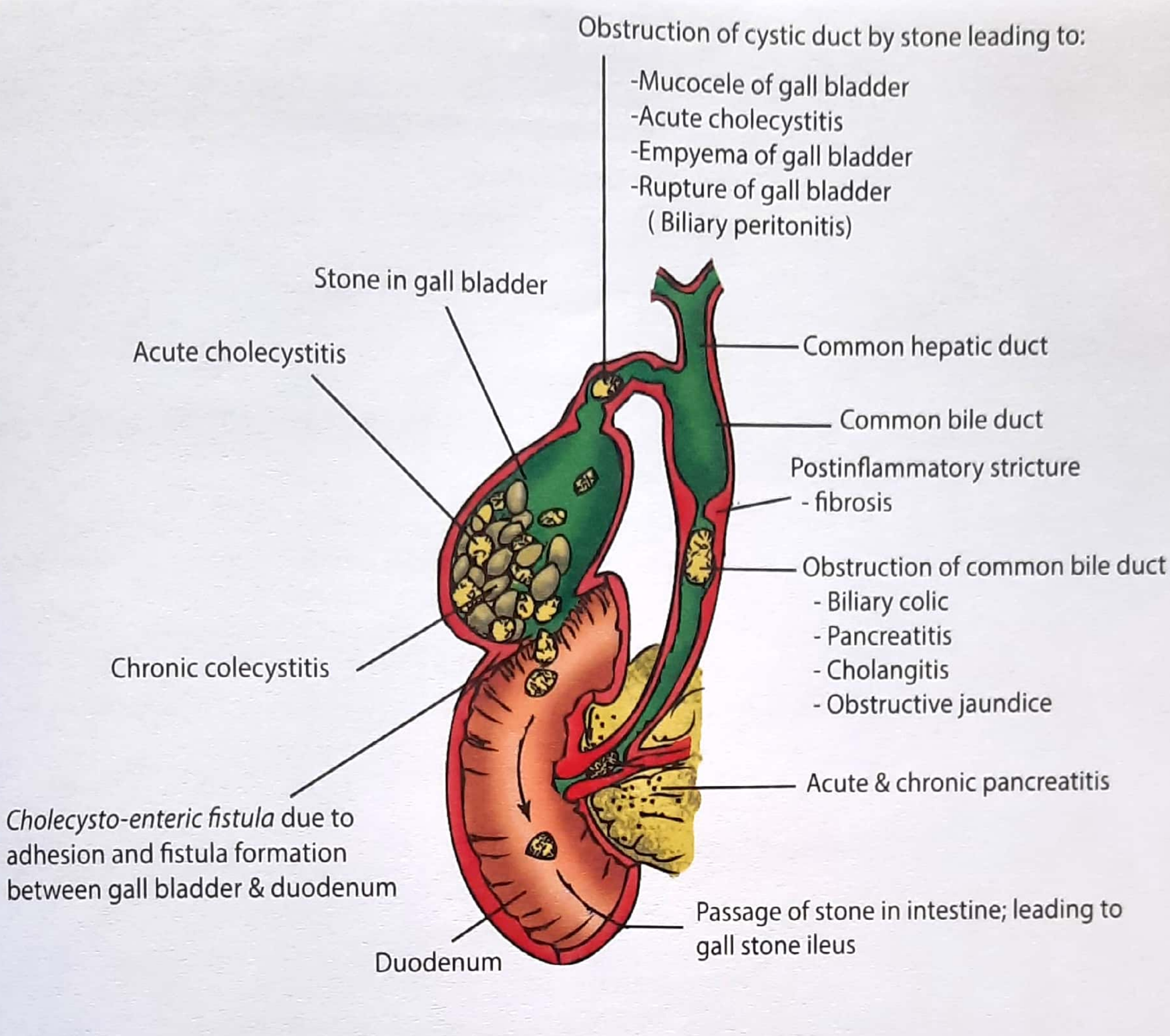

Figure 30.17: Clinical and pathological effects of cholelithiasis

Isotope scanning (HIDA, PIPIDA scanning)

- Following I.V. injection of radio nuclide (HIDA/ PIPIDA/IODIDA), they appears in the biliary tree in 15-30 minutes.
- *In acute cholecystitis gall bladder is not visualized, even through the dye is excreted in biliary tree.* (MANY PGME)
- Lack of filling of gall bladder by radio nuclide, even after 4 hours indicate an obstructed cystic duct and is *highly sensitive and specific for acute cholecystitis.* (IMP POINT)

Reason for non-visualization of gall bladder is that, the dye is unable to enter the gall bladder, because in about 95% cases, there is impaction of gall stone either in cystic duct or in Hartmann's pouch. Edema of cystic duct also causes narrowing of cystic duct and prevents dye to reach gall bladder resulting in non visualization of gall bladder.

X-ray of the abdomen

Only 10% gall stones are radio-opaque (NEET) & cast film on X-ray.

NOTE: Oral cholecystogram is not done during acute cholecystitis due to presence of nausea and vomiting, and hence there is all chances of dye to be vomited and making investigation useless.

Treatment

- I.V. fluid-patient is kept on I.V. fluid and is given nothing by mouth.
- **Antibiotics:** Third generation cephalosporins (ceftriaxone) and metronidazole.
- **Analgesic and antispasmodic** -Injection morphine as an analgesic and injection atropine to relieve spasm of sphincter of oddi.

KEY BOX 30.5

Pathological events due to gall stone

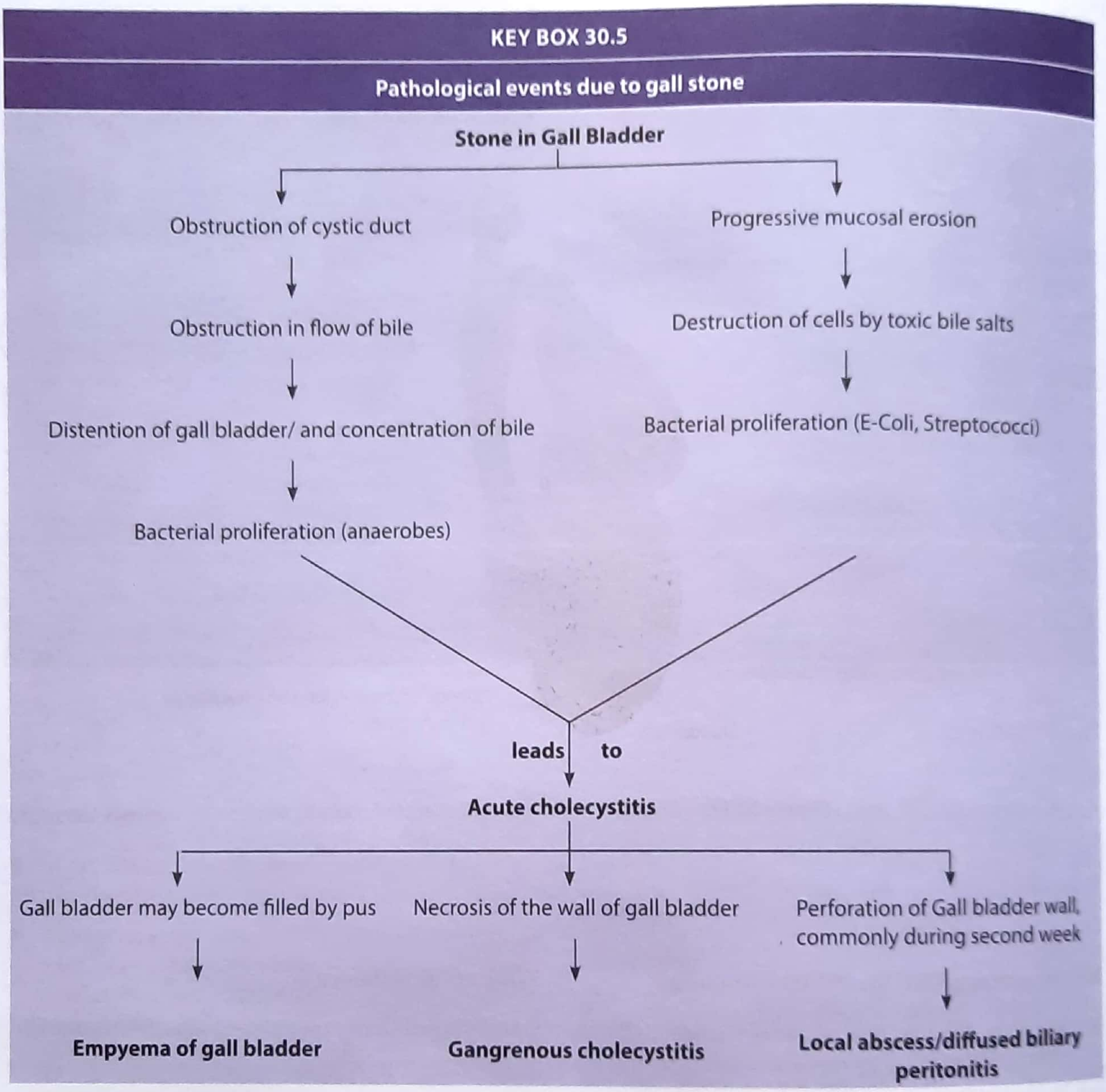

- **Early cholecystectomy;** Cholecystectomy (removal of gall bladder) is the definitive treatment for acute cholecystitis. The timing of cholecystectomy has been a matter of debate in past. Early cholecystectomy, ie; performed- with in 2 to 3 days of illness is preferred over interval cholecystectomy or delayed cholecystectomy, that is performed 6-10 weeks after initial medical treatment. Four controlled trial have supported this approach with the following data :

1. The incidence of technical complications are no greater with early cholecystectomy.
2. Early surgery reduces the total duration of illness by approximately 30 days and a definitive solution in-one hospital admission, quick recovery time and early return to work.
3. Death rate is slightly lower with early surgery because of earlier treatment for some patients whose condition would have worsened during expectant medical management.
4. The only specific contraindication to early cholecystectomy is serious concomitant disease, and if patient is unfit for surgery.

- Now a days laparoscopic cholecystectomy has become *the procedure of choice for acute cholecystitis.* (PGME)

Contraindication of laparoscopic cholecystectomy

- Refractory coagulopathy
- Obstructive pulmonary disease
- End stage liver disease

Differential diagnosis for acute cholecystitis

- Peptic ulcer with or without perforation
- Pancreatitis
- Appendicitis (high retrocecal appendicitis)
- Hepatitis
- Right side pneumonitis
- Pleuritis
- Myocardial ischemia
- Right side nephrolithiasis

3. Chronic cholecystitis

- About two third of patients with gall stone disease present with chronic cholecystitis; characterized by *recurrent attacks* of right upper abdominal pain.
- The pain develops due to a stone obstructing the cystic duct, resulting in progressively increasing tension in gall bladder wall.

Figure 30.18: Chronic cholecystitis

Figure 30.19: Laparoscopic photograph of gall bladder

- Recurrent attacks of cholecystitis convert the gall bladder into a fibrosed, non functioning, shrunken, small gall bladder.

Clinical Feature

The **chief symptom** associated with symptomatic gall stone are-

- The pain which is usually situated in right upper abdomen; increases in severity over half hour or so and *typically last for 1-5 hours.*
- It is located in right upper abdomen or epigastrium and frequently radiate to the right upper back or between two scapula.
- Pain is often precipitated by a fatty meal.
- Pain is episodic and between the attacks patient feels well.

Figure 30.20: Gall stone in cut section of gall bladder

- *When the pain lasts more than 24 hours, an impacted stone in the cystic duct or acute cholecystitis should be suspected.*

Investigation

USG Scan

An ultrasound scan of the gall bladder should usually be the first test (PGL 85). Gallstone can be demonstrated in about 95% of cases. Presently USG has become investigation of choice for gall stone disease.

Oral cholecystogram (Graham Cole's Test)

An oral cholecystogram should be obtained, if the ultrasound study is equivocal. (This test has been described earlier in this chapter).

Complication

Chronic cholecystitis predisposes to acute cholecystitis, common bile duct stone, and ***adenocarcinoma*** of gall bladder. The longer the stone have been present, the higher the chance of incidence of all these complication. However any presence of gallstone is not reason enough for prophylactic cholecystectomy, however some surgeon advice prophylactic cholecystectomy because there is an increased risk of development of carcinoma.

Generally chronic irritation results in development of squamous cell carcinoma else where in body, but *gall stone disease, resulting in chronic irritation of gall bladder mucosa results in development of Adenocarcinoma.* (PGME)

Treatment

A. Conservative (non-surgical)

1. Medical treatment

Pure cholesterol stones in the gallbladder can be dissolved in some cases, by long term treatment ***with ursodiol,*** which reduce cholesterol saturation of bile by inhibiting cholesterol secretion. (AIIMS 96, AI 98, UP). *Medical treatment has no role in treatment of pigmented gall stone,* (IMP. POINT)

However unfortunately, bile salt therapy has marginal efficacy.

Patient selection for medical treatment

- Patient with pure cholesterol gall stone.
- The gall stones must be small (<5mm) and devoid of calcium.
- Non opaque gall stone (radiolucent stones).
- Gall bladder must be functioning (to be tested by oral cholecystography before starting treatment)

Drug used are

- **Chenodeoxycholic acid** (NEET)
- **Ursodeoxycholic acid** (NEET , PGI 95)
- Dissolution of stone is achieved with in 2 years in about 50% of selected patients. However stone recur, in 50% of cases with in 5 years.
- In general medical treatment is used only rarely.

2. Lithotripsy (ESWL)

This technique has become quite successful for renal calculi but not with gall stones. Renal stone pass spontaneously after fragmentation by ESWL, but the biliary tract does not provide, such simple passage for fragmented gall stones, hence it is of little therapeutic value in gall stone disease. (PGI)

B. Surgical treatment

Indication of Cholecystectomy (PGI 07)

- Laparoscopic cholecystectomy is treatment of choice for gall stone disease unless contraindicated. Emergency Laparoscopic cholecystectomy is indicated in following situations :
  1. Acute cholecystitis
  2. Emphysematous cholecystitis
  3. Empyema of gall bladder
  4. Gall bladder perforation
  5. after ERCP for CBD calculi
- Elective
  1. Biliary Dyskinesia (diagnosed by HIDA scan)
  2. Chronic cholecystitis
  3. Symptomatic cholelithiasis
  4. GB polyp > 10 mm or Symptomatic

Indications for open Cholecystectomy

1. Poor pulmonary or Cardiac reserve
2. Suspected or known gall bladder cancer

3. Cirrhosis and portal hypertension
4. Third trimester pregnancy
5. As part of laparotomy for other procedures.

Contraindication -

- Uncontrolled coagulopathy
- End stage liver disease
- Coronary artery disease

Cholecystectomy

Cholecystectomy is indicated in most patients with symptomatic gall stones. *(PGI 2000)*

Cholecystectomy is most often performed laparoscopically, but when the laparoscopic approach is contraindicated or unsuccessful, it may be performed through laparotomy,

Steps in Open Cholecystectomy are shown in figure 30.21 & 30.22.

[Laparoscopy = Abdominal exploration using a type of endoscope, where no incision is made on abdominal wall. Operation is performed after making small holes on abdominal wall, through which laparoscope is passed in to the abdominal cavity, and operative procedure is completed]

4. Mucocele (hydrops) of Gall bladder

This occurs when the **neck of the gall bladder gets obstructed by a gall stone,** *(NEET)* and mucus secreted by gall bladder mucosa fills and swells gall bladder, however the content within gall bladder remain sterile. The bile is absorbed and replaced by mucus secreted by gall bladder epithelium. The **gall bladder may become palpable** and may become enlarged several times. A mucocele can also occur in tumours, that occlude the cystic duct, eg; cholangiocarcinoma. Please see figure 30.23.

Treatment

is early Cholecystectomy *(NEET, AIIMS 04)* to avoid complication such as infection, perforation of gall bladder.

5. Empyema of Gall bladder

In this condition gall bladder is filled with pus. It may be a sequel of acute cholecystitis or as a result of a mucocele becoming infected. The treatment is drainage of gall bladder and later (interval) Cholecystectomy.

6. Acute Acalculus cholecystitis

- Acute inflammation of gall bladder can occur without gall stone. Acute acalculus cholecystitis accounts 5-10% of all patients with acute cholecystitis.
- Acute acalculus cholecystitis typically develop in:
  - (i) Critically ill patients in ICU,
  - (ii) Patients on total parenteral nutrition
  - (iii) With excessive burn,
  - (iv) Sepsis,

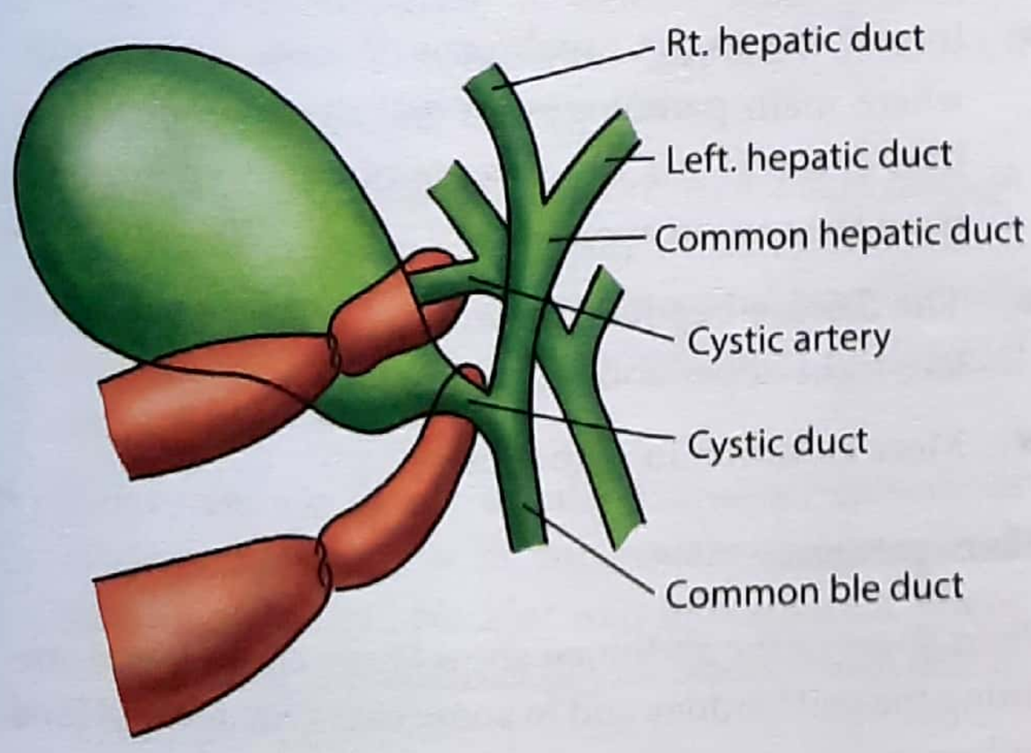

Figure 30.21: Ligation of cystic duct & cystic artery during open Cholecystectomy

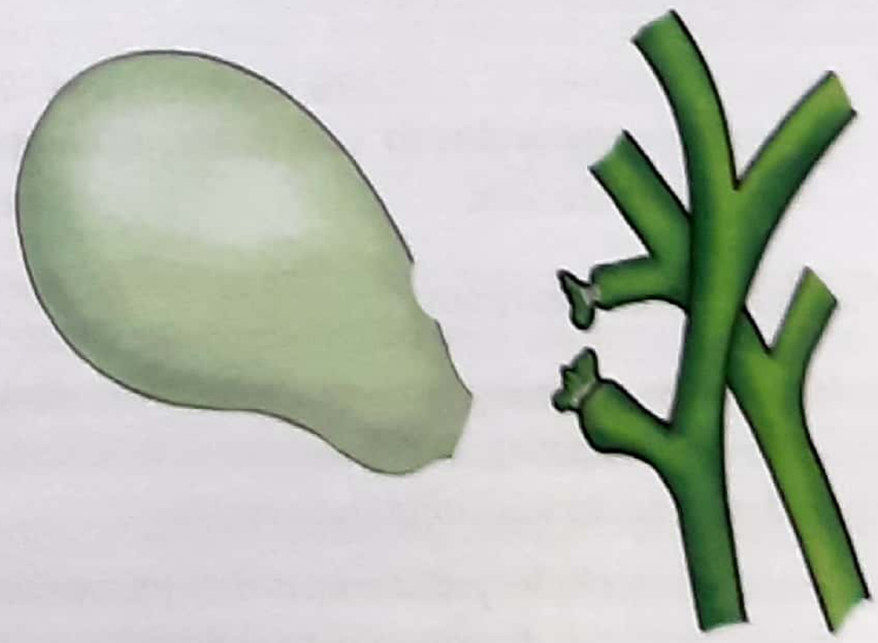

Figure 30.22: Divided (cut) Cystic duct & Cystic artery after ligation during open Cholecystectomy

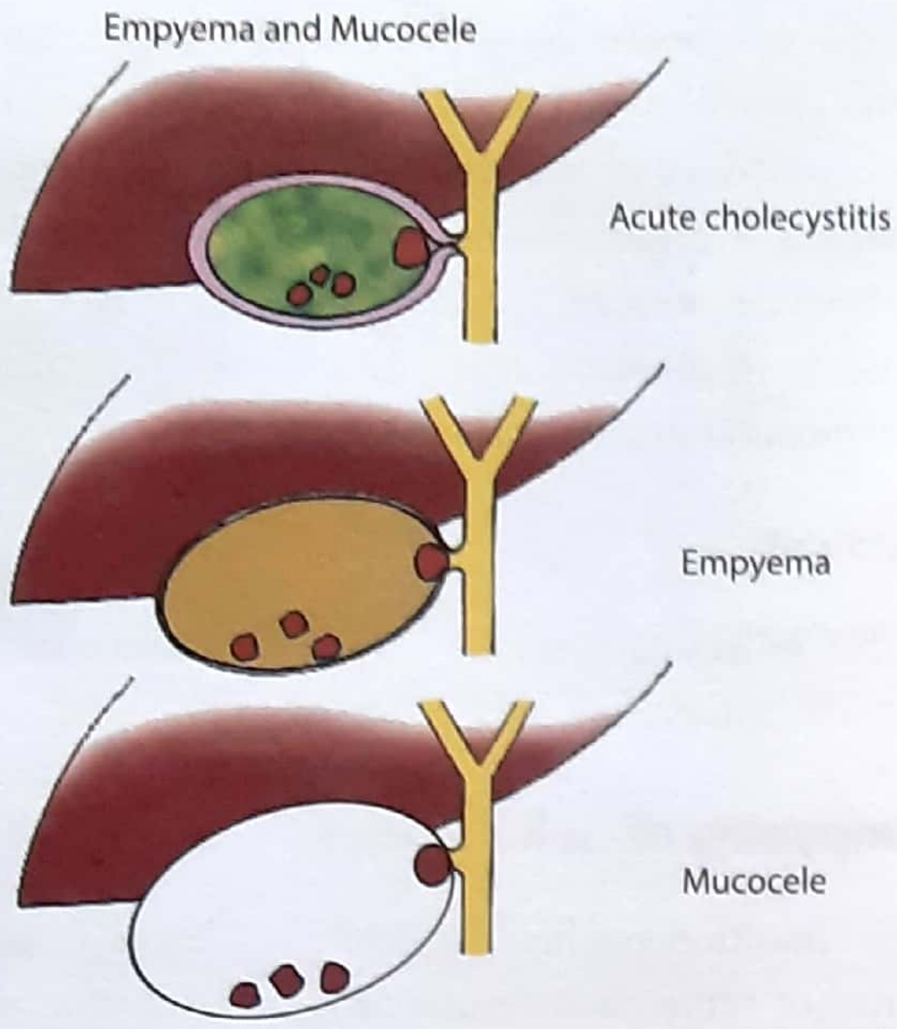

Figure 30.23: Effects of gall stone to gall bladder

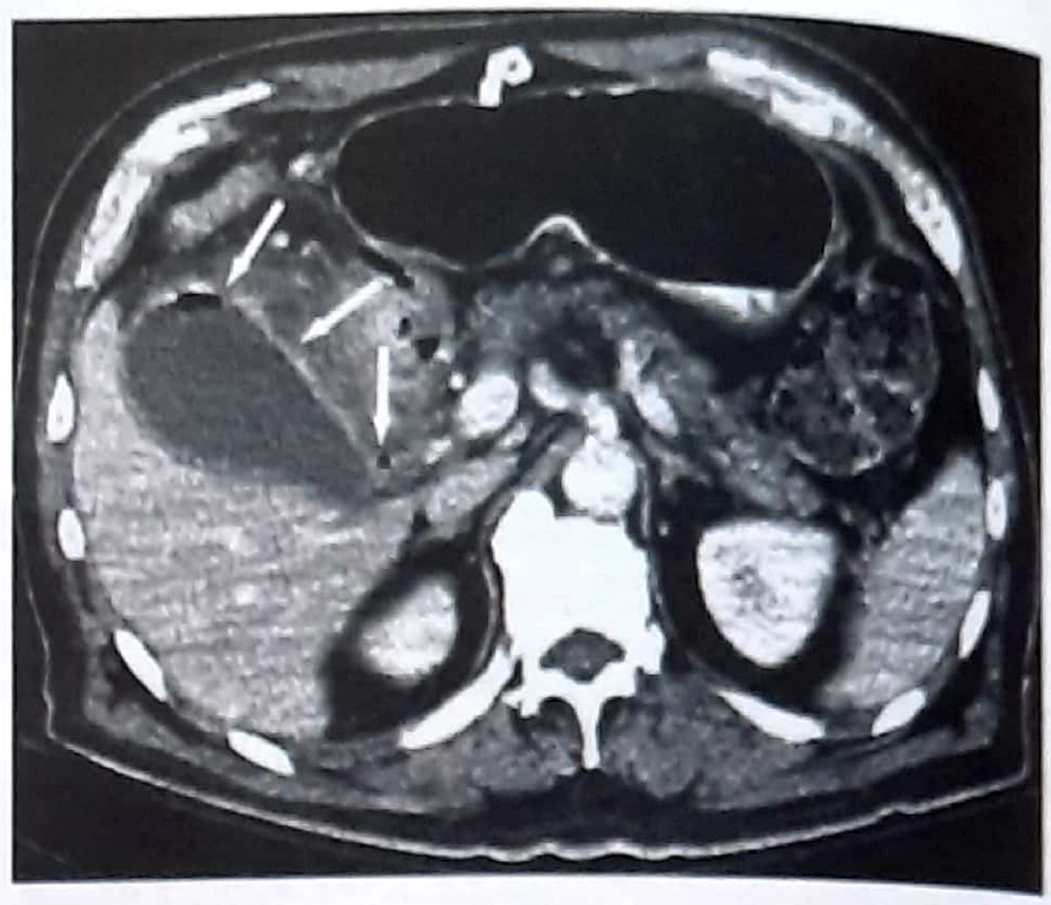

Figure 30.24: Computed tomography scan of emphysematous cholecystitis. Significant pericholecystic inflammatory changes and air in the gall-bladder wall (*arrow*) are signs of emphysematous cholecystitis.

(v) Major operation, and multiple organ failure (MOF).

- The etiology of acute acalculus cholecystitis remain unclear, although **gall bladder stasis** and **ischemia** & **Schistosomiasis** have been most often implicated as causative factors.
- The symptoms and signs of acute acalculus cholecystitis are similar to acute calculus cholecystitis with right upper quadrant pain and tenderness, fever and leucocytosis.
- The condition is associated with diabetes (possibly due to predisposition to infection).
- The post operative acalculus cholecystitis runs a fulminant course and ends with gangrene and perforation of gall bladder.

Diagnosis and treatment

Radio-isotope scanning is more useful than ultrasound. Radioisotope scanning will show absent gall bladder filling of dye in acute acalculus cholecystitis.

- Emergency cholecystectomy is the appropriate treatment, once the diagnosis is established.
- Mortality rate is as high as about 20%.

7. Emphysematous cholecystitis

- Emphysematous cholecystitis is a rare condition is which bubbles of gas produced by anaerobic infection appear in the lumen of the gall bladder or in its wall, pericholecystic space and sometimes even in bile duct also.
- **Clostridia species are most commonly implicated** *(NEET)* organism, but other gas forming anaerobes such as *E. coli* may also be found.
- This disease is **more common in men** (male: female ratio, 3:1) and 20% of them have diabetes mellitus.
- In contrast to the usual form of acute cholecystitis where main pathology is a gall stone, emphysematous cholecystitis is a disease of bacterial infection from the earliest moment.
- The disease begins with sudden and rapid progressive right upper abdomen pain.
- More common in diabetics.

Management *(UPSE 08)*

Plain X-ray of the abdomen show tissue emphysema outlining the gall bladder and in some cases, an air fluid level in lumen.

The patient should be treated with high dose antibiotic effective against clostridia and other species mentioned above. Cholecystectomy can be safely performed in most cases; once infection has been controlled.

8. Cholesterosis (Strawberry gall bladder)

(NEET, JIPMER 81, MANY PGME)

- *In this condition the (red) mucosa of the gall bladder is studded with small yellow flecks, giving a typical picture of ripe strawberry.* (KAR. 94)
- *Cholesterol content of the mucosa of strawberry gall bladder is very high* than the normal gall bladder, (PGME)
- This condition may be associated with cholesterol gall stones.
- Occasionally focal collection of lipid laden histiocytes may give appearance of polyp, which is known as ***cholesterol polyp.***
- In most cases; cholesterosis does not produce any symptom.

Limey Bile?

This is a condition when the gall bladder is filled with mixture of calcium bicarbonate and calcium phosphate giving a consistency of white tooth paste (KAR 94). The condition usually results due to gradual obstruction of the cystic or common bile duct, due to: chronic pancreatitis, cholangiocarcinoma or carcinoma of pancreas.

9. Biliary enteric fistula (cholecysto-enteric fistula)

- *Biliary enteric fistulae may occur between the gall bladder and first part of duodenum (most commonly) and less common between transverse colon or stomach* (see figure 30.10) (AIIMS JUNE 93, UP 97)
- *Passage of large gallstone of more than 2.5cm through the fistula into duodenum may cause obstruction at narrowest point of the gastro intestinal tract; usually in terminal ileum 25 to 50cm proximal to ileocecal valve.* (AIIMS, AL, UP MANY PGME)
- Biliary enteric fistula usually follow an episode of acute cholecystitis with subsequent gangrene and perforation of gall bladder wall into adjacent viscus or from pressure necrosis of gall bladder wall due to an impacted gall stone.
- X-ray of abdomen will show gas in the biliary tree, because intestinal gas may enter in biliary tree through fistulous connection between gall bladder and intestine.

Here, I will strongly advice you to go through key box 30.4 and 30.5, so that you can recap the whole story being discussed,

10. Gall stone Ileus

- Gall stone ileus is ***mechanical intestinal obstruction,*** caused by a large gall stone lodged in the lumen of gastrointestinal tract (most commonly *in terminal Ileum).* (AI 94, 97, 99, 04, AIIMS 04)

NOTE: The term gall stone ileus, is a misnomer, the cause of intestinal obstruction in gall stone ileus is mechanical ie; due to blockage of intestinal lumen by a stone and is not due to ileus (ie; loss of peristaltic activity). (PGME)

- This condition is most often seen in women, and the average age is about 70 years.
- The patient usually presents with small bowel obstruction. The obstructing gall stone enters the intestine through a *cholecysto enteric fistula located in duodenum, transverse colon and stomach (in that order of frequency)* (AIIMS, AL, PGI, MANY PGME)

Rigler's triad

- Pneumobilia
- Small bowel obstruction
- Gall stone in RIF

Management

The initial management of gall stone ileus includes relieving the obstruction. After opening the abdomen (laparotomy) the stone is extracted from the lumen of bowel by opening the intestine by an enterotomy. Additional gall stone is searched in intestine, as recurrent obstruction has been reported in up to 10% of patients with gall stone ileus.

Closure of fistula and cholecystectomy is necessary, because recurrent cholecystitis and cholangitis is common in patients with biliary enteric fistula, and gall bladder cancer has been reported in 15% of patients.

However if the patients is too unstable to withstand a prolonged operative procedure, the fistula can be closed at a second laparotomy after 6-8 weeks of first laparotomy.

Here, I would like to discuss two more condition, however they are relatively uncommon conditions :

Stone Syndromes

1. **Mirizzi Syndrome** (NEET) : It comprises obstructive jaundice due to stone impacted in the neck of gall bladder, which compresses the common hepatic duct and eventually ulcerates into common hepatic duct causing cholecysto-choledochal fistula (fistula B/W gall bladder & common hepatic duct) (Figure 30.25).

2. **Bouveret's Syndrome:** It is a very rare condition. There is duodenal obstruction due to passage of gallstone from gall bladder into duodenum through cholecysto duodenal fistula, (fistula B/W gall bladder & duodenum)

Figure 30.25: Mirizzi Syndrome

****

Before proceeding further please go through key box 30.6 on next page to know the effects due to a common bile duct stone. Also see figure 30.26

CHOLEDOCHOLITHIASIS (STONE IN COMMON BILE DUCT)

Approximately 15% of patients with stone in the gall bladder, are found to have stone in common bile duct. In only 5% cases there is only bile duct stone, without associated stone in gall bladder.

- The stone, which originate in the gall bladder and reach (drop down) the common bile duct after traversing cystic duct are called *Secondary common bile duct stones,* where as the stone developing in the bile duct it self are called *as Primary common bile duct stones.*
- *About 60% of common bile duct stones are cholesterol stones and 40% are pigment stone.*
- *The two main cause of primary CBD stone are: infection, and bile duct stasis.* (MANY PGME)

Clinical feature (PGI 02, MANY PGME)

Patient may have one or more of the following principal clinical feature, all of which is caused by obstruction in the flow of bile or pancreatic juice. Patient presents with;

- Biliary colic
- Cholangitis
- Obstructive jaundice
- Acute pancreatitis

However as *many as 50% of patient with CBD stone remain asymptomatic,* rest 50% who have symptom will have following feature (Please see key box 30.6.)

- *Biliary colic-right* upper abdomen pain, which is usually intermittent and is often associated with nausea and vomiting.
- *Biliary colic, jaundice or pancreatitis* may be isolated finding or may occur in any combination along with signs of infection (Cholangitis)

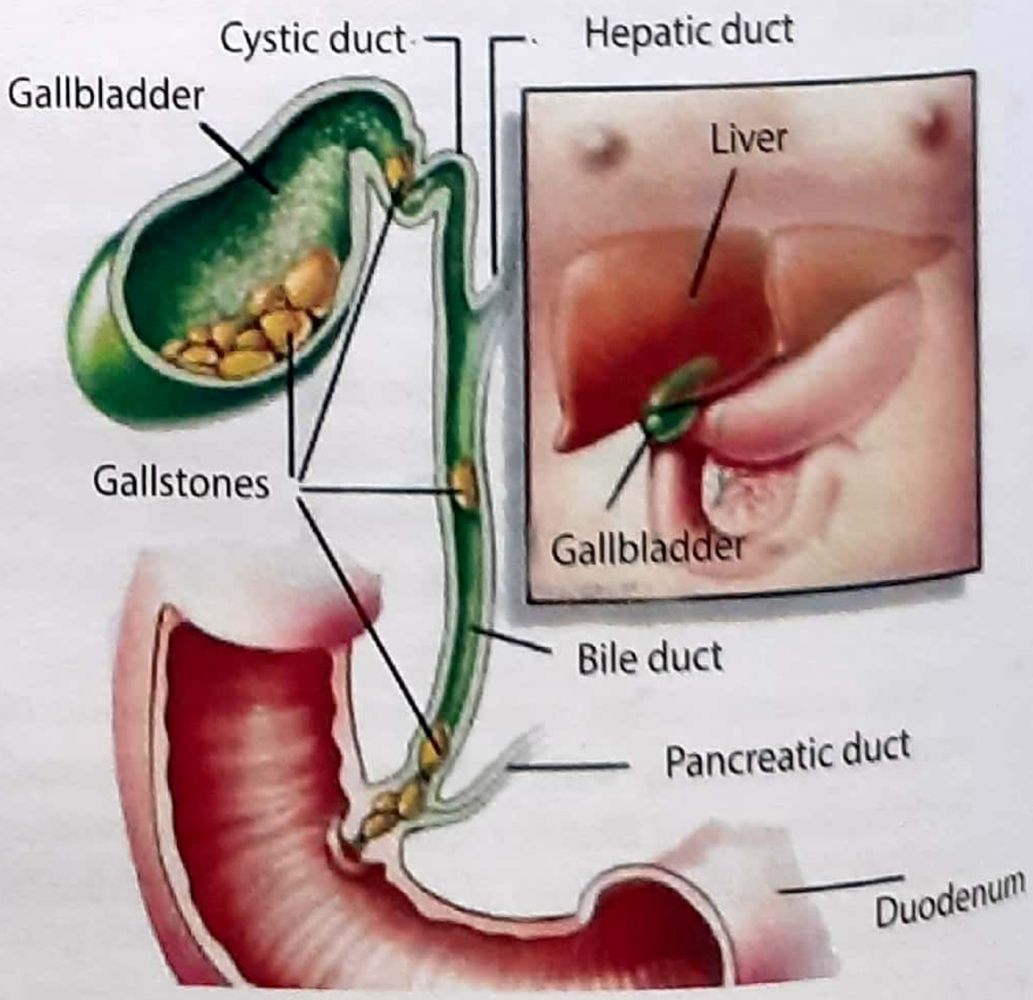

Figure 30.26: Gall bladder stone with CBD stone

KEY BOX 30.6



- *Choledocholithiasis should be strongly suspected if intermittent chills, fever, or jaundice accompanies biliary Colic.* (IMP. POINT)
- *Pruritus is usually as a result of long standing obstructive jaundice.*
- *Stool is often* ***clay*** *coloured* (PGME).

Investigation

1. Laboratory finding

- Increased WBC count: Leucocytosis of 15000/ml is usual and may be as high as 20,000/ml.
- Increased serum alkaline phosphatase, 5-nucleotidase.
- Increase Gamma-glutamyl transpeptidase (GGT).
- Increased serum bilirubin (usually less than 10mg/dl, if it is more than l0mg/dl, neoplastic obstruction is likely).
- Elevated SGOT and SGPT (AST & ALT).

NOTE: Complete obstruction of bile duct in choledocholithiasis is unusual. Bilirubin levels do not ordinarily reach the high values; as seen in malignant tumours of CBD or pancreatic head obstructing the CBD. The jaundice is *often fluctuating* and is so characteristic of choledocholithiasis, that it is fairly reliable indicator in differentiating benign and malignant common bile duct obstruction.

The bilirubin level is *usually* below 10 mg/dl in case of obstructive jaundice due to common bile duct stone, while it is usually more than 10 mg/dl in case of carcinoma of pancreas or Carcinoma of common bile duct causing obstructive jaundice.

2. Imaging study

- *X-ray and CT Scan:* Radio-opaque stones can be seen on plain X-ray-abdomen or CT scan.
- ***Ultrasonography***: Ultrasonography is useful in giving information about the stone in gall bladder as well as in common bile duct, however is difficult to demonstrate the common bile duct stone, due to bowel gas; which interferes with ultrasonic waves.
- A dilated common bile duct (>8 mm in diameter) on ultrasound in a patient with gall stone associated with jaundice and colicy pain is highly suggestive of common bile duct stone.
- ***MRCP:*** *Magnetic resonance cholangiopancreaticography* provides excellent anatomic detail of biliary tract. It is best *non invasive investigation* for a CBD stone, (MAY BE A FUTURE PGMEE QUESTION)
- ***ERCP:*** (AIIMS03, PGL 97) Endoscopic retrograde cholangio pancreaticography is the ***gold standard*** *for diagnosing common bile duct stone.* It has an added advantage of providing a therapeutic option (removal of stone) at the same time of diagnosis. Note; this an *invasive* procedure, as an endoscope has to be passed in duodenum through stomach to cannulate the ampulla of vater.
- For detail on MRCP & ERCP- Page 462 figure 30.27 & 30.28.

Treatment (PGL 01, AIMS 97, AI 99, AIIMS 01)

It can be divided for description purpose as:-

1. **Endoscopic (ERCP) removal with sphincterotomy (Treatment of choice)** (NEET, ALL-MS 94).
2. Laparoscopic choledochotomy*
3. Open choledochotomy

NOTE: *Choledochotomy means surgical opening of the common bile duct by a surgical incision.*

1. Endoscopic removal

If endoscopic retrograde cholangio pancreatogram (ERCP) has shown ductal stone, **(Choledochotomy) Performs at 11'o clock sphicterotomy** (NEET) (of oddi) and stone extraction can be performed and common bile duct is then cleared of stone.

2. Laparoscopic choledochotomy

Laparoscopic common bile duct exploration via cystic duct or common bile duct allows the stone to be retrieved in the same setting.

3. Open choledochotomy

An open common bile duct exploration (note: open here means by laparotomy) is an option, if endoscopic method has already been tried without success, or is for some reason not feasible.

After opening the abdomen (laparotomy); common bile duct is identified and is opened by incising just over the stone, then the stone is taken out and a *T tube is placed in CBD. 10-14 days later T-tube can be taken out (TN 99, KAR 96) as by this time tract is matured (epithelized).

T tube: A plastic tube made in 'T' shape.

****

Figure 30.27: Endoscopic resonance cholangiopancreatography

Figure 30.28: Endoscopic retrograde cholangiopancreatography

CHOLANGITIS

NOTE: *Cholangitis is one of three main complications of CBD stone, other two being obstructive jaundice and pancreatitis (PGI 01).*

Bacterial infection of biliary duct is almost always associated with biliary obstruction. *In the absence of obstruction* even heavy bacterial contamination fail to produce symptom or pathological change, because *bile duct is kept sterile, by continuous bile flow and immunoglobulins present in bile.*

Gall stones are most common cause of obstruction in common bile duct and subsequent cholangitis (AIIMS 94, MANY PGME). Other causes are benign and malignant CBD stricture, neoplasm, parasites. The most common organism cultured from bile in patients with cholangitis include, *E.coli* (M/C), *klebsiella*, and *bacteroids.* (AI 06)

Clinical feature

The symptoms of cholangitis (some times referred as **(Charcot's triad)** are (Mnemonic-**BJP**)

- **B**iliary colic (PGI 01, 03)
- **J**aundice (AI 95, 96)
- **P**yrexia (Fever with chills) (AIMS 98, UP 01)

This illness may progress rapidly with septicemia and dis-orientation, known as **Reynold's pentad** (PGME), which include:

- Biliary colic
- Jaundice
- Pyrexia (Fever with chills)
- Septicemia (septic shock)
- Disorientation (mental state changes)

This more serious problem, is also known as ***suppurative cholangitis.***

Treatment

- Most patients of cholangitis can be controlled with broad spectrum antibiotics.
- For patients with severe cholangitis or unremitting cholangitis despite antibiotic therapy, bile duct must be promptly decompressed.
- Urgent intervention (eg; endoscopic sphincterotomy, percutaneous transhepatic drainage or operative decompression) is required in only 10% patients with acute cholangitis.
- The remaining 90% are eventually treated by elective surgery or endoscopic sphicterotomy following antibiotic therapy.

****

OBSTRUCTIVE JAUNDICE

Jaundice is a frequent manifestation of biliary tract disorder, and the evaluation and management of the jaundiced patient are more common problem faced by surgeon.

Normal serum bilirubin level range from 0.5 to 1.3 mg/dl; when level exceeds 2.0 mg/dl, the bilirubin starts staining tissue and is clinically apparent as jaundice.

Bilirubin level rises very high (upto 30 mg/dL) but if it further rises, cause is renal failure or ↑ed hemolysis.

KEY BOX 30.7

JAUNDICE

Medical Jaundice

d/t- increased production of bilirubin, decreased hepato-cyte transport or conjugation, decreased excretion of bilirubin in bile, also called as cholestatic jaundice

Etiology (common cause)

- Viral hepatitis
- Alcoholic hepatitis
- Cirrhosis
- Drug induced cholestasis
- Hemolytic anemia

NOTE: when we use term cholestasis - it means stasis (stagnation or decreased rate) of bile flow.

d/t = due to

Surgical Jaundice

d/t decreased delivery of bilirubin into intestine due to obstruction in bile duct, also called as obstructive jaundice

Etiology

(a) causes in lumen of bile duct

- **Stone in common bile duct (M/C cause-UP 00)** *(NEET)*
- Cholangitis
- Parasite
- Hydatid cyst of biliary tree

(b) Cause in the wall

- Choledochal cyst
- Periampullary carcinoma
- CHOLANGIOCARCINOMA
- Spasm or stenosis of sphincter of oddi
- **Klatskin's tumour,** tumour at the confluence of right and left hepatic duct
- Biliary stricture

(c) Cause from out side the CBD

- Pressure on CBD by carcinoma head pancreas
- Pressure due to enlarged lymph node at portahepatis

The differential diagnosis of jaundice parallel the metabolism of bilirubin. The disorders resulting in jaundice can be divided into:-

(a) Medical Jaundice

Where there is

(i) Increased production of bilirubin,

(ii) Decreased hepatocyte transport or conjugation or

(iii) Impaired excretion of bilirubin in bile.

(b) Surgical Jaundice

This occurs when there is *impaired (decreased) delivery of bilirubin into the intestine (duodenum) through common bile duct due to obstruction in bile duct.*

- Complete obstruction in CBD prevents entry of bilirubin into intestine, *producing pale clay coloured or chalky stool.* (MANY PGME)
- Absence of bilirubin in the gut also results in *absence of fecal and urinary urobilinogen.* (MANY PGME)
- Regurgitation of conjugated bilirubin into plasma produces conjugated hyperbilirubinemia, which in turn leads to excretion of a dark brown urine containing bilirubin.
- Fat soluble vitamins are deficient.
- Please see key box 30.7 (must go through it)

COURVOISIER'S LAW

In a patient with obstructive Jaundice, if the gall bladder is palpable, it is likely due to malignancy causing obstruction of CBD and not due to stone in CBD.

Friends this is one, you will forget many times; so kindly understand the reason behind it.

Explanation

The stone in CBD is mostly a drop stone from gall bladder. Recurrent episodes of cholecystitis due to gall stone make gall bladder fibrotic and small- making it nonpalpable [KAR 94]

While a periampullary carcinoma, or cholangiocarci-noma or Ca head of pancreas blocks the passage of bile and cause pooling of bile in gall bladder causing it's distension and making it clinically palpable. See fig. 30-29 carefully. [Remember with:- *in gall stone disease: gall bladder is not palpable]*

Exception of courvoisier's law

1. Double impaction of stone ie; one in the cystic duct and other in common bile duct.
2. Oriental cholangiohepatitis (discussed later in chapter)
3. A pancreatic calculus obstructing the ampulla of vater.
4. Mucocele of gall bladder due to impaction of stone in cystic duct of gall bladder.

Friends we were discussing CBD stone and it's complication, ie; cholangitis, obstructive jaundice, one other clinical presentation of CBD stone is pancreatitis; most commonly acute pancreatitis, we will discuss in next chapter, The pancreas

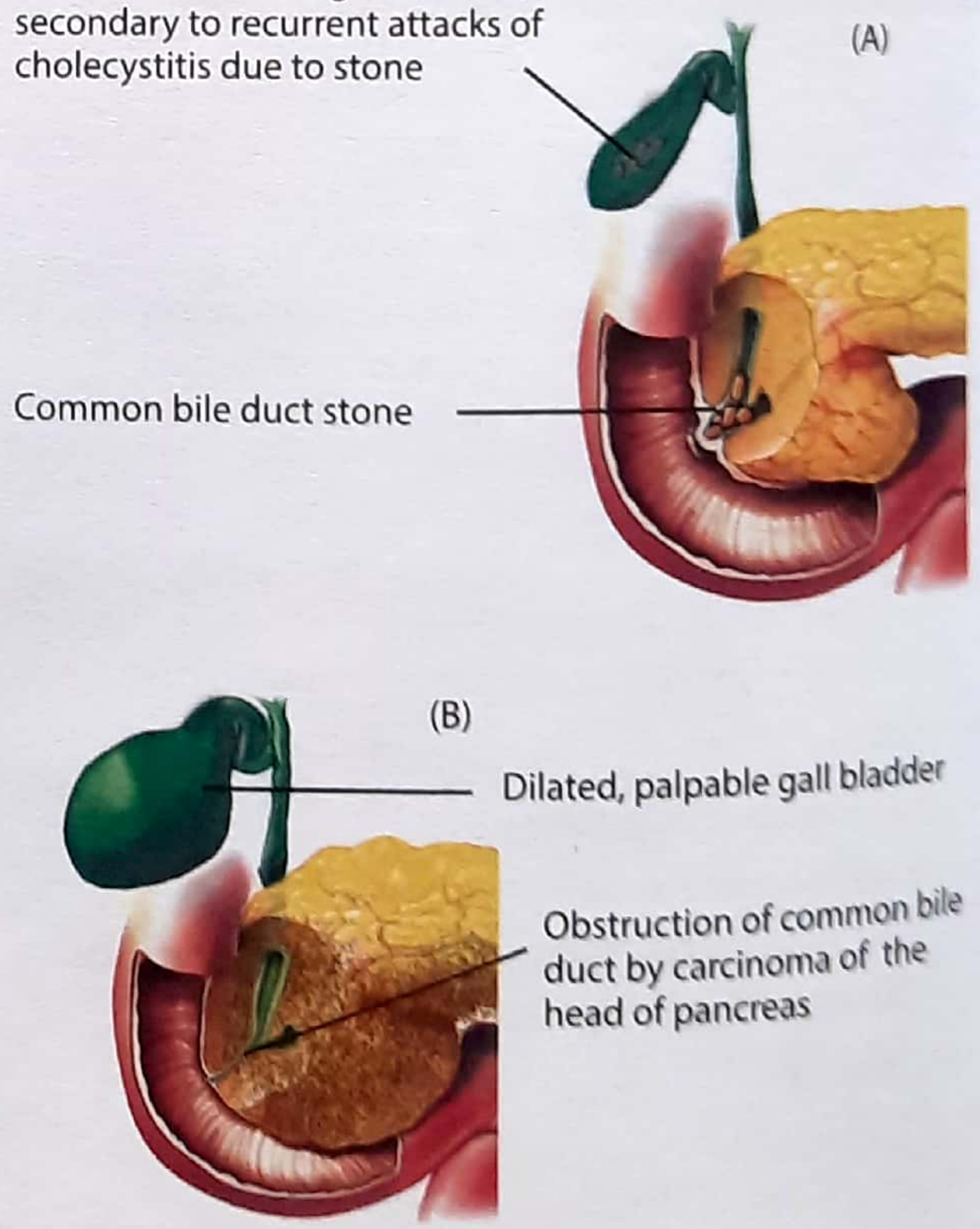

Figure 30.29: Courvoisier's law:- (A) When obstructive jaundice is caused by a calculus in common bile duct, there is no enlargement of gall bladder (B) When obstructive jaundice is caused by malignancy of CBD or Pancreatic head, the gall bladder is enlarged and may be clinically palpable.

Now I will discuss three other benign conditions related to bile duct -(i) Sclerosing cholangitis, (ii) Bile duct stricture, (Hi) Parasitic infestation of biliary tract.

****

SCLEROSING CHOLANGITIS

Primary sclerosing cholangitis is a cholestatic liver disease characterized *by fibrotic strictures* involving the intrahepatic and extrahepatic biliary tree in the absence of any known cause.

In cases, where diffused biliary strictures are caused by some known cause, such as acute cholangitis, common bile duct stones, operative trauma, or other toxic agent, the term ***secondary sclerosing cholangitis*** is used.

The clinical course of patients with sclerosing cholangitis is highly variable, with *some patients remaining asymptomatic for years, where as in other, the destructive biliary tract changes may progress rapidly to secondary biliary cirrhosis and chronic liver failure.* [PGI 05]

Recent studies suggest that genetic and immunologic factors are important in the pathogenesis of this disorder. *Primary sclerosing cholangitis is more common in certain HLA haplotype such as* HLA B-8, HLA-DR3 and HLA DQ2. (MANY PGME)

Associated disease

Several disease have been associated with primary sclerosing cholangitis, such as:-

- Ulcerative colitis (inflammatory bowel disease)
- Riedel's thyroiditis
- Retroperitoneal fibrosis
- Eventually 10-20% patients with sclerosing cholangitis will develop cholangiocarcinoma.

Clinical feature

- The mean age of presentation is 30-45 years and men are affected twice as commonly as women.
- Usual presentation is intermittent jaundice, fatigue, weight loss, pruritus and abdominal pain.
- *Investigation of choice for this condition is MRCP.* (NEET) *Please help your self figure 30.30.*

KEY BOX 30.8

White Bile

Some times above the impaction of stone in CBD, the bile looks white (it is not actually white, it is of straw colour), this is known as white bile. The **"white bile"** or surgical bile is nothing but mucus secreted from the glands lining the bile duct. (like mucocele of gallbladder)

Hydrohepotosis is a -rare condition where gross dilatatin of intra hepatic biliary canaliculi occurs, which are filled with white bile.

NOTE: *Normal colour of bile is greenish*

Treatment

- There is no known effective medical therapy for primary sclerosing cholangitis. Corticosteroids, immunosuppressant, ursodeoxycholic acid and antibiotics have been disappointing.
- Biliary strictures can be stented and dilated, either endoscopically or percutaneously.
- Surgical management with resection of extrahepatic biliary tree and anastomosis between hepatic duct and jejunum (hepatico-jejunostomy) has produced reasonable results.

Figure 30.30: Sclerosing cholangitis in a patient with ulcerative colitis, visualised by endoscopic retrograde cholangiopancreatography.

- In patients of sclerosing cholangitis with advanced liver disease; liver transplantation is the only option.

****

BILE DUCT STRICTURE (PGI 08)

Benign bile duct stricture can have numerous cause. However the **most common cause is operative injury,** (NEET) most commonly during cholecystectomy.

NOTE: *the incidence of CBD injury is more with laparoscopic cholecystectomy than open cholecystectomy.* (PGME)

Causes of Bile duct stricture are:

- After cholecystectomy (80%) M/C cause (AIIMS 94)
- After choledochotomy (ie; CBD exploration) 10%
- Fibrosis due to chronic pancreatitis
- Acute cholangitis
- Sclerosing cholangitis

Bile duct stricture, that go unrecognized or improperly managed may lead to recurrent cholangitis (discussed earlier), secondary biliary cirrhosis, which may lead into portal hypertension.

Only 15% of injuries of the bile duct are recognized at the time of operation. In rest 85% cases, the injury declares itself postoperatively by causing biliary peritonitis or obstructive jaundice.

Classification of bile duct injury

Based on the site of bile duct injury in relation to the confluence of hepatic ducts, **Bismuth classified** bile duct strictures into 5 categories.

Bismuth Classification of bile duct injury

Type 1: Low common hepatic duct stricture - hepatic duct stump >2 cm

Type 2: Mid common hepatic duct stricture - hepatic duct stump <2 cm

Type 3: Hilar stricture with no residual common hepatic duct hilar confluence intact.

STRASBERG CLASSIFICATION OF BILE DUCT INJURY (INICET NOV. 20)

Strasberg classification (figure 30.31)	
Type A	**Cystic duct leaks or leaks from small ducts in the liver bed** Bile leak from a minor duct still in continuity with the CBD. In most cases the leaks occur from the cystic duct or from the liver bed. The two injuries are combined because their presentation and management are almost identical.
Type B	**Injury to sectoral duct (commonly aberrant right hepatic duct) with consequent obstruction** In about 2% of patients the cystic duct enters the right hepatic duct rather than the CBD-CHD junction. The right duct then joins the main ductal system. Such an aberrant duct has a similar appearance to a cystic duct at the point where it joins the main duct and is in danger of being mistaken for the cystic duct or cystic artery and divided.
Type C	**Injury to sectoral duct with consequent bile leak** Transection without ligation of the aberrant right hepatic ducts with drainage of bile into the peritoneal cavity.
Type D	**Lateral injuries to major bile ducts**
Type E	**Circumferential injury/ Stricture of Major bile ducts (Subdivided as per Bismuth's classification into E1 to E5).** These injuries involve circumferential injury of one or more main bile ducts as described by Bismuth. Type E injuries cause 'separation' of hepatic parenchyma from the lower ducts and duodenum. This separation is usually the result of resection or ablation with cautery. This is the most serious type of bile duct injury and is associated with the greatest morbidity and mortality

Bismuth's classification (Type E of Strasberg classification)	
Type1 (E1)	Low CHD stricture, with a length of the common hepatic duct stump of >2 cm
Type2 (E2)	Proximal CHD stricture-hepatic duct stump <2 cm
Type3 (E3)	Hilar stricture, no residual CHD, but the hepatic ductal confluence is preserved
Type4 (E4)	Hilar stricture, with involvement of confluence and loss of communication between right and left hepatic duct
Type5 (E5)	Involvement of aberrant right sectoral hepatic duct with concomitant stricture of the CHD

Type 4: Destruction of hilar confluence - right and left hepatic ducts separated

Type 5: Involvement of the aberrant right sectorial duct alone or along with the common hepatic duct.

Management

Liver function test will usually show evidence of cholestasis - that is: increased serum bilirubin, increased SGOT, SGPT (AST & ALT), increased Alkaline phosphatase.

An ultrasound or a CT scan will show dilated bile duct proximal to the stricture, as well as provide some information about the level of stricture.

In patients with intrahepatic ductal dilatation, a percutaneous transhepatic cholangiogram (PTC) will outline the proximal biliary tree, locate the stricture and allow decompression of the biliary tree with a transhepatic catheter (a plastic tube through liver).

An ERCP will help to visualize the strictures in *distal common bile duct,* and simultaneous dilatation and/or stent* placement, which gives good results in about 50% patients.

Choledocho-duodenostomy or Roux-en-Y choledocho Jejunostomy may be the operation of choice for stricture in the distal most part of the common bile duct, (Note:- if the main road is blocked then go through other possible route)

If bilirubin level comes down very slowly possible reason may be anastomatic stricture.

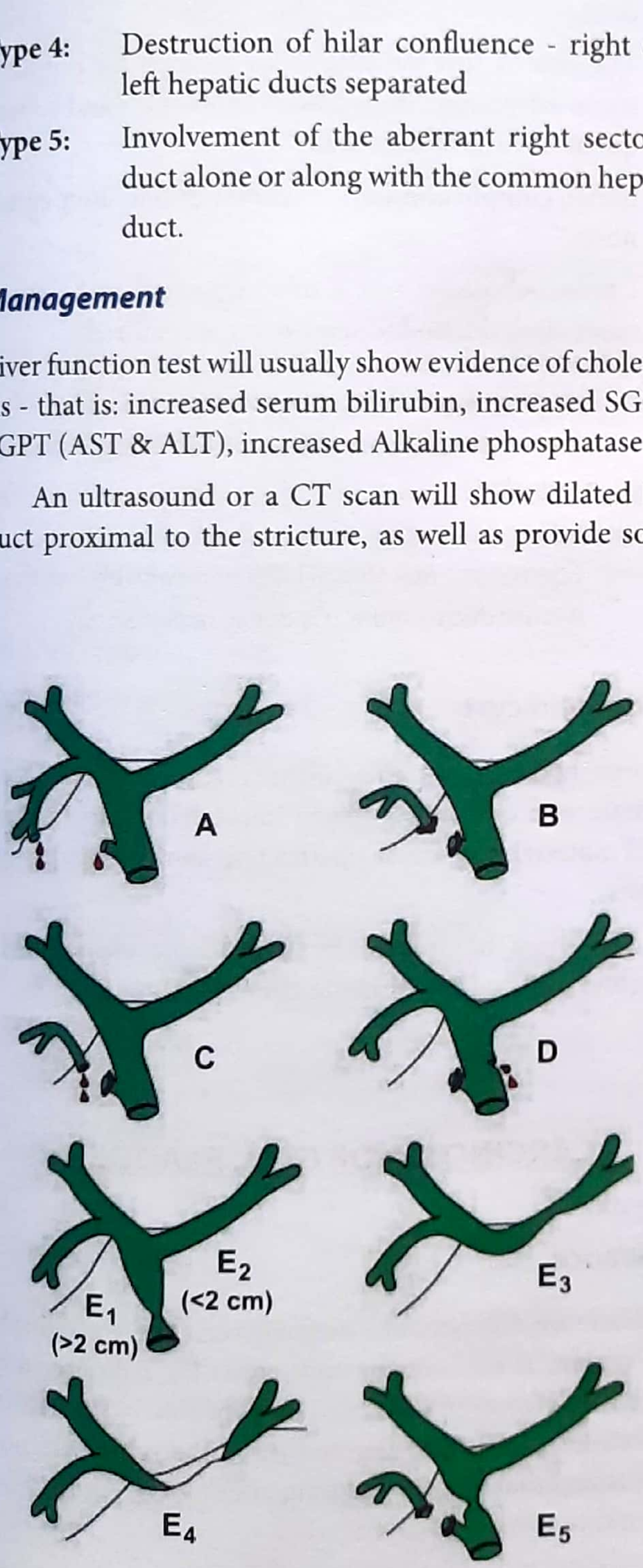

Figure 30.31: Strasberg classification

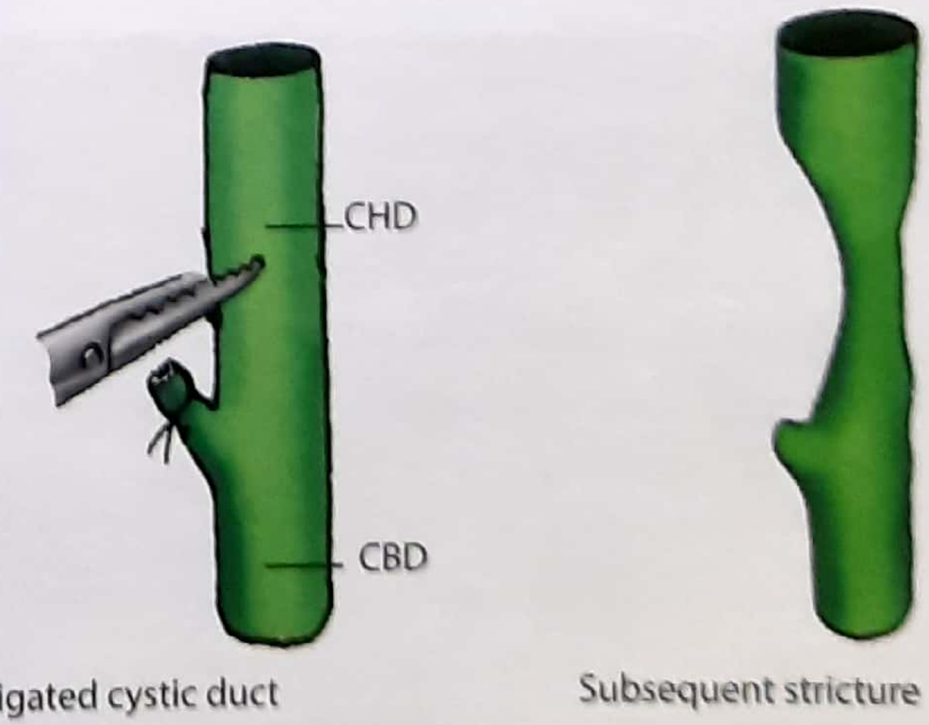

Accidental injury of CHD during cutting Cystic duct in Cholecystectomy

Figure 30.32: Showing mechanism of CBD injury during Cholecystectomy and subsequent stricture

(when we use term "stent" in surgery:- it means - a device which is introduced in a tubular structure, to keep two wall of the tubular structure apart)

****

Alagilla syndrome - Also known as Alagille & Watson syndrome

- It is syndromic bile duct paucity + arteriohepatic dysplasia + TOF.
- It is an autosomal dominant condition.
- It is caused by mutation in JAG1 & NOTCH-2 gene

Clinical feature

- Cholestasis, Jaundice, Bile duct Paucity
- TOF, murmur, peripheral pulmonary stenosis.
- Posterior embryotoxon, Axenfeld's anomaly.
- Renal tubular acidosis. Structurally renal system is normal.
- Butterfly shaped vertebrae, short stature.
- Deep set eyes
- Straight nose.
- Prominent forehead & pointed chin.

****

PARASITIC INFESTATION OF THE BILE DUCT

1. Biliary ascariasis

- The adult round worm infests the small intestine. It can enter the biliary tree through sphincter of oddi into common bile duct and cause biliary pain.
- The subsequent movement of the worm and toxin produced by it causes biliary spasm and pain.
- The round worm in the bile duct causes destruction of ductal mucosa followed by cholangitis, fibrosis and stricture formation.
- E.coli is often found in the bile of these patients.
- Complication include suppurative cholangitis, liver abscesses, empyema of gall bladder.
- In uncomplicated case, antispasmodics can be given to relax the sphincter of oddi and the worm may return to small intestine, to be dealt with anthelminthic drugs.
- Some times operation may become necessary to remove the worm.
- Worm can be extracted via ampulla of vater by ERCP.

2. Clonorchiasis

(Asiatic cholagio hepatitis, oriental cholangio-hepatitis)

- The liver fluke is endemic in oriental countries (East Asian countries). The liver fluke (Clonorchis sinensis) lives in biliary ducts including the intrahepatic duct.
- The ova of this parasite form a nidus for pigment stone formation. Stone causes cholangitis and subsequent fibrosis of duct wall.
- Other complication are cirrhosis & bile duct carcinoma.
- Choledochotomy and T tube drainage and in some cases choledochoduodenostomy is required.

NOTE: This condition is an exception for courvoisier's law - that is even in the presence of stone in bile duct gall bladder is palpable.

RECAP: *Courvoisier's law* ? If gall bladder is palpably enlarged, it is not due to stone, it is due to malignancy.

3. Hydatid cyst

A large hydatid cyst may obstruct the hepatic ducts. Sometimes a cyst may rupture into biliary tree and hydatid material may cause obstructive jaundice and cholangitis.

This may be treated by endoscopic clearance of daughter cysts or by operative choledochotomy.

****

CARCINOMA OF GALL BLADDER

Incidence

This is a rare disease, but extremely variable by geographical region. It account for approximately 2-3 percent of all cancer. However, in certain parts of North-East (Bihar and eastern UP), it is claimed to be the most common abdominal malignancy forming about 28% of gastro intestinal cancer.

Figure 30.33: Carcinoma of gall bladder

Etiology *(AIIMS 04, AIIMS 98, PGI 05, PGI 02)*

- **Gall stone** : Approximately 90% of patients with carcinoma gall bladder have gall stone. *(PGI 85)*
- Size of the gall stone has a direct relationship with development of carcinoma, larger the stone-larger the chance of development of carcinoma.
- Risk of malignant degeneration correlates with the length of time, for which gallstone has been present.
- Porcelain (calcified) gall bladder* (see below)
- Choledochal cyst
- **Typhoid carriers** *(NEET)*
- Sclerosing cholangitis
- Cholecysto-enteric fistula
- **Gall bladder polyp** *(NEET)*
- **Toxic chemicals like nitrosamines** *(NEET)*
- Adulterated mustard oil.

* **PORCELAIN GALL BLADDER:** It is calcification of the wall of gall bladder. It is an important appearance on X-ray, because it is a *premalignant condition* and is an indication for *prophylactic cholecystectomy.* *(PGME)*

Pathology

About 90% primary tumour of the gall bladder are adeno carcinoma *(AIIMS 95)*, that appear histologically to be scirrhous (60%), papillary (25%) or mucoid (15%).

Many times, carcinoma are difficult to be differentiated grossly from chronic cholecystitis. Dissemination of the tumour occurs early by direct invasion to liver and hilar structure and by metastases to the hilar lymph node, liver and lung.

Clinical feature

- The tumour is twice as common in women as in men.
- Usually detected in 6th decade of life.
- The features are similar to chronic cholecystitis, but more persistent. In advanced disease, there is weight loss, a palpable mass or evidence of metastases (ascites). The prognosis depends on the stage.
- In late cases an irregular hard lump is palpable in right hypochondrium.

Staging

Nevin staging (accounting to depth of invasion)

Stage	Depth of invasion
I	Mucosa
II	Muscularis mucosa
III	Serosa
IV	Hepatic invasion
V	Adjacent organs/ distant metastasis

Investigation

- USG and CT scan may demonstrate the extent of disease.
- The level of serum *CA19-9 is elevated in 80% of patient.

Figure 30.34: Computed tomography scan showing gallbladder cancer with invasion into the duodenum and liver parenchyma

- Histological diagnosis is confirmed by percutaneous biopsy or laparoscopic biopsy.
- Note: CA stands for Carbohydrate Antigen.

Treatment

Resection of gallbladder cancer remains the only potential for cure. Patients with gallbladder cancer can be divided into four specific subgroups of presentation:

I. Patients with a gallbladder polyp.
II. Patients with an incidental finding of gallbladder cancer.
III. At the time of or after cholecystectomy.
IV. Patients suspected of having gallbladder cancer preoperatively, and patients with advanced disease at presentation.

I. Gallbladder polyp:

The only polypoid lesions that have malignant potential and are associated with a significant rate of harboring malignancy are adenomatous polyps. The most consistent predictors of malignancy in gallbladder polyps are single polyp, size greater than 1 cm, and age older than 50 years. Cholecystectomy is generally recommended for polyps larger than 1 cm.

II. Gall bladder cancer after cholecystectomy

With the finding of carcinoma on histopathology examination after cholecystectomy, subsequent treatment depends on depth of penetration of the gallbladder wall and surgical margins. With T1a lesions, in which the carcinoma penetrates the lamina propria but does not invade the muscle layer, cholecystectomy suffices for therapy.

With T1b lesions and perineural, lymphatic, or vascular invasion, the likelihood of nodal disease increases significantly. Therefore, extended cholecystectomy is generally recommended for all patients who are medically fit with T1b or greater level of invasion. The extended cholecystectomy is directed at obtaining an R0 resection of the disease, including the draining lymph node basins. Therefore, removal of the hepatoduodenal, gastrohepatic, and retroduodenal lymph nodes should be included. Resection of the cystic duct margin to uninvolved mucosa may require resection of the CBD with Roux-en-Y reconstruction.

In patients with T2 lesions, in which the cancer extends past the muscularis but not beyond the serosa, a similar approach with radical cholecystectomy is indicated.

III. Patients suspected of having gallbladder cancer preoperatively.

Patients in whom preoperative evaluation suggests possibly resectable gallbladder cancer without metastatic disease should be offered an attempt at resection.

Radical resection in the setting of T3 and T4 lesions includes at least segments IVB and V but more often requires a central hepatectomy, including all of segments IV, V, and VIII

IV. Patients with advanced disease at presentation.

Many patients with gallbladder cancer will present with advanced disease, and therefore, the goal of therapy is palliation of symptoms. Jaundice can be managed by endoscopic biliary stenting. Pain is generally treated with oral narcotics.

Percutaneous neurolysis of the celiac ganglion can help. Intestinal obstruction is usually due to gastric outlet obstruction from local extension of tumor and is generally managed by an endoscopic duodenal wall stent.

Treatment

1. For tumour confined to mucosa and submucosal layer → ***Simple cholecystectomy***.
2. For tumours invading muscular layer, but not extension beyond serosa - ***Extended cholecystectomy,*** *which* include wedge excision of liver near the gall bladder fossa, with regional lymph node dissection of the bile duct and pancreaticoduodenal area. (AIIMS 09)
3. Lesion that has invaded beyond serosa and have invaded bile duct - should be resected, as much as possible. For nonoperable tumours; some form of pal--liative procedure is done.

Adjuvant Therapy

Gemcitabine-based regimens, often combined with a platinum agent, are typically used for treating gallbladder cancer.

Palliative procedure

In case of unresectable tumour, palliative procedure are done; like endoscopic or percutaneously placed biliary stent to relieve obstructive jaundice. Survival with unresectable tumor is less than 6 months.

KEY BOX 30.9

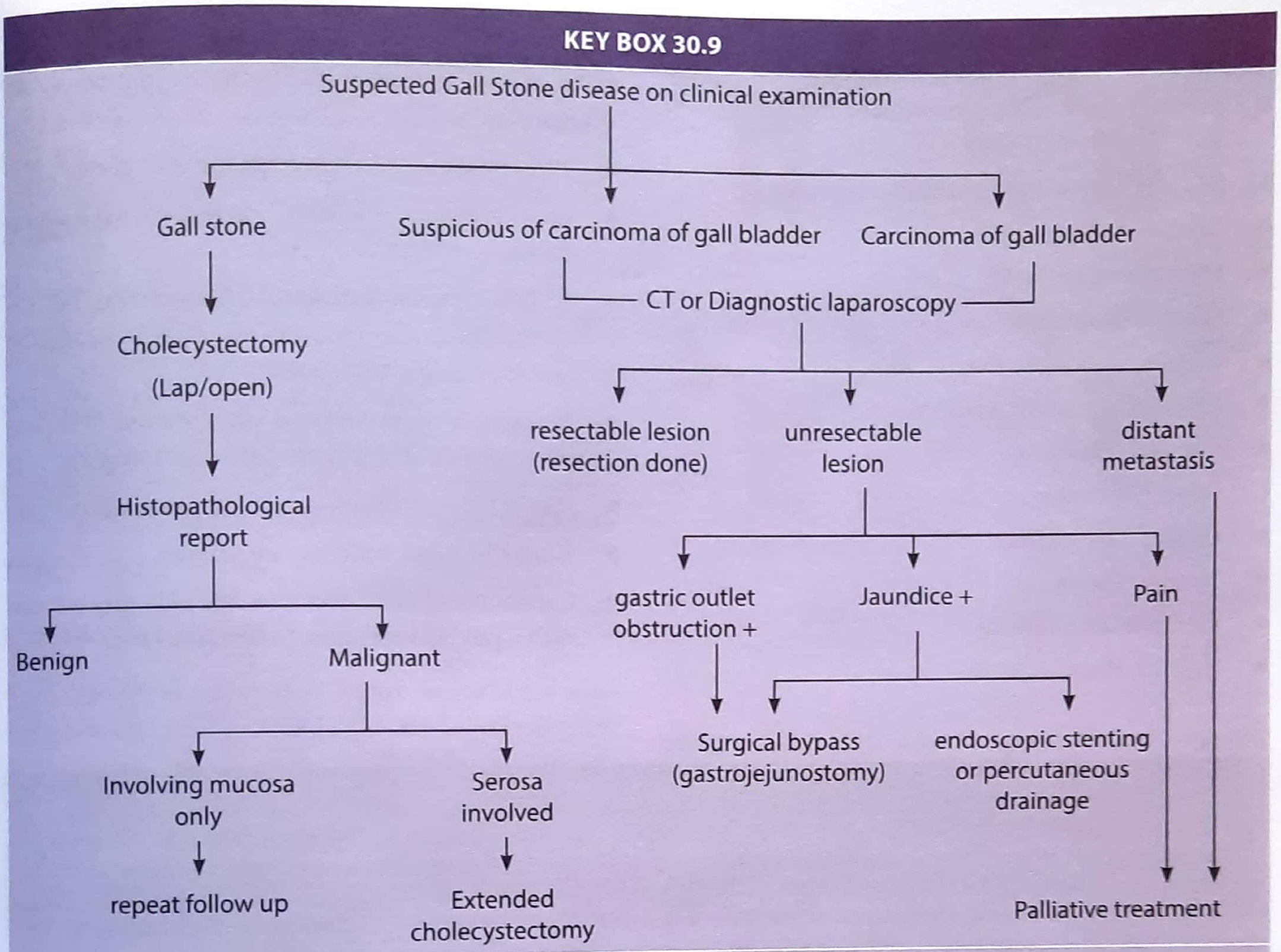

NOTE: Extended cholecystectomy = wedge resection of liver, near gall bladder bed, Lymph node dissection at porta hepatis, hepatoduodenal ligament, peripancreatic lymph node

Prognosis is very poor with 5 year survival being 5% only. The role of adjuvant chemotherapy and radiotherapy is unproven.

****

MALIGNANT TUMOURS OF THE BILE DUCT [CHOLANGIOCARCINOMA]

The carcinoma of the bile duct is an uncommon malignancy, however is much more common in UP and Bihar. Incidence of intrahepatic and extrahepatic cholangiocarcinoma is shown in figure 30.17. Perihilar is most common. *(AIIMS 08, 11)*

Etiology

The etiology of the bile duct carcinoma is vague.

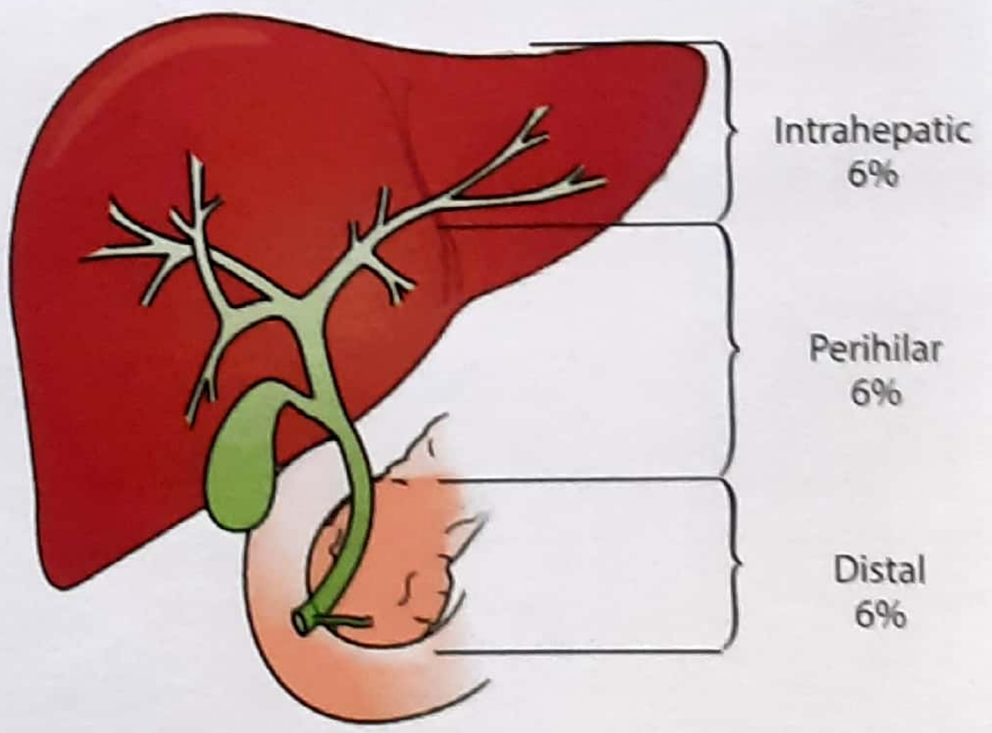

Figure 30.35: Incidence of Cholangiocarcinoma

- Unlike gall bladder cancer, it is not associated with biliary stone *(AI 97, AIIMS 09)*.
- Risk factor for cholangiocarcinoma: *(AI 96, 03, AIIMS 97)* are:- ***[Mnemonic 7 C'sJ]***
- Primary sclerosing Cholangitis
- Choledochal cyst
- **Ulcerative Colitis** *(NEET)*
- Clonorchis sinensis
- Chronic typhoid carrier
- Choledocho-enteric anastomosis
- Caroli's disease

Other risk factors -

- Dietary nitrosamines
- Toxins - Thorotrast
- Polycystic liver disease
- NAFLD, Hepatolithiasis

Clinical Feature

- Both men and women are affected with equal frequency.
- Tumour appears at an average age of 60 years.
- Most malignant bile duct tumours are adenocarcinoma.
- At presentation, metastasis is uncommon, but tumours has often grown into portal vein and hepatic artery making it inoperable.
- **Jaundice is most common presentation** *(NEET)* and often the bilirubin level is more than 10mg/dl.
- Pain in the epigastrium is mild; but pruritus is marked.
- Weight loss and weakness are marked.
- Carcinoma of distal common bile duct may present with a gall bladder lump, *(courvoisier's law)*

KEYBOX 30.10

Presentation and risk factors: Hepatocellular carcinoma, cholangiocarcinoma, carcinoma of gall bladder

	Hepatocellular carinoma	Cholangiocarcinoma	Carcinoma of gallbladder
Sex	M>F-3: 1 in HBV endemic areas; 9:1 elsewhere	F=M1:1	F>M2:1
Racial/geographic distribution	High- Asia, Africa Low- Europe, USA	High- Far East Low- Europe, USA	High in native Americans and in South America (Mexico); relatively low in Africa, Asia (UP &Bihar)
Age	30-50 years in HBV-endemic areas; 60+ elsewhere	60+	50+
Medical history	Hepatitis B and C infection: alcoholism, hemochromatosis cirrhosis, Aflatoxin	Clonorchis sinensis infection, Thorotrast exposure.	Gallstones, chronic cholecystitis
Presentation	Weight loss, anorexia, tender enlarged hepatomegaly, fever abdominal distension, ascites peritoneal hemorrhage	Weight loss, anorexia: tender hepatomegaly,	Weight loss, anorexia, gallbladder enlargement, jaundice •
Alpha-fetoprotein (AFP)	Elevated in 90%	Normal	Normal
Other secretory products	Erythropoietin (polycythemia) insulin-like polypeptide (hypoglycemia), PTH	None	None
Associated disease		- Sclerosing cholangitis - Ulcerative colitis	

Investigation

Ultrasound and CT scan define the level of obstruction and the diagnosis is confirmed by endoscopy and biopsy (ERCP).

Treatment

Most patient are inoperable, because of presence of advanced disease at the time of diagnosis. Treatment is difficult, because most of lesion are high in the hilar region involving portal vein and hepatic artery.

Resection with hepatico-jejunostomy is treatment of choice; if possible. If tumours is not resectable endoscopic stent placement is the best treatment modalities available.

KLATSKIN'S TUMOUR

It is a tumour of biliary duct system found at the confluence (Joining point) of the right and left hepatic duct (UP 02). It is the most common site for bile duct tumour (Do not get confused with bile duct to common bile duct, common bile duct is formed by joining of common hepatic duct with cystic duct). Klatskin tumour, may be of

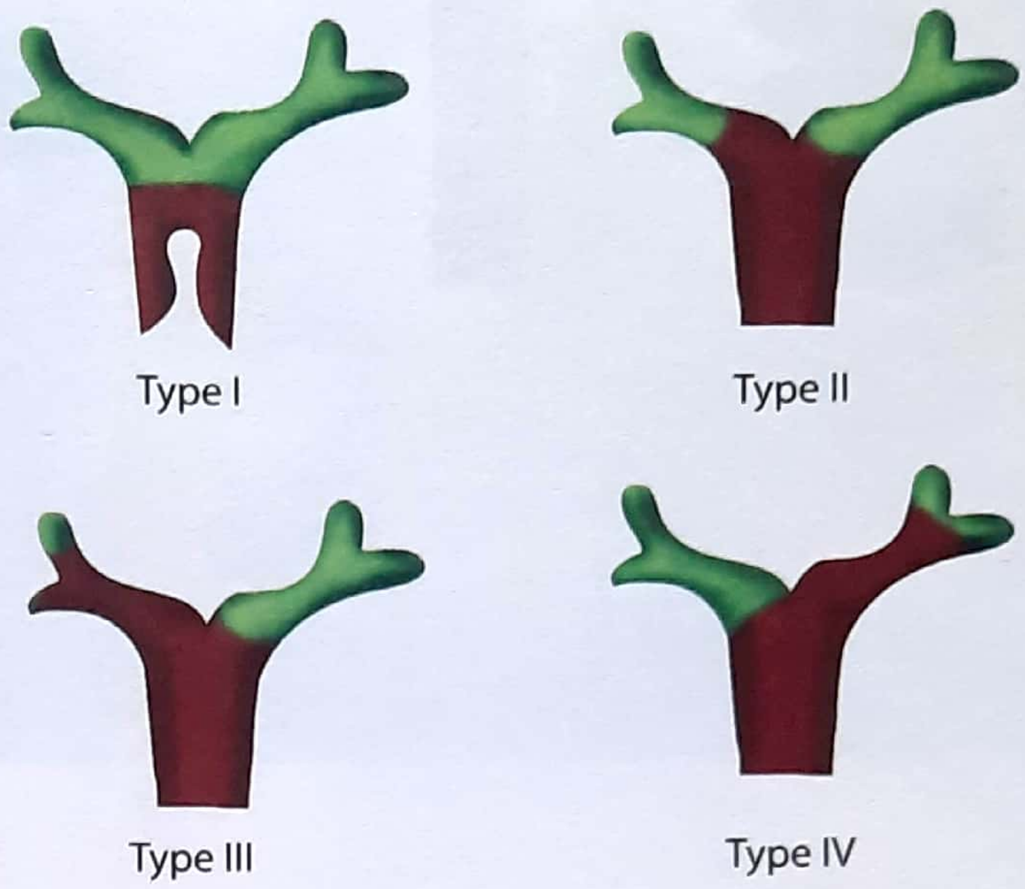

Figure 30.36: Klatskin tumour

three type, which is described diagrammatically in figure 30.35 & 30.36.

Before concluding this chpater please read key box 30.10, on page 526.

Sample Questions for Prof Examination

1. What are the varieties of gall stones?
2. Describe the various complications produced by them
   Describe briefly the treatment of acute cholecystitis.
3. Discuss etiopathology of gall stones. Discuss the diagnosis and management of a stone impacted in common bile duct
4. Discuss clinical presentation, diagnostic investigations/complications and treatment of gall bladder stones.
5. Enumerate cause of surgical jaundice. How will you manage a case with common bile duct stone.
6. Describe the clinical features, investigation and complication of cholelithiasis.
7. Discuss the differential diagnosis and management of a case of obstructive jaundice.
8. Discuss complications of a stone in gall bladder.

31 The Pancreas

Contents

- Embryology
- Congenital abnormalities
  - Pancreatic divisum
  - Annular pancreas
  - Ectopic pancreas
  - Pancreatic hypoplasia
- Surgical anatomy
- Injury to pancreas
- Acute pancreatitis
- Chronic pancreatitis
- Neoplasm of exocrine pancreas
- Endocrine tumours of pancreas

SURGICAL ANATOMY

- The Pancreas ('Pan' means all; and *kreas' means flesh) is a compound racemose* gland and is situated in retroperitoneum.
- The glands weighs approximately 80 grams. It is divided in head & neck which constitutes about 30% of gland, and body & tail which together constitute 70% of whole organ. The pancreas lies more or less transversely over the posterior abdominal wall, at the level of L1 and L2 vertebra. It is 15-20cm long about 3cm broad and about 2cm thick. Please see figure 31.2.
- The head lies with in the curve of the duodenum. It over lies the body of second lumbar vertebra and aorta. The body of the pancreas passes upwards and to the left, towards the hilum of spleen. The tail reaches the hilum of spleen and lies in lienorenal ligament.
- The uncinate process is that part of head of pancreas, which passes behind the superior mesenteric vein and is visible below the body of pancreas.

Racemose: Resembling a clustered bunch of grapes.

Embryology

The pancreas arises as dorsal and ventral out pouching of the duodenum. The dorsal pouch is rudiment of the pancreatic duct from which the neck, body and tail of the pancreas develops. The ventral pouch arises from the duodenum at a lower level and is rudiment of the bile passage, from which a pancreatic duct arise to form head and uncinate process (fig. 31.1). Due to differential growth of the wall of duodenum (second part) the dorsal duct is brought in front to form primitive dorsal duct. The lower ventral duct is carried posteriorly thus bringing the common bile duct behind the primitive duct and first part of duodenum.

After fusion of these components of pancreas, the main pancreatic duct is formed from the ventral duct and distal part of dorsal duct. The proximal part of the dorsal duct usually persist as accessory pancreatic duct

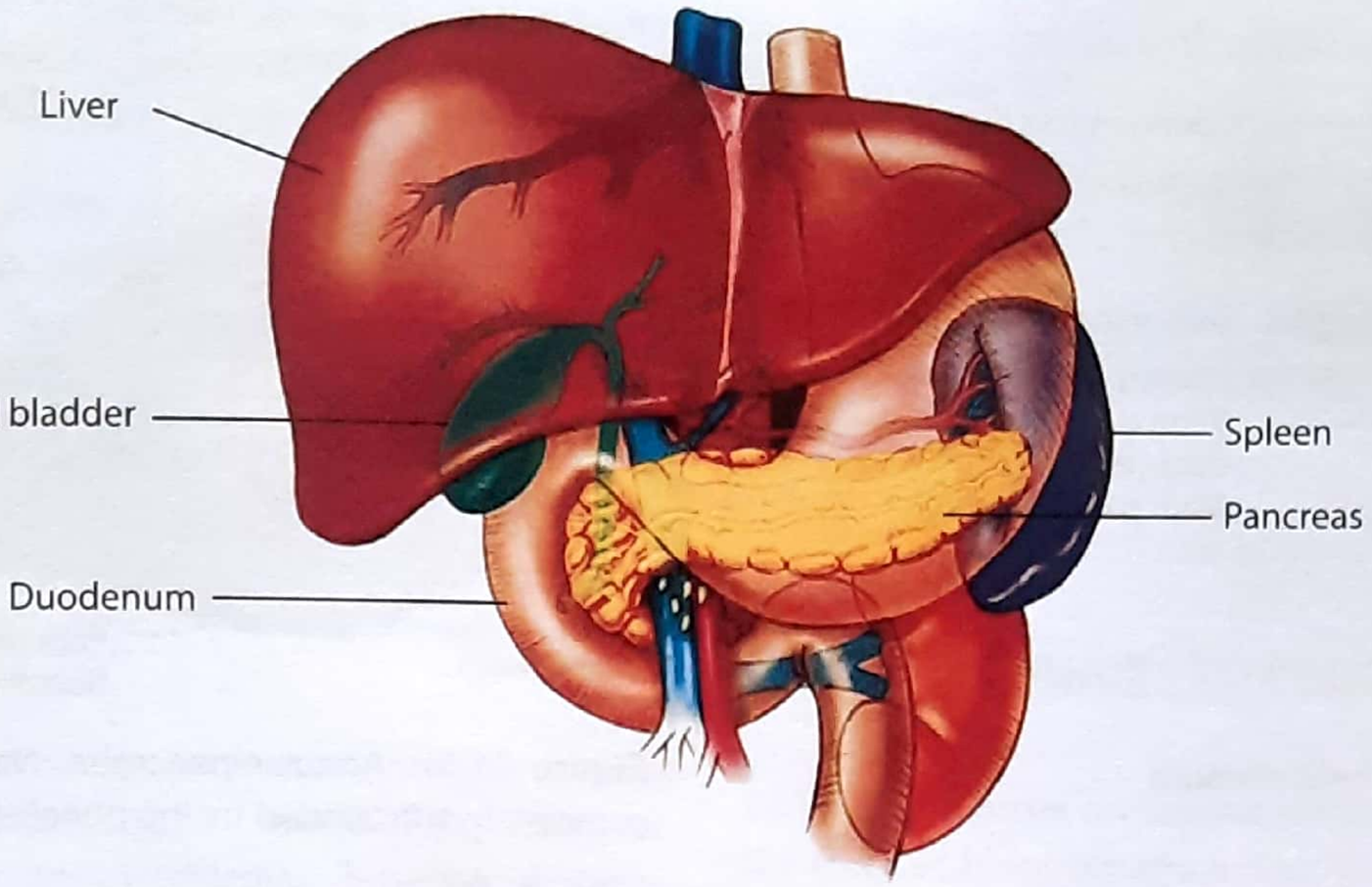

Figure 31.1: Relation of pancreas with gall bladder and Spleen

(*of santorini*), which opens into the duodenum about 2 cm proximal to main pancreatic duct (*duct of wirsung*). These two ducts usually communicate, but in about 10% of people the two duct persist without any communication. See figure 31-3.

SURGICAL PHYSIOLOGY

- After a meal, the pancreas secretes enzymes rich in an alkaline bicarbonate medium. The daily secretion is about 1-2 litres. *(PGME)*

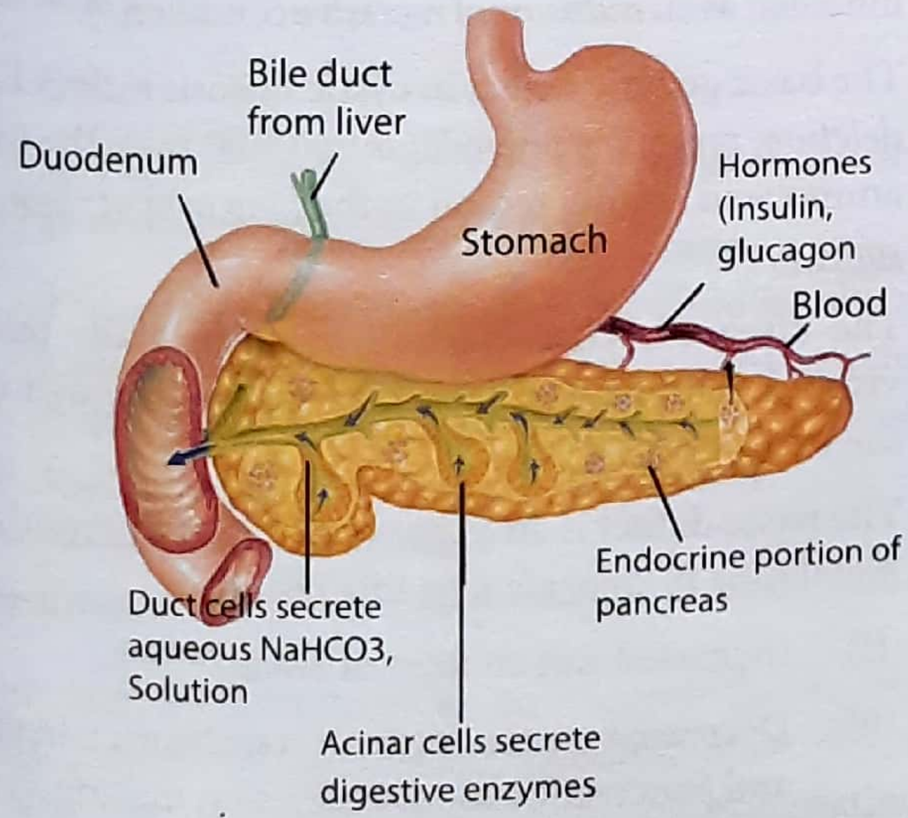

Figure 31.2: Figure showing Pancreatic duct & its secretions

- The hormone **secretin**, increases the rate of secretion of pancreatic juice and the bicarbonate content. Secretin is released from the duodenal mucosa by the stimulation of luminal acid.
- Cholecystokinin (CCK) also called as pancreozymin is released from duodenal mucosa in response to food. Cholecystokinin is responsible-for pancreatic secretions rich in enzyme. Figure 31.2 *(PGME)*
- Hormone which stimulates the secretion of Pancreatic enzymes are vasoactive intestinal polypeptide (VIP) and gastrin.
- Hormones; that which inhibit the secretions of the pancreas are somatostatins, glucagon and polypeptide.

****

CONGENIAL ANOMALIES OF THE PANCREAS

1. Pancreas divisum

In this condition there is failure of fusion of the dorsal and ventral ducts. The parts of pancreas developing from the dorsal and ventral buds open separately in the duodenum, giving rise to the condition of pancreas divisum. Fig 31.3.

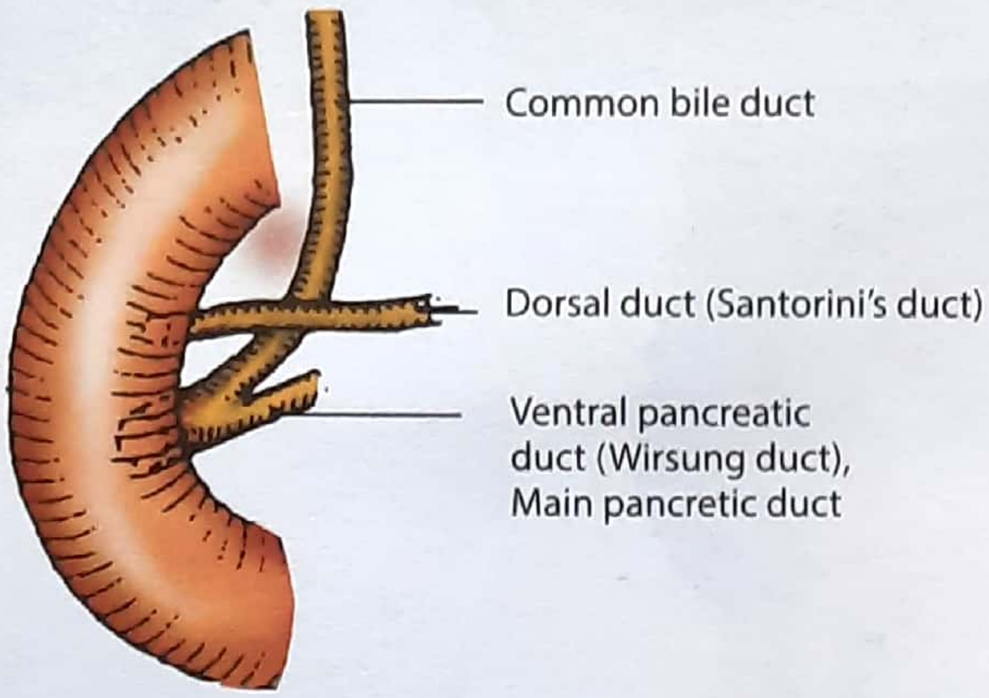

Figure 31.3: Pancreatic divisum

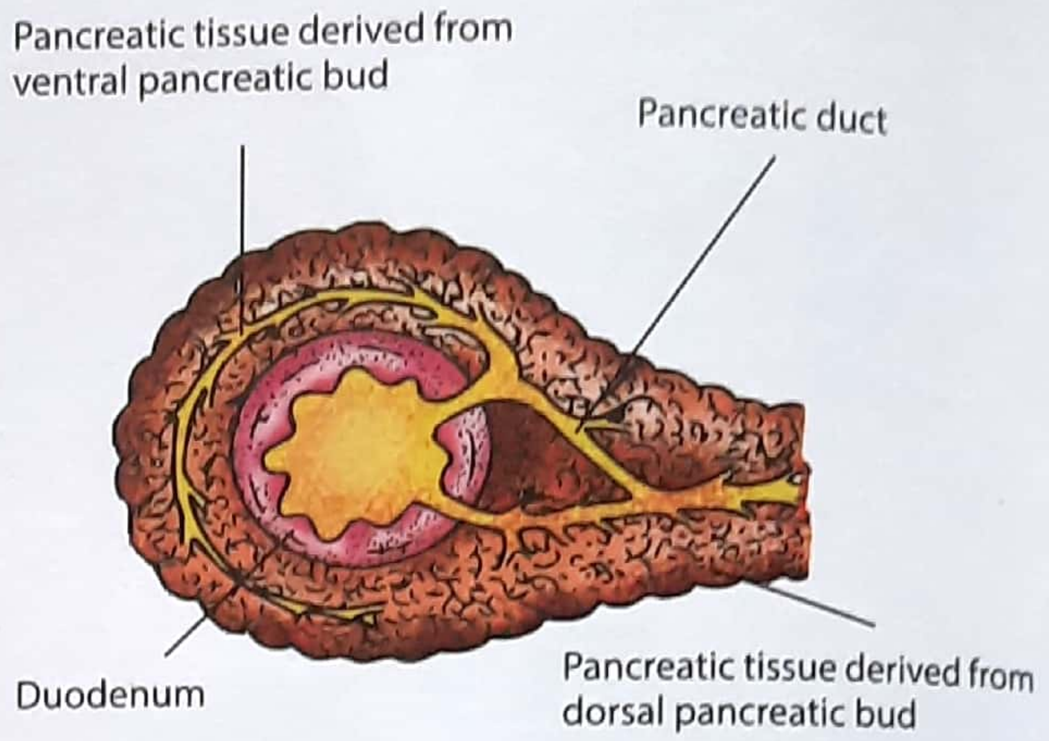

Figure 31.5: Annular pancreas. Note, the duodenum is completely surrounded by the pancreatic tissue

2. Annular Pancreas

During the developmental rotation of the duodenum, all the elements of the ventral bud do not migrate uniformly and encircle the second part of duodenum (see figure 31.4 and 31.5). This ring like encircling pancreatic tissue may give rise to duodenal obstruction in pediatric age group. It may also produce obstruction later in life due to fibrosis from chronic pancreatitis affecting this part. X-ray examination shows double bubble sign due to duodenal obstruction.

- The obstruction due to annular pancreas is treated surgically either by duodenoplasty or by duodeno-**duodenostomy or duodenojejunostomy**. *(NEET, AIIMS NOV 93, PGI JUNE 97, AL 95, PGI 02, AI 10)*

3. Accessory pancreatic tissue (Ectopic pancreas)

Accessory (ectopic) pancreatic tissue may be found in sub-mucous layer of the stomach (M/C), duodenum, small intestine, greater omentum, meckel's diverticulum. It may also be seen in gall bladder and splenic hilum. It is often felt as a nodule as an incidental finding during laparotomy. They are usually symptomless; but at times may give rise to intussusception.

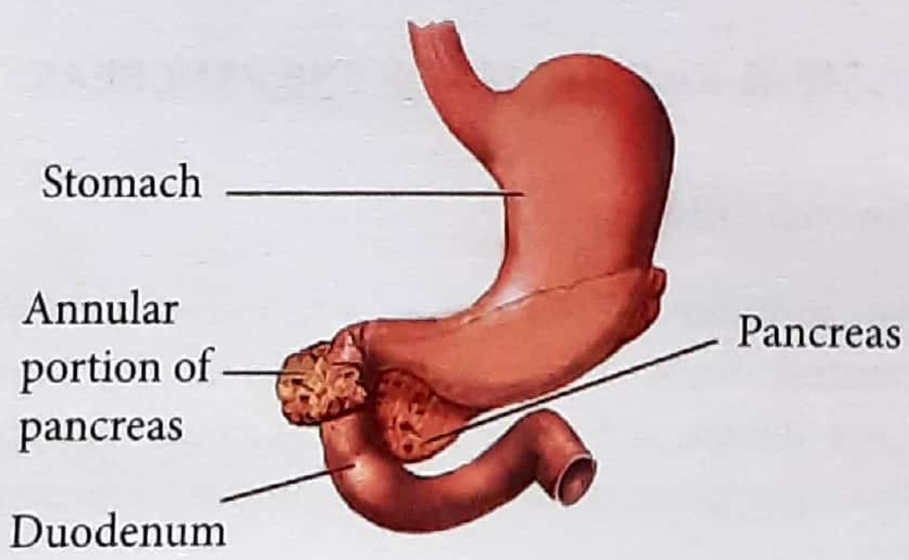

Figure 31.4: Annular pancreas

4. Pancreatic hypoplasia (Shwachman - diamond syndrome)

This is a rare congenital disorder in which the exocrine pancreatic tissue is considerably hypoplastic or may be even absent.

5. Cystic Fibrosis (Mucoviscidosis) *(IMP. PGMEE TOPIC)*

[*Split the word mucovisidosis = muco+viscid, = thick mucus*]

- Cystic fibrosis is a common congenital disease that is inherited as an ***autosomal recessive*** condition.*(MANY PGME)*
- The basic genetic defect in cystic fibrosis is *three base deletion, removing phenylalanine* (508) from the 1480 amino acid coding region in the *long arm of chromosome 7*. *(PGME)*
- The disease is characterized by **abnormally thick, viscous secretion of exocrine glands** through out the body. *(MANY PGME)*
- The **basic defect** is an *impermeability of epithelial cell membrane to chloride ions* this results in
  - (i) Increased salt content of sweat. *(PGME)*
  - (ii) Decreased water content of respiratory, intestinal and pancreatic exocrine secretion making it's secretion more thick and of increased viscosity.

- The pathological changes in cystic fibrosis are due to obstruction of ducts of exocrine glands by the viscid mucus (hence alternative name mucoviscidosis)
- The disease involves exocrine glands all over the body. Each is discussed below one by one:

1. Pancreatic abnormalities

Pancreatic abnormalities are present in 80% of patients, Pancreatic ducts are plugged with thick mucus; leading to chronic inflammation with atrophy of acini, *fibrosis and cystic dilatation of duct* (*hence called as Fibro+cystic disease of pancreas,* cystic fibrosis).

Lack of pancreatic lipase in the intestine causes indigestion of fat; leading to steatorrhea. Islets of Langerhans usually appear normal, however diabetes mellitus may occur in older patients.

2. Liver changes

Liver may become cirrhotic as a result of bile duct plugging, resulting in obstructive jaundice. Later signs of portal hypertension may appear.

3. Intestinal changes

At birth, increased amounts of viscid intestinal meconium may fill the lumen of terminal ileum and result in intestinal obstruction in neonatal period (meconium ileus).

4. Pulmonary changes

These are the most serious manifestation of cystic fibrosis. Bronchial mucus plugs; and leads to collapse of the lung, recurrent infections including lung abscess and ultimately fibrosis and bronchiectasis. Pulmonary complication are most common cause of death in a patient of cystic fibrosis. *(PGME)*

5. Other

- Changes in the vas deferens and seminal vesicle may cause infertility in male. *(IMP. POINT)*
- The mother often notice that the child is salty when kissed *(PGME)*. The diagnosis is established by determination of electrolyte levels in sweat. A sweat sodium level in excess of 60 meq/L is diagnostic.

Treatment

Basic aim of treatment is to control the secondary consequences of the disease. Malabsorption is treated by administration of pancreatic enzyme preparations. A suitable diet is low fat with added salt to replace the high losses in sweat.

Pulmonary function should be preserved with aggressive chest physiotherapy and antibiotics.

Twenty years ago survival beyond infancy was unusual; today most patient survive to adulthood due to better treatment modalities.

****

INJURIES TO PANCREAS

Pancreatic injuries are uncommon. External violence in the form of blunt trauma in the epigastrium may cause injury to head and neck of pancreas due to its crushing against the rigid vertebral column. These injuries are usually associated with injuries to other organs like spleen, stomach and duodenum and biliary tract. Kindly see key box 31.1 (next page). Need not to go in much details in MBBS.

Etiology

1. **Blunt trauma to abdomen**: Blunt trauma to abdomen may be due to road traffic accident, or fall from a height or homicidal blow on the epigastrium.
2. **Bullet injures**
3. **Sharp penetrating injury**
4. **Iatrogenic injuries:** The pancreas may be injured during operation on the stomach, duodenum or spleen. The tail of the pancreas may be clamped accidently; while removing the spleen (splenectomy).

Clinical feature

- There are no immediate pathognomonic signs of injury to pancreas. Often patient may give history of injury to the epigastric region. The patient may have severe tenderness, guarding and rigidity in the upper abdomen.
- The pancreas is seldom affected alone and injury to other adjacent organ is a rule.
- In a right sided injury, there are more chances of associated injury to the duodenum and bile duct. On the other hand; injuries to the left side of abdomen involve the stomach and spleen.

Investigation

1. Blood

Hematocrit level fall due to internal hemorrhage.

- **Serum amylase levels may starts rising only after 18-24 hours and are helpful in following the patient having blunt trauma.** *(NEET)*

2. Ultrasonography

It may show collection around the pancreas or lack of continuity. In later stages, it will show development of pseudocyst or an abscess.

3. CT scan

CT scan is now best non invasive test for pancreatic injury *(NEET, MANY PGME)*. Pancreatic contusions, laceration, fracture and hematomas can be easily diagnosed. In late stages, CT scan can show secondary effect like formation of a mass or a pseudocyst.

Treatment

In most cases, pancreatic injuries are diagnosed only during laparotomy. Minor injuries and those involving only small portion of parenchyma don't need any definitive treatment. External drainage is all that is needed in doubtful case. The further operative decision depends upon the findings at laparotomy; which is described here.

A. Injury to the Pancreatic head

Injury to pancreatic head is difficult to manage. Injured part can be debrided. The injury to main pancreatic duct can be drained externally or internally into a jejunal loop.

B. Injury to Pancreatic body

The separated ends of the pancreas should be debrided. Often it is not possible to perform end-to-end anastomosis of the pancreatic duct. In this situation the proximal segment of the duct should be ligated. A loop of jejunum is taken and the distal pancreatic duct is implanted in it, allowing free drainage of pancreatic juice into jejunum.

KEY BOX 31.1

Pancreatic Trauma

Grade	Description	Injury	Modified Lucas	Management
I	Hematoma	Minor contusion without ductal injury	Class I	Nonoperative management external drainage
	Laceration	Superficial laceration without duct injury		
II		Major contusion without duct injury Major laceration without duct injury		Non operative management with external drainage
III	Laceration	Distal transaction (body and tail) or parenchymal injury with duct injury	Class II	Conservative management distal pancreatectomy if transacted at neck, emergency pancreatectomy should be avoided
IV	Laceration	Proximal transaction or parenchymal injury involving ampulla	Class III	External drainage, intraoperative pancreatogram and if indicated, head resection
V	Laceration	Massive disruption of pancreatic head, combined pancreaticoduodenal injury, minor or severe duct disruption	Class IV a & b	External drainage if minor, whole area is covered with an open end of Roux-en-Y loop without any attempt to repair the injury • Whipple's procedure

C. Injury to distal pancreas

This is almost always associated to injury to spleen and distal pancreatectomy is often needed.

Octreotide; a somatostatin analogue can be used to inhibit pancreatic secretion.

Pancreatic Fistula

Pancreatic fistula usually follows operative trauma to the gland, or may occur after blunt or penetrating trauma to abdomen. They may also occur as a result of acute or chronic pancreatitis. The vast majority of fistula are minor (output less than 200ml/day) and resolve with in 2 weeks of injury provided adequate drainage has been established. High output fistula (out put greater than 500 ml/day) usually does not resolve spontaneously and are associated with enormous fluid and electrolyte loss; which is needed to be replaced.

A high output fistula which fail to decrease in volume or persist for more than a few weeks, ERCP is indicated and will be helpful in establishing the cause & site of fistula.

Frequently the cause is related to obstruction with in pancreatic duct, which is managed by insertion of a stent or catheter endoscopically into pancreatic duct and waiting for closure of fistula spontaneously.

****

ACUTE PANCREATITIS

Acute pancreatitis is defined as acute inflammatory process of pancreas with variable involvement of other regional tissue or remote organ system. Clinically it is characterized by acute onset of symptom in previously healthy individual, and disappearance of those symptoms as the attack resolves.

The clinical manifestation of the acute pancreatitis varies from edematous pancreatitis, which is usually a mild and self limiting disease to a narcotizing pancreatitis in which the degree of pancreatic necrosis correlates with severity of attack and it's systemic manifestation. The peak incidence in men is 30-40 years and in women 50-60 years.

Etiology

Many factors have been implicated in the causation of this disease but two factors:

(i) Biliary stone disease and

(ii) Alcoholism, accounts for 80-90% of the causes.

Most common cause of acute pancreatitis is biliary calculi, which accounts for 50-70% of patients and *next being alcohol abuse*, *(PGI 88, JIPMER 87)* which accounts for about 25% of cases. The remaining cases may be due to rare causes or idiopathic. (must see box 31.2)

Causes of Acute Pancreatitis

A. Common Causes

- Gall stones- M/C-cause 50-70% *(PGI JUNE 02, PGI 96, COMED 07)*
- Alcohol (acute & chronic alcoholism) - IInd M/C
- Hypertriglyceridemia
- Endoscopic retrograde cholangio pancreatography (ERCP) *(IMP)*

  NOTE: Acute pancreatitis is M/C complication of ERCP.

- Trauma (especially blunt abdominal trauma)
- Postoperative (abdominal & nonabdominal operations)
- Drugs (L-asparaginase, thiazide diuretics, estrogens, azathioprine, 6-mercaptopurine, methyldopa, sulfonamide, tetracycline, valproic acid, Fursemide, Contraceptive pills, Steroid) *(PGI 08)*
- Sphincter of Oddi dysfunction

KEY BOX 31.2

Causes of Acute pancreatitis (Mnemonic: Gall Stone)

G-Gall stone (M/C cause)
A-Alcohol, Azathioprine
L-L-Asparginase
L-Lipid (Hyperiglyceridemia)
S-Sufonamide
T-Trauma, Thiazide, Tetracycline
O-Oddi sphincter dysfunction
Operation (post operative)
N-Neoplasm
E-ERCP, Estrogen

KEY BOX 31.3 (a)

Pathophysiology of severe acute pancreatitis

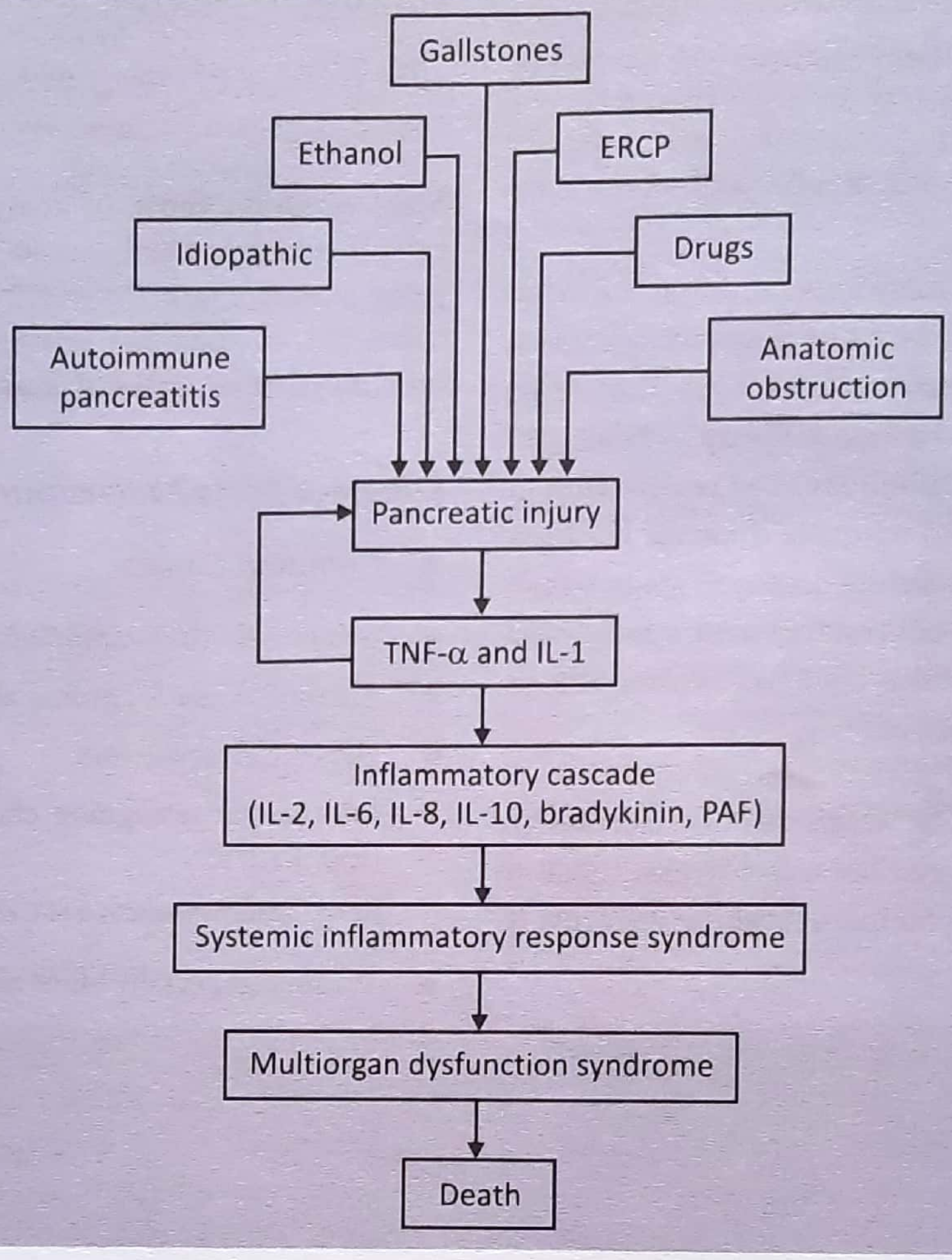

B. Uncommon causes

- Vascular causes and vasculitis
- Connective tissue disorders and thrombotic **thrombocytopenic purpura (TTP)** *(NEET)*
- Cancer of the pancreas
- **Hypercalcemia**
- Pancreas divisum
- Hereditary pancreatitis
- **Cystic fibrosis (mucoviscidosis)**
- Renal failure

C. Rare causes

- Infections (**Mumps,** Coxsackie virus, Cytomegalovirus, echovirus, parasites)
- Autoimmune (eg; Sjogren's syndrome)

D. Cause of recurrent acute Pancreatitis without obvious pathology-

- Hypertriglyceridemia
- Pancreas divisum
- Sphincter of ODDI dysfunction
- Cystic fibrosis
- Drugs

Pathogenesis

The pathological changes is acute pancreatitis are due to action of pancreatic enzymes on the pancreas & surrounding tissue. Trypsin & chymotrypsin activate lipase and elastase as well as kinins, complement and coagulation cascade. The clinical effects are shown in a flowchart in key box 31.3 (a & b).

In addition to a local action, pancreatic enzymes enter the bloodstream. However circulating amylase doesn't contribute in cell injury; instead phospholipase are thought to contribute in production of adult respiratory distress syndrome (ARDS) by interfering with the normal function of pulmonary surfactant.

Clinical feature

1. Pain:

Pain is chiefly located in epigastrium, but may also involve both upper quadrants or lower chest. **Pain is severe, constant, gradually increasing, non colicky, agonizing, tends to radiate to back or to left loin.** *(NEET)* **(Pain may somewhat be relieved by leaning forward or lying on the side with the knees drawn upwards** *(NEET, IMP. POINT)*). Pain increases when patient lies in supine position. The character of pain as described by patient is knifing or boring through back. Pain of pancreatitis is refractory to usual doses of analgesic. Rebound tenderness may be present in the central region of the upper abdomen and are usually more pronounced just above the umbilicus. In case of inflammation of tail of pancreas; tenderness at the left costovertebral angle is present.

2. Nausea and Vomiting

This usually follows the pain and usually persist even after the stomach has been emptied. The vomiting may leads to gastroesophageal tears and upper GI bleed. Vomiting and retching may relieved by passage of a nasogastric tube (Ryle's tube).

3. Fever

Initially patient present with subnormal temperature. Fever usually develops within 24 hours & fever greater than 39°C usually indicates secondary bacterial infection.

4. Respiratory distress

In early stages of acute pancreatitis when pain is severe patient may be tachypneic and breathless. Some degree of arterial hypoxemia occurs in 70% patients during first 48 hours. Pulmonary edema may occurs early in the illness but respiratory failure is a late feature due to systemic inflammatory response syndrome (SIRS).

KEY BOX 31.3 (b)

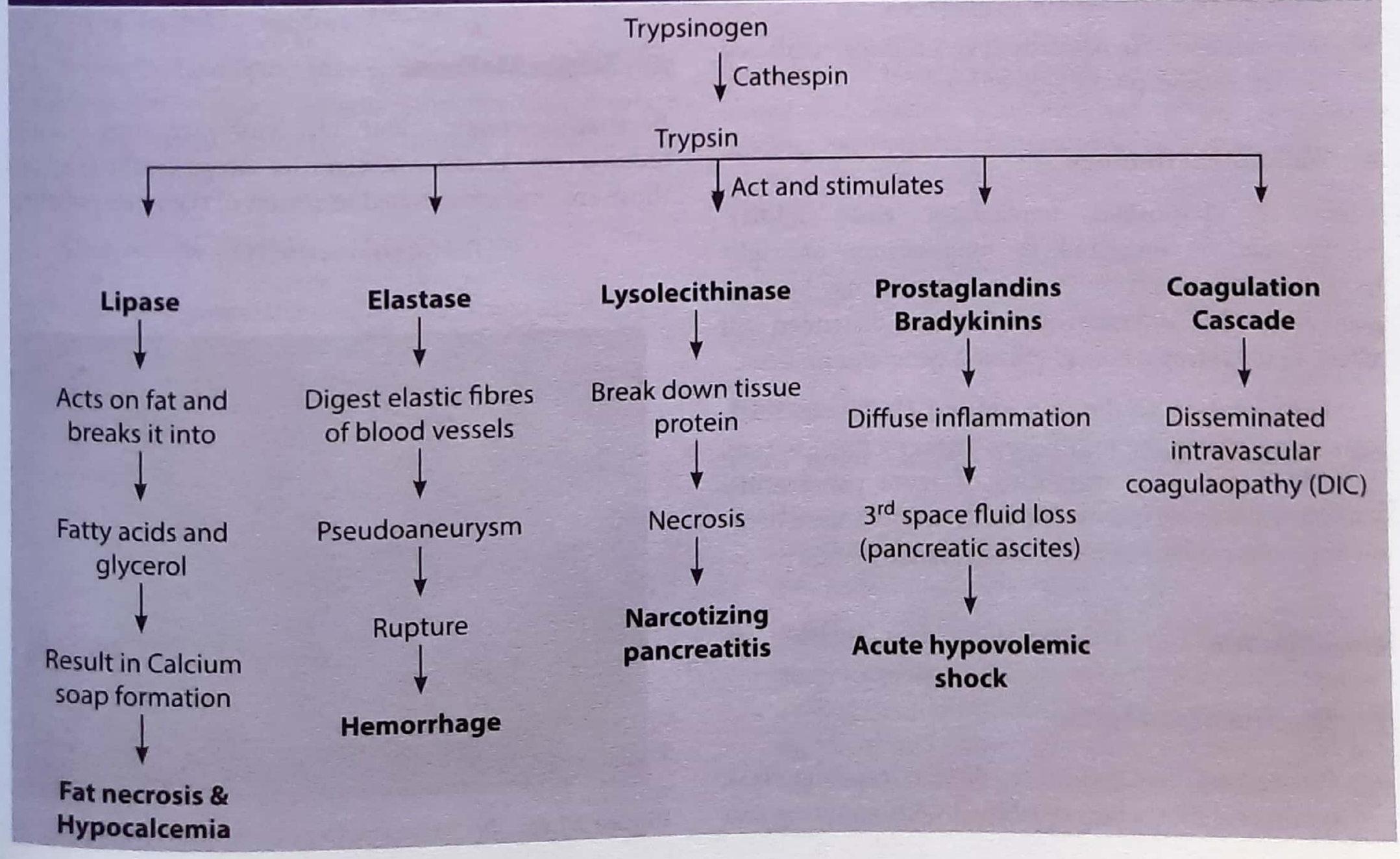

5. Hypovolemic shock

This is present in proportion to severity of retroperitoneal effusion and area of tissue necrosis.

- Shock is most common cause of death following acute pancreatitis

6. Jaundice

Jaundice; biochemical or clinical occurs in some (15%) cases. It is usually transient but some times can be intractable and severe. The common causes are extrinsic compression of intrapancreatic common bile duct or a stone impacted at papilla. Acute cholangitis may some time complicate acute pancreatitis with high grade fever and septic shock.

7. Physical finding

Patient of sever pancreatitis usually appears ill and anxious. Hyperthermia is common may be due to release of inflammatory mediators from injured pancreas.

- Tachycardia, tachypnea and hypotension caused by hypovolemic shock is often present. Breath sounds in the lower lung field is usually diminished. A pleural effusion can often be detected on either side; but commonly on left side.
- Altered mental status may be due to ethanol exposure, hypotension or hypoxemia.
- Subcutaneous fat necrosis may produce small red tender nodules on the skin of leg.

8. Abdominal findings

There is **abdominal tenderness and rigidity**, which may be **localized to epigastrium or right hypochondrium** *(AIIMS MAY 19)* or some times may become generalized. The abdomen often becomes distended and silent, as the retroperitoneal effusion generates an ileus.

Discoloration of the skin around **U**mbilicus (c**U**llen's sign) and in the loin (Grey-Turner's sign) is rare, *(MANY PGME)* but very suggestive of acute pancreatitis. These are due to peripancreatic and retroperitoneal hemorrhage and seepage of blood along fascial planes.

Investigation

1. Routine blood tests

- Pancreatitis can induce a diffuse capillary leak syndrome, that when combined with vomiting can results in significant fluid loss. This causes increased hematocrit, hemoglobin, blood urea nitrogen and creatinine.
- Serum albumin level is markedly depressed. Serum electrolytes are usually within normal range, but with severe vomiting, a hypocloremic metabolic alkalosis can develops. Hypocalcemia may explained by hypo-albuminemia. *(MANY PGME)* [Note: Calcium bounds to albumin; hence hypocalcemia]
- Serum calcium level < 2.0 mmol/lit is associated with poor prognosis. *(PGME)*
- Blood glucose is usually elevated due to increased glucagon and catecholamines combined with diminished insulin release.
- W.B.C count is usually elevated.
- Hyperbilirubinemia is usually due to CBD stones or duct obstruction by inflamed pancreas.
- Patient with severe pancreatitis can also develop DIC. In these cases, platelet count is decreased with increased FDP(fibrinogen degradation products), decreased fibrinogen level, increased PTT and PT is observed.
- Circulating level of inflammatory mediators like IL-1, IL-2, IL-6, CRP* and TNF-alfa are also increases. *CRP= C-reactive protein

2. Serum Markers

Because pancreatic acinar cells synthesize, store and secretes a large number of digestive enzymes; the levels of those enzyme are elevated in serum of the most patients.

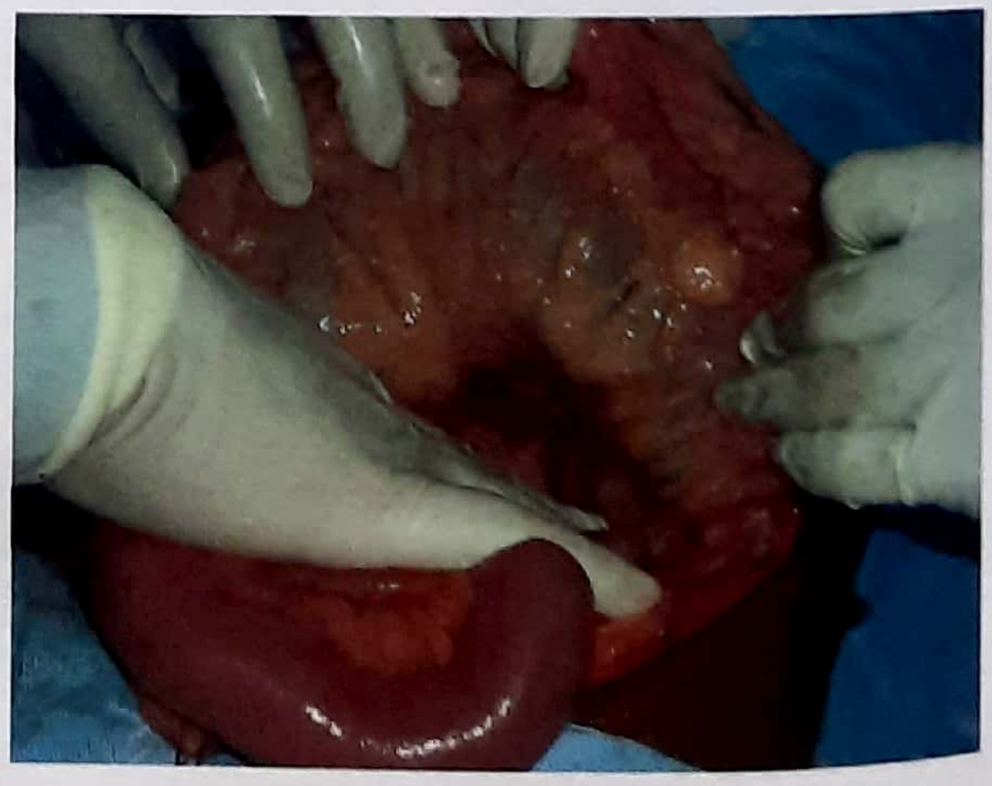

Figure 31.6: On table picture of acute pancreatitis

(i) Serum amylase

Normal serum amylase level is 80-150 somogi units/It. A serum level **>400 somogi unit is suggestive, while > 1000 somogi unit. It is almost diagnostic of acute pancreatitis.** It's concentration increase almost immediately and peaks within few hours *(PGI 2000)*. It remains elevated for 3-5 days, then gradually return to normal.

- **Persistent high levels of amylase, indicates unresolving inflammation recurrent attacks or complication like pseudocyst or abscess formation** *(NEET)*.
- Acute exacerbation of inflammation in a patient with chronic pancreatitis is not necessarily associated with marked rise in serum amylase level.
- Since hyperamylasemia can be observed in many other extrapancreatic disease, pancreatic specific amylase (P-amylase) measurement in more specific.
- Please read key box 31.4; carefully

KEY BOX 31.4

Hyperamylasemia can also occurs in some non pancreatic condition like *(PGME MANY TIME)*

- Perforated peptic ulcer
- Salivary gland disease
- Perforation of Gall bladder
- Cirrhosis, Hepatitis
- Ruptured abdominal aneurysm
- Diabetic ketoacidosis
- Intestinal obstruction
- Ruptured graafian follicle
- Ruptured ectopic pregnancy
- Ovarian cysts and cancers

(ii) Urinary Amylase

The Urinary clearance of pancreatic enzymes from circulation increases during pancreatitis, so urinary amylase level is also measured. Urinary amylase level usually remain elevated for several days after serum levels have returned to normal.

(iii) Serum Lipase

More specific than S.amylase *(AIIMS MAY 19)*

The serum level of lipase may remain elevated for longer time *(AIIMS JUNE 01)* and specificity is higher than amylase and is the **serum indicator of higher probability of disease** *(NEET)*.

3. Diagnostic Peritoneal lavage (DPL)

This may be occasionally useful if the diagnosis is still in doubt. The aspirate is very high in amylase.

? DPL; read on page 727

4. Imaging Study

(1) X-ray

- X-ray chest may show unilateral or bilateral pleural effusion.
- X-ray abdomen may reveal
  - (i) *Sentinel Loop:* This is air containing slightly dilated loop of small intestine over left upper quadrant, it is due to local involvement of small bowel adjacent to pancreas.
  - (ii) *Colon Cut off sign:* It is due to localized colonic ileus with gas in transverse colon, ceasing abruptly and suggesting colonic obstruction
  - (iii) On occasion widening of 'C' loop of duodenum in barium meal is seen.
  - (iv) Renal 'halo' sign.

(II) Ultrasound

USG is best way to confirm the presence of gallstones in suspected biliary pancreatitis. It can also detect extra pancreatic ductal dilatation and reveals pancreatic edema, swelling and peripancreatic fluid collection.

(III) CT Scan

CT scanning with intravenous contrast has become the **gold standard** for detecting and assessing the seventy of pancreatitis. *(PGI JUNE 04, MANY PGME)*.

(IV) ERCP

ERCP is not routinely indicated. Indication of ERCP are:

- Preoperative evaluation of patient with suspected **traumatic** pancreatitis to determine whether the pancreatic duct is disrupted or not.
- **Patient with suspected biliary pancreatitis and severe disease**, who do not clinically improve after 24 hours of admission, so that endoscopic sphincterotomy and stone extraction may performed, it is for that reason pancreatitis due to gall stone has best prognosis among all type of pancreatitis. *(IMP. POINT)*

- In patients older than 40 years with no identifiable cause; to rule out occult CBD stone, **pancreatic or ampullary carcinoma.** *(AIIMS JUNE 20)*
- Patient younger than 40 years who had cholecystectomy done in past; but of late has experienced **more than one attack of unexplained pancreatitis.**
- Patient presenting with unexplained jaundice.

MANAGEMENT

There are several aspects in management of an acute attack of acute pancreatitis. These includes :

A. Assessment of severity and prediction of outcome
B. Initial management of acute episode
C. Detection and management of complication
D. Indication of surgical treatment

Each will be discussed one by one:

A. Assessment of Severity and Prediction of outcome *(AIIMS 2000, 2011)*

This is done with the help of following:

1. Laboratory Criteria: This includes

(i) Ranson's Criteria *(AI 88, MANY PGME, AIIMS 06)*

For Gall stone pancreatitis

On admission	Initial 48 hours
1. Age > 70 years	Hematocrit fall > 10%
2. WBC > 18000 / mm^3	BUN elevation > 2 mg/dl
3. Glucose > 220 mg/dl	Serum Ca^{++} < 8 mg/dl
4. LDH > 400 IU/Lt	Base deficit > 5 meq/Lt.
5. AST>250U/100ml	Estimated fluid > 4 liters-sequestration

For non gall stone pancreatitis

On admission	Initial 48 hours
1. Age > 55 years	Hematocrit fall > 10%
2. WBC > 16000/mm^3	BUN elevation > 2 mg/dl
3. Glucose > 200 mg/dl	Serum Ca^{++} < 8 mg/dl
4. LDH > 350 IU/Lt.	Base deficit > 5 meq./Lt
5. AST > 250 U/100 ml	Estimated fluid > 6 liters-sequestration
6. Arterial PO_2	< 60 mmHg

(ii) APACHE II Score

- Acute physiology & chronic health examination II.
- Used for ICU mortality prediction score.

Parameters

Oxygenation	Glasgow coma scale
Temperature	S. Na^+
MAP	S. K^+
PH arterial	Creatinine
HR	Hematocrit
RR	WBC count

(iii) Glasgow Criteria

PaO_2 < 76 mmHg	Renal function BUN >45mg/dL
Age > 55 yrs.	
WBC > 15000/mm^3	Enz : LDH > 219 IU/L, AST/ALT > 96 IU/L
Ca^{+2} < 8 mg/dL	
Glucose > 200 mg/dL	Albumin < 3·4g/dL

Criteria	Score @ which severe pancreatitis
Ranson Criteria	≥ 3
Apache II	≥ 8
Glasgow socre	≥ 3
CT severity index	≥ 6
CRP	≥ 150 mg/L

Prognosis

The prognosis depends on number of Ranson's score present

Number of Ranson Score	Mortality in % (approx)
0-2	0%
3-4	15%
5-6	50%
>6	70-90 %

Score less than 3 means mild pancreatitis and more than 3 indicate severe pancreatitis.

Balthazar grading system (CT severity index)

A. Normal Pancreas
B. Pancreatic enlargement
C. Pancreatic inflammation

Atlanta criteria for acute pancreatitis
Organ failure, as defined by
Shock (systolic blood pressure <90 mm Hg)
Pulmonary insufficiency (PaO_2 <60mm Hg)
Renal failure (creatinine level >2 mg/dl after fluid resuscitation)
Gastrointestinal bleeding (>500 mL/24 hour)
Systemic complications
Disseminated intravascular coagulation (platelet count ≤ 100,000)
Fibrinogen<1 g/L
Fibrin split products >80 µg/dL
Metabolic disturbance (calcium level ≤7.5 mg/dL)
Local complications
Necrosis
Abscess
Pseudocyst
Severe pancreatitis is defined by the presence of any evidence of organ failure or a local complication.

D. Single Peripancreatic fluid collection

E. ≥ 2 fluid collection

Pancreatitis is divided as severe pancreatitis & mild pancreatitis. There is no clinical entity termed as moderate pancreatitis.

(iv) C-reactive protein

It's estimation is also useful in predicting prognosis. **A valve of > 210 mg/lits, during the first 4 days or > 120 mg/lit at the end of 1st week of an attack predicts severe disease.** (NEET) This includes:

Mortality and morbidity in acute pancreatitis is directly related to extent of pancreatic parenchyma! nacrosis, the development of peripancreatic retroperitoneal fat necrosis, occurrence of biliary tract sepsis and bacterial contamination of necrotic tissue.

Mortality in acute pancreatitis

Edematous pancreatitis	3-10%
Necrotizing pancreatitis	40-50%
Complete necrosis of pancreas	Almost 100%

Hypocalcemia & hyperglycemia associated with poor prognosis.

B. Initial Management of Acute Pancreatitis

(i) I.V. Fluids and analgesia

Large quantities of extracellular volume replacement by **isotonic fluid** (NEET) (> 10 or more liters in 24 hours) may be necessary, the objective being to bring hematocrit down to normal and maintain arterial pressure, CVP and urine output. Shock is principle cause of death in first 48 hours. Pain is relieved dine and restlessness by small doses of diazepam.

(ii) Antibiotics

There is possibility that the inflamed adjacent gut wall become more permeable to bacteria and their endotoxin, thus permitting local infection, portal endotoxemia and bacteremia. Endotoxemia may have both pulmonary and renal effects, either by direct toxicity or by inflammatory products like cytokines, interleukins and prostaglandins. These products causes systemic inflammatory response syndrome (SIRS) and contributes towards multiple organ failure (MOF). One of the major causes of mortality in acute pancreatitis is development of infected pancreatic necrosis usually by gram negative organism. Prophylactic systemic antibiotics (like cefuroxime, Imipenem) should be given to all patients assessed as having severe attack.

(iii) Role of Nasogastric decompression

Nausea and vomiting in pancreatitis can results in significant fluid as well as electrolyte loss. Retching can leads to gastroesophageal mucosal tears and result in upper GI hemorrhage. To increase patients comfort; nasogastric decompression is needed, although it does not alter the eventual outcome of attack.

(iv) Nutritional support

Patient with severe pancreatitis may be unable to eat for prolonged periods and an alternative route for providing nutrition is required. Traditionally these patients are given parental nutrition via a central venous catheter.

(v) Atropine, somatostatins, glucagons, calcitonin, steroids, peritoneal dialysis and such other measure are having limited or unproved value.

C. Management of Acute Complication

1. ***Hypocalcemia and tetany*** is managed by repeated intravenous use of 10% calcium gluconate.
2. ***Respiratory complication:*** Arterial hypoxemia may develop due to:

- Abdominal distention, with compression of lung bases and elevation of diaphragm.
- Pleural effusion
- Direct lung injury by enzymes, free fatty acids and long toxins.
- Systemic inflammatory response syndrome (SIRS).
- Reduced ventilation due to pain
- Destruction of pulmonary surfactant by activation of phospholipase A.
- Over infusion of crystalloids.
- Intranasal oxygen is administered to correct arterial hypoxemia. Positive pressure ventilation is often required in patient with severe attack of acute pancreatitis.

D. Indication of Surgery

- Uncertain diagnosis : If diagnosis of acute pancreatitis is equivocal and if other surgical causes of acute abdomen is suspect (which requires immediate surgery)
- Pancreatic abscess formation.
- Massive upper G.I. bleeding, Intraabdominal hemorrhage, pancreatic necrosis and biliary obstruction requires urgent surgery.

Complications of Acute Pancreatitis

A. General complication

Pancreatitis may involve all organs of the body:

- Bilateral pleural effusion develops in many patients. **Clinical respiratory distress, tachypnea and hypoxia may result from diffused bilateral pulmonary infiltrate.** *(NEET)* Patient may also develop **ARDS,** DIG and hypovolemic shock, which may effect kidney & lead to renal failure.
- Circulating toxins with neurogenic effect of pain lead to peripheral circulatory failure and poor tissue perfusion. This affects function of several vital organs.
- **Hypocalcemia** results from action of pancreatic lipase on the triglyceride in the fat cells, breaking these into glycerol and fatty acids, which forms complex with plasma calcium ion to form a calcium soap in Peritoneal cavity. Since most of the serum calcium form complex with glycerol and fatty acid, *there occurs decrease in serum calcium and hypocalcemia develops*. *(MANY PGME, VERY IMP. POINT)*

NOTE: *Low serum calcium has a very poor prognostic value* *(PGI JUNE95, MANY PGME)*

Hypercalcemia (Hyperparathyroidism) may cause acute pancreatitis, while acute pancreatitis may cause hypocalcemia. (imp. point)

- Rarely, pancreatic lipase enters into blood stream and causes subsequent widespread fat necrosis throughout the body, the subcutaneous fat (**Grey-Turner's sign → Flanks, Cullen's sign → Umblicus**) *(NEET, IMP. POINT)*

B. Local complication

(i) Acute fluid collection:

This occurs during the early stages of severe pancreatitis in 30-50% of patients. Most are peripancreatic but some are intrapancreatic. Those that do not regress may evolve into pseudocyst or involve areas of necrosis.

(ii) Pancreatic and peripancreatic Necrosis:

These are areas of nonviable pancreatic or peripancreatic tissue that may be either sterile or infected. They typically include areas of fat necrosis and has a putty like consistency. Some necrotic regions may evolve into pseudocyst, whereas other may be replaced by fibrous tissue.

Infected Pancreatic necrosis treated with laparotomy & surgical debridement.

(iii) Pancreatic abscess:

These are circumscribed intraabdominal collections of pus usually in proximity to pancreas, which contain little or no necrotic tissue, but arises as a consequence of pan-

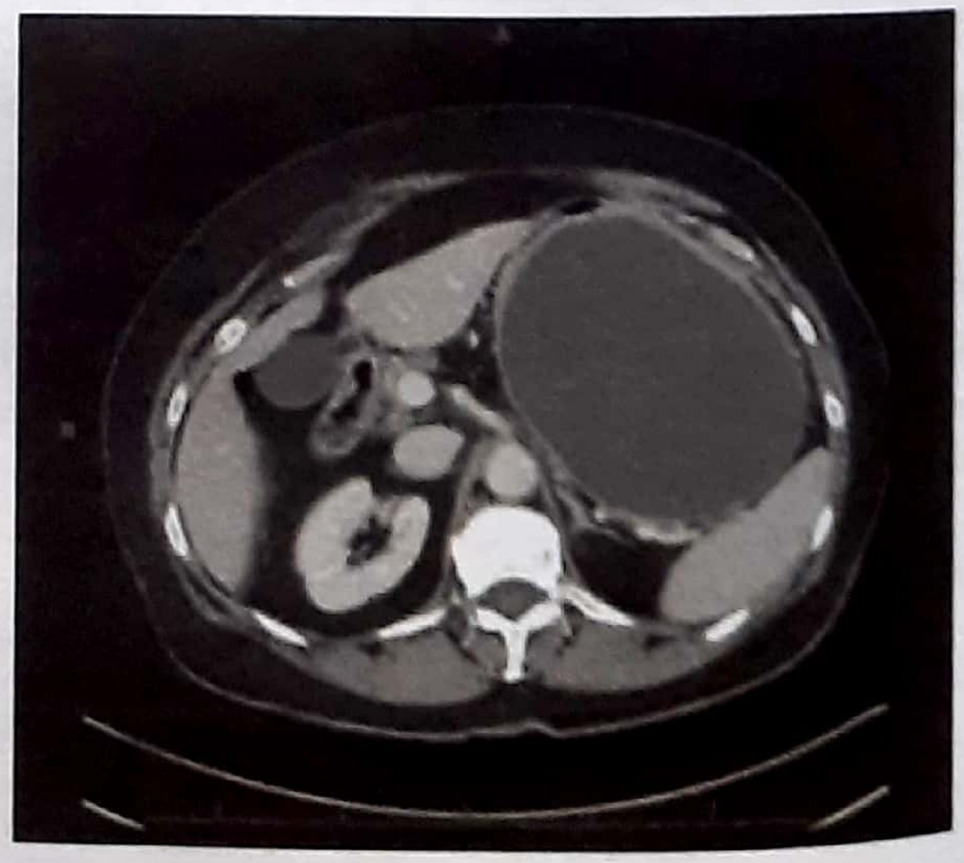

Figure 31.E1: Computed tomography (CT) scans showing a large pseudocyst arising in the tail of the pancreas.

Revised definition of morphological features of acute pancreatitis			
Time from onset	**Subtype of pancreatitis**	**Fluid collection nomenclature**	**Computed tomography findings**
4 weeks	Interstitial edematous	Acute peripancreatic fluid collection	• Homogeneous collection with fluid density • Confined by normal peripancreatic fascial planes • No definable wall encapsulating the collection • Adjacent to pancreas (no intrapancreatic extension)
	Necrotizing	Acute necrotic collection	• Heterogeneous and nonliquid density of varying degrees in different locations (some appear homogeneous early in their course) • No definable wall encapsulating the collection • Location-intrapancreatic and/or extrapancreatic
> 4 weeks	Interstitial edematous	Pseudocyst	• Well circumscribed, usually round or oval • Homogeneous fluid density • No nonliquid component • Well- defined wall; that is, completely encapsulated
	Necrotizing	Walled-off necrosis	• Heterogeneous with liquid and nonliquid density with varying degrees of loculations (some may appear homogeneous) • Well-defined wall; that is, completely encapsulated • Location-intrapancreatic and/or extrapancreatic

creatitis. In pancreatic abscess there is little necrosis and material has a liquid consistency. External drainage is the treatment of choice. *(UPSC 08)*

(iv) Pancreatic Pseudocyst

These are collections of pancreatic juice usually rich in digestive enzymes that are enclosed by a non epithelized wall composed of fibrous and granulation tissue.

(v) Pancreatic ascites

Leakage or rupture of a pseudocyst into peritoneal cavity results in pancreatic ascites. There is elevated protein and amylase level in ascites fluid. *(PGI JUNE 99)*

(vi) Pancreatico-pleural fistula

Results from erosion of a pseudocyst into pleural space.

(vii) Pseudo aneurysm

Pseudocyst that erodes into a neighbouring vessel can result in formation of a pseudoaneurysm and result in upper gastrointestinal bleeding.

****

CHRONIC PANCREATITIS

Chronic pancreatitis is an incurable, chronic inflammatory condition that is multifactorial in it's etiology, highly variable in its presentation and a challenge to treat successfully. When pancreatic inflammation leads to permanent structural and functional damage, the term chronic pancreatitis is used.

Etiology

- **Alcohol-(M/C cause of chronic pancreatitis 70%)** *(NEET)*
- Nutritional (Tropical) - 20%
- Others - 10%
  - Hereditary pancreatitis
  - Hyperparathyroidism
  - Hypertriglyceridemia
  - Autoimmune pancreatitis
  - Trauma
  - Gall stone (**NOTE:** M/C cause for **acute** pancreatitis)
  - Slow growing tumours of duct
  - Idiopathic

Pathology

- Chronic pancreatitis is characterized by shrinkage of pancreas, as a result of fibrosis and atrophy of acinar structure. The changes usually involve the gland diffusely. Rarely a firm localized mass is formed, that is difficult to be distinguished grossly from carcinoma.
- The pancreatic ducts show multiple areas of stenosis and dilatation. Distal to stenosis ducts are filled with inspissated secretions that may undergo calcification to form calculi, giving rise to ***"the chain of lakes"***. *(AIIMS, AI, UP, MANY PGME)*
- Diffused calcification gives a rock hard consistency to gland.
- Microscopically there is acinar loss with marked fibrosis. Islets tend to withstand destruction better than acini and gross lymphocytic infiltration is present.

Clinical feature

The disease occurs more frequently in men (male to female ratio is 4:1) and mean age of onset is about 40 years.

1. Pain

Pain is most common symptom of chronic pancreatitis. *(NEET* It is usually mid epigastric in location but may localize or involve either the left or right upper quadrant of the abdomen. The pain is typically deep steady and boring, often radiating to back. As the exocrine gland progressively under goes atrophy, pain reduces. In late stages with considerable deterioration of exocrine function, pain disappears almost completely. Nausea and Vomiting may accompany the pain & anorexia is the most common associated symptom. *(IMP. POINT)*

2. Malabsorption and weight loss

When pancreatic exocrine capacity falls below 10% of normal, diarrhoea and steatorrhea occurs. Patient describe a bulky, foul smelling, loose (but not watery) stool that may be pale in colour and float on surface of toilet water. In severe steatorrhea an orange, oily stool is reported.

3. Pancreatogenic Diabetes

The islets comprise only 2% mass of pancreas, but they are preferentially conserved in early stage of chronic pancreatitis. Diabetes develops in the late stages of the disease, when the islet cells are also destroyed along with the pancreatic exocrine tissue.

Frank diabetes is initially in about 20% of patient with chronic pancreatitis. Ketoacidosis and diabetic nephropathy are relatively uncommon in pancreatogenic diabetes, but retinopathy and neuropathy are seen to occur with a similar frequency as in idiopathic diabetes.

Investigation

1. Plain - X-ray of the abdomen

A plain x-ray of the abdomen shows, calculi, characteristically localized across the 1st lumbar vertebra, obliquely upward and towards the left hypochondrium.

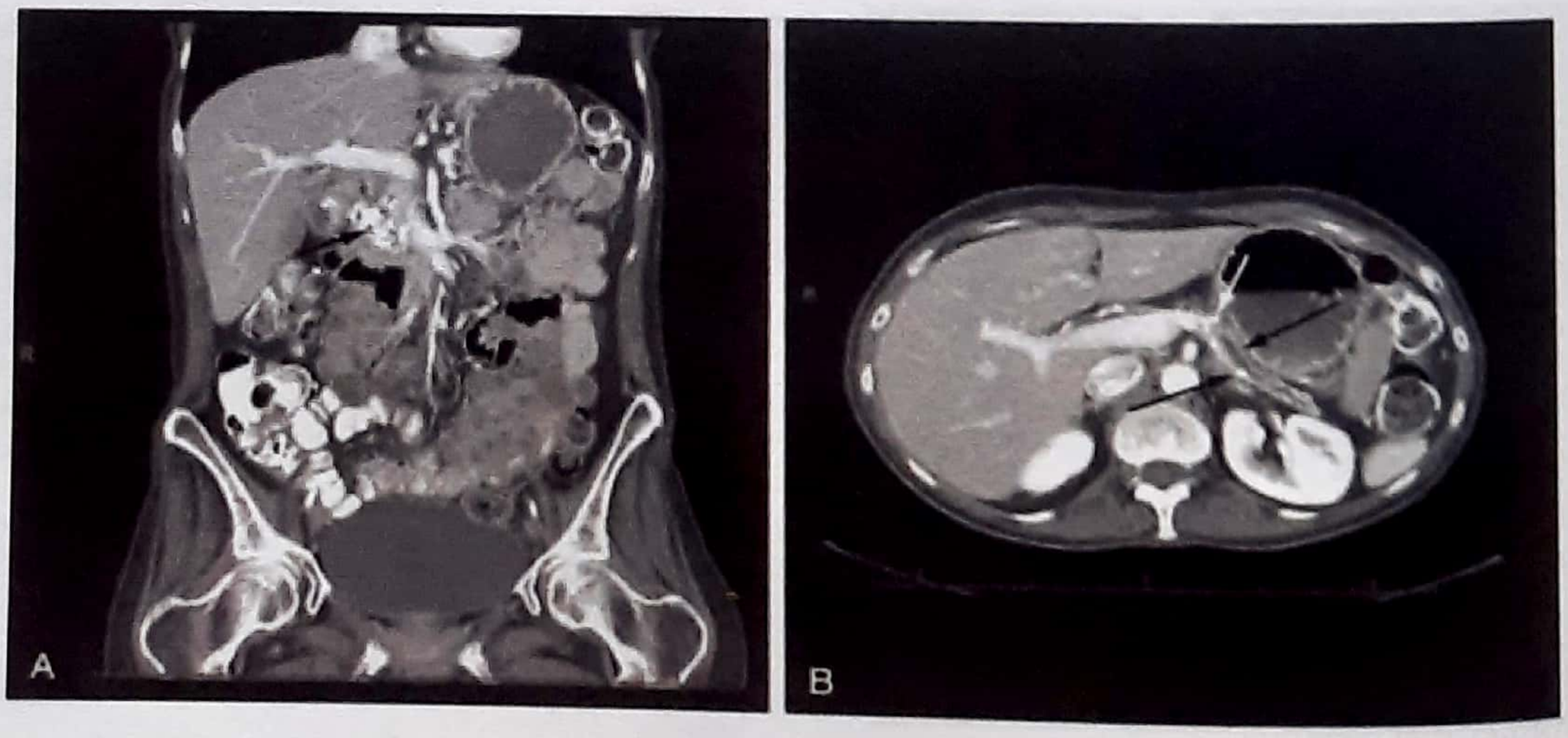

Figure 31.E2 : Typical computed tomography (CT) findings associated with chronic pancreatitis. Shown are pancreatic duct dilation (long arrow) and intrapancreatic calcifications, which are also typical of chronic pancreatitis (small arrow)

2. Ultrasonography

This is the *investigation of choice for detecting the pancreatic pathology* (MANY PGME), even small stone, not detected by plain X-ray can be detected. USG can also give information about the status of gland, swelling or atrophy of gland. USG can also show the presence of cysts in relation with pancreas. USG can also show concomitant pathology in biliary tract in the form of biliary stone or common bile duct dilatation.

3. Contrast Enhanced CT scan (CECT)

This is now the *gold standard for investigating pancreatic pathology* (MANY PGME). This outlines pancreas, tells about status of pancreatic duct and stone is pancreatic duct:,

Investigation of choice means, with respect to cost effectiveness it is best investigation, ie; USG is investigation of choice as it is cheap (about 500-700 rupees in India), while CT is gold standard, means it is best investigation in telling pancreatic anatomy if the cost of investigation is not taken in consideration. (Note: Cost of CT scan is 4000-7000 rupees)

4. MRI

With recent development of MRI the pancreas can now be clearly displayed in manner similar to CT scan. In addition, clear images of the bile duct and pancreatic duct together with fluid collection can be defined.

5. ERCP (Endoscopic retrograde cholangio pancreatography)

Change seen in chronic pancreatitis include pancreatic duct strictures, dilatation of main pancreatic duct with stone, abnormalities of pancreatic duct side branches and communication of pancreatic duct with cyst. This is now Gold Standard for diagnosis.

6. MRCP (Magnetic resonance cholangiopancreatography)

Magnetic resonance pancreatography and cholangiography may well replace diagnostic ERCP, because it is non-invasive.

7. Intraoperative Pancreatography

Intraoperative (during operation) pancreatography is done by injecting a dye, directly in the pancreatic duct and taking the X-ray picture. The stone may show filling defect. There may be stricture and, dilatation of main pancreatic duct giving a typical **'chain of lakes'** appearance. (MANY PGMEE, UP 07)

8. Pancreatic function test

Pancreatic amylase and lipase may be raised only during acute exacerbation that too, during early course of disease, when the exocrine pancreatic function is still well preserved. *In late (chronic) cases, when more that 90% destruction of pancreatic parenchyma occurs, the enzymes are often low.* Following tests are performed for pancreatic function.

(i) Lundh's test

This is an invasive test. A duodenal tube is passed and pancreatic enzyme secretion after a giving (IV) hormone like cholecystokinins (CCK) are estimated. This test gives quantitative estimation of pancreatic function.

(ii) NBT-PABA test:

Nitroblue tetrazolium Para aminobenzoic acid (NBT-PABA) test is more practical test, in which recovery of PABA in urine is measured, after oral administration. *It gives estimation of chymotrypsin function of pancreas.*

(iii) ***Fecal elastase:*** (NEET)

A simpler test now available is measure of fecal elastase levels. **Absence of which indicates chronic pancreatitis and is specific.**

Treatment

(a) Medical (AI 08)

As the changes of chronic pancreatitis are irreversible, the treatment is aimed at relieving symptoms and preventing further deterioration of pancreatic function.

1. Alcohol consumption should be stopped.
2. The intake of fat should be restricted in diet.
3. Pancreatic enzyme supplements should be given orally. They help in digestion of fat and protein and prevent their excessive losses in stool.
4. Control of pancreatogenic diabetes by diet and insulin
5. Oral analgesics and antispasmodic may be needed for symptomatic relief in pain.
6. PPI and H2-antagonists like omeprazole or ranitidine should be given.

(b) Surgical

Surgical treatment is principally of value to relieve chronic intractable pain. In most cases; it involves procedures that facilitates drainage of pancreatic duct and resection of diseased pancreas or by nerve block.

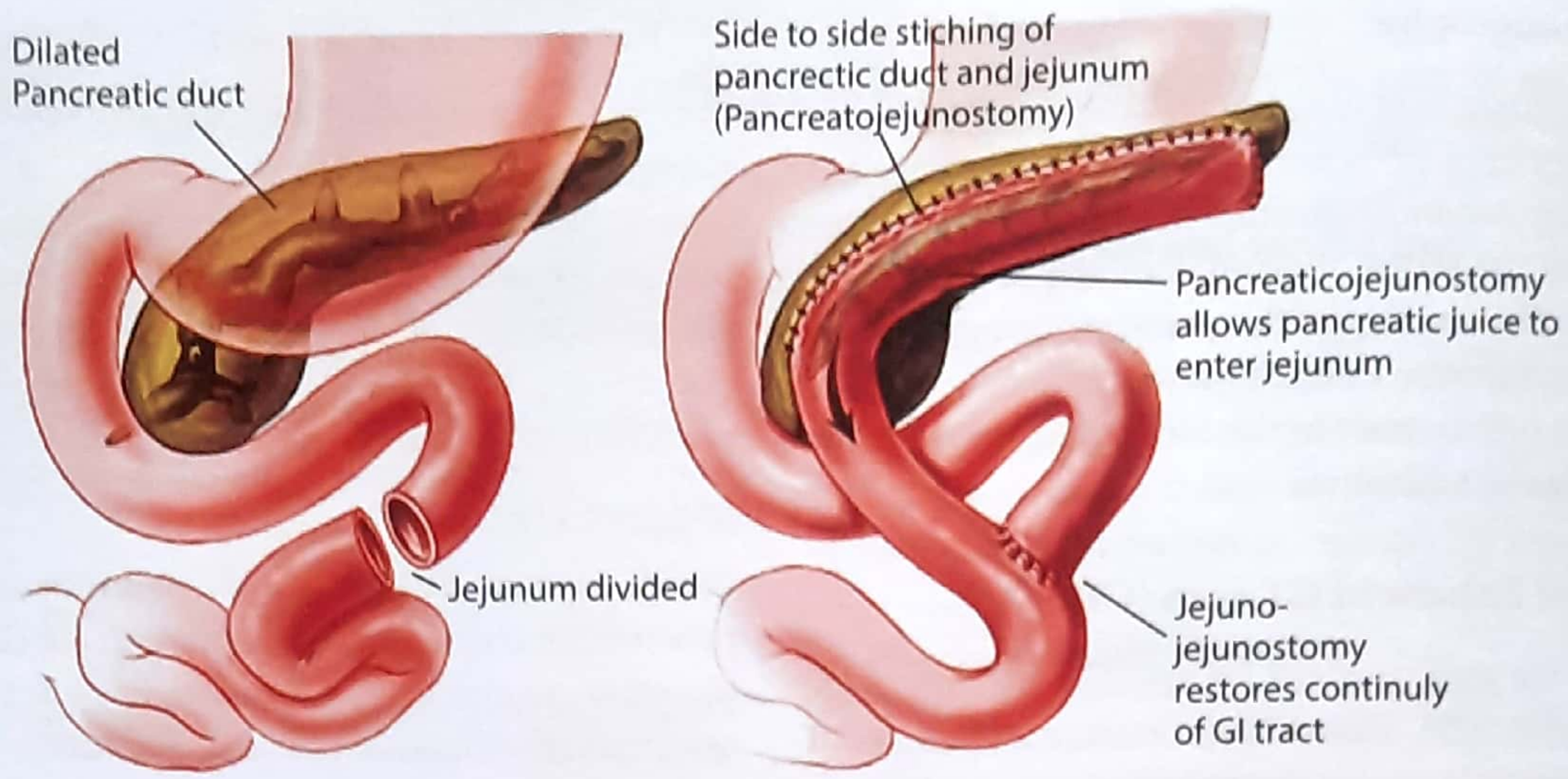

Figure 31.7: Lateral (side to side) Pancreaticojejunostomy (Puestow procedure)

The operative procedure advocated are as follow:

1. Lateral (side to side) Pancreaticojejunostomy

(MANY PGME, AI 2011)

On ERCP, if the ductal system is dilated more than 8 mm, a lateral (ie; side to side) pancreato-Jejunostomy {**Puestow procedure**} is appropriate. It may be considered as "gold standard" in surgical management. See figure 31.7

In this the pancreatic duct is opened anteriorly from tail to the head of the gland, and anastomosed side to side to a segment of proximal Jejunum. If the stone is present in pancreatic duct, it is removed at the same time.

NOTE: Side -to side here means pancreas and jejunal loop are brought side by side, consider it as bringing your both forearm side by side and anastomosing (sewing). Please see figure 31.7.

End to end anastomosis? when two terminal ends of organ/bowel or vessel are anastomosed (sewed).

2. Distal pancreatico jejunostomy

This is indicated, when a mass is discovered or pathology is found localized to tail of pancreas.

3. Whipple's pancreatico duodenectomy

This operation is performed when a malignant change is suspected is head region. This is described in detail later in this chapter.

4. Coeliac plexus block

Celiac plexus block with alcohol injection provides relief in some cases. *(UPSC 87, 88).*

Complications of Chronic Pancreatitis

1. Acute exacerbation

The patients with chronic pancreatitis may have attack simulating acute pancreatitis. The majority of complications of chronic pancreatitis are initiated during acute exacerbation. With each attack; there is deterioration of the pancreatic parenchyma.

2. Pancreatic fistula *(NEET)*

An internal fistula formation may lead to leakage of pancreatic juice in peritoneal cavity and lead to pancreatic ascites, and the leakage of pancreatic fluid may take place in extrapancreatic tissue and spread to the thorax and may lead to hydrothorax (pleuro-pancreatic fistula).

3. Intestinal obstruction

The second part of duodenum may be obstructed due to fibrotic changes in the pancreas, resulting in duodenal obstruction.

4. Splenic vein thrombosis

Chronic pancreatitis is the potent cause of splenic vein thrombosis. Which in turn leads to splenomegaly and development of varices in the stomach. The varices may lead to severe gastric hemorrhage.

5. Erosion into visceral artery

Hemorrhage from major arteries is an infrequent but often a lethal complication.

6. Pseudocyst

This is **most common complication of chronic pancreatitis.** (NEET) (Described below in details)

7. Pancreatic abscess
8. Bile duct stenosis
9. Portal vein thrombosis
10. Duct stricture and stones
11. Pancreatic carcinoma

Each of the above condition has been discussed else where in the book.

****

PANCREATIC PSEUDOCYST

A true cyst has an epithelial lining and does not communicate with pancreatic duct. A pseudocyst has no epithelial lining but communicate with pancreatic ducts and contains elevated pancreatic enzyme.

The wall of pseudocyst is made of fibrous or granulations tissue and has no true epithelial lining (hence-pseudo).

Approximately 85% of pseudocysts are located in relation with body and tail of pancreas and 15% in head. Please see figure 31.8 (AL 98, MANY PGME).

Causes of Pseudocyst formation

- Acute pancreatitis is most common cause. (PGME)
- Blunt injury to abdomen is next common cause.
- Blunt abdominal trauma in most common cause in children. (PGME)
- Acute exacerbation of chronic pancreatitis
- During the course of chronic pancreatitis

Location

In order of frequency the pseudocyst projects:

(i) Between stomach and transverse colon

(ii) Between stomach and liver

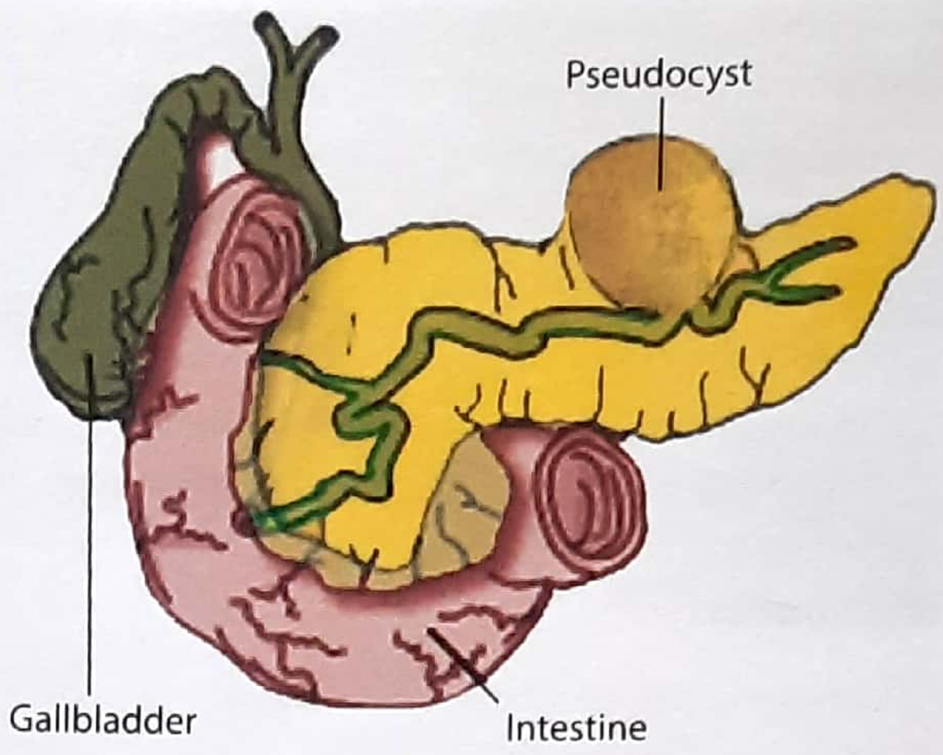

Figure 31.8: Pancreatic Pseudocyst

(iii) Behind or below transverse colon

For understanding purpose cyst can be considered like as a balloon filled with water.

Clinical feature

Clinically a **pseudocyst develops 3-4 weeks after an acute attack of pancreatitis.** (NEET) The patient either fails to improve or symptoms return after a period of improvement.

- The patient presents with progressively enlarging tense cystic swelling in epigastrium, with mild pain radiating to back. The pain is relieved by forward bending and in knee elbow position.

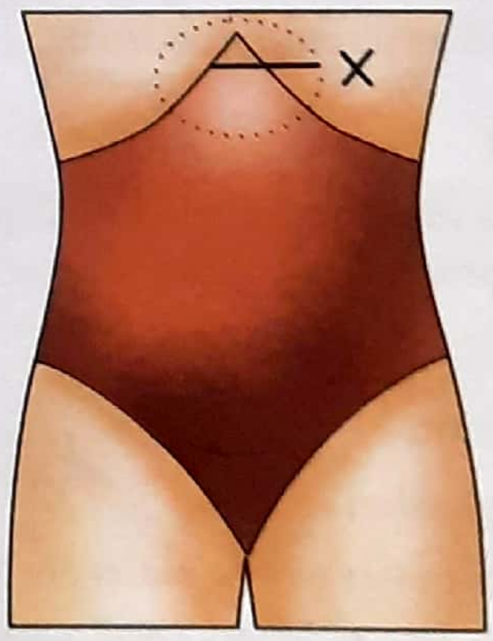

Figure 31.9: Dotted area represents area of Pseudocyst

- Persistent low grade fever, nausea and vomiting is often present.
- Patient complains about early satiety due to compression on stomach by the cyst.
- Jaundice may result from pressure on common bile duct by the cyst.
- On examination a tense cystic swelling is found in epigastrium. Please see figure 31.9, next page.

Investigation

- Elevated serum and urinary amylase.
- *Barium meal x-ray :* A barium meal X-ray taken in *lateral view shows anteriorly pushed stomach, due to displacement by an enlarged cyst,* (MANY PGME)
- If a Ryle's tube is passed, it can be felt over the swelling called as *Baid sign.*
- *USG:* can detect Pseudocyst in about 85% cases. It can give an idea about it's site, size and is usually first investigation.
- *CT scan :* is investigation of choice. (MANY PGME)
- *ERCP :* For determining pancreatic duct anatomy

Complication

The major complications are:

1. Infection

Infection in a pseudocyst occurs in 5-20% cases. Which requires external drainage. This is **most common complication** (NEET) and leads to formation of pancreatic abscess.(PGI 2000).

2. Hemorrhage

Occurs due to erosion into surrounding vessels. Most common vessel involved is splenic followed by gastroduodenal and pancreaticoduodenal.

3. Rupture

Rupture into peritoneal cavity causes pancreatic ascites, however rupture of the pseudocyst occurs in less than 5% of cases.

4. Obstruction

Due to compression of:

- Stomach: causes gastric outlet obstruction.
- Common bile duct: -Jaundice, Cholangitis

Treatment

- **Pseudocyst smaller than 6 cm size and present for less than 6 weeks may resolve spontaneously. So, it is followed with serial ultrasonic study** (NEET, MANY PGME), expecting its resolution. Ultrasound will tell that; whether the size of cyst in enlarging or regressing during the course of time. Please read key box 31.5 before going in details.

Indication for surgical intervention (MANY PGME)

(i) Age of cyst more than 6 weeks without resolution,

(ii) Size of cyst greater than 6'cm.

(iii) Evidence of secondary infection,

(iv) Development of other complication.

Surgical methods (MANY PGME)

Options are:

(a) Internal drainage

Most preferred surgical management in uncomplicated pseudocyst is internal drainage. The options are -

- Cystojejunostomy (internal drainage of cyst in jejunum)
- Cystogastrostomy (internal drainage of cyst in stomach)
- Cystoduodenostomy (internal drainage to duodenum)

If in PGME examination you get more than one correct option ie; any two or three options,- *cystojejunostomy is best option,* because it is easy to perform and provides dependent drainage. This can be done either endoscopically or after laparotomy.

Internal drainage:- Allowing free flow of cyst fluid internally; to some other organ in the body by making an opening in the cyst and connecting it to bowel lumen. Cyst empties in bowel.

Please see figure 31.10 on next page.

(b) Excision of cyst

It is usually done for the chronic cysts *involving the tail of pancreas.*

(c) External drainage

It is done if there is *gross infection in the pseudocyst* (ie; in pancreatic abscess) (AIIMS NOV 93)

KEY BOX 31.5

Patient with symptoms of pancreatits and abdominal (epigastric) lump

↓

Abd. USG, CT, Serum amylase level

↓

If pancreatic pseudocyst is confirmed

↓

Observe for 6 weeks

- Size < 6cm, asymptonatic, decrease in size of cyst → Observe → Spontaneous resolution
- Size > 6 cm, symptomatic → Internal drainage
  - **Surgical option**
    - Cysto jejunostomy
    - Cystogastrostomy
  - **Endoscopic drainage**
- If rapidly increasing and/or infection in present → Percutaneous external drainage/ catheter drainage

(d) Percutaneous aspiration

It is usually not advised. It increases the chance of infection of the cyst and recurrence is high (70%), however it may be tried in surgically unfit patient.

Before concluding; kindly go through the flow chart once again given above in key box 31.5.

****

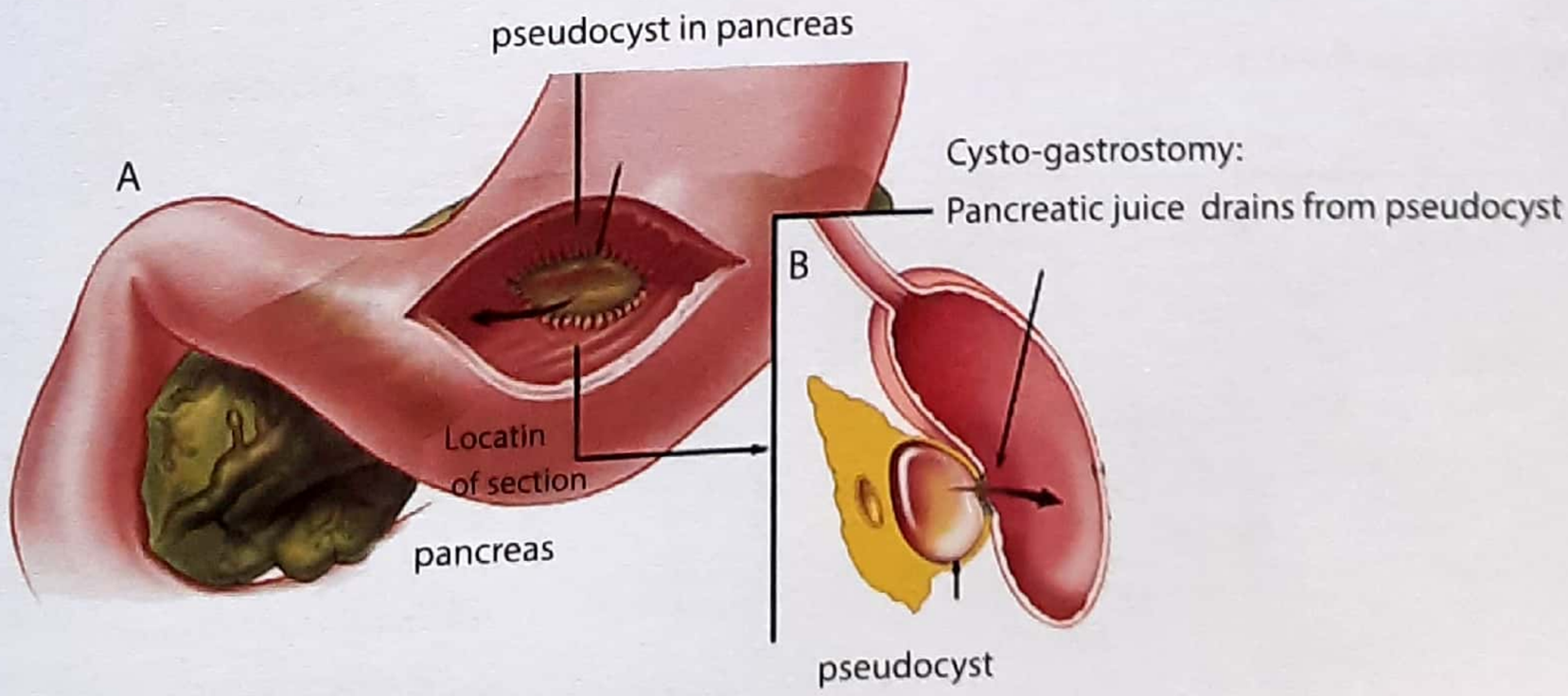

Figure 31.10: Cystogastrostomy (internal drainage of cyst in stomach)

NEOPLASMS OF THE EXOCRINE PANCREAS

- Before you start kindly read key box 31.6 carefully.
- Carcinoma of pancreas is the fifth leading cause of cancer death in united states.
- It occurs more frequently in men than women and is more common in black than white. The male to female ratio is about 4:1.
- Roughly 80% of cases occur between 60-80 years of life, where as less than 2% occur in people younger than 40 years.
- Pancreatic carcinogenesis involves the accumulation of multiple mutation. *The K-ras oncogene* is most commonly mutated gene in pancreatic cancer. *(PGME)*

NOTE: High vegetable diet and fruit has protective role in development of pancreatic carcinoma.

Predisposing Factor For CA Pancreas

- Cigarette smoking (2-3 fold increase)
- Chronic and hereditary pancreatitis.
- Obesity
- Diabetes mellitus
- Dietary consumption of fried meat and fat
- Heavy alcohol consumption (controversial)
- Long exposure to benzidine and beta-napthylamine.
- Occupational exposure to carcinogen
- Pancreatic calcinosis
- Previous gastrectomy (>20 years back)
- High coffee intake and biliary disease has been suggested but not proved.

Pathology

Nearly 90% of pancreatic malignancies arise from the exocrine pancreas and are classified as ***adenocarcinoma*** *(TN 89, MANY PGME). Other types are adenosquamous carcinoma, giant cell carcinoma etc.* Kindly see key box 31.6 for classification of pancreatic cancer.

Anatomical distribution

1. **Head: 70%** ***of malignant exocrine tumours arise from head of pancreas.*** *(NEET, PGME MANY TIMES)*
2. Body: 20%
3. Tail: 5-10%

KEY BOX 31.6

Tumours of the Pancreas

Types

Exocrine (from acini and duct)

Malignant
- Adenocarcinoma of pancreas (90%)

- Mucinous cystadenoma
- Adenosquamous carcinoma

Others

Endocrine (from islet cells)

Beta cell tumour
- Insulinoma

- Gastrinoma (G cells)
- Glucagonomas (alpha cells)
- Somatostatinomas (delta cells)
- **VIP**oma
- **PP**omas

KEY BOX 31.6 (E)

Defining characteristics of pseudocysts and pancreatic cystic neoplasms

Characteristics	Pseudocyst	SCN	MCN	IPMN
Epidemiology				
Gender Age (years)	F = M 40-60	F ≫ M (4:1) 60-70	F ⋙ M (10:1) 50-60	F = M 60-70
Imaging findings				
Location Appearance	Evenly distributed Round, thick-walled large cyst; gland atrophy ± calcification	Evenly distributed Multiple small cysts separated by internal septations with central starburst calcifications	Head ≪ body/tail Thick-walled, septated macrocyst with smooth contour, ± solid component, eggshell calcifications	Head > diffuse > body/tail Poorly demarcated, lobulated, polycystic mass with dilation of main or branch ducts
Communication with ducts	Yes	No	Very rare	Yes
Cyst Fluid Analysis				
Cytology	Inflammatory cells	Scant glycogen-rich cells, with positive periodic acid-Schiff stain	Sheets and clusters of columnar, mucin-containing cells	Tall, columnar, mucin-containing cells
Mucin stain Amylase CEA	Negative Very high Low	Negative Low Low	Positive Low High	Positive high High

CEA: Carcinoembryonic antigen, IPMN: Intraductal papillary mucinous neoplasm; MCN: Mucinous cystic neoplasm; SCN: Serous cystic neoplasm.

Spread

Direct spread to bile duct, duodenum, posterior wall of stomach and spleen.

Lymphatic spread occurs early with carcinoma situated is body and tail, rather than head.

Hematogenous spread is more common with cancer situated at head.

Clinical feature

Clinical feature of pancreatic carcinoma depends upon the location of carcinoma: (must see key box 31.6)

1. Carcinoma of the head of pancreas

- About 75% of patients with carcinoma of the head of pancreas present with *weight loss, obstructive Jaundice and deep seated abdominal pain.* (MANY PGME)
- Back pain is present in only 25% of patients and, when present is associated with worse prognosis.
- Pain is worse on lying, and patient seek relief by assuming a sitting posture, (imp. point)
- Some times; a hard palpable lump can be felt in epigastric region.
- Hepatomegaly is present in half of the cases.
- A palpable non tender gall bladder in a jaundiced patient suggests neoplastic obstruction of common bile duct (**Courvoisier's law**) most often due to pancreatic cancer. Kindly see fig 31.11 .
- Best prognosis due to early presentation and hence-detection (UP 07)

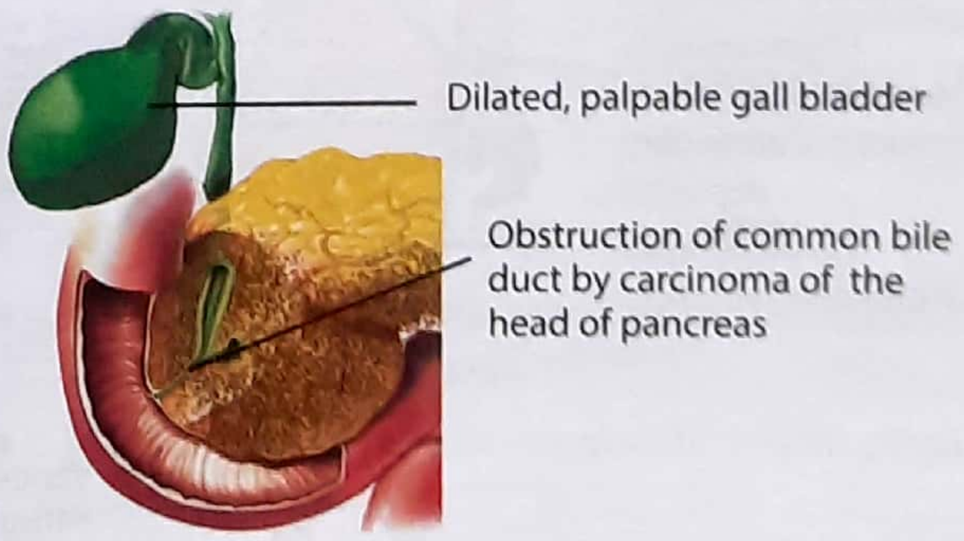

Figure 31.11: Courvoisier's law

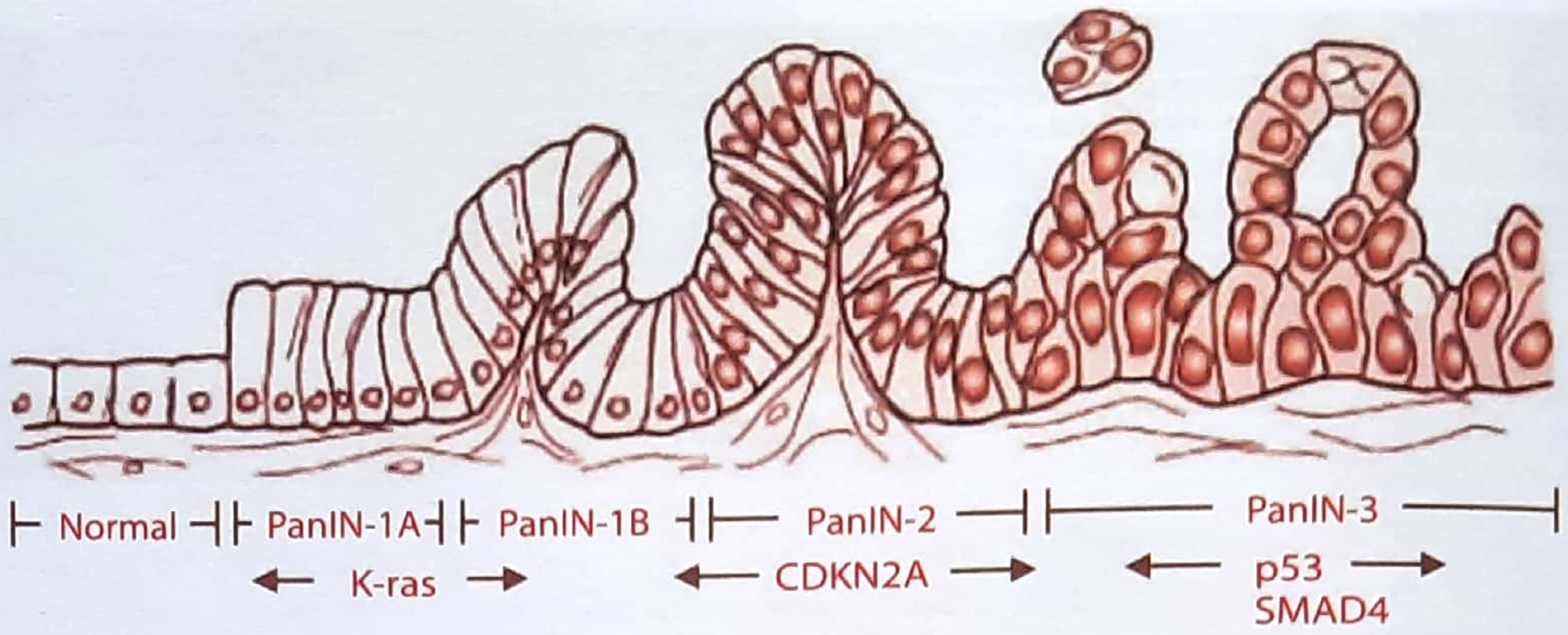

Figure 31.E3: Molecular genetic progression from pancreatic intraepithelial neuroplasia (PanIN) to invasive ductal adenocarcinoma

2. Carcinoma of body and tail of pancreas

- Tumours in pancreatic body and tail are generally larger at the time of diagnosis.
- Since carcinomas of body and tail of pancreas are away from common bile duct, less than 10% of patients are Jaundiced.
- Presenting complaints are weight loss and pain.
- Other symptoms include anorexia, abdominal discomfort and nausea.
- ***Trousseau's sign***: Migratory thrombophlebitis develop in about 10% of cases. This may also occur with gastric carcinoma, lung carcinoma and colon carcinoma. *(PGME)*.

NOTE: Tumours of the Head of pancreas are typically diagnosed earlier, because they cause obstructive Jaundice, and patients seeks medical attention and hence has better prognosis among all pancreatic carcinoma. *(MANY PGME)*

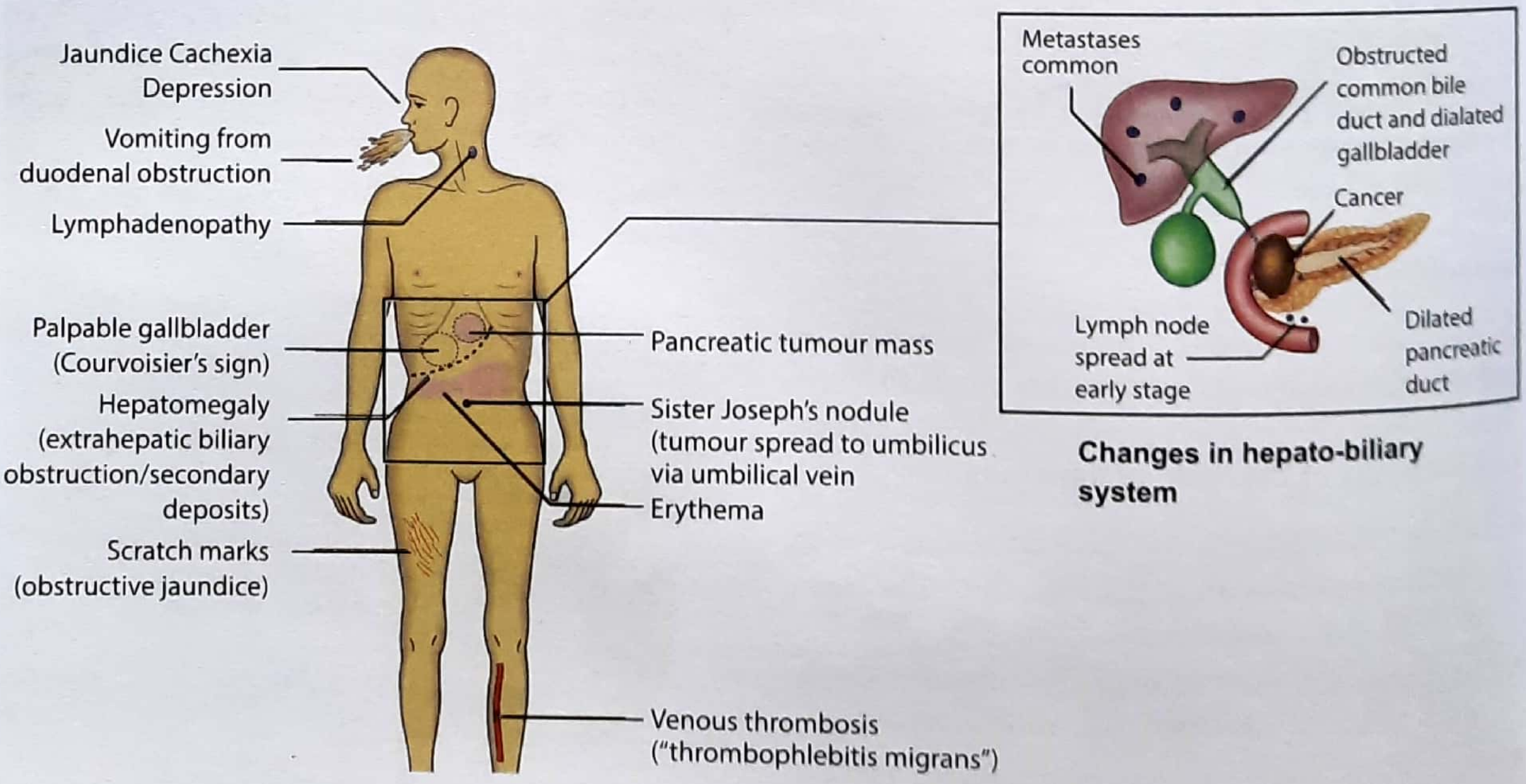

Changes in hepato-biliary system

Figure 31.12: Signs and Symptoms of Ca Pancreas

Trousseau was a French physician, who first described this sign. He him self had carcinoma of pancreas; and ultimately died of carcinoma of pancreas.

Investigation

1. Laboratory studies

- Elevated alkaline phosphate & bilirubin levels reflect either CBD obstruction or hepatic metastases.
- The two most widely used pancreatic cancer serum markers are CEA and Lewis blood group Carbohydrate Antigen CA.19-9. *(PGME)*

2. Imaging studies *(PGI DEC 2000)*

(a) Ultrasound examination

It may reveal a pancreatic mass and indicate whether the mass is solid or cystic. It can also aid in the diagnosis of Jaundiced patient by revealing the presence of extra-hepatic ductal dilatation in the absence of demonstrable biliary tract stone.

USG guided transgastric biopsy is most appropriate method of histological confirmation for carcinoma head of pancreas.

(b) Helical contrast enhanced CT scan:

It has a specificity for diagnosing pancreatic tumours of 95% or better. Its sensitivity depends on size of the tumour exceeding 95% for tumour larger than 2 cm in diameter. It is used to assess resectiblity of Ca pancreas.

KEY BOX 31.7

Presenting Sign & Symptom of Pancreatic Carcinoma

Frequent	Infrequent
• Weight loss (M/C symptom) • Obstructive jaundice (commonly with CA head of pancreas) • Abdominal pain	• Anorexia • Glucose intolerance • Palpable gall bladder • Splenomegaly • Migratory thrombo-phlebitis (Trousseu's sign)

(c) MRI

Although the sensitivity and specificity of MRI appears to equal to CT, however CT is currently more widely employed perhaps because it is cheaper, more user friendly and more easily interpreted by clinician than MRI.

(d) ERCP

It may be particularly helpful in evaluating patients with obstructive jaundice without a detectable mass on CT or MRI. Adjacent lesion of the bile duct and pancreatic duct ***(double duct sign)*** are highly suggestive of neoplastic disease. Necrotic cavity filled with contrast gives - Scrambled egg appearance. *(MANY PGME)*

(e) Barium study

Barium meal and hypotonic duodenography is rarely done these days. *They may show widening of 'C' loop of duodenum and reversed '3' sign in carcinoma of head of pancreas.* *(PGI 97)*

Treatment

(A) For resectable lesions of head

Pylorus preserving pancreaticoduodenectomy (**whipple's operation**) is required. ***This involves resection of*** *(NEET, MANY PGME)*

- **Common bile duct**
- Gallbladder
- Pylorus and distal stomach
- Truncal vagotomy
- **Duodenum** and proximal jejunum
- **Pancreas to the mid body**
- Lymphatics

The restoration of gastro intestinal continuity is achieved by making three anastomosis. Pancreaticojejunostomy, choledochojejunostomy and gastro-jejunostomy (fig. 31.13 and 31.14).

- Must see & understand figure 31.13 & 31.14.
- In modified whipple operation pylorus of stomach is preserved, ie not resected. *(PGME)*
- MC complication of this operation is disruption of gastric anastomosis. *(UPSC 07)*

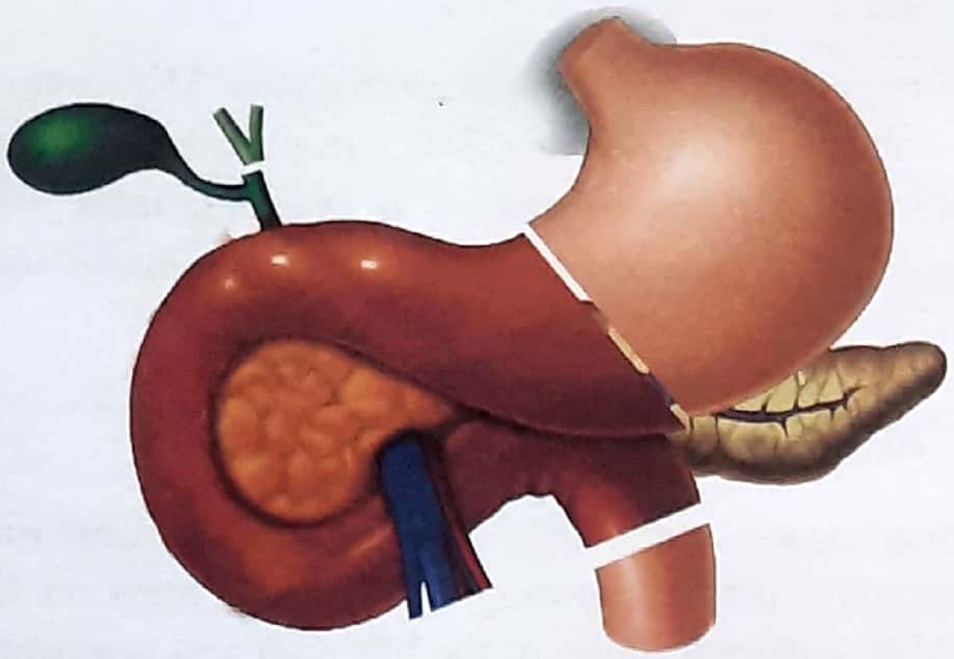

Figure 31.13: Whipple's operation (Note: Dark brown area is resected)

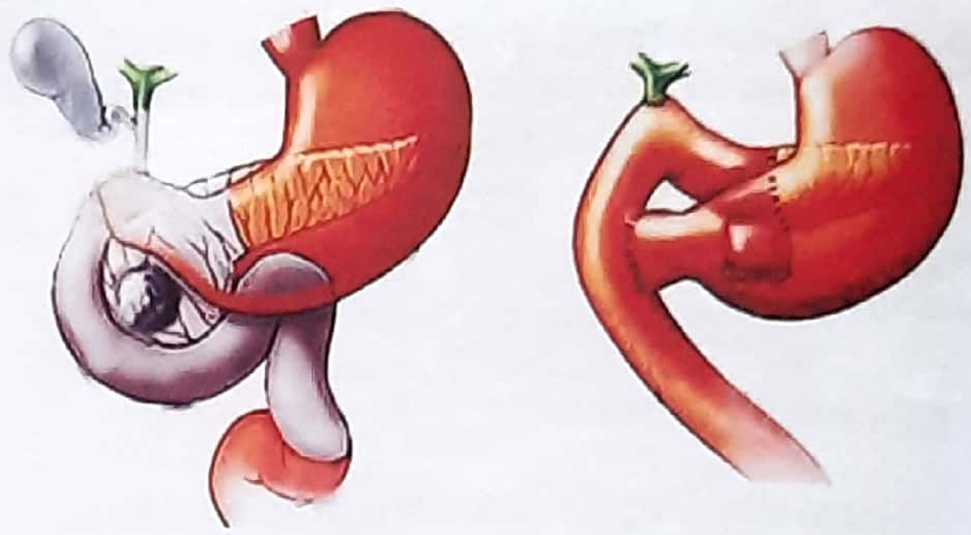

Figure 31.14: Post-operative reconstruction in Whipple's operation, showing pancreatic, biliary and gastric anastomosis. Note: A cholecystectomy and bilateral truncal vagotomy are also part of procedure. Also note; In modified Whipple's operation distal stomach and pylorus is preserved and vagotomy is then unnecessary

NOTE : Total pancreatectomy has no advantage over pancreatico duodenectomy (whipple's operation) for CA head pancreas. Total pancreatectomy produces diabetes mellitus that compromises the quality of life with no higher cure rates.

NOTE: *In modified whipple's procedure distal stomach and pylorus is preserved;* vagotomy then becomes unnecessary.

Contraindication of resection

1. Metastasis
2. Retroperitoneal seedings
3. Involvement of major artery

(B) For resectable lesion of body and tail

Distal pancreatectomy with splenectomy may be undertaken for potentially-resectable cancer of the body and tail of pancreas.

(C) For unresectable lesions

Palliative bypass can be done for unresectabe lesion, ***cholecysto-jejunostomy*** (i.e; anastomosis B/w gall bladder and jejunum) or ***choledocho-jejunostomy*** (anastomosis b/w CBD and jejunum) decreases jaundice and provides relief from pruritus, due to providing biliary drainage in intestine. Former is an easy procedure and is preferred

- Percutaneous or endoscopically (ERCP) placed stents may also provide effective palliation, and are preferred to surgical procedures.
- Unrectable tumor is which shows distant metastasis (vertebrae).

Chemotherapy

Gemcitabine based chemotherapy *(NEET, PGME)* has clear benefits in patients with metastatic disease. Its utility in combination with radiation therapy and as an adjuvant therapy is being defined.

Summary of Clinical trials defining role of adjuvant therapy after resection of pancreatic cancer

TRIAL	CONCLUSIONS
GITSG	Adjuvant chemoradiation with 5-FU and 40-Gy radiation therapy improves survival compared with observation alone.
ESPAC-1	Adjuvant chemotherapy improves survival; chemoradiation is deleterious.
CONKO-001	Adjuvant gemcitabine improves disease-free survival compared with observation
RTOG 97-04	Gemcitabine before and after 5-FU-based chemoradiation provides similar overall survival compared with 5-FU but with significantly less toxicity.
ESPAC-3	Adjuvant chemotherapy alone with gemcitabine provides similar overall survival compared with 5-FU but with significantly less toxicity.
ESPAC-4	Adjuvant combination of gemcitabine and capecitabine is superior to gemcitabine alone.

KEY BOX 31.8	
Differentiating features between carcinoma head of pancreas and periampullary carcinoma	
Periampullary carcinoma	**Carcinoma of head pancreas**
1. Weight toss and pain is less prominent	• Weight loss and pain is more prominent
2. Jaundice occurs early and progress slowly	• Jaundice occurs late but progress rapidly.
3. Stool may contain occult blood due to ulceration of duodenal mucosa by neoplasm	• Stool does not contain occult blood
4. Jaundice may show periodical waxing and waning (fluctuating). This is due to shedding off of some part of the growth, allowing obstructed bile to be excreted into duodenum and icterus is decreased or may even disappear completely.	• Jaundice is progressively increasing [NOTE: The obstructive Jaundice is almost always > l0mg /dl in case of malignancy, while in stone disease (choledocholithiasis) it is usually < 10 mg/dl]

Prognosis

The over all median survival for patients with pancreatic cancer is 20 weeks. Less than 3% of patients will survive for 5 years.

****

PANCREATIC LYMPHOMA

Lymphoma can affect pancreas. The clinical presentation is similar to pancreatic adenocarcinoma with vague abdominal pain, weight loss and jaundice. *It is very important to make definitive diagnosis of pancreatic lymphoma because there is no role of resection in pancreatic lymphoma.* Endoscopic stenting to relieve jaundice followed by chemotherapy is the standard treatment and prognosis is much better than adenocarcinoma of pancreas.

****

PERI-AMPULLARY CARCINOMA

[Periampullary- i.e. around ampulla of vater]

- Carcinoma of the ampulla of vater, distal common bile duct, duodenum and terminal pancreatic duct are *often collectively called* as periampullary carcinoma.
- The clinical features of periampullary carcinoma closely resembles to that with carcinoma of the head of pancreas.
- It may present with pain, weight loss, ***fluctuating obstructive jaundice*** *(AIIMS NOV 15) most important feature* and palpable gall bladder lump.
- The periampullary carcinoma spread far more slowly than pancreatic carcinoma and it is very important to make a definitive diagnosis; because these carcinomas are resectable and cured at the time diagnosis is made.
- *Due to possible curative resection, their prognosis is much better than carcinoma head pancreas, please see box 31.8.*

****

ENDOCRINE TUMOURS OF PANCREAS

1. Insulinoma

- It arises from β (beta) cells of the islets of pancreas and is ***most common*** **endocrine tumour** of the pancreas *(AIIMS JUNE 04, PGI 06)*
- It is *equally distributed through out the head, body and tail of the pancreas*. *(AIIMS JUNE 02, MAHE 05)*
- 90% of insulinomas are solitary and benign.
- Only about 10% *of them are malignant.*

  NOTE: *Other endocrine tumours of pancreas are almost always malignant]*

- About 5% are associated with MEN-I syndrome *(PGME)*

- There is equal sex distribution and can present at any age.
- 2-3% of tumours are ectopic and may be present in duodenal wall, hilum of spleen.
- Average size of the tumour is about 10-15 mm. It is well encapsulated.

Clinical feature

The clinical features of insulinoma is due to increase insulin release causing hypoglycemia. The symptoms of hypoglycemia is precipitated by fasting and patient always use to eat frequently and gains weight. *(AIIMS NOV 95)*. Please see flow chart in key box 31.9.

Diagnosis

Classic diagnostic criteria is **whipple's triad** *(NEET, PGI 97, UPPGME)*, which include:

1. Sign and symptoms of hypoglycemia during fasting
2. Blood glucose level below 50 mg/dl (2.8 mmol/L) during symptomatic episode.
3. Relief of symptoms by intravenous administration of glucose.

72 hours fasting glucose level

- A patient with suspected insulinoma is fasted for 72 hours, till the symptoms of hypoglycemia develop.

KEY BOX 31.9

Insulinoma

↓

Increased insulin release

↓

Hypoglycemia

Cerebral glucose ↓	Increase sympathetic
• Irrational behaviour	• Palpitation
• Memory lapse	• Sweating
• Confusion	• Tremors
• Seizures	• Tachycardia
• Coma	• Nervousness
• Visual disturbance	

- When hypoglycemia develop serum level of insulin is measured. A ratio of plasma insulin to glucose > 0.3 in diagnostic.

Localization of the tumour *(PGME)*

- USG is rarely helpful because the tumour is very small in size (10-15mm), but intra-operative ultrasound may detect most of them during operative procedure.
- Other important methods are:-
  - High resolution CT and MRI (50-60% accuracy)
  - Endoscopic ultrasound examination of pancreas
  - Selective arteriography (up to 90% accuracy)

Treatment

- The definitive treatment is surgical.
- As 90% tumours are benign and encapsulated, they can be enucleated.

NOTE : When enucleation term is used, it means removal of entire mass of tumour (without rupture) with its capsule.

- If metastasis is present, resection of tumour as well as debulking of metastasis is done.

2. Gastrinoma (Zollinger- Ellison Syndrome)

- In 1955, Zollinger and Ellison described a syndrome of severe peptic ulcer disease with hypersecretion of gastric acid and 'G' cell tumour of pancreas. *(AI 94)*

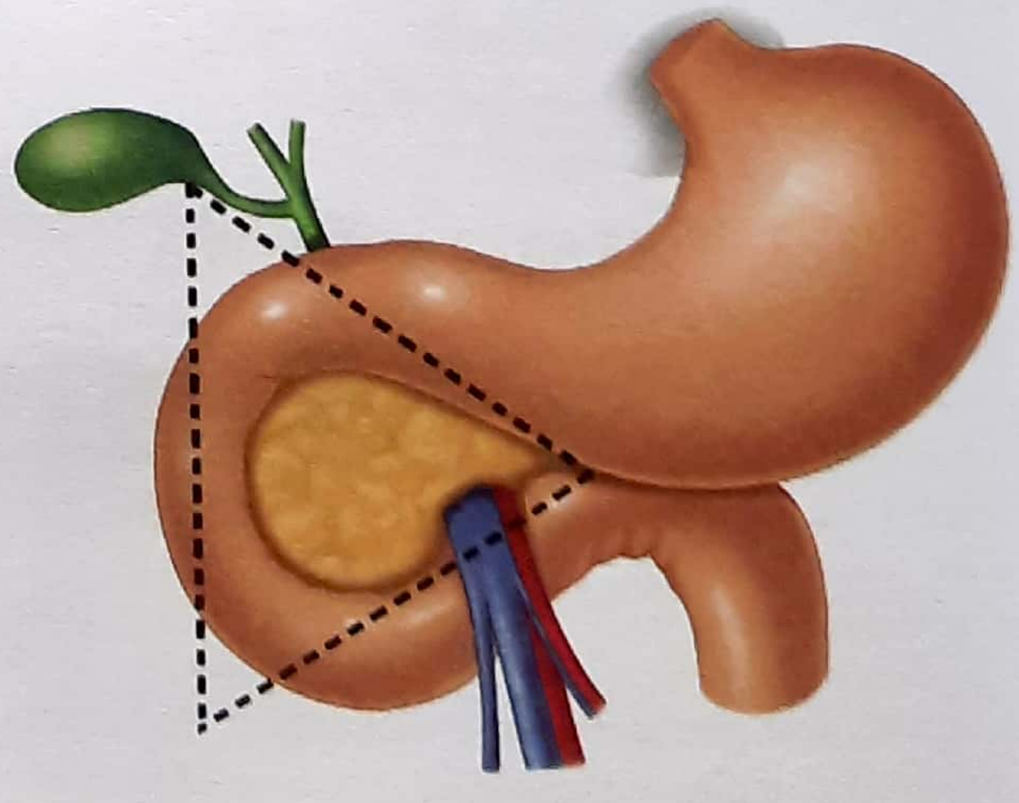

Figure 31.15: Passaro's triangle

KEY BOX 31.10

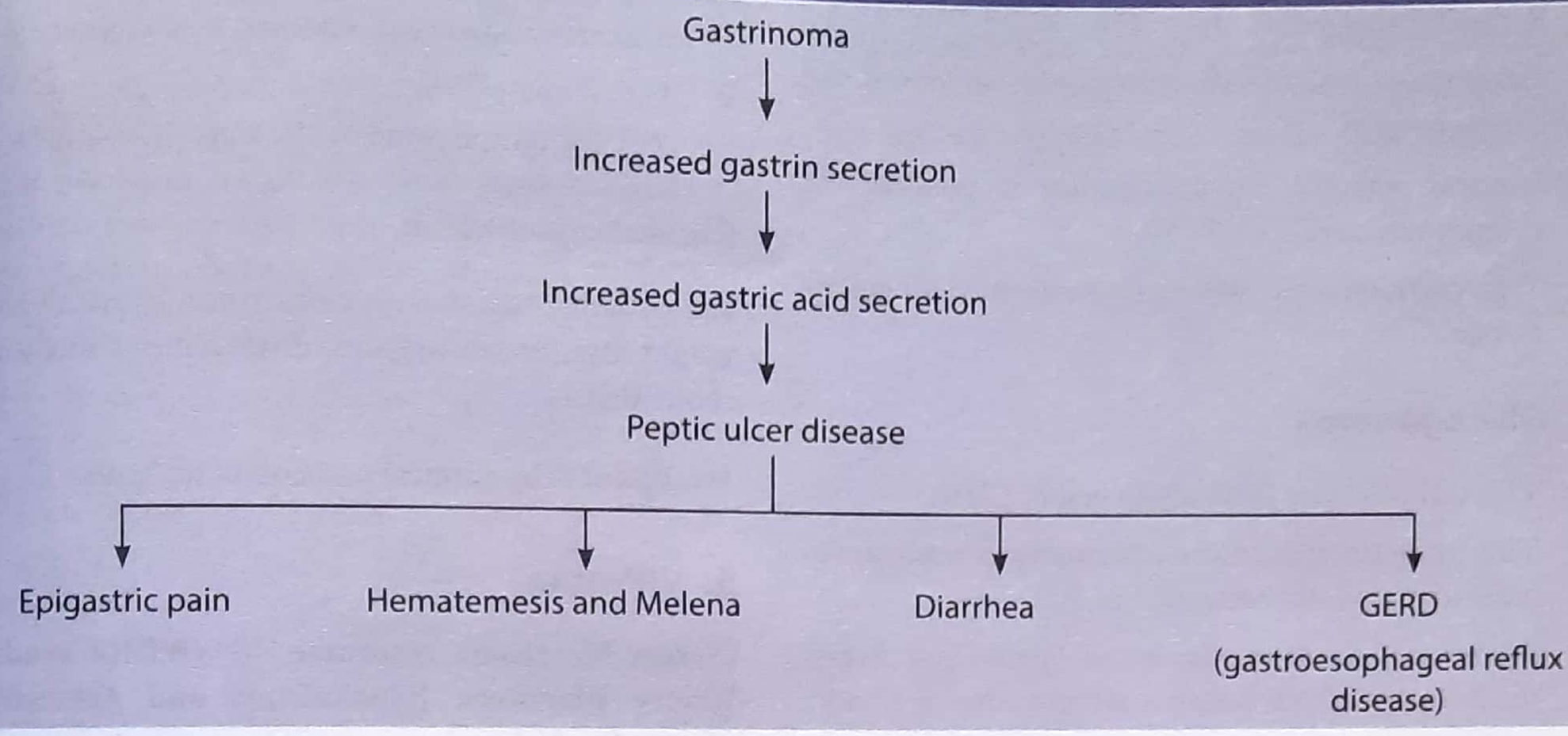

- Although normal pancreas does not contain gastrin producing cell; about 20-40% gastrinoma arise in pancreas. Most common site for gastrinoma is duodenum. *(MANY PGME, COMED 07)*
- About 90% of gastrinomas are found in gastrinoma triangle **(Passaro's triangle).** It's superior point is at the junction of cystic duct and common bile duct, inferior point is at the junction of inferior margin of 2nd and 3rd portion of duodenum and the left lateral point is at the junction of neck and body of pancreas. See figure 31.15.
- **More than 80% gastrinomas are malignant**. *(NEET, PGI 08)*
- 20-25% are solitary adenomas.
- 5-15% are associated with MEN I syndrome.
- Gastrinomas are most common endocrine pancreatic tumour associated with MEN I.
- There is a male preponderance (60%)
- Mean age of presentation is between 50-60 years.
- Most common functional endocrine tumor of pancreas. *(AIIMS MAY 19)*

Clinical Feature

These are mainly due to increased gastric acid secretion. I am giving clinical features in a flow chart for easy understanding.

- Please see flow chart in key box 31.10
- **Diarrhoea** occurs due to malabsorption of fat. Increased acid causes inactivation of pancreatic lipase.
- Clinical suspicion of gastrinoma arises when there is **peptic ulcer disease refractory to normal antiulcer therapy**, with diarrhea and recurrence of ulcer after surgical treatment.

Diagnosis *(PGI JUNE 01)*

1. ***Fasting hypergastrinemia*** *(NEET)* A fasting hypergastrinemia of >200 picogram/ml to 1000 picograms/ml is observed in patients with gastrinoma. (normal level of gastrin 100-150 pgm/ml).
2. ***Increased basal gastric acid output (BAO)*** Almost all patients with ZES has increased BAO ie; about l5 meq/hr. (normal value 5 meq/hr).
3. ***Provocative tests*** *(PGI JUNE 01)*

   Secretin provocative test

   When 2 IU/kg secretin is given through intravenous route, it produces rise is serum gastrin level to 200 pgm/ml within 15 minutes. This is most sensitive and specific test.
4. *Imaging study:* The most promising current method is somatostatin receptor (octreotide) scintrigraphy (because 90% gastrinomas has receptors for somatostatins)

- USG, CT scan and MRI are only partly successful because tumours are often very small.

Treatment

- Reducing acid secretion by PPI
- Octreotide causes decrease in gastrin secretion, and can be helpful.
- Surgical removal, by enucleation is possible for solitary tumours. *(PGI JUNE 08)*
- Total gastrectomy is now rarely performed for gastrinoma.

3. Glucagonoma

- This tumour arise from **alpha cell of islets.**
- This tumours arises more commonly in women. Female to male ratio being (2:1 to 3:1).
- *Majority of glucagonomas are malignant* and metastasize early to liver, lymph node and adrenal gland.
- Most of them are located in body or tail of pancreas.

Clinical feature

Glucagonoma presents as **characteristic skin lesions,** which are initially erythematous patches around mouth, vagina, anus **(imp. point).** Later they spread to involve trunk, extremities and face. The skin lesions are because of hypoaminoacidemia and intravenous amino acid administration clears the skin lesion.

Diagnosis

Elevated levels of fasting glucagon with typical clinical presentation usually confirms the diagnosis. Glucagon level between 200-2000 pgm/ml is found in these cases (normal level < 150 pgm/ml). Localization of the tumour can be done by CT, MRI or angiography.

Treatment

Initially patient is treated by total parenteral nutrition with high dose of amino acid, octreotide for symptomatic relief. Oral Zinc is given for stomatitis.

Definitive treatment is surgical excision of tumour, resection of tumour is done, even if metastasis is present. For *incurable tumours* chemotherapy with streptozocine and decarbazine is used.

4. Somatostatinoma

- These are rare tumours, characterized by steatorrhea, diabetes mellitus, hypochlorhydria and cholelithiasis.
- These tumours arise from delta cell (D cells) of pancreas.
- Tumours are most commonly located in head of the pancreas and are usually large and solitary.
- Mostly malignant and has metastasized to liver and regional lymph node by the time of diagnosis.

Clinical presentation

The patient present with steatorrhea, hypochlorhydria, weight loss, malabsorption, mild diabetes mellitus and cholelithiasis.

Treatment is by surgical excision of tumour.

5. VIP-oma

(Verner Morrison's syndrome *(NEET)***/WDHA syndrome; Watery Diarrhoea Hypokalemia and Achlorhydria/ pancreatic cholera.)**

It **is a non-beta islet cell tumour** of pancreas that secretes VIP (vaso active intestinal polypeptide). Tumours are predominantly solitary and 70% of them are malignant.

Clinical feature

- Patient presents with profuse **watery diarrhea** *(NEET)* (not responding to antidiarrheal agents), weight loss, dehydration, weakness and **flushing**.
- There is severe electrolyte abnormality. **Hypokalemia** occurs due to loss of K^+ ion in stool.
- Metabolic acidosis occurs due to loss of HCO^3 ions in stool.
- **Hypercalcemia** (due to parathormone production by tumours) and **hypoglycemia** (due to altered sensitivity to insulin because of hypokalemia) is often present.
- In 70% cases there is achlorhydria this is due to decreased gastric acid secretion by VIP.
- Stool volume is large. It is about 3-5 liter/day. A stool volume less than 700 ml excludes diagnosis.

Diagnosis

Diagnosis is made by an elevated fasting level of VIP> 150 picogm/ml with typical clinical presentation. CT scan, MRI, selective angiography and intraoperative USG can localize the tumour.

Treatment

Immediate aggressive rehydration with correction of electrolyte and acid base abnormality is essential. Octreotide is used to control diarrhea, either alone or with glucocorticoids; as it inhibits VIP secretion.

The definitive treatment is surgical excision of tumour. Because the tumour is mostly located in body and tail, distal pancreatectomy is done.

6. PPomas

Pancreatic polypeptide (PP)- producing neoplasm are extremely rare. They may present in patients with no clinical symptoms. Some patient may have watery diarrhea and hypokalemia, others have peptic ulcer disease.

****

Sample Questions for Prof Examination

1. Discuss the pathology, clinical features, investigations and the management of acute pancreatitis.
2. Describe the etiopathogensis, clinical features and management of acute pancreatitis.
3. Discuss etiology, symptoms sign's treatment and complications of acute pancreatitis?
4. Discuss the differential diagnosis of severe upper abdominal pain. How shall you manage a case of acute pancreatitis?

32 The Spleen

Contents

- Surgical anatomy
- Physiology
- Functions of spleen
- Rupture of spleen
- Blood disorder treatable by splenectomy
- Splenomegaly and hypersplenism
- Splenectomy
- Tropical splenomegaly

The spleen is dark, purplish in colour, highly vascular, wedge shaped organ situated in left hypochondrium of abdomen; at the level of the eighth to eleventh rib between the fundus of the stomach, the diaphragm, the splenic flexure of colon and the left kidney.

The adult spleen weighs about 150 grams and usually can not be palpated. *Spleen can be palpable only when it is enlarged 2.5 times* (UP 88). Spleen is attached to adjacent viscera, the abdominal wall and the diaphragm by peritoneal folds (also called as ligaments-see box 32.1)

The tail of pancreas is adjacent to splenic hilum. The ***lienorenal ligament*** contains the splenic vessels and ***gastrosplenic ligament*** contains the short gastric vessels and the left gastroepiploic branches of splenic artery. Another ligament ***phrenicocolic ligament*** is not attached to spleen but supports spleen at anterior end. This ligament is usually avascular; but may contain large collateral veins in patients with portal hypertension.

Accessory spleens (Splenunculi) are found in approximately 10-30% of the population. They are *located near the **hilum of spleen in 50% of cases** (M/C site)* (NEET, AIIMS 93, PGI June 95) or behind the tail of pancreas in about 30%, but they can be found through out the peritoneal cavity in the omentum, bowel mesentery and pelvis.

Ordinarily they are of no significance, but may play a role in recurrence of certain hematological disorders for which splenectomy was performed in past. Removal of accessory spleens may lead to remission of disease in these patients.

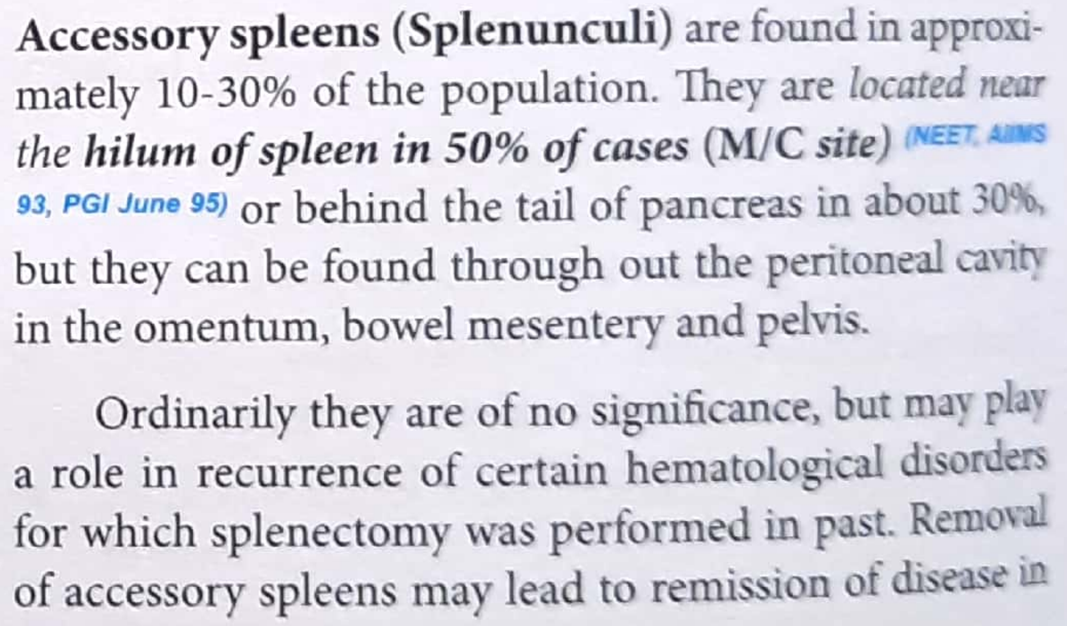

Figure 32.1(a): The spleen

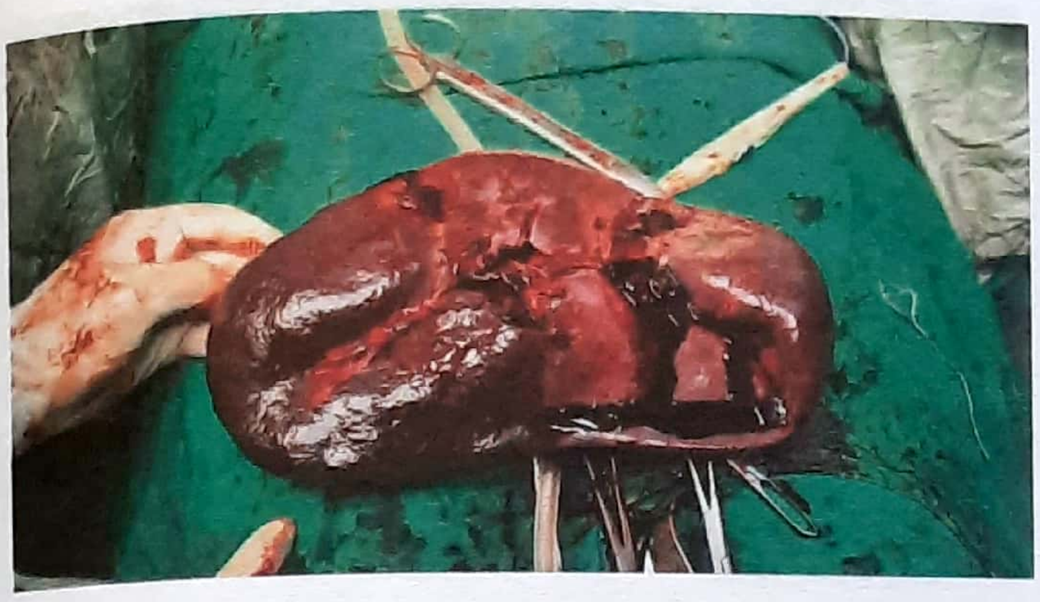

Figure 32.1(b) : Specimen of Spleen

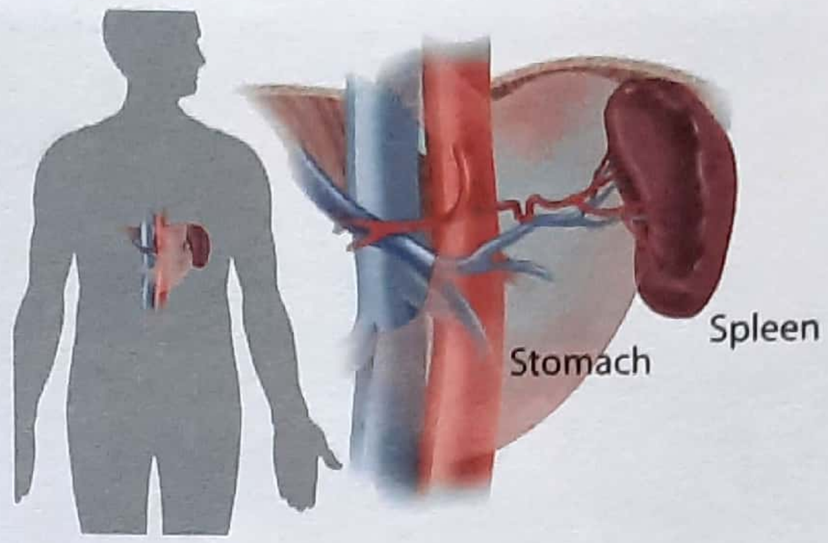

Figure 32.2: Spleen and its relation

Ectopic Spleen (Wandering Spleen)

This is an unusual condition, in which a long splenic pedicle (ligament) allows the spleen to move freely within the abdominal cavity. It often resides in lower abdomen or pelvis. The condition is 13 times more common in female than male.

Absence of spleen is extremely rare condition.

Physiology

The spleen receives about **5% of the total cardiac output or approximately 150-300 ml/minutes (200-300 liters blood daily),** such that each red cell passes through the spleen, roughly 1000 times per day. Approximately 20 ml of red blood cells are removed daily. Normal blood cells pass rapidly through the spleen while abnormal and senescent cells are retarded and entrapped and phagocytosed. In the presence of splenomegaly and other diseased states, the flow pattern of the spleen become more circuitous; as the red pulp volume expands, so that even normal cells may be trapped and phagocytosed.

The white pulp of spleen contains the various cellular components needed to generate immune response, with structural and functional relationship similar to lymph node. More over the concentration of macrophages in the red pulp vascular spaces facilitates Opsonization* of particles, coated with IgG and plays an important role in autoimmune hematological diseases. This also explains the increased risk of sepsis after splenectomy in children under 2 years of age. Even in adult; splenectomy lead to slight but definite reduction in immune system.

Normally about 30% of the total platelet pool is sequestrated in spleen but this can increase to 80% in patients with splenomegaly.

***Opsonization** Opsonization is process by which an opsonin coats foreign antigen (bacteria) making them more susceptible to macrophages and leukocytes, thus increasing phagocytosis of the microorganism.

Opsonins? Complement and antibodies are the two main opsonins.

KEY BOX 32.1(a)
Ligament: The term is used in many situation
1. A band or sheet of strong fibrous connective tissue connecting the articular end of bone (This is what, we were taught in class 12th).
2. A thickened portion or fold of peritoneum or mesentery that support a visceral organ or connects, it to another viscus eg; gastrosplenic ligament.
3. A cord like structure representing the vestigial remains of a fetal blood vessel. eg: *Ligamentum teres* which represent obliterated left umbilical vein. (PGME)

FUNCTIONS OF SPLEEN

The spleen has several major functions:-

1. In early embryonic life the spleen contributes actively in to the production of both, red blood cells and white blood cells which enter the circulation. From 5th months onwards the hemopoietic function of spleen is gradually lost.

2. The spleen recognizes and removes old, deformed or defective platelets and red blood cells.
3. The neutrophils is removed from the circulation with a half life of about 6 hours. Though the role of spleen in the destruction of neutrophils is not clearly known, yet in some hypersplenic conditions there is excess destruction of neutrophils leading to neutropenia.
4. The spleen captures and processes foreign antigens and is major site of production of specific immunoglobulin M (IgM). The non specific opsonins - *tuftsin* and *properdin* are also synthesized in spleen. It enhances phagocytosis and helps to filter particulate matter, microorganisms and cell debris and thus plays an important role in body defence mechanism.
5. Macrophages and histiocytes of the spleen remove bacteria and foreign cells.
6. Abnormal and aged erythrocytes, abnormal granulocytes, normal and abnormal platelets and cellular debris are cleared by the spleen. The abnormal shaped or rigid red cell are destroyed by "culling"*, **"Culling"** (PGI79, JIPMER 80) refers to filtering and phagocytosis of old red blood cells, which have either been damaged or are abnormally shaped or contain abnormal inclusions, such as; **Henze bodies**, **Howel-Jolly** bodies and **siderotic granule**.
7. Spleen also removes certain inclusion by *"pitting"*. Such inclusion may be red cell nuclei or malaria parasite without destroying the red cells.
8. A very important immune function of the spleen is production of specific antibody especially immunoglobulin M (IgM). In person in whom splenectomy has been done, the level of IgM fall and the antibody response to the blood born antigen diminishes.
9. The spleen is a reservoir for red blood cells (RBC), platelets.

****

RUPTURE OF SPLEEN

The spleen is most common abdominal organ to be injured in blunt abdominal trauma. (many PGME)

Mechanism of injury

1. Blunt trauma to abdomen

Automobile accident, bicycle injury, sports injury, fall from height are the most common cause of blunt trauma to abdomen. In blunt trauma other organs besides spleen may be injured of which the liver, the kidney, the chest (rib-fracture), the lungs, the small bowel and large bowel and the stomach are important.

KEY BOX 32.1(b)

Biologic substances removed by the spleen

Normal Subjects
Red blood cell membrane
Red blood cell surface pits and craters
Howell-Jolly bodies
Heinz bodies
Pappenheimer bodies
Acanthocytes
Senescent red blood cells
Particulate antigen
Patients With Disease
Spherocytes (hereditary spherocytosis)
Sickle cells, hemoglobin C cells
Antibody-coated red blood cells
Antibody-coated platelets
Antibody-coated white blood cells

2. Penetrating injuries to abdomen

Gun shot wounds, missile injuries are most common injuries causing penetrating injuries.

3. Iatrogenic trauma

Spleen may be injured during vagotomy operations. Gastrectomy or Nissen's fundoplication for gastroesophageal reflux disease.

4. Spontaneous rupture

Spontaneous rupture of spleen occurs only when spleen is pathological. Such rupture may occur from minor trauma. *The most common cause of spontaneous splenic rupture is malaria* (AIIMS, many PGME).

Other causes of spontaneous rupture of spleen include kala-azar, lymphoma, infectious mononucleosis.

Types of rupture

Splenic rupture can be divided in two types:

1. Acute rupture

This occurs mostly due to blunt trauma and is featured by immediate intra peritoneal bleeding. This can be further divided in two type:

(a) The Usual type

There is initial shock from where the patient recovers by treatment. Fortunately this is much more common.

(b) Hurricane type

The patient succumbs rapidly, giving no chance to initiate proper treatment. These patients often die before they reach hospital.

Figure 32.3(a) : Splenic injury with subcapsular hematoma. Despite only a 1cm capsular tear, this injury demonstrated ongoing hemorrhage.

2. Delayed rupture

In this type; after an interval of a few days or even weeks of injury, sudden intraperitoneal bleeding starts. This delayed rupture is reported in 10-15% of cases of blunt trauma. This may be due to:

(i) Dislodgment of blood clot (hematoma) which was temporarily sealing a small tear of spleen.

(ii) Detachment of omentum, which was plugging a small tear of spleen.

(iii) Ultimate rupture of gradually enlarging hematoma.

Splenic rupture is graded in 5 categories, on the basis of extent of severity of injury. For this kindly see key box 32.2. Just go through it and advised not to waste your time on it at this level.

Clinical feature

1. Some degree of shock due to hypovolemia is always present, which is characterized by tachycardia, low blood pressure and increasing pallor.
2. Local bruising and tenderness in left hypochondrium.
3. Fracture of lower 3-4 rib on left side is also a common finding.
4. Patient usually complains of generalized upper abdominal pain.
5. ***Kehr's sign***: *(AIIMS nov 93, AI 95):* In a case of splenic rupture *pain may be referred to the tip of left shoulder.* This is due to irritation of left lobe of diaphragm, which is supplied by left phrenic nerve. The pain in left shoulder is referred pain.

Investigation

1. **Laboratory findings:** Hematocrit value may be reduced if there is major bleeding. An elevated leucocyte count (15,000-20,000/cc) are usually present.

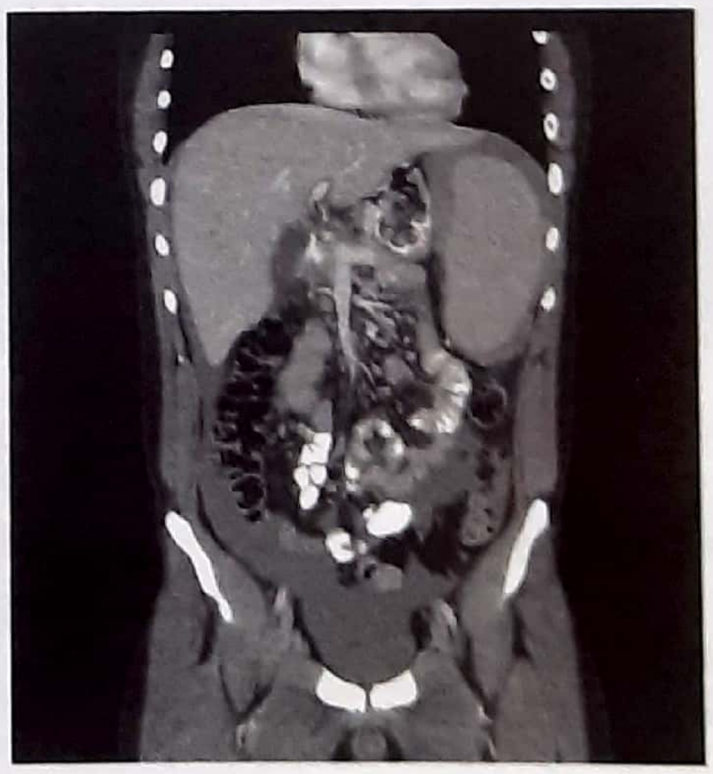

Figure 32.3(b): Radiographic signs of delayed rupture of the spleen: (1). Left diaphragm is raised (2) Stomach is dilated (3) Opacity in the left hypochondrium (4) Indentation of the stomach. (5) Transverse colon displaced (6) Fluid between the coils of intestine

KEY BOX 32.2

AAST Spleen Injury Scale (2018 revision)

Grade	AIS Severity	Imaging Criteria (CT findings)	Operative criteria	Pathologic criteria
I	2	Subcapsular hematoma <10% surface area Parenchymal laceration <1 cm depth Capsular tear	Subcapsular hematoma <10% surface area Parenchymal laceration <1 cm depth Capsular tear	Subcapsular hematoma <10% surface area Parenchymal laceration <1 cm depth Capsular tear
II	2	Subcapsular hematoma 10%-50% surface area Intraparenchymal hematoma <5 cm Parenchymal laceration 1-3 cm	Subcapsular hematoma 10%-50% surface area Intraparenchymal hematoma <5 cm Parenchymal laceration 1-3 cm	Subcapsular hematoma 10%-50% surface area; Intraparenchymal hematoma <5 cm Parenchymal laceration 1-3 cm
III	3	Subcapsular hematoma >50% surface area Ruptured subcapsular or intraparenchymal hematoma ≥5 cm Parenchymal laceration >3 cm depth	Subcapsular hematoma >50% surface area or expanding Ruptured subcapsular or intraparenchymal hematoma ≥5 cm Parenchymal laceration >3 cm depth	Subcapsular hematoma >50% surface area Ruptured subcapsular or intraparenchymal hematoma ≥5 cm Parenchymal laceration >3 cm depth
IV	4	Any injury in the presence of a splenic vascular injury or active bleeding confined within the splenic capsule Parenchymal laceration involving segmental or hilar vessels producing >25% devascularization	Parenchymal laceration involving segmental or hilar vessels producing >25% devascularization	Parenchymal laceration involving segmental or hilar vessels producing >25% devascularization
V	5	Any injury in the presence of a splenic vascular injury with active bleeding extended beyond the spleen into the peritoneum Shattered spleen	Hilar vascular injury, which devascularizes the spleen Shattered spleen	Hilar vascular injury which devascularizes the spleen Shattered spleen

2. **Routine X-ray of the abdomen** *(AI, JIPMER)*. This investigation is extremely helpful, where USG or CT scan is not possible. The probable X-ray finding in a case of splenic rupture are: [Figure 32.3(b)]
   (i) Fracture left lower ribs.
   (ii) An obliterated splenic shadow. *(JIPMER, 86, 87)*
   (iii) Elevated left lobe of diaphragm
   (iv) Obliteration of the psoas shadow on the left side.
   (v) The gastric air bubble may be displaced medially and transverse colon inferiorly.
3. **Ultra Sonography:** This has become the **investigation of choice** in diagnosis of splenic rupture. Ultrasonography will show presence of blood in abdomen. It can also demonstrate splenic enlargement and hematomas in and around the spleen.
4. **CT Scan:** It is the **most accurate method** available for diagnosis of splenic injury, the problem with it is that

it is very costly and a patient with splenic rupture, if hemodynamically unstable, should not be sent for CT scan to radiology department. Transportation of patient may cause dislodgment of hematoma, which may result in massive bleeding.

5. **Splenic angiography:** This is particularly useful in evaluating a delayed rupture.

6. **Isotope Scan:** Technetium-Sulphur colloid scan demonstrate active bleeding and intraparenchymal hematoma.

Treatment

- Treatment starts with treating the shock with rest, sedation, antibiotics, fluid replacement and arrangement of blood for transfusion.
- Laparotomy with or without splenectomy may be necessary in about 75% of cases, while conservative treatment* in 25%.

Selection for Non-Operative (conservative) Management (SNOM)

This should be based on the following criteria:

1. Patient is hemodynamically stable and does not deteriorate during observation.
2. An asymptomatic hematoma identified by imaging, because many of these will resolve.
3. Minimal feature of bleeding, from a lesion that has been identified by imaging.
4. Total blood transfusion requirements do not exceed two units ($2 \times 350 = 700$ ml).

Operative treatment

Of the 75% of patients who are operated, a majority of them have to undergo splenectomy, although the **recent trend is to try and preserve the spleen** by various suturing techniques *(splenorrhaphy) are advised* when feasible.

If the spleen is avulsed or pulped, and if the victim is desperately ill with multiple abdominal injuries or if the emergency surgeon is inexperienced with splenic conservation, then splenectomy is still the right option. Otherwise, the surgeon should attempt to preserve the spleen, particularly in infants and children. Careful technique permits preservation in up to two third of injuries.

Operative mortality for ruptured spleen alone ranges from 5-15%, and when it is associated with other visceral organ injury, mortality rate goes up to 20-40%.

Splenosis? *(PGI 79, AIIMS 85)*

This condition is caused by multiple small implants of splenic tissue on peritoneal surface following traumatic rupture of spleen. It is usually an incidental finding during laparotomy for some unrelated problem. However these splenic implants stimulate formation of adhesion and may be a cause of adhesive intestinal obstruction.

****

BLOOD DISORDERS TREATABLE BY SPLENECTOMY

1. Hereditary spherocytosis

This is the most common cause of congenital hemolytic anemia transmitted as an **autosomal dominant** trait and caused by the *deficiency of spectrin, an important structural protein* of **RBC membrane.** *(many PGME)*

The obvious *abnormality in hereditary spherocytosis is a change in the shape of the red cell* from its normal biconcave shape to spherical shape. These spherocytes become less pliable than normal erythrocytes and it's life span is shortened; with it's destruction occurring in the spleen.

- There is excessive destruction of RBC in the spleen causing splenomegaly and anemia. The rise in unconjugated bilirubin produces acholuric jaundice.
- Periodic exacerbation of hemolysis can occur what is called as hemolytic crisis. This usually follow an acute viral illness and usually associated with severe anemia, headache, abdominal pain and pancytopenia.
- Pigment gallstone occur in about 85% of adults with spherocytosis but are uncommon below the age to 10 years. Every child with gall stone should be investigated for congenital spherocytosis.
- Chronic bilateral leg ulcer is a rare complication and heal only after splenectomy.

Treatment

The erythrocyte membrane defect can not be reversed by any known therapy. *The only treatment available is splenectomy, even when the anemia is fully compensated and patient is asymptomatic* *(PGI)*.

When there is associated gall stone disease; simultaneous cholecystectomy is performed. However splenectomy should be delayed until the age of six years to avoid the risk of post splenectomy sepsis.

2. Hereditary elliptocytosis

Hereditarily elliptocytosis (ovalocytosis) resembles spherocytosis except that the abnormal red cells are oval and the disease is usually less severe. The excessive destruction of these abnormal red cells is spleen causes anemia, mild jaundice and splenomegaly in about 10% of cases.

Symtomatic patient should have splenectomy and cholecystectomy if gall stone disease is present.

3. Thalassemia Major (Cooley's anemia)

The thalassemia are characterized by *decreased rate of synthesis of hemoglobin chains* that are structurally abnormal (**Note:** *above two diseases were due to defect in RBC membrane shape).*

Hemoglobin has four globin chain, namely- alpha, beta, gamma and delta. When there is defect in synthesis of alpha chain, it is known as alpha thalassemia and when there is defect in synthesis of beta chain it is known as beta thalassemia. Other two conditions (gamma and delta thalassemia) are very rare.

Homozygous beta thalassemia is characterized by total or near total absence of synthesis of beta chain, with a marked decrease in the amount of HbA. Gamma chain production then persist into adult life; resulting in persistently elevated HbF level (AI). Delta chain synthesis is also increased to compensate for the absent beta chain causing an increase in HbA; levels (AI).

Clinically homozygous beta thalassemia begins in early child hood with severe anemia, hemolytic jaundice and splenomegaly. Growth retardation and delayed puberty are common features. Gall stones are present in about 25% of patients.

Thalassemia minor (Cooley's trait)

The heterozygous state of beta thalassemia may be asymptomatic or may present clinically with a mild hemolytic process characterized by mild anemia, jaundice and mild splenomegaly. Thalassemia minor do not require treatment.

4. Acquired Auto-immune Hemolytic anemia (AIHA)

The etiology is formation of an antibody produced by the body against its own red blood cells. Binding of these auto antibody to the erythrocytes membrane occur maximally at body temperature (37°C, warm antibodies) or at 40°C (cold antibodies). The warm antibodies are of IgG class [Remember it as G → for Garam], where as cold antibodies are of IgM class.

Based on the presence of "warm" and "cold" antibodies the autoimmune hemolytic anemia is divided in warm autoimmune hemolytic anemia and cold autoimmune hemolytic disease.

This classification is useful since patients with cold antibodies are not benefited by splenectomy. Please read key box 32.3 carefully.

(a) Warm auto-immune hemolytic anemia

The disease, usually affects women over age of 50 years. The onset is usually insidious. Patient may present with anemia, jaundice and fever. A palpable spleen is present in over half of cases.

Corticosteroids represents the mainstay of treatment and are very effective.

KEY BOX 32.3

Autoimmune hemolytic anemia

	Warm antibody induced	Cold antibody induced
Antibody	IgG against Rh antigen	IgM against I antigen
Causes	Idiopathic, drug induced, lymphoma, leukemia	Idiopathic, mycoplasma, mono, Waldenstrom's macroglobulinemia
Comb's Test	+ **IgG** or IgG and C3	- IgG **Only C3 +**
Cold agglutinin	Negative	Positive
Treatment	**Steroid, Splenectomy.** If treatment refractory: immunosuppressive! Cyclophosphamide or Cyclosporin	No Steroid or Splenectomy. Immunosuppressive treatment!! Cyclophosphamide or Chlorambucil

Splenectomy is indicated for patients, who fail to respond to 4-6 weeks of high dose of corticosteroid therapy or those who relapse after an initial response to steroids.

(b) Cold autoimmune hemolytic disease

Cold autoimmune hemolytic disease is a rare cause of hemolysis that occurs mainly in older patient, more commonly in women.

It is caused by an IgM autoantibody. Patients present with cold induced hemolysis or Raynaud's phenomenon.

5. Idiopathic Thrombocytopenic purpura (ITP)

Idiopathic thrombocytopenic purpura is a common disease in which severe reduction of platelet number in blood is caused by immune destruction of platelets. It can occur in two forms :

(a) Acute ITP

Acute ITP is seen mainly in children. In about 50% cases there is a history of viral infection 2-3 weeks back. It is believed that immune complex bind to the surface of platelets; resulting in phagocytosis by splenic macrophages.

Acute ITP is characterized by spontaneous recovery in majority of patients over a period of 6 weeks to 6 months. A short course of steroid therapy may be prescribed. *Splenectomy is contra indicated in acute phase of ITP.* **(many POME, AIIMS, PGI, UP-PG)**

(b) Chronic ITP

Chronic ITP occurs mainly in adults with female to male ratio being 3:1. There is frequent occurrence of relapse during pregnancy. Thrombocytopenia results due to peripheral destruction of platelets that have found an IgG antiplatelet autoantibody on their surface.

The initial attack may be less severe. Splenectomy is indicated in all patients with chronic form of the disease, steroids are given only to provide temporary improvement before surgery.

Clinical features

Patients of either form presents with bleeding tendency. Clinical bleeding occurs when the platelet count fall to very low levels, less than 40,000/ ml (Note: normal level of platelet is 150,000-400,000). Most common clinical feature is purpura*.

KEY BOX 32.4

Features	Acute ITP	Chronic ITP
Peak incidence (age)	2 - 6 years	20 - 40 years
Sex predilection	None	3:1 female : male
Antecedent infection	Common 1-3 weeks before	Unusual
Onset of bleeding	Abrupt	Insidious
Platelet count microliters	<20,000/ microliters	30-80,000/
Eosinophilia/ lymphocytosis	Common	Rare
Duration	2-6 weeks; rarely longer	Months or years
Spontaneous remission	Occurs in 80% of the cases	Uncommon

ITP: Idiopathic thrombocytopenia purpura

Bleeding may also occur from mucosal surfaces, leading to hematuria, melena, and hemoptysis. In about 3% cases intracerebral hemorrhage occurs- a complication associated with a high mortality rate

NOTE: **Purpura:* A condition characterized by hemorrhages in skin, mucous membrane, internal organ and other tissue.

NOTE: In chronic ITP spleen is not enlarged, yet splenectomy is done. In acute phase of ITP splenectomy is not done, (may be future pgme question)

Kindly read key box 32.4

6. Splenectomy for leukemia

Leukemia needs to be considered in differential diagnosis of splenomegaly.

Splenectomy is solely indicated to treat the effects of secondary hypersplenism and to relieve discomfort and pain by a large spleen, eg; CML, GLL and Hairy cell leukaemia.

7. Felty's syndrome

The association of **splenomegaly, rheumatoid arthritis** and **leucopenia** in an elderly patient is known as felty's syndrome. **(many PGME)**

In some patients where rheumatoid arthritis becomes resistant to steroid; the response to steroid may improve after splenectomy.

*****

SPLENOMEGALY AND HYPERSPLENISM

Broadly, **splenomegaly-means enlargement of spleen and hypersplenism means increase in the function of spleen.**

Hypersplenism is a concept, which refers to increased splenic function with peripheral cytopenia and hyperplastic bone marrow with splenic enlargement.

Enlargement of spleen occurs in a variety of conditions which may be medical or surgical. A short list *of surgical causes of splenomegaly* is given below :-

1. Blood Disorders

- Hereditary spherocytosis
- Autoimmune hemolytic anemia
- Idiopathic thrombocytopenic purpura
- Thalassemia major
- Sickle cell anemia (In only early stage of disease)
- Leukemia

2. Infective cause

(a) Bacterial

- Typhoid and Paratyphoid
- Tuberculosis
- Anthrax

(b) Viral

- Infectious mononucleosis

(c) Protozoal and Parasitic

- Malaria
- Schistosomiasis (Egyptian splenomegaly)
- Kala-azar
- Tropical splenomegaly
- Hydatid cyst

Figure. 32.4: Surface marking of massive splenomegaly

3. Neoplastic

- Tumours of the spleen
- Hodgkin's lymphoma
- Non-Hodgkin's lymphoma
- Hairy cell leukemia
- Idiopathic myelofibrosis

4. Circulatory disorders

- Portal hypertension
- Splenic vein thrombosis
- Cirrhosis
- Hypersplenism due to portal hypertension

5. Miscellaneous disease

- Felty's syndrome
- Sarcoidosis
- Gaucher's disease
- Wiskott-Aldrich syndrome
- Porphyria

****

Palpation of spleen is very important as you may get a long case in prof examination (viva)

KEY BOX 32.5		
Differentiation of Left renal Lump and Splenomegaly		
FEATURES	**RENAL LUMP**	**SPLENOMEGALY**
INSPECTION		
• Situation and extent	Loin; upwards and downwards	Left hypochondrium, towards umbilicus
• Loin fullness	Present	Absent
• Movements with respiration	Slightly present	Markedly present
PALPATION		
• Edge	Rounded	Sharp
• Notch	Absent	Present
• Insinuation of fingers between lump & costal margin	Possible	Not possible
PERCUSSION		
• Anteriorly	Resonant	Dull
• Over the renal angle	Dull	Resonant
• Ballottement	Present	Absent (except in huge splenomegaly)

Palpation of Spleen

Normally the spleen is not palpable. A spleen should be more than 2.0-2.5 times its size to become palpable.

Figure 32.5: Method of examination of a renal lump

Method of Palpation

As the spleen enlarges medially and inferiorly towards right iliac fossa, it projects for a varying distance below the left costal margin towards the right iliac fossa. Palpation of the spleen requires elevation of the left lower rib-cage and flank, from behind, by left hand and the abdomen is palpated with the right hand starting in the right iliac fossa (Fig. 32.6). When uncertainty remains as to whether a spleen is palpable or not the patient should be positioned in the right semiprone position as this results in anterior displacement of the organ (Fig. 32.6).

Palpation of the spleen should be carried out *during deep inspiration* because at that time the diaphragm comes down and pushes the spleen downwards, making it more accessible to the tips of the examining fingers. In very enlarged spleens a distinct notch is palpable along the anterior margin. A patient with massive splenomegaly is shown in figure 32.4.

Here, I will also like to describe palpation of renal lump, because it is often difficult to differentiate between a left renal lump and splenomegaly.

Please read key box 32.5 carefully.

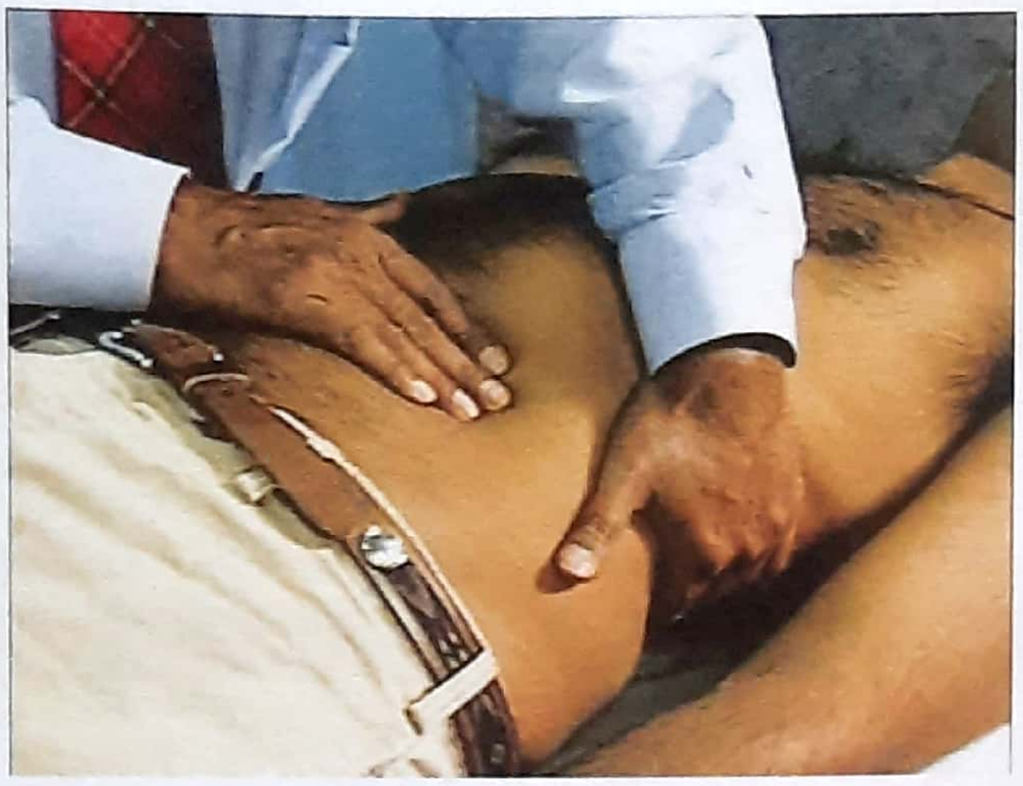

Figure 32.6 Palpation of spleen

(a) Palpation of the spleen requires elevation of the left lower rib cage and flank as the abdomen is palpated with the right hand starting in the right iliac fossa.

(b) When uncertainty remains as to whether a spleen is palpable, the patient should be positioned in the right semi-prone position, because this will result in anterior displacement of the organ.

Examination of Renal Lump

The kidneys are examined by the technique of *bimanual palpation* shown in Figure 32.5. For the right kidney, the left hand is placed beneath the right flank and the right hand is placed anteriorly. The left hand is used to lift the retroperitoneal contents and thereby trap the mass or kidney between the two hands. The kidneys are not palpable in healthy although in thin patients the lower poles may be felt occasionally. On the right side, an enlarged kidney has to be differentiated from a mass in the hepatic flexure or enlarged liver. On the left, the differentiation is between an enlarged spleen and mass in the descending colon.

*****

SPLENECTOMY

Indications (PGI 07)

1. **Traumatic rupture of spleen (M/C)** (NEET)
2. **Hematologic disease** (AI 96, 2000, AIIMS 01)
   - Congenital spherocytosis
   - Acquired autoimmune hemolytic anemia which has not been relieved by steroid
   - Chronic **Idiopathic thrombocytopenic purpura** (In this condition spleen is not enlarged, but it is involved in the excessive platelet destruction)
   - *Note: **In acute** ITP, splenectomy is not indicated.*
   - **Thalassemia major** (NEET)
   - Leukemia
   - **Hereditary spherocytosis** (NEET)
3. **Hodgkin's disease**
4. **Other indications**
   - Aneurysm of splenic artery
   - Tropical splenomegaly
   - Splenic cyst
   - Splenic neoplasm
   - Splenic abscess
   - As a part of the surgical procedure, eg; in operation for carcinoma of stomach and the distal pancreas.

PHYSIOLOGICAL CHANGES AFTER SPLENECTOMY

1. Hematological changes

(a) RBC

The RBC count and indices do not change, but abnormal RBC with nuclear remanent may appear as *Howell Jolly bodies, Heinz bodies and siderocytes.* (many PGME)

(b) Platelets

Platelets are usually increased, (NEET) occasionally markedly so, and may stay at level of 400,000-500,000/μd.

(c) Leukocytes

Leucocytosis with polymorphonuclear predominance occur soon after splenectomy, (NEET) but is replaced by lymphocytosis and monocytosis after several weeks.

(d) Increased coagulability of blood.

2. Changes in bone marrow

Yellow bone marrow of long bone is gradually replaced by red bone marrow over a period of six months.

3. Lymph node enlargement

There may be mild lymphadenopathy due to a compensatory increase in hemopoietic activity.

4. Changes in reticuloendothelial system

The remainder of reticuloendothelial system under goes hypertrophy.

5. Hypertrophy of accessory spleens (if present)

6. OPSI :

[Over whelming Post-Splenectomy Infection]

- Severe infection (especially by **encapsulated bacteria** or parasites) occurring in splenectomised patient.
- This is most common fatal late complication of splenectomy.
- May occur at any time after splenectomy, most cases occur between 2 to 5 years after splenectomy.
- More common in children < 4 yrs and if splenectomy has been done for malignancy or hematological disorders.
- Present initially as mild prodrome of fever, myalgia, malaise, headache, vomiting, diarrhea and abdominal pain which progresses rapidly to fulminant sepsis and death within hours despite antibiotics and intensive care (50 to 70% mortality).
- **Most common organism implicated in OPSI is S. pneumoniae followed by H.influenzoe, N. meningitidis** *(NEET)*
- Patients should be immunized within 2 weeks of splenectomy with
  - Polyvalent **pneumococcal vaccine** *(NEET)*
  - **H. influenze** *(NEET)* type b conjugate, and
  - **Meningococcal** *(NEET)* polysaccharide vaccine.
- Antibiotic prophylaxis is controvesial, when given, is a single daily dose of penicillin or amoxycillin and is recommended for children at risk.
- Splenectomy causes a small (1-5%) but definite risk of fulminant, potentially life threatening infection.
- The most common organism responsible for this are *streptococcus pneumoniae (Pneumococcus 50-90%), Hemophilus influenzae type B. Meningococcus, Babesia and malaria.* *(AI, 2000, AIIMS 99, & many PGME)*
- If elective splenectomy is planned, patient should be vaccinated against Pneumococcus, H. influenzae and meningococcus, two weeks before surgery.
- If spleen is removed in emergency, as in blunt trauma to abdomen, vaccination should be given as soon as possible, lethal sepsis is more common in children below 12 years and is rare in adults.

Complication of Splenectomy *[AIIMS 92, 93, 94, 97]*

(a) Pulmonary

- **Left lower lobe atelectasis* - (M/C complication)**
  - Pleural effusion (commonly on left side)
  - Pneumonitis

Atelectasis: It is a collapsed or air less condition of lung.

(b) Infection

- Subphrenic abscess and hematoma
- OPSI (1-5%)-described above.

(c) Pancreatic complication after splenectomy

- Pancreatitis
- Pseudo pancreatic cyst
- Pancreatic fistula

(d) Thromboembolic

- Disseminated intravascular coagulopathy (DIC)
- DVT
- Portal vein thrombosis
- Axillary vein thrombosis

(e) Stomach related

- Hematemesis, due to mucosal damage of stomach
- Acute gastric dilatation
- Gastric fistula-due to compromise in vascular supply of fundus and greater curvature.

Some author has mentioned OPSI: as Opportunist Post Splenectomy Infection.

AUTO-SPLENECTOMY

This condition is seen with **sickle cell disease.** The splenic changes are very characteristic in sickle cell disease.

The spleen may *be* slightly enlarged in early childhood as a result of reticulo-endothelial hyperplasia. Subsequently, repeated ischemic episodes cause infarction, fibrosis and progressive decrease in splenic substance called- as autosplenectomy (PGME).

In adults with sickle cell disease, the spleen in usually quite shrunken and composed of multiple brown scars containing of hemosiderins called as ***Gamma-Gandy bodies*** (PGME).

*****

TROPICAL SPLENOMEGALY

Tropical splenomegaly is reported in many areas of world, where malaria is endemic. It is as a result of **hyperimmune response** as a result of repeated attack of malarial parasite and is *not accompanied with signs of portal hypertension* -Splenomegaly is associated with high malaria antibody titer. Tropical splenomegaly may also be associated, with kala azar and schistosomiasis.

Clinical feature

Splenomegaly may be present for many years with complains of weakness and asthma. Splenomegaly may also result from occult infection and malnutrition.

- Past history of recurrent fever is almost always present.
- The spleen is large firm and extends into the right iliac fossa across the midline.
- *Malarial spleen is the most common cause of pathological splenic rupture.* (many PGME)

Treatment

- The massive splenomegaly observed in this condition may require removal (splenectomy) especially for those patients disabled by anemia or local symptom due to pressure on adjacent organs.
- Lifetime antimalarial therapy is indicated in malaria endemic areas.
- Congestive splenomegaly - **Causes** -
  - Budd chiari syndrome
  - Portal vein obstruction
  - Hepatic vein obstruction

*****

CYSTS AND TUMOUR OF SPLEEN

- Parasitic cyst are almost always echinococcal. They may be asymptomatic but usually the patient notice splenomegaly. Calcification of the cyst wall may be seen on X-ray. Treatment of choice is splenectomy.
- Other cysts of spleen are dermoid, endothelial and pseudocyst.
- Most *common benign tumour of spleen is hemangioma.* (PGME)
- The other rare primary tumours of spleen include lymphoma, sarcoma and hamartoma.

*****

SPLENIC ABSCESS

Splenic abscesses are very rare. The most common mode of development of an splenic abscess is hematogenous spread of infected organism from another location. *Bacterial endocarditis is the most common source of infection,* other are osteomyelitis, IV drug abuse, immunocompr-omised, polycythemia vera (PV) and sickle cell anemia.

- The clinical presentation is with left hypochondrium pain, fever with chills and rigor and splenomegaly.
- Rupture of a splenic abscess may lead to subphrenic abscess or peritonitis.
- Diagnosis is usually made by ultrasound or CT scan.
- Two thirds of splenic abscess in adult are solitary and remaining one third are multiple. This ratio is reversed in children.

Treatment

The initial approach in treatment of splenic abscess depends on whether it is unilocular or multilocular.

(a) **For Unilocular abscess:** CT guided drainage with antibiotic administration. The success rate of this is about 80-90%.

If patient does not recover by this procedure, splenectomy should be done without delay.

(b) **For multilocular abscess:** They should be treated by splenectomy.

*****

33 Peritoneum, Omentum, Mesentery and Retroperitoneum

Contents

- Peritoneal fold
- Peritonitis
  - Primary
  - Secondary
  - Tertiary Peritonitis
- Special forms of peritonitis
  - Meconium Peritonitis
  - Biliary peritonitis
  - Tuberculous peritonitis Chylous Ascites
- Intra peritoneal peritonitis
  - Pelvic abscess
  - Subphrenic abscess
  - Pneumoperitoneum
- Neoplasm of peritoneum
- Mesenteric tear
- Mesenteric cysts
- Non specific mesenteric lymph adenitis
- Tuberculosis of mesenteric lymph node
- Retroperitoneal fibrosis

THE PERITONEUM

The peritoneum is a thin serous membrane lining the wall of the abdominal and pelvic cavities and clothing (wrapping) the abdominal and pelvic viscera. It can be regarded as a "balloon" into which organs are pressed into, from out side. The *parietal peritoneum lines the inner surface of abdominal and pelvic cavities and the visceral peritoneum covers the organs.* The potential space between the parietal and the visceral layer, which is in effect the inside space of balloon is called peritoneal cavity. The peritoneal cavity normally contain only about 10-50 ml of fluid; which serves as lubricant and allow free movement between viscus.

Between the parietal peritoneum and fascial lining of abdominal and pelvic wall is a layer of connecting tissue called as extraperitoneal tissue.

Peritoneal cavity can be **divided into two parts**; the greater sac and the lesser sac. The **greater sac** is the main compartment of the peritoneal cavity and extends from the diaphragm down into pelvis. The **lesser sac** is smaller and lies behind the stomach.

Greater and lesser sac communicates with each other through an oval window, called the opening of the lesser sac or the *epiploic foramen (foramen of winslow).* (PGME)

The parietal peritoneum is richly supplied with somatic nerves and when irritated causes severe pain (IMP. POINT). The visceral peritoneum, however is poorly supplied with nerves and pain arising from them is vague and mild.

INTRAPERITONEAL AND RETROPERITONEAL RELATIONSHIP

The term intraperitoneal and retroperitoneal are used to describe the relationship of various organs to their peritoneal covering. An organs is called as intraperitoneal; when it is almost totally covered by visceral peritoneum. The stomach, jejunum, ileum and spleen are good examples of intraperitoneal organs. (figure 33.1)

Retroperitoneal organs are those organs that lie between the posterior layer of peritoneum and posterior abdominal wall and are only partially (anteriorly) covered with visceral peritoneum (figure 33.1). The pancreas, the ascending and descending part of the colon, kidney are examples of retroperitoneal organs.

PERITONEAL LIGAMENTS, OMENTUM AND MESENTERIES

Peritoneal ligaments are two layered folds of peritoneum that connect solid organ to the abdominal wall or to other solid organ (note: they do not possess the dense fibrous tissue present in ligaments associated with bone).

Liver for example; is connected to the diaphragm and the anterior abdominal wall by falciform ligament.

Omenta are two layered folds of peritoneum that connect the stomach to another viscus. The **greater omentum** connects the greater curvature of the stomach to transverse colon. It hangs down like an apron in front of the coils of small intestine. See figure 33.2.

The lesser omentum suspends the lesser curvature of the stomach to under surface of liver (fig. 33.3). The gastrosplenic omentum (ligament) connects the stomach to the hilum of spleen.

Mesenteries are two layered folds of peritoneum anchoring small intestine to posterior abdominal wall. The mesenteries of transverse colon and sigmoid colon are called as transverse mesocolon and sigmoid mesocolon.

In the mesentery, the blood supply to intestine is contained together with lymph nodes and visceral nerve fibres. (VERY IMP. POINT)

*****

RECAP: Till now we have discussed peritoneum, peritoneal ligaments, omentum and mesentery. Now lets come to disease part.

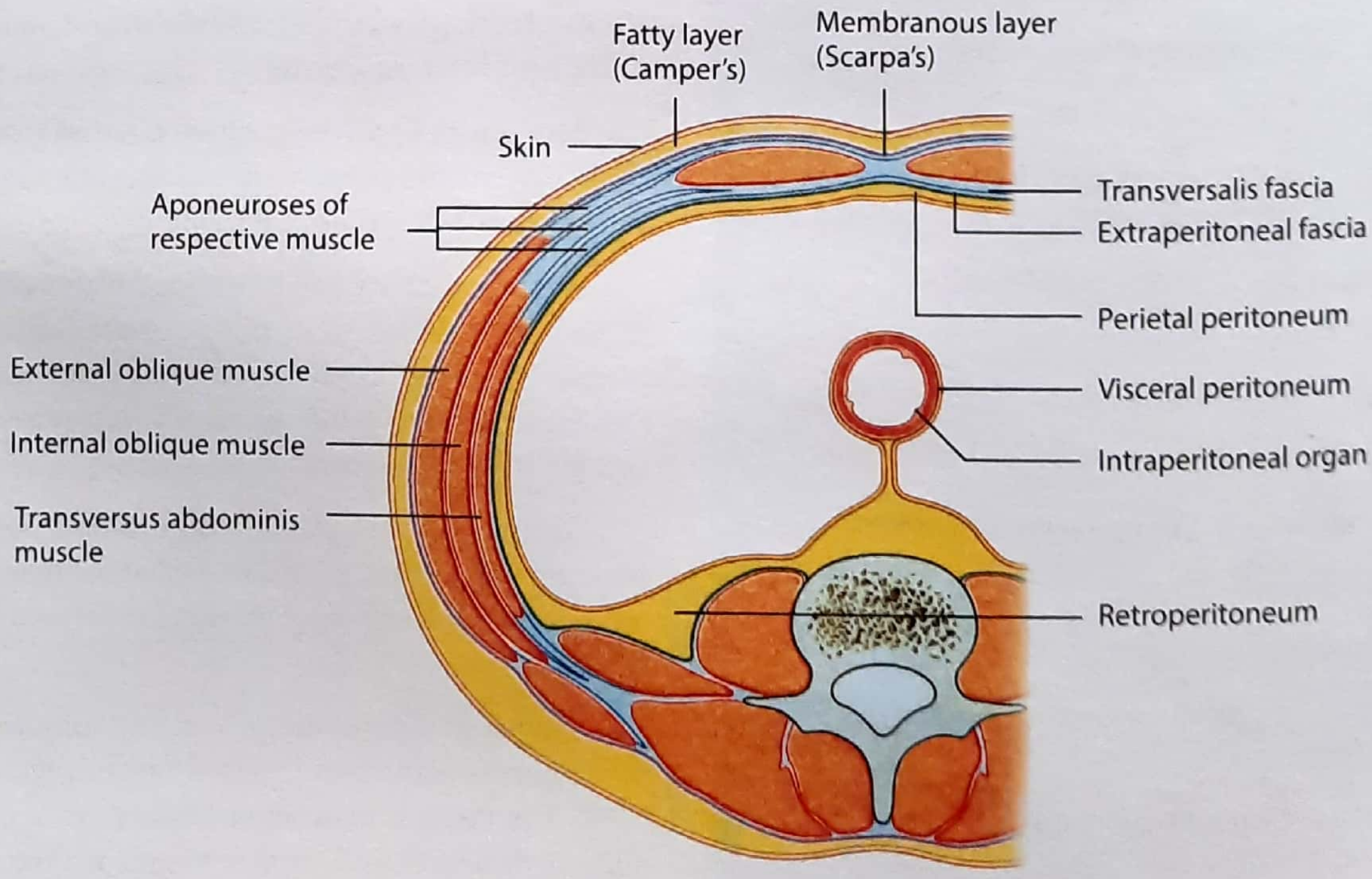

Figure 33.1(a): Transverse section showing the layers of the anterior abdominal wall, note intraperitoneal and retroperitoneum organ

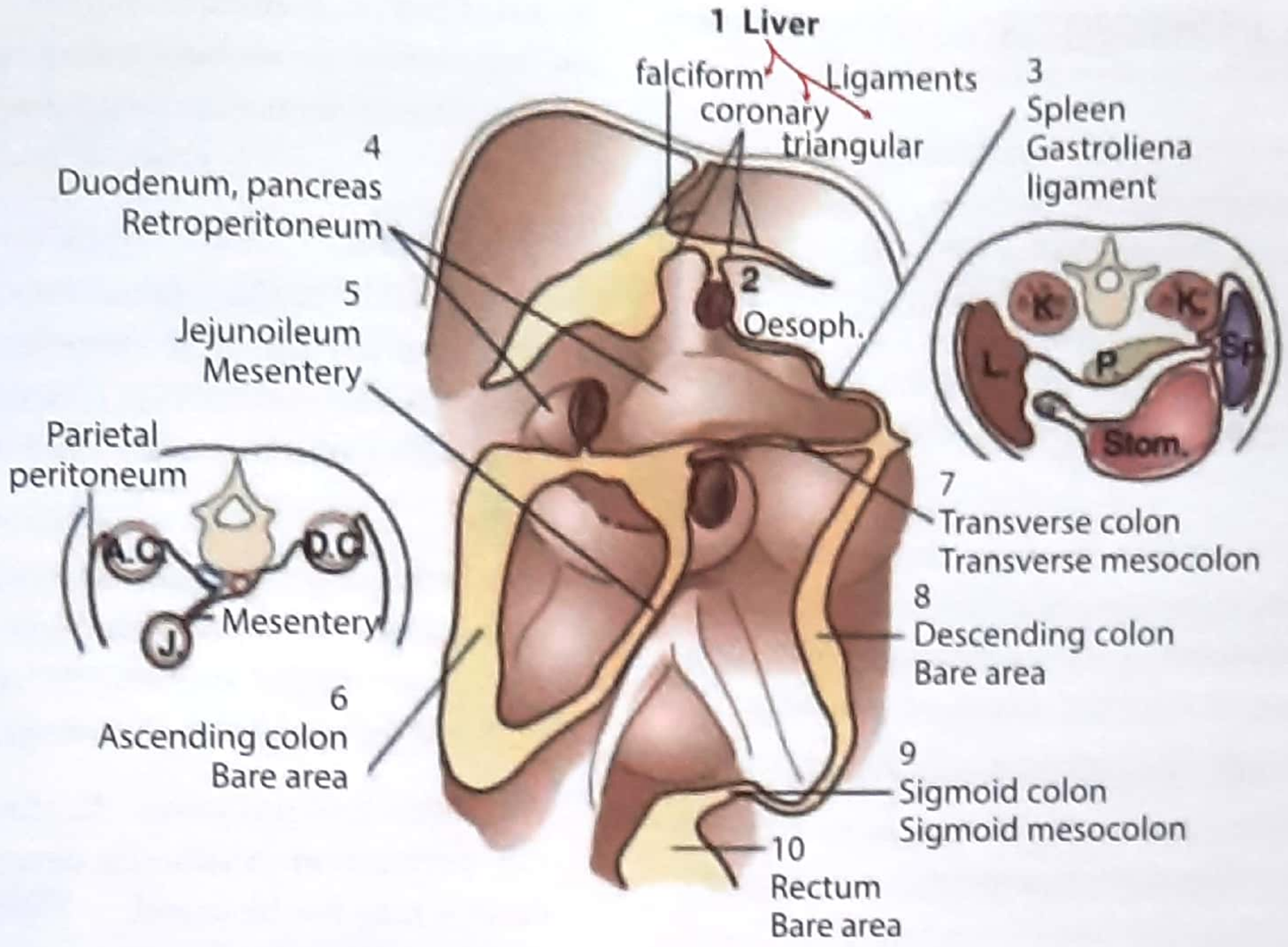

Figure 33.1(b) : Peritoneal ligaments and mesenteric reflections in the adult.

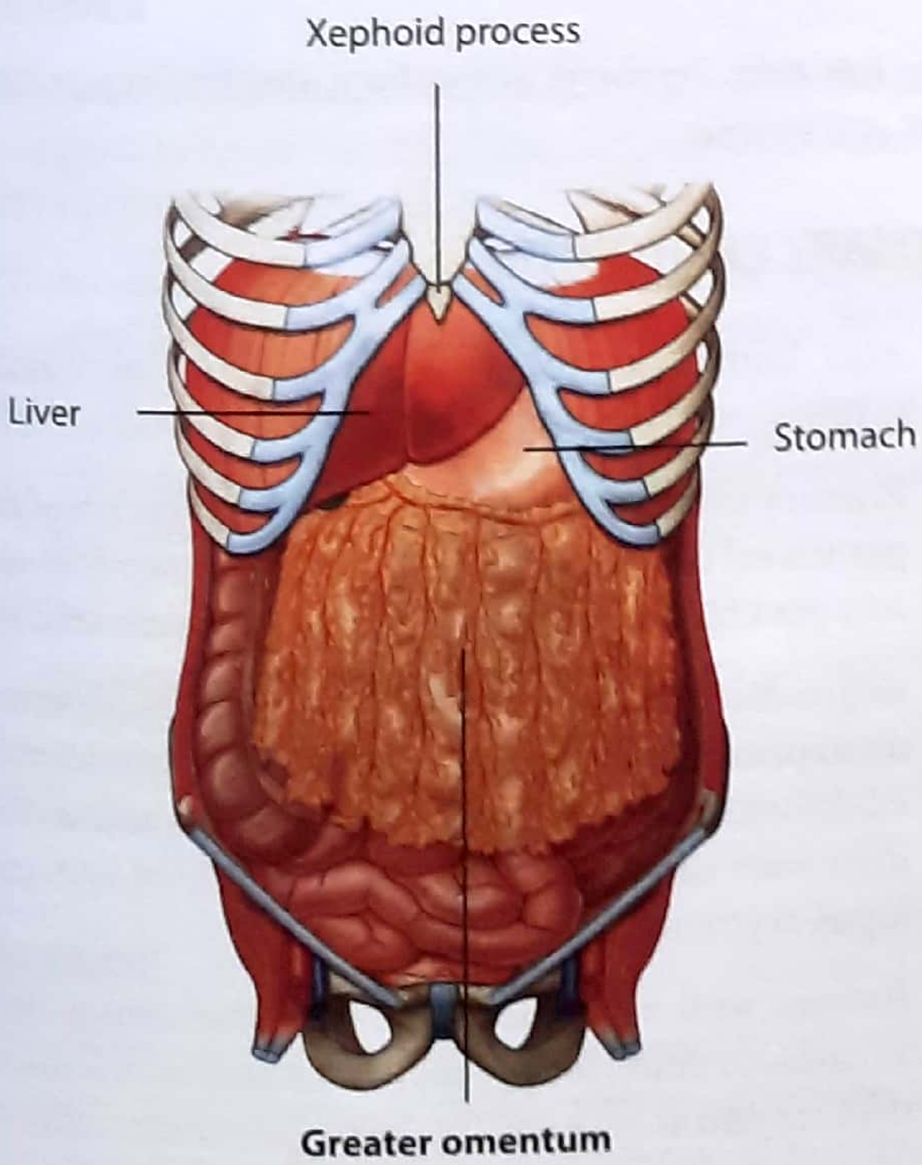

Figure 33.2: Greater Omentum

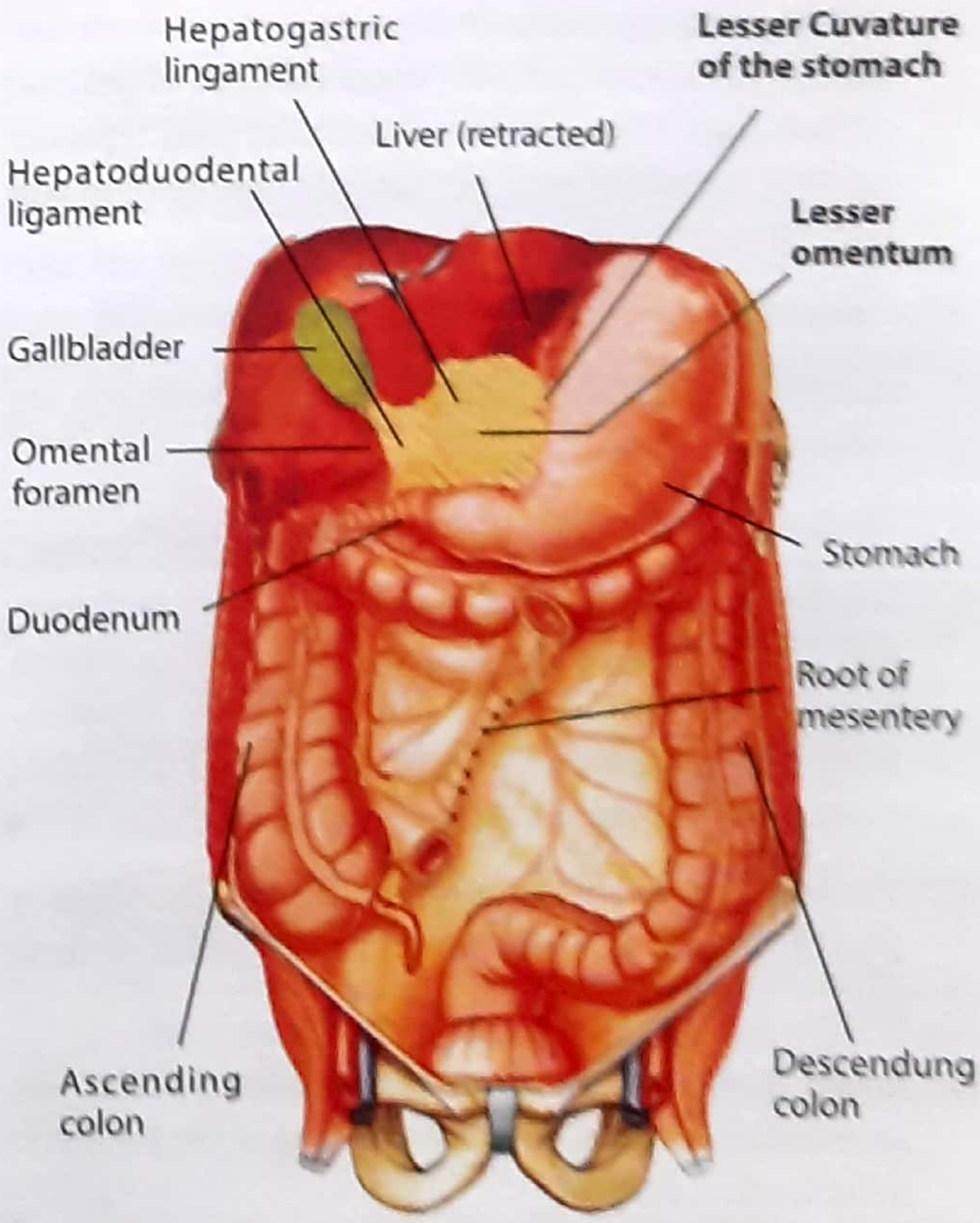

Figure 33.3: Lesser omentum, Root of Mesentery

PERITONITIS

Inflammation of the peritoneum can *be* caused by a number of etiologic agents including bacteria, fungi, viruses, chemical irritants and foreign bodies (like talc). Currently peritonitis is organized into three divisions.

Primary peritonitis refers to inflammation of peritonea] cavity *without* any documented source of contamination.

Secondary peritonitis is the *most common* form of peritonitis and refers to peritoneal infection arising from an intra-abdominal source, usually following perforation of a hollow viscus eg; duodenum, ileum or appendix.

Tertiary peritonitis develops following failure of the treatment of secondary peritonitis & represents either a failure of the host inflammatory response or a superinfection.

Clinical presentation

1. *Abdominal pain* is the predominant presenting symptom. The characteristics of the abdominal pain can vary depending upon the ultimate cause. The pain of fully established peritonitis is constant, burning and *aggravated by motion* and may be localized or diffuse; depending upon the area of parietal peritoneum inflamed. The abdominal pain typically starts at the site of local peritoneal inflammation and later becomes diffused.
2. Anorexia is frequently present.
3. Nausea & vomiting as well as thirst and oliguria are frequently present.
4. Systemic signs include fever and tachycardia.
5. If septic shock is present; patient may have tachycardia, hypotension and warm pink extremities (warm shock). If severe shock is present, severe hypotension, hypothermia and cool and clamy extremities may be seen (cold shock).
6. Patients often prefer to remain still and recumbent in a position that yields minimal exacerbation of their pain.
7. Bowel sound are usually markedly diminished or absent and abdominal distention owing to the paralytic ileus is often present.
8. Abdominal wall rigidity; due to voluntary guarding and reflex muscle spasm are also seen. However with localized peritonitis, tenderness is focal and the remainder of the abdomen may be relatively soft and non-tender. Ileus may be minimal or even absent.

Investigation

- In general; routine laboratory and radiographic studies often add little specific information in the evaluation of peritonitis. Leucocytosis with a predominance of immature neutrophil forms is almost uniformly present.
- *Free intra peritoneal gas under diaphragm* (MANY PGME) is indicative of a perforated viscus, which may be found on upright abdominal, lateral decubitus abdominal or, upright chest radiograph.
- An absence of gas under diaphragm does not rule out perforation peritonitis because on about 20% cases it may not be found.
- In general USG, CT and especially magnetic resonance imaging (MRI) should not be routinely used in patient with acute peritonitis, exclusive of very exceptional situations. Such studies have no role in the evaluation of peritonitis and only contribute unnecessary delay in treatment and unnecessary increase in cost. In comparison, CT and ultrasonography are both extremely useful in the diagnosis of intraperitoneal abscess.

Now lets take Primary, Secondary and tertiary peritonitis one by one:

PRIMARY PERITONITIS

- Also known as spontaneous bacterial peritonitis (SBP).
- Primary peritonitis refers to bacterial infection of the peritoneal cavity originating from an *extra peritoneal site;* possibly by lymphatic or hematogenous seeding.
- Representing approximately 1% of all cases of peritonitis, primary peritonitis most commonly occurs in adults with alcoholic cirrhosis and ascites and in *children with nephrotic syndrome* (JIPMER 88) or systemic lupus erythematosus.
- Patients with ascites secondary to other causes such as cardiac failure, malignancy and autoimmune disorders are also at high risk for developing this condition.
- In children, primary peritonitis is commonly caused by *Streptococcus pneumoniae* (PGME) and is often anteceded by an ear or upper respiratory tract infection.

- The theory of translocation of enteric bacteria is less favored now although **the predominant pathogens in primary peritonitis in *adults* are *coliform bacteria*.** (NEET)
- In females, particularly children; ascending contamination originating from the genitalia and conducted via the fallopian tubes has been implicated as an important route of infection. This may explain the high female: male ratio of primary peritonitis.
- The protein content of the ascitic fluid may influence this risk. *Patients with ascites of a low protein concentration <1 gm /dl are 10 times more likely to develop primary peritonitis than patients with ascitic fluid with a protein concentration > 1 gm/dl.* (MANY PGME)

Clinical presentation

In children, there is a bimodal incidence occurring in neonates and at 3-6 years of age. The onset of symptoms is acute and mimics that of secondary bacterial peritonitis, characterized by fever, vomiting, lethargy, abdominal pain and distension. The presence of bowel sounds is variable. In adults the presentation is more subtle and up to 30% of patients may be asymptomatic.

Diagnosis

In children, the diagnosis of primary peritonitis is rarely made prior to operation. In adults; *diagnostic paracentesis* is the most useful initial study.

(i) An ascitic fluid **neutrophil count of >250 cell/ mm^3 is strongly indicative of peritonitis.** (NEET)

(ii) An elevated neutrophil count and a low ascitic fluid pH may have a specificity of 97% for peritonitis owing to the low bacterial concentration.

(iii) However stain demonstrating a single type of organism is highly suggestive of primary peritonitis.

(iv) Because of low bacteria concentration culture is often negative. Blood culture is positive in 70%.

Treatment

It should be treated aggressively. Adequate drug levels in the ascitic fluid can be achieved by parenteral intravenous administration of antibiotics, intraperitoneal instillation of antibiotics in not necessary. For patients; particularly those with cirrhosis or who require empirical therapy, broad spectrum therapy to cover both gram negative and gram positive bacteria should be selected.

Prognosis

In children successful treatment results in a survival rate of > 90%. Cure rates in excess of 75% can be expected in adults.

SECONDARY PERITONITIS

Secondary peritonitis is the consequence of contamination of peritoneal cavity from an organ within the peritoneal cavity, most commonly after perforation of hollow viscus (perforated appendicitis, perforated duodenal ulcer).

The mortality depends upon the initial cause eg; mortality for limited processes such as perforated duodenal ulcer and perforated appendicitis is usually low, ranging from 0% to 10%. The mortality related to intestinal perforation (ileal) and diseases of the biliary tract is substantially higher; ranging from 20% to 40%. Postoperative peritonitis resulting from a leaking intestinal anastomosis is associated with a substantial mortality, approaching about 30%.

Most common cause of secondary peritonitis is an adult male is perforated appendix (AL 93) and middle aged male is duodenal perforation (AIIMS 92).

Outcome of disease is also influenced by other factors as well. The presence of advanced age, renal, cardiac, hepatic or pulmonary insufficiency, malignancy and diabetes increase the mortality associated with bacterial peritonitis, perhaps as much as three folds.

Clinical feature

- The clinical features of peritonitis are related to the degree of localization of disease. Pain is usually a predominant feature and may be severe and constant.
- If only the visceral peritoneum is involved, pain from fore gut, mid gut and hind gut is referred respectively to the epigastrium, umbilical and supra pubic region where as sub diaphragmatic pain may be referred to the shoulder tip. Once the parietal peritoneum is involved pain and tenderness are localized. Please see figure 33.4.
- There may be diarrhea or constipation in early phases but constipation associated with paralytic ileus is usual in advanced disease.

- ***Peritonism*** is usually present ie; palpation of abdomen demonstrate *involuntary* anterior abdominal voluntary guarding (muscle contraction). The patient complains of local tenderness. Board like rigidity is a features of a perforated peptic ulcer and perforated appendix.
- ***Rebound tenderness:*** ie; deep palpation followed by sudden release of palpating hand will evoke severe pain and is a valuable sign.
- The patient is likely to have pyrexia and tachycardia with low urine output. Respiratory movements are reduced to limit pain from diaphragmatic descent. The patient looks unwell and toxic. Vomiting may or may not be present.
- In the intermediate stages of peritonitis the local and systemic symptoms and signs may improve, but if the infection progresses the patient develops terminal signs. Such as swinging pyrexia, tachycardia, tachypnea, hypotension and oliguria. The patient's face is drawn and anxious (**Hippocratic faces**).
- Paralytic ileus soon ensues and toxemia is accompanied by electrolyte imbalance, renal dysfunction and ultimately multi organ failure (MOF).

Management

It comprises of:

1. Resuscitation
2. Initiation of antibiotic therapy
3. Elimination of the source of bacterial contamination
4. Reduction of the bacterial inoculum and
5. Continued metabolic support.

- In all cases of peritonitis some degree of hypovolemia is present owing to 3rd space fluid loss in peritoneal cavity. The rapidity at which resuscitation is accomplished is dependent upon the degree of hypovolemia and the physiological status of the patient
- The effectiveness of fluid replacement efforts can be judged by the normalization of pulse rate, blood pressure and increase in urine out put.
- Restoration of **urine output** *is a reliable indicator of adequate fluid resuscitation,* (IMP. POINT)
- Supplemental oxygen may be necessary and in more extreme circumstances; endotracheal intubation and mechanical ventilation may be needed to preserve oxygenation.

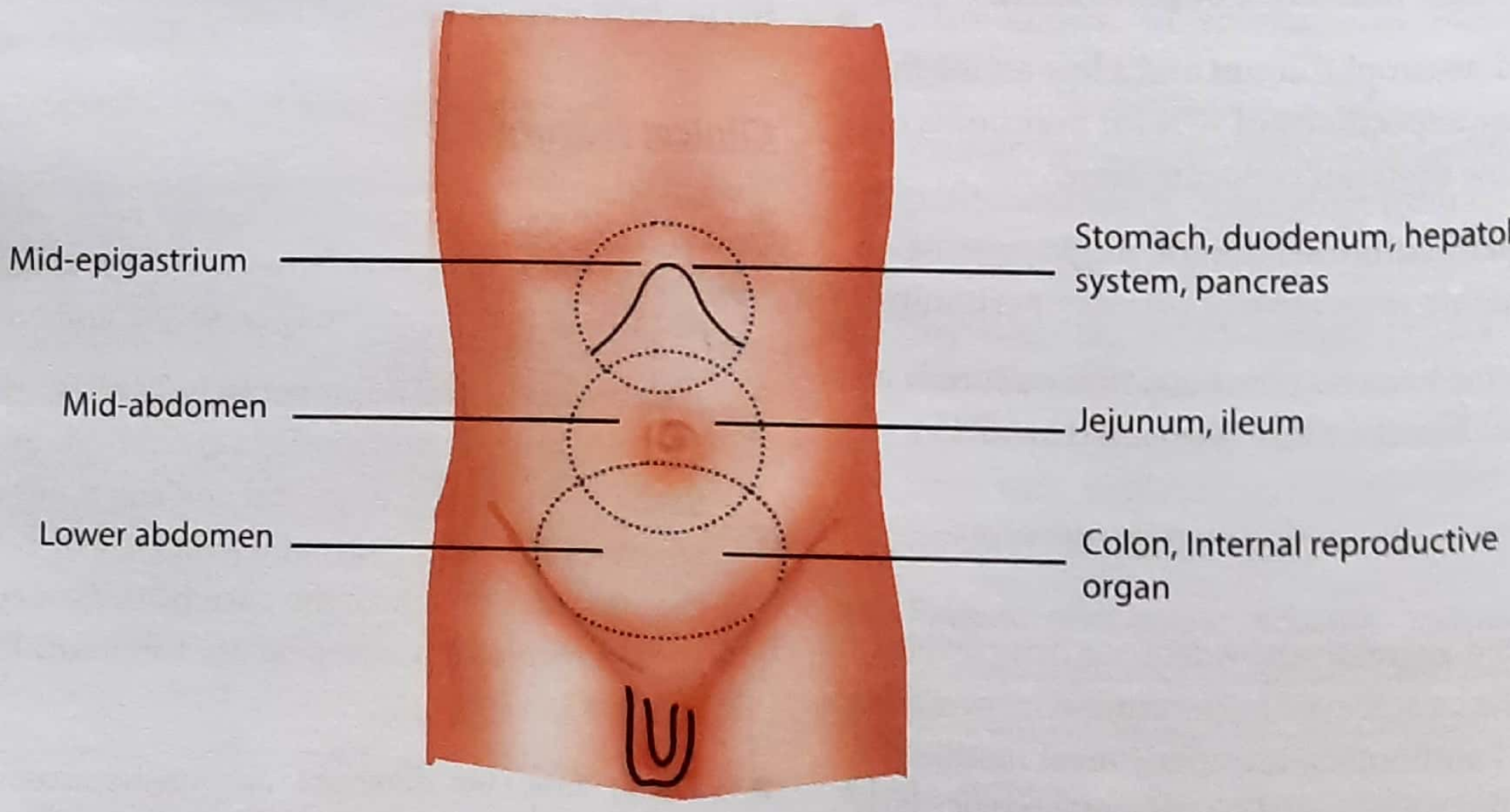

Figure 33.4: Visceral pain site

- Nasogastric decompression (by Ryle's tube aspiration) should be initiated as soon as a clinical diagnosis of peritonitis is obtained. (Ryle's tube: read on page no 432, 436) The microbial contamination of the peritoneal cavity depends upon the portion of the gastrointestinal tract involved.
- Perforations of the esophagus usually involve gram positive cocci & anaerobes, reflective of oral microflora. Perforations of the stomach and duodenum usually result in chemical peritonitis owing to acid injury rather than from bacterial infection. However secondary infection later occurs. The number of bacteria per gram of intraluminal contents in the colon varies from 10^7 in the cecum to 10^{12} in the rectum with an anaerobe to aerobe ratio of 100:1, therefore perforations of the small intestine (distal small intestine) or colon result in massive polymicrobial contamination.
- The majority of patients have mixed aerobic & anaerobic with E *coli* & *Bacteroides fragilis* being the most common combination (TN 01, AI06). Presumptive therapy should include coverage for both aerobic gram negative rods and anaerobic organisms.

Surgical Management

In secondary peritonitis, surgical control of the infecting organ (perforated organ) is the mainstay of treatment. Operative management is directed towards the control of the source of contamination. This can be accomplished by closure of the perforation or resection of the perforated viscus followed by anastomosis between healthy ends.

The secondary goal of operative management is to reduce the bacterial inoculum. This can be achieved by swabbing and debriding fibrin, blood and necrotic material and copious irrigation (wash) of the peritoneal cavity with Normal saline (or RL) solution. The addition of antibiotics or antiseptic agents to the irrigant solution has not been shown to decrease the mortality due the intraperitoneal infection, although it may decrease the incidence of wound infections.

Continuous postoperative lavage has received renewed interest. This technique involves the placement of multiple catheter or drains at the time of operation. In the immediate postoperative period, lavage is begun by instilling large volumes of crystalloid solutions (>2L) containing a mixture of antibiotics and heparin. Lavage is conducted on 3 hour cycles for a period of 48 to 72 hours. The incidence of postoperative abscess formation and mortality can be reduced.

TERTIARY PERITONITIS

- *It refers to a persistent diffuse peritonitis usually following the initial treatment of secondary peritonitis. It represent both a failure of host responses and superinfection.*
- The clinical presentation is characterized by low grade . fever, leukocytosis, elevated cardiac output and low systemic vascular resistance.
- The general metabolism is elevated and these patients are in catabolic state.
- In spite of the indications of occult sepsis, both CT scan and laparotomy often fail to identify a focal source of infection. Instead a frequent finding is a diffuse peritoneal infection with a dispersion of fibrinous material over peritoneal surfaces.
- If superinfection is present, culture data yields two distinct categories of microorganisms (1) infection with highly virulent gram negative aerobic bacteria such as *Pseudomonas* and *Serratia* species with antibiotic resistance characteristics and (2) infection with low virulence organisms such as *Staphylococcus epidermidis, Enterococcus* and *Candida* species, which are resistant to the initial antibiotic therapy.
- Treatment of highly resistant bacteria is based upon sensitivity information. In the absence of a focal site of infection such as an intraperitoneal abscess, operative management has minor role in the treatment of this entity.

*****

SPECIAL FORMS OF PERITONITIS

1. MECONIUM PERITONITIS

Meconium is a sterile mixture of epithelial cells, mucin, salts, fats and bile and is formed when the fetus starts swallowing amniotic fluid. Meconium peritonitis *develops late in intrauterine life or during or just after delivery* (PGI JUNE 1999) when meconium which is **sterile:** enters the peritoneal cavity through an intestinal perforation and causes chemical reaction* as exudates are secreted in peritoneal cavity (ie; chemical peritonitis) that organize itself rapidly and matting of intestinal loops occurs and in matter of weeks the extruded meconium becomes calcified.

Meconium remains sterile until about 3 days after birth. After that acute bacterial peritonitis takes place due to secondary bacterial infection.

Clinical feature

Meconium peritonitis should always be considered, when a child is born with a tense abdomen with vomiting and *failure to excrete meconium even after 24 hours of birth.* (MANY PGME)

Radiography

Free air in peritoneal cavity *(snow storm appearance)*, and large quantity of fluid levels and **calcification** *often more distinct on the surface of liver or the spleen* are characteristic finding. (KAR 95, UPSC 2000)

Treatment

The prognosis is poor however infants particularly with no associated congenital anomalies can be salvaged by closure of intestinal perforation and drainage of peritoneal cavity. Prognosis of this condition is not very good.

2. BILIARY PERITONITIS

Biliary peritonitis usually follows the slippage of a clip or ligature on the cystic duct applied during cholecystectomy. Occasionally; an accessory bile duct is divided during cholecystectomy and cause biliary peritonitis. Another common cause of bile leakage is from choledochotomy after removal of T tube. Perforation of gall bladder following an empyema or rupture are rare causes.

Clinical symptoms are mild, low grade fever, tachycardia, Ileus, Jaundice would provide clues to diagnosis, which is confirmed by USG/CT scan. Early surgical intervention will prevent the septic complication of this disease.

3. TUBERCULOUS PERITONITIS

The incidence of tuberculous peritonitis has declined over the past decade. This is now a rare disease but is still very common in India. It usually occurs in patients who are malnourished or have cirrhosis.

In majority of cases; it is due to secondary involvement and there is some primary focus elsewhere in the body, though sometimes the primary focus remains obscure in about more than 30%. It is later demonstrated to be in the lung. The various possible sites of primary are:

(i) Pulmonary tuberculosis
(ii) Tuberculosis of mesenteric lymph node
(iii) Tuberculosis of ileocecal region
(iv) Tuberculosis of kidney
(v) Tuberculosis of salpinx

Majority of cases are due to reactivation of latent peritoneal tuberculosis which are developed by hematogenous spread from a pulmonary focus.

A. Acute tubercular peritonitis

Some times tuberculous peritonitis presents as acute peritonitis and often the abdomen is opened. Straw coloured fluid with tubercles scattered throughout the peritoneum and greater omentum is usual finding inside the abdomen. Immediately the fluid is evacuated and a small portion of omentum is resected and sent for histopathological examination. The abdomen is closed *without drainage.*

B. Chronic tubercular peritonitis

This is more common form of presentation. The onset is insidious presenting with fever, weight loss, anorexia and weakness. Young adults and female are usually affected. **Four forms of tuberculous peritonitis are described.**

1. Ascitic form

Patient presents with moderate ascitic with abdominal discomfort, vomiting, evening rise in fever, weight loss and anorexia. Occasionally one can feel a transverse solid mass in the upper abdomen; which is nothing but a mass of **rolled up omentum infiltrated with tubercles.** (NEET) Tubercles stud the peritoneum, Shifting dullness and umbilical hernia may be present.

- Ultrasound and CT scan confirm the ascites.
- The fluid is straw coloured, clear and rich in lymphocytes with a high specific gravity (often 1.020 or more). .
- Mycobacterium tuberculosis can be cultured from aspirated ascitic fluid.
- *Laparoscopy and laparoscopic biopsy confirms the diagnosis.*

2. Encysted form

Encysted form is similar to the above but in this form only one localized part of abdominal cavity is affected, thus a localized intra-abdominal swelling is produced. When the swelling is in the pelvis; an ovarian cyst is often wrongly diagnosed. (IMP. POINT)

3. Fibrous form (Adhesive form)

This is characterized by fibrinous deposits in the abdomen, *which cause adhesions between the coil of intestine,* particularly in ileum, as a result of which there is abdominal pain and distension. These patients may develop an adhesive intestinal obstruction. Antituberculous therapy (ATT) will often cure the condition, but surgery may be required for established obstruction.

4. Purulent form

It is rare form. When it occurs, it is usually secondary to tuberculous salpingitis. It is characterized by formation of caseous pus (cheese like pus) and is localized as multiple cold abscess. In due course, these abscess may rupture spontaneously externally on the abdominal wall or internally into intestine. Once this stage is reached; the prognosis is poor.

Usually general treatment of tuberculosis is enough ***The Peritoneum*** to cure this condition though occasionally surgery may be required to evacuate cold abscess.

On the whole tuberculous peritonitis is no more a dangerous condition due to advent of proper antitubercular drugs. Usually after 9 month of antituberculous treatment the patient become asymptomatic. Tuberculous peritonitis often heal with formation of dense adhesion, causing future intestinal obstruction; which may require laparotomy and adhesionolysis.

*****

INTRAPERITONEAL ABSCESS

Intraperitoneal abscesses may occur in virtually any location with in the peritoneal cavity, even within abdominal viscera. The most common mechanisms by which they develop are:

1. Residual loculations following diffuse peritonitis
2. Infection of an intraperitoneal fluid collection following laparotomy.
3. Leakage from a spontaneous visceral perforation or failed intestinal anastomosis.

Visceral abscesses commonly develop from the hematogenous or lymphatic seeding of solid organs; such as the liver, spleen or pancreas. The mortality of intraperitoneal abscesses treated without drainage is 100%.

The common sites for intraperitoneal abscess have been shown in figure 33.5 and 33.6.

Among them pelvic (m/c site) and subphrenic spaces are common sites. See figure 33.5 and 33.6.

PELVIC ABSCESS

The pelvis is the most common site of an intraperitoneal abscess (JIMPER 86, 97). Pelvic abscess often follows a ruptured appendix, infected fallopian tube, ruptured colonic diverticula or as squeal to a diffused peritonitis and anastomotic leakage following bowel surgery.

Clinical Feature

Pus may accumulate in pelvic cavity without serious constitutional disturbance. Patient usually complains of poorly localized, dull lower abdominal pain. **Most characteristic symptom of pelvic abscess are diarrhea and passage of mucus in stool** (UP 07). Some patients may also complain of urgency and frequency of micturitions. Diarrhea and urgency (and frequency) are due to irritation of rectum and urinary bladder respectively by the abscess. A large pelvic abscess may cause intestinal obstruction by compressing bowel loops.

Examination

Unless the pelvic abscess involves the anterior abdominal wall and attains a large size no physical sign will be present on examination of the abdomen. However the abscess usually can be felt directly by rectal or vaginal examination, (figure 33.7).

The typical pelvic abscess bulges as a tender mass into the anterior rectal wall. This is usually soft cystic. In a women the swelling which is soft and cystic can be palpated in the posterior fornix on vaginal examination.

Treatment

As abscess any where in body, the pus should be drained by incision either *through the rectum (in males) or through vagina (posterior colpotomy in females)* (UPSC 87, 88, DELHI 96, AP

98). Please see figure 33.6. Rarely transperitoneal exploration (laparotomy) is indicated, if previous drainage attempts have been unsuccessful.

SUBPHRENIC ABSCESS

There are seven subphrenic spaces, in which pus may get collected. Four of them are intaperitoneal spaces and three of them are extraperitoneal spaces. Three of these spaces are on left side of body and three on right side of body and one is approximately in mid line. See key box 33.1 & figure 33.10.

KEY BOX 33.1	
Intraperitoneal	**Extraperitoneal**
1. Left superior anterior (left subphrenic space)	1. Right extraperitoneal space
2. Left inferior posterior (left subhepatic space)	2. Left extraperitoneal space
3. Right superior anterior (right subphrenic space)	3. Mid line extraperitoneal space
4. Right inferior posterior (Right inferior posterior) [m/c site] (UP 06)	

Clinical Features

- The symptoms and signs of subphrenic infection are frequently nonspecific. It is said pus somewhere, pus no where detected, that means under the diaphragm.
- Patient with subphrenic abscess may present with vague upper quadrant pain or referred shoulder pain and hiccups.
- A swinging pyrexia is usually present.
- If the abscess is placed anteriorly, abdominal examination will reveal some tenderness and rigidity or even a palpable lump.
- Examination of chest is important and in most of the cases collapse of the lung or evidence of pleural effusion or empyema is found.

Diagnosis

- Blood count usually show a leucocytosis.
- Physical examination and plain radiography appear to have limited value in both detecting and locating an inraperitoneal abscesses. *Ultrasonography and CT are mainstay of the diagnosis.* (PGME)

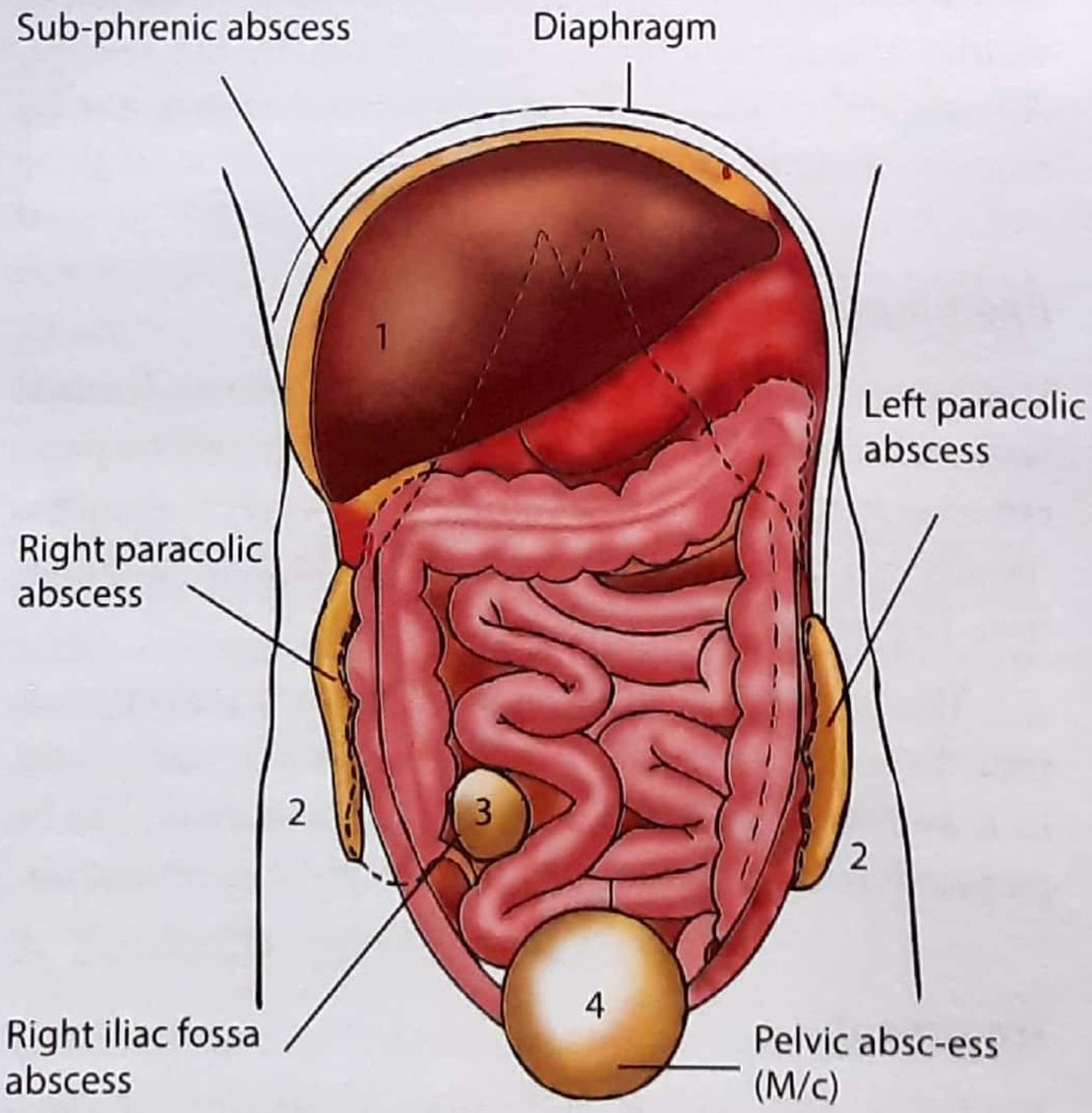

Figure 33.5: Sites of intra-peritoneal abscess

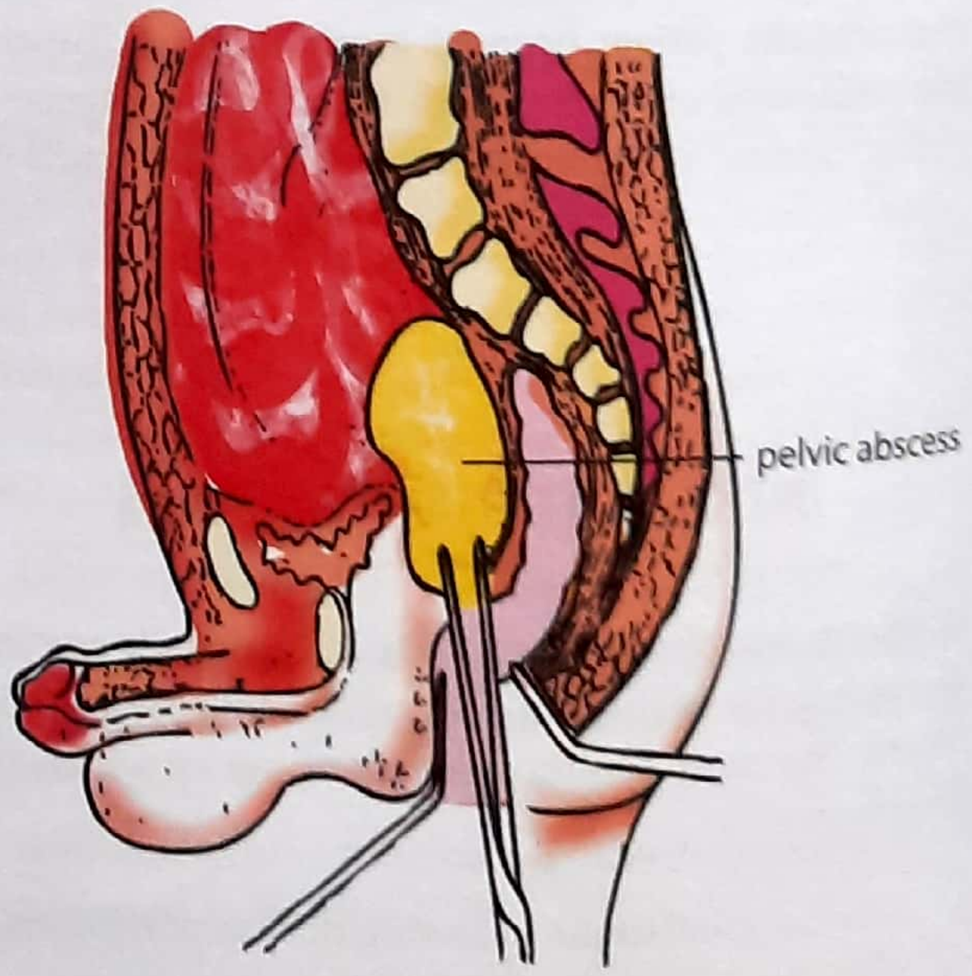

Figure 33.6: Opening of a pelvic abscess in rectum

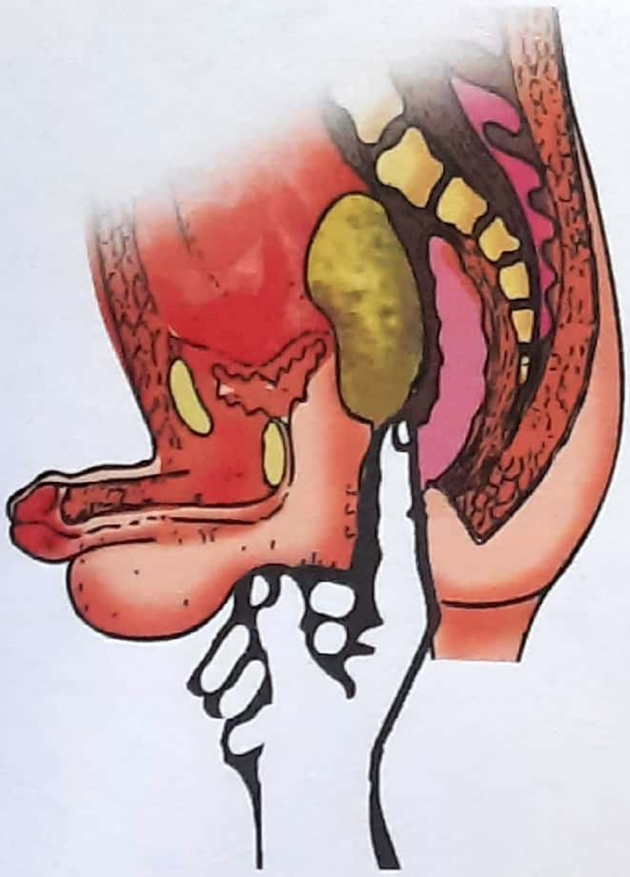

Figure 33.7: Pelvic abscess can be felt on per rectal examination, arrow indicating abscess

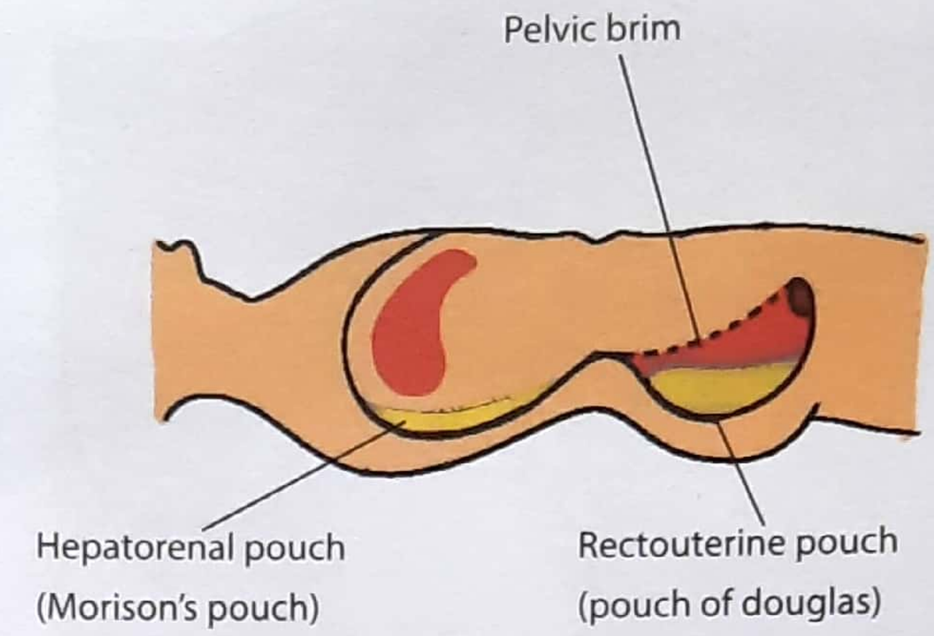

Figure 33.8: Two most common sites of collection of pus in peritoneal cavity

- **Ultrasonography** has a diagnostic accuracy in excess of 90%. However; the role for ultrasonography is limited by a number of shortcomings, because Imaging may be distorted by bowel gas especially in patients with profound ileus.
- CT scan is currently the *most accurate* modality available for the diagnosis of intraperitoneal abscess. The diagnostic accuracy rates of up to 95% have been reported. The major disadvantages of CT is the higher cost, the lack of portability and the use of ionizing radiation.

Management

The management of intraperitoneal abscesses is similar to the management of secondary peritonitis. Immediate attention is given to the resuscitation and general support of the patients. Although the efficacy of antibiotics is limited, empirical therapy should still be instituted as early as possible. Antibiotic selection is directed towards both aerobic and anaerobic pathogens. The mainstay of **treatment is drainage** of the abscess which can be accomplished by either (i) percutaneous or (ii) surgical techniques.

(i) Percutaneous drainage

Percutaneous drainage is a well accepted and favoured alternative in the treatment of intraperitoneal abscess. This offers several potential advantages, such as fewer complications, reduced hospitalization, avoidance of general anesthesia and lower costs when compared to surgical drainage.

Percutaneous drainage is also considered in the following situations:-

1. Multiloculated or multiple abscesses
2. Abscesses with enteric (bowel) communication and
3. The need to traverse peritoneum or a solid viscera to reach the abscess.

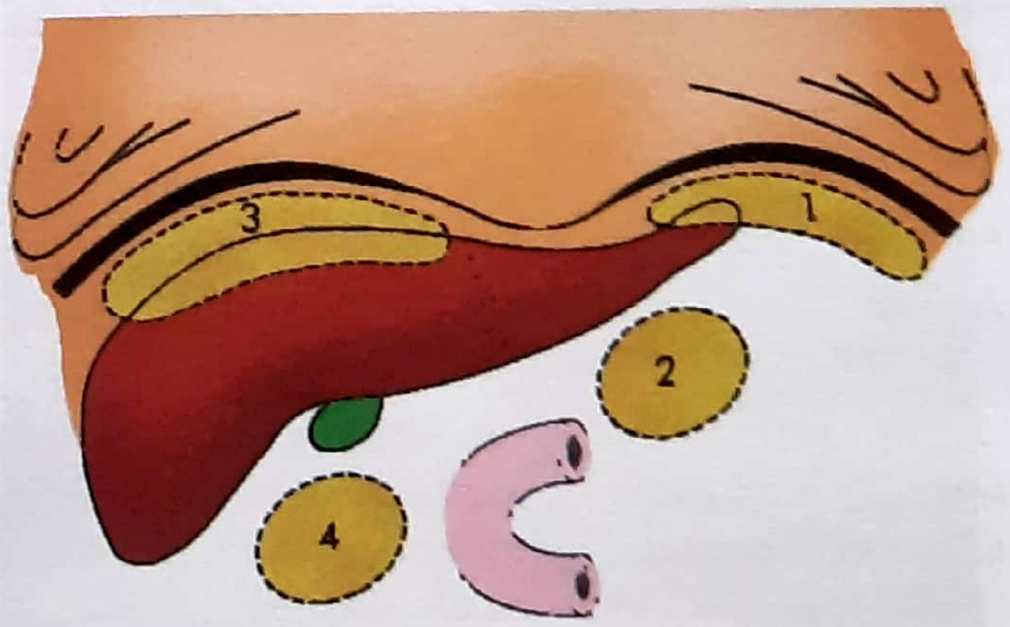

Figure 33.9: Intra-peritoneal subphrenic abscess on sagittal section [1]. Left superior (left subphrenic) [2]. Left inferior (left subhepatic) [3]. Right superior (right subphrenic) [4]. Right inferior (right subhepatic)

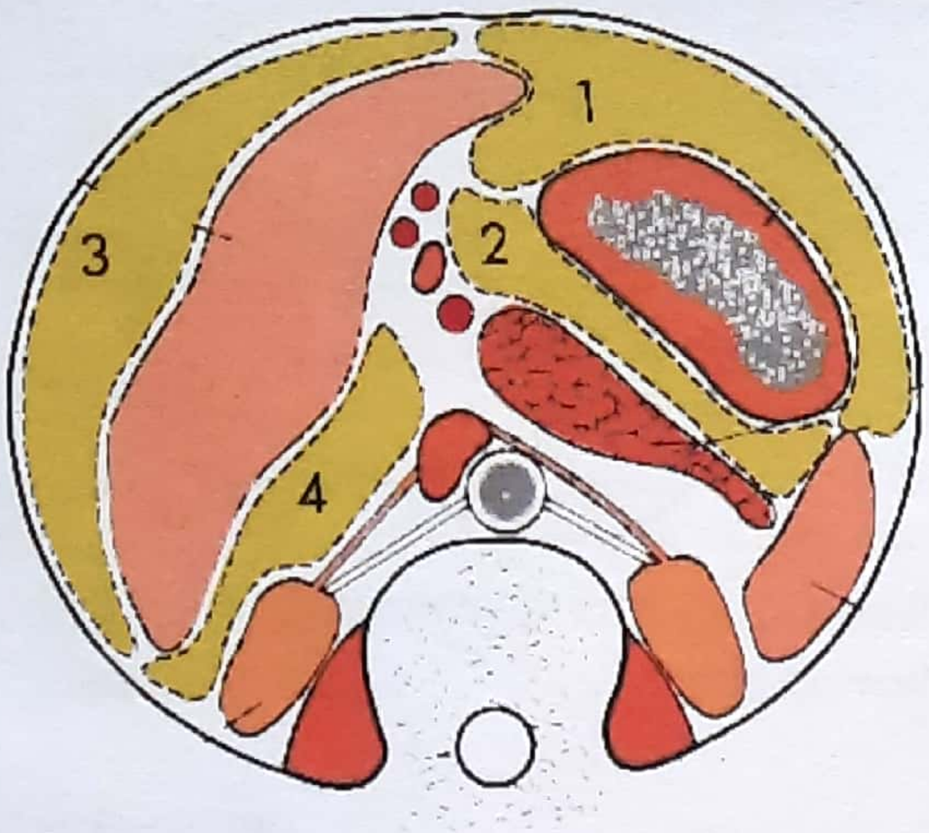

Figure 33.10: Intraperitoneal subphrenic abscess on transverse section (1). Left superior space (2). Left inferior space (3). Right superior space (4). Right inferior space

Situation in which percutaneous drainage is unlikely to be successful and therefore *contraindicated* are:

1. Ill defined abscess
2. Fungal abscesses
3. Infected hematomas
4. Necrotic tumour mass and
5. Interloop abscesses.

In these situations; open surgical drainage is the preferred method of management.

(ii) Surgical drainage

Surgical drainage is indicated when:-

1. The abscess is poorly defined
2. The abscess material is viscous or extensive necrotic debris is present (eg; lesser sac abscesses).

During operation the abscess wall should be identified and the cavity aspirated with a needle to confirm the nature of the abscess. The abscess should then widely opened and its contents evacuated. Drains are placed in most dependent position and externalized via separate incision on anterior abdominal wall.

*****

CHYLOUS ASCITES

In some patients the ascites fluid look milky. This is due to excess of fat content; chylomicrons (triglycerides).

Most of them are associated with malignancy, usually lymphoma. Other causes are filariasis, tuberculosis, cirrhosis, abdominal trauma and nephrotic syndrome.

This is a rare condition. The prognosis is poor unless the underlying cause is cured. In addition to other measures used to treat ascites, patient should be placed on fat free diet with medium chain triglyceride supplement.

*****

PNEUMOPERITONEUM

1. Causes

Iatrogenic -

- Surgery, peritoneal dialysis, Biopsis.

Perforation of GI Tract -

- Peptic ulcer, Infarction, Malignant neoplasm, obstruction, Pneumatosis cystoides rupture, endoscopy,

Penetrating abdominal injury

2. Investigation

- Best X-ray view for pneumoperitoneum : Erect Chest X-ray. (Figure 33.12)
- Those who cannot get into erect position : Left lateral decubitus view.

3. X-ray signs of pneumoperitoneum

- Football sign (Figure 33.11)
- Falciform ligament sign
- Rigler's sign (Figure 33.13)
- Cupola sign
- Triangle sign

Differential diagnosis

- **Chilaiditi syndrome** or interposition of colon between liver and diaphragm can mimic pneumoperitoneum.

Figure 33.11 : Football sign: radiolucent gas is seen outlining the peritoneal cavity

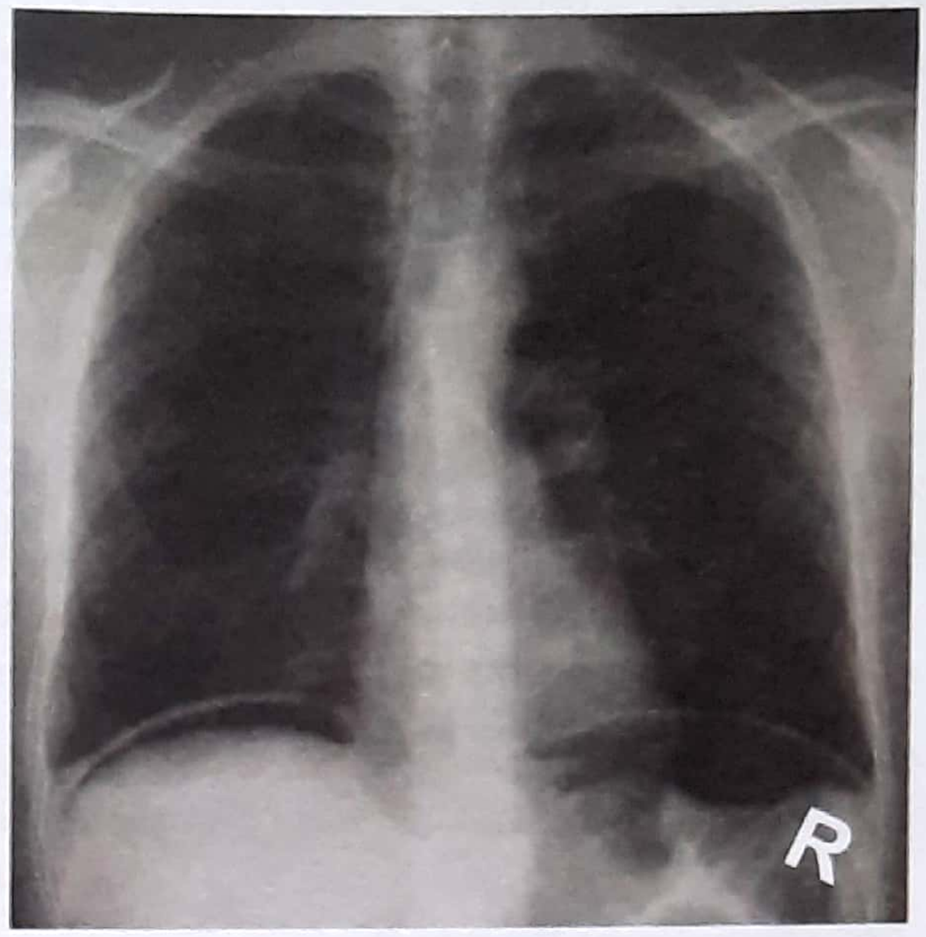

Figure 33.12 : The plain chest xray shows air under the diaphragm which is indicative of bowel perforation

Treatment

- **If patient hemodynamically unstable, first stabilize patient by IV fluid & antibiotics followed by laprotomy.** *(AIIMS MAY 16)*

*****

KEY BOX 33.2

NOTE: **Drainage** word is very commonly used in surgery and for an undergraduate; it is very difficult to understand drain and drainage, who had often, not seen any major abdominal operation.

- Abdomen is a closed cavity, when a laparotomy is done (say for any reason), all the pus or fluid can not be taken out in spite of all efforts, so we place a plastic tube (open at both end) in abdominal cavity; most commonly in pelvic (most dependent part) so that any fluid present in abdomen comes out from abdominal cavity through this tube. This tube is brought out from the abdomen by making a small incision on anterior abdominal wall. This tube is called as drain and procedure is drainage,
- [Friends do not get confused with drainage procedure done in peptic ulcer disease: GastroJejunostomy, kindly revise this in chapter 28 -Stomach; page no. 347]

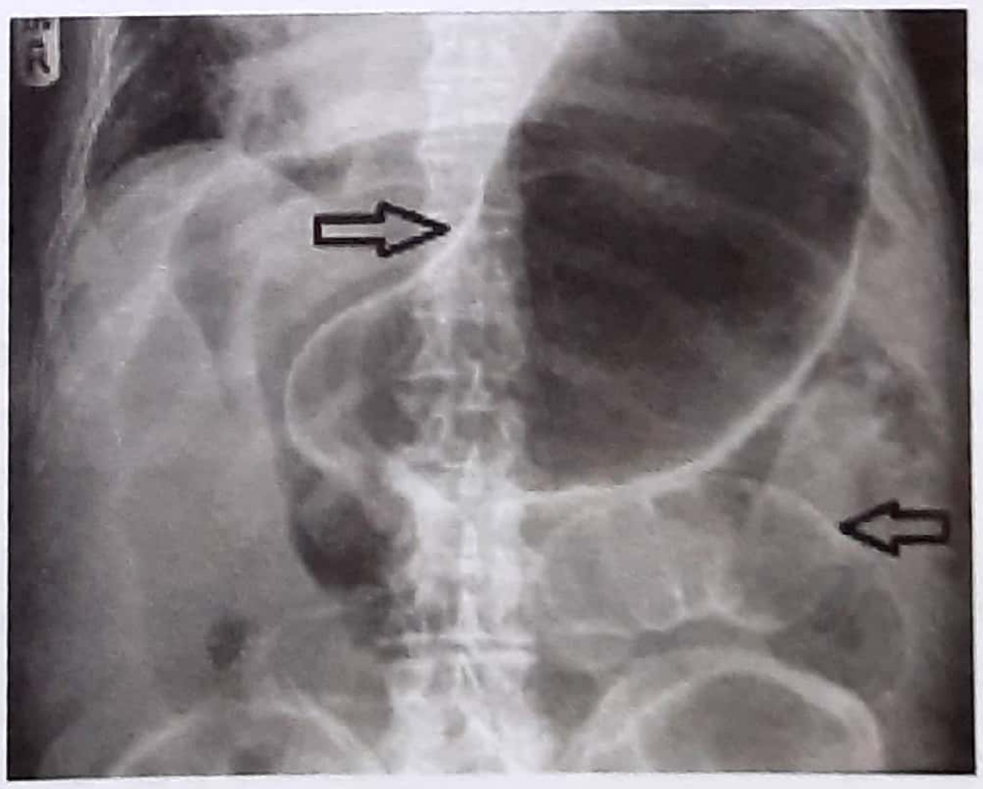

Figure 33.13 : Rigler sign: In the given plain x ray of the abdomen, both sides of the stomach wall and both sides of the wall of a loop of small bowel are visible. Both sides of the bowel wall become visible because of the free gas surrounding the bowel; this is known as Rigler sign diagnostic of pneumoperitoneum.

NEOPLASM OF PERITONEUM

1. Carcinoma Peritonei

- In advanced stage of intra-abdominal malignancy peritoneum is involved; the condition is called a carcinoma peritonei.
- Peritoneal metastases are frequently seen with the primary lesion, typically in GI tract. Less commonly, primary may be in breast, ovary, lung or pancreas.
- Both parietal and visceral peritoneum are studded with secondary metastatic deposits and the peritoneal cavity becomes filled with clear, straw coloured or blood stained ascitic fluid.
- On laparotomy these nodule are firm to hard.

2. Pseudomyxoma Peritonei

- This is an uncommon condition in which peritoneal cavity is filled with mucinous (Jelly like) substance.
- In order of frequency; two condition are responsible for this:- rupture of a **mucinous ovarian cyst** (NEET) and rupture of a mucocele of appendix. (PGI DEC 08)
- The condition is ***more common in women.*** (NEET, UP 06, 07)
- Abdomen is filled with yellowish jelly like substance in abdominal (peritoneal) cavity.
- Locally malignant tumor.
- Needs surgical debulking & chemotherapy.
- The current treatment of patients with pseudomyxoma peritonei involves resection of as much of the tumor as possible (cytoreduction) and hyperthermic intraperitoneal chemotherapy (HIPEC). Operative management includes lesser and greater omentectomy, stripping of involved parietal peritoneum, resection of involved organs, and appendectomy or ileocolectomy.
- The most commonly used drugs for intraperitoneal chemotherapy are mitomycin C and oxaliplatin.
- Of patients, 25% to 35% will develop a serious complication, most commonly prolonged ileus and pulmonary complications. Hemorrhage, intraabdominal infections, enterocutaneous fistula, pancreatitis, and bone marrow suppression are also reported.

3. Peritoneal Mesothelioma

It is a rare primary neoplasm of peritoneum and is derived from the mesodermal lining of the peritoneum. *Prolonged exposure to Asbestos is a well recognized cause* (MANY PGME), It involves *pelvic peritoneum* more commonly. It is not radiosensitive but alkylating agents give remission.

Patient seldom complains until late; when they have abdominal distension and pain. Some patients may presents with partial bowel obstruction.

As with pseudomyxoma peritonei, combined-modality approaches using cytoreductive surgery and HIPEC offers better survival rates.

Systemic chemotherapy with cisplatin and pemetrexed has a modest benefit on survival and is used for palliative treatment of patients who are not surgical candidates.

*****

MESENTERIC TEAR (LACERATION OF MESENTERY)

Mesentery may be injured by either penetrating or blunt abdominal trauma. Most penetrating injuries are due to stabbing or gun shot wound. Blunt injury may result in mesenteric tear due to seat belt injury *(seat belt syndrome)* (UP 05)

Clinical Feature

There is no specific clinical feature of this condition. Depending on length of mesenteric tear varying degree of shock is noticed. Large tear of mesentery may lead to ischemia of the bowel.

Abdominal pain, tenderness, rigidity are almost always present. *A transverse tear of mesentery is much dangerous than longitudinal tear; due to more likely hood of vascular impairment of the involved segment of bowel,* because blood vessels supplying bowel (mesenteric arteries) are contained in mesentery (Figure 33.14).

Treatment

Basic treatment consist of controlling the bleeding at laparotomy. If the tear in the mesentery is large and the blood

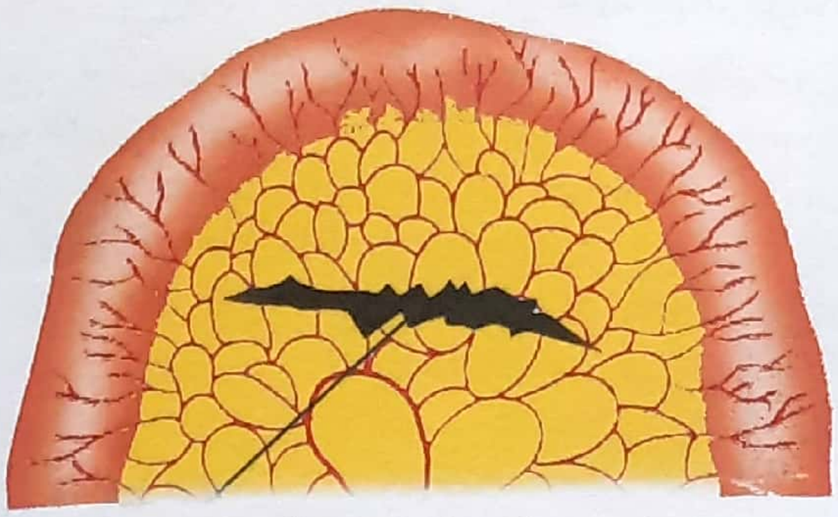

Transverse tear in mesentery (more dangerous)

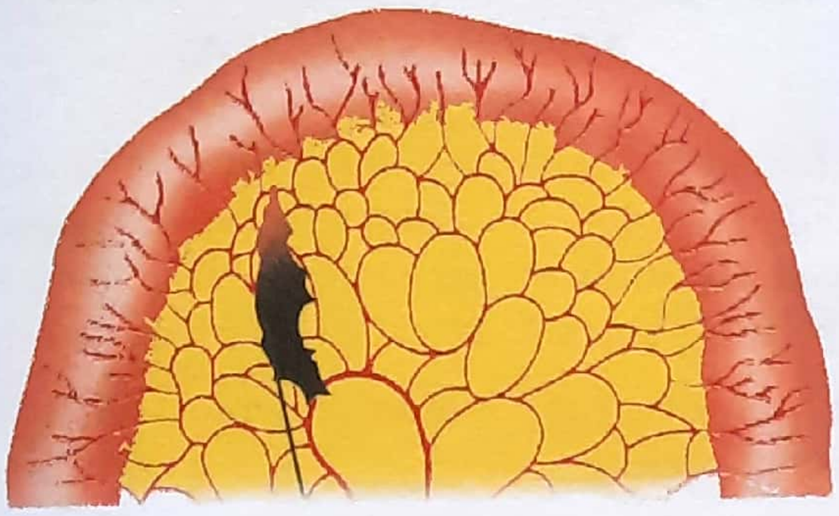

Vertical tear in mesentery (less dangerous)

Figure 33.14: Mesenteric tear

supply to the part of intestine is cut off, the ischemia part of the small intestine should be resected and end to end anastomosis between viable bowel ends should be done.

*****

MESENTERIC CYSTS

Cysts related to mesentery are classified as: *(PGI 97)*

- **Chylolymphatic cyst (M/C)** *(NEET)*
- **Enterogenous cyst** *(NEET)*
- **Dermoid (Teratomatous) cyst** *(NEET)*
- Urogenital cyst

Now lets discuss each condition one by one:

Types

1. Chylolymphatic Cyst

This is the **commonest** variety of mesenteric cyst *(JIPMER 87)* and arises from the congenially misplaced lymphatic tissue that has no efferent (out flowing) communication with the lymphatic system. The fluid inside the cyst is clear lymph, however occasionally there may be chyle of varying consistency (hence named as; chylo-lymphatic cyst)

2. Enterogenous Cyst

(Entero+genous= Originating in relation with intestine)

Develops from a diverticulum (out pouching) at the mesenteric border of intestine, which has become detached from the intestinal canal during embryonic life. The cyst wall is lined by muscle and mucous membrane and the content of the cyst is either yellowish brown or mucinous.

3. Dermoid (teratomatous) Cyst

This is extremely rare in mesentery. This cyst contains structure derived from ectoderm, mesoderm and endoderm.

4. Urogenital Cyst

These cysts may be develop from uro-genital remnant.

Clinical Feature

Mesenteric cyst is most often seen in the second decade of life. Mesenteric cyst usually presents as:-

1. A mesenteric cyst most commonly presents as a painless abdominal swelling (lump) in the umbilical region.
2. The ***swelling moves freely in a plane at right angle to the line of root of mesentery* (Tillaux sign)*** *(INICET 20 NOV. AP 97)*. Please see figure 33.15.

NOTE:- an ovarian cyst is freely movable in all the direction, which is most common D/D of mesenteric cyst, key box 33.3]

3. Recurrent attacks of abdominal pain
4. Occasionally a mesenteric cysts may present acute abdomen due to: *(IMP. POINT)*
   - Torsion of the cyst
   - Rupture of the cyst (Causing peritonitis)
   - Hemorrhage in the cyst
   - Infection of the cyst

Root of mesentery is 6 inches long and is directed obliquely downwards and to the right. It extends from the duodeno jejunal flexure (On the left side of L, vertebra) to right sacroiliac joint. Kindly see figure 33.15 & figure 33.3.

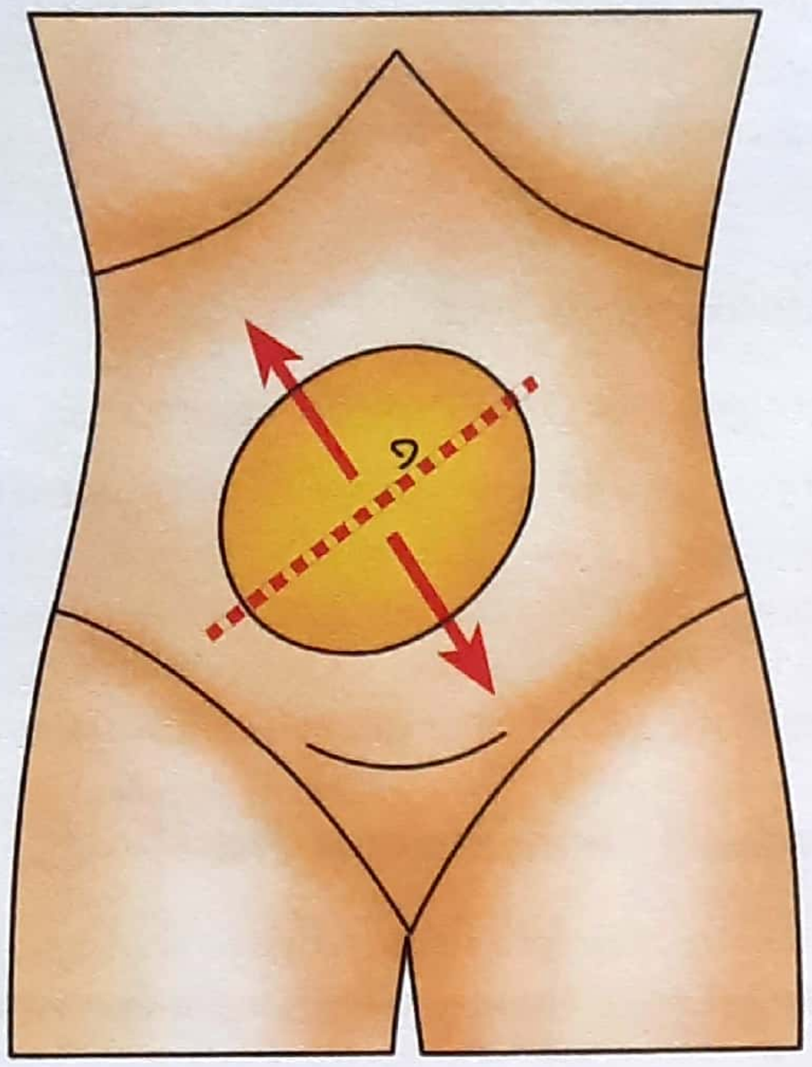

Figure 33.15: Mesenteric cyst moves freely only at right angle to the root of mesentery (root of mesentery marked by dotted line) - **Tillaux sign**

Investigation

- *Barium Meal X-ray* is often diagnostic. The coils of small intestine will be seen displaced by the cyst.
- *Ultrasound and CT scan* will confirm the diagnosis.

Treatment

Chylolymphatic cyst

Enucleation is the treatment of choice. Older treatment; marsupilization of a mesenteric cyst has been abandoned because of its high recurrence results & fistula formation.

Enterogenous Cyst

For these enucleation should not be done. An enterogenous (entero = intestine, genous = origination) cyst originate in close relation with intestine, hence the treatment is resection of the cyst with the adherent portion of the intestine followed by intestinal anastomosis. (TN 95, UP 05)

KEY BOX 33.3
Freely moving lump in abdominal cavity
• Ovarian Cyst • Subserous fibroid • Floating kidney • Omental Cyst • Wandering spleen • Hydrops (mucocele) of gall bladder

*****

NON SPECIFIC MESENTERIC LYMPH ADENITIS [NSMLA]

- This condition is one of the common cause of acute abdominal pain in children. Nonspecific mesenteric lymph adenitis was so named to distinguish it from specific (Tuberculous) mesenteric lymphadenitis.
- It is now very much more common than the tuberculous variety.

Etiopathogenesis (JIPMER94, AMU 87)

- The etiology often remains unknowns, although some cases are associated with *Yersinia* (AI 94) infection of the ileum. In some cases, an unidentified virus is blamed. In about 25% of cases, a respiratory infection precedes an attack of NSMLA.
- Some time appendicitis has been incriminated to cause this condition, though at laparotomy appendix in found to be absolutely normal. However; appendicectomy reduces the incidence of further attacks.
- This condition may be as a result of hypersensitivity reaction to a foreign protein in food.
- There are small size, enlarged firm lymph nodes in ileocecal mesentery. In very acute cases the nodes are distinctly red and very large. There may be small increase in peritoneal fluid.

Clinical feature

- Non specific mesenteric lymph adenitis (NSMLA) is a common cause of acute abdominal pain during childhood. The condition is unusual after puberty.
- The condition more commonly occurs, when child is tired after playing..
- Early in the attack the temperature may be elevated.

- There is a history of short attack of central abdominal pain lasting for 10-30 minutes and associated with circumoral pallor.
- Vomiting occurs in about 1/3 or cases.
- **Shifting tenderness** is a valuable sign, which clearly differentiate this condition from acute appendicitis. If the child is turned to left side in lying posture for 5 minutes, the site of maximal tenderness will move towards the left than the original site, while in a case of acute appendicitis tenderness remains at the same spot (McBurney's point).
- **On rectal examination** - there may be tenderness on right side of pelvic.
- **Leukocytes count:** There is often a leucocytosis of 10,000 - 12,000 /ml or more.

Treatment

As the prognosis is excellent and complete recovery almost always occurs without specific treatment, no specific treatment is required except assurance and bed rest. Only when it becomes difficult to exclude acute appendicitis, appendicectomy is performed.

*****

TUBERCULOSIS OF MESENTERIC LYMPH NODE

This is a very rare condition in western world, but still very common in India. Affection of mesenteric lymph node usually occurs through payer's patches and mesenteric lymphatics draining to the lymph node. The causative agent is often bovine tubercular bacilli. A quite few cases may be due to ingestion of patient's own sputum, containing tubercle bacilli in case of pulmonary tuberculosis.

Clinical feature

A patient with tuberculous mesenteric lymph adenitis may present in one of the following six forms.

1. With abdominal pain.
2. With general symptoms of tuberculosis, eg; loss of appetite, evening rise temperature, weight loss
3. Calcified tuberculous lymph node on X-ray
4. With features almost similar to appendicitis
5. With mesenteric cyst
6. With intestinal obstruction: caseating mesenteric lymph nodes may cause adherence of coils of small intestine leading to intestinal obstruction.

Treatment

Full course of Anti tubercular treatment (ATT).

*****

RETROPERITONEUM

- Note pre peritoneal space (in front of peritoneum) also note retro peritoneal space (behind the peritoneum) See figure 33.1 and 33.16.

Retro peritoneal space is a space which is situated behind posterior envelop of peritoneum and anterior to posterior abdominal wall. The common structure (organs) present are given in box 33.4, and are called as retro-peritoneal organs. Liposarcoma is most commonly seen in retroperitoneal space. *(INICET 20 NOV.)*

Retroperitoneal Fibrosis

Retro peritoneal fibrosis is an uncommon inflammatory condition which is characterized by proliferation and deposition of fibrous tissue (fibromatoses) in the retroperitoneum. **70%of cases are idiopathic- termed as Ormand's disease** *(NEET, KER 98, MANY PGME)*, where as 30% are associated with various drugs (mainly; ergot alkaloids, methylsergide, dopaminergic agonists, hemorrhage, retroperitoneal operations, radiation therapy or primary / metastatic neoplasm). Also see key box 33.5.

Retroperitoneal fibrosis is a group of fibromatoses, other being Dupuytrern's contracture and Peyronie's disease. There is well documented association of this condition with scleroderma and mediastinal fibrosis.

Clinical feature

- Condition in **more common in men** *(NEET)* between 40-60 year of age patient often presets with:-

KEY BOX 33.4	
Retroperitoneal structures	
• Kidneys	• Ureters
• Pancreas	• Duodenum (D2 and D3)
• Bladder	• Adrenal glands
• Ascending colon	• Descending colon
• Rectum (Upper 2/3)	• Aorta
• Inferior vena cava	• Iliac vessels
• Seminal vesicles	• Vas deferens
• Lymphatics	• Vagina (Upper 1/3)
• Ovaries	• Nerves (lumbar-symathetic)

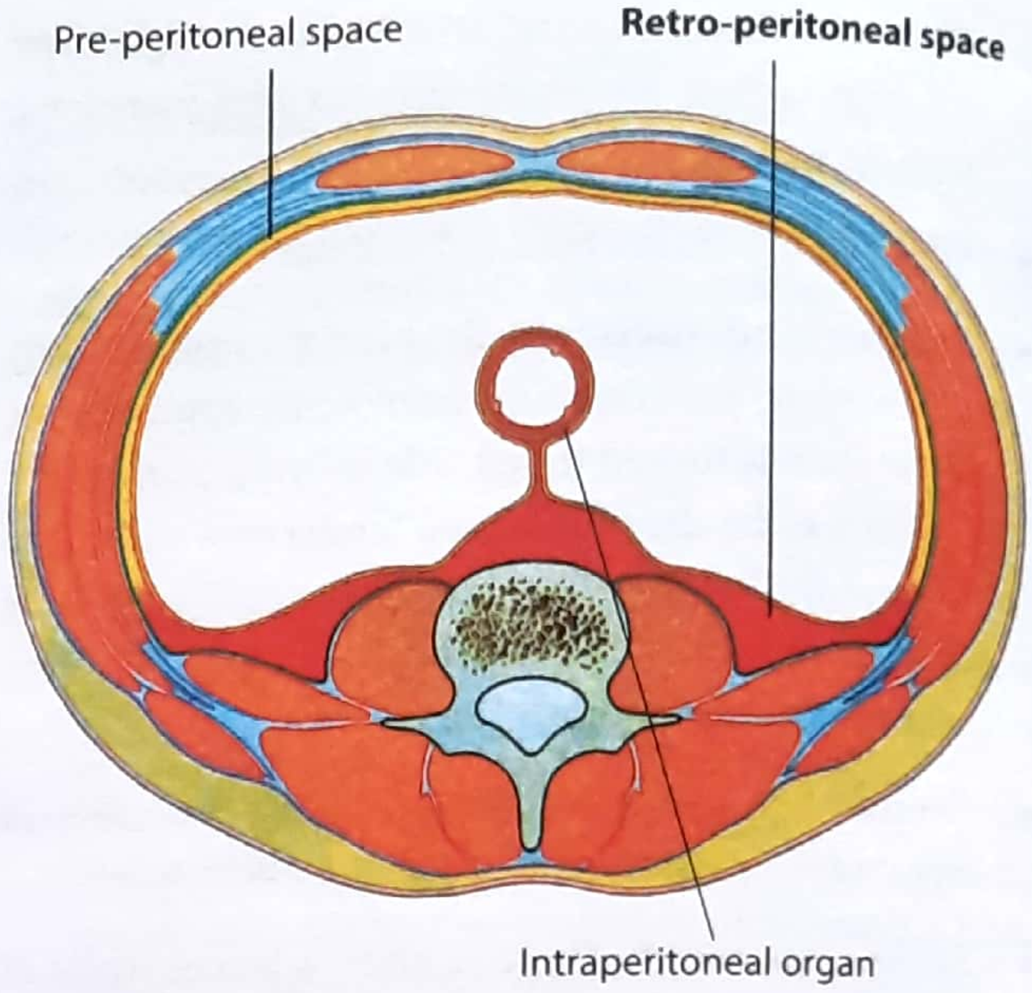

Figure 33.16 : Retro-peritoneal space

- Dull abdominal or flank pain
- Weight loss
- Hypertension (causing head ache)
- Scrotal of leg edema

- **Most common retroperitoneal organ** involved in retro peritoneum fibrosis is **middle 1/3 of ureter**. *(NEET, AIIMS 93)*

- Other organs may be IVC and aorta. Ureters are involved in late cases and patients usually present with urinary symptoms:-
  - Pyuria
  - Abdominal lump (due to hydronephrosis)
  - Frequency of micturition
  - Hematuria
  - Signs of renal failure
- Disease is most commonly bilateral but unilateral cases do occur.

Diagnosis

Diagnosis can be made by ***intravenous urogram,*** which will demonstrate with:

Diagnostic triad of

(i) Hydronephrosis,

(ii) Hydroureter associates with delayed excretion of dye (due to renal failure) and

(iii) Medially deviated ureters.

KEY BOX 33.5
Causes of Retro Peritoneal fibrosis
Benign:
• Idiopathic (Ormond's disease)-70% (M/C)
• Abdominal aortic aneurysm
• Chronic inflammation-chronic pancreatitis, Histoplasmosis, Tuberculosis
• Auto immune disease-Ankylosing spondylitis, Thyroiditis, SLE, PAN, Wegner's granulomatosis, sclerosing cholangitis
• Drugs-Methylsergide, Beta blockers, hydralazine dopaminergic agonist.
Malignant
• Lymphoma
• Carcinoid Tumour
• Sarcoma
• Gastric Cancer

Other diagnostic modalities are:

- CT Scan
- MRI
- CT guided biopsy (to differentiate b/w benign and malignant fibrosis)

Treatment

In Early cases - Steroid can be (NEET) helpful. Stop drugs responsible for fibrosis.

In Severe late cases - Surgical treatment, in the form of Ureterolysis with transposition of ureters is done.

Retroperitoneal Trauma (AIIMS JUNE 20)

Retroperitoneum is divided into 3 zones, based on type of viscera & difference in **blunt trauma**.

Zone 1	Central	Always explored after proximodistal vascular control.
Zone 2	Lateral	Only explored if pulsatile or expanding hematoma else conservative /embolization.
Zone 3	Pelvic	Only explored if pulsatile or expanding hematoma, else conservative/angioembolization.

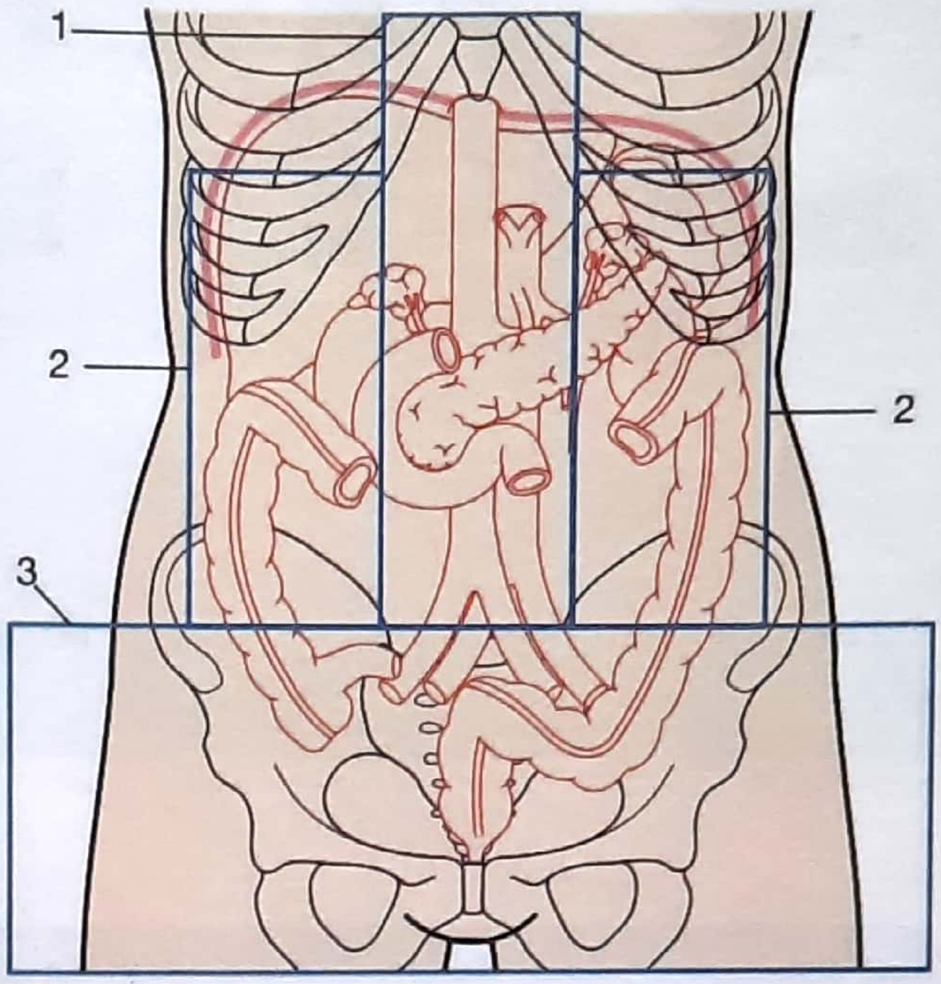

Figure 33.17 : The zones of the retroperitoneum.
Zone 1 : central; Zone 2 : lateral; Zone 3 : Pelvic

- If penetrative injury in any zone, surgical management is done.
- Mattox maneuver is left medial visceral rotation to expose aorta.
- Cattle brosch maneuver is done by right medial visceral rotation to expose IVC.

*****

Sample Questions for Prof Examination

1. Write short notes on:
   Mesenteric cyst
   Tubercular mesenteric lymphadenitis
2. Discuss etiopathogenesis, and management of pelvic abscess.

34 The Small and Large Intestine

Contents

- Peritoneal fold
- Surgical anatomy
- Hirschsprung's disease (Congenital megacolon)
- Idiopathic megacolon (chronic functional constipation)
- Diverticular disease
- Meckel's diverticula
- Colonic diverticulitis
- Ulcetative colitis
- Chron's disease
- Tuberculosis of the intestine
  - Hyper plastic ileocecal tuberculosis
  - Ulcerative tuberculosis
- Short bowel syndrome
- Ischemic colitis
- Tumours of the small intestine
- Tumours of the large intestine
  - Non neoplastic epithelial tumours
  - Benign neoplasm
  - Malignant neoplasm
- Fecal fistula (entero-cutaneous fistula)
- Ileostomy and colostomy

SURGICAL ANATOMY

- The **small intestine** extends from the pylorus to the ileocecal junction. It is about 6meters in length. The small intestine consist of the duodenum, jejunum and ileum. The jejunum and ileum together extend from the duodenojejunal junction to the ileocecal valve.
- The jejunum consist of proximal 40% and ileum consist for the distal 60% of small intestine. The jejunum and ileum are suspended (attached) from the posterior abdominal wall by mesentery. Mesentery contains vascular supply to the bowel (jejunum& Ileum) Please see figure 34.1.
- The wall of jejunum is thicker and more vascular than ileum. (See key box 34.1 & figure 34.2)
- The large intestine consist of cecum, ascending colon, hepatic flexure (right colic flexure), transverse colon, splenic flexure (left colic flexure), descending colon, sigmoid colon (pelvic colon) and the rectum. Please see figure 34.4.
- The ascending colon is 5 inches long, transverse colon is about 20 inches long, descending colon is 10 inches long and sigmoid colon is 15 inches long. [just to remember (1,4,2,3) multiplied by 5]. Total length is about l.5 meters. The large intestine is wider than small intestine in calibre. The calibre is greatest at its commencement and gradually diminishes towards the rectum. The greater part of the large intestine is retroperitoneal and fixed (ascending and descending colon). The longitudinal muscle coat forms only a thin layer in large intestine (Figure

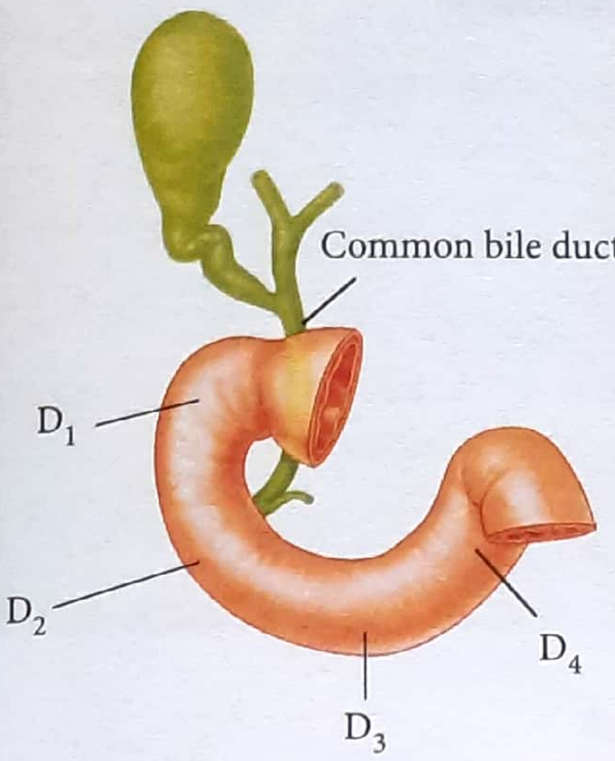

Parts of Duodenum

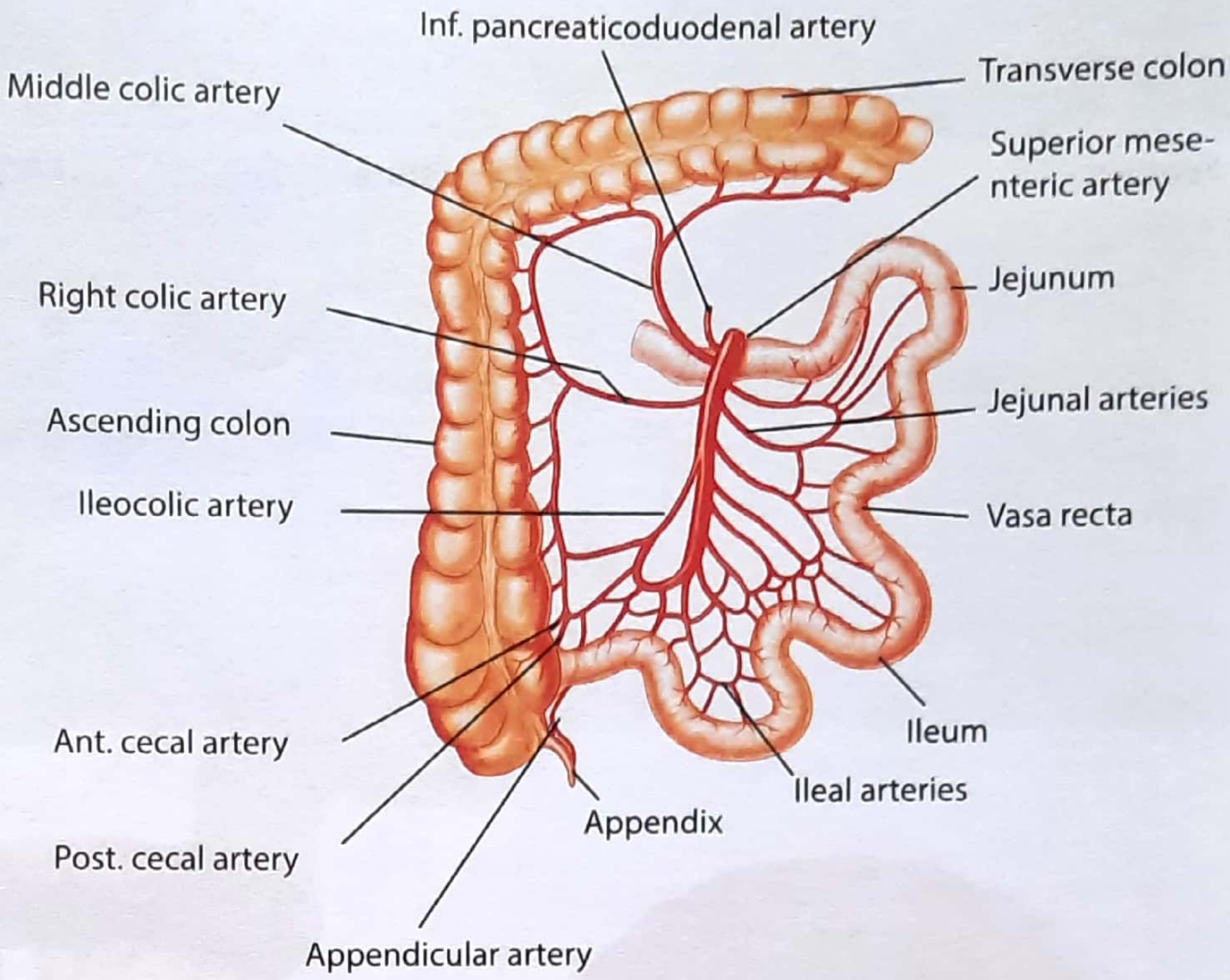

Figure 34.1: Duodenum, Jejunum, Ileum

34.3). The greater part of it forms three ribbon like bands called the taeniae coli. [Note: longitudinal muscle coat is part of muscularis externa]. The wall of colon show sacculations and puckering. Small bag of peritoneum filled with fat; called appendices epiploicae are scattered over the surface of the large intestine, except on the appendix, cecum and the rectum, (fig 34.4).

*****

KEY BOX 34.1

Difference between Jejunum and Ileum

Feature	Jejunum	Ileum
1. Location	Occupies upper and left part of abdominal cavity	Occupies lower and right part of the abdominal cavity.
2. Wall	Thicker	Thinner
3. Lumen	Wider	Narrower
4. Mesentery	• Window present • Fewer arterial arcades (1-2) • Fat less abundant	• Window absent • Arterial arcades numberous (4-6) • Fat more abundant
5. Peyer's Patches	Absent	Present
6. Villi	Leaf like (large) and more abundant	Shorter, finger like (thinner) and less abundant
7. Lymph code	Less in number	More in number

KEY BOX 34.2

Difference between The Small and The Large Intestine

Feature	Small Intestine	Large Intestine
1. Appendices epiploicae	Absent	Present (except appendix, cecum & rectum)
2. Taeniae coli	Absent	Present
3. Haustration and sacculations	Absent (Surface is smooth)	Present
4. Calibre	Smaller	Wider
5. Fixity	Greater part is mobile (except D_2 and D_3)	Greater part is fixed (except transverse colon and sigmoid colon).
6. Peyer's patches	Present in ileum	Absent
7. Villi	Present	Absent

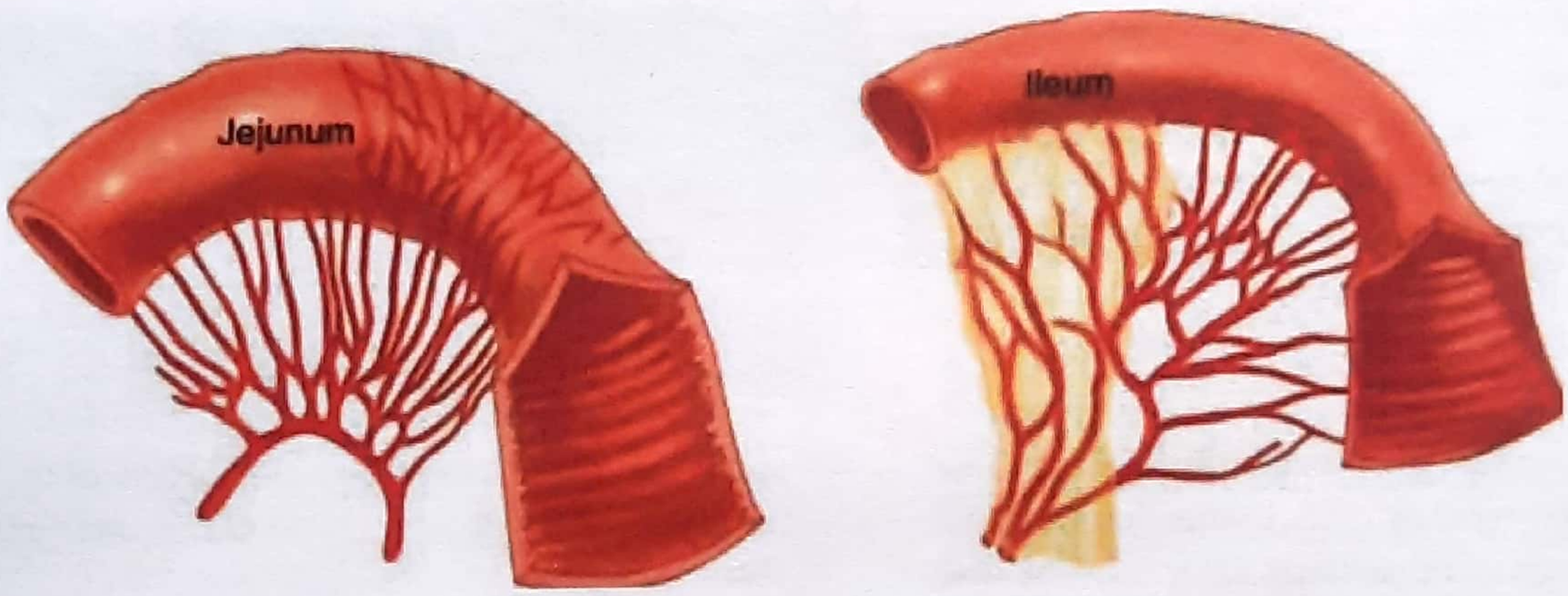

Figure 34.2: Arterial supply of small intestine (a) Jejunum (b) Ileum

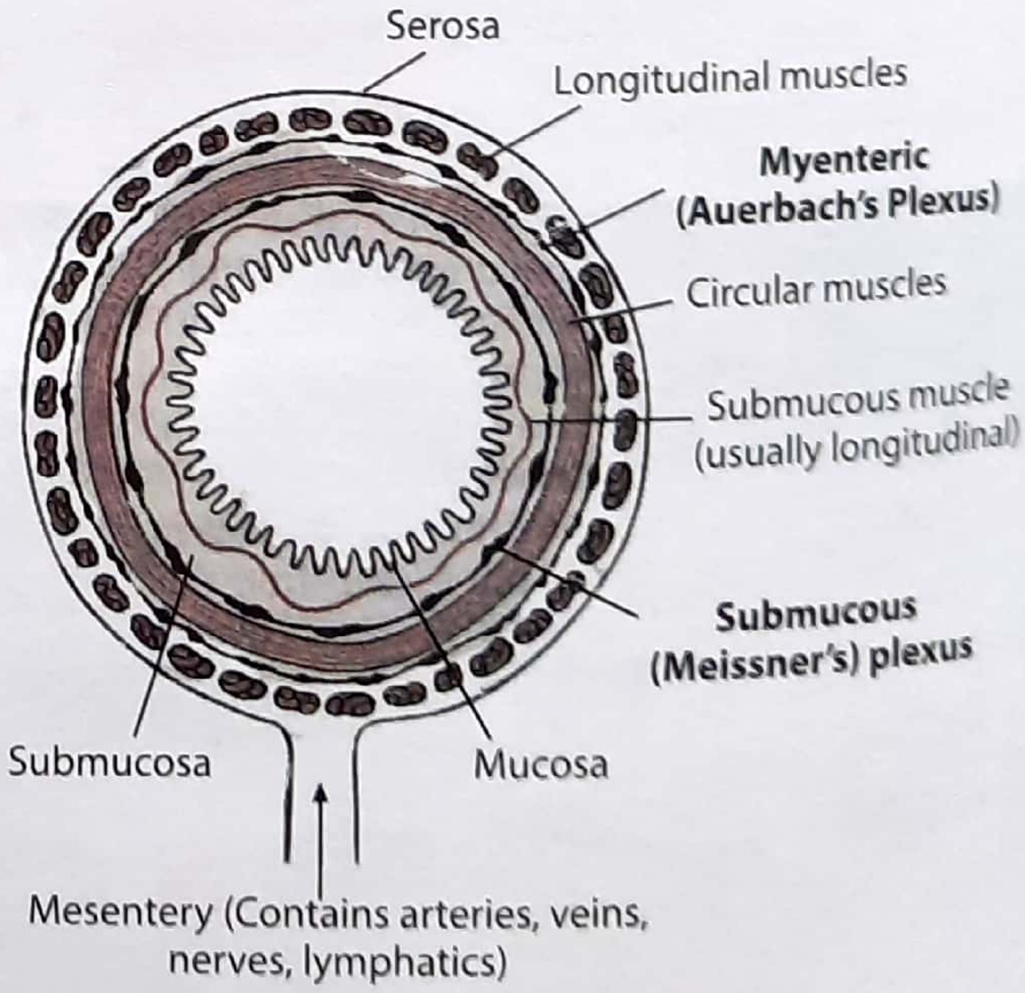

Figure 34.3: Diagramatic representation of layers of stomach, small intestine and colon. Structures of esophagus and distal rectum is similar, except that they do not have serosa & mesentery

KEY BOX 34.3

Layers of intestine from inside to outside (fig 34.3)

1. Mucosa
2. Submucosa
3. Muscularis
   (i) Circular muscle layer
   (ii) Longitudinal muscle layer
4. Serosa

These layers are present in stomach, small intestine and colon. The structure of the esophagus and the distal rectum is similar except that they do not have serosa.

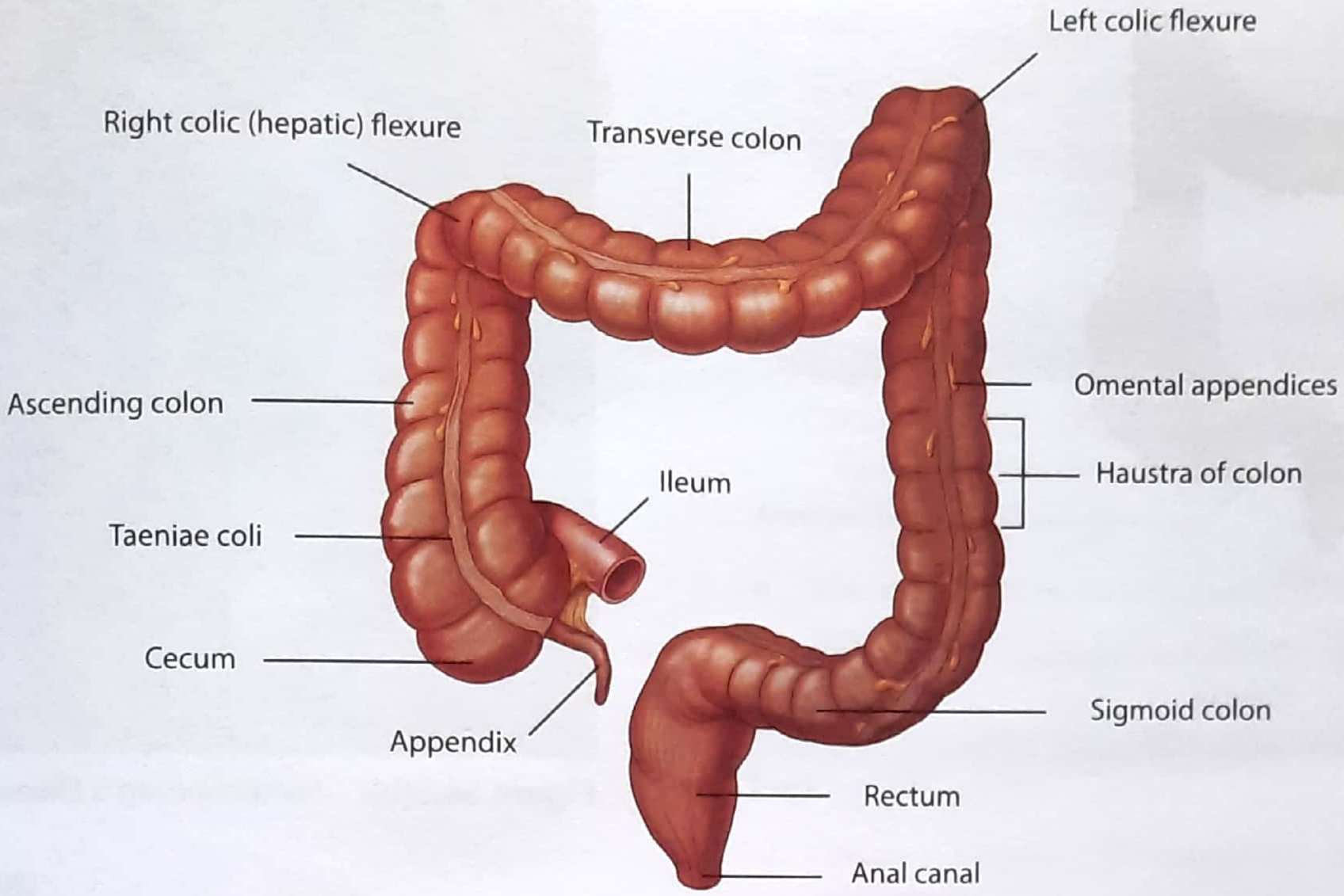

Figure 34.4: Large intestine

DEVELOPMENTAL ABNORMALITIES

- Congenital atresia of the duodenum
- Congenital atresia of small intestine (ileum and jejunum).
- Congenital atresia of ascending colon
- Atresia at multiple intestinal segment.
- Meconium ileus and meconium plug syndrome
- Volvulus neonatorum.

- ***All above listed conditions cause intestinal obstruction in newborn and have been discussed in the next chapter (intestinal obstruction)***

*****

HIRSCHSPRUNG'S DISEASE
(CONGENITAL MEGACOLON)

Syn: Primary megacolon

Before discussing Hirschsprung's disease lets know myenteric plexus and meissner's plexus.

There are two major networks of nerve fibers that are intrinsic to the gastrointestinal tract: the myenteric plexus ***(Auerbach's plexus)***- between the outer longitudinal and middle circular muscle layers and the submucous plexus ***(Meissner's plexus)***- between the middle circular layer and the mucosa. Please see key box 34.3 & fig. 34.3.

- Hirschsprung's disease is caused by failure in migration of ganglionic cell in the **myenteric plexuses of the colon from the neural crest**. *(AIIMS 97, UP 05, PGI06).*
- Most causes are sporadic.
- The aganglionic segment usually starts at anorectal junction and extends proximally (upwards) for a variable distance. *(IMP. POINT)*
- In approximately 95%cases; aganglionosis is restricted to rectum, however rarely aganglionic segment may be longer and in exceptional cases the entire colon and small intestine may be affected.
- The disease is more common in male child than in female child and male to female ratio in 4:1.
- The absence of ganglion cells in the myenteric plexus results in failure of peristalsis in affected segment. This segment remains narrow and spastic and represents a zone *of functional intestinal obstruction.* *(IMP. POINT)*

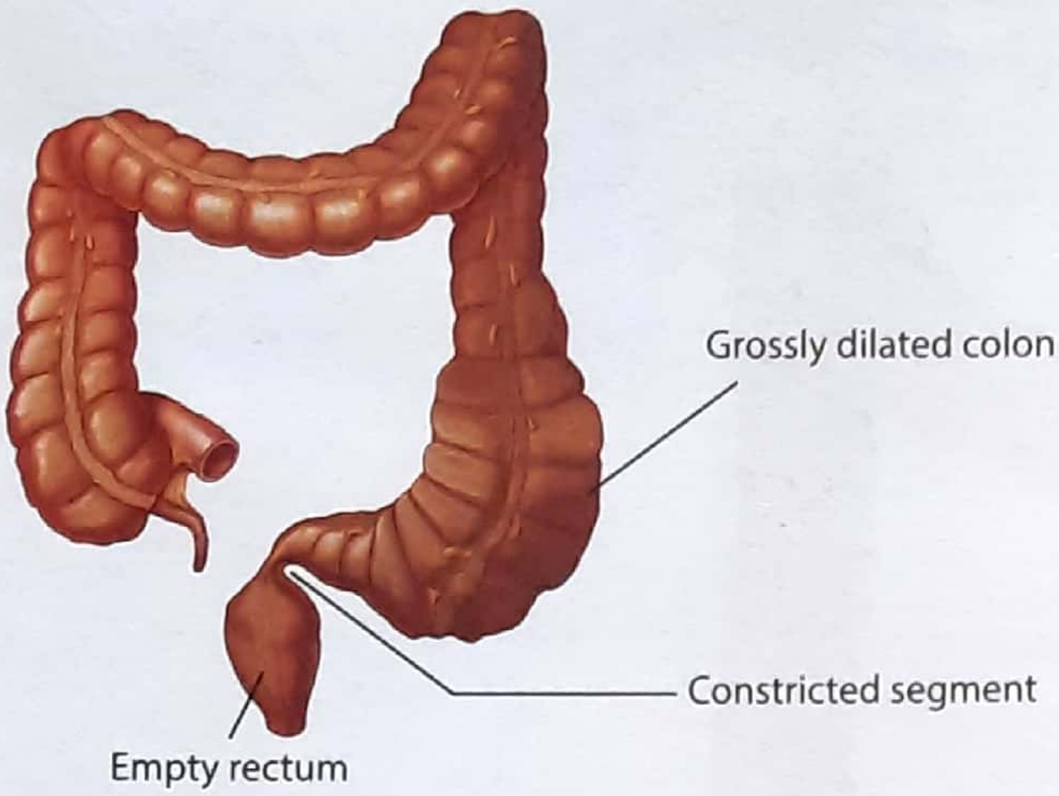

Figure 34.5(a): Congenital megacolon or Hirschsprug's disease

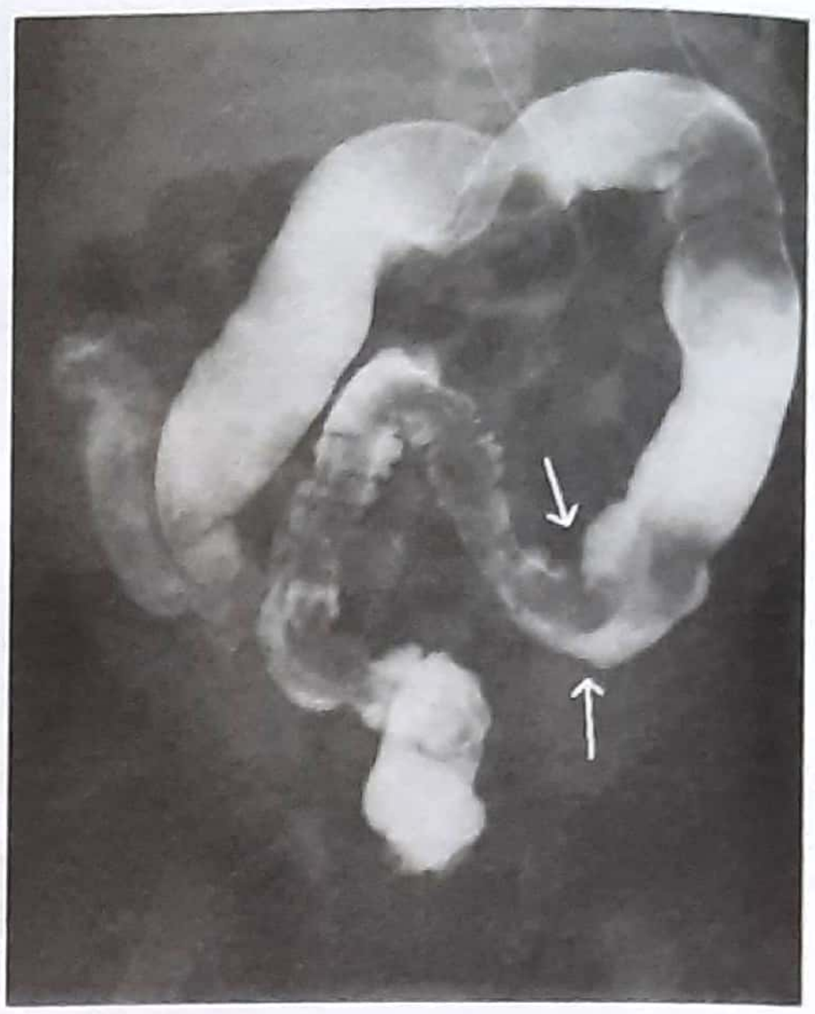

Figure 34.5(b): Hirschsprung's Disease

- As a result of *narrowing & obstruction the colon proximal to the aganglionic segment dilates enomously (hence called as megacolon) leading to abdominal distension* (NEET, AIIMS NOV 99). See figure 34.5 (a & b).

Clinical feature (VERY IMPORTANT FOR PGME)

- Most common presentations abdominal distension.
- Most affected children present soon after birth with *failure to pass meconium* in 24 hours, followed by abdominal distention and bilious (bile containing) vomiting* (MANY PGME). Persistent vomiting lead to loss of fluid and electrolytes; resulting in fluid and electrolyte imbalance
- Stasis of abdominal content leads to growth of bacteria resulting in enterocolitis; which may subsequently result in intestinal perforation and subsequent septicemia.
- In a few cases; the onset is delayed and presents with chronic constipation starting in first few weeks of life.
- Perianal soiling is **not** a feature of Hirschsprung's disease, which is often a feature of idiopathic megacolon. (PGME, AIIMS, PGI)
- Rectal examination reveals empty (no stool in) rectum. (PGME)

Meconium?: First feces of a newborn infant made up of salts, liquor amnii, mucus, bile and epithelial cells, this substance is greenish black. First meconium stool should pass in first 24 hours. Meconium passage persist for about 3 days.

Diagnosis

A. Rectal Biopsy

- *Confirmation of diagnosis depends upon absence of ganglion cells in the biopsy specimen* (NEET, AIIMS NOV 97, PGI 98, MANY PGME).
- *The biopsy specimen is usually taken from just above the anorectal junction.* (MANY PGME)

B. Radiology

Barium enema: It is done by injection the radio opaque Barium (Ba) into the rectum and descending colon and then obtaining a X-ray of abdomen. This will show the dilated proximal segment and the length and site of involved segment of intestine. See figure 34.5b and 34.6.

C. Anorectal Manometry

This is useful test in the constipated young child or adult who is other wise fit.

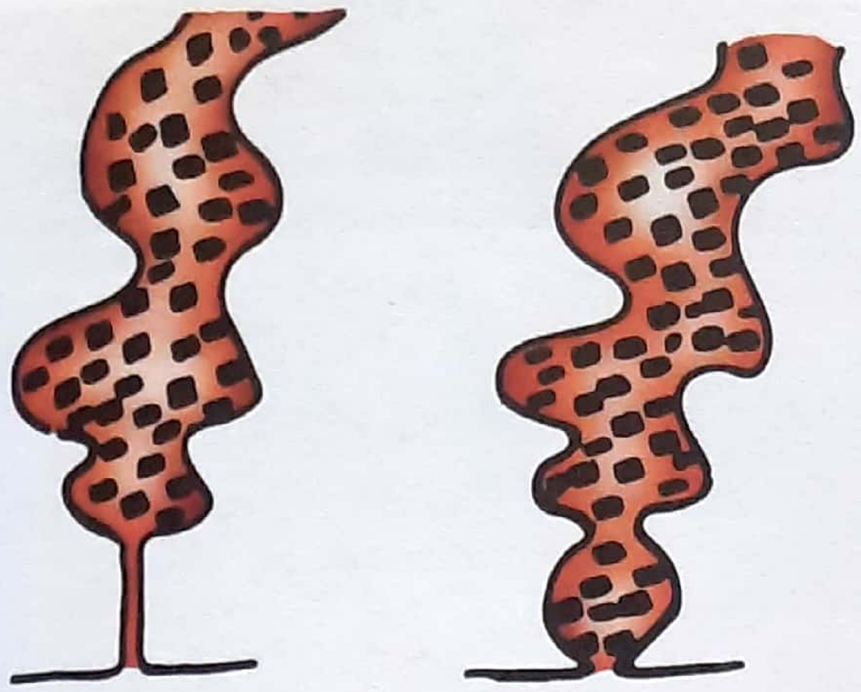

Figure 34.6: Barium enema appearance of megacolon

Treatment

This depends upon the age of the patient, the length of the involved segment, the severity of symptoms and the presence of enterocolitis. Treatment option depends upon the clinical presentation.

Child may present with any one of the below mentioned situations and treated accordingly.

(a) Neonates presenting with enterocolitis and obstruction

An initial colostomy is performed to divert the fecal content away from the diseased segment (this will also relieve obstruction).

(b) Short segment disease with minimal symptoms may respond to an extended myectomy which includes; removal of a strip of rectal wall up to the area where normal ganglion cell start.

(c) Long segment disease

In a neonate definitive *operation is postponed till 10-12 months of life until the child weighs approximately 10kg.* (PGI 79, TN89)

Till then a temporary colostomy is performed. When the child becomes of one year; then the definitive procedures can be performed. The definitive operative procedures are:

- Duhamel operation (UP 01)
- Swenson's procedure
- Soave's operation (coloanal anastomosis)

*****

IDIOPATHIC (SECONDARY) MEGACOLON

(CHRONIC FUNCTIONAL CONSTIPATION)
Syn: Acquired/Secondary megacolon

- The main differential diagnosis to hirschsprung's disease (congenital megacolon) is idiopathic megacolon.

Cause of Acquired Megacolon (Secondary Megacolon)

1. Chagar's Disease : (Trypanosoma cruzi + megaesophagus)
2. Medications: anticholinergic drugs
3. Neurological disorders : paraplegia, poliomyelitis MND, Multiple Sclerosis.
4. Rectal Cancer.

- This usually occurs in older children or in young adults.
- On digital examination (DRE) the rectum is loaded with feces. (cf. Hirschsprung's disease - rectum is empty).
- *Anus in usually patulous and perianal soiling is common* (PGI MAY 05). This may result in habitual constipation.

  [Soiling here means-Presence of fecal matter around the anal verge]
- The rectal biopsy shows normal ganglion cells which helps to differentiate this from Hirschsprung's disease.
- SEE BOX 34.4 (read carefully), on next page.
- **Treatment:** consist of regularization of bowel habits by using laxative and repeated enema.

*****

KEY BOX 34.4		
Differentiation of primary megacolon (Hirschsprung's disease) & secondary (acquired) megacolon		
FEATURES	**PRIMARY MEGACOLON**	**SECONDARY MEGACOLON**
History		
- Incidence	Most common in boys, Boy: girl :: 4:1	Common in boys, Boy: Girl 2:1
- Onset of symptoms	Immediately after birth (few days or weeks)	Few months after birth
- Passage of meconium	Delayed	Normal
- Intestinal obstruction	Occur in 2/3 of cases	Does not occur
- Defecation	Painless	Painful
Signs		
- Abdominal distension	Huge (Mainly gaseous)	Moderate (fecal mass)
- Anal canal	Long	Short
- Rectum	Empty (Scybala high up)	Full of fecal matter
- Rectal biopsy	Abscence of ganglion cells	Normal

ANGIO DYSPLASIA

- Angiodysplasia has been recently recognized as a common and important cause of lower gastrointestinal bleeding
- Angiodysplasia is a vascular malformation associated with aging, probably as an acquired degenerative change.
- Angiodysplasia occurs particularly in the right side of colon, ie; ascending colon and cecum of elderly patients over the age of 40, but may occur anywhere in the gastrointestinal tract.
- Angiodysplasia is characterized by the presence of numerous dilated, tortuous, thin walled blood vessels in the mucosa and submucosa of colon.
- Rupture of these vessels cause painless bleeding; which can be sudden and severe.

Diagnosis

- Selective superior and inferior mesenteric angiography shows the site and extent of disease.
- If this fails, a radio active test using technetium 99m (^{99}TG) labeled red cells may confirm and localize the source of hemorrhage.

Treatment

Some angiodysplastic lesions can be treated by colonoscopic diathermy, but if bleeding is brisk and the patients is seriously ill, surgical resection of the involved segment of colon becomes necessary to control the bleeding at laparotomy.

*****

Figure 34.6 (e): Angio dysplasia on endoscopy

DIVERTICULAR DISEASE

Diverticulum *(pleural- diverticula)* is a sac or pouch in the wall of a tubular organ.

A diverticulum is an outpouching of the mucosa of intestine. They are classified as true and false.

True diverticula (Congenital diverticula)

The wall of true diverticula have *all the layers of the intestinal musculature* such as congenital diverticula eg; Meckel's diverticula.

False diverticula (Acquired diverticula)

These are actually mucosal herniation through the weakened intestinal wall, often at a point of deficiency in the muscularis externa. False diverticula has only mucosa which is covered by fibrous tissue and do not have all muscular layer of intestinal wall. Most of the alimentary canal diverticula are thought to be acquired. Acquired diverticula are **p**ulsion diverticula, ie;- due to increased intra luminal **p**ressure, a portion of intestinal mucosa **p**ouches out. *(PGI JUNE 05, UP PGME)*

Now lets take different small bowel diverticula.

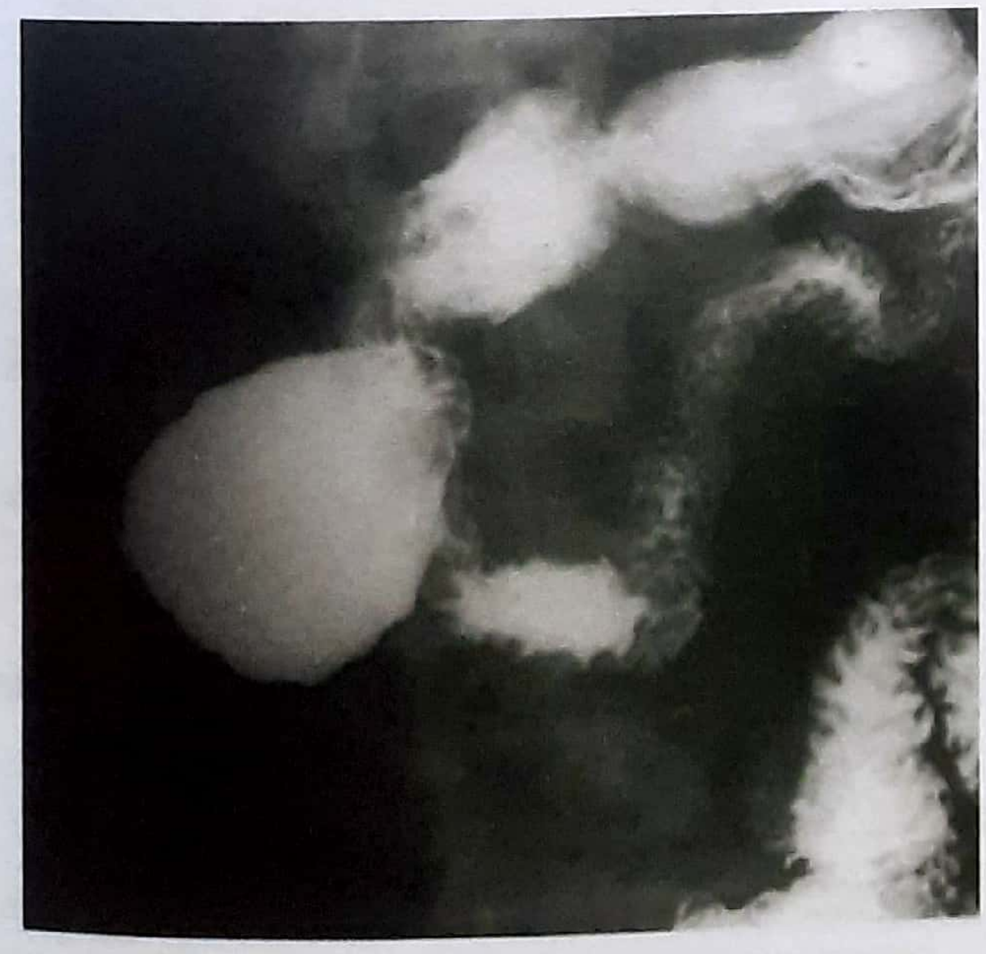

Figure 34.7(a): Duodenal diverticulum

SMALL INTESTINE DIVERTICULA

Most of these diverticula arise from the **mesenteric side of the bowel** *(PGI JUNE 05)*. [Mesenteric side of bowel means; the side of bowel at which the mesentery is attached, see fig. 34.2 & 34.3, page 592]. The cause of diverticula formation at mesenteric border is because of development of potential weakness at point where the blood vessel get entry to small intestinal wall *(PGI JUNE 98)*.

Duodenal diverticula

Most of them occur in older patients on the inner wall of the second and third part. These diverticula are usually asymptomatic and are found incidently on Ba meal X-ray. (Figure 34.7a)

Jejunal diverticula

These are usually multiple and variable in size (fig. 34.7 b, c). A patient may present clinically as:

1. Symptomless
2. Give rise to abdominal pain, flatulence
3. Produce a malabsorption syndrome causing anemia, steatorrhea, hypoproteinemia and Vitamin B12 deficiency.
4. May present as acute abdomen-when inflammation or rupture occurs in a diverticula.

Figure 34.7(b): Jejunal diverticulum

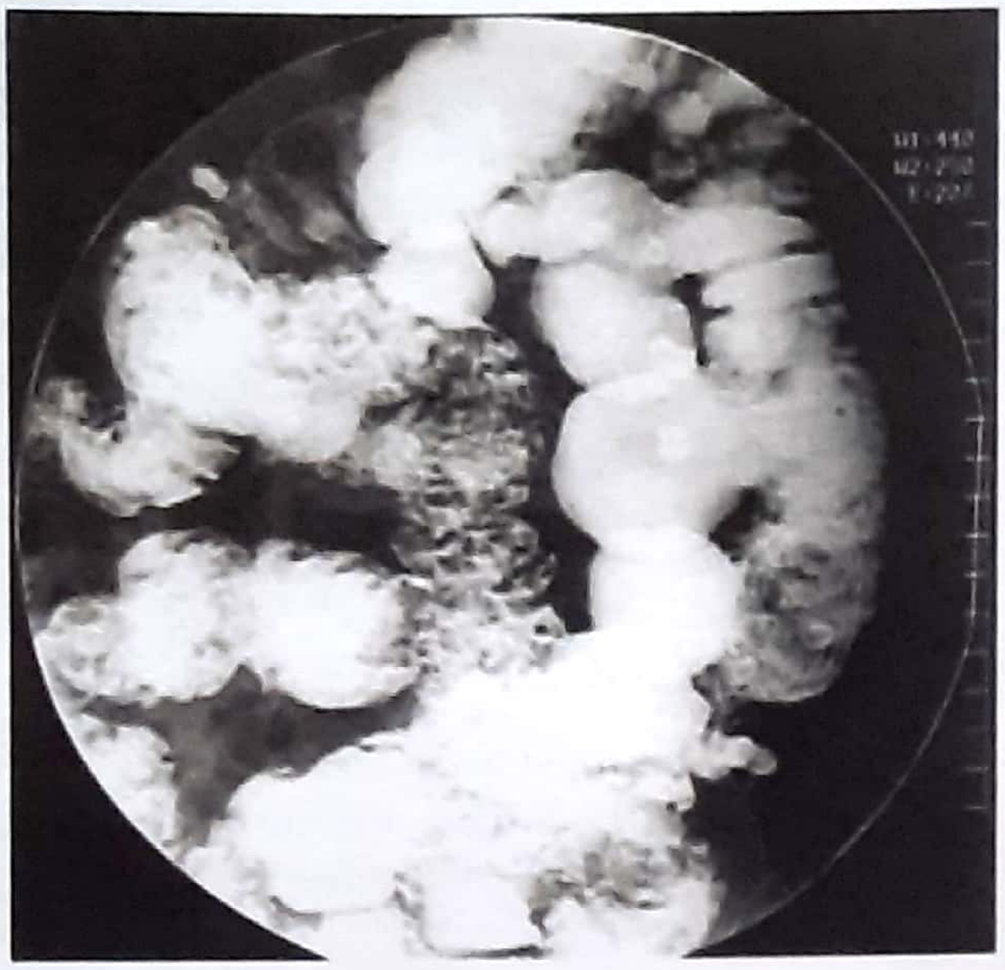

Figure 34.7(c): Contrasted radiograph demonstrating jejunal diverticula

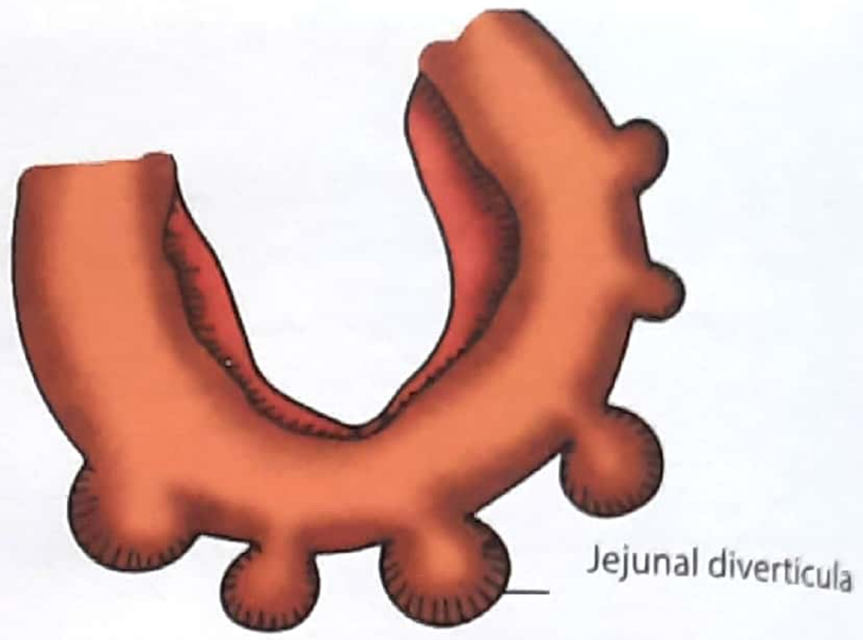

Figure 34.7(d): Jejunal diverticula

Treatment

In serve cases resection of the affected segment with end to end anastomosis can be effective.

Large intestine diverticula has been discussed later in this chapter

*****

MECKEL'S DIVERTICULA (PGI 2010)

First of all; I would like to discuss the vitello intestinal duct and its anomalies. The vitello intestinal duct (or the omphalo mesenteric duct) is the connection between the yolk sac (vitello means yolk sac) and the developing gut (intestine) of a developing embryo.

- Normally, it gets obliterated and disappears at/after birth.
- But sometimes it may persist in various forms giving rise to congenital anomalies. Such as:-

  (a) Umbilical fecal fistula: due to persistence of entire vitellointestinal duct, (fig. 34.8: A)

  (b) Umbilical sinus: When the duct is obliterated at the intestinal end, but communicates with the umbilicus at the distal end. (fig 34.8. B)

  (c) Meckel's diverticulum: when the duct is obliterated at the umbilicus but persists at it intestinal end. (fig. 34.8: C & 34.9)

  (d) Umbilical cyst or vitelline cyst: when both ends are occluded but the tract in between persist. (fig 34.8: D)

  (e) Fibrous band: the entire tract may be obliterated,but a fibrous band may persist between the ileum and the umbilicus. The fibrous band may lead to intestinal obstruction due to rotation (twisting) of small bowel around this band, (fig # 34-8E and 34.10B)

Now lets discuss Meckel's diverticulum.

*****

MECKEL'S DIVERTICULUM (PGI 2010)

- Represents the *patent intestinal end of vitellointestinal duct* (NEET, AI 94, AIIMS MAY 05, UP 07).
- Meckel's diverticulum is situated at the ***antimesenteric*** *border of small intestine (ileum) (fig. 34.9 (a & b))* (NEET, AI96)
- Meckel's diverticulum is a *true diverticulum as it has all the 3 layer of the intestine and* has its own blood supply. (NEET, MANY PGME)
- It is the *most common congenital anomaly* (NEET) of the gastrointestinal tract. (PGI 80, AIIMS 80, 81)
- Male to female ratio is 3:2.
- Approximately 20% of meckel's diverticula contain *heterotopic mucosa, of which more than 50% consists of gastric mucosa (M/C).* (NEET) Second most com-

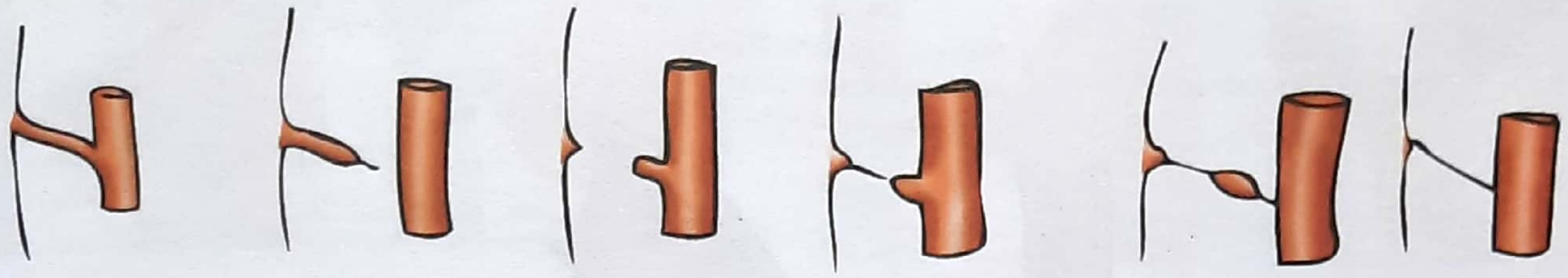

A: Umbilical fistula B: Umbilical sinus C: **Meckel's diverticula** C2: Meckel's diverticula with fibrous band D: Umbilical cyst E: Fibrous band

Figure 34.8: Anomalies of vitellointestinal duct

mon ectopic mucosa is that of **pancreas (pancreatic acini)- 40%** Other mucosa are colonic mucosa, brunner's gland, pancreatic islets, endometriosis and hepatobiliary tissue.

- **Rule of "2"** for Meckel's diverticula. *(PGI JUNE 95 , UP 01, MANY PGME)*
  - Present in 2% of population.
  - 2 inch in length (Usually 3-5 cm)
  - 2 feet proximal to ileocecal valve. *(COMED 07)*
  - (60 cm. proximal to ileocecal junction)
  - 1/2 .of these who are symptomatic, are younger than 2 years of age.

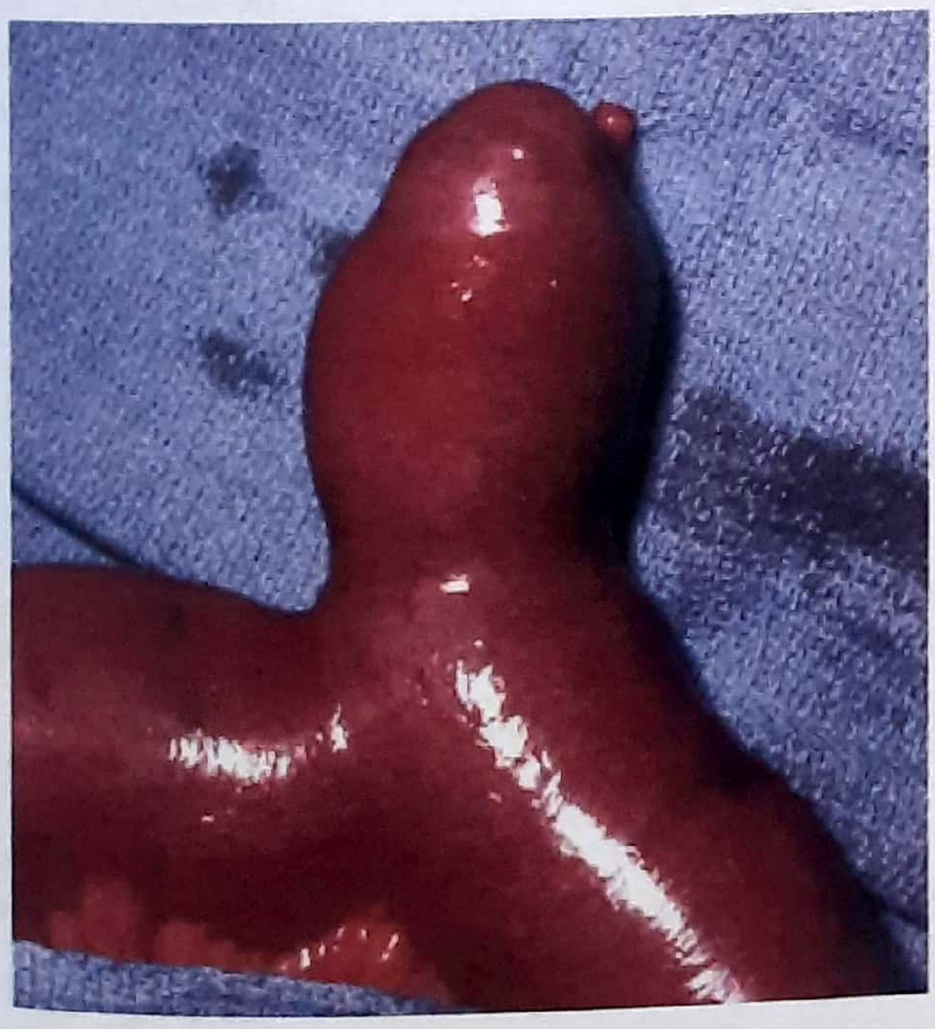

Figure 34.9(a): Meckel's Diverticulum

Clinical feature

1. Majority of meckel's diverticula are *asymptomatic.*
2. When they become symptomatic they present with either of the following:- pain, per rectal bleeding, intestinal obstruction or perforation peritonitis. *(APPG 08)*
3. The ***most common*** clinical presentation of a meckel's diverticulum is gastrointestinal bleeding (melena)

Complication *(PGI JUNE 01, KERALA 86)*

In order of frequency these are

1. Severe Hemorrhage

This is most common complication of Meckel's diverticula. This occurs secondary to peptic ulcer disease, due to presence of heterotrophic gastric mucosa in meckel's diverticulum *(MANY PGME)*.The bleeding is painless and melena can occur.

2. Intussusception

Rarely; the diverticulum inverts into the ileum and acts as **Treatment** the apex of an intussusception, (fig 34.10.D)

3. Meckel's diverticulitis

This is inflammation in a Meckel's diverticulum. *The symptoms closely simulates to that with acute appendicitis and* symptoms may simulate to the symptoms of perforated duodenal Ulcer, (fig 34.10.A)

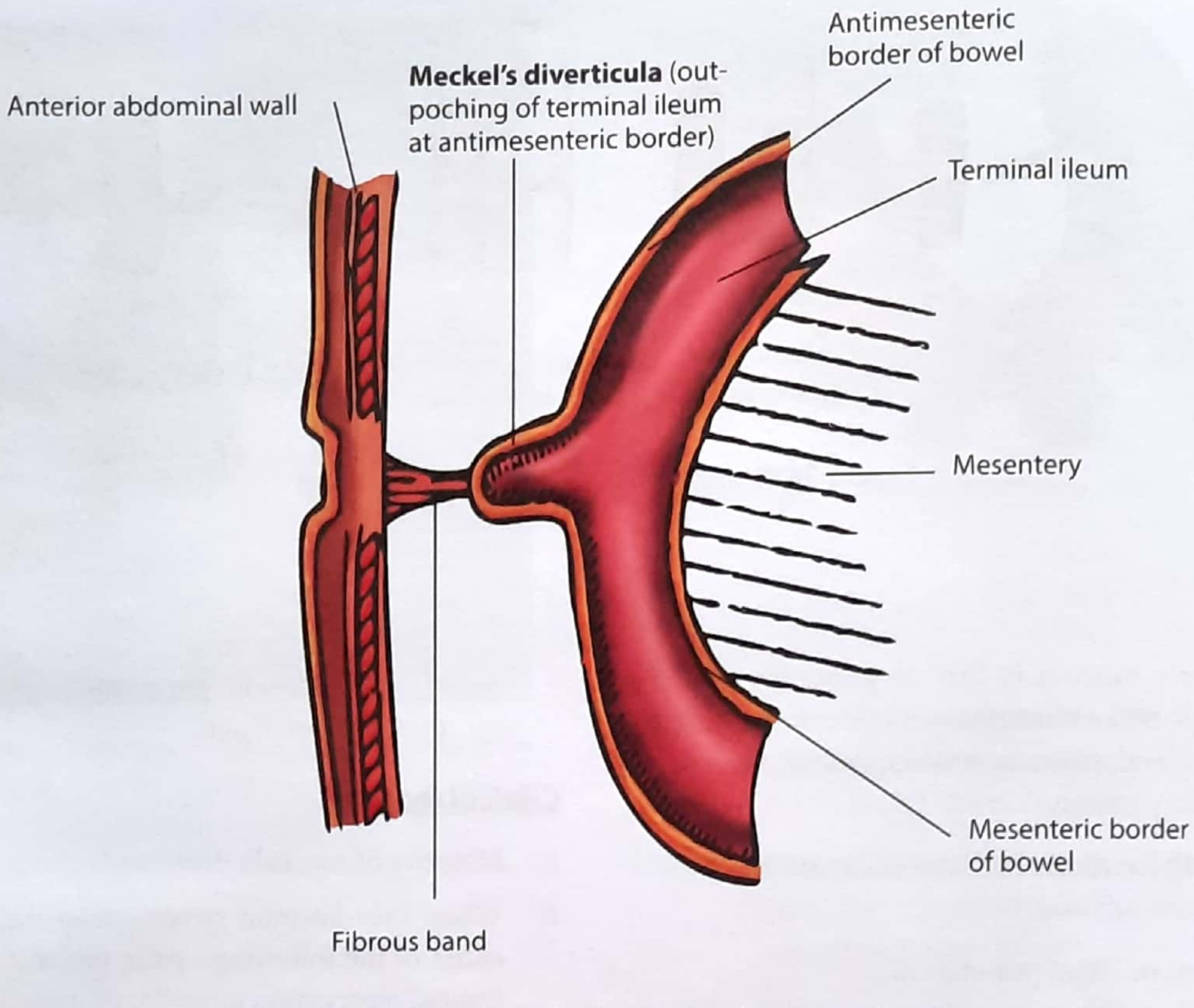

Figure 34.9(b): Meckel's diverticula with fibrous band

4. Chronic peptic ulcer disease

Many patient present with chronic peptic ulcer disease due to presence of gastric mucosa in diverticulum. (Figure 34.10c)

5. Intestinal obstruction

The presence of a band between the apex of the diverticulum and umbilicus may cause obstruction by the band itself, or by a **volvulus** around it. (fig 34.10.B)

Rarely meckel's diverticulum is found in sac of inguinal or femoral hernia. This is known as **litter's hernia.**

Investigation

Ba- X ray study

It is not a very informative study. Meckel's diverticulum can be very difficult to be demonstrated by contrast radiology, because of overlying loops of bowel.

Technetium Pertechnetate radio isotope scanning

If repeated episode of lower GI bleed occurs an ectopic gastric mucosa is suspected, *it can be demonstrated by isotope scanning* (AIIMS JUNE 99, UPSC 04). The isotope is taken by the gastric mucoid cell present in meckel's diverticulum and will show a "hot" spot; usually in lower abdomen; right to the umbilicus.

Treatment

Diverticulectomy

- *Symptomatic meckel's diverticulum* should be resected.
- For *asymptomatic meckel's diverticulum,* It is generally recommended that asymptomatic diverticula found in a children during laparotomy should be resected.
- *While in adults, they should be left as such provided the base in wide* (AIIMS JUNE 97) but, *If the base is narrow, the diverticulum should be resected.* (PGME)

*****

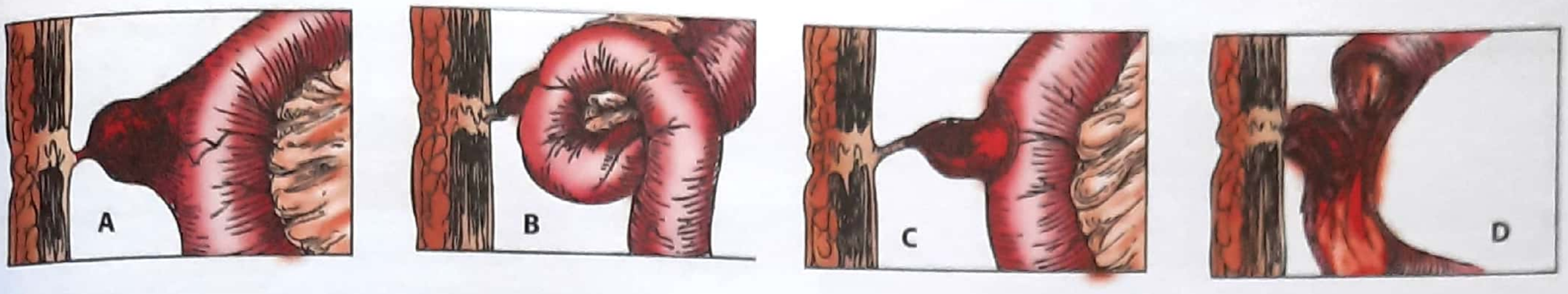

Figure 34.10: Complications of Meckel's diverticula; (A) Acute inflammation causing diverticulitis (B) Volvulus causing intestinal obstruction (C) Peptic ulceration in diverticulum (D) Intussusception.

COLONIC DIVERTICULA

- Diverticula of the colon are acquired *herniation of colonic mucosa through the circular muscle layer of the colonic wall at the mesenteric border** at the points, *where the blood vessels get entry in the colonic wall* (PGI JUNE 98).
- The ***condition is most common in sigmoid colon*** (NEET, AIIMS 97, MANY PGME) but cecum may be also affected.
- Very rarely colonic diverticulosis may involve the entire large bowel, but *rectum is never affected.*
- Size of diverticula vary from, few millimeter to several centimeters in diameter. Fig 34.11 (a, b & c).

Mesenteric border of intestine is that border, at which the mesentery is attached, note that meckel's diverticula arise from anti-mesenteric border, (see fig 34.3 & 34.9)

Etiology

- While diverticulosis of the colon is common in western countries, it is rare in Indian subcontinent. This rarity is due to high fibrous diet of Indians; as compared to the refined low fibrous diet of western world.

Clinical feature

- The prevalence of colonic diverticula is about 25%, in over 40 years and as high as 50% in over 60 years in western countries.
- *In 90% of cases, the sigmoid colon* is involved and is almost always the site of inflammation ie;- **diverticulitis.**
- In some patients colonic dysfunction may cause symptoms of distension flatulence and sensation of heaviness in lower abdomen. If diverticula are extensive, they may cause severe colicy pain in the left iliac fossa.
- **Saints triad:** (UP 03, MANY PGME) This includes:
  - Gall Stone
  - Diverticulitis
  - Hiatus Hernia

Mnemonic: **S**tone **D**iverts **H**ernia

Diagnosis

Colonic diverticulosis remains asymptomatic in most people and is detected incidently on **barium enema X-ray.** In addition to diverticula, barium enema film may show segmental spasm and muscular thickening that narrow the lumen and give it a **"saw tooth"** appearance, **(imp. point).** Barium enema is investigation of choice for diverticulosis. (AIIMS 07)

Treatment

Diverticulosis should be treated with a high fibrous diet. Pain is relieved by antispasmodics.

KEY BOX 34.5

Saint's Triad; Mnemonic "Stone Diverts Hernia"

- Gall Stone
- Diverticulosis of colon
- Hiatus Hernia

Complications (of colonic diverticula)

- Per rectal bleeding,
- Diverticulitis,
- Perforation, leading to peritonitis,
- Pericolic abscess,
- Intestinal obstruction - due to fibrosis
- **Fistula formation**- Vesico-colic, vaginocolic, colo-cutaneous or enterocolic fistula. Vesicocolic fistula, between urinary bladder and sigmoid colon is the most common. *(PGI 81, 89)*
- Anemia.

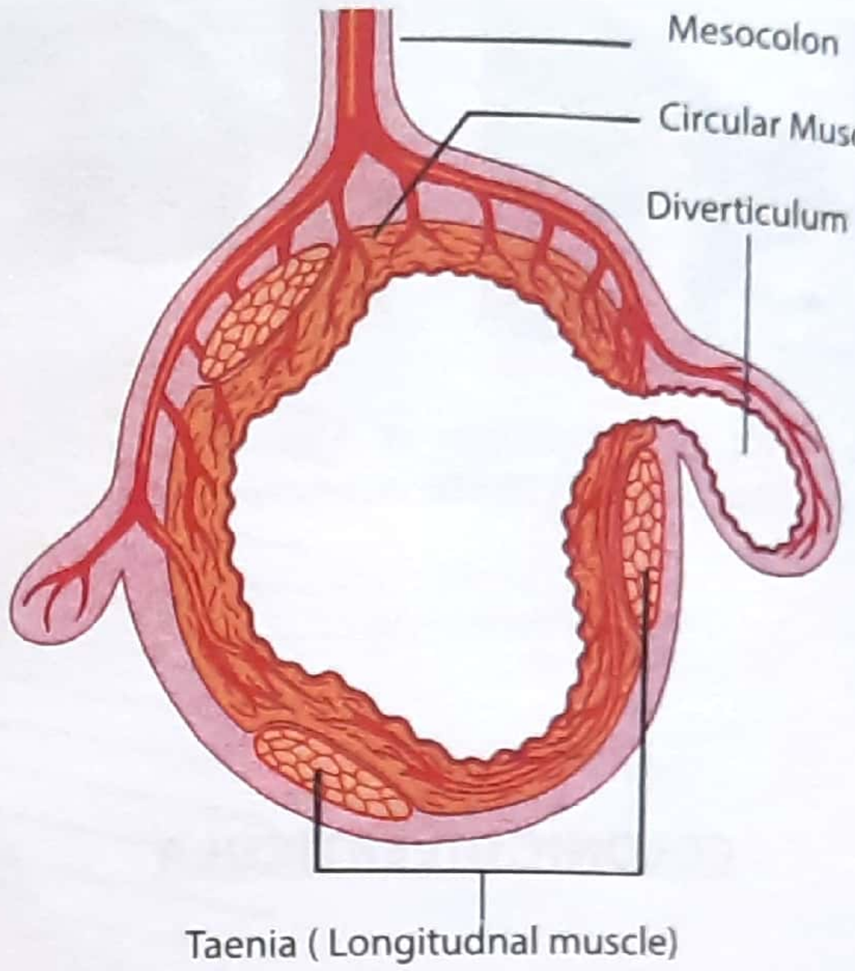

Figure 34.11(a): Cross section of sigmoid colon, showing diverticula

COLONIC DIVERTICULITIS

Inflammation of a colonic diverticula may result in to diverticulitis. Only one diverticulum is involved at a time, usually in the sigmoid colon. Episodes of diverticulitis may be followed by year free of symptoms, but the condition is essentially progressive ie; the longer the duration, the worse are the symptoms and greater is the risk of complication.

Clinical feature

- The acute attack consist of localized abdominal pain, that is mild to severe.
- Infection causes **fever**, leucocytosis and *left lower quadrant abdominal pain*, giving a clinical picture *simulating left sided appendicitis*. *(AIIMS 05,AP, MANY PGME)*

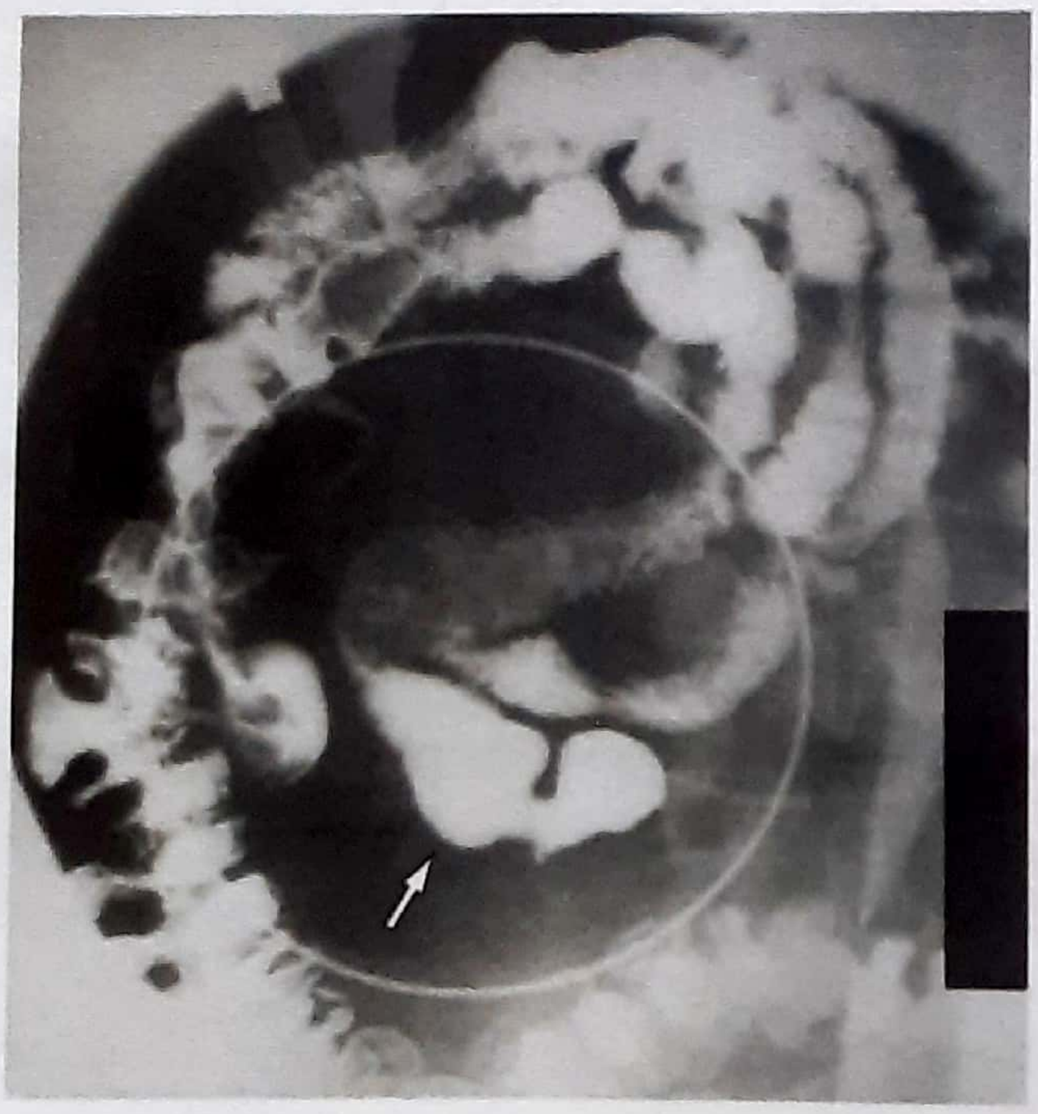

Figure 34.11(b): Barium X-ray study

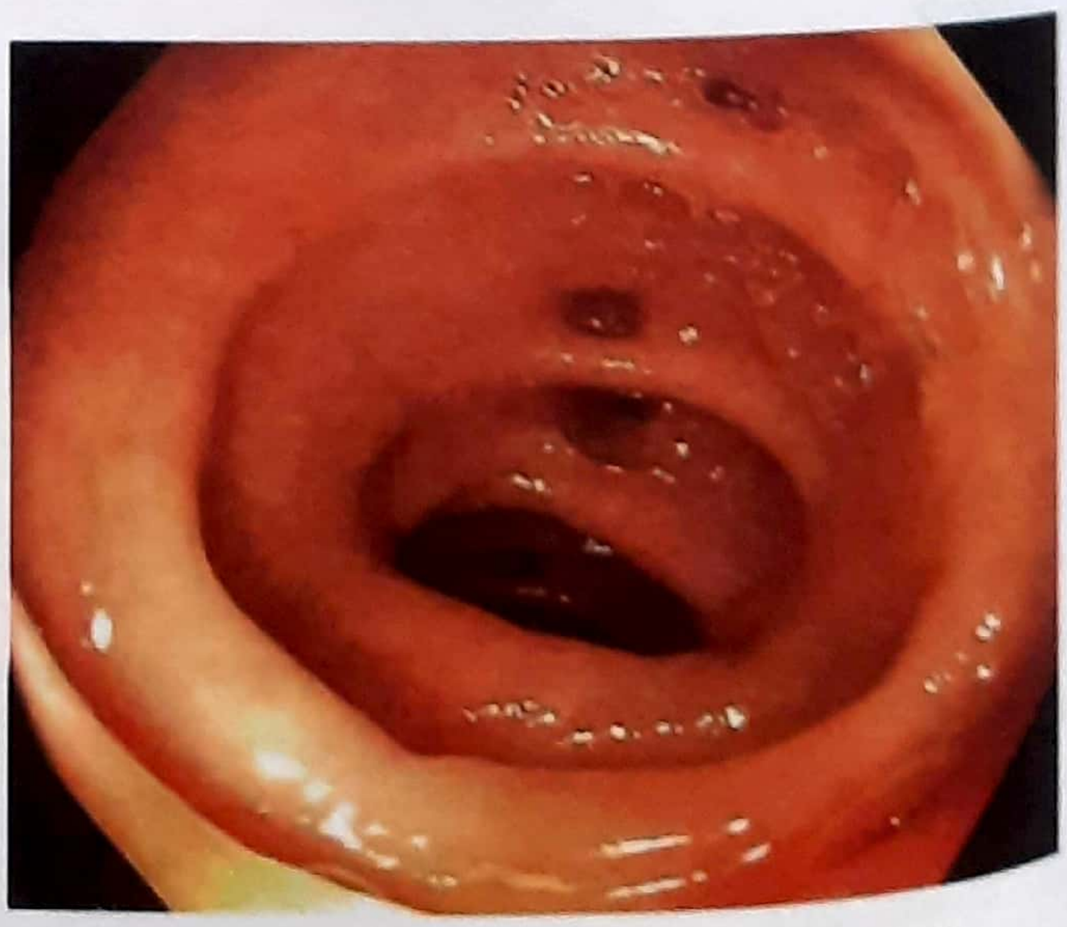

Figure 34.11(c): Endoscopic view of diverticulosis

- Extension of inflammation to the pericolic fat may occur : resulting in **pericolic abscess** formation and/or rupture into peritoneal cavity resulting in **peritonitis.** (Fig. 34.12(a))
- Some patients may present with intestinal obstruction as a result of marked pericolic fibrosis and stricture formation resulting from healed diverticulitis.
- A true left sided appendix is found with situs inversus.

Treatment

Medical treatment should be tried in all cases with first attack of uncomplicated diverticulitis. This includes:-

- Admission to hospital
- Nil orally and Ryle's tube aspiration
- Intravenous fluids
- Broad spectrum antibiotics
- Injection morphine to relieve pain

Significant improvement of all symptoms are expected in 48 hours. If the symptoms are not relieved by medical treatment; then surgery is indicated.

Surgical treatment: Indications of surgical therapy are:

(i) Who do not respond to medical therapy

(ii) Patients who have at least two documented attacks of diverticulitis.

(iii) In all patients with complications; such as diverticulitis with abscess, intestinal obstruction, perforation peritonitis, fistula formation.

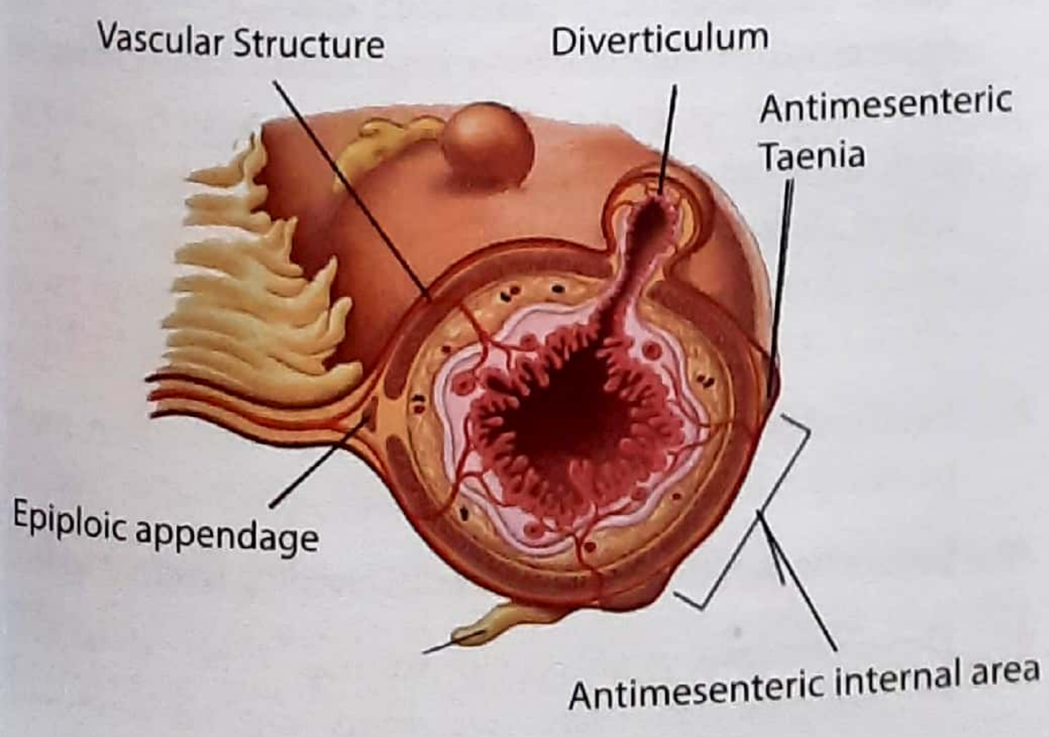

Figure 34.12(a): Cross section through colonic diverticula

Modified Hinchey classification system	
Stage 0	Mild clinical diverticulitis
Stage Ia	Confined pericolic inflammation-phlegmon
Stage Ib	Confined pericolic abscess (within sigmoid mesocolon)
Stage II	Pelvic, distant intraabdominal or intraperitoneal abscess
Stage III	Generalized purulent peritonitis
Stage IV	Fecal peritonitis

Operative Procedure include

- A *Sigmoid colectomy* (excision of sigmoid colon) with colorectal anastomosis [anastomosis between descending colon and rectum] (Note: the disease is most common in sigmoid colon- *(PGME)*
- Primary resection with Hartmann's procedure: Diverticular disease and carcinoma coexist in about 12% of cases. In these case, this procedure may be required. In this procedure permanent end colostomy is done, after resection of diseased part of sigmoid colon. *(IMP. POINT)*

*****

ULCERATIVE COLITIS

Ulcerative colitis is an inflammatory bowel disease of uncertain etiology. It has a chronic course characterized by remissions and relapses. (For hindi speakers kuch din patient theek rahta hai, phir kuch din beemar rahta hai)

This is a very important for PGME examination, but not so for Final prof examination.

Etiology

- The cause is unknown; no infectious agent has been identified.
- Allergy to milk protein has been suggest as a possible cause.
- The sex ratio is equal, it is uncommon before the age of 10 & most patients are between the age of 20-40 years.

- Psychologic stress frequently precipitates ulcerative colitis, leading to the suggestion that the disease has a psychosomatic basis.
- **Three hypothesis** has been proposed for development of ulcerative colitis but none of them has been proved.
  (i) A mucosal immunological reaction.
  (ii) A weakened mucosal barrier
  (iii) Defective mucosal metabolism of butyrates.
- **Smoking** seems to have **protective** effect.

Pathology

Friends! This is a very very important topic for PGME, *not so for final Prof.*

- Ulcerative colitis is a **disease of rectum**, which is involved in almost all cases (AIIMS 87, AIIMS 92)
- The disease starts in rectum, and extends proximally from the rectum in a ***continuous*** *manner without skip areas* (DELHI 95). Total colonic involvement is not uncommon and when the ileocecal valve is incompetent, retrograde ileal may involvement occurs, hence the condition is also called as ***back wash ileitis***. (PGME) *Please see figure 34.13b at page no. 608.*
- It is a nonspecific inflammatory disease, *primarily affecting mucosa and superficial submucosa only* (PGI DEC 01) and only in severe disease; deeper layers of the intestinal wall are affected.

  (**NOTE:** Whole thickness, ie; all four layers of intestinal wall is not involved in ulcerative colitis as that occurs in chron's disease)
- Collar button ulcer is seen.
- When the disease is chronic (ie; long standing), inflammatory polyp ***(pseudopolyp)*** occurs in about 20% of cases and may be numerous. Polyps of ulcerative colitis are inflammatory polyps and have *no (or very little) chances of under going malignant changes.* (AIIMS NOV 02)
- In severe fulminant colitis; a segment of the colon usually the transverse colon may become acutely dilated and the intestinal wall of this segment then becomes extremely thin and may perforate a condition known as **toxic megacolon**. (AIIMS NOV. 94, MANY PGME)
- On microscopic examination there is an increase of inflammatory cell in lamina propria and in the wall of crypts; ultimately resulting in formation of ***crypt abscesses***. (PGME)
- The crypts are reduced in number as a result of inflammatory changes & results in atrophy and irregularity ***crypt atrophy***.
- With the passage of time; these changes becomes severe and precancerous changes develop;which may lead to severe dysplasia or carcinoma in situ. (MANY PGME)

Symptoms

- A patient with ulcerative colitis has, fever, lower abdominal pain and diarrhea with blood and mucus in stool.
- Weight loss is quite common feature of the disease. (PGME, UPSC)
- The disease usually has a chronic course, with remissions and exacerbations.

Disease Severity

Disease severity can be graded as

1. **Mild:** Rectal bleeding or diarrhea with four or fewer motions per day and the absence of systemic signs of disease.
2. **Moderate:** More than four motions per day but no systemic signs of disease.
3. **Severe:** More than four motions per day with one or more signs of systemic illness like; Fever over 37.5°C, pulse rate more than 90 per minute, hypo albuminemia and weight loss more than 3 kg.

Complication (PGI JUNE AI 90, AI 90, AIIMS, UP 97)

1. **Toxic megacolon (Fulminant colitis)** (AIIMS 87) : In severe fulminant disease a segment of colon usually the transverse colon, may become acutely dilated and intestinal wall then becomes extremely thin. On **plain abdominal**; (NEET) X-ray colon appears dilated more than 6 cms. X-ray is the first investigation an is often investigation of choice. (NEET) Figure 34.12(b).
2. **Perforation:** Thin walled, acutely dilated colon may perforate; leading to peritonitis.
3. **Severe hemorrhage:** Severe rectal bleeding is uncommon.
4. **Development of colon carcinoma** (PGI JUNE 99, PGI JUNE 98). Patients *with ulcerative colitis have an increased risk of developing colon cancer. The* over all risk is

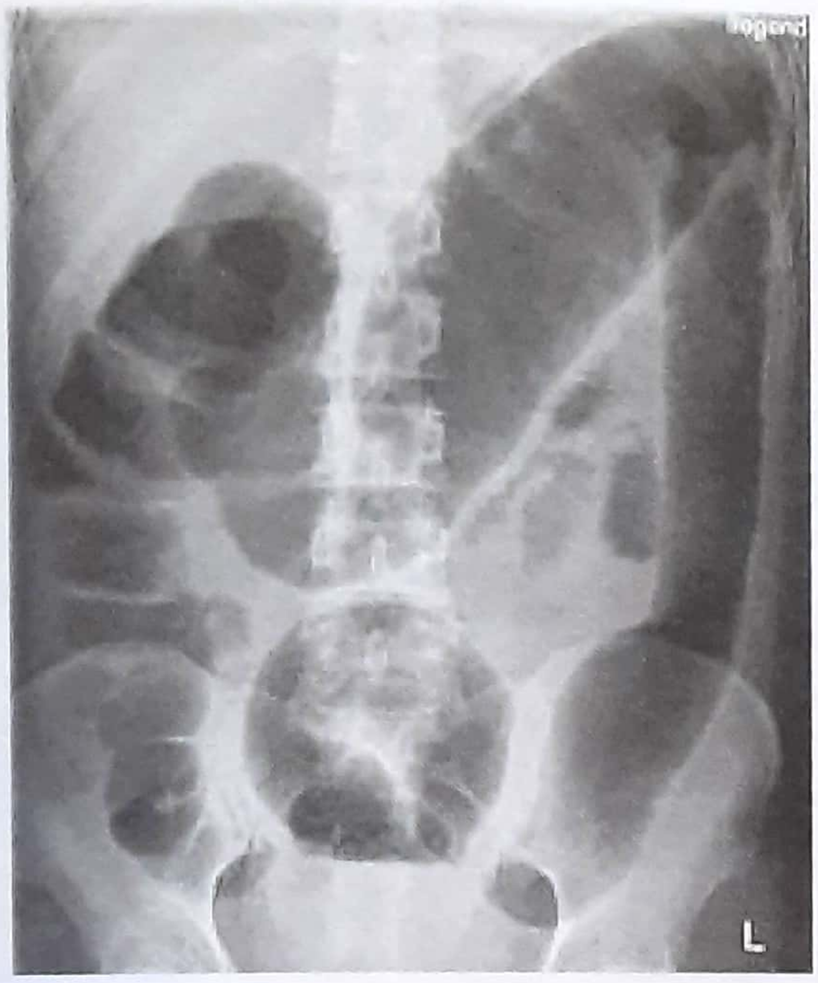

Figure 34.12(b): Toxic megacolon (colon dilated more than 6 cm)

about 3-5%. Epithelial dysplasia precedes carcinoma in most cases. Regular surveillance by colonoscopy and biopsy in indicated in a known patient with ulcerative colitis of more than 10 years duration. The presence of high grade dysplasia in a mucosal biopsy impresses a high risk of cancer and is an indication for colectomy (excision of colon).

Investigation

Barium enema

The principle signs are loss of haustration (especially in distal colon) mucosal changes and pesudo polyps. Hose pipe appearance seen.

Sigmoidoscopy

[This is visualization of sigmoid colon by an endoscope]

Sigmoidoscopy is essential for diagnosis of early disease, that do not show up on barium enema. The initial finding on Sigmoidoscopy are those of proctitis (inflammation), viz; hyperemic [reddish] mucosa; which bleed on touch and pus like exudates.

Colonoscopy and biopsy

Mucosal biopsy taken at colonoscopy are useful in diagnosis. The presence of crypt atrophy, distortion of crypt architecture and an increased number of lymphocytes and plasma cells in lamina propria are helpful in differentiating ulcerative colitis from other causes of acute colitis.

KEY BOX 34.6
Extra Intestinal Manifestations of Ulcerative
COLITIS
• **Arthritis** occurs in about 15% of patients with ulcerative colitis and affects mainly large joints.
• **Sacro-Ueitis and Ankylosing spondylitis are 20 times** more common in patients with ulcerative colitis.•
• **Hepato biliary** disease: *sclerosing cholangitis* **(IOC - MRCP** *(NEET)* has been reported in as many as 70% of patients with ulcerative colitis. **Bile duct carcinoma** has an increased incidence in patients with ulcerative colitis. Surgery for ulcerative colitis does not improve features of hepatobiliary system.
• **Skin lesions** includes: erythema nodosiun, *pyoderma gangrenosum* *(AI 99)* or apthous ulceratioa.
• Eye: Iritis (Uveitis), conjunctivitis, Episcleritis.

However these mucosal change can be seen in both ulcerative colitis and crohn's disease. The **only finding** that reliably differentiate ulcerative colitis and crohn's disease is the *presence of non caseating epithelioid granulomas in crohn's disease.* *(AIIMS, AI, PGI, MANY PGME)*

- Colonoscopy and biopsy can be helpful -

1. To establish the extent of inflammation
2. To distinguish between ulcerative colitis and crohn's disease (by presence of noncaseating epithelioid granuloma in latter)
3. To monitor response of treatment
4. To assess malignant change.

Treatment

(a) Medical management

Patients with long standing disease present with anemia, hypoproteinemia, weight loss and vitamin deficiency, and first; these are to be corrected.

Sulfasalazine *(AI88, AI91)* is the primary drug for ulcerative colitis. 5- aminosalicylic acid component of the drug, which split from sulfasalazine by colonic bacteria is the main agent which acts topically. Newer preparations (mesalazine) which also release 5- Aminosalicylic acid are now available. They have minimal side effects.

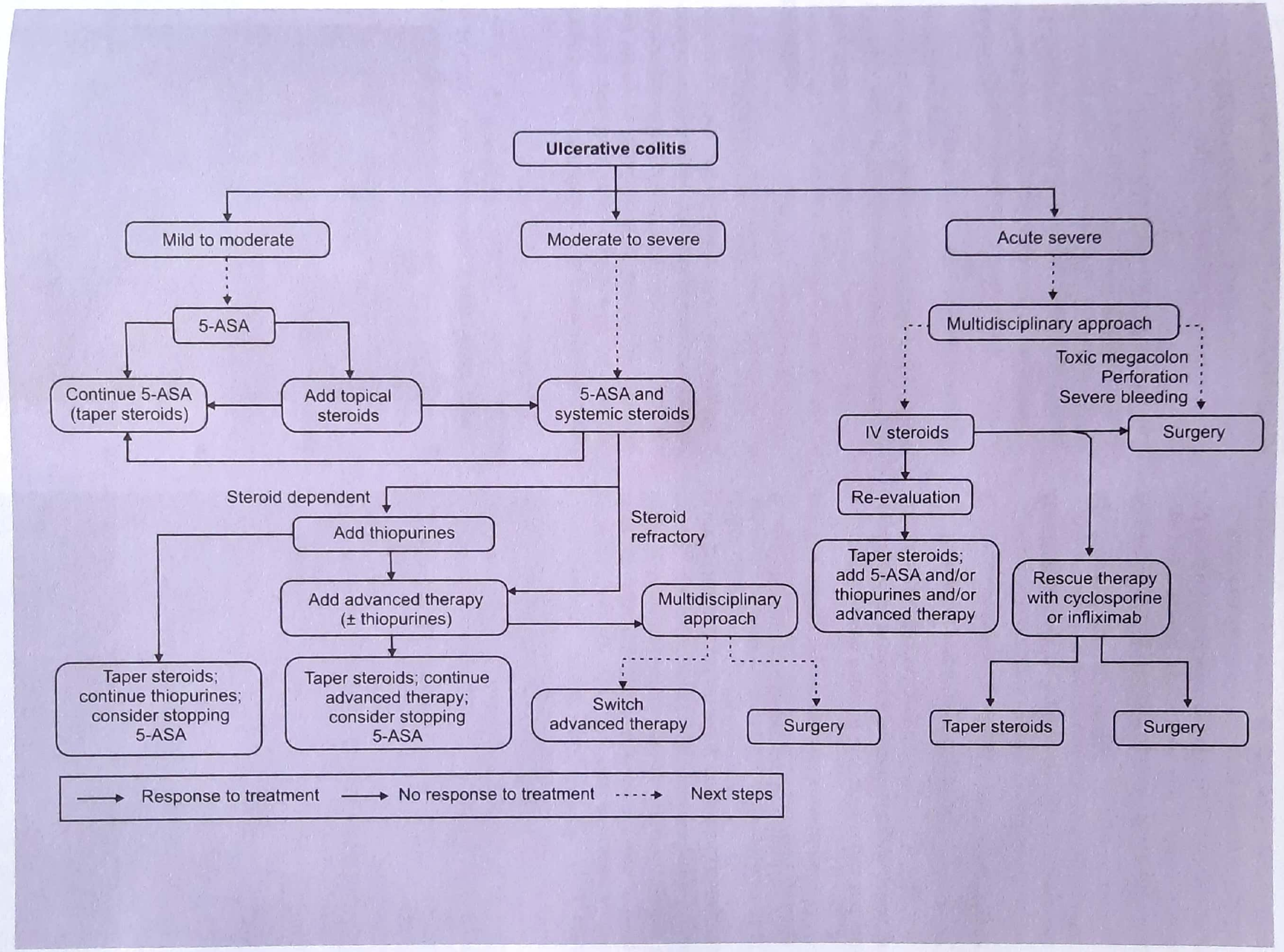
Ulcerative colitis
Mild to moderate
Moderate to severe
Acute severe
5-ASA
Multidisciplinary approach
Toxic megacolon
Perforation
Severe bleeding
Continue 5-ASA (taper steroids)
Add topical steroids
5-ASA and systemic steroids
IV steroids
Surgery
Steroid dependent
Steroid refractory
Re-evaluation
Add thiopurines
Taper steroids; add 5-ASA and/or thiopurines and/or advanced therapy
Rescue therapy with cyclosporine or infliximab
Add advanced therapy (± thiopurines)
Multidisciplinary approach
Taper steroids; continue thiopurines; consider stopping 5-ASA
Taper steroids; continue advanced therapy; consider stopping 5-ASA
Switch advanced therapy
Surgery
Taper steroids
Surgery
Response to treatment
No response to treatment
Next steps

Treatment of acute phase

- Corticosteroids are used in the acute phase of disease. Antidiarrheal drugs such as diphenoxylate and loperamide are useful in acute phase.

(b) Surgical management

Emergency surgery is indicated in:-

(i) Fulminant colitis with perforation

(ii) Toxic megacolon

(iii) Massive hemorrhage

(iv) Suspicion of carcinoma on colonoscopic biopsy

1. Emergency Procedure (AIIMS 86, 88)

Total abdominal colectomy with end ileostomy is done rather than total proctocolectomy. Although rectum is involved in about > 90% cases with ulcerative colitis. Most patients improve-dramatically after an abdominal colectomy only. Note: Proctocolectomy means excision of total colon and rectum, (note: procto= rectum).

2. Elective Procedures (PGI JUNE 05)

(i) Total Proctocolectomy with end ileostomy:

This is still standard procedure. Most of the patient adapt to permanent ileostomy. In 1969; Kock introduced *continent ileostomy (Kock's pouch)*. This procedure is generally done in a patient with chronic ulcerative colitis.

(ii) Total colectomy with ileorectal anastomosis:

This is a good procedure for young patients with mild to moderate disease. In this procedure total colon is removed and anastomosis is made between remaining bowel that is; ileum and rectum (ileorectal anastomosis).

(iii) Total Procto-colectomy with Ileal (pouch) analanastomosis:

This is now **procedure of choice** (AIIMS JUNE 95). In this procedure total colon and rectum is excised (cut and removed) and ileum is brought down in pelvis and anastomosed (sewed) to anal canal; ileo-anal anastomosis above the dentate line. Before anastomosing ileum to anal canal a pouch either **J** shaped or **W** shaped is made in ileum. This decreases the transit time of contents in ileum. This is called as ileal pouch-anal anastomosis.

*****

CROHN'S DISEASE

- Crohn's disease is a chronic inflammatory disorder that affects most commonly the ileum accounting for 60% of cases and colon accounting for 30% cases but has potential to involve any part of gastrointestinal tract from the lip to the anal margin.
- It is slightly more common in women than men and is most commonly diagnosed in young patients between the ages of 25 to 40. There does however seems to be a second peak of incidence around the age of 70 years.
- Crohn's disease has a familial tendency with about 30% patients giving a positive family history, however there is no inheritance pattern and the familiar tendency is likely to be the result of sharing the common environment.

Etiology

- The cause of crohn's disease is unknown. Despite extensive study, no infective agent has been found; though similarities between crohn's disease and tuberculosis have focused attention toward *mycobacteria.*
- There is strong but nonconclusive evidence that crohn's disease is the result of some immunological injury. Antibodies with activity against intestinal epithelial cells has been identified in the serum of patients with crohn's disease.
- More recently; focal ischemia has also been postulated as a possible causative factor.
- Patients with crohn's disease frequently have T cell dysfunction.
- *Smoking increases the risk three folds.* (NEET) *(Note : Smoking seems to have protective effect for Ulcerative colitis)*

Pathology

A. Site of involvement

Terminal ileum is the most common site involved in crohn's disease (NEET, MANY PGME). Next most common site is colon. Involvement of the oral cavity, larynx, esophagus, stomach and perineum are rare. (Figure 34.13 (a & b))

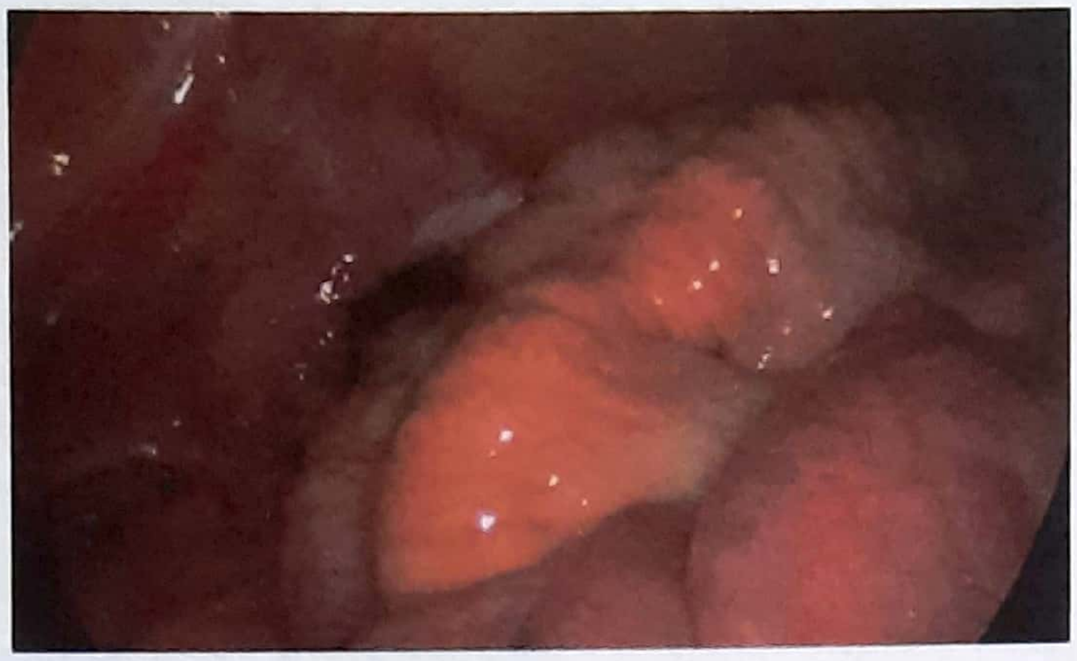

Figure 34.13(a): Crohn's disease

Patients with crohn's disease commonly has perianal lesions (AI, PGI97) *such as perianal abscesses, fistula in ano and skin tags. Perianal disease occurs in both Ileal and colonic disease and is not dependent on the presence of rectal involvement.* (PGME)

B. Gross appearance

Involvement is typically segmental with discontinuous involvement of intestine. Word discontinuous here means that, disease (ie; inflamed) areas of intestine is separated from normal intestine. Normal and affected (diseased) intestine are sharply demarcated from one another. On gross appearance, it appears that disease has *skipped* (left/omitted) patches of intestine - ***These lesions are called as skip lesions**** (NEET, AIIMS NOV 94, AIIMS 91)

- In chronic phase, the affected segment is greatly thickened and becomes rigid giving rise to "*lead pipe*" or "*garden hose*" appearance. (PGI JUNE 2000) (*Figure 34.13(e)*)
- Marked *fibrosis causes luminal narrowing and stricture formation; which leads to intestinal obstruction.* (AIIMS JUNE 2000).
- In ileal involvement of Crohn's disease, the fat, which is normally present in the mesentery, moves slowly over the ileal wall and surrounds the ileal wall; called as "*creeping fat*" (UP, AI)

Important Notes:

In Crohn's disease; a part of intestinal wall is pathologically involved, but at the same time another part of adjacent intestinal wall is pathologically normal, ie; the disease does not involve intestinal wall in continuous manner but it involves the intestinal wall in patches. The normal areas of intestinal wall which is not involved by the disease, ie; skipped (left) by the disease is called as "skip lesion" (MANY PGME)

In Ulcerative colitis intestinal wall is continuously involved.

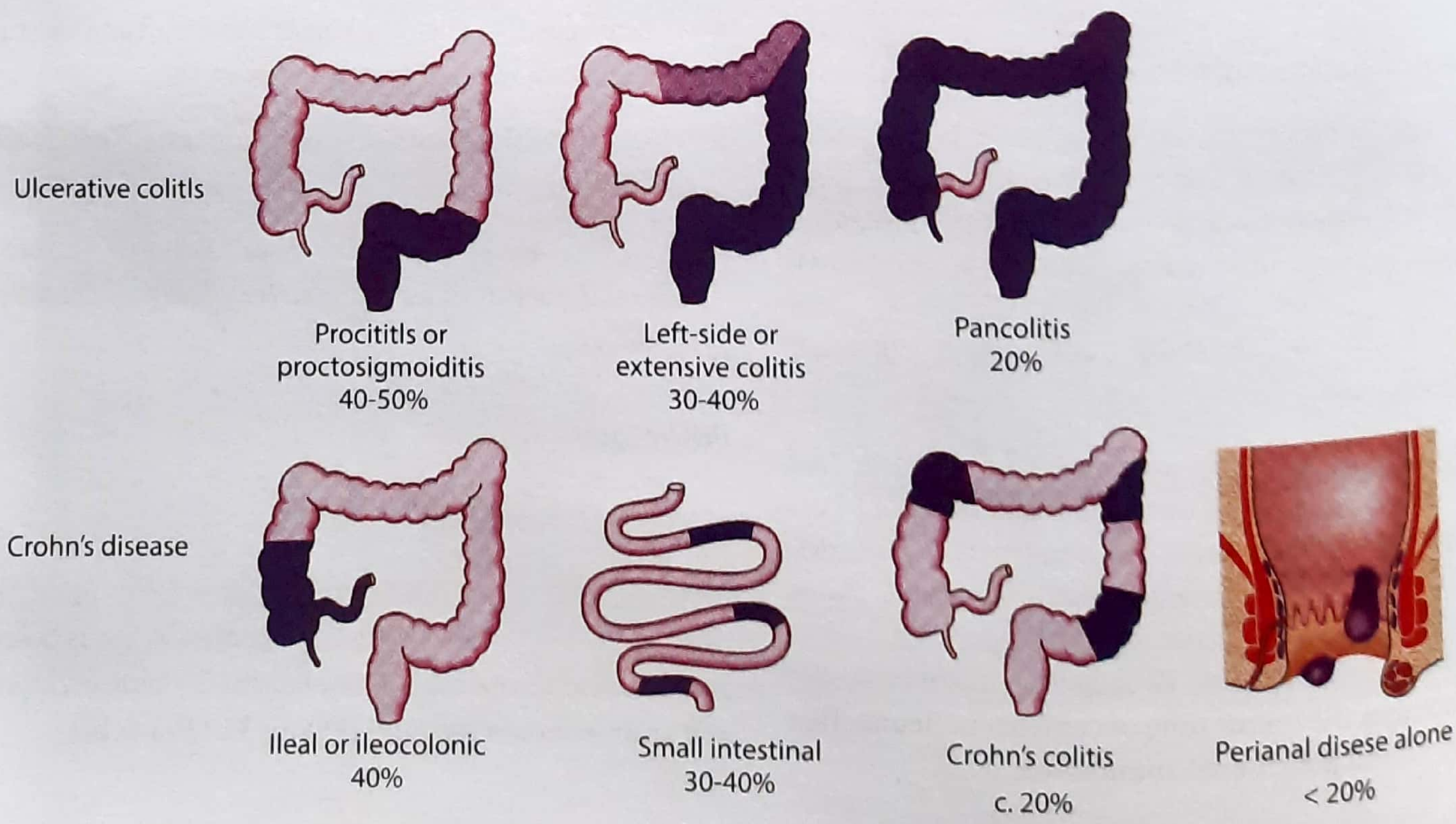

Figure 34.13(b): Note the pattern on involvement of intestine in Ulcerative colitis and Crohn's disease

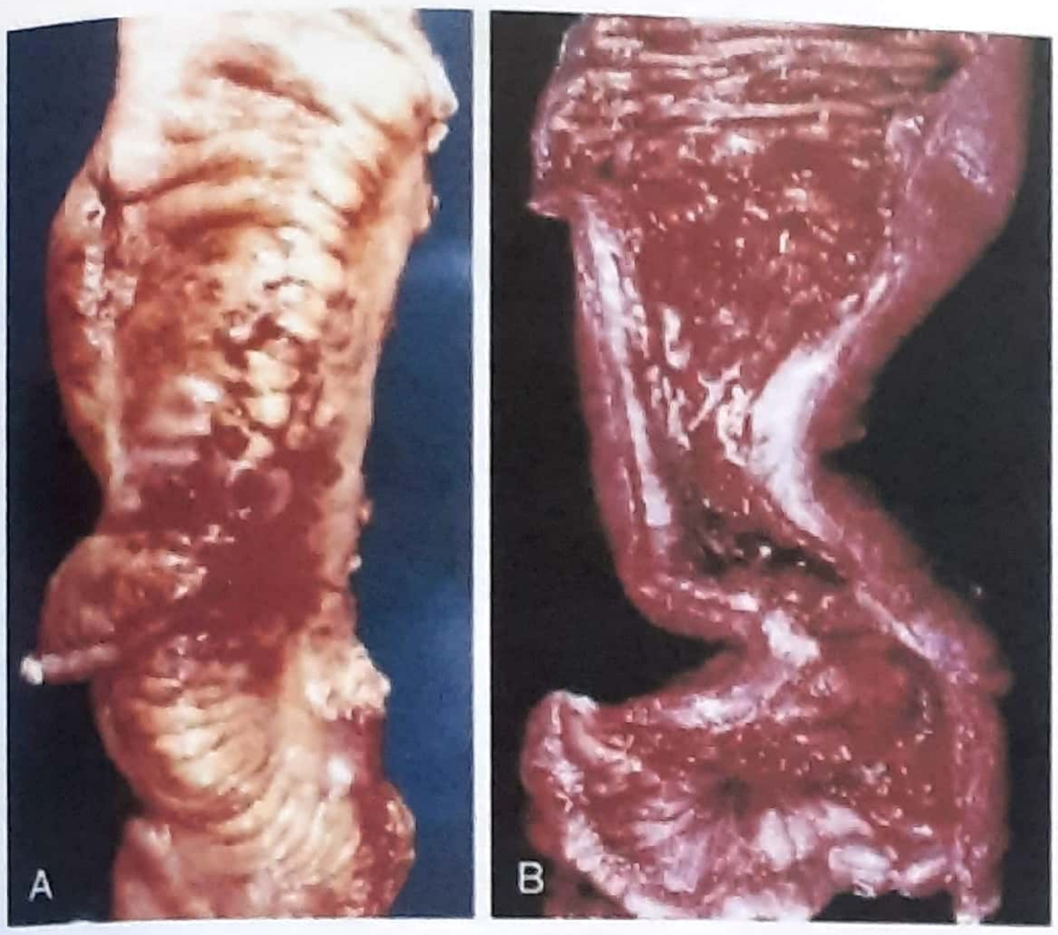

Figure 34.13(c): Gross pathologic features of Crohn disease. (A) Serosal surface demonstrates extensive fat wrapping and inflammation. (B) Re-sected specimen demonstrates marked fibrosis of the intestinal wall stricture, and segmental mucosal inflammation.

C. Microscopic features

- The *earliest mucosal lesion are discrete apthous ulcers.* (MANY PGME)
- Crohn's disease *involves full thickness* of the intestinal wall (AIIMS NOV 94) ***[trans-mural]***.

NOTE: Ulcerative colitis involves only mucosa and superficial submucosa are involved. Full thickness ie; all four layers of intestinal wall is not involved.

- Due to full thickness involvement of intestine in crohn's disease; *fistula (communication between two viscera) may be present.*
- The mucosal surface of intestine shows longitudinal snake like ulcers ***(Serpiginous ulcer)*** and shows a ***cobblestone appearance.*** (MANY PGME)
- Pseudopolyps and mucosal bridges are seen.

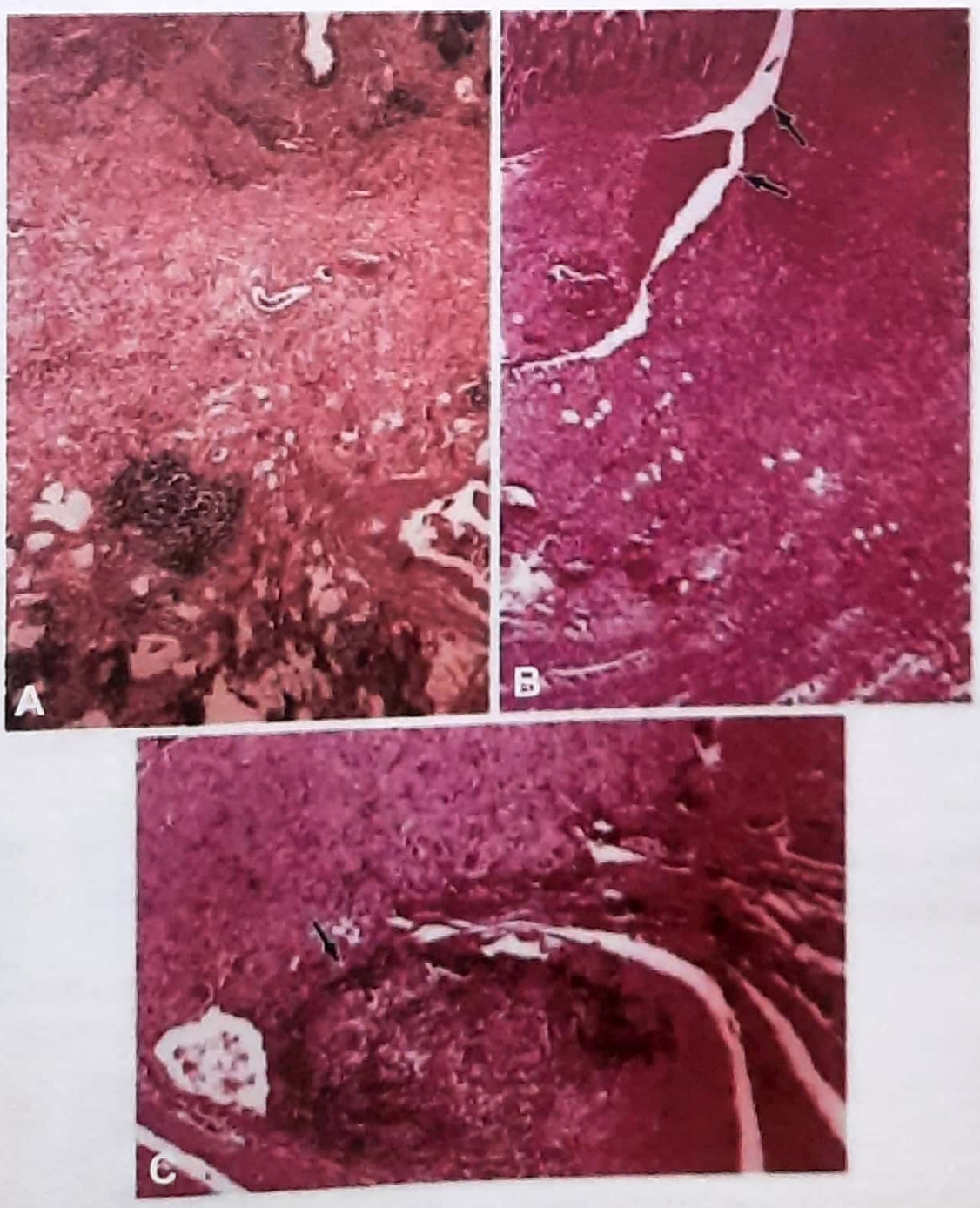

Figure 34.13(d): Microscopic features of Crohn disease. (A) Transmural inflammation (B) Fissure ulcer (*arrows*) (C) Noncaseating granuloma located in the muscular layer of the small bowel (*arrow*)

Figure 34.13(e): Lead pipe sign/Garden hose sign

- A ***Non-caseating giant cell granuloma*** (AIIMS 91) is the diagnostic histological feature but occurs in only 60% of patients.

Clinical feature

Acute crohn's disease

Acute crohn's disease occurs in only 5% of cases. Symptoms and signs resemble those of acute appendicitis. Rarely, there could be perforation of intestine; resulting in peritonitis. Acute colitis with or without toxic megacolon can also occur in Crohn's disease, but is less common than in ulcerative colitis.

Chronic crohn's disease

Chronic disease is characterized by remissions and relapses over a long period of time. Asymptomatic periods may last several months. With the passage of time, weight loss and anemia appears, thickening of the intestine may produce an ill-defined mass in the abdomen.

Diagnosis

Radiology

The principle finding of small bowel during barium meal follow through include thickening of bowel wall with stricture ie; ***String sign of kantor*** (MANY PGME, UP 05, APPG 08)

Deformity of the cecum, fistulas, abscesses and skin lesions are additional finding of importance. Other important investigations include:

- Sigmoidoscopic examination
- Colonoscopy
- *Abnormal D-xylose absorption* suggests extensive disease or fistula formation, since carbohydrate is normally absorbed in the jejunum.

Complication

1. Crohn's disease may be complicated by intestinal obstruction or by *fistula formation* between loops of bowel and adjacent viscera. (AIIMS 2000, UP 08)
2. Fistulas *(abnormal connection between two organs)* between ileum and colon results in malabsorption, where as *entero vesical fistula* between bowel and urinary bladder leads to urinary infections and passage of gas *(pneumaturia)* and feces in urine. (Figure 34.13F, page 613)
3. Extensive disease of terminal ileum results in malabsorption syndrome in which there may be failure of absorption of vitamin B and bile acid; resulting in megaloblastic anemia and fat malabsorption. Iron deficiency anemia may also occur as a result of chronic occult bleeding
4. *Extra-intestinal manifestation* (MANY PGME) include ankylosing spondylitis, arthritis and uveitis. Extra intestinal menifestations are less common than ulcerative colitis.
5. Crohn's disease carries a *slight increased risk of development of carcinoma of the colon,* but much less than ulcerative colitis. (IMP. POINT) However, is the most common cause of death due to ulcerative colitis. (AIIMS 09)
6. Most common cutaneous manifestation in inflammatory bowe disease: erythema nodosum in crohn's disease and pyoderma gangrenosum in ulcerative colitis. (Figure 34.13E1, page 613)

Please read flow chart and key box 34.7 on page 612 before moving forward.

Treatment

It is empirical and symptomatic. Surgical intervention is reserved for specific problem and should not be regarded as curative.

THIRTY FOUR

Inflammatory Bowel Disease :

Clinical findings in Crohn's Disease

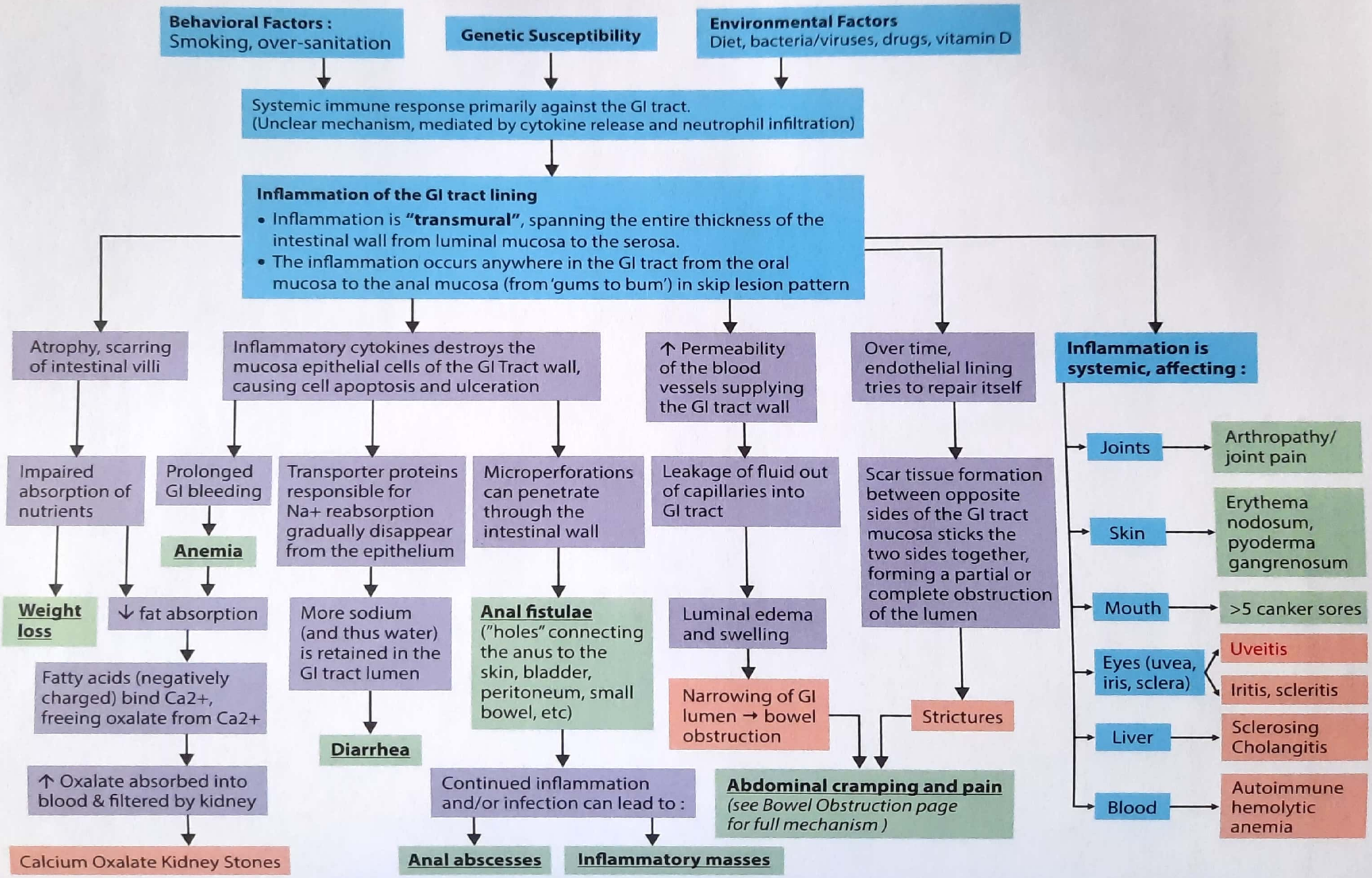

KEY BOX 34.7		
Difference Between UJlcerative Colitis and Crohn's Colitis		
Clinical Features	**Ulcerative colitis**	**Crohn's colitis**
Rectal involvement	Over 90%	Rectum spared in > 50%
Distribution of lesions	Continuous	Skip lesions
Mucosal appearance	Friable, purulent, diffusely involved	Aphthous, linear ulcers with cobblestones
Associated ileal disease	10% mild, terminal ileal inflammation	50% have combined ileal and colonic involvement
Perianal abscess, fistulas	Rare	Common
Intestinal strictures and obstruction	Not seen	Common
Intestinal fistula	Not seen	Common
Fissures (radiologic)	Not seen	Common
Intestinal perforation	Rare	Rare
Intestinal hemorrhage (Severe)	Common	Rare
Toxic megacolon	Rare	Very rare
Extra intestinal manifestations	Common	Rare
Sclerosing pericholangitis	Common	Rare
Uveitis or arthritis	Common	Common
Pyoderma gangrenosum	Rare	Not seen
Pathologic features		
Depth of inflammation	Mucosal (rarely submucosal)	Transmnral (Through the wall)
Creeping mesenteric fat	Not seen	Common
Fibrous thickening of wall	Not seen	Common ("lead pipe")
Crypt abscesses	Common	Common
Pseudopolyps	More common	Common
Granulomas (epithelioid, noncaseating)	Not seen	Common (IMP. POINT)
Fissures (microscopic)	Not seen	Common
Dysplasia	Common	Rare
Carcinoma	About 5%	Rare (1%)
Stricture	Rare	common

A. Medical treatment

Consists of nutritional support and oral medication.

Drugs used

- Sulphasalazaline
- Immunosuppresion (azathioprine and cycloserine)
- Steroids (usually prednisolone)
- Metronidazole and antidiarrheal drugs

Figure 34.13(E1): Crohn disease patient with erythema nodosum

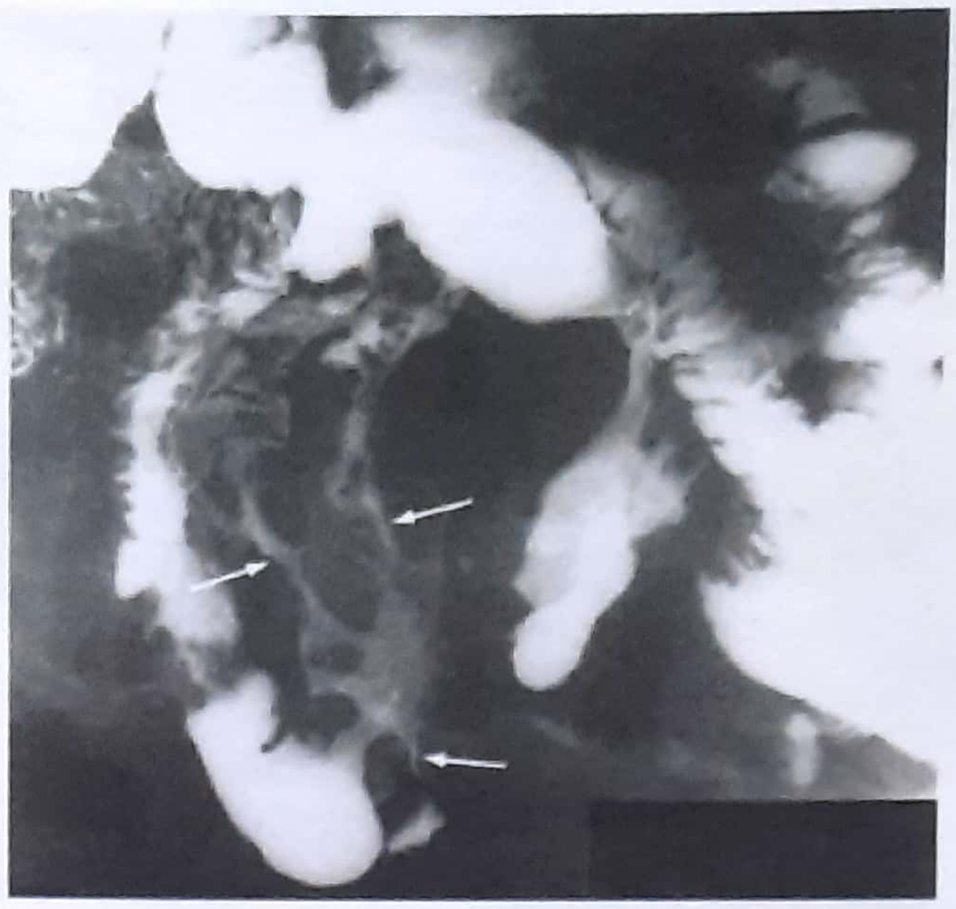

Figure 34.13(f): Intraabdominal fistulas in Crohn disease

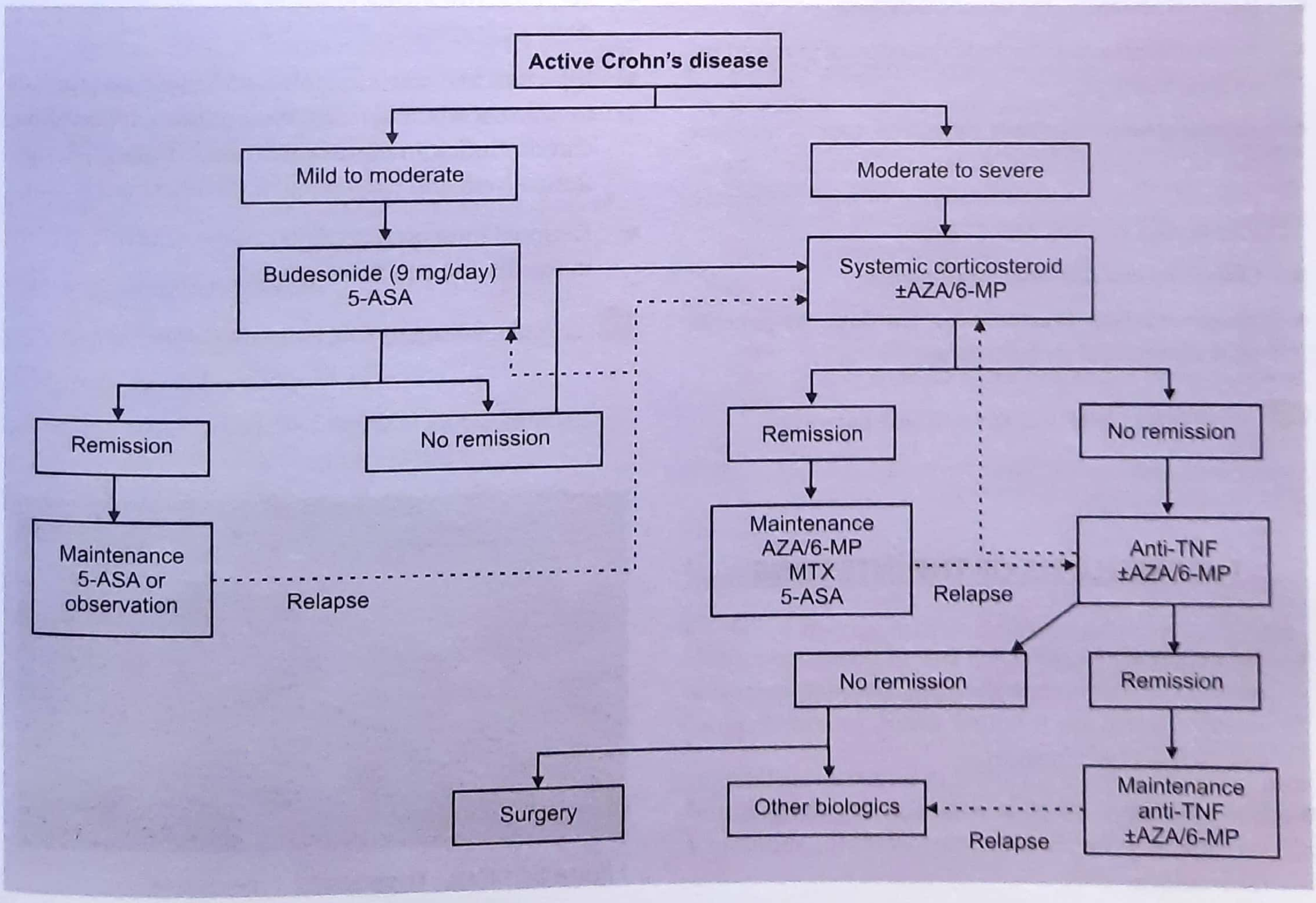

KEY BOX 34.7.1

Contraindications to stricturoplasty

- Excessive tension due to rigid and thickened bowel segments
- Perforation of the intestine
- Fistula or abscess formation at the intended stricturoplasty site
- Hemorrhagic strictures
- Multiple strictures within a short segment
- Malnutrition or hypoalbuminemia (<2.0 g/dl)
- Suspicion of cancer at the intended stricturoplasty site

B. Surgical Treatment

This is to be considered when the disease does not respond to medical treatment and for complications. Surgical treatment should not be considered as curative.

The choice of surgical procedure depends upon the site and character of disease and its complication. The operative procedures are:-

- ***Ileocecal resection***- for ileocecal disease
- ***Segmental resection***- include resection of involved intestinal segment.
- ***Stricturoplasty***- Multiple strictured area of intestine can be treated by local widening procedure; sticturoplasty. For contraindications of stricturoplasty. Please read key box 34.7.1 above.
- ***Colectomy and ileo-anal anastomosis***
- ***Temporary loop ileostomy***-can be done in patients with acute distal crohn's disease.

MUST READ CAREFULLY KEY BOX 34.7, page 612

*****

TUBERCULOSIS OF THE INTESTINE

- Tuberculosis can affect any part of the gastro intestinal tract from mouth to the anus. The sites *most commonly* affected are terminal ileum, proximal colon, stomach and peritoneum.
- Ileocecal TB - multiple adhesion are formed, and surrounding fat is also involved in abdominal tuberculosis.

Tuberculosis of the intestine occurs in **two forms.**

1. Primary infection is usually due to bovine (animal) strain of mycobacterium tuberculosis and results from ingesting infected milk. This produces **Hyper plastic tuberculosis** and involves **most commonly ileocecal region** (AIIMS JUNE 97, AI 01, UP 2000, AI 89) (Figure 34.14a)
2. The more common form; **Ulcerative tuberculosis** is secondary to pulmonary tuberculosis and arises as a result of swallowing his own sputum containing mycobacterium tuberculosis by a patient. Ulcerative form has been found more often in malnourished adults, while hyperplastic form is classically found in relatively well nourished adult. (figure 34.14d, page 616)

Now lets take both forms one by one:

1. HYPER PLASTIC ILEOCECAL TUBERCULOSIS

- This is caused by ingestion of mycobacterium tuberculosis by a patient, who has high resistance to the organism.
- *Terminal two inches of ileum and the cecum is most commonly affected.* (MANY PGME)
- Infection first starts in lymphoid follicle and spreads to submucous and subserous plane and resulting chronic inflammation causes thickening of the intestinal wall and narrowing of the intestinal lumen.
- Regional mesenteric lymph nodes are involved early in the disease and may caseate*.

Caseation-means turning into a cheese like material.

Figure 34.14(a): Hyperplastic Tuberculosis

- Unlike crohn's disease; which closely simulates hyperplastic tuberculosis; abscess and fistula formation is rare in abdominal tuberculosis.
- If untreated; Sub-Acute Intestinal Obstruction (SAIO) or Acute Intestinal Obstruction (AIO) or perforation of intestine proximal to a stricture may occur. *(PGI DEC 99, PGI JUNE 96)*. This is due to narrowing of the lumen of the involved segment; secondary to fibrosis.

Clinical feature

Female out number male by 2:1, usual age of onset is between 20-40 years.

1. **Attacks of abdominal pain:** Off and on due to sub acute intestinal obstruction are often the first symptom (80-90% cases) this may be associated with intermittent diarrhea in about 20 percent cases.
2. **Features of "blind loop syndrome"** may develop due to partial obstruction in the ileum leading to stasis, distension and subsequent infection. Anemia (due to vit B_{12} malabsorption), loss of weight and steatorrhea are the common features of blind loop syndrome.
3. **Abdominal lump:** Some times; a lump in the right iliac fossa is present *(UP 2000)*. In Indian subcontinent hyperplastic ileocecal tuberculosis is often the first D/D for right iliac fossa lump.
4. **Fever:** Evening rise in temperature may be present.

Radiological examination

No other investigation is as much suggestive as a barium meal follow through X-ray. This shows *(UP 2000)*

1. ***Narrowing of the affected segment*** ie; the terminal ileum and the cecum. (Figure 34.14b)
2. ***Pulled up cecum**** *(NEET)*- the cecum is pulled up and may appear subhepatic on X-ray. *(PGME)*
3. As the cecum is pulled up, hence the ileocecal angle* is widened (becomes obtuse; see below). *(PGME)* (Figure 34.14b)
4. OTHER FEATURE
   - Accelerated intestinal transit time.
   - Hyper segmentation of barium column (chicken intestine)

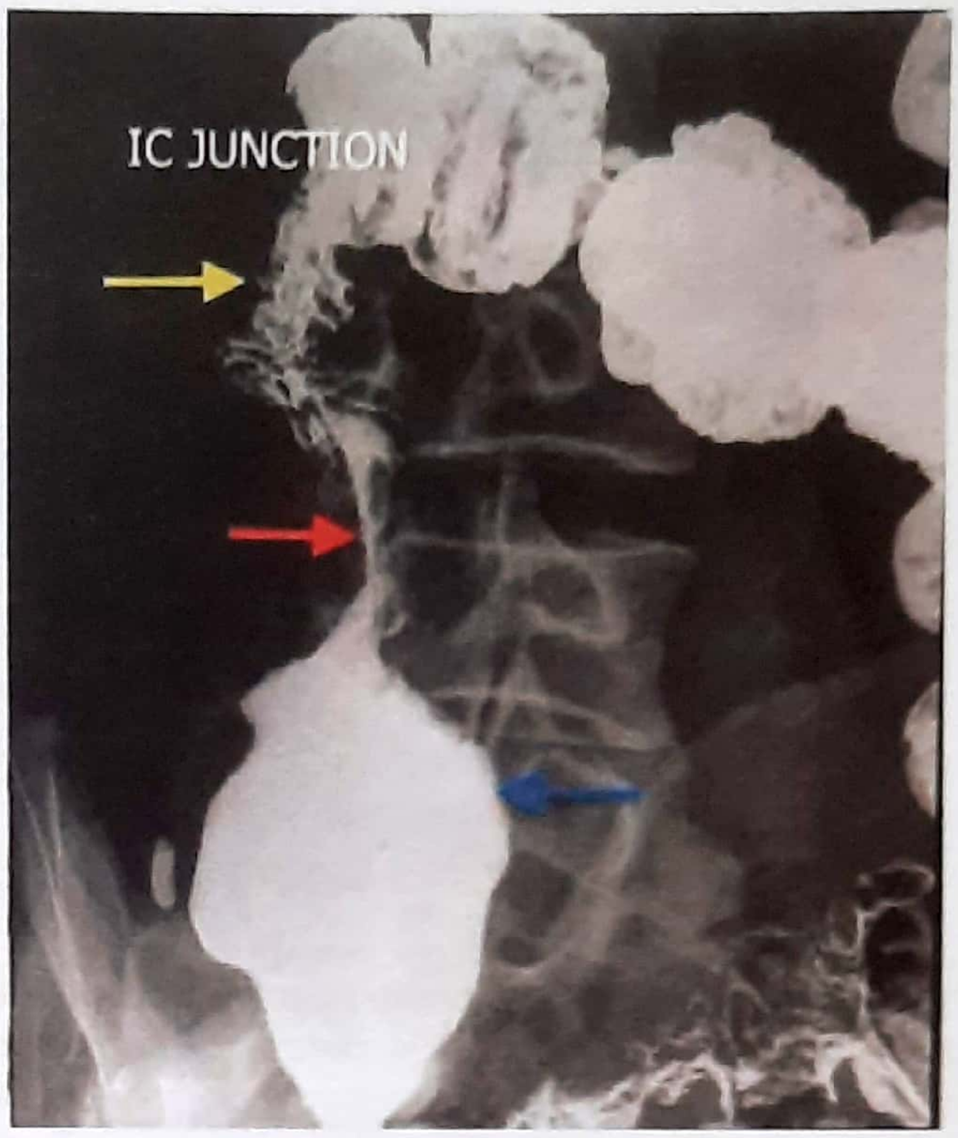

Figure 34.14(b): Narrowing of affected segment

5. **PCR** (Polymerase chain reaction)- is an emerging diagnostic tool for diagnosis of T.B.
6. **Fleischner sign:** *(NEET)* This is also known as **inverted umbrella sign**. This refers to a widely gaping, thickened, patulous, ileocecal valve and narrowed, ulcerated terminal ileum.

The normal ileocecal angle (angle between ileum and cecum) is about 90 as the cecum is pulled up in ileocecal tuberculosis, the angle between ileum and cecum increases and may even become 180°.

NOTE: However in most cases X-ray chest is negative (ie; normal)

Treatment

- When the diagnosis is definite and there is no intestinal obstruction, the treatment is full course of anti tuberculous treatment (ATT).
- When obstruction is present or ATT fails; surgery is advised under cover of ATT. The operation of choice is **right hemicolectomy*** with ileotransverse anastomosis (see figure 34.14c).

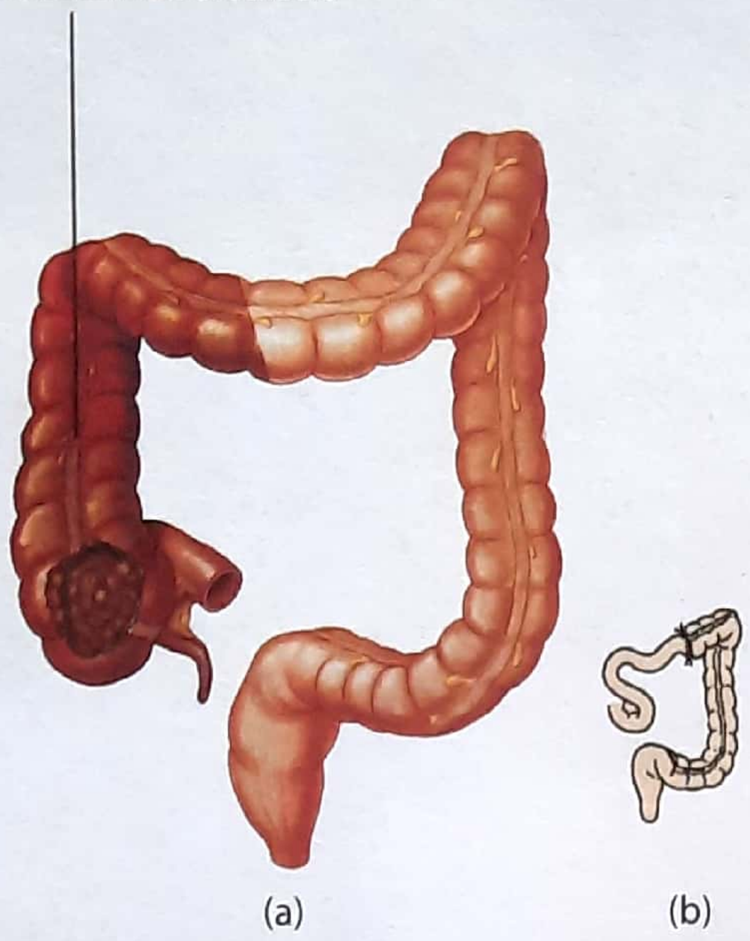

Figure 34.14(c) : Right hemicolectomy, note the dark shaded area is resected and anastomosis is made between remaining ileum and transverse colon (b) ileo-transverse anastomosis. Note - dark area is resected and anastomosis is done between ileum and transverse colon.

NOTE:

- ***Right hemicolectomy** =*

  Excision of terminal ileum + cecum + ascending colon + proximal transverse colon. (Figure 34.14c)

- Else where in intestine; tuberculosis of intestine is treated by a *segmental resection of involved bowel,* followed by end to end anastomosis; between healthy (ie; non diseased) bowel loops.

- If tuberculous stricture is present in intestine *stricturoplasty* is useful for fibrotic stricture of intestine.

2. ULCERATIVE TUBERCULOSIS

- Ulcerative tuberculosis is more common form of intestinal tuberculosis. Ulcerative tuberculosis results from swallowing of his/her own sputum by a patient of pulmonary tuberculosis.

- There are ***multiple ulcers in the terminal** ileum lying transversely.* **NOTE:** Tubercular ulcer lie Transversely. (Figure 34.14(d) & 34.14(e))

Figure 34.14(d): Ulcerative Tuberculosis

Clinical feature

Diarrhea and weight loss are the predominant symptoms. Stools contains pus and bad odour and have occult blood on microscopic examination.

Investigation

- Stool examination is very important, it contain occult blood, pus and even tubercle bacilli.
- Chest X-ray may shows pulmonary tuberculosis.
- Barium meal examination fails to show the distal ileum, cecum and most of the ascending colon. This is due to narrowing and hypermotality of the ulcerated segment.

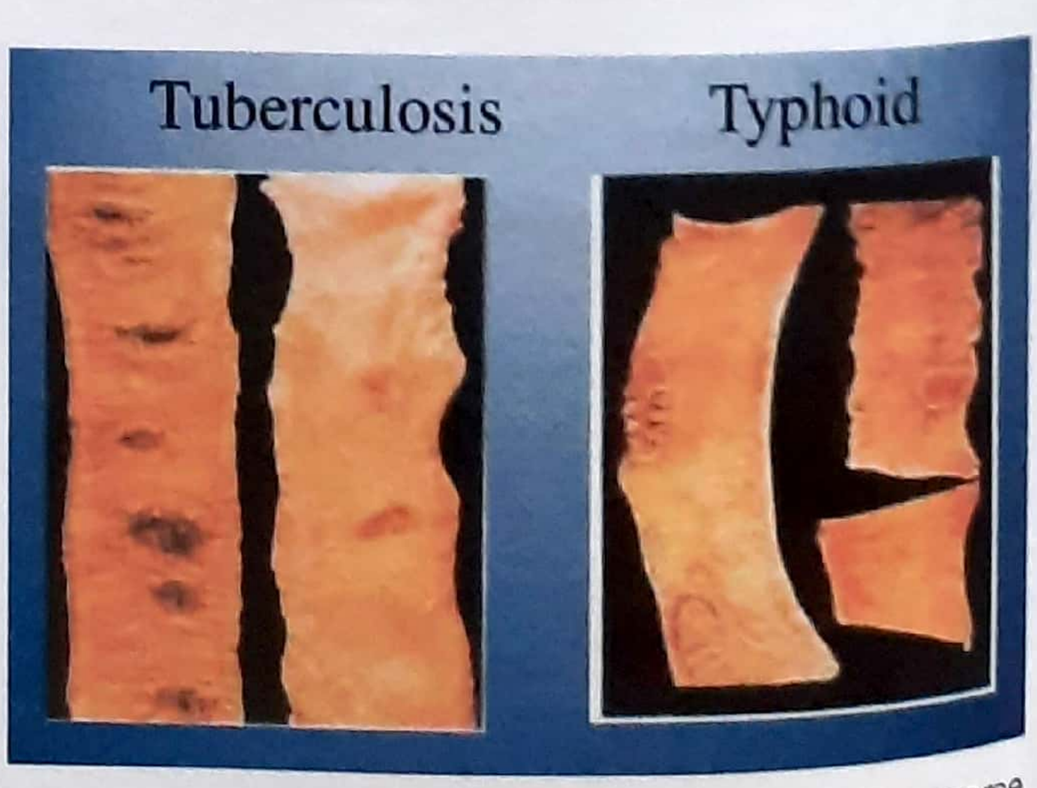

Figure 34.14(e): Ulcerative Tuberculosis (Transverse ulcer)

Treatment

- Conservative therapy in the form of ATT usually cures this condition; if detected early.
- An operation is required, when perforation or intestinal obstruction is present in late cases.

*****

SHORT BOWEL SYNDROME

(AIIMS JUNE 94,95,96, AI 94,98 PGI JUNE 99)

- This is a malabsorptive condition of intestine, *as a result of shortened bowel (in length) because of its resection done in the past due to some bowel pathology.*
- The *most common cause* are: mesenteric infarction, crohn's disease, blunt trauma to abdomen.
- *If distal ileum and ileocecal valve can be preserved, even 70% of resection can be tolerated by most of the patients.* (NEET, IMP. POINT)
- Resection of terminal ileum results in malabsorption of bile salts and **Vit B_{12}**, which lead to **steatorrhea** and megaloblastic **anemia**. (NEET) (**NOTE:** bile salts and Vit B12 are absorbed from terminal ileum), Extracellular volume depletion.
- *Resection of small bowel (ileum) leads to Oxalate stone formation in kidney.* (UP 04, UPSE 07)
- *Incidence of gall stone formation is also increased.*
- *Large resection (>90%) of small bowel may result in gastric hypersecretion due to reduced inhibition of acid secretion.* (NEET) *Leads to chronic TPN dependence.* (NEET)

*****

ISCHEMIC COLITIS

- Ischemic colitis is caused by extensive atherosclerotic narrowing of the *inferior mesenteric artery* and the collateral arteries that supply colon. (Figure 34.14f)
- The *splenic flexure of colon is most commonly involved followed by midsigmoid colon* (AIIMS JUNE 95, PGI DEC 97). Rectum is usually spared because of its rich collateral circulation. (Figure 34.14g)
- The condition is usually self limiting but healing with fibrosis may cause stricture or narrowing of bowel lumen.

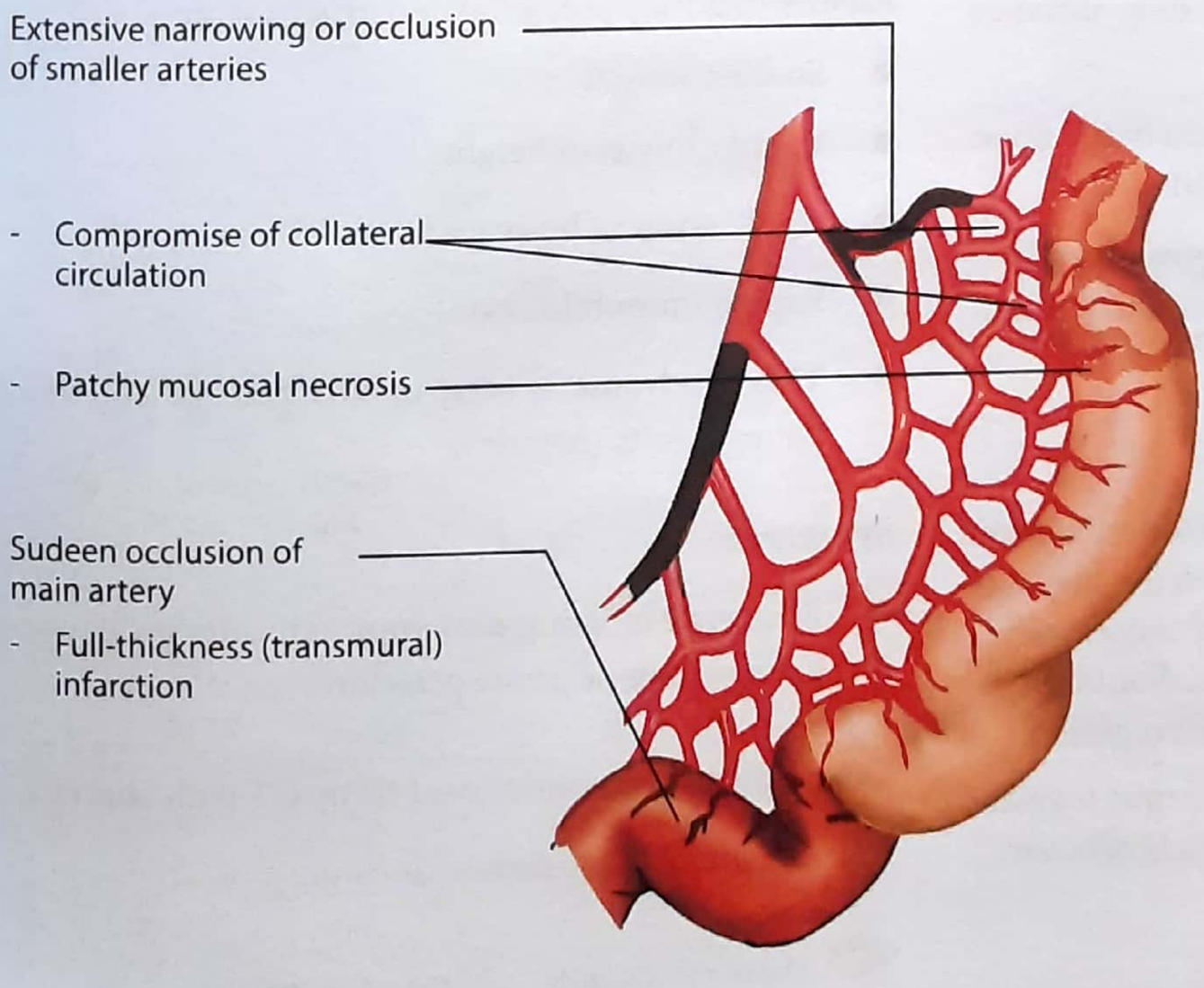

Figure 34.14(f): Pathogenesis and clinical feature of intestinal infarction and ischemia

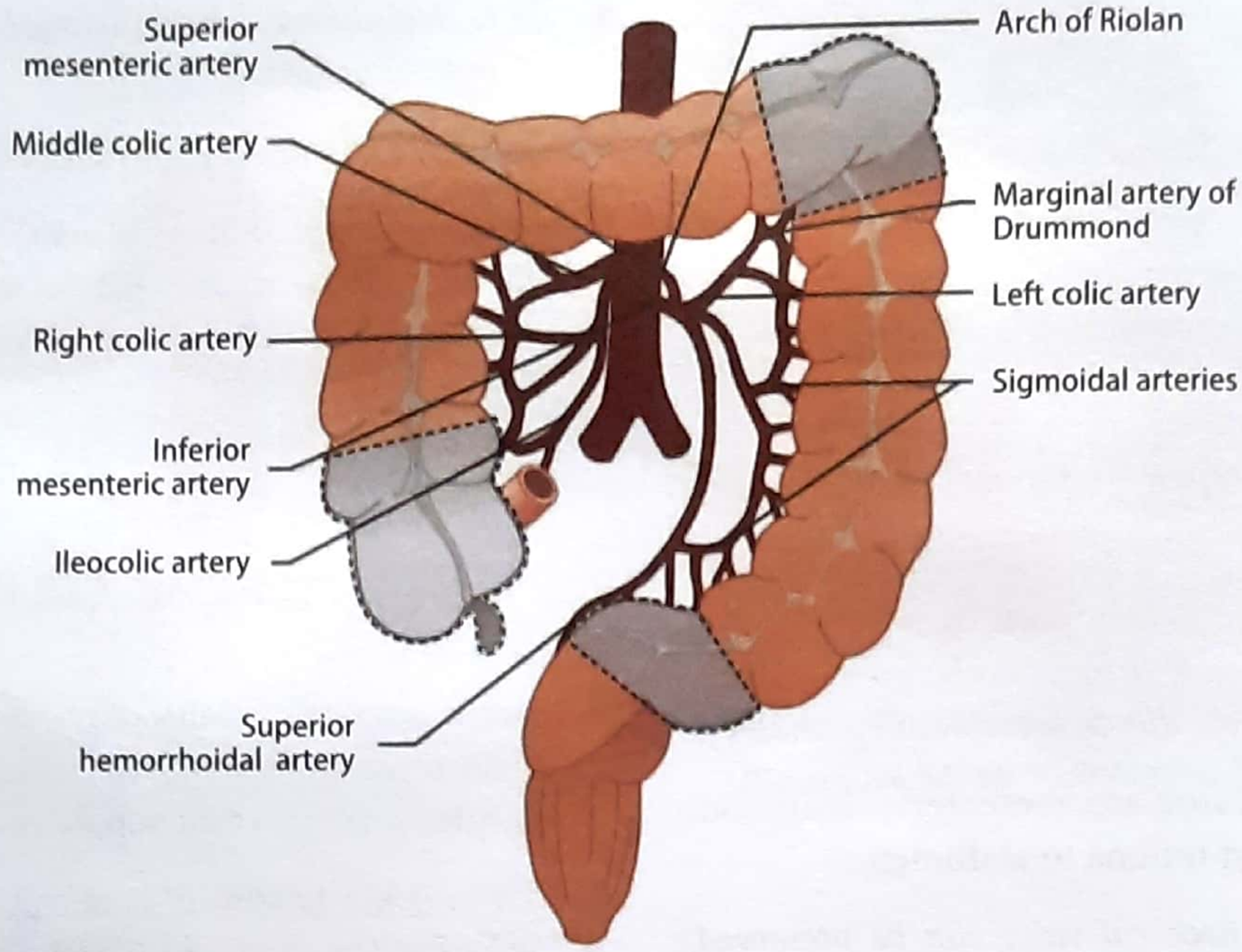

Figure 34.14(g): Lightly shaded colonic regions especially vulnerable to ischemia

- Clinically patients present with an acute attack of left side abdominal pain, fever and bloody diarrhea.
- Risk factor include vascular disease, diabetes mellitus, vasculitis and hypotension. Other factors associated with the disease include oral contraceptive pills, cocaine abuse, coagulopathies, long distance running.
- The diagnosis of ischemic colitis is often based upon the clinical history and physical examination.
- **Plain x-ray** film may show **"thumb printing"** *(AIIMS 86,88)* which result from mucosal edema and submucosal hemorrhage.

Treatment

The treatment of ischemic colitis depends upon clinical severity. Unlike ischemia of the small bowel, the majority of patients with ischemic colitis are treated conservatively (medically) by bowel rest (nil orally) and antibiotics. About 80% of patients will recover with this regimen.

Rest of them will require resection of ischemic segment of bowel and anastomosis between healthy ends of bowel.

*****

Superior Mesenteric Artery Syndrome (Wilkie's syndrome)

3rd part of duodenum is compressed between superior mesenteric artery & aorta; due to decrease angle.

Factors that may precipitate obstruction are -

- Sudden weight loss.
- Rapid growth in height.
- Application of body cast.
- Supine immobilization.
- This syndrome is seen in this patients common is young adults (females).

Symptoms

- Epigastric bloating & crampy pain after meal relieved by vomiting or prone position.

Investigation - Barium meal study CT with contrast.

Management - Duodenojejunostomy.

Please see figure 34.14(h), to understand this.

*****

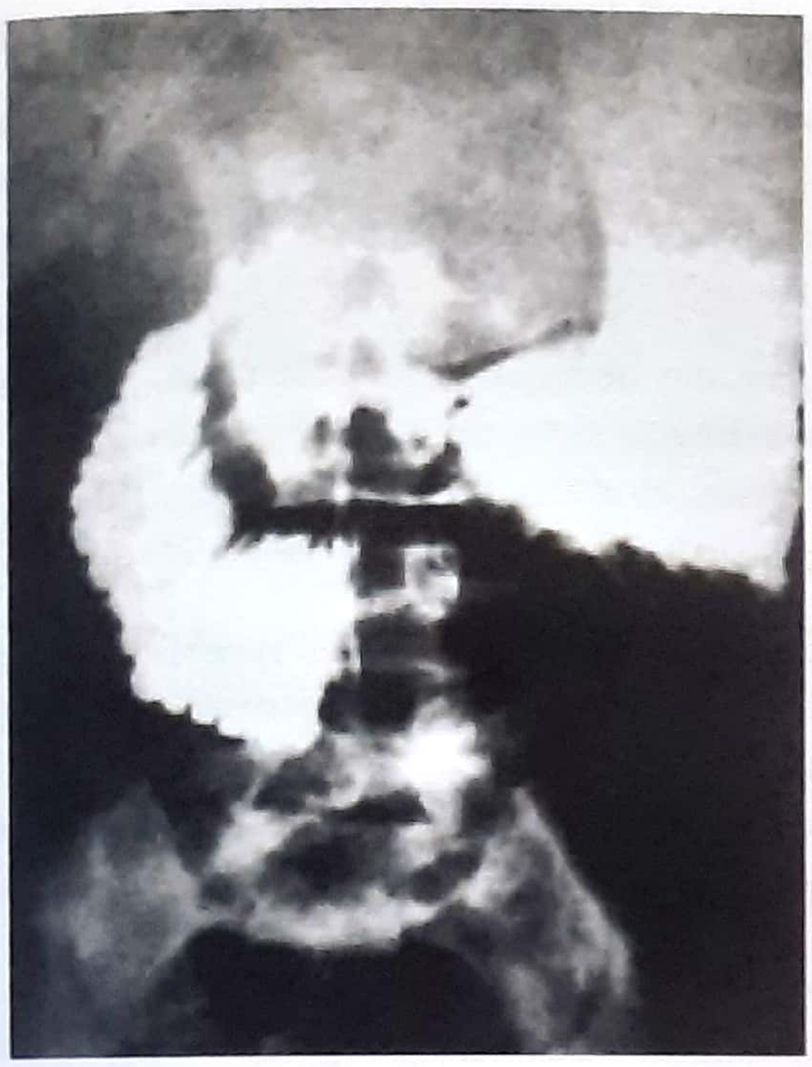

Figure 34.14(h): Superior Mesenteric Artery Syndrome

Lower GI Bleed

Defined as bleeding from a site distal to ligament of Treitz.

Most common site - Colon (Ca colon)

Most cause in India - Hemorrhoids > IBD *(NEET)*

- Most common cause of significant lower GI bleed

↓

Diverticular disease *(NEET)*

- Most common cause in children → Intussusception
- Patients with acute lower GI Bleed typically present with hematochezia, lower they may also present with melena in case of (right side colonic bleeding).

Management

Please understand this with help the given below flowchart

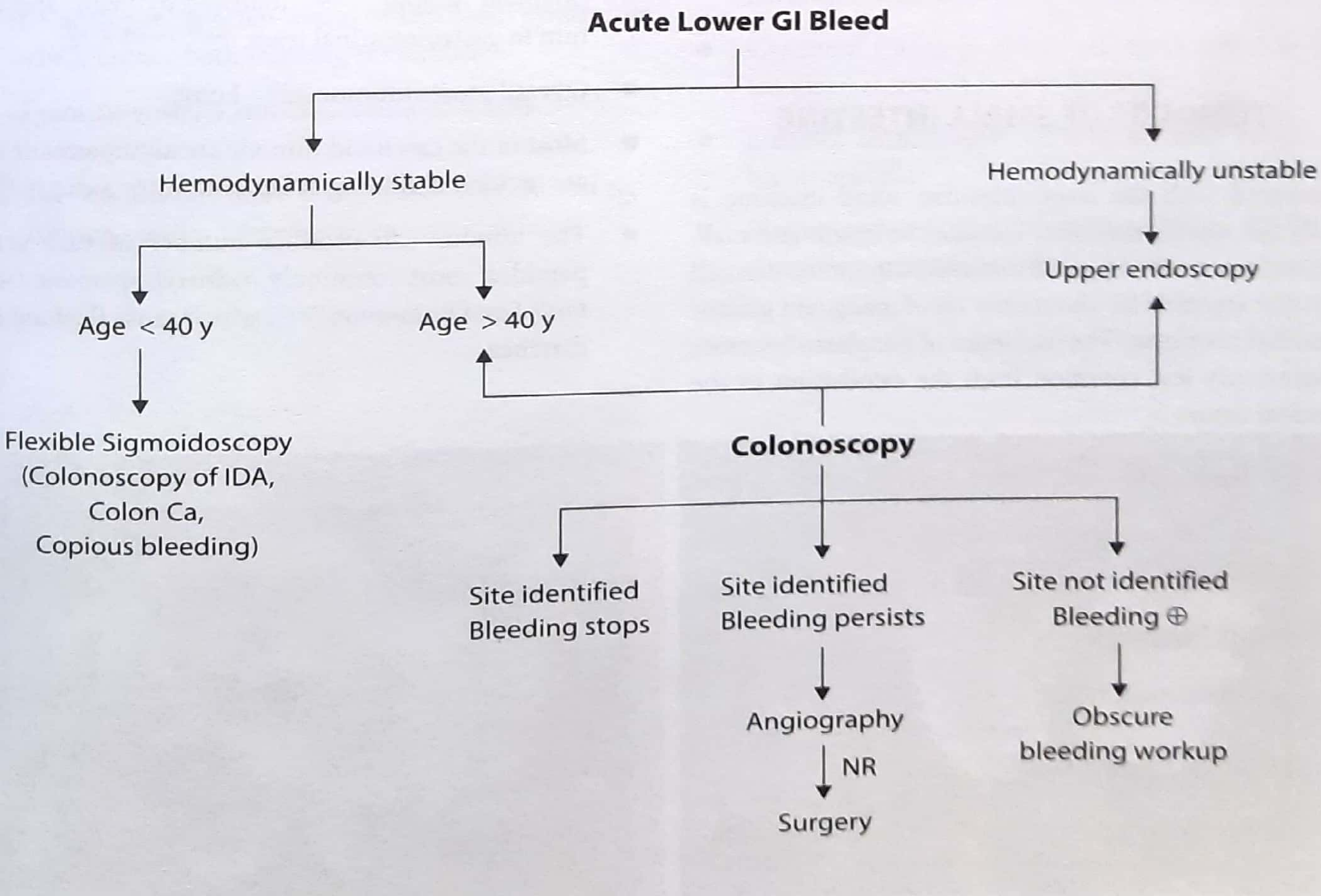

Relative frequency of PR bleed in India	
Common causes	
Colonic sources	70-90%
Inflammatory bowel disease	30-40%
Haemorrhoids	30-40%
Neoplasms	15-20%
Arteriovenous malformation, Angiodysplasia	2-5%
Diverticula	2-5%
Small bowel sources	10-20%
Meckel's diverticulum or other diverticula	
Vasculitis	
Ulcers, e.g., typhoid	
Less common causes	2-5%
Solitary rectal ulcer syndrome (SRUS)	
Infectious enterocolitis	
Ischaemic colitis	
Aortoenteric fistula	
Colonic varices is portal hypertension	
Radiation proctitis	
Lesions associated with use of NSAIDs	

TUMOURS OF SMALL INTESTINE

Compared with the large intestine; small intestine is rarely the seat of neoplasm. Despite the length and massive surface area of the small intestine, carcinoma of small intestine accounts for about only 1% of malignant gastrointestinal neoplasm. The incidence of neoplasm becomes progressively less common from the duodenum to the terminal ileum.

Benign Tumours

Adenoma, submucous lipoma and stromal cell tumours occurs from time to time.

Malignant Tumours

There are three main types.

1. Malignant lymphoma

- Small bowel lymphoma may be primary or secondary to systemic lymphoma (more common).
- Incidence of small bowel lymphoma increases with Crohn's disease & immunodeficiency syndrome.
- Most lymphoma are non hodgkin's B-cell lymphoma.
- It usually presents with worsening of diarrhoea & local obstructive symptoms, aneurysmal dilatation of small bowel.
- Mainstay of treatment is chemotherapy, however surgery may be required for obstruction, perforation or bleeding.

2. Carcinoma

Most common, (NEET) histological type is adenocarcinoma. These can present with obstruction, bleeding and diarrhea.

3. Carcinoid Tumour

- Carcinoid tumours arise from neuroendocrinal cells present in the mucosa through out the gastrointestinal tract. Neuro endocrinal cells were formerly termed ***argentaffin cells***, **APUD** (amine precursor uptake and decarboxylation) cells or **kulchitsky cells**.
- *The tip of the appendix is the most common site for carcinoid tumour* (NEET) followed by ileum and rectum in gastrointestinal tract. (MANY PGME, AI 10)
- Overall most common site - Lung.
- Most of the carcinoid tumour are asymptomatic and are incidental finding at laparotomy or autopsy.
- The tumour can produce number of vaso active peptides; most commonly *hydroxytryptamine (serotonin) and histamine*; (NEET) which cause flushing and diarrhea.

Figure 34.14(i): Lymphoma of the small intestine

- More common in females than males.
- ***Appendiceal carcinoid*** are usually incidental finding at appendectomies and are almost always less than 2 cm in diameter and are benign in 99% of cases. *Only those rare tumours that have diameter more than 2cm have potentially malignant behaviour.* (AIIMS, PGME)
- The ileum is next most frequent site. Ileal carcinoid tend to be malignant in about 60% of cases. Please see key box 34.8 and figure 34.15.
- The primary carcinoid tumour is small, but when they metastasize, the liver is usually involved.

Treatment

- For appendiceal carcinoid of less than 2cm, an appendectomies is all that is required. (IMP. POINT)
- For ileal carcinoid- resection of diseased segment with end to end anastomosis is done.
- In patient with metastatic disease to liver; multiple enucleations of hepatic metastases or even partial hepatectomy can be carried out.
- *Medical treatment* in form of octreotide (a somatostatin analogue) is often useful in carcinoid syndrome; which reduce both flushing & diarrhea.
- *5 year survival for carcinoid tumor is > 60%.* (NEET)

Lets discuss one more topic; which is of clinical significance and is related with carcinoid tumour

Carcinoid Syndrome

- Carcinoid syndrome occurs only when a malignant intestinal carcinoid has metastasized to the liver. Serotonin & histamine produced by hepatic metastases now reaches the systemic circulation & produce symptoms.
- Carcinoid syndrome is characterized by smooth muscle stimulation by serotonin, which causes abdominal cramps, diarrhea and bronchospasm.
- Histamine causes vasodilatation in skin and results in episodic flushing.
- Serotonin causes fibrosis of cardiac valve. Pulmonary and tricuspid valve fibrosis & subsequent stenosis are the common lesions occurring in carcinoid syndrome.
- **The right sided valves** are chiefly affected in carcinoid syndrome because serotonin is rapidly metabolized in lung and present in very low concentration in pulmonary venous blood; that returns to right side of heart. (MAY BE A FUTURE PGMEE Q)
- The elevation of various humoral factors forms basis for diagnostic test.
- Carcinoid tumor produces serotonin which is metabolized in liver & lung to 5 HIAA.
- Elevated urinary level of 5-HIAA with HPLC are highly specific.
- Plasma concentration of chromogranin A (Cg A) and serum gastrin are highly specific.

Figure 34.14(j): Gross pathologic characteristics of neuroendocrine tumor (NET). (A) NET of the distal ileum demonstrates the intense desmoplastic reaction and fibrosis of the bowel wall, (B) Mesenteric metastases from a NET of the small bowel

KEY BOX 34.8		
Incidence and risk of cancer of intestinal carcinoid		
Site	**Incidence**	**Malignant**
Appendix	40%	1%
Jejunum	55%	60%
Rectum	20%	15%
Stomach	5%	High
Colon	10%	High

- Somatostatin receptor scintigraphy is test of choice to identify extraabdominal metastatic disease.
- CECT used for identifying site of disease & presence of lymphatic or hematogenous metastasis.

*****

TUMOURS OF LARGE INTESTINE

It is classified as:-

A. Non-neoplastic epithelial tumours
B. Benign neoplasm
C. Malignant neoplasm

Now lets take them one by one, but before going into details go through key box 38.9.

A. NON-NEOPLASTIC EPITHELIAL TUMOURS

1. Intestinal hamartoma

First of all, know what is *Hamartoma?*- This is a tumour resulting from the **overgrowth of normal tissue.** In other words; it is over growth of normal tissue. The growth is self limiting and benign.

What is a polyp?- It is a tennis racket shaped **benign** tumour. When the "handle of racket" is long it is known as pedunculated polyp and when the "handle of racket" is very short or absent it is called as sessile polyp. (fig 34.16 and 34.17)

Figure 34.15: Carcinoid of Appendix

Intestinal hamartomas are uncommon in the intestinal mucosa, and presents as a polyp. They can be found as an isolated lesion any where in the intestine or as in familial hamartomatous polyposis in *Peutz-Jeghers syndrome.* The *isolated non familial hamartomatous polyps are not associated with an increased risk of carcinoma.* (MANYPG)

Peutz-Jeghers syndrome (PJS), juvenile polyposis syndrome, and PTEN hamartoma syndrome.

2. Hyper Plastic Polyp

They are most common polyps in colonic mucosa and results from hyperplastic changes in colonic epithelial cells. They *are not associated with an increased risk of colon cancer.* (PGI JUNE 98, MANY PGME).

KEY BOX 34.9		
Classification of Large Intestine Tumour		
A. Non-neoplastic Epithelial tumours	**B. Benign neoplasm**	**C. Malignant neoplasm**
• Intestinal hamartomas • Hyperplastic polyps • Juvenile retention polyps	• Tubular adenoma • Villous adenoma	• Adeno carcinoma • Malignant lymphoma • Gastrointestinal stromal tumours (GIST) • Carcinoid tumours.

3. Juvenile retention polyps

They are common occurring mainly in the rectum of a children and young adults. The juvenile polyps are not associated with an increased risk of carcinoma. (AIIMS MAY 06).
They are most common polyps in children and may present as per rectal bleeding. (PGI DEC 98, AL 07).

B. BENIGN NEOPLASM

Colonic Adenoma

Adenoma of the colon are present in about 15-30% (NEET) of all individuals over the age of 50 years.

The two major types are:

1. Tubular adenoma &
2. Villous adenoma

1. Tubular adenoma (Adenomatous polyp, polypoid adenoma)- (M/C)

- Tubular adenomas account for over 90% *of colonic adenoma* (MANY PGME).
- They are commonly multiple (10-20) and are pedunculated with a well defined stalk (compare this to a tennis racket). Figure 34.16 and 34.17.
- Tubular adenoma *are premalignant lesions.* (NEET, PGME)
- Through the risk of cancer is small (1-3%), (AI 04) The frequency of these polyps in the population make them the *most important* precancerous colonic lesion. (MANY PGME)
- The risk of developing carcinoma increases with increasing size and number of polyps.
- Polyps over 2cm in diameter should be considered highly suspicious of being malignant.
- Most patients with tubular adenomas are asymptomatic. A few will present with overt rectal bleeding, many will have occult blood in stool.
- The diagnosis is made by colonoscopic visualization and biopsy. Pedunculated polyps can be safely removed; when seen at colonoscopy.
- Sessile polyp has maximum malignant potential.

2. Villous adenoma

- Villous adenomas are uncommon; comprising less than 10% of all colonic adenoma.
- They commonly occur in older individual as a solitary large sessile lesions without a defined stalk (AIIMS 97) (compare this to a tennis racket without handle)
- The most commonly location being rectum.
- Their consistency is so soft that even large growth may be difficult to be felt on per-rectal examination.
- Villous adenoma have a 30-70% *incidence of carcinoma* (AIIMS FEB 97).
- *The cancer most common arising from a villous adenoma is papillary adenocarcinoma.*
- Patents with villous adenoma frequently presents with bloody diarrhea or mucus discharge and occasionally hypokalemia; due to loss of K^+ ion in stool (TN 89, AIIMS 08).

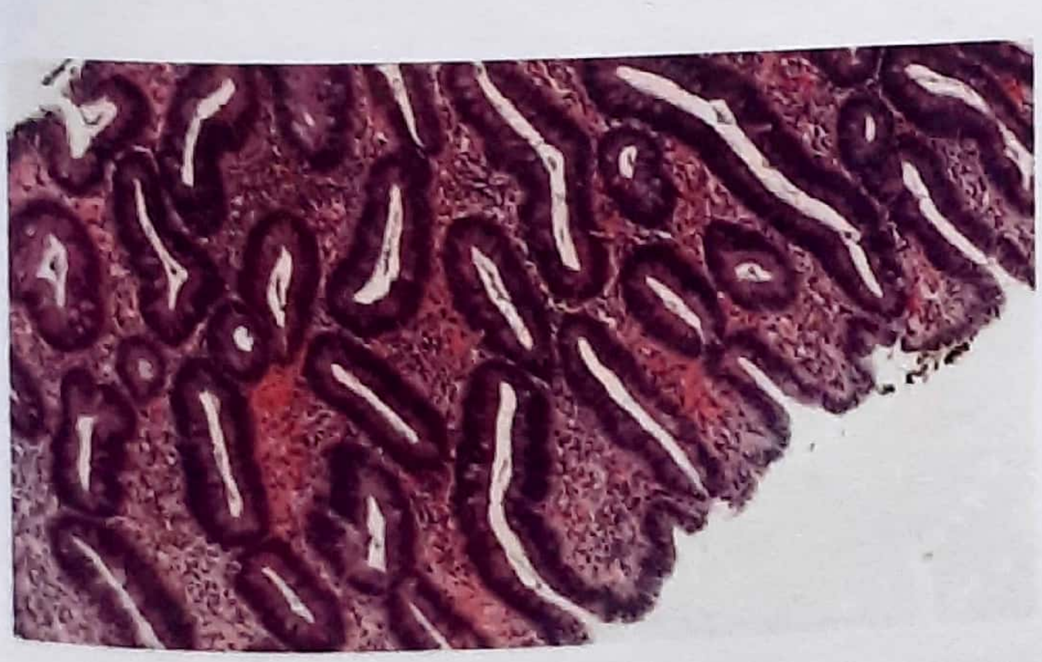

Figure 34.16: Histology of tubular adenoma

Figure 34.17(a): Histology of a villous adenoma

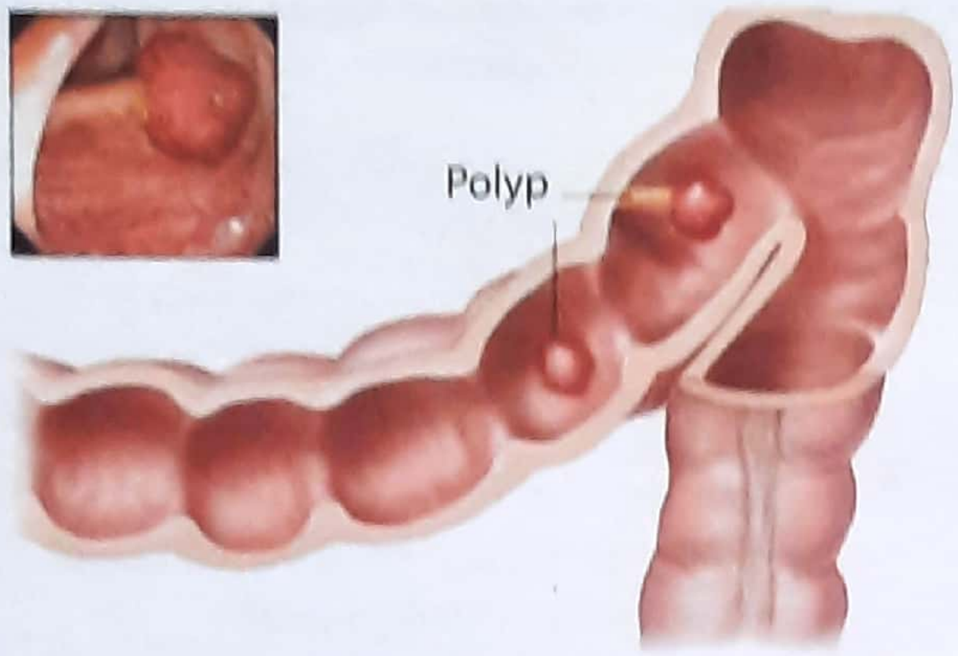

Figure 34.17(b): Polyp in colon

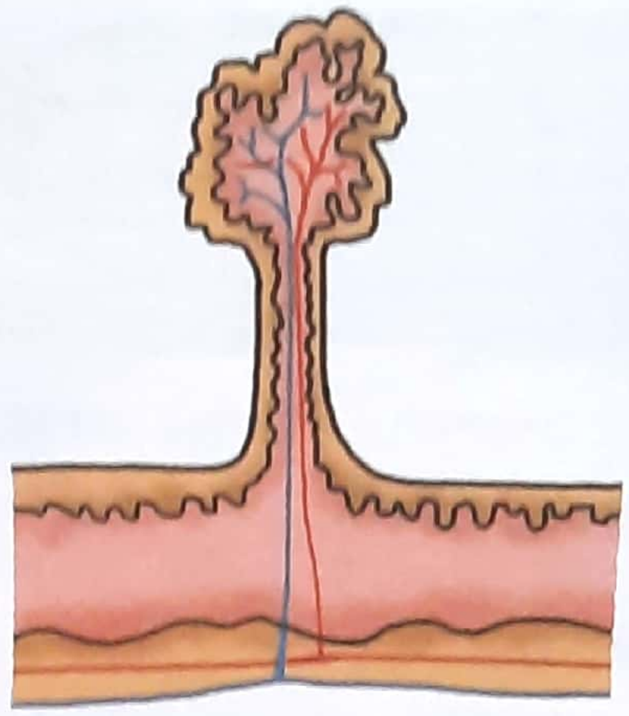

Figure 34.17(c): Stucture of a pedunculated polyp

- Because these are sessile and have *high incidence of malignant change* (AIIMS 93). The usual treatment consist of excision of the segment of colon harbouring the lesion.

One more condition which is needed to be adressed here is familial adenomatous polyposis.

FAMILIAL ADENOMATOUS POLYPOSIS (FAP Syndrome)

The familial adenomatous polyposis syndromes are a group of inherited disease, characterized by the presence of multiple polyps in the intestine. Several different type exist.

KEY BOX 34.10.1 (AI 07, AIIMS 09, 10)

Familiar Adenomatous Polyposis Syndromes

Syndrome	Types of Polyp	Locations	Cancer Risk	Inheritance	Other features
Familial Polyposis Coli (NEET)	Adenoma	Colon	100%	Autosomal dominant	Commonest, presents with rectal bleeding
Gardner's Syndrome	Adenoma	Colon, Small-intestine	100%	Autosomal dominant	Bone (osteoma) and soft tissue (desmoid) tumours. Periampullary carcinoma duodenum
Turcot's Syndrome (PGI JUNE 02)	Adenoma	Colon	100%	Autosomal recessive	Nervous tissues neoplasms (glioblastoma multiforme)
Peutz- jeghers syndrome (AIIMS 01, AI 2000, AP 05)	**Hamartoma** (NEET)	Jejunum, rest of intestine (PGI 09)	Slight increase (PGI JUNE 03)	Autosomal dominant	**Pigmentation in mouth, theca or granulosa cell tumours of ovary.** (NEET)
Juvenile: polyposis	Retention polyp	Colon	Slight increase	Autosomal dominant	*most common polyps in children* (PGI 98)

Familial Polyposis Coli

- Familial polyposis coli is the *commonest* of the familial polyposis syndrome (MANY PGME)
- It has an autosomal dominant inheritance pattern. (IMP AIIMS 10, 11)
- Recently Adenomatous Polyposis Cell (APC) gene has been isolated on *chromosome 5.*
- The *number of polyps exceeds 100 in all cases, and frequently reaches several thousand.* (NEET, PGME)
- Polyps are not present at birth but begins to appear at about 10-20 years of age. Polyps are manifested by rectal bleeding. (AIIMS 10, 11)
- In *all cases colon carcinoma develop at around 35-40 years of life, hence all patients should be screened by colonoscopy at regular interval.* (AI 03, AIIMS 06, COMED 05, AIIMS 10, 11)
- Diagnosis is made by colonoscopy and biopsy.
- *Total colectomy to prevent cancer* is highly indicated, once the diagnosis has been made. (IMP. POINT)

Other types of FAP syndrome are given in a tabular form, which are:-

- Gardner's syndrome
- Turcot's syndrome
- Peutz-jeghers syndrome
- Juvenile poliposis coli.
- Please read box 34.10 very important for PGME.

C. MALIGNANT NEOPLASM OF COLON

[Kindly see the key box 34.9 on page 622; and revise what have you read till now in tumours of colon]

1. Adenocarcinoma of The Colon

Microscopically; the neoplasm is a columnar cell carcinoma originating in the colonic epithelium. Macroscopically tumour may take four form.

(i) Annular
(ii) Tubular
(iii) Ulcerative
(iv) Cauliflower (Least malignant form)

Etiology (PGI DEC 02, JUNE 02)

1. Dietary factors

(a) **Animal fats (meat)** (NEET)
(b) Low fiber diet
(c) Alcohol

NOTE: Antioxidants (Vitamin A, C, & E) calcium and selenium *decreases* the risk of colon cancer. (AI 09, AIIMS 11)

2. Hereditary factor

(a) Villous and Tubular adenoma
(b) Polyposis coli syndrome
(c) Hereditary non-polyposis colon cancer (HNPCC)- ***Lynch syndrome.*** *(see box)*

KEY BOX 34.10.2

Recommendations for repeat colonoscopy following endoscopic removal of polyps

INDEX COLONOSCOPY FINDINGS	REPEAT COLONOSCOPY
Small (<10 mm) hyperplastic polyps in rectum or sigmoid	10 years
Low risk:	5-10 years (AGA guidelines)
One to two small tubular adenomas	10 years (ESGE guidelines)
<10 mm, with low-grade dysplasia	3 years
High risk:	
Villous histology or high-grade dysplasia or size ≥10 mm or ≥3 polyps	6 months
Piecemeal removal of polyp	5 years
Sessile serrated polyp <10 mm	3 years
Sessile serrated polyp >10mm or with dysplasia or traditional serrated adenoma	

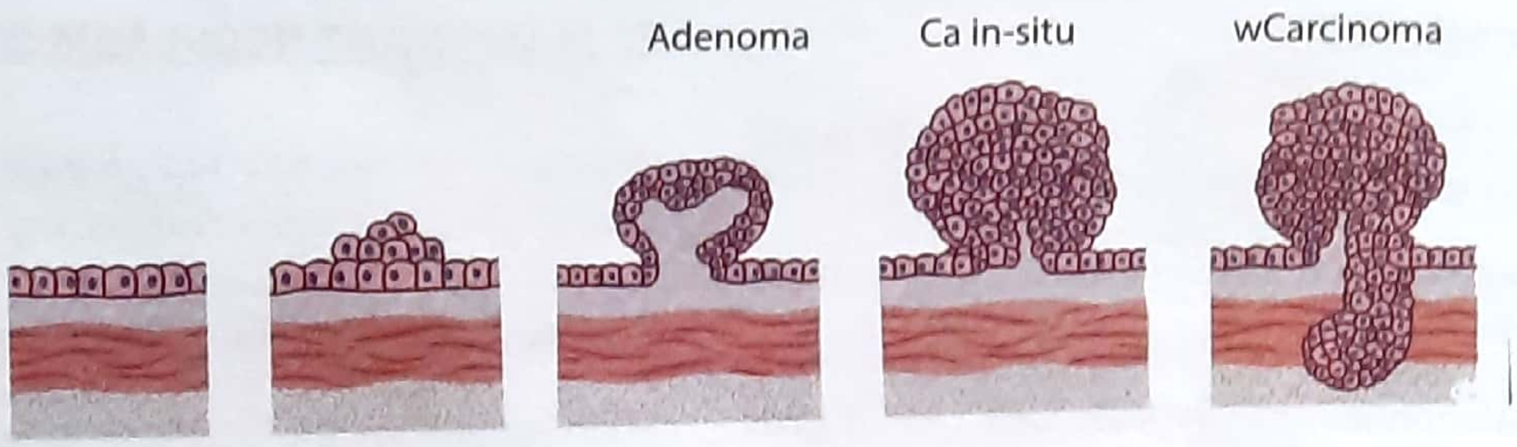

Figure 34.18: Adenoma - Carcinoma sequence

(d) Genetic mutations: APC gene, Mismatch repair genes myc, k-ras, erb-B2, src, p 53, DCC. *(AI 09, AIIMS 10, 11)*

3. **Inflammatory bowel disease**

   (a). *Ulcerative colitis* *(NEET)*

   (b). Crohn's disease

4. *Steptococcus bovis bacteremia* *(NEET)*

5. **Other risk factors**

   (a) Ureterosigmoidostomy

   (b) *Cigarette smoking* *(NEET)*

   (c) X-ray exposure

- High fibre diet is most protective in Ca colon.

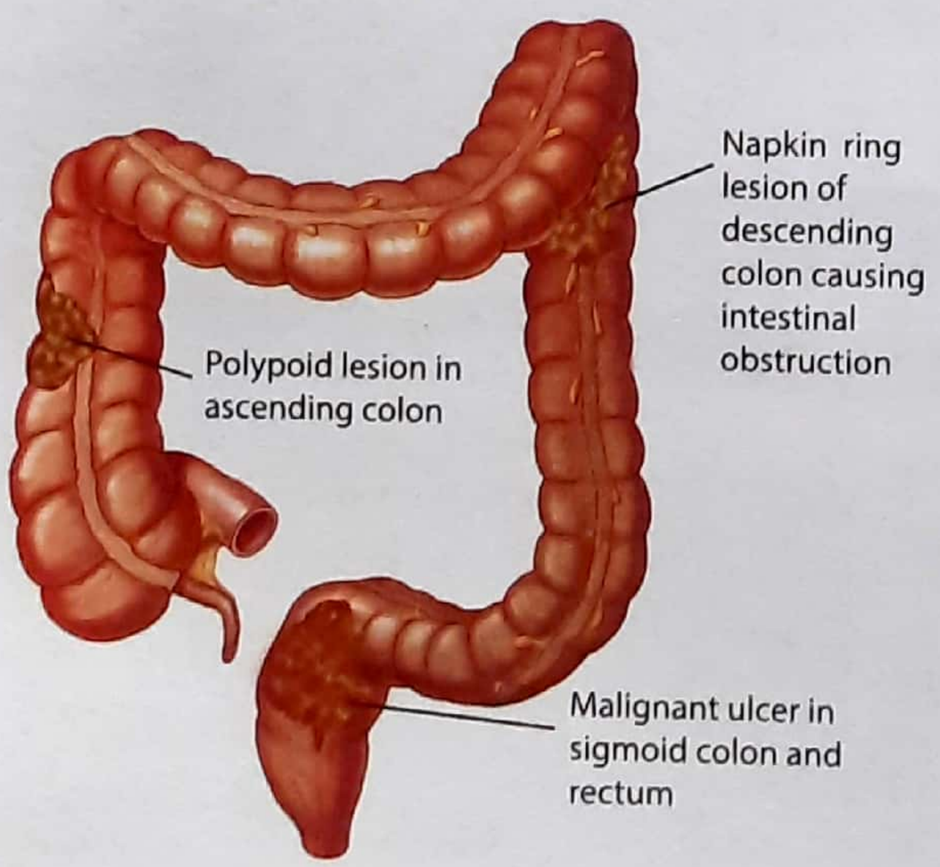

Figure 34.19: Distribution of Colo-rectal carcinoma

Pathology

- The most common site of colorectal carcinoma is *recto-sigmoid region** *(NEET)* which accounts for about 60% of colon carcinoma, *(MANY PGME)*. The remainder being distributed throughout the colon, (fig. 34.19 and 34.20)
- Carcinoma in the right side of the colon tend to be large polypoid masses that project into lumen. *(AIIMS 94)*.
- Left sided cancers tend to involved the whole circumference and often constrict the lumen (**"napkin ring " or"apple core"**) and present as intestinal obstruction *(PGI JUNE 01)* .

Clinical feature

Colon carcinoma is asymptomatic in its early stages. A symptomatic rectal carcinomas can be detected by careful per rectal examination in about 70-80% patients; which should be part of every routine physical examination.

Symptoms of colorectal carcinoma are non specific, and generally develops when the Cancer is locally advanced. Clinical feature of colon cancer depends up on the site of cancer in colon; which are described here:-

(i) Right sided colon cancer

Right sided colon carcinoma commonly presents with abdominal pain, weight loss, anemia, diarrhea and a palpable abdominal mass is frequently present. *(MANY PGME)* They rarely present with intestinal obstruction because they are polypoid masses in more wider part of colon where the feces are still semisolid and hence pass through the lumen.

(ii) Left sided colon cancer: *(PGI MAY 19)*

Hereditary Non Polyposis Colon Cancer (HNPCC) *(NEET)* **(Lynch Syndrome)**

- Autosonal dominant
- Due to mismatch repair (MMR) gene: inactivation/ mutations in following genes
  - MLH1 and MSH2 (M/C)
  - PMS1, PMS2 & MSH6
- Hallmark of disease is microsatellite instability.

LYNCH 1 Syndrome

- Colorectal Cancer with early age of onset (40-45 yrs)
- Excess of synchronous and metachronous colon cancers (40% increased risk).

LYNCH 2 Syndrome

- Same as lynch 1 + associted high risk of CA endometrium, transitional cell CA of ureter and renal pelvis, CA stomach, small bowel, ovary and pancrease *(AIIMS NOV 09)*
- Proximal colon is involved more commonly and has better prognosis.

DIAGNOSIS

Revised Amstardam Criteria: (also called as 3-2-1-0 rule)

1. 3 or more relatives with HNPCC related cancer
2. Atleast 2 successive generations affected.
3. Atleast 1 case diagnosed before 50 yrs. age
4. Familial Adenomatous polyposis excluded.
5. Tumor varified by pathological exmination?

Screening: anual colonoscopy starting at age 20-25 years or at least 10 years younger than youngest age at diagnosis in family.

Treatment: Total colectomy with ileo-rectal anastomosis.

Commonly present with intestinal obstruction, because they tend to be constricting lesion (**"napkin ring "or" apple core"**) in a narrow part of the colon, where the feces are solid. *(MANY PGME)*

Other presentation - Altered bowel habits hematochezia.

Left colon has smaller lumen than right colon *(MANY-PGME)*

(iii) ***Carcinoma of Transverse colon:***

They may produce reflex symptoms and may be mistaken for a carcinoma of stomach. The symptoms may be hyperacidity, heart burn and vomiting.

Please go through key box # 34-11 on next page.

Spread of Carcinoma Colon

(a) Local spread

The tumour is limited to bowel wall for a considerable time without causing much symptom. The ulcerative type more commonly invades locally and an internal fistula may result for example into urinary bladder (colovesical fistula).

(b) Lymph node spread

This is the *most common form* of tumour spread. *(MANY PGME)*

(c) Hematogenous spread

Hematogenous spread occurs via portal vein to liver. This accounts for large proportion of late death.

Investigation

This includes:

1. *Stool examination* for occult blood
2. *Sigmoidoscopy*
3. ***Colonoscopy and biopsy***- is ***investigation of choice*** *(NEET)* for most colorectal carcinoma- *(KERELA 97, MANY PGME)*

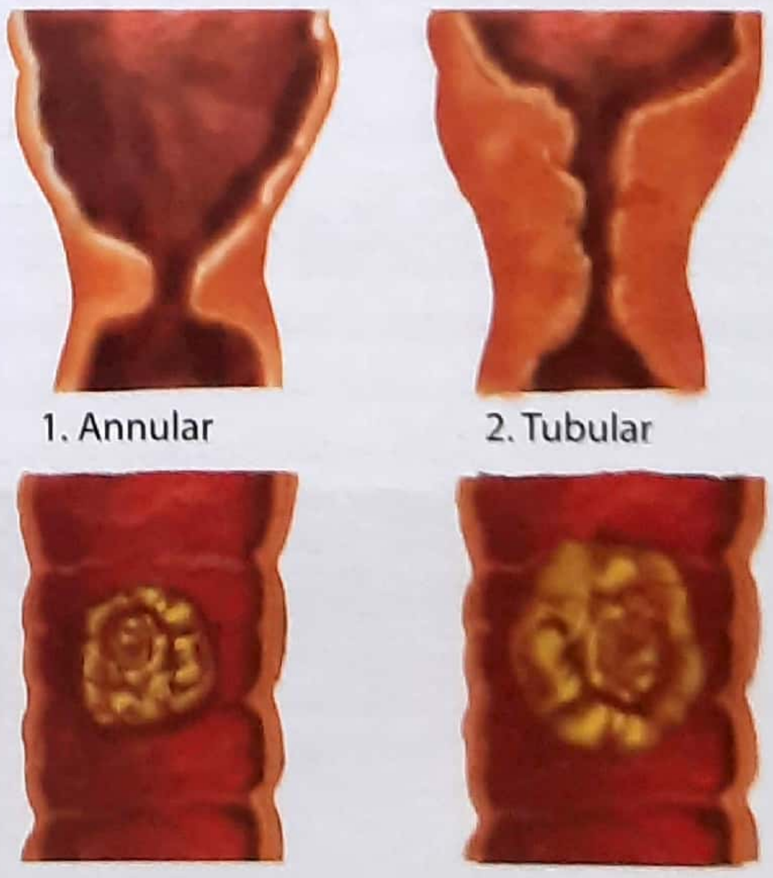

Figure 34.20: Four common macroscopic varieties of carcinoma of the colon

4. *Barium X-ray*- shows filling defect ["napkin-ring" or **"apple core appearance"**] (NEET) in left sided colon carcinoma.
5. ***Serum carcinoembryonic antigen (CEA)*** (NEET) levels are elevated in about 70% patients with colon cancer. However this is not specific; because it may be elevated in many other types of cancer (pancreas, lung and rectum).

TNM Staging of Colorectal Carcinoma -

T1	Tumor invades submucosa
T2	Tumor invades muscularis propria
T3	Through muscularis propria into subserosa or pericolic tissue
T4	Directly invade other organ or structures or perforates visceral peritoneum
N1	Metastasis to 1-3 pericolic or perirectal nodes
N2	≥ 4 nodes
N3	Metastasis in any node along course of named vascular trunk or apical nodes
M0	No Distal metastasis
M1	Distant metastasis

Treatment

Bowel preparation
(preparation of bowel before surgery)

- Full mechanical bowel preparation before colonic surgery is essential (PGI 04, AIIMS NOV 2000, AIIMS JUNE 94)
- Only liquid diet is advised 48 hours before surgery.
- Bowel preparation is done; because it *decreases the bacterial load of colon and rectum, which in turn* decreases the incidence of post operative infection.

The bacteria count of colon and rectum is very high.

- PEG (Polyethyl glycol) solution, and sodium phosphate solution is most common used and patient is asked to drink about 2-3 liters of this solution, so that colon and rectum is washed.
- These solution may cause electrolyte abnormality, hence patients should be given appropriate I.V. fluid in preoperative room.
- Antibiotic prophylaxis is also recommended; which further decreases bacterial load of colon
- A combination of neomycin and erythromycin is most commonly used, (other are metronidazole and ciprofloxacin)
- A broad spectrum intravenous antibiotic should be administered at the time of surgery (infact just prior to skin incision, at induction of anesthesia).

Operation (PGI 08)

The abdomen is opened and the tumour is assessed.

There are some anatomic vascular landmarks when performing a colorectal resection. The ileocolic pedicle originates from the superior mesenteric vessels just caudal to the second portion of the duodenum

- The middle colic vessels originate from the superior mesenteric vessels at the level of the inferior margin of the pancreas.
- The inferior mesenteric vein can be easily identified at the level of the ligament of Treitz.
- The IMA originates from the aorta, 2 to 3 cm caudal from the area where the IMV is identified; its origin is surrounded by the mesenteric and hypogastric nervous plexus.

KEY BOX 34.11

Clinical features of carcinoma colon

	Ascending colon, Cecum	Transverse Colon	Descending/Sigmoid
Manifestation	- Bleeding - anemia Melena - Abd. pain - Abd. lump - Diarrhea	- Dyspepsia - Abd. Pain - Mass - Obstruction/ perforation - Low back pain	- Changing bowel habits - Abdominal lump - Intestinal obstruction - Hematochezia

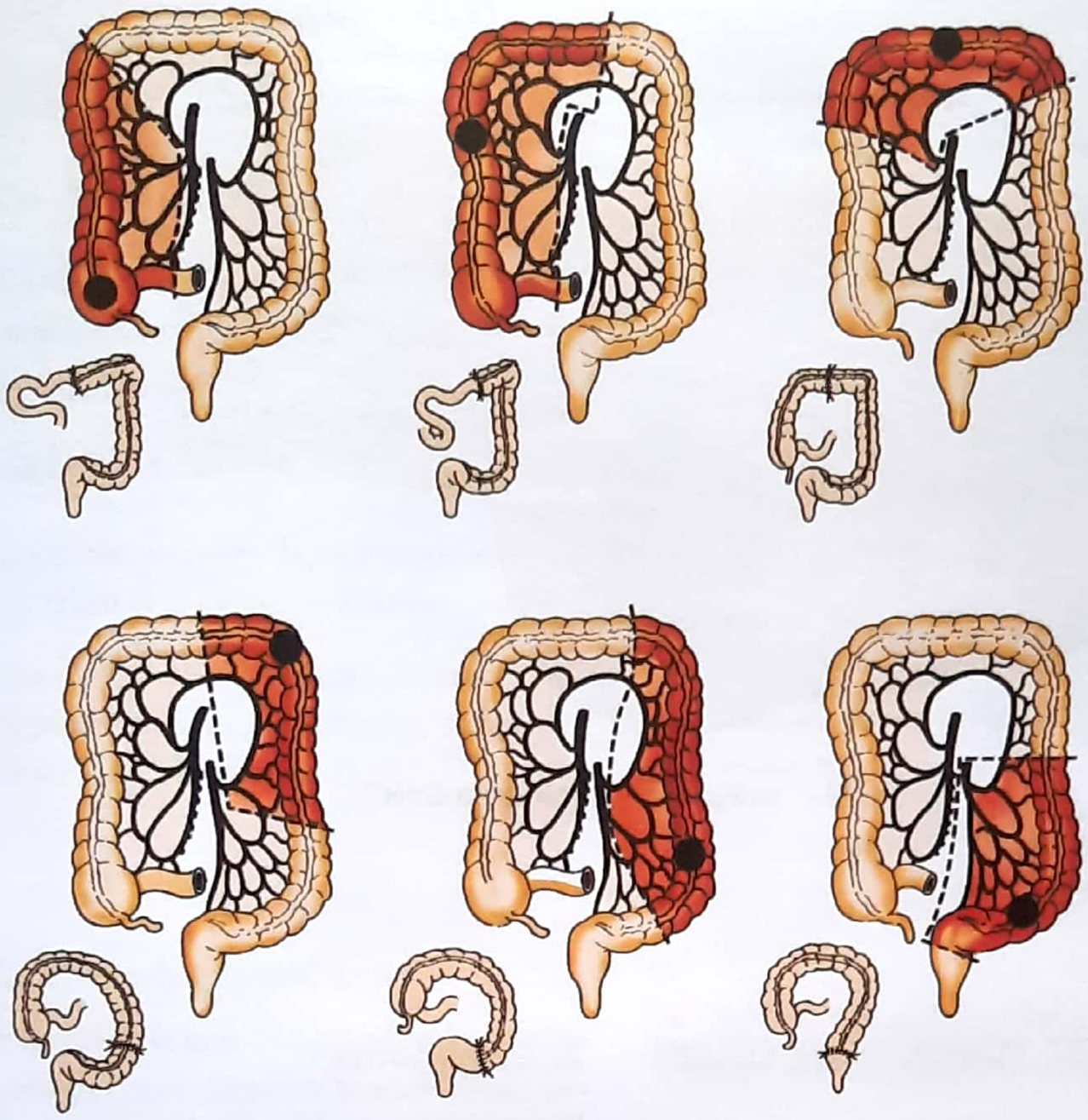

Figure 34.21: Extent of surgical resection for cancer of the colon at various sites. The cancer is represented by black disc. Anastomosis of the remaining bowel after resection is shown in inset.

- The left colic artery originates about 2 cm distally to the origin of the IMA.

*IMA - Inferior mesenteric artery.

*IMV - Inferior mesenteric vein.

NOTE: Liver secondaries are not contraindication for surgical resection, because the best palliative treatment for carcinoma of colon is removal of the tumour. *(AI 02, AI 98)*

The significant of this fact is that while in most of the cancer; surgery is not indicated when liver metastesis is present which denotes advanced disease. But in case of CA colon surgery is indicated even if liver metastesis is present; because it is the best way of palliative treatment. (* Palliative treatment relives from symptoms due to disease without curing the disease)

NOTE: Mesenteric lymph node involvement is also not a contraindication for surgery. Now lets come to operative part:-

(a) For operable lesions

Treatment consist of wide surgical resection of the intestine and its regional lymphatic drainage.

The extend of resection of the intestine will depend upon the site of the colon involved. I have tried to make you understand better by diagrams. Kindly go through Fig. 34.21 and make out your self the extent of resection of intestine in different cases. Please see table in key box 34.12 very carefully for text.

(b) When growth is found to be inoperable

- If growth is situated in cecum or ascending colon (right side of colon) a by pass procedure using an ileocolic anastomosis is made.
- If growth in descending colon- a transverse colostomy is done to relieve obstructive symptoms.
- If growth is in pelvic colon (sigmoid colon)- a left iliac fossa colostomy is made.

*****

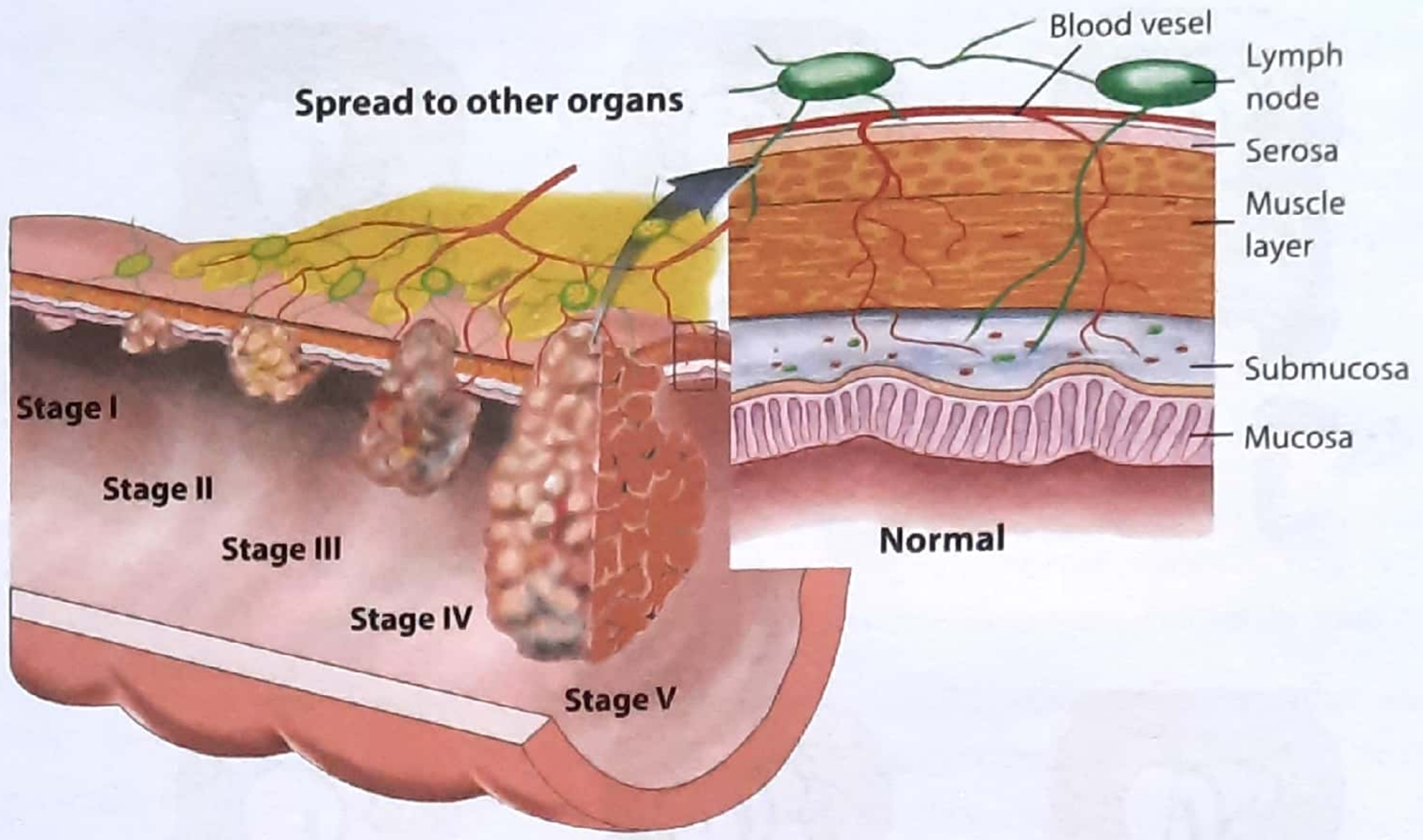

Figure 34.22: Stages of Carcinoma Colon

OTHER RARE MALIGNANT TUMOURS OF COLON

1. Carcinoid

This is a rare tumour of the large bowel. The colonic carcinoid does not produces serotonin and histamine and do not produce carcinoid syndrome. Clinical presentation is the same as for other cancer colon. *(AI 10)*

2. Lymphoma

Lymphomas are the most common of non- carcinomatous malignant tumours of the large bowel. Non-Hodgkin's lymphoma and kaposi's sarcoma are two AIDS - related cancers that affect the colon and rectum. The clinical manifestations are similar to an adenocarcinoma. Treatment is basically by chemotherapy.

KEY BOX 34.12

Tumour location	Vascular ligation	Colon resection	Anastomosis
Cecum, Ascending colon	Ileocolic, Right colic	Right hemicolectomy	Ileotransverse anastomosis
Hepatic flexure	Ileocolic, right & middle colic	Extended right hemicolectomy with omentectomy	Ileo descending
Distal transverse, Splenic flexure	Left Branch of middle colic left colic with/ without Ileocolic, right & middle colic	Left hemicolectomy Extended right hemicolectomy	Transverse sigmoid or Ileosigmoid colostomy
Descending Colon	Inferior mesenteric or left colic	Left hemicolectomy	Transverse colorectal or descending colorectal
Sigmoid colon	Inferior mesenteric or sigmoid	Left hemicolectomy or sigmoid resection	Descending colorectal

Please see figure 34.21, page 629

3. Gastro intestinal stromal tumours (GIST)

Earlier known as leiomyoma and leiomyosarcoma, may present with massive hemorrhage.

Commonly occurs in duodenum & stomach.

Here we finish tumours of small and large intestine.

*****

FECAL FISTULA (ENTEROCUTANEOUS FISTULA)

- Fistula is an abnormal passage from a hollow organ to the surface or from one organ to another.
- Enterocutaneous (intestine *with* skin) or fecal fistula is a fistula between intestine and anterior surface of abdominal wall ie; skin. See figure 34.23.

Types of fistula

Enterocutaneous fistula can be divided into:

(a) **High out put fistula:** When the intestinal contents coming out through fistula is **more than 500 ml/day**

(b) **Low out put fistula:** When the intestinal contents coming out through fistula is less **than 500 ml/day.**

Cause of Fistula Formation

1. **Previous surgery:** Most common cause of fecal (enterocutaneous) fistula formation is previous surgery. This happens most often in patients with adhesion between loop of intestine following previous surgery or as a result of anastomotic leakage (ie; break-down of stiching of intestine in layman's language)
2. Opening of an abscess connected with chronic diverticulitis or carcinoma of colon.
3. After an operation for gangrenous appendicitis or appendicular abscess (in this case fistula formation occurs between cecum and anterior abdominal wall)

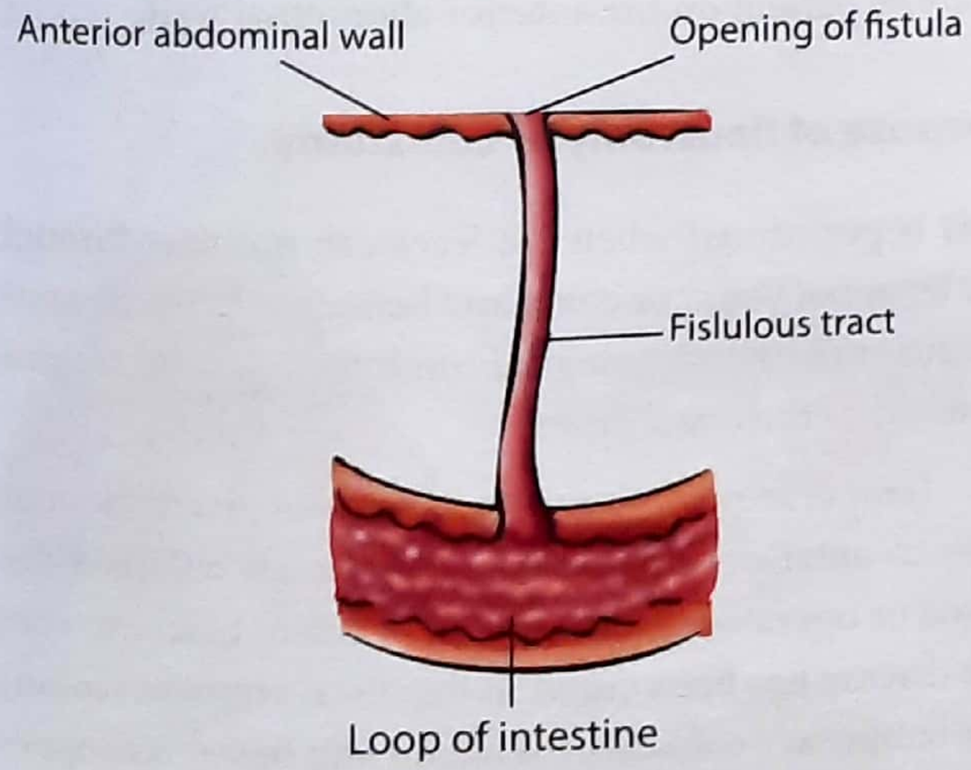

Figure 34.23: Diagramatic representation of fecal fistula

Character of Discharge from A Fistula

- The **discharge from a fistula connected with duodenum (leads to highest electrolyte imbalance) or jejunum contains bile and cause severe excoriation (damage) to the skin and is often greenish in colour.**
- When ileum or cecum is involved in fistula formation the discharge is mainly liquid containing fecal matter.
- When the distal colon is affected site; the contents are usually semisolid or solid fecal matter.

Problem Associated with Fistula

1. *Fluid and electrolyte loss/disbalance* (PGI DEC 2000) -High output fistula may result in excessive fluid and electrolyte depletion.
2. *Skin excoriation* - Proximal intestinal fistula more commonly causes skin excoriation (damage) due to reaction of intestinal juice with skin.
3. *Sepsis*- Due to entry of intestinal content into peritoneal cavity.
4. *Hemorrhage* - Patients with fecal fistula are at risk of sudden hemorrhage from eroded vessels within fistula.

Management

1. Correction of fluid and electrolyte loss.
2. The patient should be kept nil orally. Intra venous fluid should be started.
3. Somatostatin analogue (Octreotide), lomotil or codeine may be useful to reduce fistula output.
4. Sepsis should be controlled by antibiotics.

KEY BOX 34.13		
Factors influencing spontaneous closure of fistulas		
Factor	**Favourable**	**Unfavourable**
Fistula	Long fistulous tract, intestinal continuity, absence of obstruction, End fistula, no abscess, Bilio pancreatic fistula	Short fistulous tract, diseased adjacent bowel, distal obstruction, abdominal wall defect
Organ of origin	Colon	Gastric, duodenum, ileum
Sepsis	Absent	Present
Etiology	Anastomotic leakage, bowel disease,	Malignancy, inflammatory
Age	Healthy adult	Old debilitated
Fistula output	<500 ml/day	>500 ml/day
Malnutrition	Absent	Present
Duration of fistula	Acute	Chronic

Surgical Treatment

- Most fistula (especially low output) will close with conservative treatment, provided there is no obstruction in distal bowel loop. Factors responsible for sponotaneous fistula closure are given in key box 34.13.
- If a fistula fails to close after 6-8 weeks, further investigation should be carried out to determine the underlying reasons; and surgical treatment should be considered.
- The basis of surgery is to remove the diseased bowel and the fistula and to carry out a restorative end to end anastomosis.

*****

ILEOSTOMY AND COLOSTOMY

This is a very important topic for Final prof. VIVA examination. May get a short case on this.

Stoma?

(Greek, mouth)- It is an artificially (surgically) created opening, between a loop of intestine and anterior abdominal wall. When this stoma is made between the ileum and anterior abdominal wall; it is called as ileostomy and when it is made between colon and anterior abdominal wall it is called as colostomy. *(UP 06)*

Ileostomy

This is an opening in a portion of ileum, through the anterior abdominal wall to out side body surface. The fecal matter is allowed to come out and collected in a bag worn on the anterior abdominal wall.

Colostomy

This is a opening in a portion of colon through the anterior abdominal wall to out side the body surface. The fecal matter is allowed to come out and collected in a bag worn by patient on the anterior abdominal wall.

Purpose of Ileostomy or colostomy

This is performed when the feces can not pass through the terminal ileum or colon and hence out from the anus because of some pathological condition or due to surgical removal of the distal bowel.

Temporary colostomies are done to divert the fecal flow to anterior abdominal wall from an inflamed/diseased or operated distal segment of colon. Later on when the disease has been cured in the distal segment (colon), the temporary colostomy is closed and bowel is dropped down (returned back) in abdominal cavity.

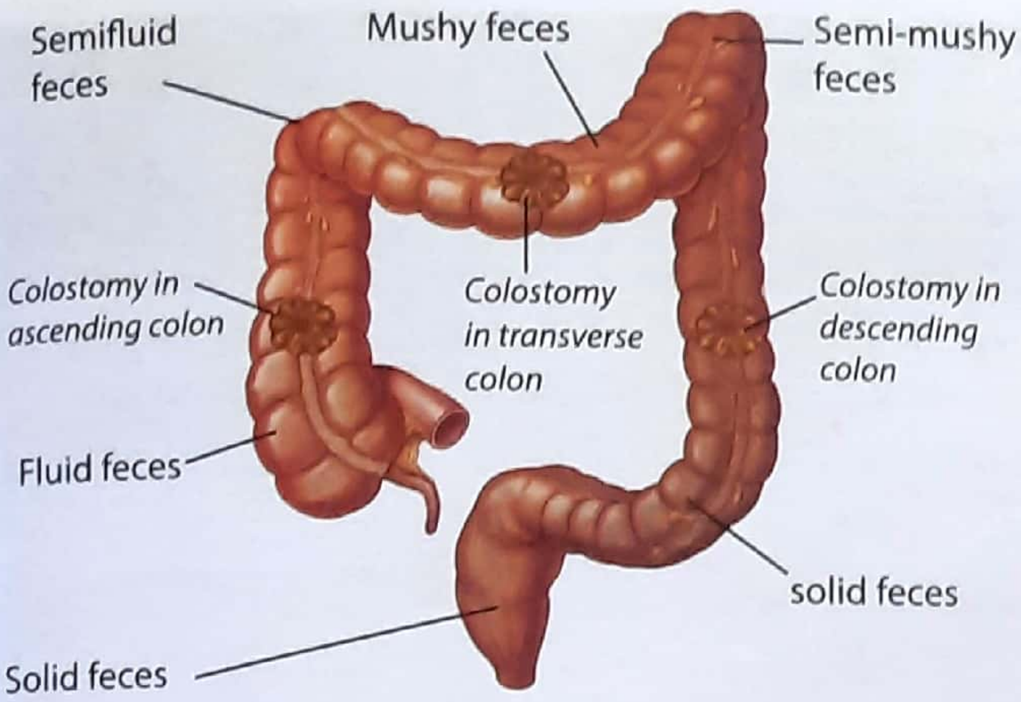

Figure 34.24.A: Sites of colostomy

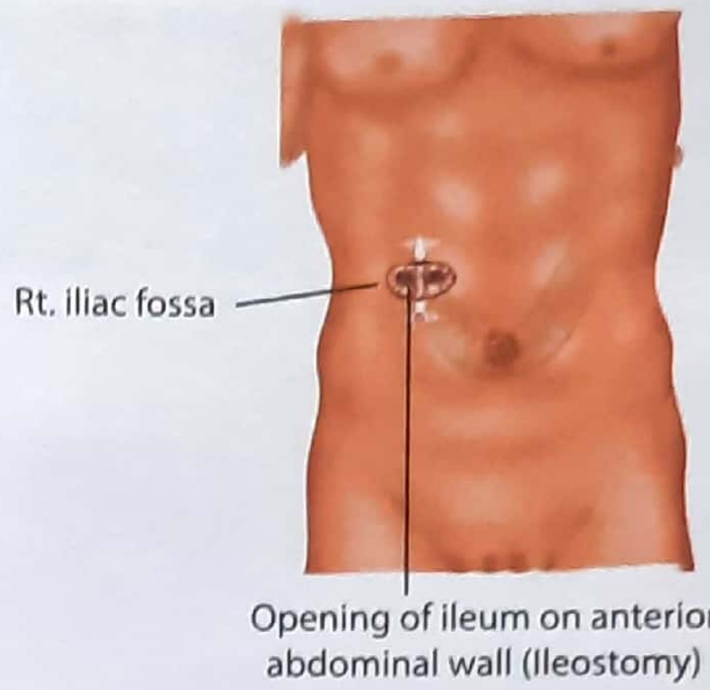

Figure 34.24.B: Ileostomy in right iliac fossa

Types of Ileostomy

- Loop ileostomy
- Permanent ileostomy

1. Loop Ileostomy (Temporary)

When a loop of ileum is brought out on the surface of anterior abdominal wall and opened, it is called as loop ileostomy. This is done to divert the feces to anterior abdominal wall [which is collected into a bag] so that feces do not pass distally in colon or terminal ileum; which is pathological/diseased. When the disease of colon or distal ileum is cured, the ileostomy wound (incision) is closed by suturing and is dropped down (returned back) into abdominal cavity. Please see figure 34.24. A&B carefully

2. Permanent Ileostomy

This is a permanent opening of ileum on the anterior abdominal wall. This is done when the resection of whole colon and/or rectum is required. For example; ulcerative colitis, advanced carcinoma of colon.

Ileostomy dysfunction: The daily output from ileostomy is about 500 ml and an amount more than 1000 ml is abnormal and termed as ileostomy dysfunction. This may produce water and electrolyte depletion.

Method of Creating a Colostomy

STEPS

For understanding purpose, I have narrated this with the help of diagrams:-

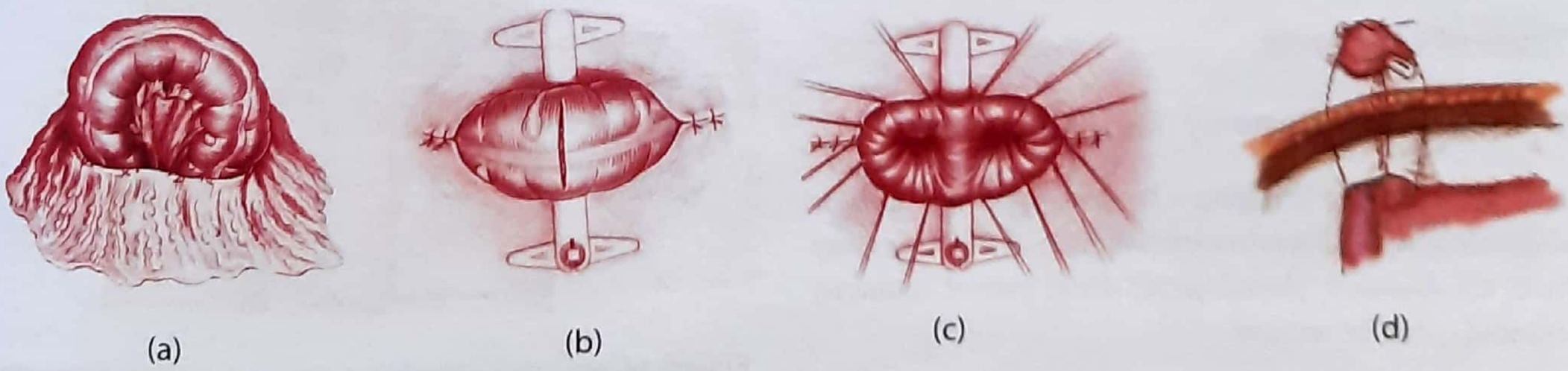

Figure 34.25: Steps in creation of colostomy; read text

KEY BOX 34.14	
How To Differentiate Between Ileostomy and Colostomy	
ILEOSTOMY	**COLOSTOMY**
1. SITE- Done more commonly in right iliac fossa 2. Content - Less formed (Liquid) 3. Colour of content is usually greenish (d/t bile) 4. Contents are odourless 5. Lumen of stoma is narrower 6. Appendices epiploicae and taeniae coli are not present.	• More commonly in right hypochondrium - (for transverse colostomy.) and left iliac fossa for sigmoid colostomy. • More formed (semisolid or solid). • Usually yellowish • Content have fecal odour • Lumen of stoma is wider • Some times, appendices epiploicae and taeniae coli may be seen.

Step I: A part of colon is pulled out on anterior abdominal wall, after making an incision on abdominal wall (Fig 34.25A)

Step II: Opening the colostomy (Note incision is made on anterior wall of the bowel loop) Fig. 34.25B

Step III: The open end of the colon is everted, Fig 34.25C

Step IV: The everted margins of colon is stitched to the anterior abdominal wall, to holds the colon in place. Fig 34.25D

NOTE: The steps in creating a ileostomy is same as that in colostomy. The difference lies only in selection of site on anterior abdominal wall.

- Ileostomy is most commonly made in right iliac fossa.
- Whereas a transverse colostomy is made in right hypochondrium and a sigmoid colostomy is made in left iliac fossa. Please see figure 34.26 & 34.27.

Types of Colostomy

1. Temporary colostomy (loop colostomy)

This is made after bringing a loop of colon on anterior abdominal wall. This provides diversion of the feces away from the diseased (pathological) distal part of colon, ie; sigmoid colon or rectum.

2. Permanent colostomy (end colostomy)

This is done after excision of the rectum for a carcinoma. This is formed by bringing the distal end (terminal end) of divided colon on the anterior abdominal wall and suturing it to the anterior abdominal wall (in the left iliac fossa). Figure (34.27), formed in Hartman's procedure.

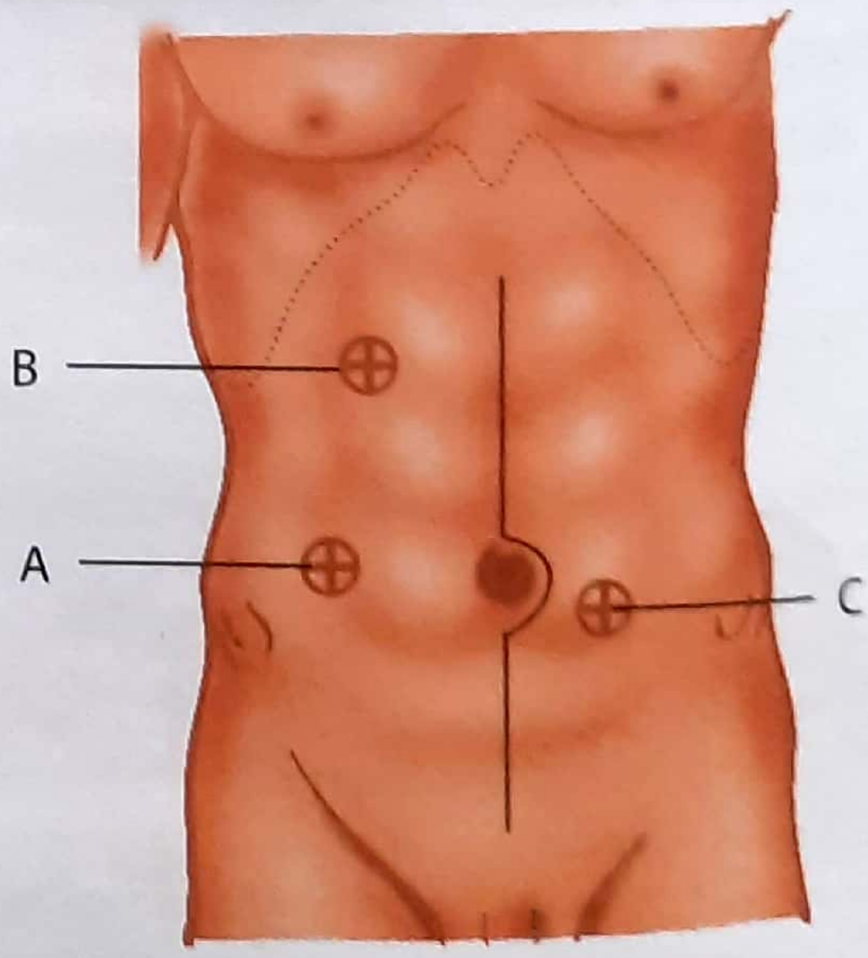

Figure 34.26: Site of ileostomy and colostomy (A) ileostomy (B) transverse colostomy (C) Pelvic/Sigmoid colostomy

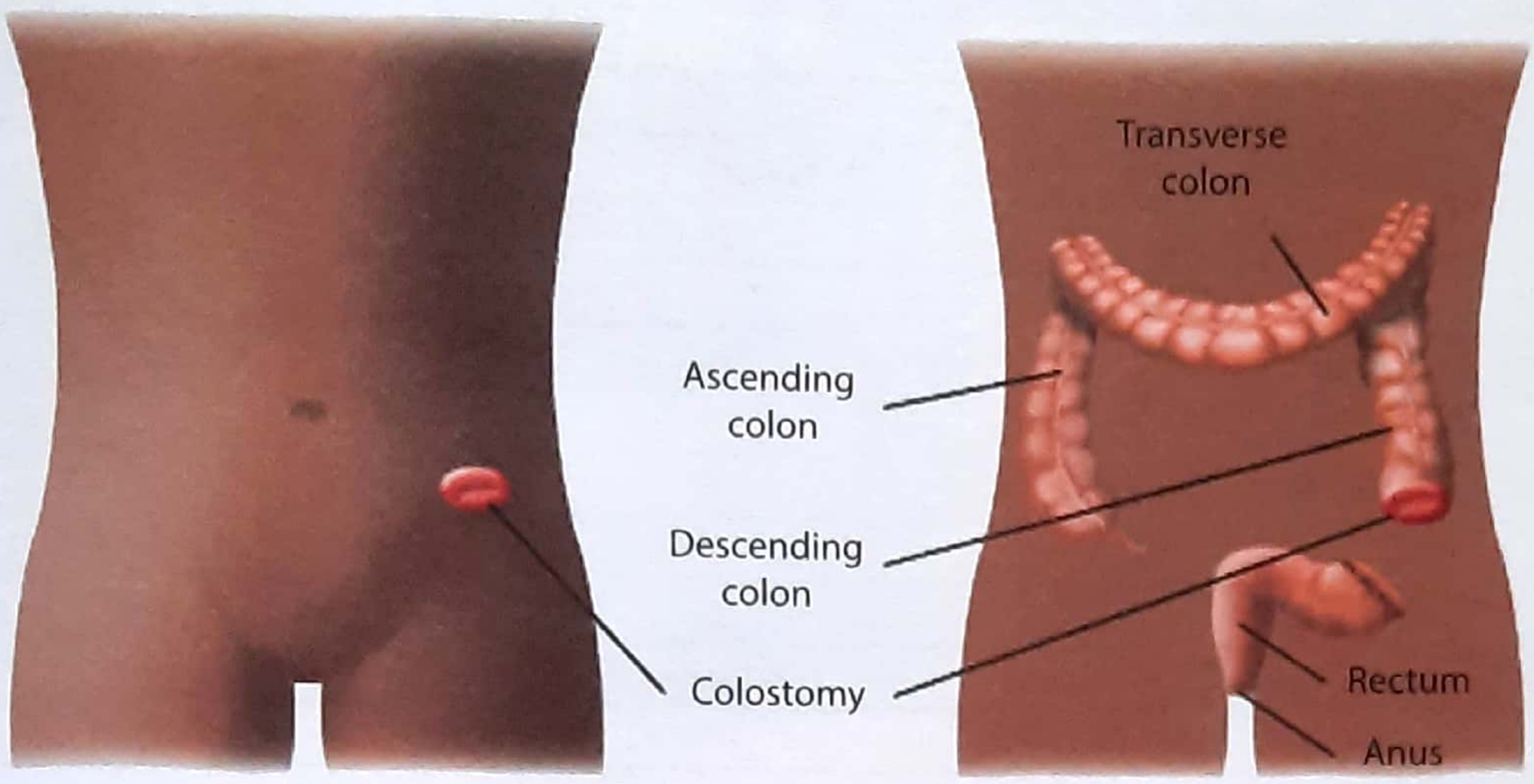

Figure 34.27: Bowel Resection end colostomy

3. Double barrel colostomy

In this is a spur is constructed between two antimesenteric limb of colostomy; which can subsequently be divided.

Contraindications for Colostomy

- Stoma near skin & bony prominence
- Poorly motivated patient
- Stoma through previous scan.
- Age is not a contraindication.

Complication of lieostomy and Colostomy

1. Ileostomy diarrhea (upto 4-5 liters/day) in early post operative period.
2. Skin problem: Chemical burning of skin (excoriation) by digestive enzymes and fungal infection.
3. Fluid and electrolyte loss; more in ileostomy
4. Leakage of intestinal content: due to poorly fitted appliance (colostomy bag)
5. Retraction of intestinal stoma.
6. Stenosis of the stoma
7. Obstruction
8. Ulceration at mucocutaneous junction may cause bleeding.
9. Parastomal hernia (M/C with end colostomy) (AI 09)
10. Odour of content (more offensive in colostomy)
11. Prolapse of colostomy
12. Colostomy diarrhea.

NOTES

Sample Questions for Prof Examination

1. Describe the pathology and clinical features of carcinoma of pelvic (sigmoid) colon - How will you investigate and treat it ?
2. Write short notes on:

   Meckel's diverticula

   Hirschsprung's disease

   Carcinoid Tumour

   Diverticular disease

35 Intestinal Obstruction

Contents

- Classification
- Dynamic (mechanical) intestinal obstruction
- Closed loop obstruction
- Important causes of intestinal obstruction
  - Volvulus
  - Volvulus neonatorum
  - Volvulus of the small intestine
  - Cecal volvulus
  - Volvulus of sigmoid
  - Intussusception
  - Adhesive intestinal obstruction
  - Band causing intestinal obstruction
- Acute intestinal obstruction of new born.
  - Congenital atresia
    - Duodenal atresia
    - Jejuno-ileal obstruction
    - Arrested rotation with band
    - Meconium ileus
    - Meconium - plug syndrome
- Adynamic obstruction
- Pseudo obstruction
- Mesenteric vascular disease
  - Acute mesenteric ischemia
  - Chronic mesenteric ischemia
  - Mesenteric venous thrombosis

The normal flow of intestinal contents may get blocked or interrupted by a mechanical cause or because of impaired intestinal motility as a result of which patient presents with an acute abdomen.

Intestinal obstruction can be classified as:

1. **Dynamic (mechanical) or**
2. **Adynamic (Paralytic)**

DYNAMIC (MECHANICAL) INTESTINAL OBSTRUCTION

In this condition, there is a **physical barrier obstructing the progress of the intestinal contents** ie; food and intestinal secretions.

Classification

The obstruction may be classified **on the basis of**

1. Degree of block

(i) Complete or

(ii) Partial

2. Integrity of blood supply

(a) Simple: Blood supply to bowel is intact.

(b) Strangulated: When blood supply of bowel is compromised at an early stage. This may lead to gangrene of bowel or rupture and peritonitis.

3. Nature of presentation

(a) **Acute:** Usually seen in small intestine with sudden onset of severe colicky central abdominal pain, distension and constipation.

(b) **Chronic:** Usually seen with large intestine with lower abdominal colic and absolute constipation followed by distension.

(c) **Acute on chronic:** This usually starts in large intestine and later involves the small intestine as well.

(d) **Subacute:** Implies incomplete obstruction.

4. Level of obstruction

(a) **High small bowel:** Vomiting occurs early with rapid dehydration and minimal distension.

(b) **Lower small bowel:** Pain is predominant symptom and central abdominal distension is marked. Vomiting is often delayed.

(c) **Large bowel:** Distension is early. Pain is usually mild, however; vomiting is either very late or absent.

KEY BOX 35.0

Causes of intestinal obstruction

Dynamic

- Intraluminal
  - Faecal impaction
  - Foreign bodies
  - Bezoars
  - Gallstones
- Intramural
  - Stricture
  - Malignancy
  - Intussusception
  - Volvulus
- Extramural
  - Bands/adhesions
  - Hernia

Adynamic

- Paralytic ileus
- Pseudo-obstruction

Etiology

The various causes of mechanical intestinal obstruction can be grouped as extramural, intramural and intraluminal. (NOTE: *mural means; wall of an organ)*

A. Small Intestine

(a) Extramural: (From out side the wall)

(i) *Adhesions develops after abdominal surgery* (NEET): are the *most common cause* (NEET).

(ii) Internal hernias

(iii) Tumours

(iv) Intra abdominal abscesses

(v) Malrotation with Ladd's bands.

(vi) Annular pancreas (duodenal obstruction)

(vii) Bands: Congenital or acquired

(viii) Intussusception

(ix) Volvulus

(b) Intramural: (In the wall of intestine)

(i) Small bowel neoplasms.

(ii) Congenital lesions: Atresia, Stenosis, Meckel's diverticulum.

(iii) Inflammatory lesions : Tuberculosis, Crohn's disease, radiation and postoperative strictures, diverticulitis.

(c) Intra-luminal (Inside the lumen of bowel)

(i) Meconium ileus

(ii) Gall stone ileus.

KEY BOX 35.1

Cardinal features of obstruction (A,B,C,D)

- **A**bdominal pain
- **B**ilious vonMting/Vomiting
- **C**onstipation
- **D**istension

(iii) Foreign bodies : Bezoars, worms infestation and swallowed foreign bodies.

(iv) Incompletely digested food material; especially after gastrectomy (bolus obstruction)

B. Large Intestine

(a) Extramural (From out side the wall)

(i) Volvulus: Sigmoid (75%), Cecal (20-30%).

(ii) Adhesions (post operative, inflammatory)

(iii) Hernia, particularly sliding type.

(b) Intramural (In the wall of intestine)

(i) Carcinoma of the colon: This is the most common cause of large bowel obstruction. *(PGI 86, UPSC 88)*

(ii) Inflammatory lesions : Ulcerative colitis, diverticulitis, radiation enteritis.

(iii) Imperforate anus (In neonatal period)

(c) Intraluminal (Inside the lumen)

(i) Meconium ileus.

(ii) Fecal impaction, foreign bodies

Pathophysiology

1. Changes above the level of obstruction

Dilatation and distension of the bowel due to:

(a) Gas: Swallowed atmospheric air (70%) *(AI 95, PGI 98)*, diffusion of gas from the blood into the bowel lumen (20%) and products of digestion and bacterial activity (10%) the majority (90%) of this gas is made up of nitrogen and hydrogen sulphide. *(IMP. POINT)*

(b) Fluid : This is made up of various digestive juices, such as saliva (1000-1500 ml), gastric juice (1500-2500 ml), bile (1000 ml), pancreatic juice (1500 ml), succus enterricus (3000 ml). Following obstruction, these fluids accumulate within the bowel lumen proximal to obstruction and aggravates abdominal distension. Key box 35.2.

(c) Peristalsis: Initially; there is increased peristalsis to overcome the obstruction. If the obstruction is not relieved the bowel begins to dilate causing a reduction in peristaltic activity and ultimately resulting in flaccidity and paralysis of bowel musculature.

KEY BOX 35.2

Approximate.volumes of digestive juices produced fey the gut in 24 hours

Saliva	1000-1500 ml
Gastric juice	1500-2000 ml
Bile	1000 ml
Pancreatic juice	1500 ml
Succus enterricus (from small intestine)	3000 ml

2. Changes below the level of obstruction:

The bowel exhibits normal peristalsis and absorption until it becomes empty; when it contracts and becomes immobile.

3. Physiological effects

(a) Dehydration and electrolyte loss due to

(i) Reduced fluid intake and vomiting

(ii) Defective intestinal absorption

(iii) Sequestration in the bowel lumen.

(b) Diminished diaphragmatic movements

Due to abdominal distension and consequent pulmonary complications.

(c) Hypovolemic shock

(d) Thrombosis of the mesenteric veins.

KEY BOX 35.2-1

Causes of strangulation

Direct pressure on the bowel wall

- Hernia orifices
- Adhesions/bands

Interrupted mesenteric blood flow

- Volvulus
- Intussusception

Increased intraluminal pressure

- Closed-loop obstruction

4. Strangulations

- The viability of the bowel is threatened; because of impairment of blood supply.
- Initially venous return is compromised, causing edema of the bowel wall. Later on arterial supply is also impaired leading to gangrene and subsequent perforation of intestinal wall. *(IMP. POINT)*

Clinical features

The clinical feature of *acute intestinal obstruction* and *strangulated intestinal obstruction* vary:

1. Acute Intestinal Obstruction

This type of obstruction has *four cardinal features, pain, vomiting, distension and constipation.* These features vary according to:- the location of the obstruction, the duration, the underlying pathology and the presence or absence of intestine ischemia. Late manifestations that may be seen, include dehydration, oliguria, hypovolemic shock, pyrexia, septicemia, respiratory embarrassment and peritonism.

(a) Pain: Pain is the first symptom *(PGI 82, DNB 90)* occurring suddenly and is usually severe. It is colicky in nature and is usually felt around the umbilicus or lower abdomen. *Constant severe pain indicates either infarction (gangrene) of the bowel or the onset of peritonitis (PGI DEC 03).* (**Note:**- Paralytic ileus is painless).

(b) Vomiting: Vomiting is a marked feature of high (ie; proximal) small bowel obstruction; but is less commonly encountered in colonic (ie; large bowel) obstruction. The more distal the obstruction; the longer is the interval between the onset of symptoms and the appearance of nausea and vomiting. Initially the vomitus consists of food followed by bile stained fluid which later on becomes feculent (caused by bacterial overgrowth). Blood in the vomitus indicates strangulation of bowel.

(c) Distension - In the small bowel the degree of distension is dependent on the site of obstruction; the *more distal the lesion the greater is the distension (PGI DEC 03).* It is caused by accumulation of gas and fluid within the obstructed bowel. Visible peristalsis may be present. Distension is delayed in colonic obstruction. *The prime cause of distension is swallowed atmospheric air.* *(MANY PGME)*

KEY BOX 35.3

Obstruction
↓
Distension proximal to obstruction
↓
Venous compression
↓
Congestion and edema of bowel wall
↓
Progressive arterial compromise
↓
Ischaemia of bowel
↓
Gangrene
↓
Perforation of bowel wall
↓
Peritonitis
↓
Septic shock

(d) Constipation - may be classified as absolute (ie; neither feces nor flatus is passed, ie; obstipation) or relative (where only flatus is passed). Obstipation is a cardinal feature of complete intestinal obstruction. Constipation may not be present in Richter's hernia, gall stone ileus, mesenteric vascular occlusion, obstruction with pelvic abscess and partial block. (see key box 35.4)

KEY BOX 35.4

Intestinal obstruction without constipation

- Richter's hernia
- Gall stone ileus
- Mesenteric vascular occlusion
- Obstruction associated with pelvic abscess
- Fecal impaction/colonic neoplasm

(e) Other manifestations

(i) Dehydration

(ii) Hypokalemia

(iii) Fever

(iv) Abdominal tenderness & rebound tenderness are indicative of ischemic bowel & developing peritonitis.

(v) Auscultation confirms the presence of excessive bowel sound.

(vi) Rectal examination in small bowel obstruction usually reveals an empty rectum.

Vomiting & abdominal distension is sure sign of obstruction.

2. Strangulated Intestinal Obstruction

It is important to distinguish strangulating from non strangulating obstruction. In addition to the features of simple obstruction, additional features are :

(i) Presence of shock

(ii) Persistent pain

(iii) Generalized tenderness

(iv) Rigidity

(v) Rebound tenderness (due to peritonism*)

(vi) Persistent pain in spite of adequate conservative management.

Figure 35.1.1: Visible peristalsis in a patient of acute intestinal obstruction

NOTE: *PERITONISM?: It is a condition having the clinical signs of peritonitis and shock; without inflammation of the peritoneum.

Investigation

The diagnosis of intestinal obstruction is usually made by history and clinical examination; however some investigation may help in confirming diagnosis.

1. ***Blood examination***: In early phase, in which the effects are predominantly due to extracellular fluid loss, the hematocrit rises in proportion to fluid loss.
   - WBC levels are elevated in strangulated obstruction.
   - Electrolyte abnormalities; commonly hypokalemia.
2. ***X-ray of abdomen***: Plain films of the abdomen are taken with the patient standing and lying down and *is investigation of choice.* (PGI JUNE 03, MANY PGME)
   - **Multiple air fluid levels are pathognomonic of intestinal obstruction** (NEET). Gas levels appear earlier than fluid level. fig 35.15.1 page 655 (PGI 96, MANY PGME).

X-ray findings

- *The jejunum* is characterised by its valvulae conniventes, which completely pass across the width of the bowel & are regularly spaced giving a "concertina" or ***step ladder pattern*** (NEET). [Figure (35.1.2)]

Figure 35.1.2: (Note step ladder pattern)

- Distal ileum is relatively featureless.
- The *large bowel shows haustral folds.*
- *Cecum* shows a large oval gas shadow in right iliac fossa.
- String of pearl appearance in small bowel obstruction.
- *Sigmoid volvulus* appears as a large dilated loop of bowel which resembles a "bent inner tube", "coffee bean" or symbol "omega" with the apex in left lower quadrant and the convexity in the upper right quadrant *(MANY PGME)*
- To know whether large or small bowel obstruction first check cecum - if distended large bowel obstruction if collapsed - small bowel *(AIIMS NOV 18)*.

KEY BOX 35.5

Differentiation of healthy (viable) and strangulated (non-viable) bowel at laparotomy.

Intestine	Viable	Non-viable
• Apperance of bowel at laparotomy	Colour is lighter and pinkish	Dark brown in colour
• Mesentery	Bleeds if pricked	Does not bleed if pricked
• Peritoneum	shiny	Dull or lusterless
• Intestinal musculature	Firm, peristalsis may be observed	Flabby, thin and friable, no peristalsis.

Management

The principles in the management of intestinal obstruction are following A, B, C, D, E, F

A. Admission in the hospital - Patient is Admitted in the hospital & Advised not to take any thing orally.

B. Bowel care and Blood arrangement - *Use of purgative is contraindicated* *(PGME)*. Blood should be arranged for transfusion during/after the surgery, especially if strangulation is suspected.

C. Charting and Chemotherapy - Charting of temperature, pulse rate, respiratory rate, blood pressure and urine out put should be started and done at regular short time intervals. Chemotherapy in form of pain killers & intravenous antibiotics should be started.

D. Decompression of bowel- is done by introducing a Ryle's tube in stomach. This is an important step in early management of intestinal obstruction. This helps in decreasing distension, vomiting and pain.

For Ryles's tube please see figure 35.16 on page 656.

E. Emergency laparotomy: In almost all cases of acute intestinal obstruction, emergency laparotomy is required. The abdomen is opened by an appropriate midline incision and obstruction is treated upon findings. Few examples are given below:-

- If a ***band is found*** - it is ***divided***, (cut)
- ***Adhesion B/W intestinal loop - Released***.
- ***Volvulus : derotation*** of bowel is done and if gangrene is present resection of the gangrenous segment of bowel and end to end anastomosis is done between healthy (viable) bowel loop. (See key box 35.5)
- ***Intestinal stricture: stricturoplasty*** or resection of diseased part of intestine. (Followed by anastomosis)
- *Enterostomy:* for obstruction cause by; gall stone ileus, bezoars, foreign body, food.

NOTE: Enterostomy - means opening the intestine (bowel) by making a small incision on it followed by its closure.

F. Fluid and electrolyte balance - Fluid and electrolyte deficit should be corrected. This has very important role in treatment of intestinal obstruction. Close watch on fluid and electrolyte status is kept before, during and after surgery.

Ileal obstruction due to round worm infestation - enterotomy, removal of worm & primary closure of bowel (ileum).

NOTE: In acute partial ileal obstruction non-operative management is often successful.

*****

CLOSED LOOP OBSTRUCTION

As the term indicates itself; that it is an obstruction within a closed loop. This occurs when the bowel is obstructed at both the proximal and distal points forming a closed loop. The example of closed loop obstruction are:

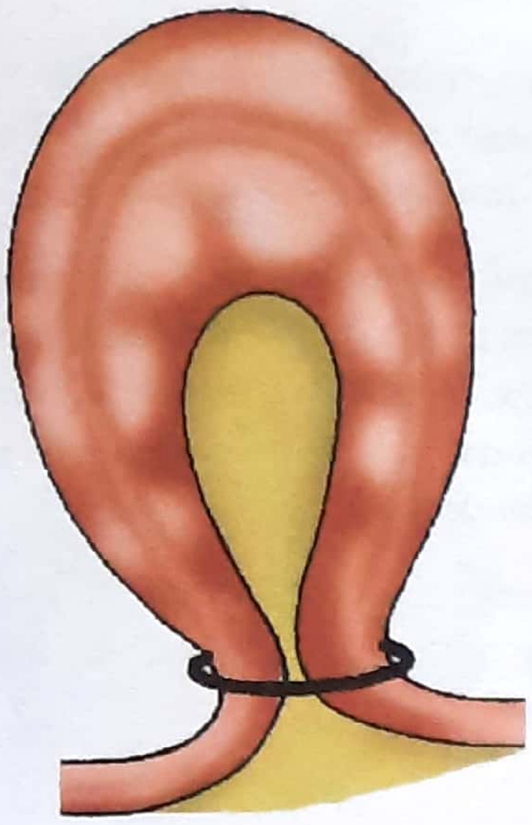

Figure 35.2: Closed loop obstruction

- Volvulus
- Strangulated hernia
- Annular (constricting) carcinoma of left side colon ie; descending colon and sigmoid colon.

Pathophysiology

- This condition is usually seen with a left side annular (constricting) carcinoma of colon, with *competent* ileo-cecal valve. A competent ileocecal valve does not allow backflow of colonic content into ileum.
- The intestine between the ileocecal valve and carcinoma of colon becomes a closed loop and the condition is known, as closed loop obstruction.
- There is no early distension of the proximal intestine.
- With the passage of time the intraluminal pressure with in this closed loop increases and *caecum bears the maximum pressure* (PGI 89) and becomes markedly distended, with subsequent impairment of blood supply resulting in perforation of cecum, through a clear cut hole, known as *pistol shot* perforation.

*****

IMPORTANT CAUSES OF INTESTINAL OBSTRUCTION

In this section we will discuss :

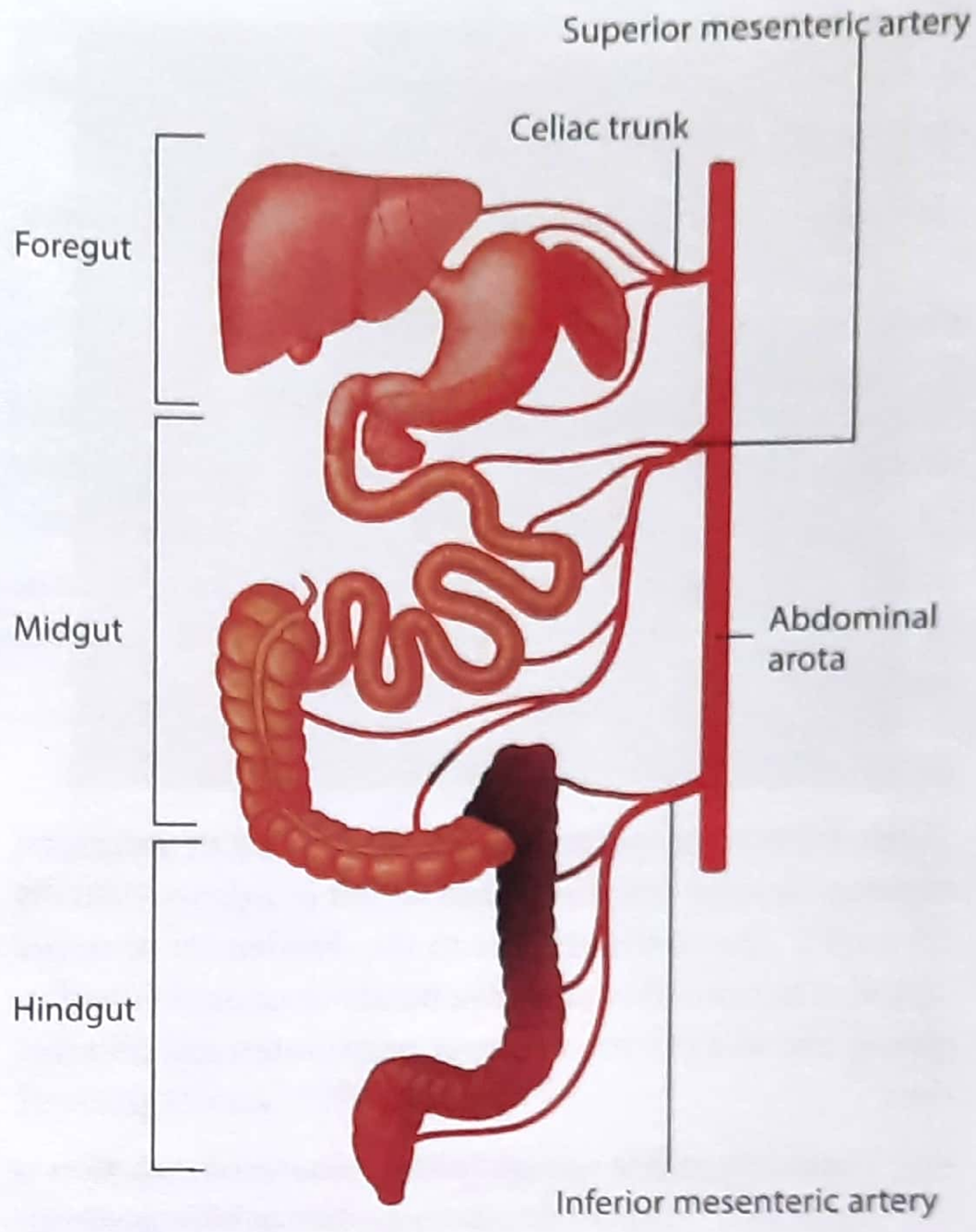

Figure 35.3: Foregut, mid gut and hind gut and their blood supply

- Volvulus
- Intussusception
- Obstruction by adhesion
- Band causing intestinal obstruction

Now lets take each of them, one by one:

Volvulus (Twisting Of Bowel) (AI 08)

Volvulus is defined as; **twisting or axial rotation of a portion of bowel around it's mesentery.** When complete, it forms a closed loop obstruction with resultant ischemia due to vascular occlusion. There are two clinical types: Primary and secondary

Primary Volvulus: Occurs as a result of congenital malrotation of the gut, abnormal mesenteric attachment or congenital bands. (See fig. 35.4) Examples: include volvulus neonatorum, cecal volvulus and sigmoid volvulus, (described on next page)

Secondary volvulus: This is more common and is due to axial rotation of a small segment of bowel loop around an acquired adhesion.

Now lets take some common types of volvulus one by one:

Volvulus Neonatorum

Volvulus neonatorum usually *occurs in the midgut and develops when the intestine twists on its vascular pedicle (the superior mesenteric artery) and causes ischemia* (NEET) and obstruction of entire mid gut. The condition can be very serious- leading to gangrene of the entire small bowel.

Clinical feature

Three fourths of patients with anomalies of intestinal rotation *develop intestinal obstruction in infancy* (usually 1st week). The obstruction is in the duodenum or upper jejunum as a result of adhesive bands or midgut volvulus; giving rise to a picture of upper gastrointestinal obstruction.

- Vomiting of bile occurs initially (note; obstruction is distal to 2nd part of duodenum - hence bilious vomiting)
- Bloody stool with signs of peritonitis are manifestations of intestinal ischemia.

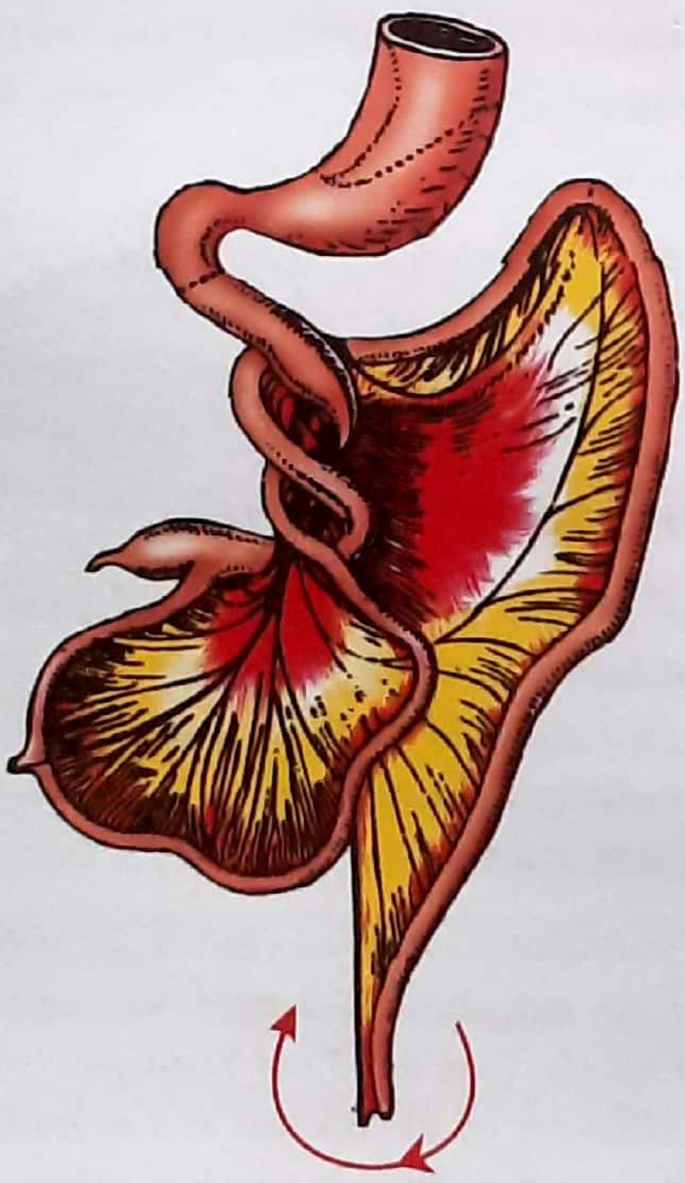

Figure 35.4: Volvulus neonatorum (note: clock wise rotation)

Investigations

1. *Plain X-ray* - reveal evidence of duodenal obstruction. A dilated stomach (proximally) and a duodenum gives 'double bubble' appearance.
2. *Barium meal* is confirmatory; revealing the abnormal position of the duodenojejunal junction, which is seen right of midline in this condition, (NOTE: duodenojejunal junction is normally placed to the left of midline).
3. An *ultrasound* examination may show an abnormal relationship of the superior and inferior mesenteric artery and vein.

Treatment

- The only treatment is surgical.
- Because most of the time volvulus neonatorum ***results from clockwise twisting*** of small bowel. Untwisting (derotation) is ***done in anticlock wise manner to relieve obstruction.*** (MANY PGME)
- If trans-duodenal *band of ladd* is found; it should be divided.

Volvulus of Small Intestine

- This may be primary or secondary and usually occurs in the lower ileum. (Fig 35.5)
- It may follow an adhesion formation from the antimesenteric border of an intestinal loop to the parietes or to the female pelvic organs, due to previous surgery or Meckel's diverticulum.
- Sometimes It could be related to consumption of large amounts of vegetable matters.
- Clinical signs and symptoms are similar to those of acute intestinal obstruction.
- **Treatment** consists of reduction of twist with great care, looking for signs of gangrene and removal of causative factor.

Cecal Volvulus

Etiology

1. This may occurs as a part of volvulus neonatorum or de novo; the *twist is usually clockwise.* (IMP. POINT)
2. It usually occurs along with part of ileum and ascending colon and is called ileocecal volvulus.

Figure 35.5 (a) : Volvulous of small intestine

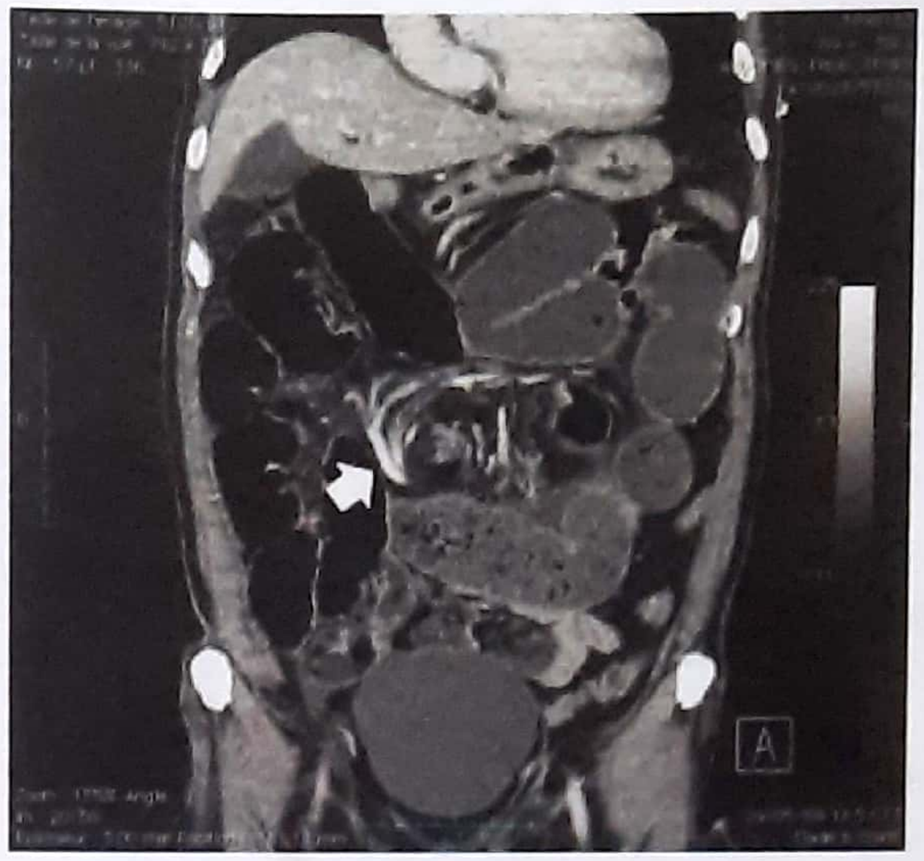

Figure 35.5 (b) Volvulus of Small Intestine (CT scan)

3. It is more common in women and usually presents itself as acute intestinal obstruction.
4. Predisposing factors are, lax and mobile cecum, ascending colon and previous surgery.

Clinical features

1. Symptoms are similar to small bowel obstruction.
2. Initially the obstruction may be partial with the passage of flatus and feces.
3. It may cause acute closed-loop obstruction with rapidly supervening gangrene and generalized peritonitis.

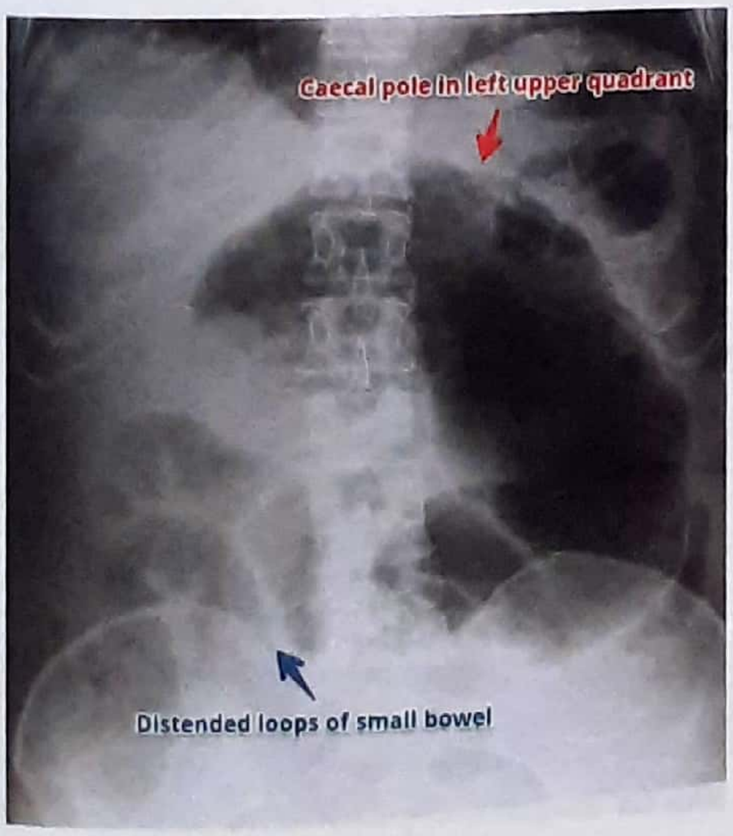

Figure 35.5 (c) : Cecal Volvulus

Investigations (PGME)

1. Plain X-ray reveal an *Oval gas shadow in right iliac fossa* (IMP, POINT). Figure 35.5 (c)
2. Barium enema reveals the narrowing, accompanying the twisting of the colon (bird's ***neck*** deformity) and absence of barium in the cecum.

Treatment

1. The condition may resolve spontaneously, but usually requires surgical intervention.
2. Surgery consists of derotation of cecum followed by cecopexy* and/or a cecostomy.
3. If the cecum is ischemic or gangrenous, a right hemicolectomy is performed.

For Hindi speakers; When suffix- pexy is used, it means "chipkana". (ie; anchoring) In cecopexy cecum is fixed to posterior layer of anterior abdominal wall by applying a suture.

Volvulus of The Sigmoid Colon

Etiology

- It is the *commonest cause of large bowel obstruction* (DNB) in Africa, Europe and USA. It is also reported to be very common in India and accounts for 7% of all cases of intestinal obstruction.
- It is frequent in elderly, institutionalized patients; who are mentally retarded.

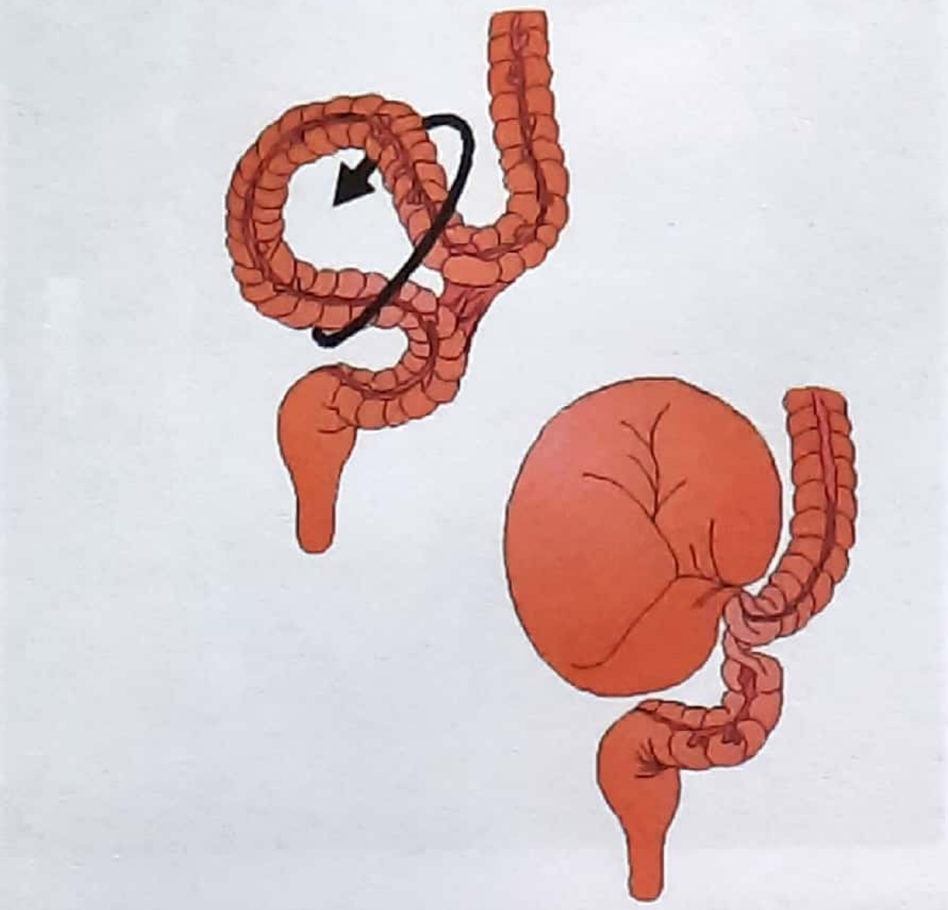

Fig 35.6 (a) : Volvulus of sigmoid colon; note the anti-clock wise twist *(UP 05, 07)*

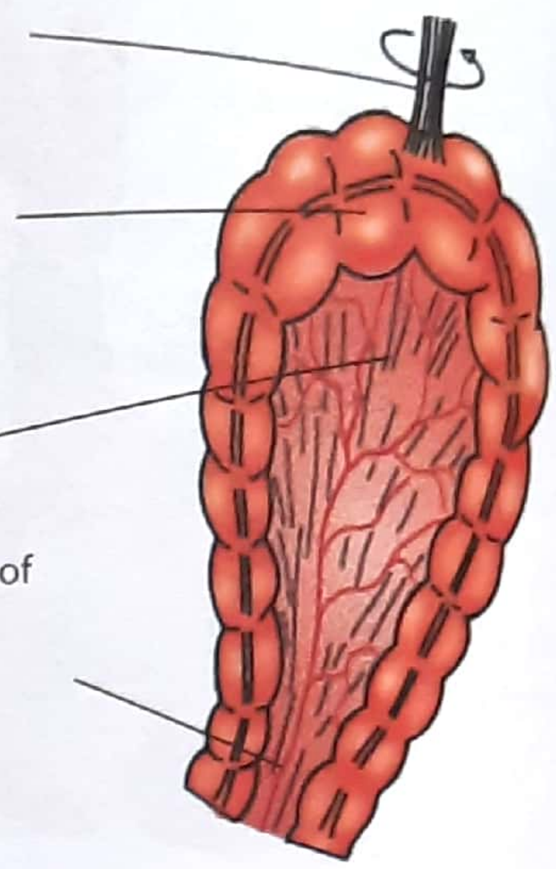

Fig 35.7: Etiology of sigmoid volvulus

- ***Predisposing causes*** *(PGME)* are;
  - (i) long pelvic meso-colon,
  - (ii) Overloaded pelvic colon
  - (iii) Band of adhesions (peridiverticulitis) and
  - (iv) Narrow attachment of the pelvic mesocolon. Other factors include previous surgery, high residue diet and **chronic constipation** *(NEET)*. Please see figure 35.6 (a & b) and 35.7.
  - (v) Chaga's disease
  - (vi) Hirschsprung's disease
- **Torsion occurs** around the mesenteric axis, and always in **Anti-clockwise direction.** *(UP 05, 07, MANY PGME)*. Please see figure 35.6 (a).
- It is the commonest cause of strangulated obstruction in the large intestine.

Figure 35.6 (b) : Volvulus of The Sigmoid Colon

Clinical Features

- The symptoms are of large bowel obstruction, which may initially be intermittent, followed by the passage of large quantities of flatus and feces.
- Abdominal distension is an early and progressive sign, which is massive. Hiccups and vomiting occurs late.
- Constipation is absolute.
- The development of generalized abdominal pain, tachycardia, tenderness, fever and hypovolemia suggest that strangulation of bowel has occurred.

Investigation

1. Plain *X-ray shows massive colonic distension.* A dilated loop of bowel running diagonally across the abdomen from right to left, with two fluid levels seen, one within each loop of bowel, the so called *"bent inner tube"* or ***"omega sign,*** *(MANY PGME)* (Fig. 35.6b)
2. A barium enema shows the column of barium tapering to a narrow point, the appearance having been described as a ***'bird's beak'*** pointing towards the

site of obstruction. Barium enema is contraindicated if strangulation is suspected.

Treatment

- At laparotomy; the sigmoid is **derotated** (in **clockwise direction**), then sigmoid colon is assessed for viability. If the sigmoid is viable, then this loop is fixed to the posterior layer of anterior abdominal wall in the left iliac fossa **(sigmoidopexy)***, which may be sufficient in most of the cases. [For viability of bowel- see box 35.5 on page 642]

SIGMOIDOPEXY? Surgical fixation of sigmoid colon to inner surface of anterior abdominal wall in left iliac fossa, as to avoid future/recurrent torsion.

- If volvulus cannot be reduced (derotated), strangulation should be suspected and immediate resection of sigmoid is carried out. ***Paul- Mikulicz procedure*** is useful, particularly if there is suspicion of impending gangrene. This procedure involves resection of strangulated segment, (figure 35.9)
- An alternative is a sigmoid colostomy. Alternatively defer the reconstruction of the colon to a later date & limit the emergency operation to a hartmann's procedure.
- Resection of the sigmoid loop & end-to-end anastomosis between descending colon & rectum (colorectal anastomosis) is indicated for recurrent obstruction.

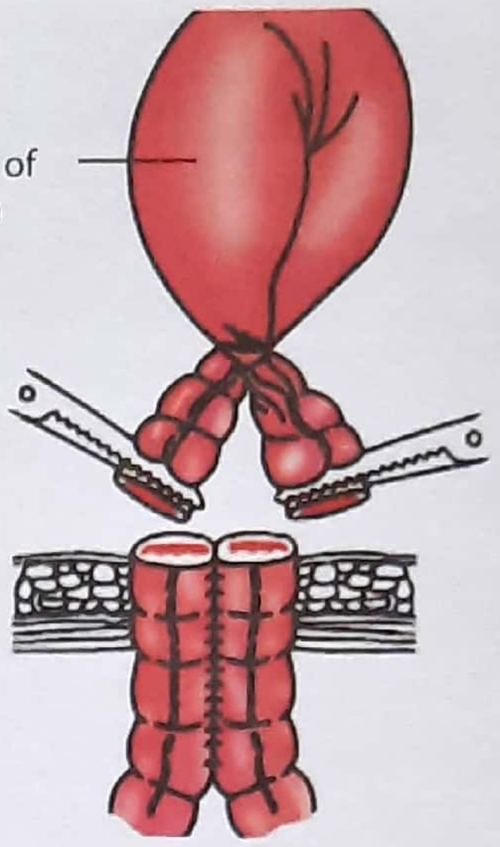

Figure 35.9: Paul-mikulicz operation for sigmoid volvulus

Compound Volvulus (Ileo-Sigmoid Knotting)

- This is not a true sigmoid volvulus, but as both the ileum and sigmoid colon undergoes twists and both of them are involved in producing the features of volvulus, it is called compound volvulus. (figure 35.9E)
- This occurs due to long mesentery of ileum getting twisted around the sigmoid colon.

*****

Figure 35.8: On (operative) table photograph of sigmoid volvulus; note massively distended sigmoid colon

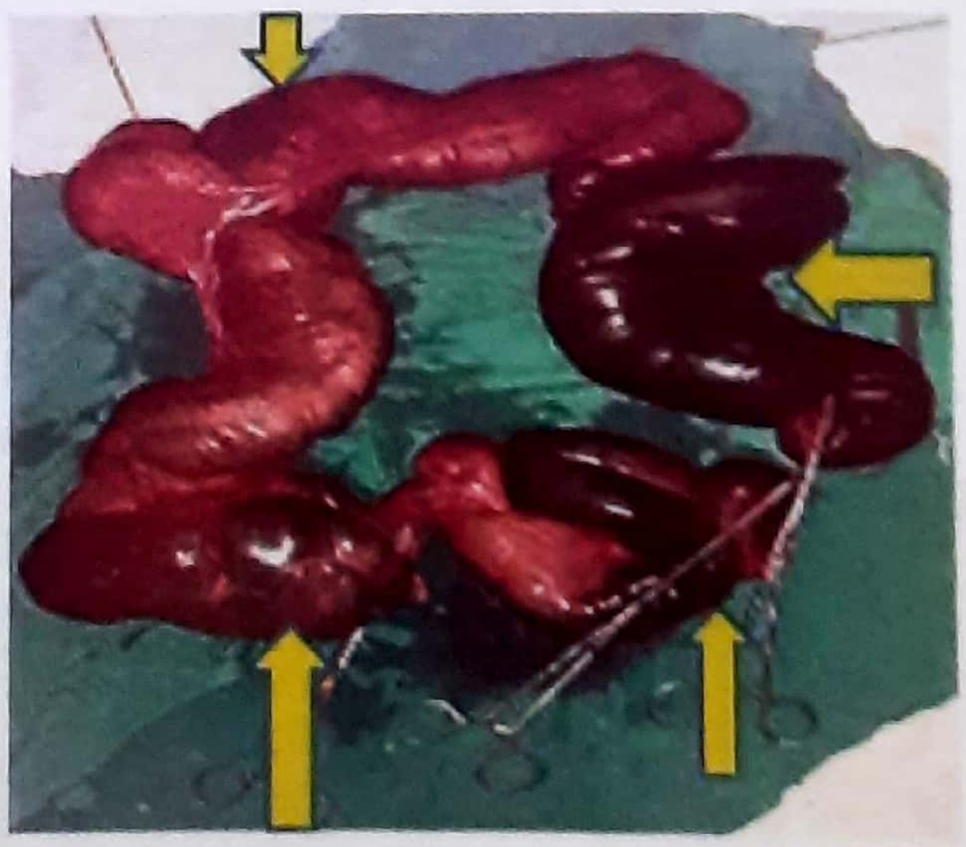

Figure 35.9E : Compound Volvulus

INTUSSUSCEPTION

Intussusception is defined as invagination of *one part of the intestine into the adjacent part (almost always the promixal into the distal* and very rarely in the opposite direction ie; retrograde). Please see figure 35.10. *Intussusception usually begins from terminal ileum.* (NEET)

Etiology

1. This is the most common cause of bowel obstruction in the age group 2 months to 5 years (peak incidence at 3-9 months). It is more common in males.
2. In about 70-95% of cases cause is idiopathic.
3. An associated illness, such as gastroenteritis or urinary tract infection is found in 30% of the patients.
4. It may also be related to upper respiratory tract infection such as adenovirus or rotavirus.
5. Some children may have a lead point such as a meckcel's diverticulum, polyp, Henoch-Schonlein purpura, (JIP. 80, 81 AIIMS 90) lymphoma, submucosal lipoma or hemangioma, carcinoid tumour, ascaris lumbricoides, worm infestation and appendicitis.
6. Adult cases are invariably associated with some cause, which are usually a polyp, a submucous lipoma, meckel's diverticula or tumour.
7. Peak incidence is during summer and springs.
8. *Most common cause is hypertrophy of submucous peyer's patches.* (NEET)

Figure 35.10: Formation of intussusception (Read text)

Part of Intussusception

[Figure 35-11 and 35-12]

1. **Intussuscipiens - This is the outer tube (distal bowel)** (PGI DEC 97) **which receives the inner tube (proximal bowel) into it.** (NEET)
2. **Intussusceptum**- It is proximal bowel (inner tube) which enters inside the distal bowel.
3. **Apex**- It is the part which advances into the distal bowel. Please see figure 35.11.
4. **Neck**- This is the junction of entering layer with the mass. This is the narrowest part.

Various type

- There are various types of intussusception but the **commonest variety is ileocolic.** (NEET, AI 89, PGI DEC 95, UP 01) followed by ileocecal.
- Next common are ileo-ileo-colic and ileoileal, while least common being colo-colic. Please see box 35.6.
- However, colo-colic intussusception is most common in elderly and mostly occurs due to malignancy.

Clinical features

Clinical features vary in children and adults. The condition is very common in children and the features are:-

1. Sudden onset of severe, cramping abdominal pain, associated with drawing up of legs. Pain last for a few minutes, recur every 15 minutes and become progressively severe.
2. During attacks; the child has facial pallor and between attacks is listless and drawn.

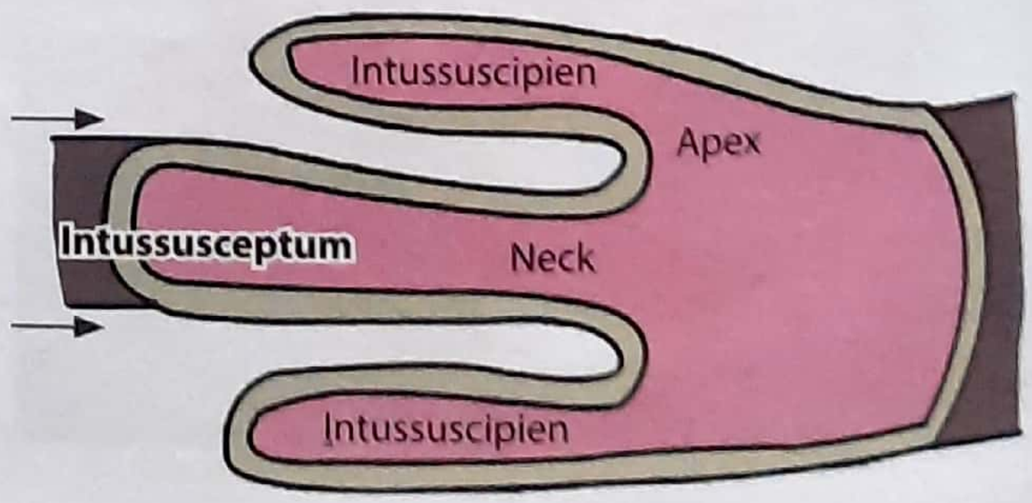

Figure 35.11: Different parts of intussusception

Figure 35.12A: Ileocolic intussusception causing small bowel obstruction (on table photograph)

KEY BOX 35.6	
Types of intussusception in children (after RE Gross) (n=702)	
	Percentage of series
Ileoileal	5
IleoColic	77
Ileoiliocolic	12
Colocolic	2
Multiple	1
Retrograde	0.2
Others	2.8

3. Vomiting may be clear initially but becomes bilious in nature as obstruction progresses.
4. The passage of stool may be normal initially, but later blood and mucus are present- ***'red currant' jelly stool.*** *(MANY PGME)*
5. Patient presents with triad of symptom:
   - Abdominal pain
   - Abdominal lump (fig 35.13A)
   - Red current jelly stool

   However it should be noted that *triad of symptoms "abdominal pain, lump in abdomen and* ***red currant jelly stool"*** *(NEET, AIIMS JUNE 2000, MANY PGME)* is present in only 50% of cases.

Red currant = Small edible red berry.

6. If unrelieved even after 24-36 hours; the pain becomes continuous, with abdominal distension and profound vomiting and ultimately death.
7. Rarely; it may cure by itself due to sloughing of the intussusceptum.

Examination of abdomen

- On examination the abdomen is not much distended. *A sausage shaped lump may be palpable in the upper right to mid abdomen, with concavity towards the umbilicus, in about 60% cases.* Please see figure 35.13A. *(MANY PGME)*

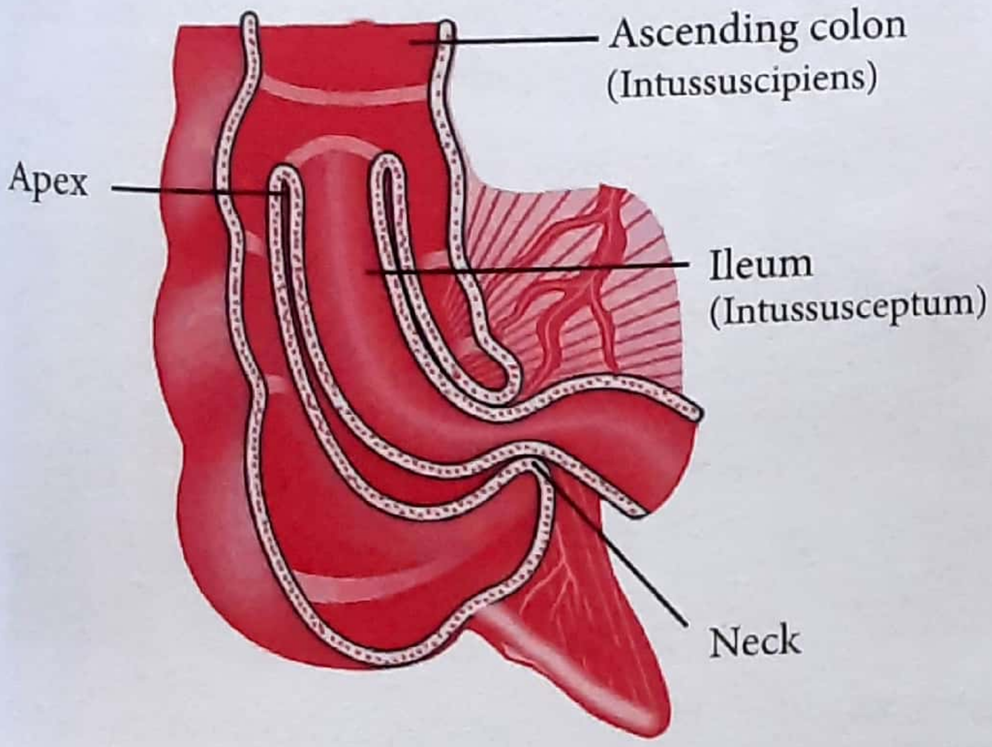

Figure 35.12B: Ileocolic intussusception (note; this is most common type)

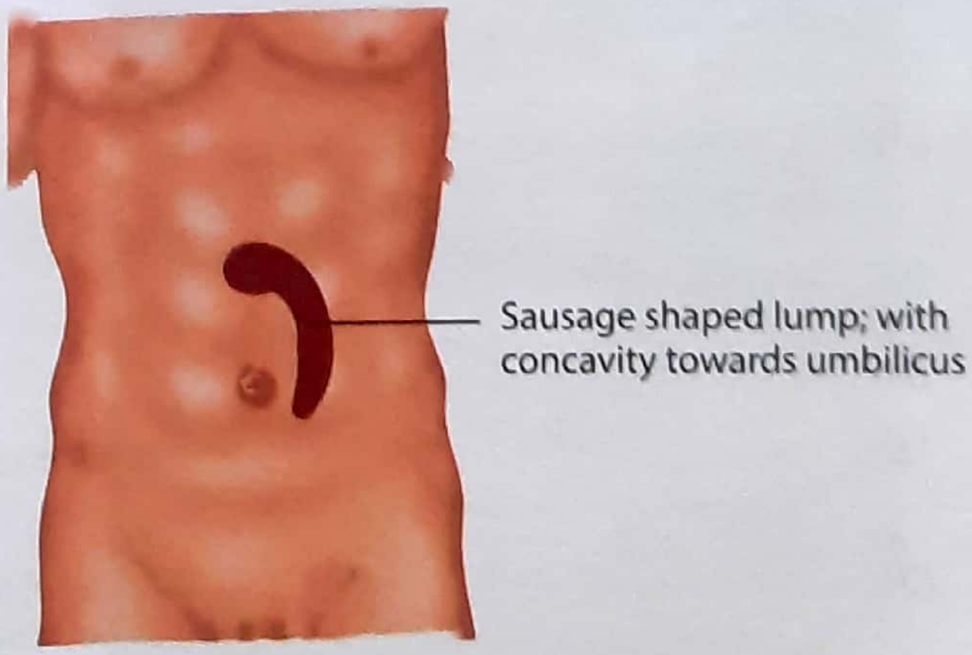

Figure 35.13A: Site of abdominal lump

KEY BOX 35.7

Probable Mechanism of intussusception *(AI 03)*

Change in dietary habit (Secondary to weaning)

↓

Alteration in the intestinal flora

↓

Inflammation of intestinal tract

↓

Inflammatory swelling of peyer's patches in terminal ileum *(AI 02, TN 90)*

↓

Protrusion into lumen

↓

Initiation of intussusception (Fig. 35.11)

- The right iliac fossa may feel empty (sign *of Dance)*. which is due to shifting of contents. *(PGI 01, MAHE 05)*.
- **On rectal examination,** blood-stained mucus may be found on the examining finger. *(IMP. POINT)*
- Occasionally in *extensive ileocolic or colocolic intussusception, the apex may be palpable onPR examination or even protrude out through the anus.* *(PGI DEC 99, UP PG)*

Investigations *(PGI JUNE 01)*

1. **Plain X-ray abdomen reveals:**
   (a) Dilated loops of small intestine.
   (b) Air-fluid levels.
   (c) Absent cecal gas shadow.
   (d) A soft tissue mass effect in the right upper quadrant.
   (e) **Gasless abdomen** *(NEET)*
2. **Barium enema:**
   (a) Especially useful to diagnose the presence of ileocolic or colocolic form.
   (b) Shows '***coiled spring***' **sign** *(NEET)* or '*claw sign*' at the point of bowel invagination. *(PGME, APPG 08)* (Fig. 35.13B)

Figure 35.13B : Intussusception : Barium enema showing claw sign. *(PGME)*

3. Ultrasound examination of abdomen may be helpful in making the diagnosis.
4. Equivocal cases of ileo-ileal intussusception may be further evaluated by CT scan. It shows Target sign (Fig. 35.13D)

Management

The key point for successful management are:

1. Early diagnosis (discussed earlier)
2. Adequate resuscitation
3. Effective reduction.
4. Operative treatment

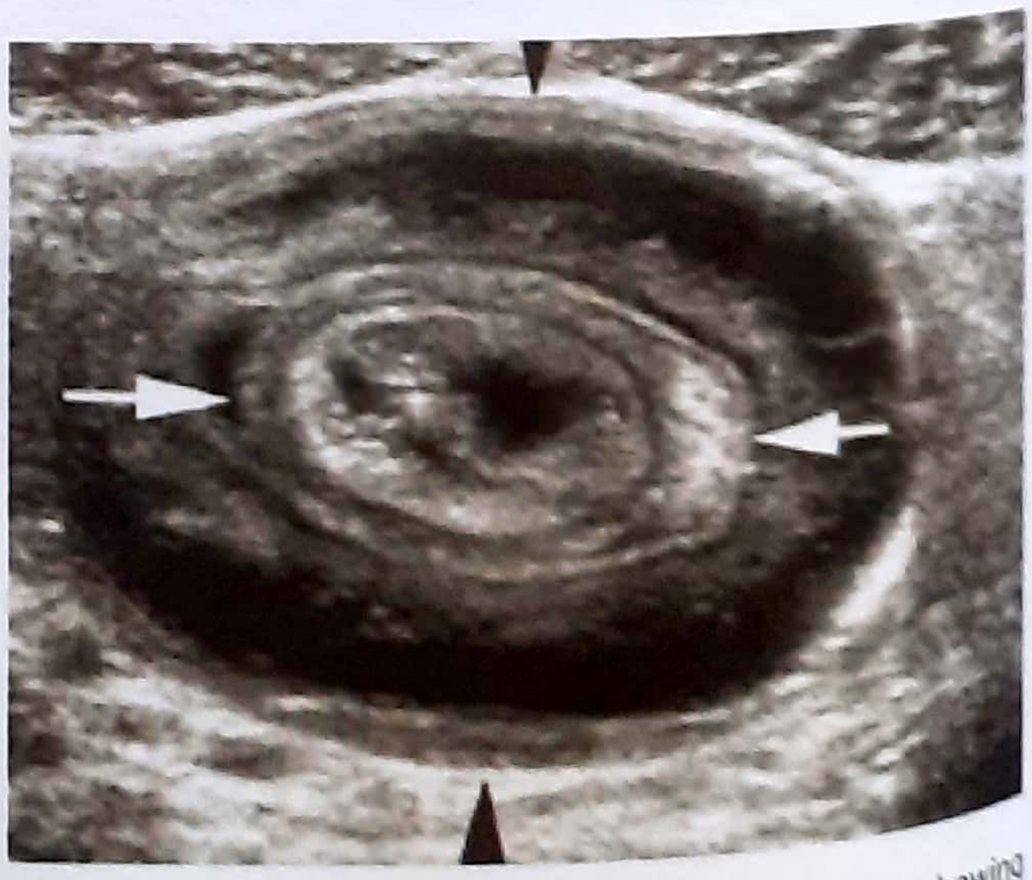

Figure 35.13C : Intussusception : Ultrasound showing **target sign or dougnut sign**; hypoechoic edematous outer bowel wall (black arrows) and compressed layer of bowel wall with associated fat telescoping within (white arrows)

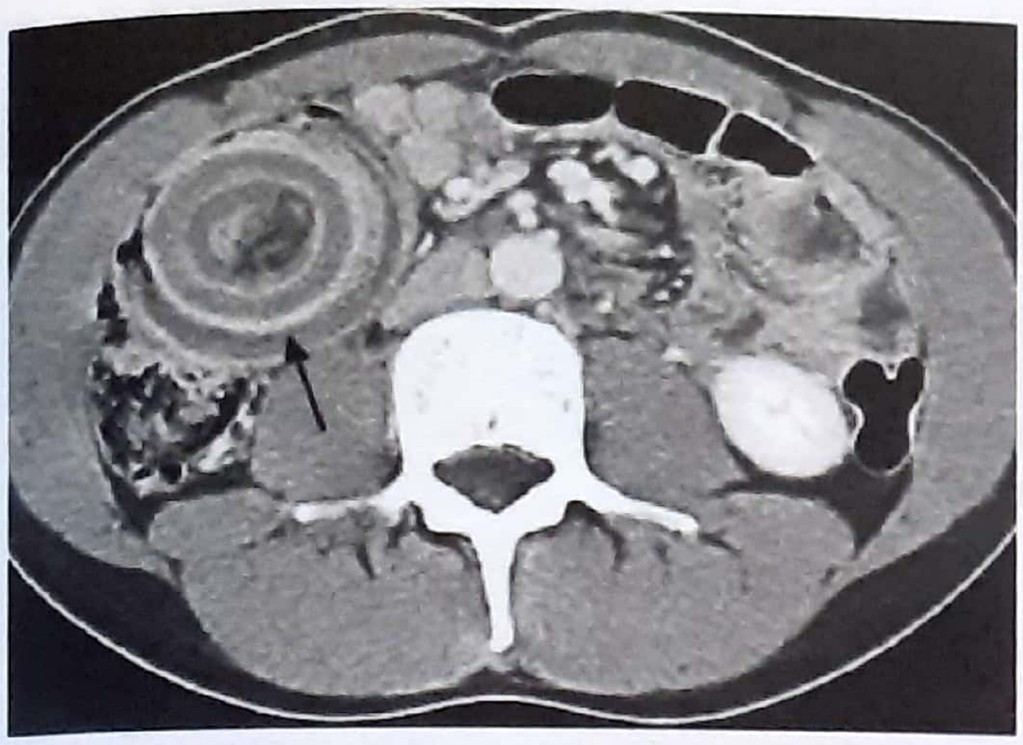

Figure 35.13D : Intussusception : CT scan showing layers of the bowel forming concentric rings (Target sign) *(MAY BE PGME QUESTIONS)*

1. **Early diagnosis:** Discussed above.

2. **Adequate resuscitation**

Begins with intravenous fluid therapy, administration of intravenous antibiotics and nasogastric aspiration (by Ryle's tube).

3. **Reduction* of intussusception**

This may be non-operative or operative depending on the clinical condition. In the absence of peritonitis, perforation and strangulation, the non-operative reduction should generally be attempted.

- The **contraindication** for nonoperative reduction are:
  - (i) Perforation,
  - (ii) Strangulation
  - (iii) Profound shock and
  - (iv) History of illness for more than 48 hours.

KEY BOX 35.8
Intestinal obstruction with abdominal lump
• Intussusception
• Pelvic abscess
• Malignancy of gastro-intestinal tract
• Hyperplastic ileocecal tuberculosis

Nonoperative methods

- Reduction can by done by using either **air (air reduction)** or by **liquid (Barium enema, ie; hydrostatic reduction).**
- The mechanism is similar for both - by pushing air or Barium enema through the anus. The inrussuscipiens (distal bowel) is distended which causes widening of neck and pushes the intussusceptum and thereby reduces the intussusception.

REDUCTION?: *When used in Operative surgery; means a surgical process done for restoration of bowel for normal positioning of bowel. Various reduction procedures are:-*

(a) **Air reduction**

Air reduction technique was first developed in china. During, air reduction the column of insufflated air is monitored, so as not to exceed 80 mm Hg for infants less than 6 months of age, and 120 mm Hg for older infants for a period of less than 3 minutes. A satisfactory reduction is noted when the abdominal mass disappears and the small bowel (ileum) becomes distended by air. (Figure 35.13E)

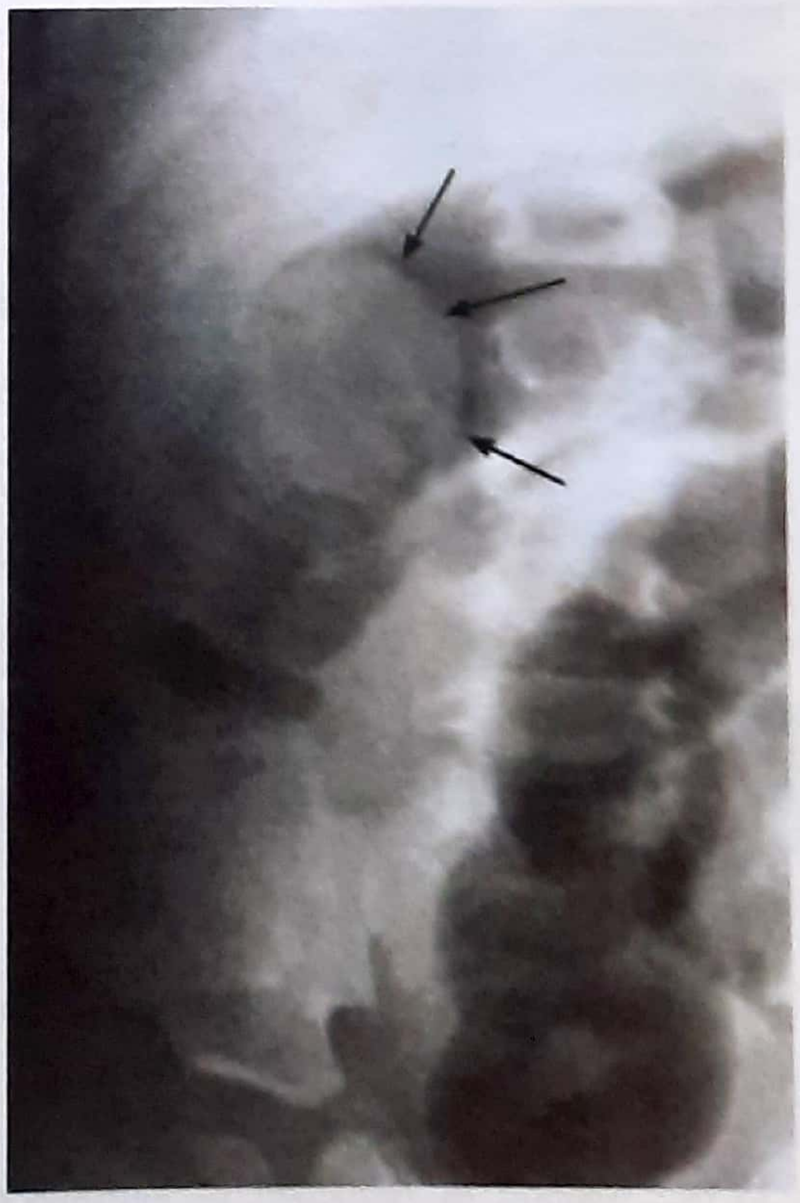

Figure 35.13E : Air enema reduction of an intussusception

(b) Hydrostatic (pressure) reduction

Traditionally hydrostatic reduction is achieved with a Barium enema (AI 91). The Barium is given under X-ray control in an effort to distend the inrussuscipiens and reduce the intussusception. The buttocks are strapped by adhesive tape to prevent the expulsion of Barium.

- Complete reduction is confirmed when the barium is seen to flow freely and reach terminal ileum which can be checked by taking a X-ray film. The abdominal mass; if present should disappear.
- Successful nonoperative reduction is recorded in about 55% to 80% of cases.

4. Operative Reduction

- Surgical intervention is required when hydrostatic or air reduction techniques have failed.
- The abdomen is opened through a transverse right lower quadrant incision. The intussusception is milked back proximally by progressive compression of bowel, just distal to intussusception *and not by pulling proximal bowel.* (Fig. 35.14)

Resection and anastomosis

This is indicated when there is/are following finding at laparotomy:

1. Gangrenous changes in bowel
2. Reduction is impossible
3. Perforation of bowel during reduction

In the usual type (ileocolic) a right hemicolectomy* is done.

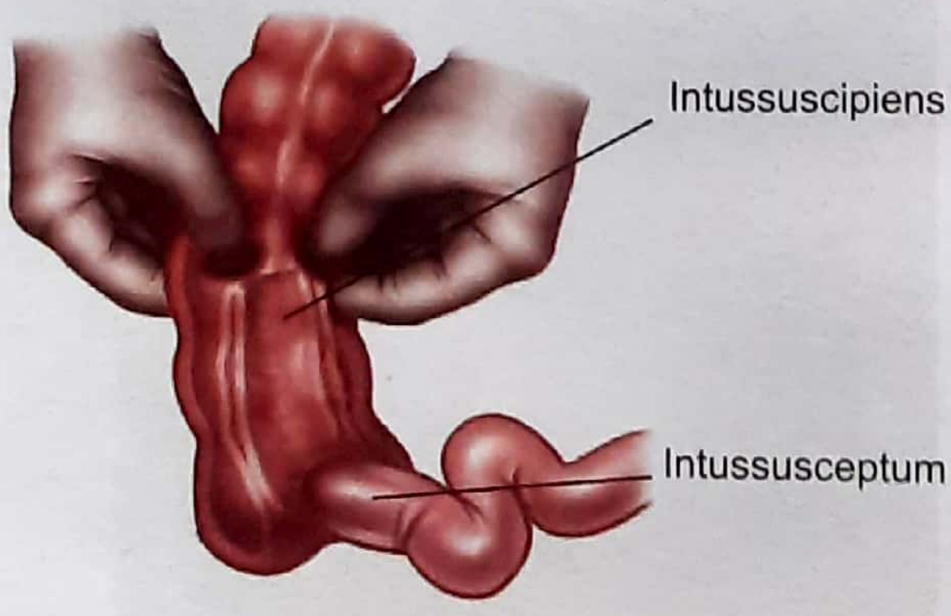

Figure 35.14: Method of reduction of intussusception (note the position of hand)

Right hemicolectomy = *Excision of terminal ileum + cecum + ascending colon + proximal transverse colon,* followed by ileo-transverse anastomosis to maintain continuity of bowel. Please see figure 36.15 on page 676.

The incidence of recurrent intussusception following hydrostatic reduction ranges from 8-10% while following resection and anastomosis; the recurrence rate is very low (0-3%)

*****

OBSTRUCTION BY ADHESIONS (ADHESIVE INTESTINAL OBSTRUCTION)

Intestinal adhesions (between bowel loops) are most common cause of intestinal obstruction (MANY PGME)

Causes

1. They may result from a *previous surgical exploration of abdomen* ie; after previous laparotomy *(Most common cause)* (MANY PGME)
2. Laparotomy done for gynecological procedures, acute appendicitis (with or without perforation), intestinal perforation, intra abdominal abscesses have higher incidence of adhesion formation.
3. Ischemic areas, site of anastomosis, reperitonealization of raw surface.
4. Foreign material eg; - talk use in surgical gloves, gauge, starch.
5. Infection : Tuberculosis and crohn's disease.
6. Radiation enteritis.

KEY BOX 35.8E

The common causes of intra-abdominal adhesions	
Acute inflammation	Sites of anastomoses, reperitonealisation of raw areas, trauma, ischaemia
Foreign material	Talc, starch, gauze, silk
Infection	Peritonitis, tuberculosis
Chronic inflammatory conditions	Crohn's disease
Radiaiton enteritis	

KEY BOX 35.9

Pathogenesis of Adhesion Formation

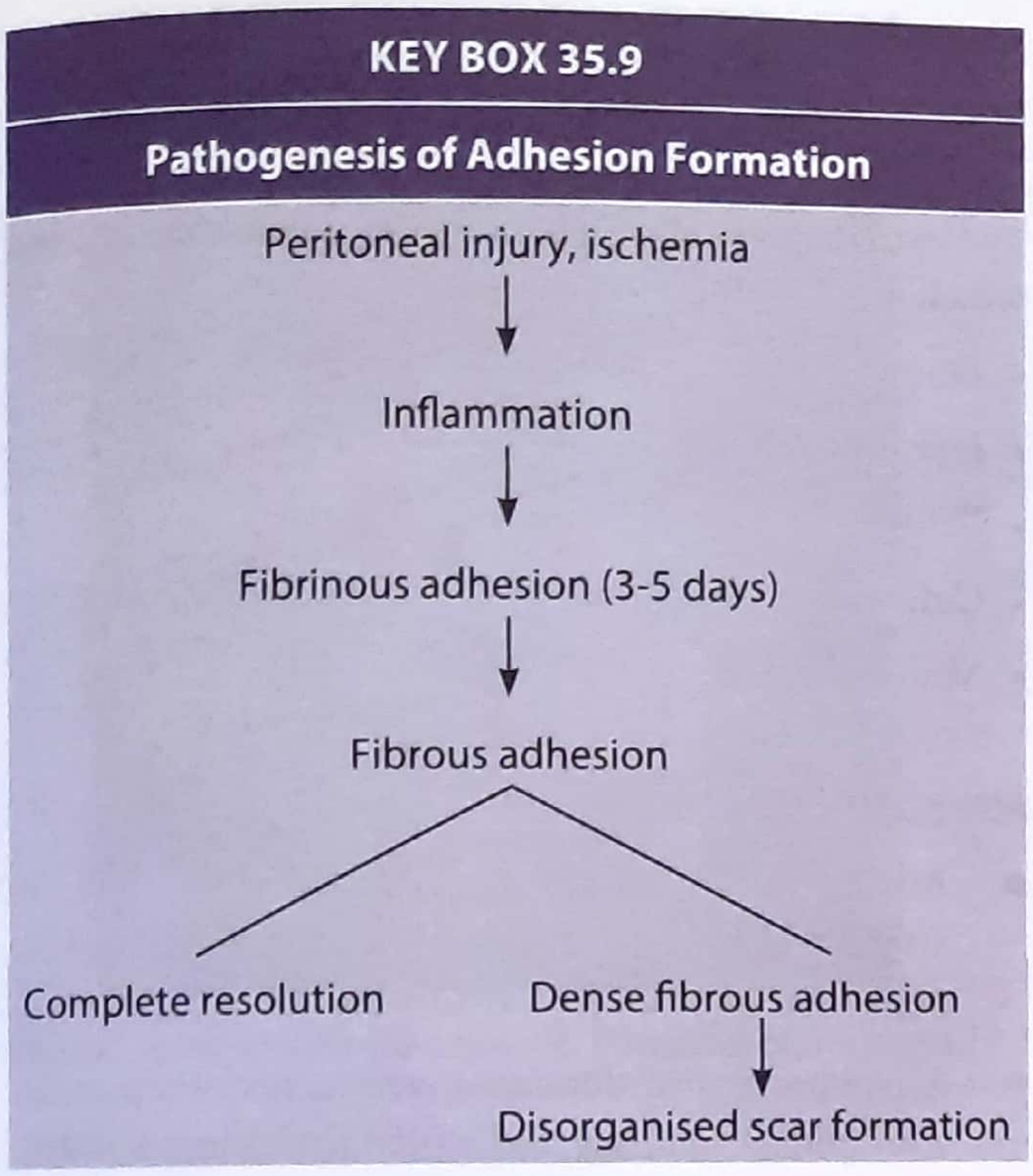

Pathogenesis

Ischemia and irritation of the intestine are chief factor responsible for adhesions. Please see key box 35.9 to understand pathogenesis.

Types of Adhesion

1. **Fibrinous adhesion** - They are also known as *bread and butter* adhesions. These adhesions are produced by fibrin, inflammatory cells and plasma proteins. They are the cause of early post operative adhesive obstruction; which usually settles down within 3-5 days. Majority of them disappear in due course of time.
2. **Fibrous adhesion** - If the infection persist or a foreign body is present, the fibrinous material is converted in fibrous band. This is responsible for late intestinal obstruction. Please read box 35.9 once again.
3. **Disorganized scar formation** - With passage of time, disorganized scar formation takes place.

TUBERCULOUS ADHESION: These are dense adhesion developing due to chronic inflammation. Separation of these adhesion may be very difficult at laparotomy.

Investigation

- *Plain X-ray abdomen* shows dilated bowel loop.
- *Contrast enhanced CT scan* - CT has sensitivity of 100% and specificity of 90%.

Management

The best management for an adhesive intestinal obstruction is it's prevention. This can be done by:

I. Prevention of post operative adhesion formation

- Good surgical technique
- Less use of sponges, mops and gauges.
- Keeping intestine intra-abdominal, rather than on anterior abdominal wall during surgery.
- Covering the intestine by hot saline soaked sponges during surgical procedure.
- Installation of colloid into peritoneal cavity before closure of abdomen.
- Instillation of steroid or heparin, before abdominal closure. Covering anastomosis and raw peritoneal surface by omentum before abdominal closure.

II. Conservative treatment

- In the form of Ryle's tube aspiration and IV fluid.
- Patient is kept nil orally.
- Most patients are benefitted in 48-72 **hours.** If this is not successful; a reoperation may be required.

III. Surgical methods

Procedures

- Adhesionolysis (breaking adhesion) at laparotomy.
- Noble's plication operation
- Charles phillips trans mesenteric plication operation
- Intestinal intubation.
- Laparoscopic adhesionolysis is more often being used.
- More recently absorbable and nonabsorbable membrane barriers such as PTFE (polytetra fluoro ethylene) and membrane composed of carboxymethyl cellulose with hyaluronic acid is being used.

*****

BAND CAUSING INTESTINAL OBSTRUCTION

The most common cause of bands are previous peritonitis and a congenital bands.

Causes of bands

- **Congenital**
  - Band of ladd (Trans-duodenal band)
  - Band associated with vitello-intestinal duct
- **Acquired**
  - Post peritonitis
  - Associated with diverticulitis
  - A portion of greater omentum acts like a band when becomes adherent to parities.

Treatment: At laparotomy bands are divided.

*****

ACUTE INTESTINAL OBSTRUCTION OF NEWBORN

- Neonatal intestinal obstruction has an approximate incidence of 1:2000 live birth.
- History of *maternal polyhydramnios, abdominal distension or failure to pass meconium within first 24 hours of life, could be strongly indicative of intestinal obstruction,* (MANY PGME)
- Congenital atresia and stenosis are the *commonest cause* (MANY PGME). Please read box 35.10.
- Volvulus neonatorum, meconium ileus. Hirschsprung's disease may also be responsible.

KEY BOX 35.10

Causes of Neonatal intestinal obstruction

- Congenital atresia and stenosis (M/C cause)
- Volvulus aeonatonim
- Meconium ileus
- Hirschprungs disease
- Arrested rotation and congenital bands.

Important Causes

1. Congenital atresia

The incidence of atresia varies with the anatomical site, which are:-

- Duodenum - 35% (M/C) (AIIMS 95, MANY PG)
- Jejunum - 15%
- Ileum - 25%
- Colon - 10%
- Multiple sites - 15%

Duodenal atresia / stenosis

- Atresia of the duodenum occurs at the level of ampulla of vater (2nd part of duodenum). 30% of the newborns have Down's syndrome.
- A newborn with duodenal atresia/stenosis presents with *bilious vomiting and minimal abdominal distension, due to proximal bowel obstruction.* (AI 03)
- Radiography reveals a classical *"Double-bubble" sign.* (due to air filled, stomach and duodenal bulb appears as two bubble) (MANY PGME)
- ***Treatment:*** Surgical treatment is *duodenoduodenostomy or duodenojejunostomy.* (MANY PGME, AI, UP, AIIMS)

2. Jejuno-Ileal Obstruction

- The cause could be either atresia or stenosis or as a result of intrauterine vascular accident occurring late in pregnancy.
- *In jejunal atresia early distension is lacking but vomiting occurs early.*
- *In ileal atresia the child is born with abdominal distension or presents with in 24 hours of birth. However, in both the condition vomitus contains bile.* (AI 03, MP POINT)
- Plain X-ray shows dilated loop of small bowel.

3. Arrested Rotation with Band

- This is a congenital anomaly, where in the cecum remains in the left hypochondium and ascending colon is found on the left side.
- A peritoneal band is found running from the cecum to the right side the abdomen, crossing over the

Figure 35.15-1: Air-fluid level in intestinal obstruction

Figure 35.15-2 : Barium study of Meconium ileus

duodenum:- The *transduodenal band of ladd.* This band compresses the second part of duodenum and causes duodenal obstruction.

- Treatment is by dividing the band and fixation of cecum in the right iliac fossa at laparotomy.

4. Meconium Ileus *(IMP PGME TOPIC)*

Before discussing tneconium ileus, I would like to discribe meconium first.

Meconium?

Meconium is Greek word; which means poppy (opium) juice. It is first feces of a new born infant; made up of salts, liquor amnii, mucus, bile and epithelial cells. This substance is greenish black, almost odourless and tarry (tar like). *First meconium stool should pass during the first 24 hours.*

The meconium is kept in fluid (ie; in liquid form) by the action of pancreatic enzymes. In *cystic fibrosis,* where pancreatic enzyme secretion is reduced/absent, meconium could not be kept in fluid *(AI 2000, 96, 98)*

In this situation the meconium becomes inspissated and fills the terminal ileum. Because it is very dry and relatively hard and hence, could not be passed out and results in progressive neonatal obstruction.

The condition is due to an *autosomal recessive* genetic defect. A family history may be present.

Clinical feature

- Abdominal distension is usually absent at birth, it develops rapidly with failure of passage of meconium.
- Vomiting soon follows and it is usually bilious.

Any small bowel obstruction distal to 2nd part of duodenum, where in CBD opens, results in bilious (bile) vomiting. *(AL 94)*

For example

In pyloric stenosis where the obstruction is above (proximal) 2nd part of duodenum (ie; at pylorus) the vomitus does not contain bile, where as ileal obstruction, jejunal obstruction, duodenal atresia result in bilious vomiting.

Investigation

Straight abdominal x-ray *(ALIMS 07)*

- Will show enormously distended small bowel *without air-fluid level;* because meconium is viscid. *(PGI98)*
- Small bubbles of gas are trapped in the inspissated meconium and thus *produces* "***ground glass appearance***". *(PGME)*

- Air mixed with meconium produces a typical *"soap bubble"* sign. (PGME)
- A gastrograffin enema will show a micro colon and terminal ileum filled with pellets of meconium.

Treatment

Conservative

Gastrograffin contrast enema is the first line of treatment of meconium ileus (IMP POINT). Dilute gastrograffin is introduced into colon as enema. It fills the ileum. Gastrograffin absorbs fluid from the interstitial space into lumen of the ileum, as gastrograffin is hyper-osmolar, (which absorbs water) and make meconium soft. Now the soft meconium is passed naturally. Large volumes of intravenous fluid are needed to correct fluid losses from intestinal tract, resulting from absorption of water by Gastrograffin.

Surgical treatment

If the conservative treatment fail *Bishop-koop operation* is done. [I am not discussing Bishop - koop operation, because it will be boring and "too much for a UG"]

5. Meconium-plug syndrome (AIIMS 07)

Occasionally a meconium plug in the rectum may cause intraluminal intestinal obstruction. This readily resolves after enema. A rectal wash will stimulate the newborn to pass tenacious meconium and the obstruction is immediately relieved.

Other causes of intestinal obstruction are:

- Volvulus neonatorum (discussed on page no 945)
- Hirschsprung's disease (discussed on page no 593)

*****

RECAP: Friends till now we were discussing mechanical, ie; obstructing causes of intestinal obstruction, now we will discuss, paralytic ileus ie; feature of obstruction due to loss of peristaltic activity of bowel.

ADYNAMIC OBSTRUCTION (PARALYTIC ILEUS)

- Paralytic ileus is a disorder in which there is neurogenic failure* of peristalsis to propel intestinal content.

Neurogenic control of intestine lies in the myenteric plexus ofAuerbach and the submucous plexus of meissner.

- This results in collection of fluid and gas in the intestine resulting in distension, vomiting, absent bowel sound and failure to pass flatus and feces.
- **There is no mechanical obstruction.**

Clinical types (PGI JUNE 99)

(based on etiology)

1. Traumatic

(a) *Postoperative* - A degree of ileus occurs usually after any abdominal operation and is self limiting with a variable duration of 24-72 hours. *It may be prolonged in the presence of hypoproteinemia, renal failure,* ***hypokalemia***. (NEET, PGME)

(b) *Spinal anaesthesia*

(c) *Accidental* - Fracture spine/ribs, spinal cast appliance, retroperitoneal hematoma and head injury.

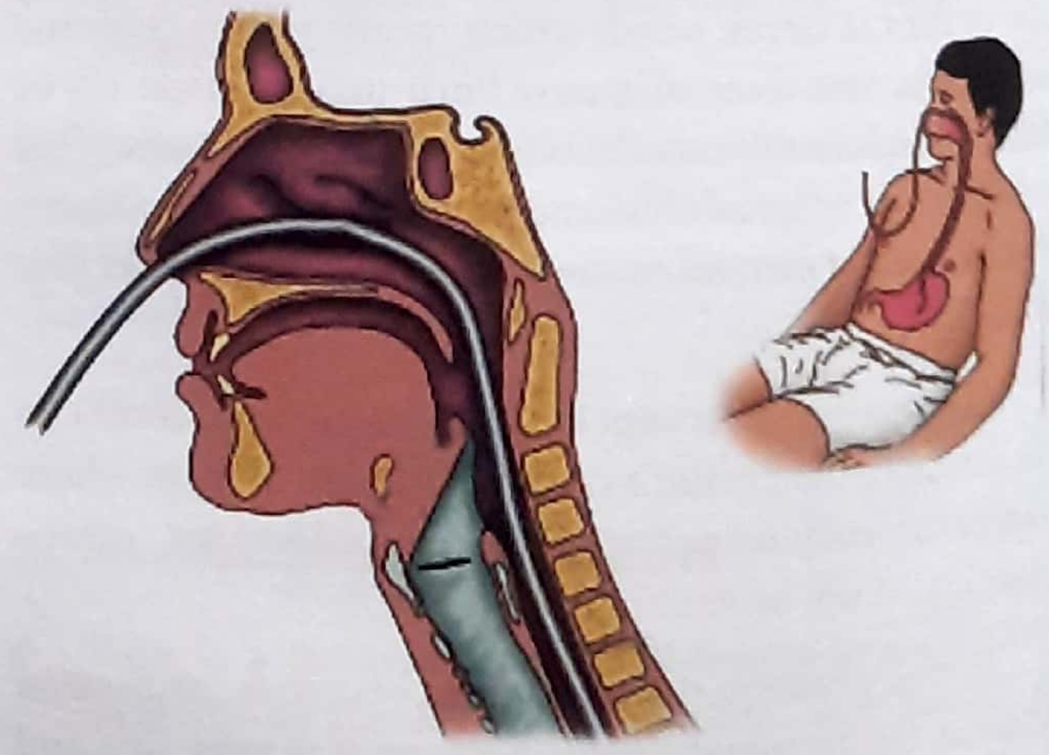

Figure 35.16: Passing Ryle's tube (Nasogastric tube) in stomach

2. **Inflammatory**
   (a) Local : Intra abdominal sepsis, appendicitis, pancreatitis, ulcerative colitis, regional ileitis, typhoid.
   (b) Systemic : Septicemia, pneumonia, meningitis.
3. **Metabolic**
   (a) Diabetic ketoacidosis
   (b) Uremia & Hypokalemia
4. **Vascular:** Mesenteric thrombosis
5. **Miscellaneous**
   (a) Torsion testis
   (b) Post-gastroenteritis
   (c) Porphyria
   (d) Ureteric colic

NOTE: Type 1 and 2 are most common cause of paralytic ileus.

Clinical features

1. Paralytic ileus is significant, if 72 hours after laparotomy, there is no return of bowel sounds on auscultation and there is no passage of flatus.
2. No colicky pain but only abdominal discomfort.
3. Effortless vomiting, if gastric aspiration is not done post operatively by Ryle's tube, (figure 35.16)
4. Gradual distension due to collection of gas and flatus in the intestine; later the distension becomes enormous.
5. No passage of flatus or visible peristalsis
6. Absent bowel sounds: Silent abdomen
7. No local tenderness and rigidity
8. Abundant gastric aspiration by Ryle's tube
9. Tympanitic note on percussion.

Investigations

Plain X-ray of the abdomen shows gas filled loops of intestine with multiple fluid levels and elevated diaphragm.

Management

(a) Preventive measures

- Use of nasogastric aspiration by Ryle's tube in post-operative period.
- Restriction of oral intake, until bowel sounds returns and the passage of flatus.
- Maintenance of electrolyte balance, (especially K^+).

NOTE: Hypokalemia leads to ileus.

(b) Specific treatment

- Removal of the primary cause.
- Adequate gastrointestinal decompression by Ryle's tube.
- Close watch on fluid and electrolyte balance.
- Medical therapy with adrenergic blocking agent in association with cholinergic stimulation (neostigmine) may be used in resistant cases.
- If paralytic ileus is prolonged and threatens life, laparotomy is considered to exclude any hidden cause and facilitate bowel decompression. *(PGI JUNE 98)*
- There is no place for enema, purgatives and GI. stimulants. *(PGI JUNE 99)*
- First recovers - Small intestine
- Last recovers - Large intestine

*****

PSEUDO-OBSTRUCTION

- Colonic pseudo-obstruction is a clinical condition with symptoms; signs and radiological appearance of acute obstruction but without any identifiable cause.
- The symptoms may be acute or chronic. The acute pseudo-obstruction is also called **as Ogilvie's syndrome.** *(NEET, AIIMS 07, UP 07)*
- Pseudo-obstruction often occurs in elderly medically ill patients.
- Impairment of the intestinal motility is the primary defect and this can be due to derangement in the intestinal musculature or neural control.

KEY BOX 35.10E

Factors associated with pseudo-obstruction

- Metabolic
  - Diabetes
  - Hypokalaemia
  - Uraemia
  - Myxedema
  - Intermittent porphyria
- Severe trauma (especially to the lumbar spine and pelvis)
- Shock
  - Burns
  - Myocardial infarction
  - Stroke
- Idiopathic
- Septicaemia
- Postoperative (for example fractured neck of femur)
- Retroperitoneal Irritation
  - Blood
  - Urine
  - Enzymes (pancreatltis)
  - Tumour
- Drugs
  - Tricyclic antidepressants
  - Phenothiazines
  - Laxatives
- Secondary gastrointestinal Involvement
  - Scleroderma
  - Chagas' disease

- The term primary colonic pseudo obstruction may be used, when no definite causative factor leading to obstruction is found. The diagnosis is often made at laparotomy.
- Critical diameter of caecum when perforation is considered eminent in pseudo-obstruction is **>12 cm.** *(NEET)*

Diagnosis

- Straight X-ray abdomen shows colonic obstruction with marked cecal gas shadow.
- A contrast enema (Ba enema) will accurately differentiate a pseudo-obstruction from a mechanical obstruction.
- Air-fluid levels are *unusual* in pseudo-obstruction.

Treatment

Once confirmed, pseudoobstruction can be treated by colonoscopic decompression. If colonoscopy fails; a tube cecostomy may be required.

The chronic form may respond to cisapride or Itopride (prokinetic drugs) which increases intestinal motility.

In resistant cases subtotal colectomy and ileorectal anastomosis may be required.

*****

MESENTERIC VASCULAR DISEASE

1. Acute Mesenteric ischemia

Acute mesenteric ischemia results from mesenteric arterial occlusion.

Etiology

1. Embolization of superior mesenteric artery secondary to atrial arrhythmia, mural thrombi account for about 50% cases. This is most common cause.
2. Thrombosis of superior mesenteric artery- secondary to atherosclerosis account for about 30% cases.
3. Non-occlusive mesenteric ischemia accounts for about 20% of all episodes of intestinal ischemia.

Clinical features

Acute mesenteric ischemia is a surgical emergency. It presents as :

1. *Severe acute mid-abdominal pain out of proportion to physical findings in patient with atrial fibrillation or atherosclerosis* *(INICET NOV 20, AIIMS NOV 2000, NOV 97).*
2. Early symptoms are nausea, vomiting, diarrhea, diffuse abdominal tenderness **without** peritoneal signs, (ie; guarding and rigidity)
3. Fever, bloody diarrhea and peritonitis occur late and are ominous findings. *(AI 01)*

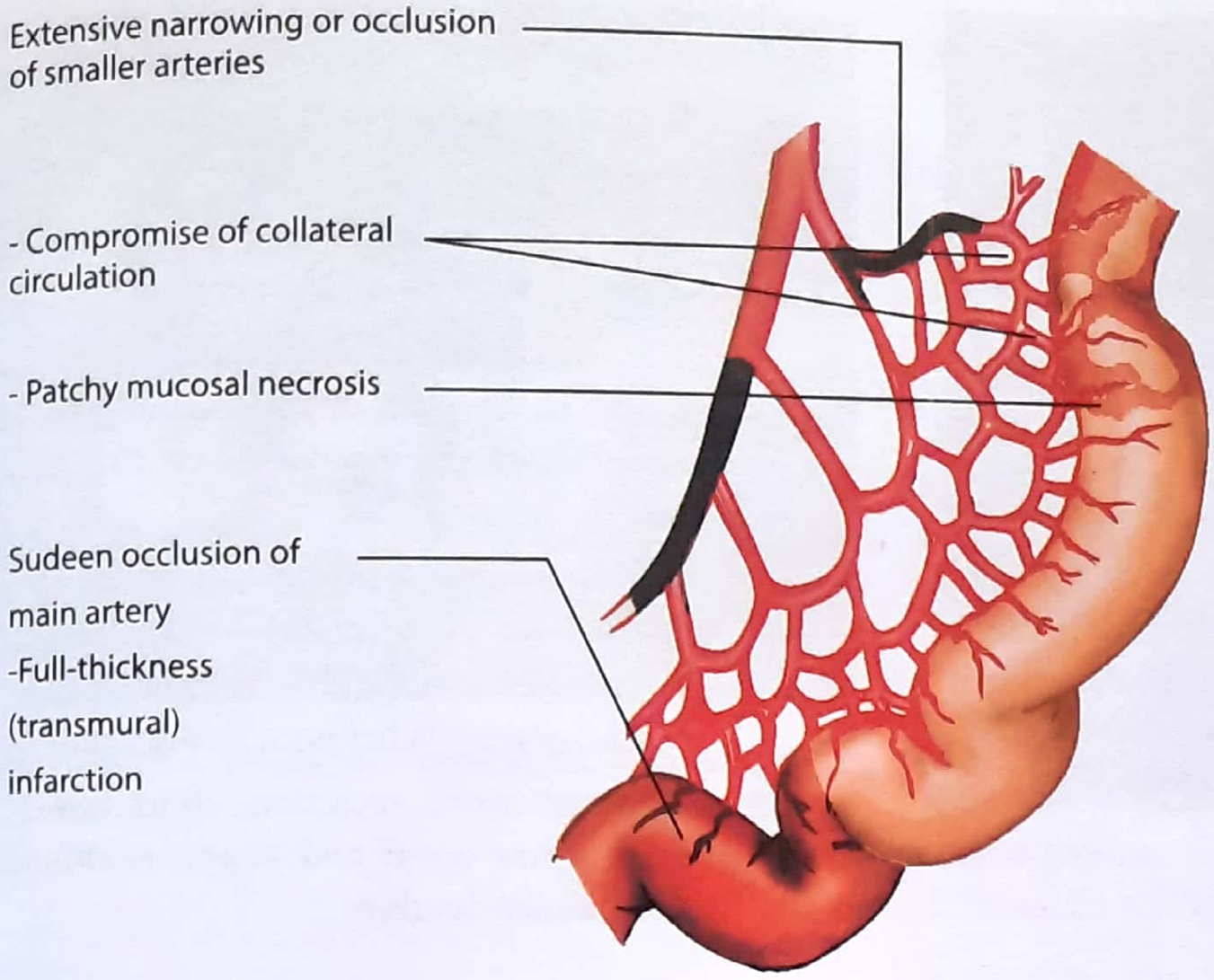

Figure 35.16E: Pathogenesis and clinical feature of intestinal ischemia

4. Hypovolemic shock rapidly ensues.
5. Lately; patient presents with intestinal obstruction.

Figure 35.16E; 35.17 a & b.

Investigation

- Laboratory finding will reveal profound neutrophil leucocytosis.
- Absence of gas in small intestine on plain X-ray abdomen. The *presence of gas bubbles in the mesenteric vein is rare, but pathognomonic.*

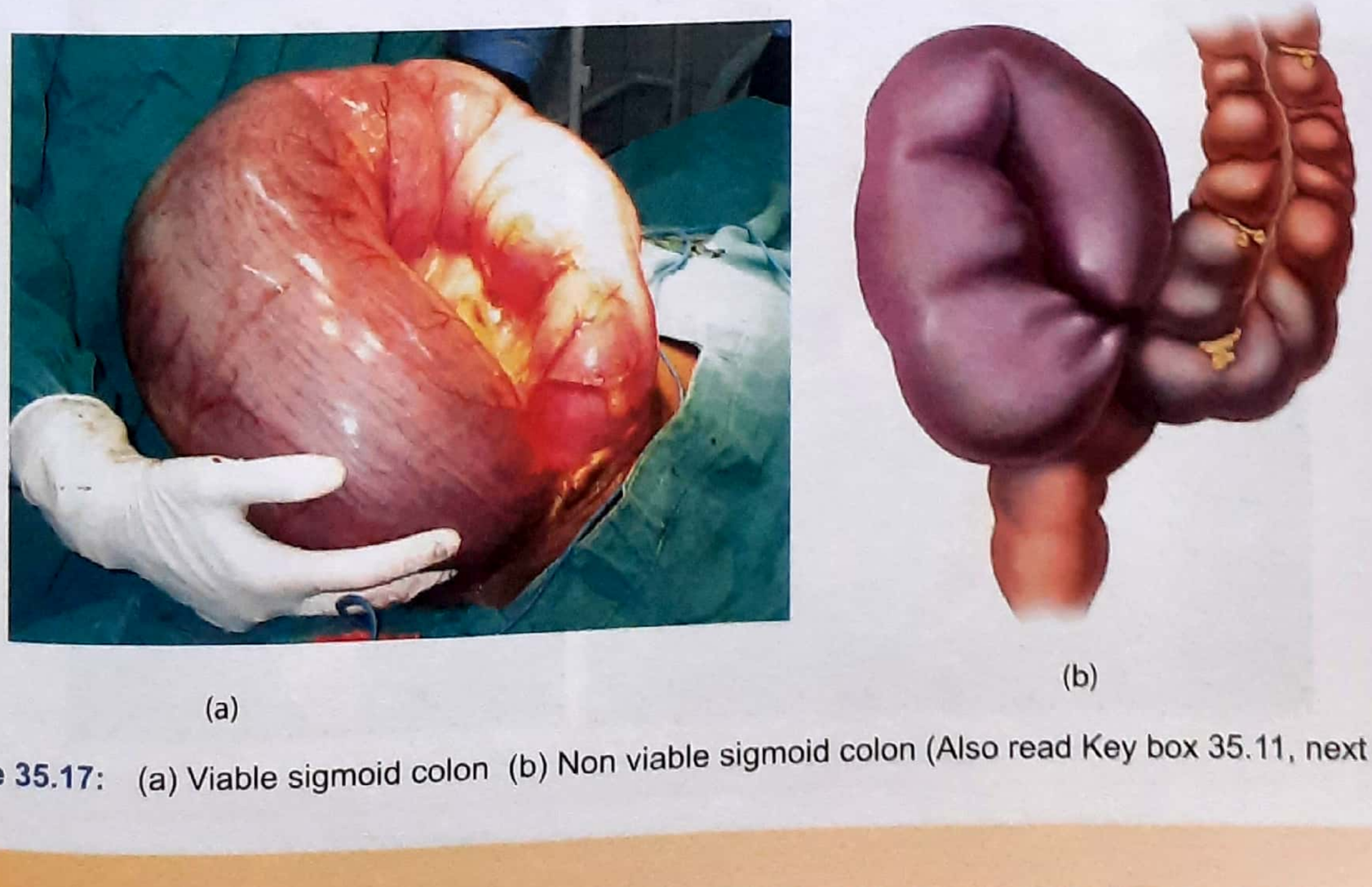

(a) (b)

Figure 35.17: (a) Viable sigmoid colon (b) Non viable sigmoid colon (Also read Key box 35.11, next page)

KEY BOX 35.11		
Differentiation of healthy (viable) and Strangulated (non-viable) bowel at laparotomy		
Intestine	**Viable**	**Non-viable**
• Appearance of bowel at laparotomy	Colour is lighter and pinkish	Dark brown in colour
• Mesentery	Bleeds if pricked	Does not bleed if pricked
• Peritoneum	shiny	Dull or lusterless
• Intestinal musculature	Firm, peristaltic may be observed	Flabby thin and friable, no peristalsis

- Mesenteric angiography is the definitive diagnostic test.

Management

- Fluid and electrolyte resuscitation.
- Subsequent treatment depends upon the arteriographic finding:-

1. If embolus is found, involving superior mesenteric artery (SMA); surgical embolectomy is performed, and subsequent anticoagulant (heparin) is given.
2. If thrombosis is found, urgent aortomesenteric bypass is performed.
3. The treatment of nonocclusive mesenteric ischemia involves direct arterial infusion of vasodilators (ie; papaverine or nitroglycerine into SMA).
4. Following embolectomy or bypass; the bowel is assessed for viability. See key box 35.11. Nonviable (necrotic) bowel should be resected and anastomosis between healthy ends done.
5. After extensive resection, short bowel syndrome may occur and severe nutritional abnormalities develop.

2. Chronic mesenteric ischemia

This results from slowly progressive stenosis or occlusion of the visceral vessels (that is, celiac, superior mesenteric and inferior mesenteric arteries). This is owing to the atherosclerotic involvement of two or three main visceral arteries. Angiography confirms the diagnosis.

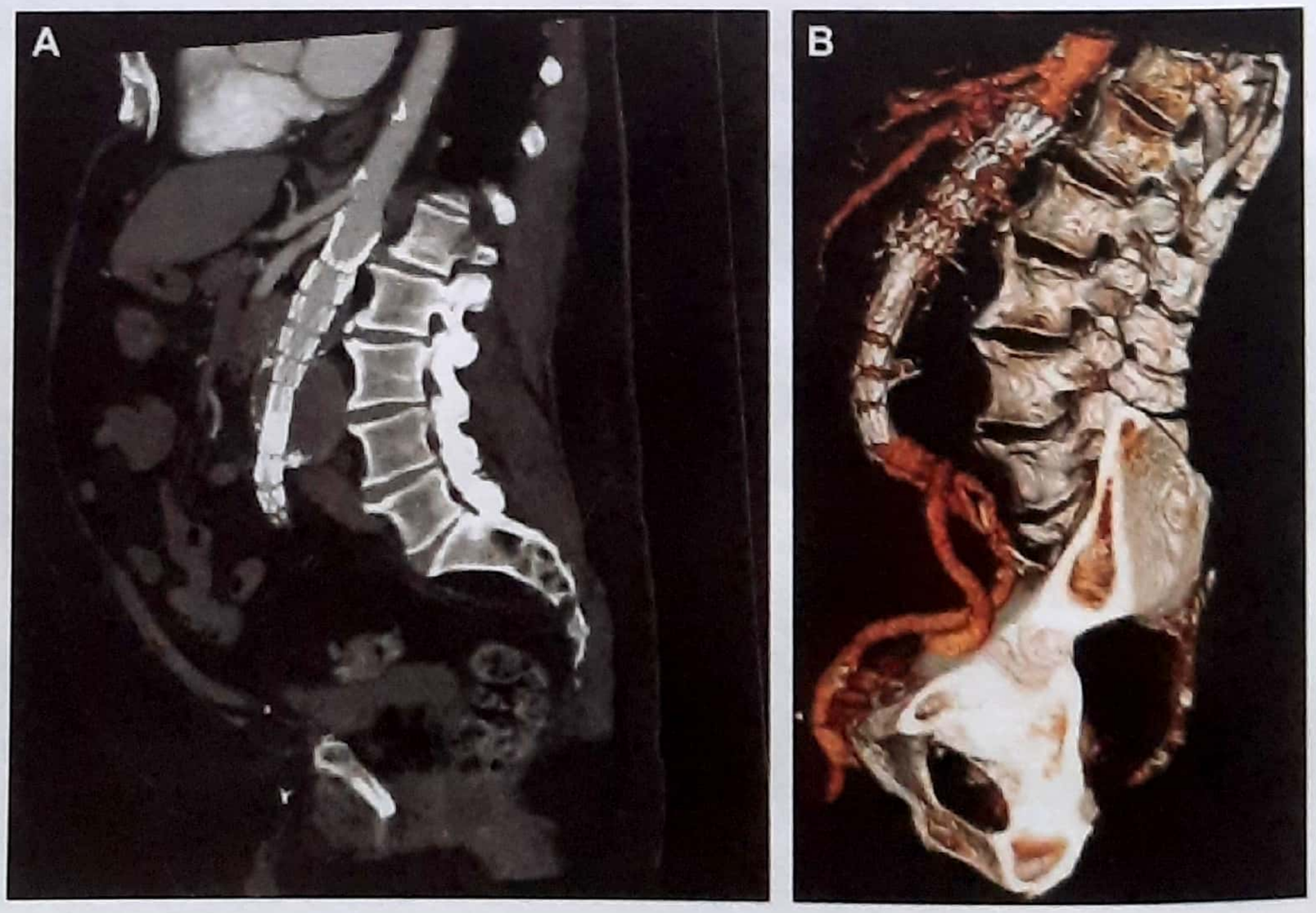

Figure 35.18 : Acute chronic mesenteric ischemia

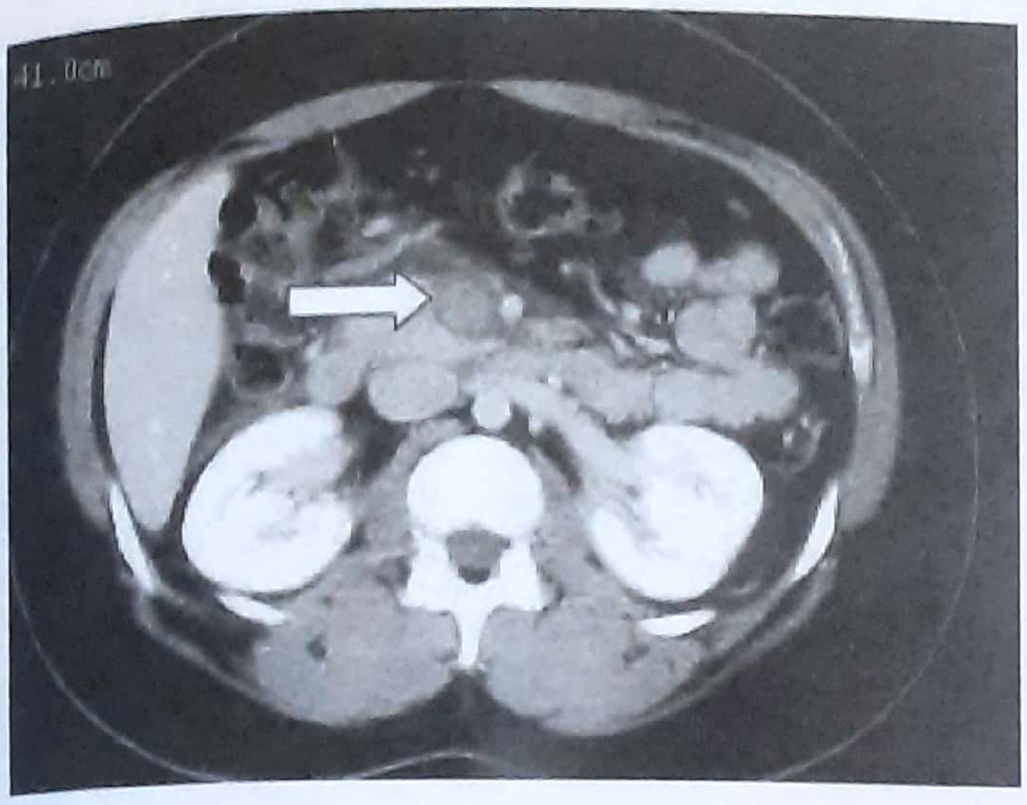

Figure 35.19 : Mesenteric venous thrombosis colon

3. Mesenteric venous thrombosis

This may present more insidiously (slowly) than acute mesenteric ischemia. Typically patient complains of progressive abdominal pain and distension and many times may be confused with intestinal obstruction *(PGI JUNE 03)*.

Etiology

It is frequently associated with hypercoagulable states, including patients with a neoplasm or hematologic abnormality.

Diagnosis

Diagnosis is suggested by CT scan that reveals concentration of contrast in the wall of the mesenteric vein without luminal flow. (Figure 34.19)

Treatment

(a) Nonoperative treatment is anticoagulants (intravenous heparin) with treatment of the underlying disorder.

(b) Laparotomy may become necessary if peritonitis develops. However 75% of patients can be treated nonoperatively; if the diagnosis is made promptly and appropriate treatment is given.

*****

Clinical features

1. Chronic epigastric abdominal pain, occurring after meals (food fear), which may be relieved by defecation.
2. Weight loss.
3. Post prandial abdominal pain.

Treatment

It consist of nutritional correction and surgical revascularization by bypass procedure or endarterectomy.

Sample Questions for Prof Examination

1. Describe the etiology, pathology, clinical features and management of acute small intestinal obstruction intussusception in an one year old child.
2. Define intussusception describe the clinical features, differential diagnosis and management of acute intussusception in an one year old child.
3. What are the cause of intestinal obstruction? Describe the diagnosis and management of a case of volvulus of sigmoid colon.
4. Describe acute intestinal obstruction in a neonate?
5. Write short notes on:

   Paralytic ileus

   Adhesive intestinal obstruction

   Meconium ileus

36 The Vermiform Appendix

Contents

- Surgical anatomy
- Acute appendicitis
- Appendicular lump
- Recurrent appendicitis
- Tumour of appendix

SURGICAL ANATOMY

- The normal adult appendix is on an average 7.5-10 cm long. It is narrow blind tube and it's open end communicates with the cecum. (Fig. 36.0 and 36.1)
- In infancy; the lumen of the appendix is relatively wide; and as age advances it gradually undergoes narrowing. This is one of the reason why appendicitis is rather uncommon in infancy; but common after first few years of life (in adolescents and young adult).

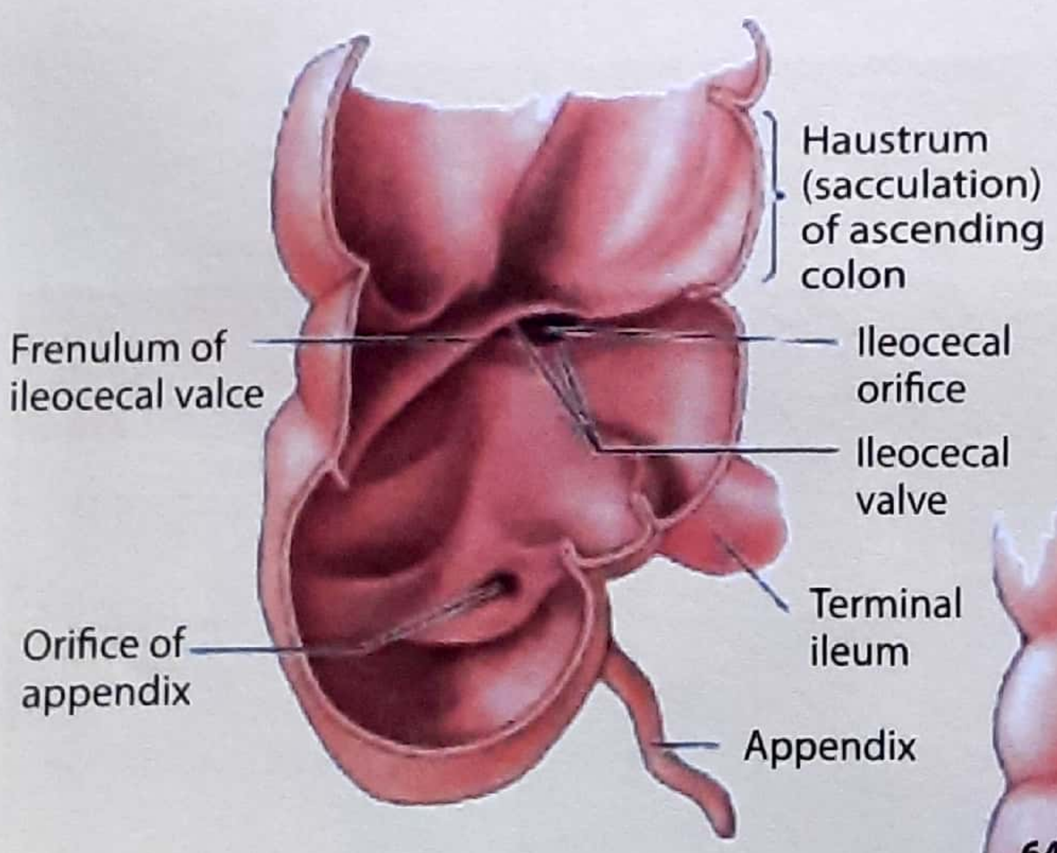

(A) Anterior view

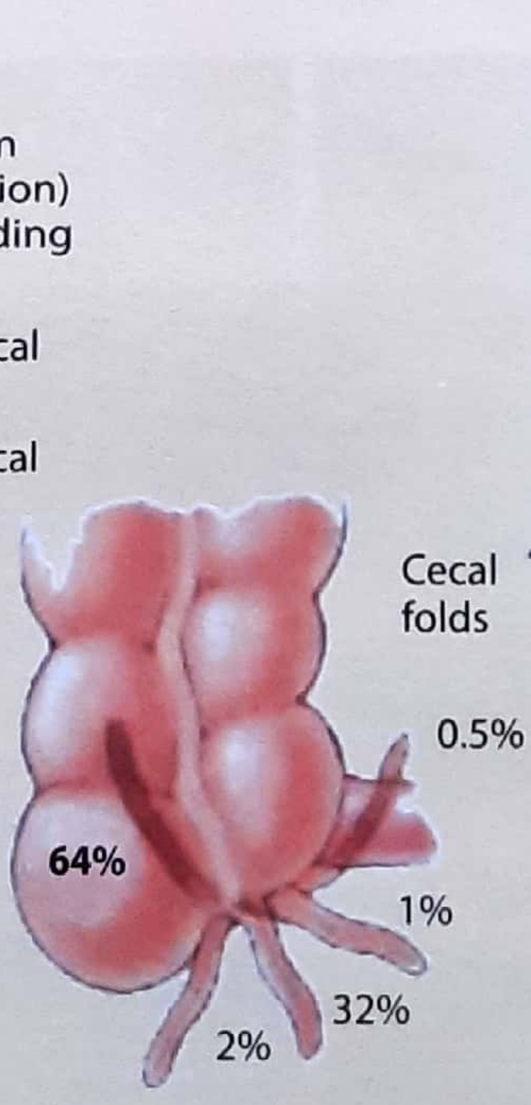

(C) Anterior view

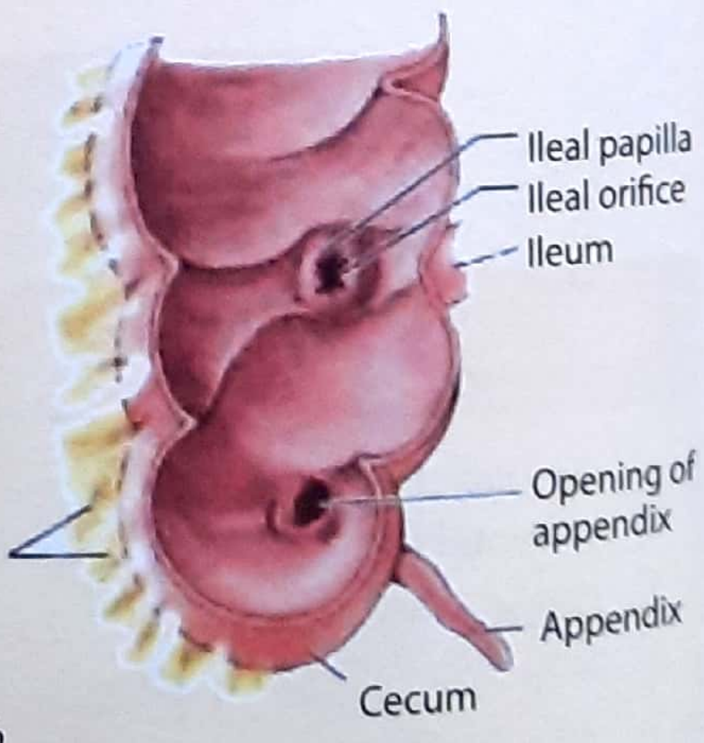

(B) Anterior view

KEY BOX 36.1	
Various anatomical position of the appendix	
1. Retro Cecal (R/C)	74% (Jipmer 87, U93)
2. Pelvic	21
3. Pre-ileal	1%
4. Postileal	0.5%
5. Subcecal	1.5%
6. Paracecal	2%

- In old age, the appendix atrophies and consequently appendicitis is again relatively rare.
- Appendix has large aggregations of lymphoid tissue in it's walls and is suspended from terminal ileum by the mesoappendix; which, contains appendicular vessel.
- The *appendicular artery is a branch of the lower division of the ileocolic artery.* (MANY PGME)
- *Appendicular artery is an* end artery; thrombosis of which results in gangrene & necrosis of the appendix; a condition called as Gangrenous appendicitis.

Sites of Appendix

Relative frequencies of various anatomical positions of the appendix are the following:

1. Irritates psoas major if inflamed
   Retro Cecal (R/C is M/C) - **74%** (NEET, JIPME87, UP 93)
2. Pelvic - 21 → **Most dangerous position** (NEET)
3. Pre-ileal - 1%
4. Post-ileal - 0.5%
5. Subcecal, Paracecal - 1:5%, 2%

Just to remember:

RC is **MC** ie; RetroCecal (R/C) site is Most Common (MC) (UP 93, MANY PGME). See box: 36.1 & Figure: 36.1.

*****

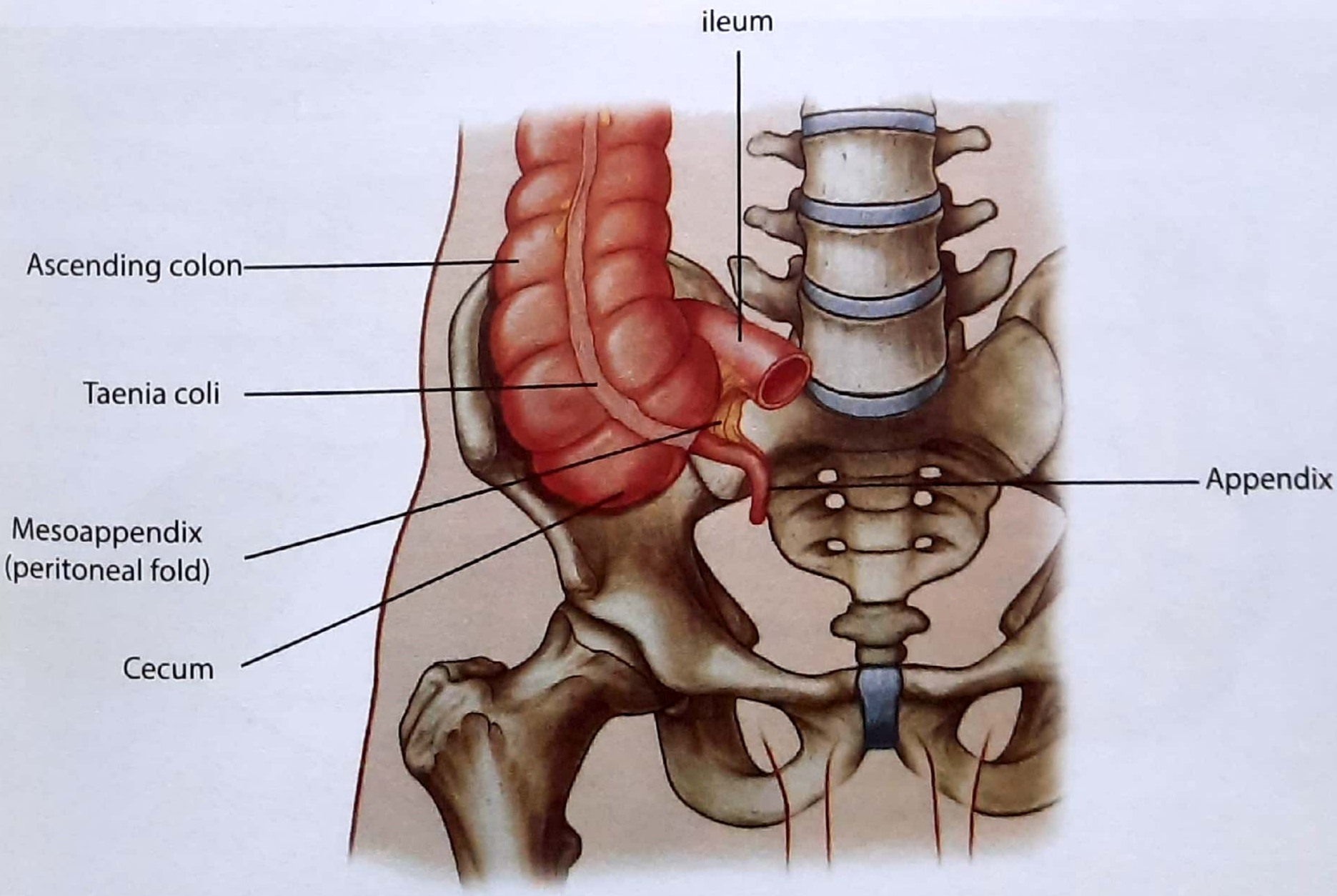

Figure 36.1: Position of appendix in right iliac fossa and it's relations

ACUTE APPENDICITIS

- Acute appendicitis is the **commonest surgical emergency.** *(MANY PGME)*
- It occurs at all ages, with peak incidence in teens and early 20s.
- In most cases, inflammation of the appendix is preceded by obstruction of the appendix lumen by either
  - (i) a fecolith (hardened inspissated mass of feces) or
  - (ii) by kinking of appendix lumen or
  - (iii) by submucosal lymphoid hyperplasia.
- Stagnation; distal to obstruction permits multiplication of bacteria. These bacteria then invade the mucosa and appendix wall; causing acute inflammation of appendix termed as acute appendicitis.
- Yersiniosis enterocolitica produces sign & symptoms mimicking acute appendicitis.

Incidence

The incidence has been steadily dropping over past 25 years however, the incidence in the developing countries which in the past has been quite low has been rising in proportion due to economic gains and change in life style.

The incidence of appendicitis is equal among males and female before puberty. In teenagers and young adults, male-female ratio increases to 3:2 at 25; there after the greater incidence in male declines.

Etiology

1. Diet

Decreased dietary fibre and increased consumption of refined carbohydrate increases chances of appendicitis.

2. Family tendency

It has been seen that many members of the same family sometimes suffer from appendicitis. This may suggest familial tendency for this condition. This is common with retrocecal appendix. This could be due to poor blood supply.

3. Infection

Infection by direct invasion from the lumen or blood stream. A mixed growth of aerobic and anaerobic organism is usual and *most common* bacteria are *E.coli, Streptococcus fecalis and Bacteroids.* *(MANY PGME)*

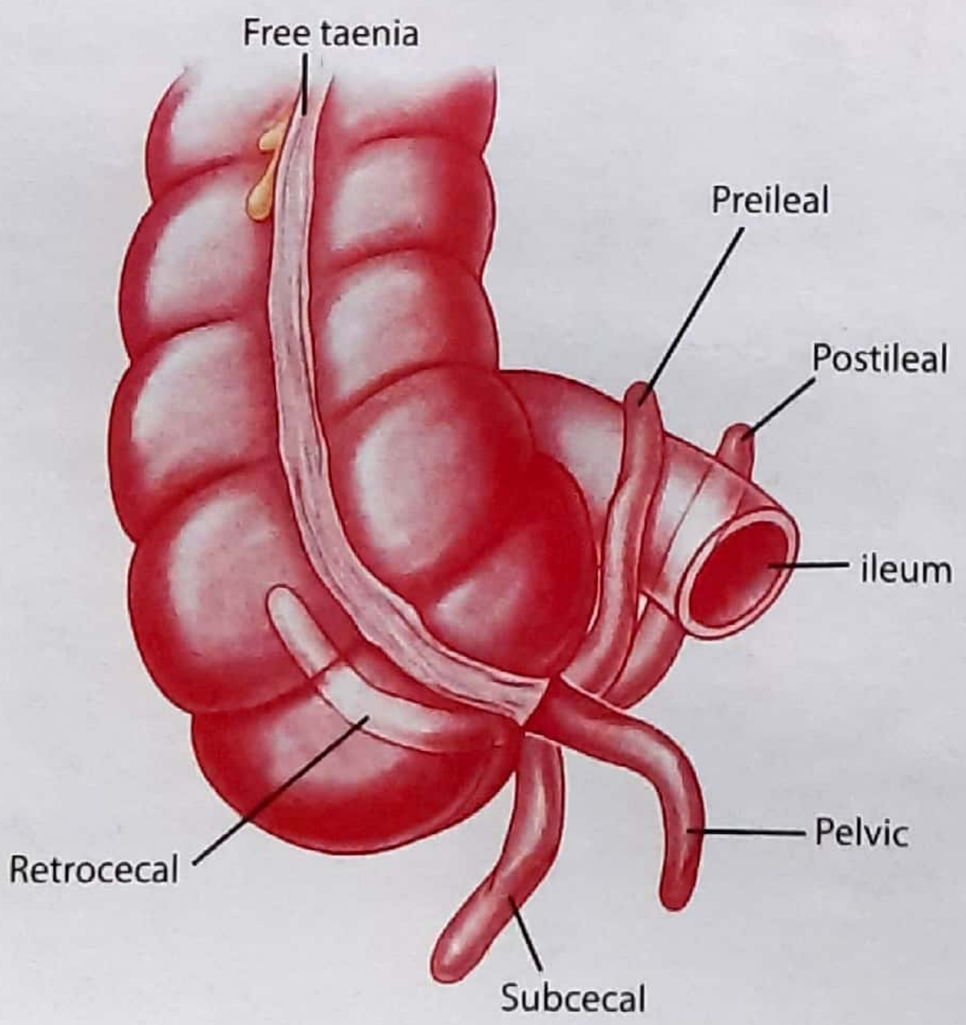

Figure 36.2: Different anatomical positions of appendix

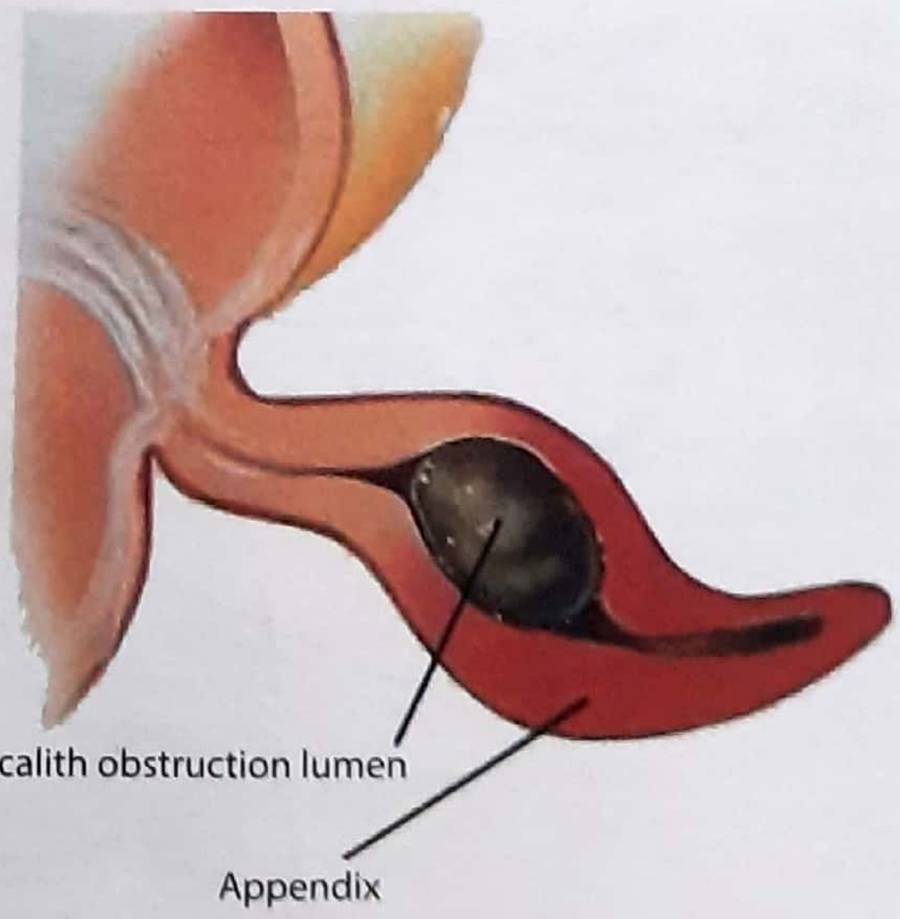

Figure 36.3: Fecolith in appendicular lumen

4. Obstruction of appendix lumen

The causes could be:

(a) Hyperplasia of submucosal lymphoid follicles (60%): This is **the most common cause in children and young adults.** *(NEET)*

(b) Fecolith* (35%): This is the most common cause in adults.

(c) Foreign bodies (4%)

(d) Stricture and tumours (1%)

(e) Worms(<l%) such as pin worm *(oxyuris-vermicularis)*

(f) Acute kinking of appendix by a band of old adhesion or a congenital band.

(g) Vegetable and fruit seeds.

(h) Contraction of base of appendix in a sphincteric manner.

FECOLITH is composed of inspissated *(dried)* fecal material, calcium phosphate, bacteria and cellular debris.

- Incidental finding of a fecolith at laparotomy is a relative indication for prophylactic appendectomy. *(PGME IMP. POINT)*

Pathology

There are two distinct types of pathology for inflammation of appendix (appendicitis).

1. Obstructive

The obstruction at the proximal end (cecal end) of appendix results in a closed loop obstruction; and continued normal secretion from appendiceal mucosa very rapidly produces distension of appendix, which is also contributed by rapid multiplication of the resident bacteria of the appendix. Pressure in the organ increases; and exceeds venous pressure. Capillaries and venules are occluded; but arteriolar inflow continues; resulting in engorgement and vascular congestion. When the distension overcomes the arteriolar pressure, there is *distal gangrene,* ***at the tip*** *(IMP. POINT)*. Often within twelve to eighteen hours later, there occurs perforation in the devitalized gangrenous appendix *(DUB 89, 91)*; which leads to peritonitis, *(mind: gangrene occurs at tip)*

Risk factors for perforation of appendix *(UP 04)*

- Extremes of age (very old & infants)
- Immunosuppression
- Diabetes mellitus

KEY BOX 36.1.1

Bacteria commonly isolated in perforated appendicitis

TYPE OF BACTERIA	ISOLATES (N = 694)
Gram-Negative Bacteria	
Escherichia coli	448 (64.6%)
Pseudomonas aeruginosa	114 (16.4%)
Klebsiella pneumoniae	37 (5.3%)
Citrobacter species	18 (2.6%)
Enterobacter species	10 (1.4%)
Serratia marcescens	3 (0.4%)
Raoultella planticola	3 (0.4%)
Comamomas testosteroni	2 (0.3%)
Aeromonas species	2 (0.3%)
Proteus species	2 (0.3%)
Acinetobacter species	1 (0.1%)
Yersinia species	1 (0.1%)
Morganella species	1 (0.1%)
Gram-Positive Bacteria	
Enterococcus species	27 (3.9%)
Streptococcus species	20 (2.9%)
Staphylococcus species	5 (0.7%)

- Free lying pelvic appendix
- Previous abdominal surgery

2. Non-obstructive

This occurs due to infection: which begins in the mucosa, usually at the bottom of one of the crypts where a small focus of suppuration is formed. When the infection reaches the submucosa; it spreads rapidly including subserous coat along the penetration vessels.

Clinical feature

Symptoms

1. Pain

- Initially vague pain is experienced around umbilicus.
- Pain is constant in non-obstructive type, where as colicy in obstructive type. *(IMP. POINT)*
- Later on when the parietal peritoneum is affected; the pain shifts to right iliac fossa and becomes well localized constant. Please see figure 36.4.

2. Gastric upset:

Anorexia, nausea and vomiting follows the onset of pain.

Gastric upset never precede pain; but always follow pain, (important point to remember) [Key box 36.2]

3. Low grade fever

4. Many patient may feel constipated, however diarrhea may be associated with a *pelvic appendicitis due to irritation of rectum by inflamed appendix.* *(PGME)*

Signs

1. Brown furred tongue and foul breath.

KEY BOX 36.2
Murphy's triad (Jipmer 86, 87, Ker 87)
• **Pain (First)** *(NEET)*
• Vomiting (next)
• Fever (last)
in that order in a patient with acute appendicitis

Typical site of pain

1. Hiatus hernia
2. Cholecystitis
3. Gastric ulcer
4. Duodenal ulcer
5. Appendicitis

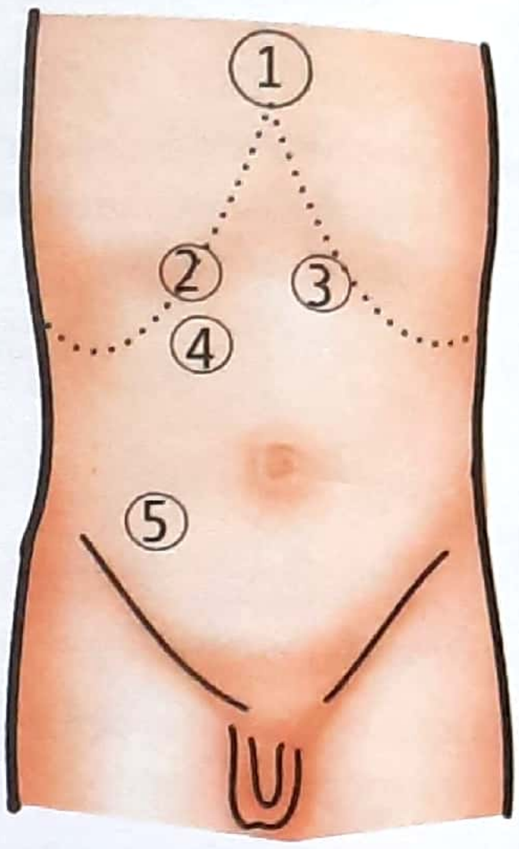

Figure 36.4: Typical site of pain

2. Pulse rate: There is no changes initially but after 6 hours; pulse rate rises with rise in temperature.
3. Temperature: The temperature is only slightly elevated (37.8°C) in the absence of perforation of appendix.

Abdominal examination *(VERY IMPORTANT)*

(i) ***Localized tenderness at McBurney's point-*** *McBurney's* point lies at the junction of lateral 1/3 and medial 2/3 of line joining the anterior superior iliac spine and the umbilicus. *(UP 93, MANY PGME)* Figure 36.5.

(ii) ***Pointing sign*** - Patients point out the exact site of pain by a finger; which is towards right iliac fossa.

(iii) ***Rebound tenderness in right iliac fossa.***

(iv) ***Hyperaesthesia in sherren's triangle:*** Sherren's triangle is formed by joining umbilicus, right pubic tubercle and right anterior superior iliac spine, (fig # 36.7)

(v) ***Rovsing's sign*** *(NEET, TN 01)*: On deep palpation in **left iliac** fossa, pain is felt by patient in **right iliac fossa,** in a case of appendicitis. *(IMP. POINT)*

(vi) ***Generalized rigidity and tenderness:*** In cases of peritonitis; which develop after perforation of appendix.

(vii) ***Psoas test:*** *Extension of hip is painful in retrocecal appendix, which lies on psoas muscle.* *(NEET, AIIMS 07)*

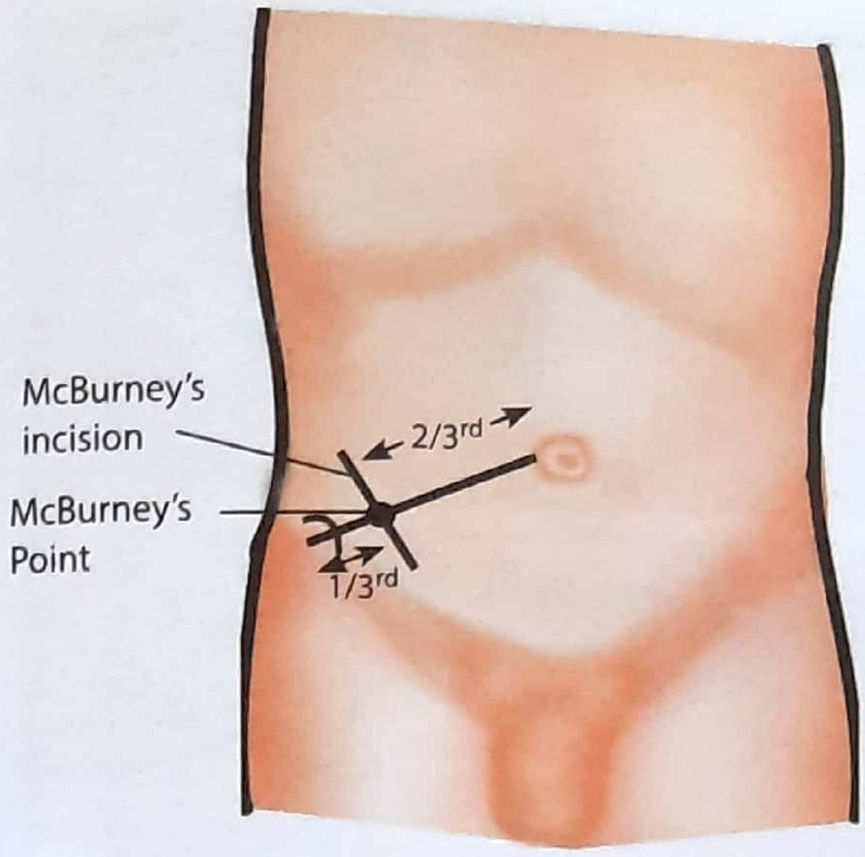

Figure 36.5: McBurney's Point and McBurney's incision

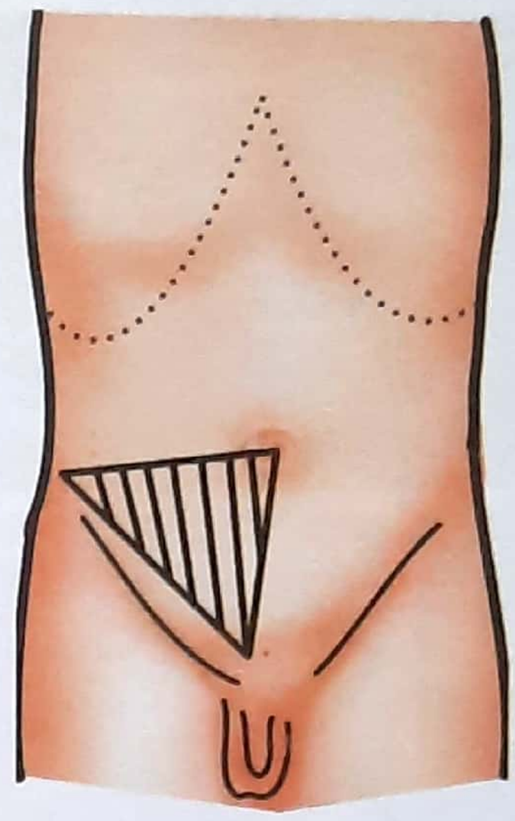

Figure 36.7: Sherren's triangle

(viii) ***Obturator test :*** **Internal rotation at hip joint causes pain in pelvic region**, if an inflamed appendix is in contact with obturator internus.

(ix) ***Palpable tender appendicular lump :*** This has been discussed on the next page.

(x) ***PR examination :*** During PR examination; the patient may feel pain on the right side of rectal wall.

Figure 36.6: McBurney's Point tenderness

<u>Special features of acute appendicitis according to age</u>

(a) Infants

(i) It is rare in infants below 3 years of age.

(ii) Incidence of perforation (about 99%) & post-operative morbidity is highest in infants among all age group

(iii) Diffuse peritonitis may develop rapidly, due to under developed greater omentum in infants.

(b) Children

(i) Vomiting is a common feature.

(ii) Bowel sounds are usually absent in the early stages.

(c) Elderly

(i) Gangrene and perforation occur more frequently

(ii) Abdominal signs are minimal due to lax abdominal wall

(iii) Morbidity and mortality is high.

(d) Obese

(i) Obesity may obscure and diminish local signs.

(ii) There may be technical difficulties during surgery.

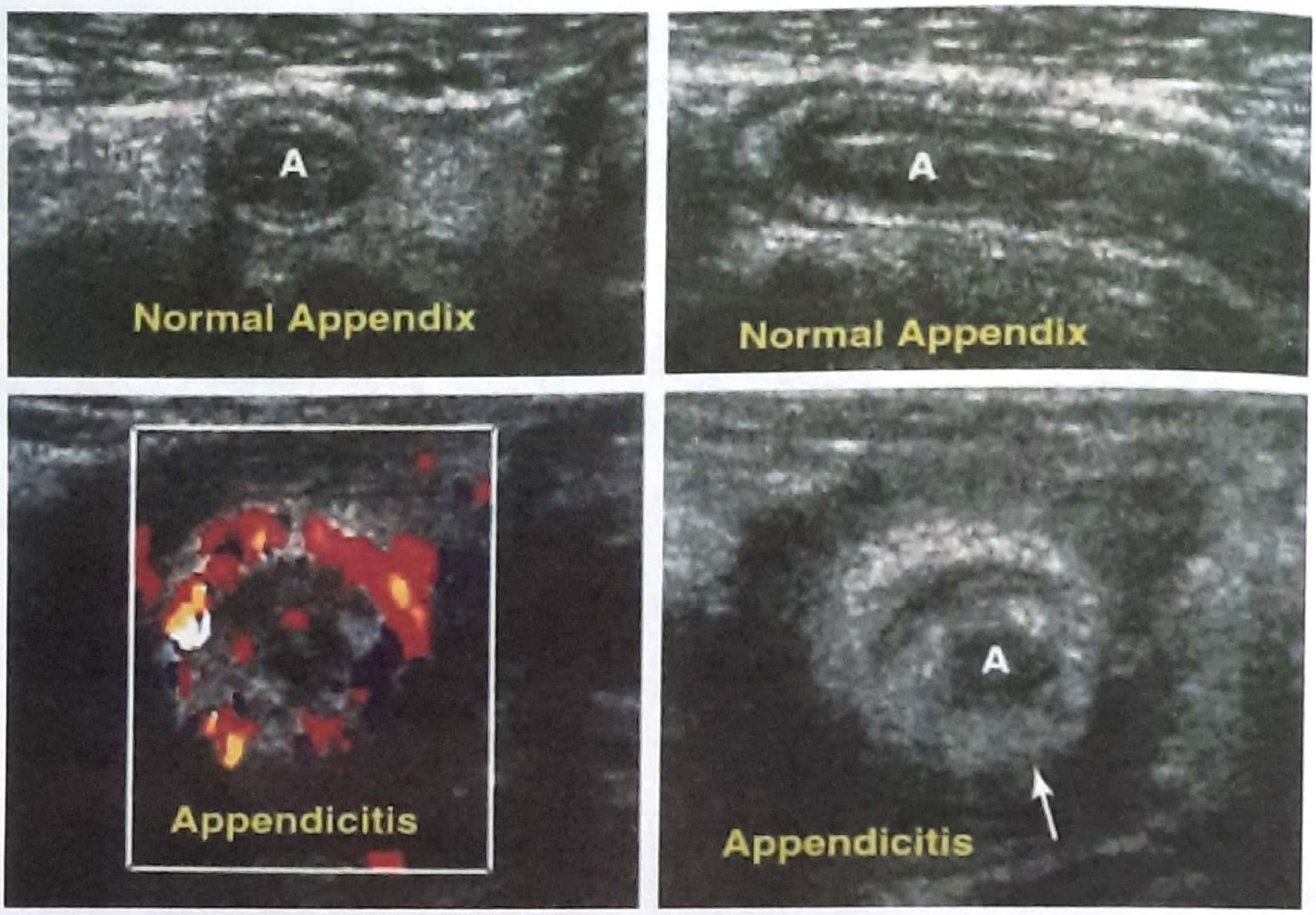

Figure 36.8: Ultrasound image of a normal appendix (top) illustrating the thin wall in coronal (left) and longitudinal (right) planes. In appendicitis, there is distention and wall thickening (bottom right), and blood flow is increased, leading to the so-called ring of fire appearance.

(e) Pregnancy

(i) Appendicectomy is the *most common extra uterine abdominal procedure. performed during pregnancy.* (PGME)

(ii) Acute appendicitis is *equally common during all the three trimesters.* (MANY PGME)

(iii) During the third trimester, the cecum and the appendix are progressively pushed into the right upper quadrant of the abdomen and can result in back pain.

(iv) Delay in diagnosis, resulting in rupture of appendix results in an increased fetal mortality rate.

Investigation

1. Laboratory finding

The average leucocyte count is 15,000/uL and 90% of patients have counts over 10,000/ul.

The urine examination is usually normal, but a few leukocytes and erythrocytes and occasionally seen. Rarely even gross hematuria may be noted; particularly in retrocecal or pelvic appendicitis.

2. Plain X-ray of the abdomen

(a) May be normal

(b) A radioopaque fecalith may occasionally be seen in right lower quadrant.

(c) Absence of bowel gas in RIF. (right iliac fossa)

(d) If appendix is gangrenous or has perforated: the X-ray shows intramural gas in appendix, displaced cecum or ***rarely*** free air in the peritoneum.

3. Ultrasonography

Sonography has low sensitivity level (80%); it has high specificity (> 90%). (figure 36.8) This is now investigation of choice in children. Often the appendicular lumen diameter is almost always > 7mm. (JIPMER MAY 19)

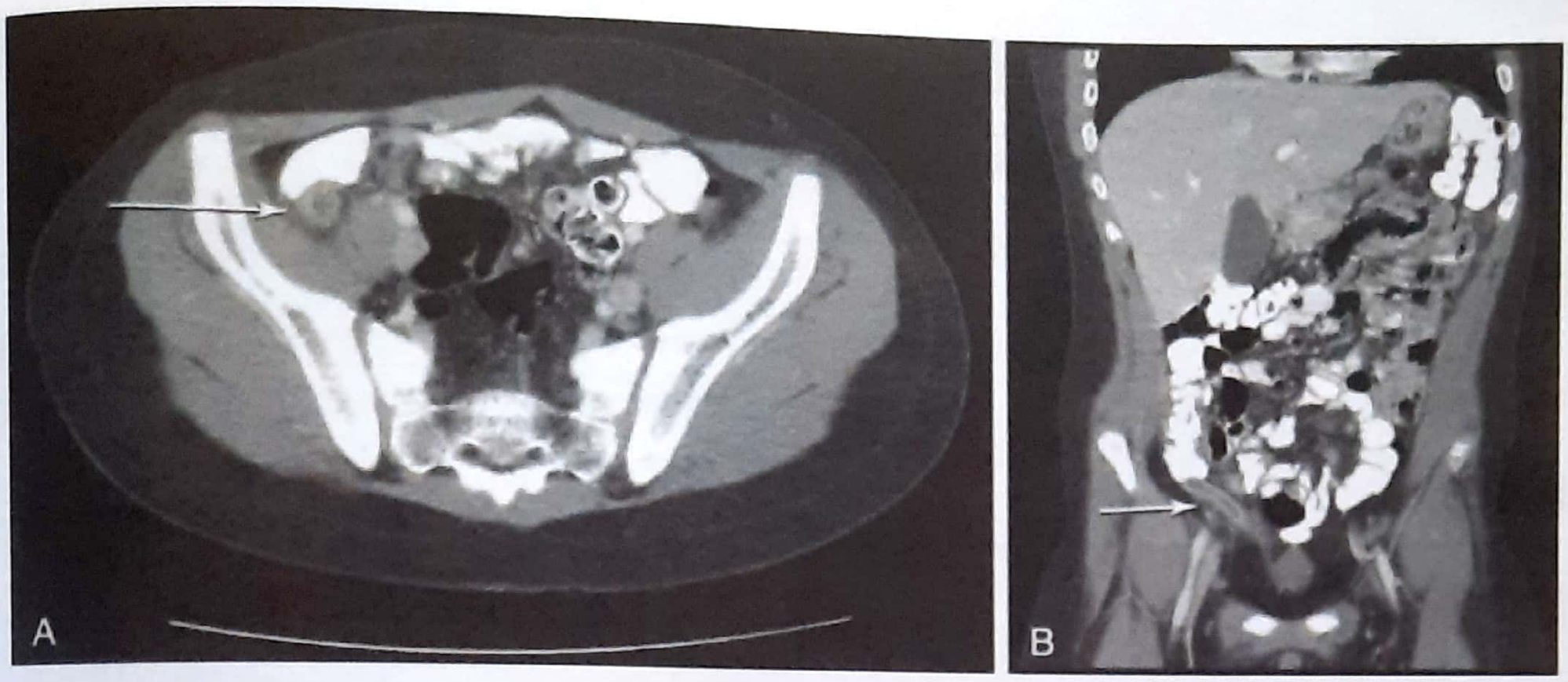

Figure 36.9: Computed tomography scan of the abdomen demonstrating classic findings of acute appendicitis. (A) Sagittal view with arrow demonstrating a thickened, inflamed, and fluid-filled appendix (target sign). (B) Coronal view of same patient.

4. CTScan

CT scan is very useful and cost effective in the right clinical setting and is ***investigation of choice, in adults*** (NEET, IMP. POINT)

Ultrasound imaging is less reliable than CT scan. But the problem, with CT scan is that it is costly and has radiation hazards (should not be carried out in children and pregnant women). (Figure 36.9)

CT is done when -

1. USG is equivocal
2. 1st line test in obese patient
3. There is gaseous distension of bowel
4. In the event of probable advanced appendicitis

Alvardo Scoring For Acute Appendicitis

(This is also known as **MANTRELS*** score). (NEET)

Acute appendicitis is by no means an easy diagnosis, that is why a scoring system, as described by alvardo is used which is based on *three symptoms, three signs and two laboratory finding.* Total score in 10.

The Alvarado score

		Value
Symptoms	• Migration	1
	• Anorexia	1
	• Nausea	1
Signs	• Tenderness in right lower quadrant	2
	• Rebound pain	1
	• Elevation of temperature	1
Laboratory	• Leukocytosis	2
	• Left shift of WBC	1
Total score		10

KEY BOX 36.3

Essentials of Diagnosis (For Appendicitis)

- Abdominal pain
- Anorexia, nausea and vomiting
- Localized right lower quadrant pain
- Abdominal tenderness
- Low-grade fever
- Leukocytosis

GENERAL APPROACH TO THE PATIENT WITH SUSPECTED APPENDICITIS

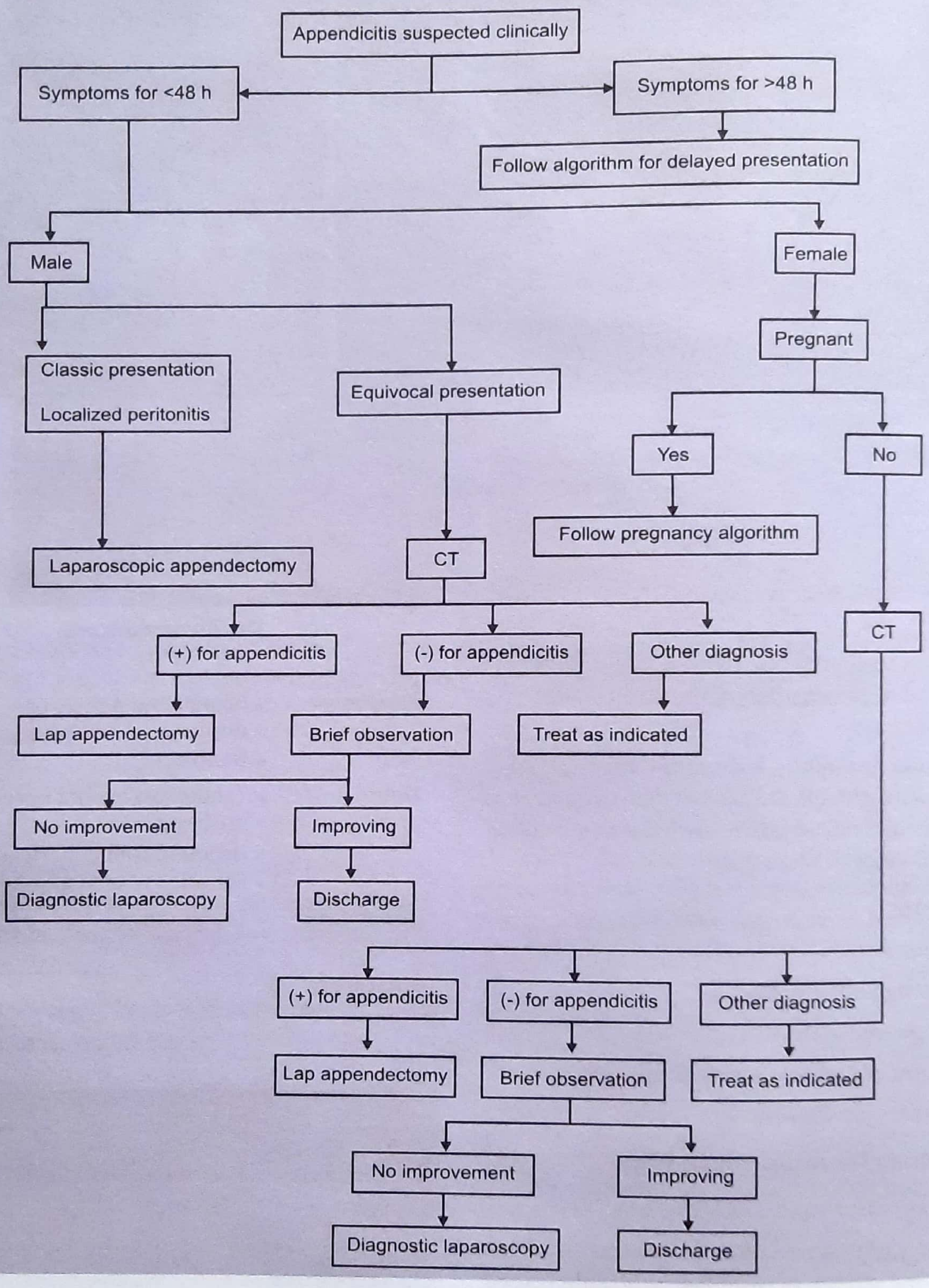

* **MANTRELS:** **M**igration of pain; **A**norexia; **N**ausea or vomiting; **T**enderness; **R**ebound pain; **E**levation of temperature; **L**eucocytosis; **S**hift to left (segmented immature neutrophils)

* **RIF** *Right iliac fossa*

Interpretation

- Patients with score of 1-4 are extremely unlikely to have appendicitis.
- Score between 5-6 are equivocal and need further investigation i.e. USG or/and CT scan.

- Score between 7-10 highly suspicious of acute appendicitis.

Kalan has modified this score and excluded *'shift of neutrophils to the left'* from score, and their patients were scored 9 rather than 10 points.

Complications of Acute Appendicitis

If not treated; acute appendicitis leads in to (ie; fate of **acute appendicitis)** *(PGME)*

1. Appendicular lump (Discussed later)
2. Perforation → Early perforation leads to diffuse peritonitis.
3. Peritonitis (local or general)
4. Appendicular abscess
5. Adhesion formation (adhesive intestinal obstruction)
6. Portal pyermia (pylephlebitis)-rare

Differential Diagnosis

1. Acute gastroenteritis
2. Acute mesenteric lymphadenitis → most common
3. Meckel's diverticulitis
4. Terminal ileitis
5. Right ureteric colic
6. Perforated peptic ulcer
7. Acute cholecystitis

NOTE: There are many other uncommon D/D of acute appendicitis, but I have listed only common once.

Treatment

The treatment of acute appendicitis is **appendicectomy,** which is carried out as soon as diagnosis is made. Intravenous fluids, and appropriate antibiotics should be started.

Steps in appendectomy

Left above location of possible excision of open appendectomy below right.

1. When peritonitis is suspected, therapeutic IV antibiotics should be started.
2. Appendicectomy may be performed by conventional open operation or by using laparoscopic techniques.
3. The **incisions** for **appendicectomy are :**
   (a) ***Gridiron incision (McBurney's)*** is the standard approach, (See figure 36.12) *(MANY PGME)*

   Most common nerve injured is iliohypogastric nerve. *(PGME)*

   (b) ***Rutherford Morrison incision*** is used if better access is required. This is a *muscle cutting incision.* *(KAR 94)*

   (c) A *transverse skin crease (lanz)* incision has gained popularity in recent years as the exposure is better and extension of incision; if required is easier. Fig. 41.6.1 (upper incision) page 751.

   It is a muscle splitting incision.

   (d) ***Right lower paramedian incision*** is made, if the diagnosis is in doubt or perforation peritonitis is suspected. (Page 751)
4. ***Laparoscopic appendicectomy*** is particularly useful in early stage of appendicitis and in women of child-bearing age. (Figure 36.11)

Post-operative Complication

These are relatively uncommon.

1. Would infection.
2. Intra abdominal abscess (M/C- *pelvic abscess; more common with laparoscopic appendicectomy than open appendicectomy)*
3. Post operative ileus
4. Venous thrombosis and embolism.
5. Respiratory complication
6. Portal pyemia (pylephlebitis) - This is a suppurative thrombophlebitis of the portal venous system.
7. Fecal fistula
8. Adhesive intestinal obstruction
9. Right inguinal hernia: This is believed to be more common following a grid-iron incision for appendicectomy, due to *injury to the ilioHypogastric nerve.* *(AI 03)*

TO REMEMBER H for Hernia and H for Hypogastric, i.e; due to injury to ilio-Hypogastric nerve.

*****

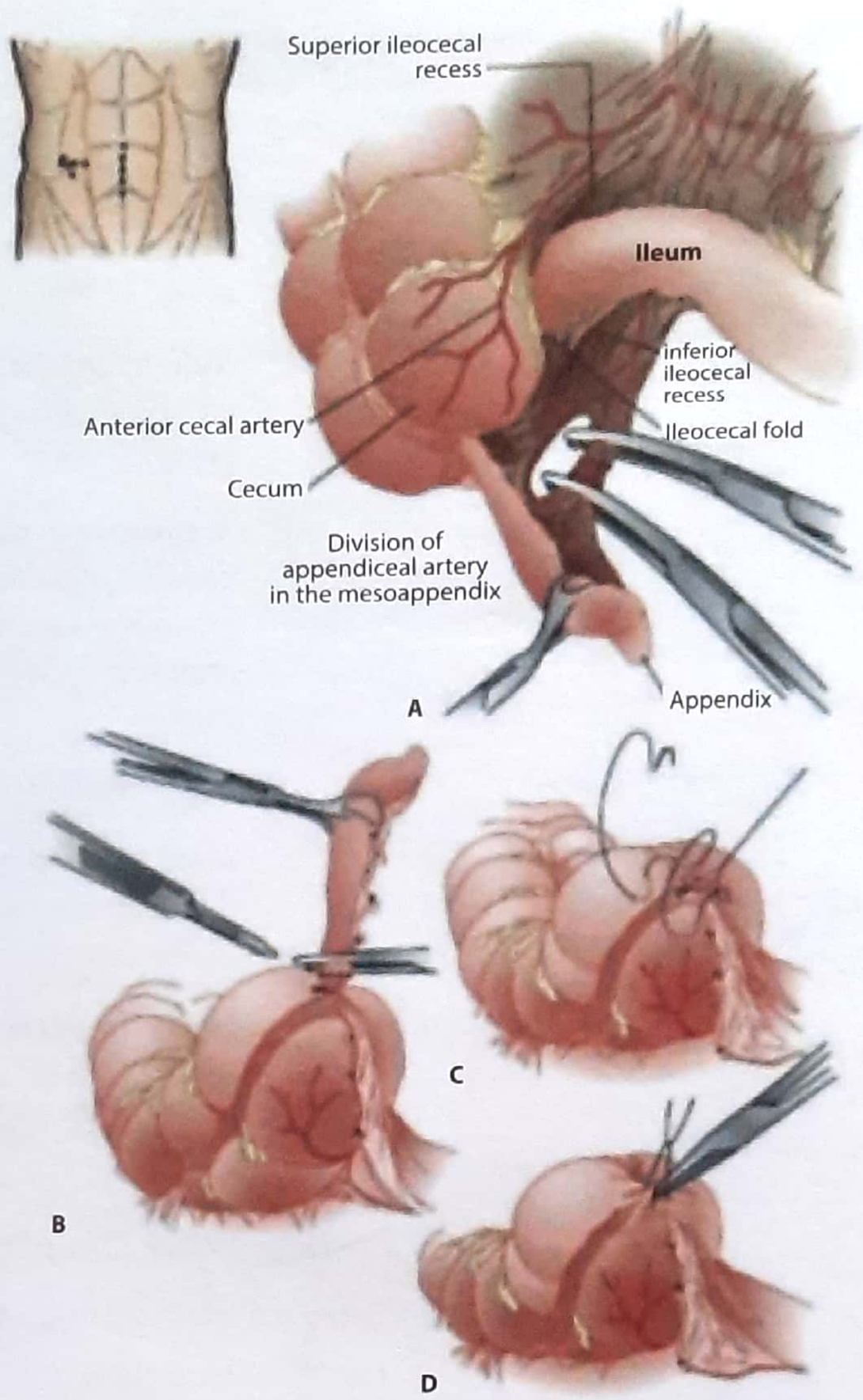

Figure 36.10: Steps in appendectomy. Left, location of possible incisions for an open appendectomy. Right, Division of the mesoappendix. (B) Ligation of the base and division of the appendix. (C) Placement of purse-string suture or Z stich. (D) Inversion of the appendiceal stump.

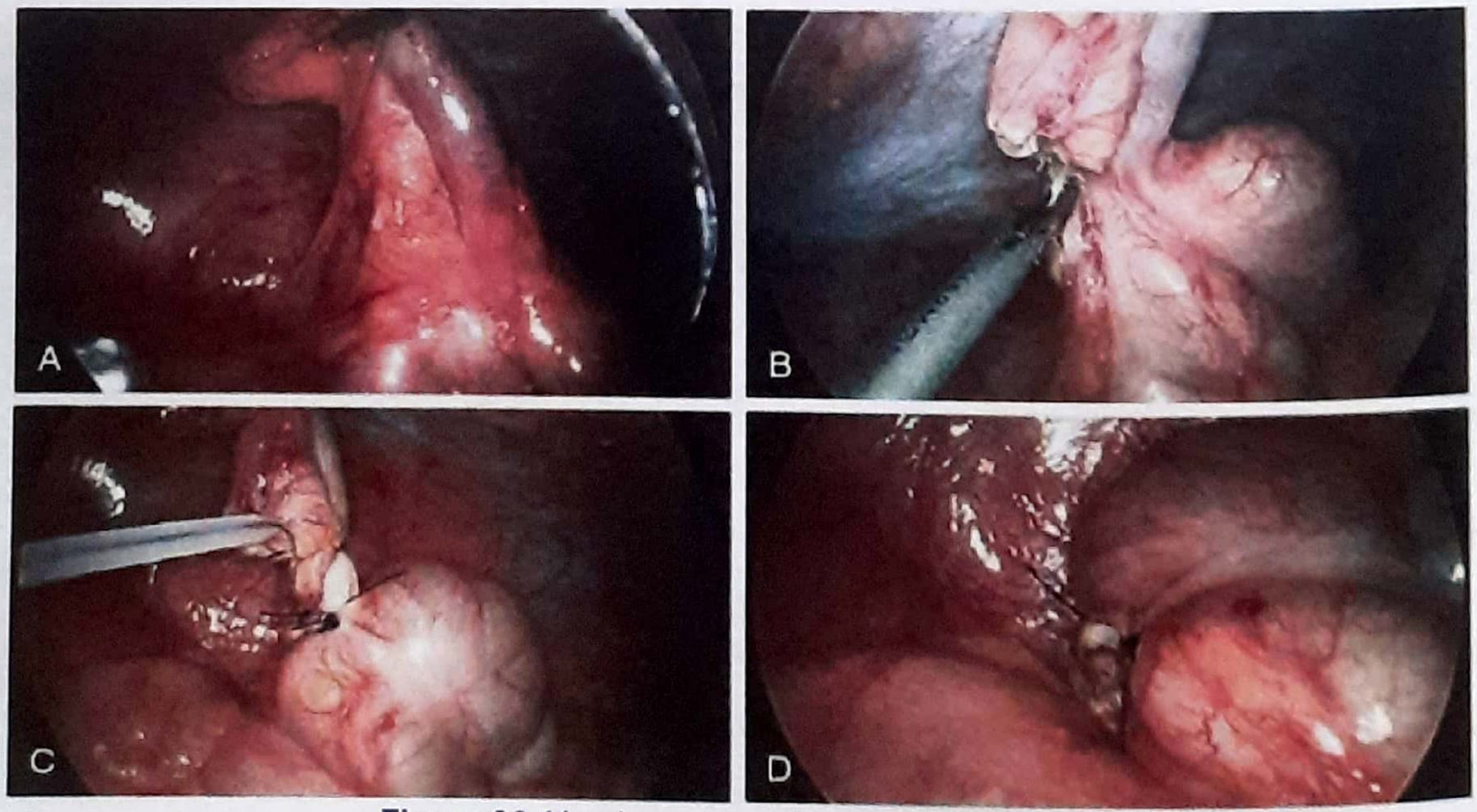

Figure 36.11: Laparoscopic appendectomy

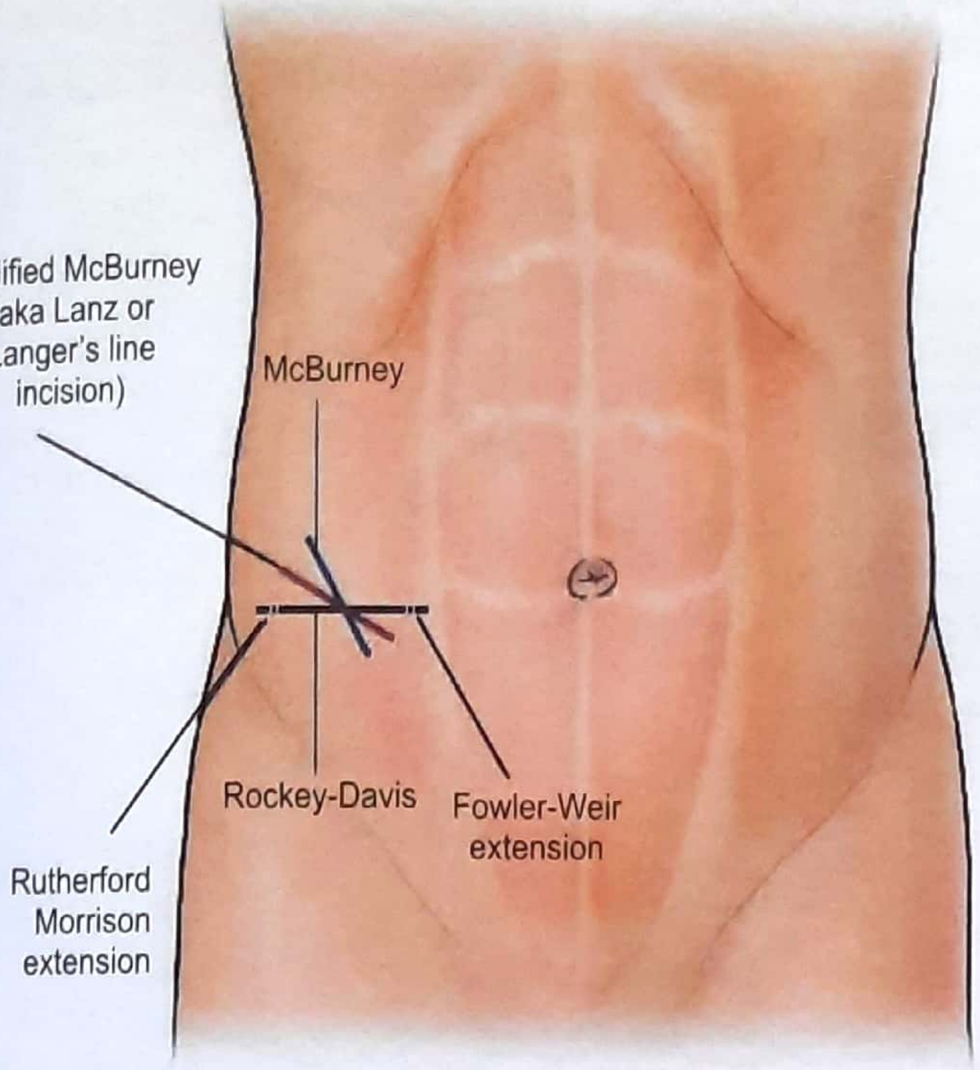

Figure 36.12: Incisions for appendicectomy

APPENDICULAR LUMP (MASS)

- It is a palpable, tender appendicular lump- formed by Inflamed appendix, greater omentum, inflamed cecum, coils of intestine, ascending colon and neighbouring peritoneum.
- This condition usually develops *after third day* of commencement of an attack of acute appendicitis.
- It develops as a protective mechanism of body defence to prevent generalized peritonitis.

Differential diagnosis (of appendicular lump)

- Hyperplastic ileocecal tuberculosis (M/C, D/D)
- Carcinoma of the cecum
- Amebic typhlitis
- Crohn's disease
- Actinomycosis of cecum
- Lymph node enlargement

Management

Conservative treatment is indicated, as immediate abdominal exploration, and appendicectomy has a higher incidence of intestinal fistula formation and need for a right hemicolectomy due to the dense inflammatory process making surgical anatomy obscure. Appendicectomy at this time is difficult, bloody and dangerous.

The **principles of initial conservative** treatment are **(Oshner-Sherren regimen)**: *(NEET, UP 05,JIP 92, MANY PGME)*

(a) Charts of clinical signs; size of lump
(b) Pulse charting every four hourly.
(c) Temperature charting
(d) Nil by mouth, until documented improvement.
(e) Broad-spectrum IV antibiotics with Gram-negative and Gram-positive coverage.
(f) Intravenous fluids
(g) Prophylactic thromboembolic therapy.

Now see this flow chart:

Conservative management will give two clinical picture

- Improvement → Continue antibiotic therapy, then interval (after 6-8 weeks) appendicectomy
- **Does not improve/worsen** *(NEET)* → **Immediate exploratory laparotomy, with appendicectomy and abscess drainage (if present)**

*****

RECURRENT APPENDICITIS

Chronic appendicitis, per se, does not exist. Patients labelled thus (wrongly) are usually examples of the recurrent form of the disease.

Recurrent appendicitis is a mild subacute attack of varying intensity appearing in episodes. It may have usual or unusual clinical features and usually terminate in acute appendicitis. The treatment is interval appendicectomy.

*****

MUCOCELE OF THE APPENDIX

This is an *aseptic dilation* of the appendix due to blockage of the proximal end of it's lumen.

SUGGESTED ALGORITHM FOR THE NON-OPERATIVE MANAGEMENT OF ACUTE UNCOMPLICATED APPENDICITIS

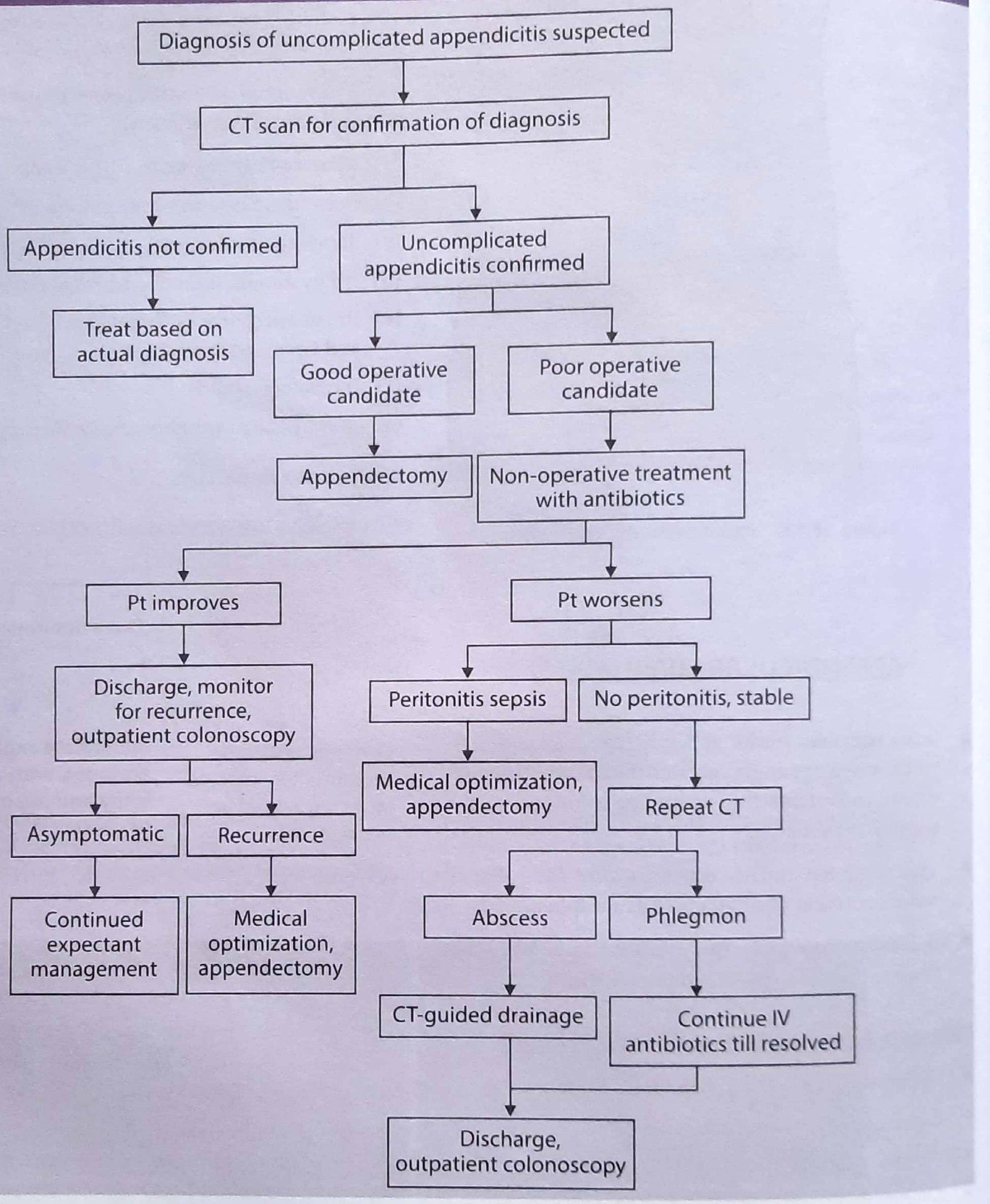

Etiology

This follows occlusion of the proximal end of appendix lumen. It is usually due to a fibrous stricture and some times due to a neoplasm at the base of the appendix.

Pathology

Appendix is grossly enlarged due to accumulated sterile secretions. It may contain several milliliters of mucus. It can be due to a benign non inflammatory occlusion or a malignant grade I mucus papillary adenocarcinoma.

(AL 89)

Clinical features

The symptoms are those of mild, subacute appendicitis. If infection supervenes, the symptoms become more severe. An infected mucocele is called an empyema. Rupture of a mucocele of the appendix is a cause of *Pseudomyxoma peritonei**. (PGME)

This is an uncommon condition in which peritoneal cavity is filled with mucinous (Jelly like) substance.

Investigations

Investigation of choice are abdominal USG and CT scan. (Figure 36.13)

Treatment

Preferred treatment is appendicectomy. If the mucocele is caused by a mucus secreting adenocarcinoma, right hemicolectomy is advisable (see below).

*****

TUMOURS OF APPENDIX

Carcinoid tumours

- Carcinoid tumours are the **most common** (NEET) neoplasm of the appendix (AIIMS NOV 93)
- Carcinoid tumours arise from neuroendocrinal cells (APUD cells, Kulchitsky cells) present in the mucosa throughout the gastrointestinal cells.
- The **tip** of the appendix is the *most common site for carcinoid tumour* (PGME). See figure 36.14, 36.15.
- Appendix carcinoids are usually incidental finding at appendicectomy and rarely gives rise to metastases.
- The *carcinoid of appendix are benign in over 99% of cases.* Only those rare tumours that are **over 2 cm in diameter have potentially malignant behaviour.**

Treatment

Depends upon size of tumour at laparotomy.

- A carcinoid tumour of less than 2 cm in benign and only appendicectomy is done. (UP)
- A *carcinoid tumour of* ***more that 2 cm and/or*** *lymph node positive should be considered malignant and* ***right hemicolectomy**** is indicated. (NEET, AIIMS NOV 2000, AIIMS JUNE 99)

[*Right hemicolectomy: Involves removal of :- terminal ileum + cecum + ascending colon + right half of transverse colon along with it's mesentery. Figure 36.16]

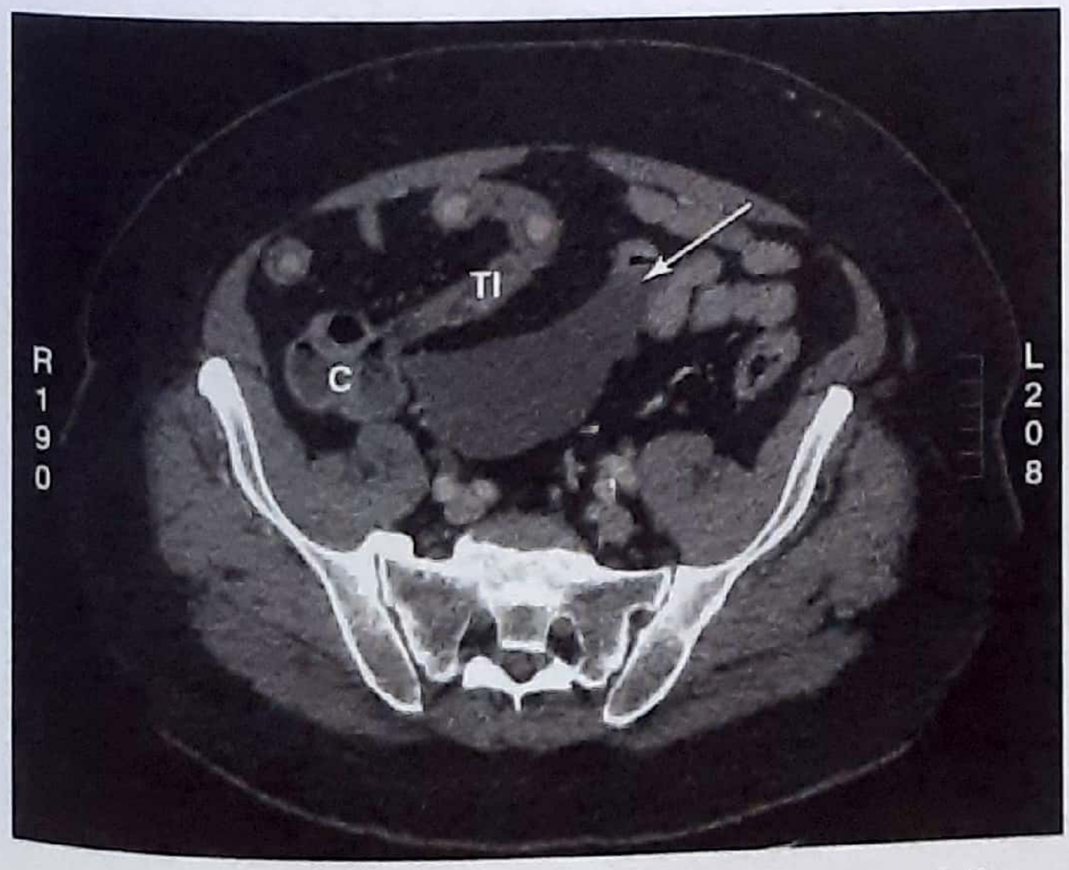

Figure 36.13: Computed tomography scan of the abdomen in a patient with a benign 10-cm mucocele.

Figure 36.14: Carcinoid of Appendix

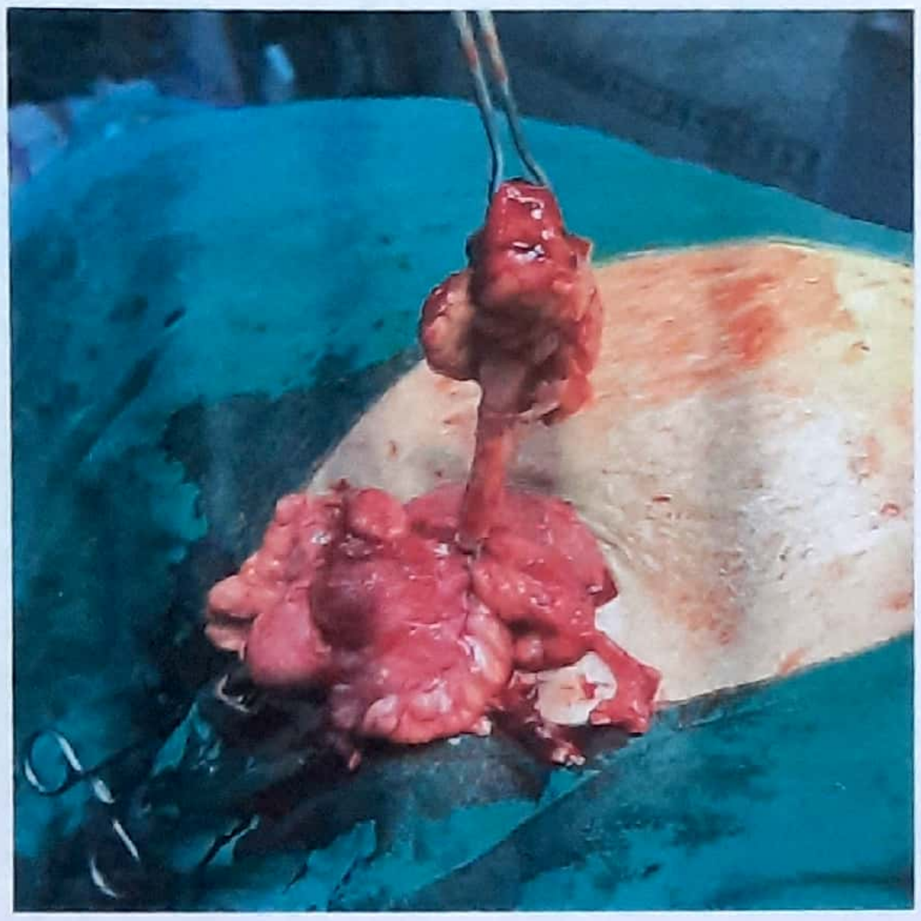

Figure 36.15: On table picture of carcinoid of appendix, carcinoid is present and tip of the appendix

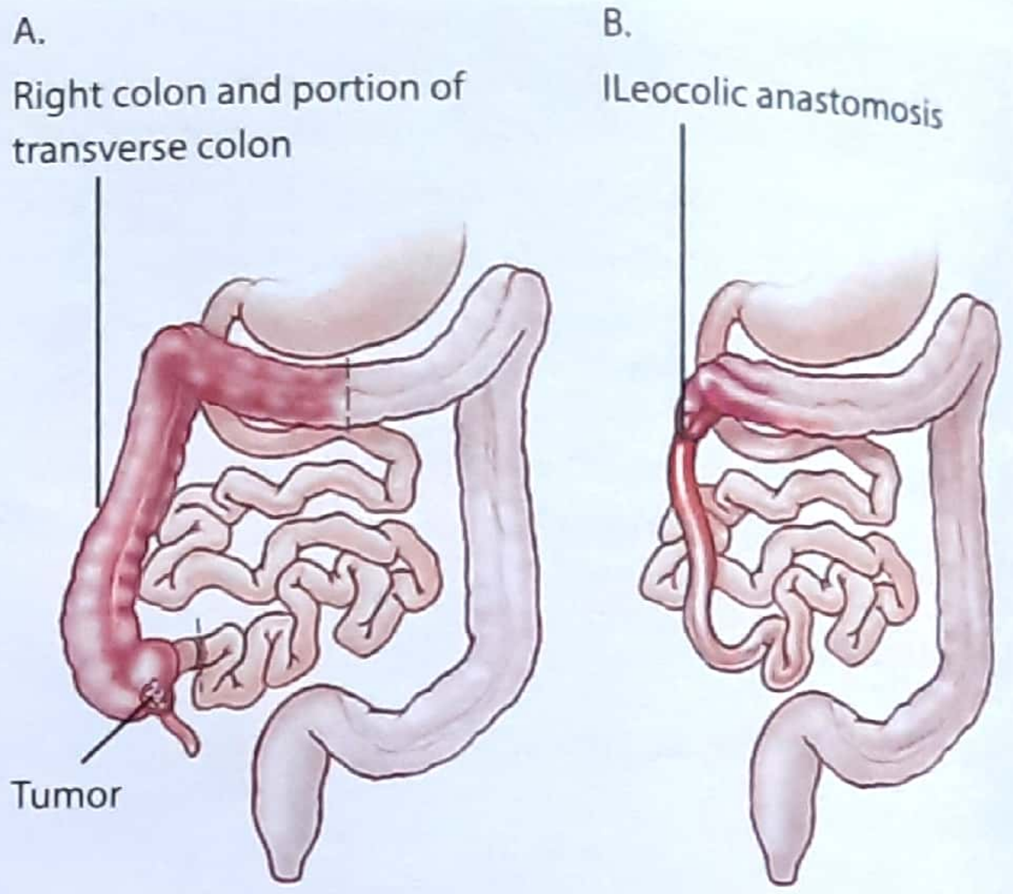

Figure 36.16: Right hemicolectomy, note the dark shaded area is resected and anastomosis is made between remaining ileum and transverse colon (ileo- transverse anastomosis)

Primary Adenocarcinoma

Primary adenocarcinoma (NEET) of the appendix is extremely rare. It is usually of the colonic type and should be treated by right hemicolectomy (see figure 36.16).

Lymphoma of appendix is treated by right hemicolectomy.

Sample Questions for Prof Examination

1. Discuss the clinical features, differential diagnosis and management of acute appendicitis.
2. Describe the pathology, clinical features and management of acute appendicitis. What are the differential diagnosis.
3. Describe the pathology of acute appendicitis. What are the way in which an attack can terminate?
4. Describe the management of a case of appendicular perforation with diffuse peritonitis.
5. Describe the signs, symptoms, diagnosis and treatment of acute appendicitis.
6. Describe the etiology pathology clinical features and management of acute appendicitis?
7. Give etiology, pathology clinical feature and management of acute appendicitis?
8. Discuss differential diagnosis of a lump in right iliac fossa.

37 The Rectum

Contents

- Surgical anatomy
- Proctitis
- Prolapse of rectum
- Solitary rectal ulcer
- Benign tumours of the rectum
- Carcinoma of rectum
- Bleeding per rectum

SURGICAL ANATOMY

- The rectum has an ill defined anatomical beginning, and surgically the rectosigmoid junction lies opposite the sacral promontory. From here the rectum follows the curve of the sacrum; to end at the anorectal junction.
- The rectum has three lateral curvatures: upper & lower are convex to right, while middle is convex to left.
- On the mucosal (luminal) aspect, these three curves are marked by semicircular fold *(Houston's valves)*.
- The lower part of rectum, that lies immediately above the pelvic diaphragm is dilated to form rectal ampulla.
- Distension of the rectum causes the desire to defecate.

Peritoneal Relations

- The adult rectum is approximately 18-20 cm is length and is divided into three equal part. Upper 1/3, middle 1/3 and lower 1/3. Please see figure 37.1.

  (i) The upper 1/3 of the rectum is covered with peritoneum *in front* and *on the lateral side.*

  (ii) Middle 1/3 is covered with peritoneum *in front*

  (iii) The lower 1/3, which is dilated to form the rectal ampulla and *is devoid of peritoneum.*

The lowest part of the rectum is separated by prostate and coccyx by a facial condensation, which are:-

(a) From the prostate in front by Denonvillier's fascia

(b) From the coccyx and last two sacral vertebrae behind by Waldeyer's fascia

Blood supply

Arterial supply

- The *superior rectal artery* is a direct continuation of the inferior mesenteric artery and is chief artery supplying the mucous membrane.
- The *middle rectal artery* is a small branch of the Internal iliac artery.
- The *inferior rectal artery is* a branch of the Internal pudendal artery.

Venous drainage

Superior rectal vein-drain into inferior mesenteric vein and is a tributary of the portal circulation.

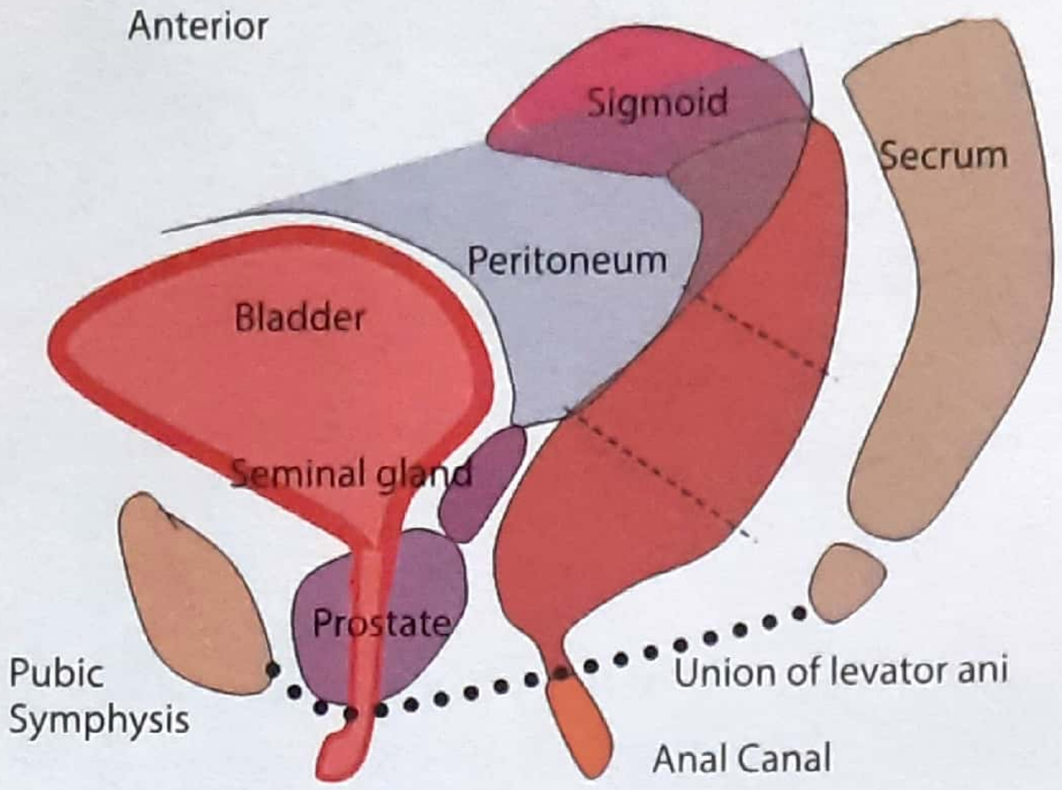

Figure 37.1: The boundaries of Recto-uterine pouch and peritoneal reflection of rectum

The middle and inferior rectal veins drain into internal iliac and internal pudendal veins respectively.

Lymphatic drainage

1. Lymphatics from the upper half of the rectum passes along the superior rectal vessels to inferior mesenteric nodes after passing through pararectal nodes (of gerota) and sigmoid nodes.
2. Lymphatics from the lower half of the rectum, pass along the middle rectal vessels to the internal iliac nodes.,

Now lets discuss Diseases of rectum.

*****

PROCTITIS

Inflammation of rectal mucosa is known as proctitis. It may be associated with similar disease of the colon when the condition is called as proctocolitis. Proctitis may be acute or chronic.

Etiology

1. Idiopathic nonspecific proctitis is most common cause and its etiology is still unknown.
2. Ulcerative proctitis, as a part of ulcerative colitis.
3. Bacillary dysentery causes acute proctitis.
4. Amebic dysentery produces chronic proctitis with amebic ulcer. Some time amebic granuloma may present as a small mass at rectosigmoid junction which may be confused to a carcinoma on per-rectal examination.
5. Proctitis may be
   - Tuberculous proctitis
   - Gonococcal proctitis
   - Syphilitic proctitis (now rare)

Clinical feature

The typical symptom of proctitis is tenesmus. *Tenesmus* is painful straining to empty the bowel without resultant evacuation. Acute proctitis is associated with prodromal symptom such as fever, malaise etc.

Rectal examination

The mucosa of the rectum is swollen and tender. On the examining finger; blood with mucus may be found.

- Sigmoidoscopy will reveal red edematous, inflamed mucosa with small superficial ulcer.
- Biopsy may be necessary to exclude carcinoma.

Treatment

Stool softeners and specific antibiotic therapy is given.

*****

PROLAPSE OF RECTUM

Rectal prolapse can be differentiated into

1. Partial prolapse
2. Complete prolapse (Procidentia)

When *only the mucosa and submucosa of the rectum come out through the anus it is called* partial prolapse. The length of such prolapse is never more than 3.75 cm.

In *Complete rectal prolapse* the whole rectum comes out through the anus and protrusion consists of all layers of the rectal wall. It is always more than 3.75 cm in length and usually about 10 cms. (Figure 37.2 and 37.3)

Etiology

This condition occurs more often in extremes of life. Children below 3 years of age and elderly people are most commonly affected.

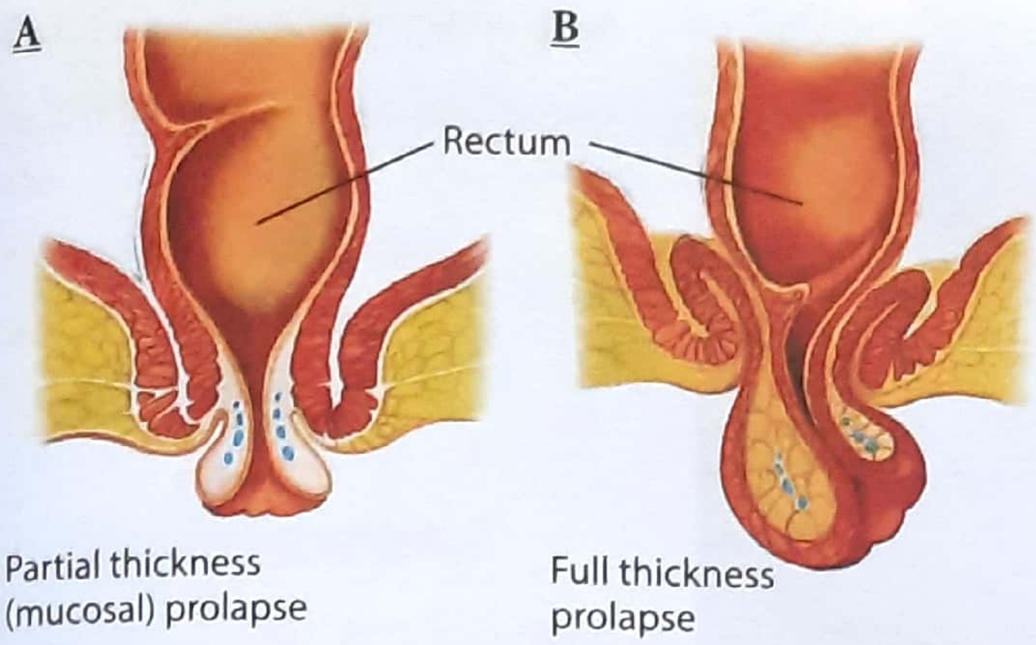

Figure 37.2: Rectal prolapse

Figure 37.3: Rectal prolapse in sixteen year old boy

1. In Infants

- As the rectal curve of the rectum has not yet developed, the direct downward course of rectum predispose to this condition.
- Diminishes tone of anal musculature.

2. In Children

- Faulty bowel habit - habitual constipation.
- It can follow an attack of *whooping cough* or *excessive straining.* (PGME)
- It can follow an *attack of diarrhea* resulting in loss of ischiorectal fat, which supports the rectum. (PGME)

3. In adults

- Loss of anal tone.
- Third degree hemorrhoid may be associated with partial prolapse.
- As a post operative complication of fistula in ano or fissure-in-ano.

KEY BOX 37.1

Treatment of rectal prolapse

Partial prolapse
(less than 3.75 cm)

1. Digital reposition
2. Injection therapy
   Injection of ethanolamine oleate
   Submucous injection with 5% phenol in almond oil.
3. Excision of partial prolapse after applying Goodsall's ligature
4. Theirsch's operation

Complete prolaps
(more than 3.75 cm)

1. **Perineal procedures**
   Delorme's operation
   Altemeir's operation
   Thiersch wiring
2. **Abdominal procedure**
   Well's procedure
   Ripstein's sling operation
   Mesh rectopexy
   Lahaut's operation
   Low anterior resection
   (Rectosigmoidectomy)
3. **Electrical stimuli**

Figure 37.4: The internal rectal prolapse of a male patient is nicely demonstrated by detecography. (B) and (C) Progression of the internal rectal prolapse.

- Excessive straining due to urethral obstruction, from enlarged prostate, stricture urethra or excessive coughing due to COPD.
- In female: torn perineum may cause prolapse.

Treatment

Please see flow chart first; in key box 37.1 on page 679.

(a) For partial prolapse

1. Digital reposition:

In infants, partial prolapse is usually temporary and self limiting. Mother is taught to replace the protruded bowel through the anal sphincter.

2. Injection therapy:

This can be done by submucous injection of *ethanolamine Oleate or 5% phenol in almond oil.* It causes aseptic fibrosis & mucus membrane becomes fixed to the muscular coat.

3. Excision of the prolapsed mucosa:

When the prolapse is unilateral; the redundant mucosa can be excised after inserting and tying a **Goodsall's ligature.**

4. Thiersch's operation:

The procedure is described later.

(b) For Complete prolapse (AI 10)

Surgery is required and operation can be performed via the

1. Perineal approaches
2. Abdominal approaches
3. Electrical stimuli

1. Perineal approach

Mnemonic: **T**he **A**LL **D**elhi are perineal procedure, ie **T**hiersch, Altmeirs & Delorme's procedure are perineal procedures.

These procedure do not require laparotomy. The pathology is dealt from below, ie; perineum.

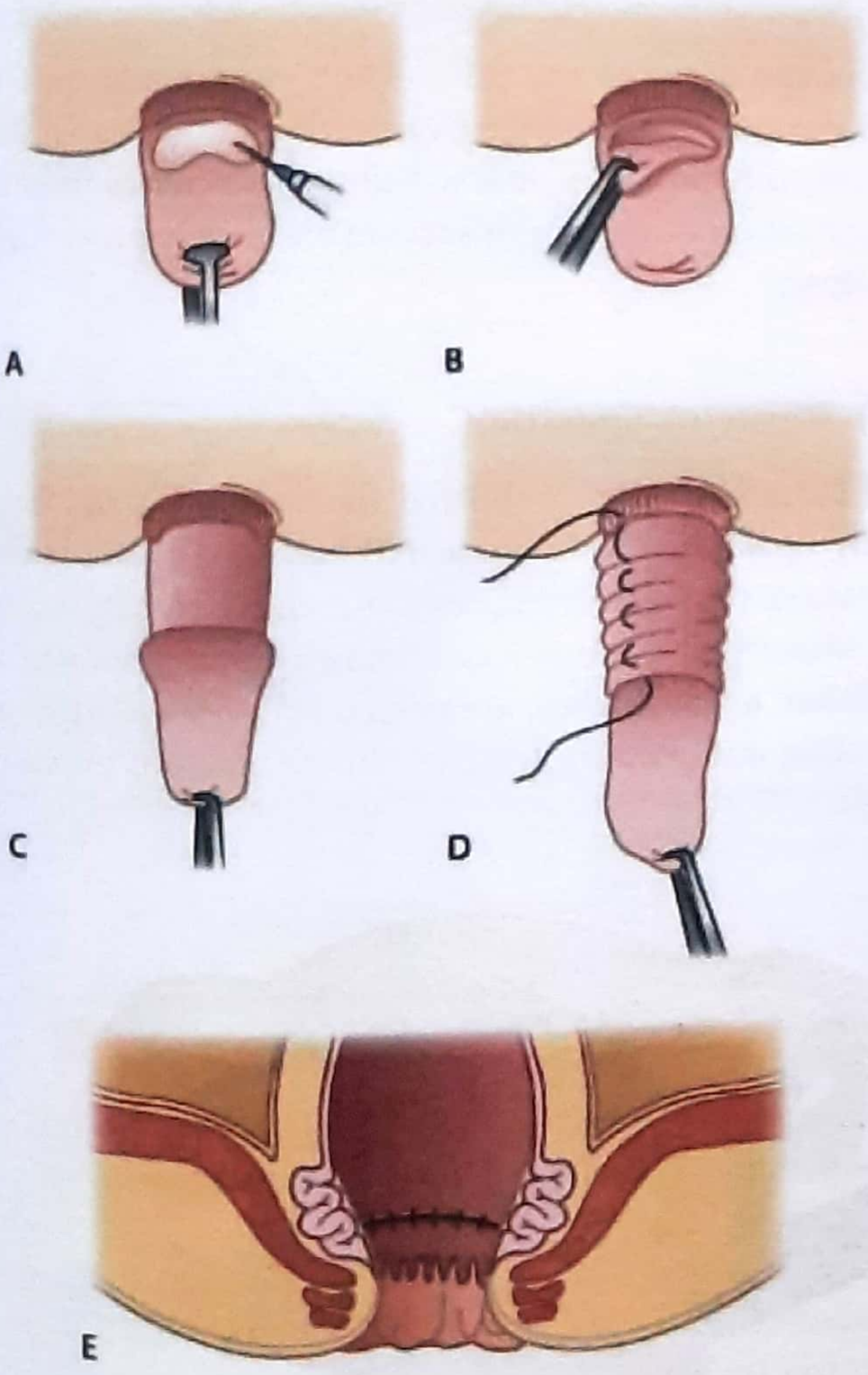

Figure 37.5 : The **Delorme procedure**. The mucosal layer is infiltrated with epinephrine containing solution (A), Incised (B), and stripped off the underlying muscularis (C), Plication of the muscularis propria is performed (D), The operation concludes with an anastomosis between the proximal and distal mucosal edges (E).

(i) Delorme's operation (SGPGI 04)

Delorme's operation consists circumferential removal of mucosa from the prolapsed rectum over its entire length and placing interrupted sutures in the underlying muscle. So that when tied, the muscle is plicated towards the anal canal. This procedure has the effect of reducing the prolapse and creating a ring of muscle within the anal canal, which narrows the orifice and prevents recurrence. (Figure 37.5)

(ii) Thiersch's operation (UP 94)

Thiersch's operation aims to place a steel wire or a silastic or nylon or gracilis muscle around the anal canal. However; it may cause chronic perineal sepsis or anal stenosis; hence it is no longer used. However; *Thiersch's operation is still procedure of choice in elderly individuals who are not fit for long surgical procedure and who have short life expectancy.* (NEET, MANY PGME) (Please see figure 37.6)

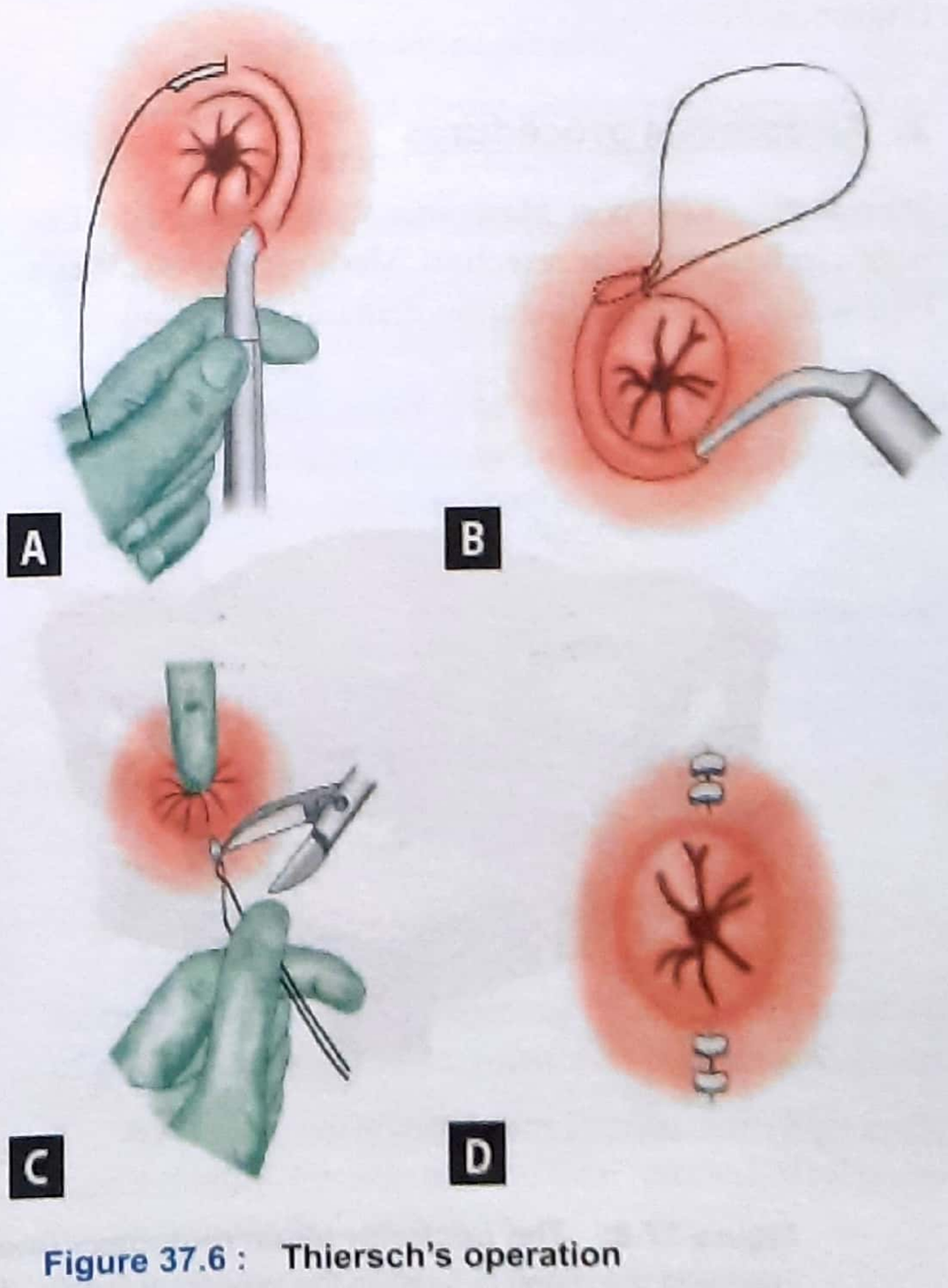

Figure 37.6 : **Thiersch's operation**

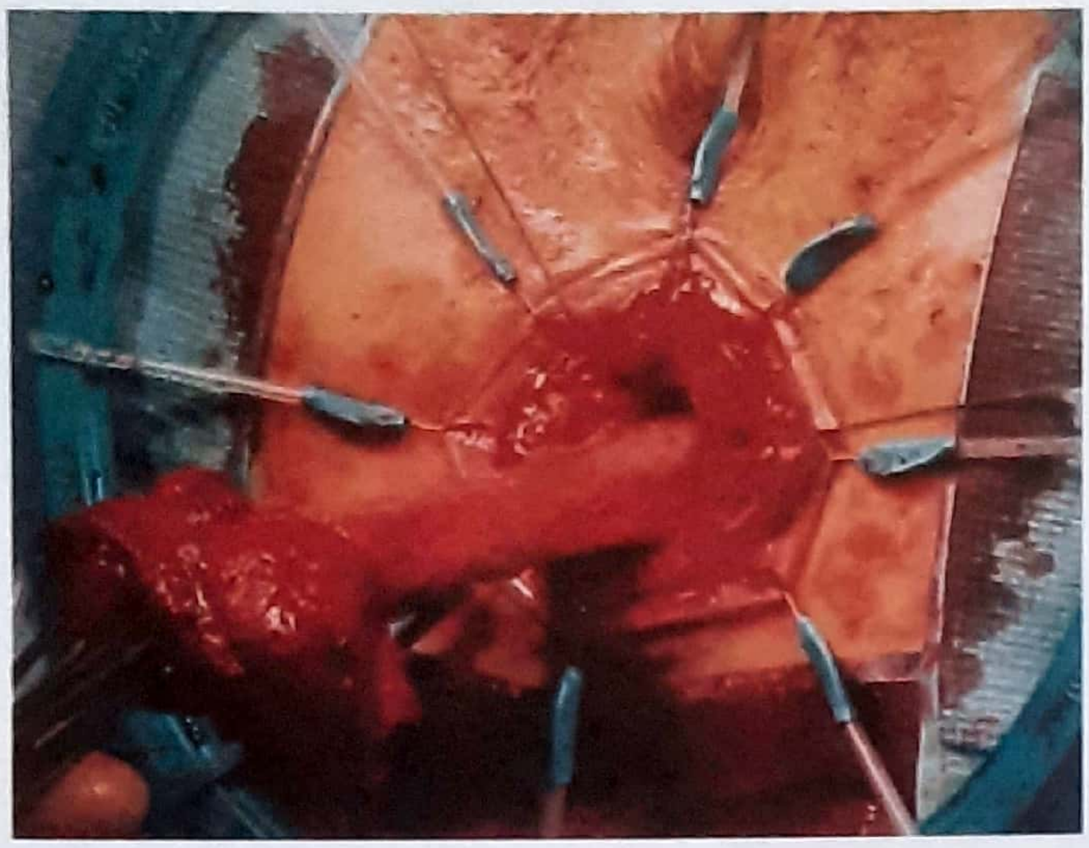

Figure 37.7: The **Altmeir's procedure** or perineal proctectomy. The redundant rectosigmoid colon is resected through a transperineal approach and a hand-sewn coloanal anastomosis is performed.

(iii) Altmeir's operation

In this operation; full thickness of prolapsed rectum with lower part of sigmoid is excised followed by anastomosis of part of the sigmoid to the anal canal from below. (Figure 37.7)

2. Abdominal procedures

Mnemonic: "Low cost Mesh was Well Replaced in Lahore"; ie; Low anterior resection, Mesh rectopecxy, Well's Operation, Ripstein's operation, Lahaut's operation

These procedures require opening of abdominal cavity (laparotomy). After opening abdominal cavity; the rectum is dealt as described below:-

(i) Resection rectopexy (Frykman goldberg procedure, Low anterior resection)

In this redundant sigmoid colon is resected and anastomosis is made between descending colon and rectum, ie; colorectal anastomosis is made. Then rectopexy is done.

For Hindi speakers; When suffix- pexy is used, it means *"chipkana"*. In rectopexy, rectum is fixed to sacrum.

(ii) Well's operation

The operation is very popular. Through an abdominal approach, the rectum is mobilized from the sacrum; a sheet of polyvinyl alcohol sponge is kept behind rectum and is then fixed between the front of the sacrum and the lateral margins of the rectum by interrupted sutures. In due course, this produces marked fibrosis & causes permanent fixation of rectum to sacrum and hence preventing prolapse.

(iii) Ripstein's operation

The rectum is fully mobilized from all sides and held tautly upwards, a 'T' - shaped Teflon sling (5 cm wide) is passed round rectum, and the ends are sutured to the sacral fascia about 5 cm below the promontory. In addition, a few stitches, are passed between the edges of the sling and rectum; which holds the rectum in place. (Figure 37.8)

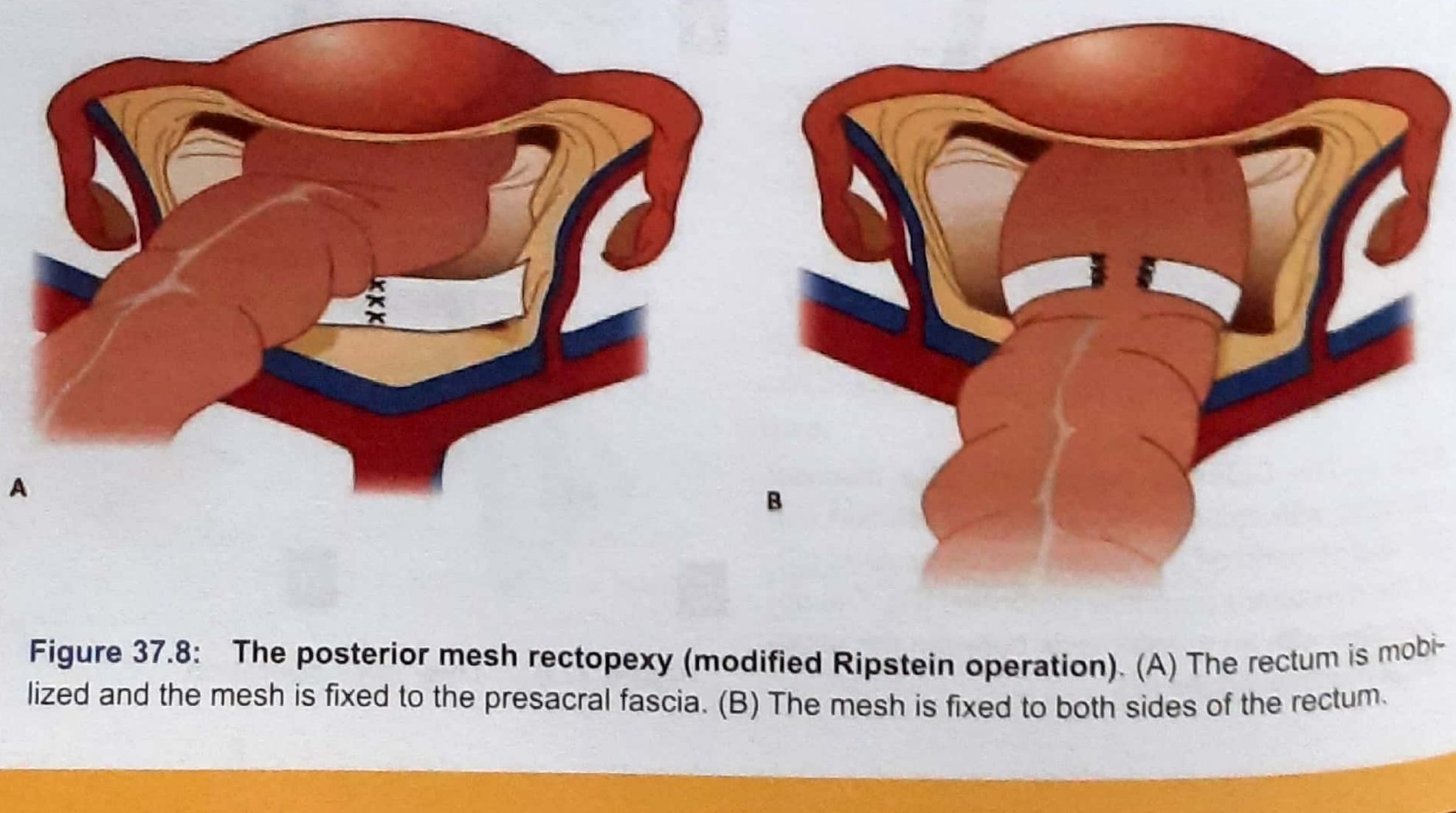

Figure 37.8: The posterior mesh rectopexy (modified Ripstein operation). (A) The rectum is mobilized and the mesh is fixed to the presacral fascia. (B) The mesh is fixed to both sides of the rectum.

Figure 37.9: Ventral mesh rectopexy. The mesh is attached to the anterior rectal wall and the sacral promontory.

(iv) Mesh rectopexy

The principle of this is same as that of well's operation. Only difference is that; in this a marlex mesh is used instead of polyvinyl sponge. (Figure 37.9)

(v) Lahaut's operation

The principle here is to mobilize the distal sigmoid colon and the rectum and then fixing it from sliding, by extra peritonealization through the rectum sheath.

3. Electrical stimulation

Electrical stimulation of the muscles of the pelvic floor and anus is used for rectal prolapse with incontinence. The stimulation is applied by means of electrodes placed in the region of the anus with an implanted receiving aerial. The power is supplied through a radiofrequency link from a source placed above the skin overlying the aerial. The continuous electrical stimulation causes contraction of the muscle to maintain increased tone to preserve continence and hold the prolapse in place. Please see box 37.1, once again on page 679.

*****

SOLITARY RECTAL ULCER SYNDROME
(MUCOSAL PROLAPSE SYNDROME)

- It is a benign condition, which takes the form of an ulcer on the **anterior rectal wall**, however many times ulceration may not present. (only 50% have ulcer)
- The importance of this condition is because, **it must be differentiated from an ulcerative rectal carcinoma** or inflammatory bowel disease particularly Crohn's disease.
- MC in women aged 20-40 yrs.
- Persistent trauma by sexual malpractice is suggested explanation to this condition.
- It could also be due to a combination of internal intussusception or **anterior rectal wall prolapse** or as a result of increase in intra rectal pressure.
- The diagnosis is confirmed by histological examination, which shows *subepithelial collagen deposits.*
- **Histological features** are *(AIIMS 07)*
  - Mucosal hyperlasia
  - Fibrosis of Lamina propria
  - Distortion of Crypt architecture without dense inflammation of Lamina propria
  - Thickened and disorganised muscularis mucosa
- The condition although benign, is often difficult to treat. Bowel training is helpful.
- Symptomatic relief may sometimes be achieved by an abdominal rectopexy. In rare cases rectal excision may be required. *(PGI DEC 07)*

The term solitary rectal ulcer is a misnomer because many times multiple ulcers are present. (10-15% cases).

*****

BENIGN TUMOURS OF THE RECTUM

Rectum along with the sigmoid colon is a frequent site of polyps. Polyps have a tendency to become malignant.

A *sessile polyp of more than 2cm has very high malignant potential.* For this reason; total removal of all polyps are recommended. *(MANY PGME)*

Polyps relevant to the rectum are (MANY PGME)

1. Juvenile polyp
2. Adenomatous polyp
3. Villous adenoma
4. Familial adenomatous polyposis

Above all conditions have been discussed in detail in chapter 34, page no. 624.

Note - In villous papillomatous polyp of rectum, K^+ is lost causing hypokalemia. (NEET)

*****

CARCINOMA OF RECTUM

Sixty percent of colorectol cancers are situated at the rectum and rectosigmoid region (MANY PGME). One third of the cancers of *large bowel* and about 90% of *rectal carcinoma* are within the reach of digital examination and 60% of the growth can be seen by sigmoidoscopy. After stomach the rectum is the next most common site for gastrointestinal tract cancer.

Growths are evenly distributed along the whole length of the rectum. One third in the upper one third, another one third in the middle third and rest in the lower third of the rectum.

Origin (PGME MANY TIMES)

1. Adenoma-Carcinoma sequence

It is believed that most colorectal carcinoma starts as an adenoma and due to series of genetic change, which progressively change the adenoma (which is not dysplastic) to one that show severe dysplasia and finally into a carcinoma (adenoma → carcinoma sequence) (UP 05) (Figure 34.18 page 626)

2. Genetic mutation in colorectal carcinogenesis

The various genes linked to colorectal carcinogenesis has been identified and can be classified in four categories.

(i) *Proto-Oncogenes:* Includes *K-ras, srs* and *cmy* genes.

(ii) *Tumour suppressor genes:* are APC genes, P53, MCC genes and DPC4 gene.

(iii) *DNA mismatch repair genes:* hMSH-2, MLH1 genes.

(iv) *The modifier gene:* include COX-2 and CD-44 gene of all these ***K-ras*** gene is the mutated commonly mutated oncogene.

Etiological factors of colorectal carcinoma has been discussed in chapter 34, under topic colon cancer; as they are common for both (page no: 625)

Pathological type

1. **Annular (infiltrating) variety** : This variety is common at rectosigmoid junction. It presents with constipation and intestinal obstruction.
2. **Ulcerative variety:** This variety can occur any where in rectum and tumour has raised, rolled out edges.
3. **Polypoidal (cauliflower) variety:** This is more common in roomy ampulla of the rectum.
4. **Colloid variety:** This is rare. The tumour contents are gelatinous due to large number of mucin producing cells & is more malignant variety.

Histological Grading

Histologically, majority of carcinoma rectum are *adenocarcinoma.* (MANY PGME) They may be well differentiated, moderately differentiated or poorly differentiated (anaplastic). *Prognosis of rectal carcinoma is best assessed by histological grading.* (MANY PGME)

Grade :		Prognosis
Low grade	Well differentiated (11%)	Good
Average grade	Moderately differentiated (64%)	Fair
High grade	Poorly differentiated (25%)	Poor

Poorly differentiated tumour means very poorly resembling the normal cell of that organ ie; more malignant

Spread of Carcinoma Rectum

1. Local spread

- Local spread occurs circumferential, rather than in longitudinal direction.
- It takes 18 months to 2 years for an annular growth to encircle the whole lumen of rectum.
- After the muscle coat has been penetrated, the growth spreads into the surrounding fat, but is still

limited by perirectal fascia (fascia of denonvillier).

- Anterior extension of rectal cancer involves prostate, seminal vesicle and bladder base in males and vagina and uterus in females, resulting in fistula formation between two organs.
- Posteriorly sacral plexus get involved in late cases and causes sciatica.
- In either sex lateral extension may involve ureter; resulting in hydronephrosis. Down ward spread is rare.

2. Lymphatic spread

- The lymphatic spread from carcinoma rectum, *above the peritoneal reflection* occurs almost exclusively in upward direction.
- From below the peritoneal reflection, the most drainage is in upward direction.
- *Virtually no lymphatics of the rectum drain downward.* (MAY BE FUTURE PGME Q)

3. Hematogenous spread

As a rule hematogenous spread of colon cancer occur late. Anaplastic tumours of the young adults are more prone to spread by blood stream. The principle sites for blood borne metastases are liver (33%), lungs (22%) and adrenals (11%).

4. Peritoneal dissemination: results in ascites, carcinomatous nodule over peritoneum.

Staging

As a rule carcinoma of rectum does not metastasize early (MANY PGME). Duke's classified carcinoma of the rectum into following stages.

Dukes Staging (Figure 37.10) (UP 07)

Stage A: Growth is limited to the rectal wall (15%); prognosis excellent.

Stage B: Growth is extended to the extra rectal tissues, but no metastasis to the regional lymph nodes (35%); prognosis reasonable.

Stage Cl: Secondary deposits present in the regional lymph nodes (Nodes involved by cancer).

Stage C2: Nodes accompanying the supplying blood vessels; prognosis bad.

Stage D: Widespread metastases.

Prognosis *(as per dukes staging)*

Dukes A - 5 year survival is 90-100%

Dukes B - 5 year survival is 50-80%

Dukes C - 5 year survival is less than 50%

Clinical feature

1. Bleeding

- Bleeding is the **earliest** and **most common** symptom. (MANY PGME)

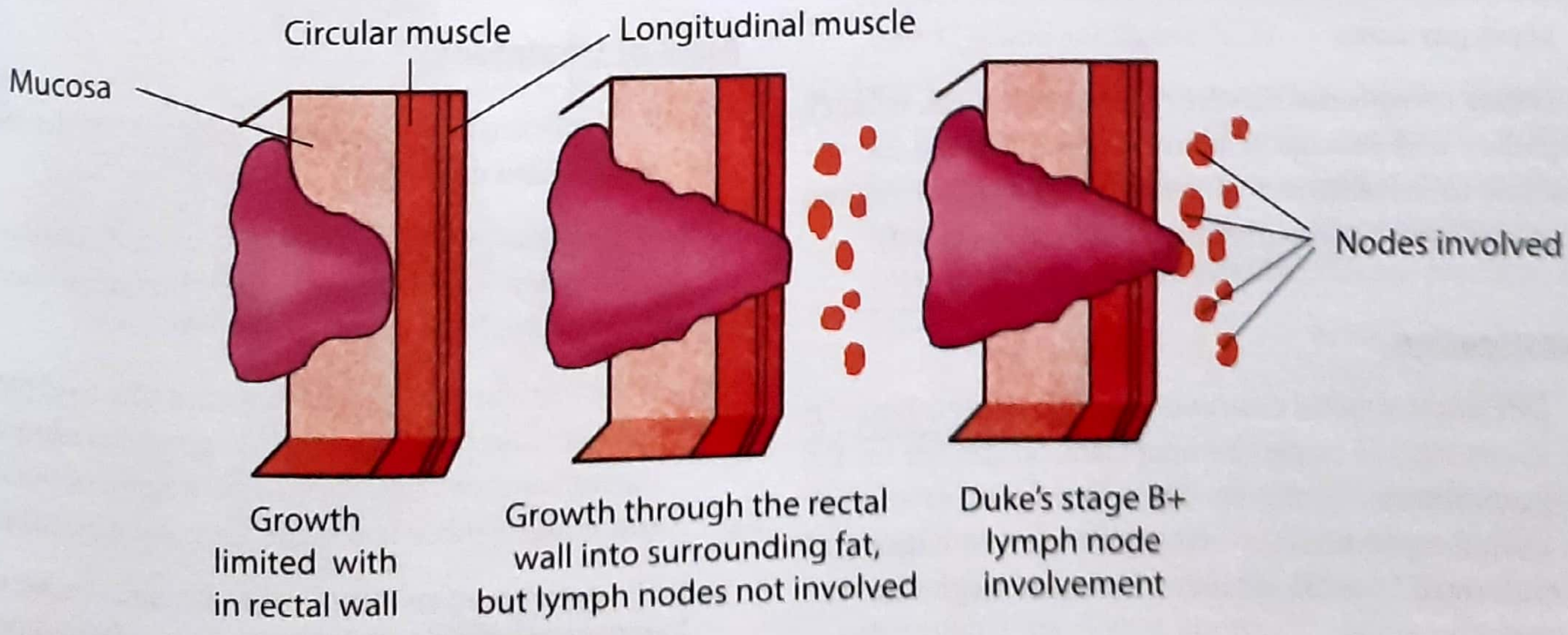

Figure 37.10: **Dukes classification** of carcinoma rectum

- Bleeding may be slight or profuse and usually of fresh blood. Which may be seen at the end of defecation or noticed accidentally .
- Patient may have associated secondary hemorrhoids.
- The bleeding may be mixed with mucus at times.

2. Altered bowel (stool) habit

(i) ***Tenesmus:*** It is painful straining to empty the bowels without resultant evacuation. It is almost invariably present in tumours of the lower half of the rectum, Patient often describes that; I feel, I want to go; but nothing happens. (Jata hu par hoti nahi hai)

(ii) ***Increasing constipation:*** which may require increasing doses of laxatives to empty the bowels.

(iii) ***Sense of incomplete defecation.***

(iv) ***Passage of blood and mucus:*** which gets collected above the annular growth at the pelvirectal junction, especially in the early hours (dawn) of the day called *"early morning spurious diarrhea"* (PGME)

Spurious, means false, because content of stool is not feces, but mucus and blood retained in rectum secreted by rectal mucosa during night whole patient is sleeping.

3. Pain

- Pain is a late symptom.
- It may be colicky due to some degree of intestinal obstruction.
- Severe pain may be present due to local erosion into prostate/bladder, or due to invasion into sacral plexus.

4. Weight loss: is suggestive of metastases to liver.

5. Mass per anus

6. Other symptoms may be recurrent dysuria, urinary frequency and passage of blood or mucus from the vagina due to involvement of urinary bladder and vagina; eg. recto-vesical or recto-vaginal fistula respectively.

Investigation (UP 08)

1. *DRE (digital rectal examination)/PR examination:* In about 90% of cases; the neoplasm can be felt on PR examination. It can be felt as hard, flat or oval or encircling tumour or ulcer with everted edges and indurated base. Blood may be present on glove of examining finger.
2. *Proctoscopy:* The growth appears as an ulcer with everted edges. A biopsy is taken and sent for histopathological examination to confirm the diagnosis.
3. *Sigmoidoscopy:* It is done for growth in upper rectum, near rectosigmoid junction. Biopsy should be taken to confirm the diagnosis. **Flexible sigmoidoscope can visualise a lesion upto 60 cm from anal varge.** (NEET)
4. *Colonoscopy:* It is required in all patients to exclude coexisting tumour, be it an adenoma or carcinoma.
5. *Barium enema:* Double contrast medium is preferable. (See figure 55.1 on page no 994)
6. *Abdominal Ultrasonography:* It is required to detect liver secondaries.
7. *Trans rectal Ultrasonography (THUS):* This is done to know the level of penetration of adjacent structure by tumour.
   - Detect pararectal lymph node status.
   - Invasion of adjacent structures.
8. *CT Scan:* This helps to known the extension of tumour and lymph node status. CT Scan of abdomen is more accurate for liver metastases.
9. *MRI:* More recently MRI Scan has become **most useful investigation for rectal carcinoma**. It can accurately tell about extent of invasion of rectal wall by tumour as well as lymph node status. (AIIMS NOV 04) Best for staging.

Treatment

- Treatment policies depend on fitness of patient and extent of spread of the tumour.

Aims of treatment

(i) Radical excision of rectum, together with the mesorectum and draining lymph nodes.

(ii) *Widespread metastases is not a contraindication for surgery** in fact rectal excision is often the best means of palliation, (MANY PGME, AIIMS, AI, PGI)

(iii) If the tumour is locally advanced, a course of preoperative radio therapy should be given. It reduces the size of tumour (called as down staging of tumour) and make it more amenable for radical excision.

(iv) *The presence of solitary liver metastatic nodule does not necessarily rule out the possibility of resection.* (PGI JUNE 05, MANY PGME)

[Hepatic lobectomy or segmental liver resection is done for liver metastases]

(v) When a rectal excision is possible, the aim should be to restore gastrointestinal continuity by making colo+rectal (remainimg) or anal anastomosis, and fecal continence by preserving the anal sphincter.

Preoperative preparation

- Mechanical bowel preparation- It has been described in chapter 34, page 627-628.
- Prophylactic antibiotics.
- Correction of anemia and electrolyte abnormality.

A. Operative Procedures

Operative procedure depends upon location of the tumour in the rectum and its distance from anal verge *(PGI JUNE 02)*

Friends! read this very carefully it is a very important topic. I have tried to make it easier. Before going in details note that length of rectum is about 18 cms.

1. Carcinoma of upper 2/3 of rectum

(Carcinoma situated above 6 cm from anal verge)

Low-anterior resection

The operation of choice for carcinoma rectum of upper 2/3 is ***low anterior resection*** *(NEET, AIIMS FEB 97, PGL 90, AIIMS 92)*

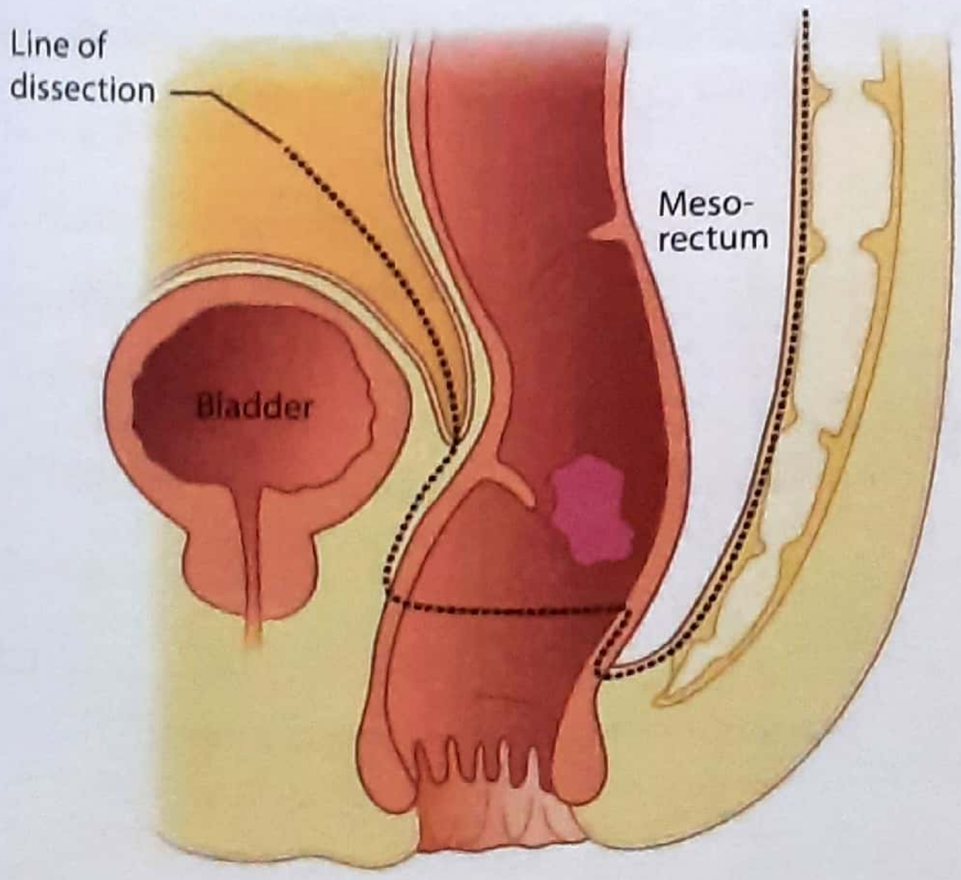

Figure 37.11 : Low anterior resection for cancer of the upper rectum (note line of dissection)

- **The anterior resection** is abbreviation for more correct term *anterior procto+sigmoidectomy, with descending colo+ rectal anastomosis.* (Figure 37.11)

The term **low anterior resection** indicates the operation entails resection of the rectum, below the peritoneal reflection through an abdominal approach and making an anastomosis between descending colon and remaining part of rectum.

In this operation the anal sphincters are not resected, because they are not involved is most of the case. This is because, lymphatic spread of rectum is almost always in upward direction and never in down ward direction. Since the anal sphincters are not resected in this operation; this is a sphincter saving surgery and fecal continence is maintained.

Also note

The **high anterior resection** indicates resection of the proximal rectum or rectosigmoid above the peritoneal reflection. [**Note:** *Upper 2/3 of rectum is covered by peritoneum anteriorly].*

2. *Carcinoma of Distal 1/3 of rectum*

(Carcinoma situated with in 6 cm from the anal verge)

For this **APR** (?) is done *(AIIMS 97, AIIMS JUNE 01, KERALA 94, AI 94)*

1. Abdomino perineal resection (APR) *(VERY IMP):*

- This is also known as **Mile's procedure.** In this operation complete excision of the rectum and anus by simultaneous dissection through the abdomen (by one surgeon) and perineum (by other surgeon) with closure of the perineum; followed by creation of permanent end sigmoid colostomy. Kindly see key box 37-2 and see figure 37.12.
- An abdominal-perineal resection (APR) is indicated in advanced lower 1/3 rectal carcinoma that has involved the anal sphincters or when the tumour is too close to the sphincters or in whom sphincter preserving surgery is not possible. Please read key box 37.2.

2. Local excision

- Local excision of rectal cancer is an excellent operation for a small cancer in distal rectum, that has penetrated into muscularis. This is accomplished through a trans anal approach and usually involves

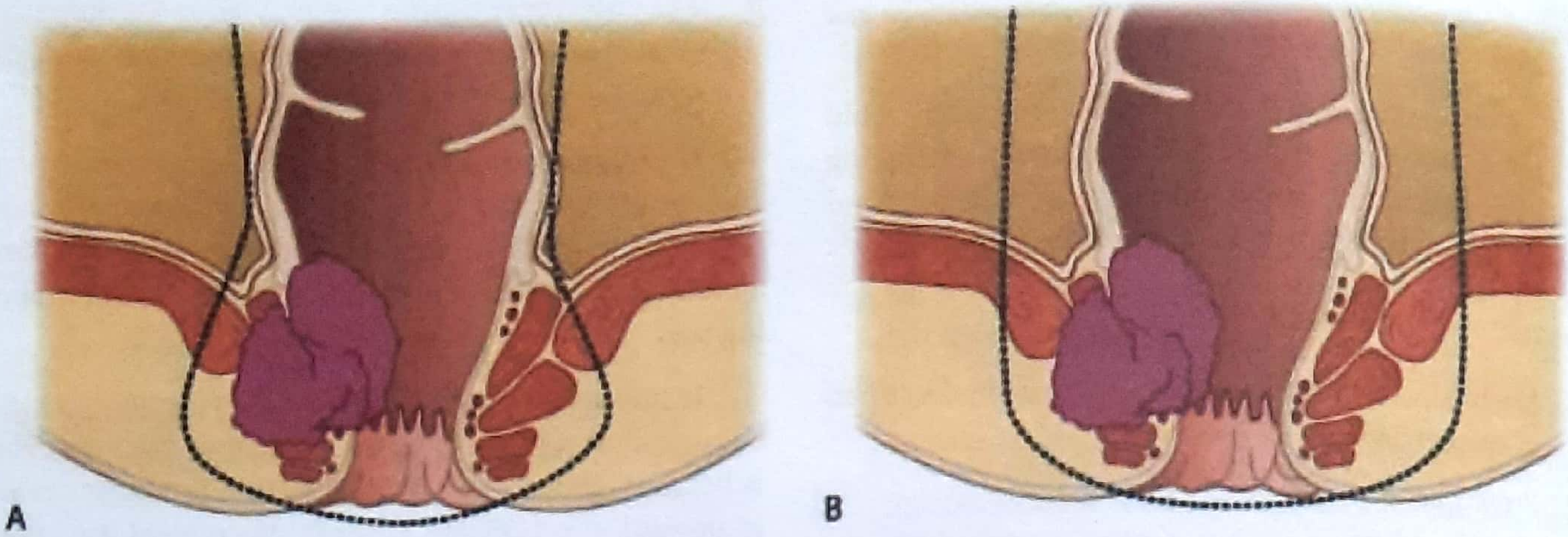

Figure 37.12 : (A) Conventional abdominoperineal resection. The line of the dissection tends to cone towards the rectum. (B) Cylindrical abdominoperineal resection with en bloc removal of the levator ani.

excision of the full thickness of the rectal wall underlying the tumour; followed by reapproximation of rectal wall.

- This *operation is indicated for mobile tumours that are less than 4 cm in diameter, that involve less than 40% of the rectal wall circumference, and that are located within 6 cm from the anal verge.* These tumours should be stage T1 (limited to submucosa) or T2 (limited to muscularis) with well or moderately differentiated histology and no vascular or lymphatic invasion.
- Surgical transanal resection of rectal lesions has long been popular as a form of sphincter-sparing surgery.
- This technique has now largely been supplanted with the technique of TAMIS, whereby standard laparoscopic instruments and an access port similar to that used for single-port laparoscopy is used in the anal canal to allow for safe excision of lesions above the level of the very distal rectum.

KEY BOX 37.2

Abdomino-perineal resection [APR-Mile's procedure]

Abdominal dissection (By 1st surgeon)

↓

Proximal Rectum and sigmoid colon are mobilized through an abdominal incision

↓

Excision of Rectum

↓

Later a sigmoid end colostomy is fashioned on lower left side of anterior abdominal wall.

Perineal dissectino (by 2nd surgeon)

↓

This is done up to the level of levator ani muscles

↓

Includes excision of anus, anal canal, anal sphincters and distal rectum

↓

Then suture closure of perineum is done

NOTE: Mobilization: when used in operative surgery means a process of making a fixed part, movable

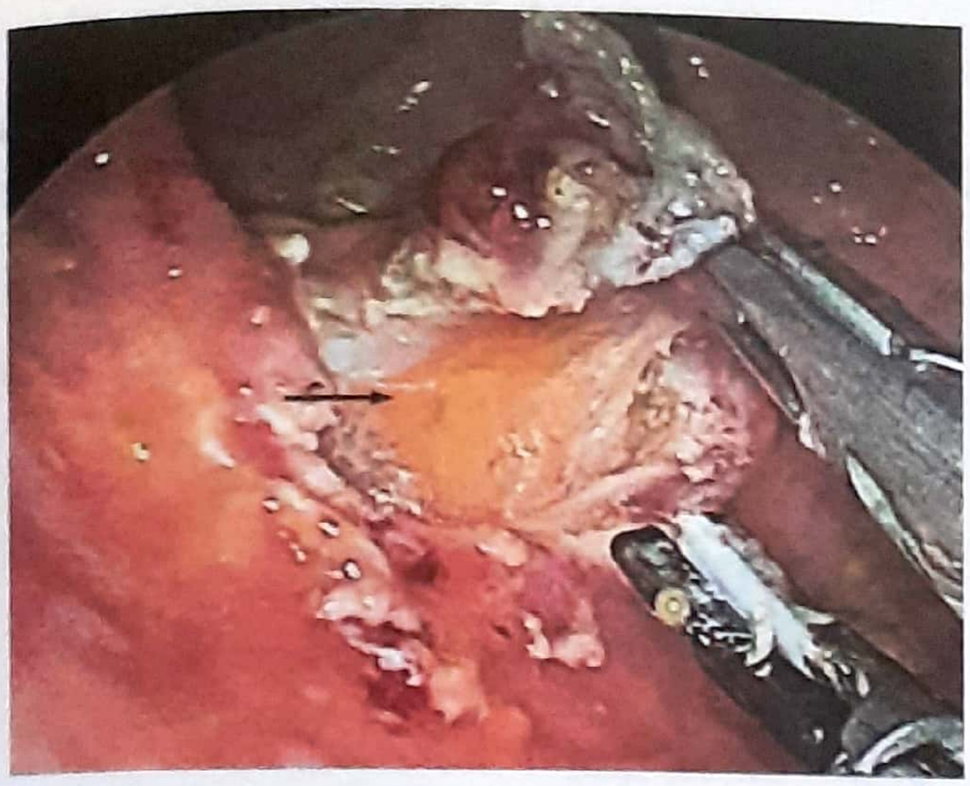

Figure 37.13 : Rectal cancer

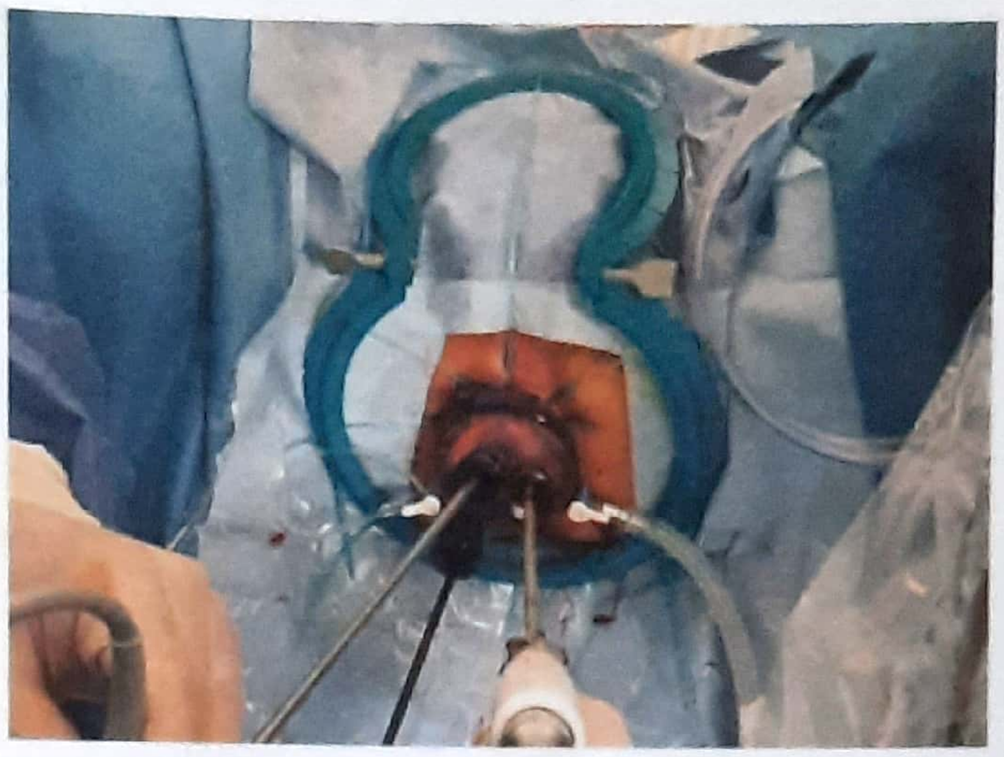

Figure 37.14 : Transanal total mesorectal excision (TaT TME).

3. Transanal total mesorectal excision (TaTME)

- Recently, a new emerging technique has been proposed when approaching sphincter-preserving procedures in order to facilitate the detachment of the rectum and to improve the vision in the narrow pelvic space. This approach utilizes transanal platforms also used for TAMIS. The distal rectum is closed with a purse string and is divided with a harmonic scalpel. (Figure 37.14)
- The transanal TME technique has been shown to be oncologically safe with a low rate of involved circumferential margins and good quality of mesorectal excision. After the operation, all patients show a decrease of resting sphincter pressures, but the squeeze pressures are unchanged and functional results are acceptable.

B. Inoperable Cases

Palliative colostomy

Locally advanced growths with gross infection of the neoplasm and with intestinal obstruction, a temporary loop colostomy is done on anterior abdominal wall on the left iliac fossa. This relieves obstruction.

Hartmann's operation

This is the procedure of choice for old and feeble patients (MANY PGME), who may not be able to tolerate relatively long and complicated, either anterior resection or abdomi-no-perineal resection.

Through a lower abdominal incision, the abdomen is opened and the rectum is excised, the lower end of the rectum is closed and a sigmoid colostomy (end colostomy) is performed. Please see figure 37.15.

C. Role of Radiotherapy in carcinoma colon

- As a palliative measure for inoperable cases.
- For local recurrence
- Radiotherapy reduces the size of rectal carcinoma if given preoperatively, making tumour operable. This reduction of tumour invasiveness by preoperative radiation is known as down staging of tumour.

D. Role of Chemotherapy in Carcinoma Colon

- The drug used most frequently used is **flurouracil** (5-FU) (PGME). Systemic folinic acid (leucovorin) has an adjuvant effect when used in combination with 5-FU.
- Chemotherapy reduces incidence of metastasis and prolongs survival-. It destroys malignant cells which are released into circulation during manipulation of tumour done during surgery.
- A combination of 5-FU and levamisole (nonspecific stimulator of immune process) is effective in Dukes class C.
- 5-FU and FA are combined with oxaliplatin in the FOLFOX protocol. In the CAPOX (or Xelox) regimen, oral capecitabine is used instead of 5-fluorouracil folinic acid (5-FUFA)
- Possible chemotherapy regimens are as follows:

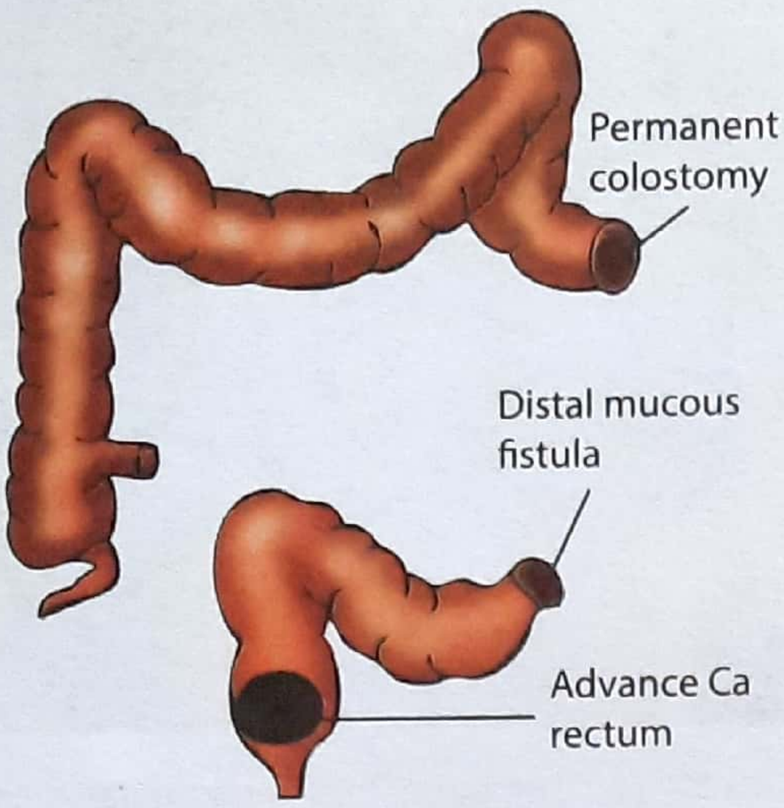

Figure 37.15: Hartmann's operation

1. Anti-EGFR antibodies (panitumumab, cetuximab) can be used in pan-Ras wild-type and BRAF wild-type neoplasia. The mutational analysis can be per formed on the primary tumor but also preferably on the metastatic tumor
2. The standard treatment in BRAF-mutated metastatic disease is the administration of FOLFOXIRI (oxaliplatin + irinotecan + 5-FUFA) and bevacizumab. BRAF mutated patients have the worst prognosis.
3. If the primary tumor is right sided, anti-EGFR antibodies given in addition to chemotherapy (FOLFOX [oxaliplatin + 5-FUFA] or FOLFIRI [irinotecan + 5-FUFA]) are not superior to chemotherapy alone in first-line treatment: therefore, they are usually not administered in this phase. Doublets (FOLFOX or FOLFIRI) or the triplet FOLFOXIRI in fit patients, in combination with anti–vascular endothelial growth factor antibody (bevacizumab), could be the best choice.
4. In left-sided primary tumors, the addition of cetuximab or panitumumab to FOLFOX/FOLFIRI could be the first line of treatment. However, also in this case, the use of FOLFOXIRI can be considered.
5. In older or unfit patients, unable to tolerate doublets, capecitabine with bevacizumab is an appropriate treatment.

*****

BLEEDING PER RECTUM

When the source of bleeding lies ***distal to duodenojejunal flexure,*** it is referred to as lower gastro intestinal tract bleeding. The bleeding may be fresh, altered or occult.

Lower gastrointestinal tract bleeding can be divided into 3 groups.

- Patients with minor bleeding (occult)
- Patients with slow bleeding (moderate)
- Patients with rapid bleeding (severe)

A. Occult blood loss

This is that which is not apparent to necked eye but is detected by microscopic stool examination. About 10-50 ml of blood is necessary to have stool occult blood test positive.

B. Chronic bleeding

This is manifested by recognizable blood loss either altered or fresh. Patient is hemodynamically stable. The patient may be anemic with or without systemic changes.

C. Acute bleeding

This is defined by rapid, severe bleeding per anus. Patient becomes hemodynamically unstable, (ie; hypotension and tachycardia)

Causes

Causes of bleeding per rectum can be divided into two main groups: Local causes and general causes:

(A) Local causes

1. Anal canal

- Hemorrhoids
- Anal fissure
- Fistula- in - ano
- Mucosal prolapse
- Crohn's disease of anal canal
- Carcinoma of anal canal

2. Colorectal

- Rectal prolapse
- Diverticular disease (M/C cause)
- Polyps

- Ulcerative colitis
- Crohn's disease
- Angiodysplasia
- Carcinoma

3. *Small intestine*

- Intussusception
- Crohn's disease
- Meekel's diverticulum
- Tumours

(B) General cause

- Blood dyscrasia
- Drugs (NSAIDS and Steroids)
- Chronic renal failure
- Chronic liver failure

Character of bleeding

(A) Bleeding with pain

- Anal fissure
- Fistula-in-ano
- Carcinoma of anal canal
- External hemorrhoids
- Ruptured perianal hematoma
- Ruptured ano rectal abscess

(B) Bleeding with out pain

1. *Blood alone* - Polyp, Diverticular disease.
2. *Blood after defecation*- Hemorrhoid (splash in a pan)
3. *Blood mixed with mucus:*- Ulcerative colitis, Crohn's disease, Intussusception, Ischemic colitis.
4. *Blood mixed with stool* - Carcinoma colon

Management

The management of rectal bleeding is based on the cause. These have been discussed in respective topics in this book.

KEY POINT

- Most common cause of Lower GI hemorrhage in elderly is Diverticulosis.
- Most common cause of Lower GI hemorrhage in elderly in India- Colorectal carcinoma.
- Most common cause of Lower GI hemorrhage in adults- Hemorrhoid.
- Most common cause of Lower GI hemorrhage in Children- Rectal polyp.

*****

Sample Questions for Prof Examination

1. Mention the cause of bleeding per rectum. Discuss the diagnosis and management of carcinoma of lower third of rectum.
2. What are the cause for bleeding per rectum. Describe the management of carcinoma of lower third of rectum.
3. What are the common cause for bleeding from the rectum?
4. Write short notes on rectal prolapse. How will you manage a case of partial rectal prolapse.

38 The Anus and Anal Canal

Contents

- Surgical anatomy
- Pilonidal sinus
- Post anal dermoid
- Anal fissure
- Hemorrhoid
- Fistula in ano
- Pruritus ani
- Perianal abscess
- Proctalgia fugax
- Carcinoma of anal canal

SURGICAL ANATOMY

- The anal canal is the terminal part of the large intestine. It is situated below the level of the pelvic diaphragm. It lies in perineum (anal triangle) in between the right and left ischiorectal fossa.
- **The anal canal is 3.8cm (38mm) long** *(MANY PGME) and* extends from the anorectal junction to the anal verge.
- Except during defecation, lateral walls of rectum are kept in apposition by levator ani muscle.

Interior of Anal Canal

The interior of anal canal shows many important features and can be divided into three parts. Please see figure # 38.1 & 38.2.1 & 38.2.2.

1. Upper part (mucous)

- This part is *about 15mm long.* It is lined by mucous membrane and is endodermal in origin. The mucous membrane show 6 to 10 vertical folds: these folds are called as the anal columns *of Morgagni.* (fig. 38.1)
- The lower ends of the anal columns are united to each other by short transverse folds of mucous membrane. These folds are called the anal valves. The anal valves together form a transverse line that runs all around the anal canal. This is *pectinate line.* (fig. 38.1)

2. Middle part (transitional zone or pecten)

The *next (middle) 15 mm* of the anal canal is also lined by mucous membrane, but anal columns are not present

KEY BOX 38.1	
Epithelial lining of anal canal *(PGME MANY TIMES)*	
Upper part :	Stratified columnar
Middle part :	Stratified squamous without sebaceous and sweat glands.
Lower part:	Stratified squamous with sebaceous and sweat glands.

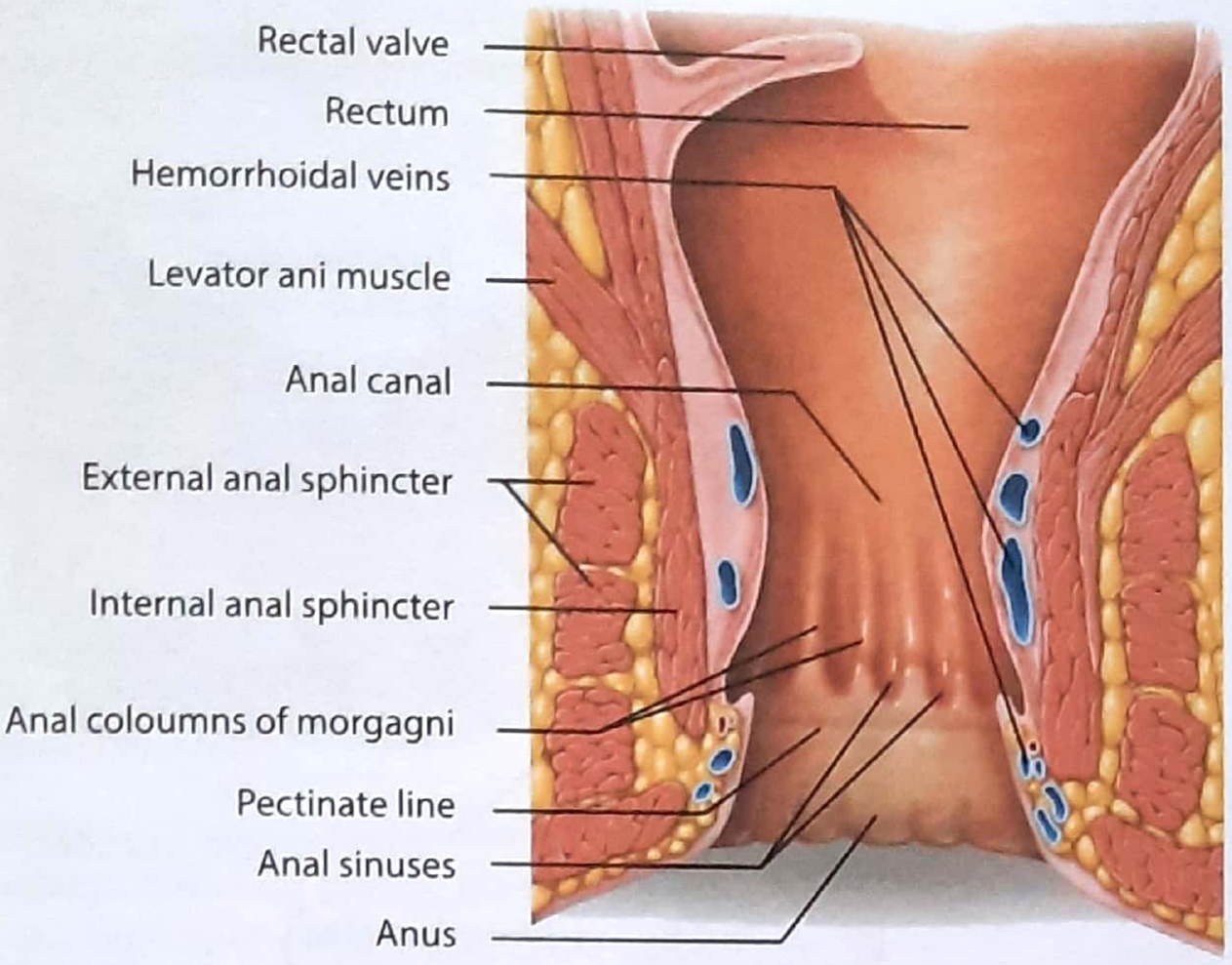

Figure 38.1: Anatomy of anal canal

here. The mucosa has a bluish appearance, because of a dense venous plexus; that lies between it an the muscle coat. This region is referred as transitional zone or pecten. The lower limit of the pecten often has a whitish appearance because of which, it is referred as the *white line of hilton*.(*fig.* 38.2.2)

3. Lower part (cutaneous)

It is about *8 mm long* and is lined by true skin, containing sweat and sebaceous glands. Please see box 38.2.2 page 694.

Anal Sphincter

1. Internal anal sphincter

- It is *thickened continuation of circular muscle layer of the rectum.* (AIIMS 79, DELHI 96)
- It is *involuntary* in nature. (MANY PGME)
- It surrounds the upper three fourth (30 mm) of anal canal extending from upper end of the canal to the white line of hilton.

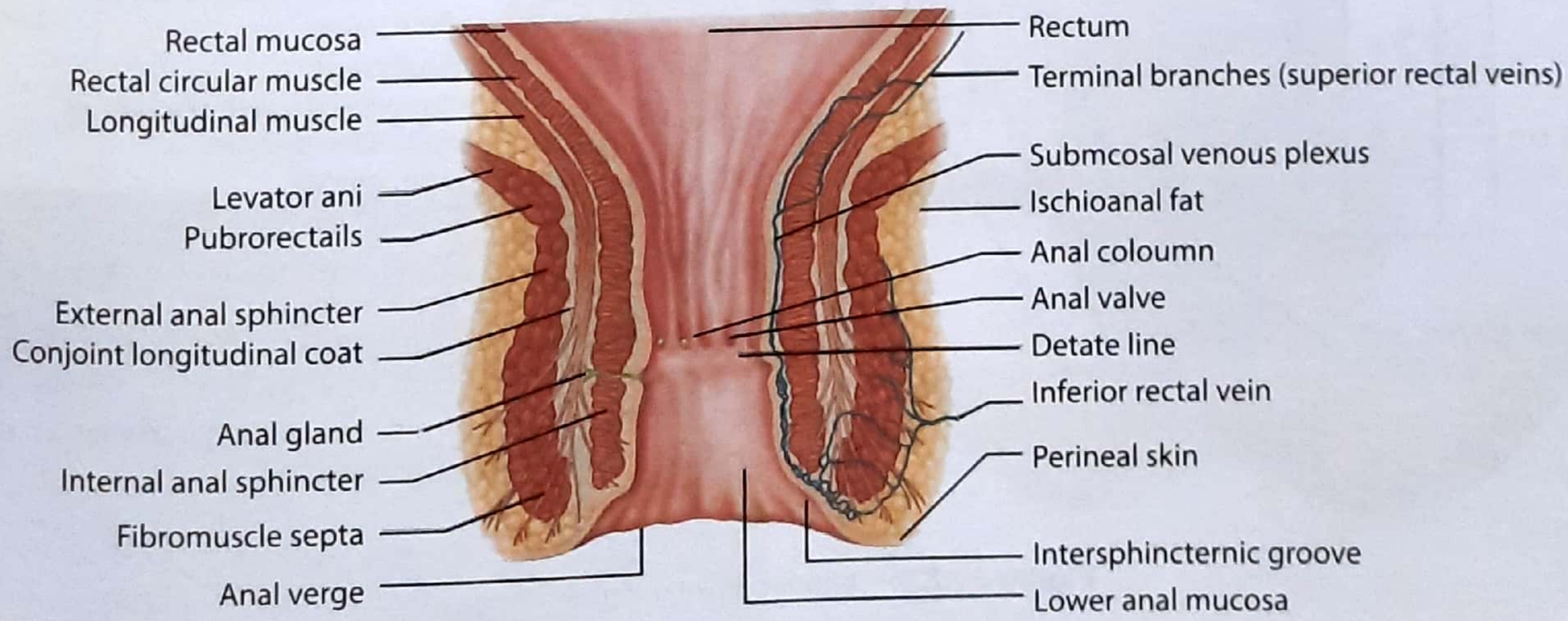

Figure 38.2.1: Interior of anal canal

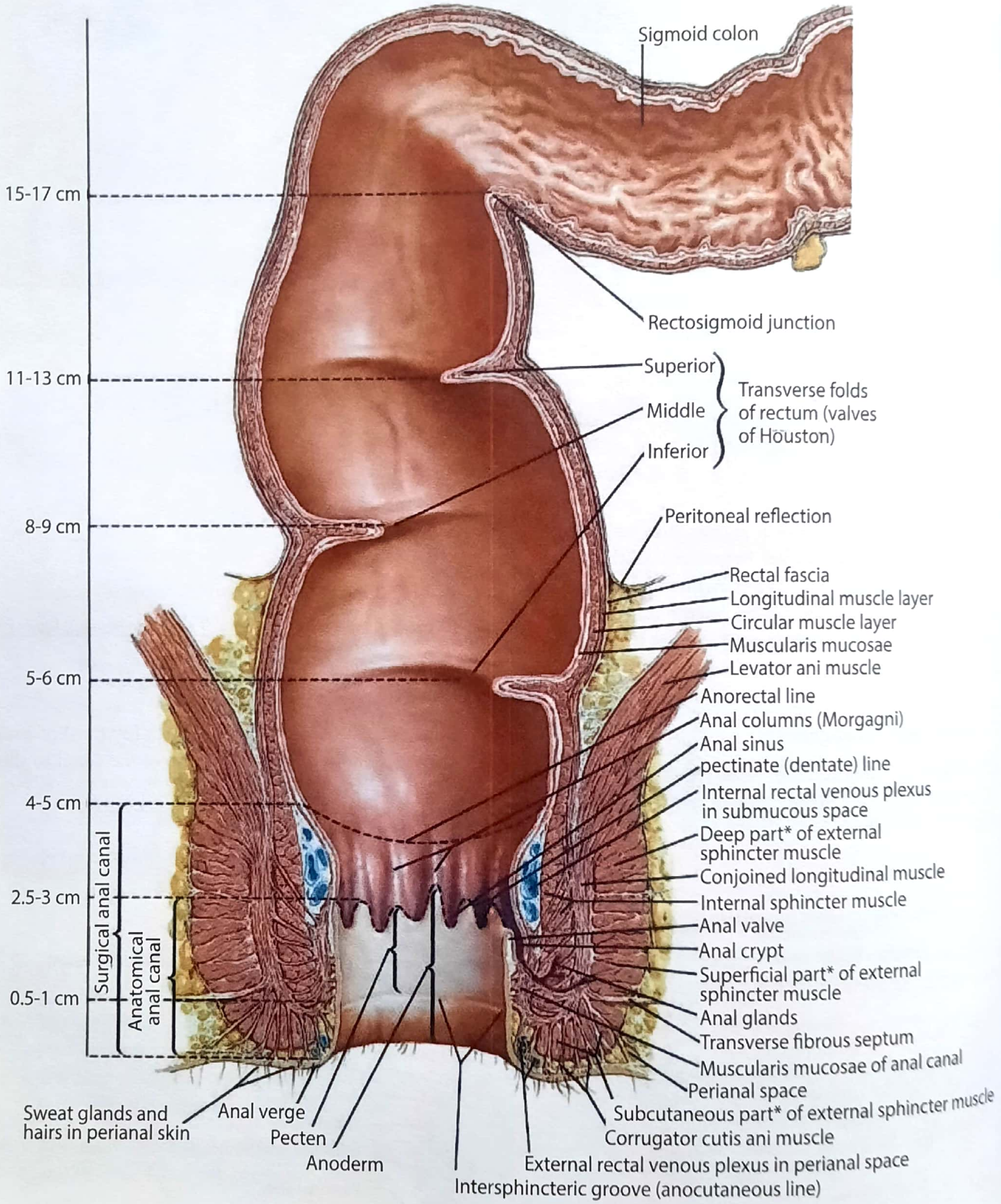

Figure 38.2.2: Interior of anal canal

- Spasm and contracture of this muscle play a major role in fissure-in-ano and other anal disease.

2. External anal sphincter

Formerly subdivided into deep, superficial and subcutaneous portion is now considered to be one muscle.

- The fibres surround the lower part of the internal sphincter and are inserted anteriorly onto the perineal body.
- Unlike the pale internal sphincter muscle, which is involuntary the *red external sphincter is composed of voluntary (somatic) muscle.* (MANY PGME)
- Between the internal (involuntary) sphincter and the external (voluntary) sphincter muscle, there is a potential space; the *inter-sphincteric plane*. This is an important site for infection.

Anorectal Ring

This is a muscular ring present at the anorectal junction, and in **formed by the fusion of:**

1. Puborectalis muscle,
2. Deep part of external sphincter and the
3. Internal sphincter. (Mnemonic = DIP)

Of all these muscles *puborectalis is most important muscle responsible for rectal continence.* (AP 86, PGI 86, AIIMS 87, KERALA 88)

- Puborectalis plays a key role in maintaining the angle between the anal canal and is essential for preservation of continence, (IMP. POINT)
- Surgical division of anorectal ring results in fecal incontinence. Please read box 38.2, important PGME topic.

KEY BOX 38.2

Factors Responsible For Fecal Continence
(AI 95, MANY PGME)

- Adequate neurogenic control
- Functional internal and external sphincter
- Anorectal ring **(puborectalis-Most/Imp)**
- Anorectal angle
- Hemorrhoidal cushions

Arterial Supply

- The part of anal canal ***above*** *the pectinate line is supplied by superior rectal artery.* (PGME)
- The part of anal canal *below the pectinate line is supplied by inferior rectal artery.* (PGME)

Venous Drainage

- The internal rectal venous plexus (hemorrhoidal plexus), lies in the submucosa of anal canal. It drains mainly into the superior rectal vein; but communicates freely with the external plexus and thus with middle and inferior rectal veins.

NOTE: Superior rectal vein is a vein of portal system, while middle & inferior rectal vein are vein of systemic circulation.

- The internal plexus is therefore; an important site of communication between the portal and systemic vein.
- Veins present in the three anal columns situated at 3, 7 and 11 O'clock position are large and are potential sites for the formation of primary piles (hemorrhoid). Please see figure 38.3.

Lymphatic Drainage

- Above the pectinate line: Internal iliac node.
- Below the pectinate line: Superficial inguinal node and then into deep inguinal lymph nodes.

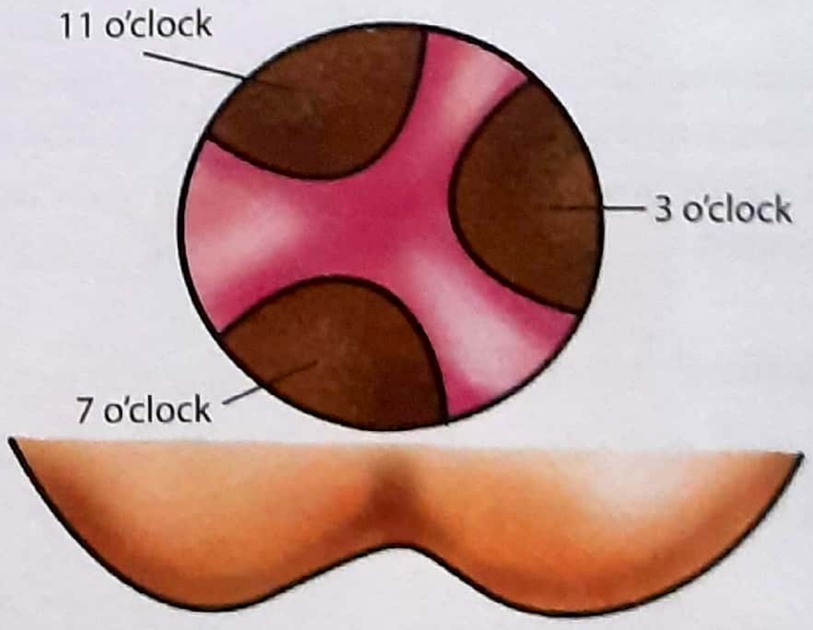

Figure 38.3: Veins present in anal column

KEY-BOX 38.3			
Anal canal	**Arterial supply**	**Venous drainage**	**Lymphatic drainage**
• Above pectinate	Superior rectal artery	Superior Hemorrhoidal plexus	Internal iliac nodes
• Below pectinate line	Inferior rectal artery	Inferior Hemorrhoidal plexus	Superficial inguinal nodes (PGI 89)

Nerve Supply

1. Above the pectinate line

The anal canal above the pectinate line is supplied by autonomic nerve, sympathetic (from inferior hypogastric plexus, Ll-2) and parasympathetic (pelvic splanchnic, S2,3,4). Pain sensation is carried by both.

2. Below the pectinate line

The anal canal below the pectinate line is supplied by somatic (inferior rectal S2,3,4) nerves.

Please read key box 38.3.

*****

RECAP: Till now we were discussing surgical anatomy of anal canal. Now lets discuss diseases related to anal canal.

PILONIDAL SINUS

[Latin : Pilo+ nidal; ie; Pilus = hair, nidus = nest]

Pilonidal sinus is a sinus in the sacrococcygeal area, containing nests of hair or their fragments.

Etiology

1. Congenital theory

It is considered as a sinus resulting from a persistent caudal remnant of the original neural canal or a sinus connected with a post anal dermoid; however this theory is dis-favoured.

2. Acquired theory

Many think that pilonidal sinus originate as a result of foreign body granuloma, the foreign body being hair.

3. Occupational disease

Pilonidal sinus most commonly affects *hair dressers and jeep drivers* (PGME), ie; **Jeep Bottom**. Hair broken due to vibration and friction as a result of sitting on a hard seat of jeep enters the opening of the sweat gland. As a result, loose hair travels down the inter gluteal furrow to penetrate deep in the skin and forms a sinus.

4. Inter digital pilonidal sinus

It is an occupational disease of hair dressers. The hair with in inter digital cleft or clefts being the customer's. Very rarely pilonidal sinus may occur at umbilicus.

Pathology

The tract has squamous lining and hair is lying loose in the sinus. The hair follicle is never demonstrated in the wall of pilonidal sinus.

Clinical feature

- The peak incidence is between 20-30 years of life.
- The disease commonly affects hairy men. (AI 07)
- The most common complaint is chronic or recurring sinus in the midline just above inter gluteal cleft. (Fig. 38.4; next page)
- The discharge is often blood stained and contains foul sebum.
- Dull or acute throbbing pain (when infected) may be present.

Complication

Complications are abscess formation, recurrent infection, recurrent sinus formation and very rarely carcinoma.

Treatment

(A) Patients with mild symptoms

- Patients with mild symptoms are treated conservatively.
- Cleaning the track, removing all hair, followed by frequent washing of the part with a detergent and water.

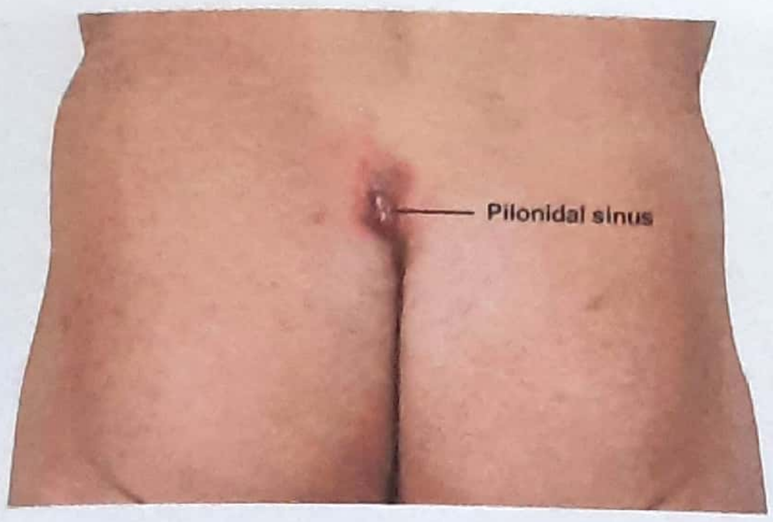

Figure 38.4: Pilonidal sinus

- Avoiding sitting for long periods of time.
- **Sitz bath** is advised- This is to sit in a tub, filled with lukewarm water with antiseptic solution. Note only hip remains in the tub; while the legs are out of tub.

(B) Acute exacerbation (abscess formation)

- Rest, bath, local antiseptic dressings and broad spectrum antibiotics. If these are not successful; then immediate incision and drainage of the abscess is done.

(C) Chronic pilonidal sinus (AI 07)

Treatment of chronic pilonidal sinus is excision of sinus tract. Which is done by either of the following way:-

(i) Open method (Wide local excision): The treatment is complete excision of the sinus tracks. Methylene blue is injected into the mouth of the sinus to outline the tract so that the entire tract is identified and can be *excised* (AI 07). The defect is allowed to granulate. Healing takes several weeks (6-8 weeks). Patient should be instructed to keep the area clean and dry. The recurrence rate is low. **Position of patient in surgery is Jack knife position** (NEET). Rhomboid flap is used for pilonidal surgery.

(ii) Closed method: In this; after complete excision of the tract the wound is closed by 'Z' plasty. This method carries 10-20% chances of recurrence. (Figure 38.4.1).

*****

Post Anal Dermoid

- A soft cystic swelling may sometimes be present in the space behind the rectum and anal canal and in front of lower part of sacrum and coccyx.
- Though congenital, such cyst remains symptomless till adult life; until and unless it becomes infected or burst; forming a sinus.
- A large post anal dermoid may give rise to difficulty in defecation due to pressure on rectum.
- Treatment is by complete excision of the cyst after removing the coccyx.

*****

Figure 38.4.1: Limberg flap. (A) Initial marking of a proposed incision, (B) Completed rotation of the flap.

ANAL FISSURE

The meaning of word *'Fissure'* is - *Long narrow crack.*

Definition

Anal fissure is defined as a tear/crack or an elongated ulcer in the long axis of lower anal canal.

Location

The **commonest locations are in the midline posteriorly (90%) in the anal canal** (NEET, MANY PGME). The next most frequent location is midline anteriorly; especially in a multi-para women. Lateral or multiple fissures should raise suspicion of trauma, inflammatory bowel disease, neoplasm and infection or sexual malpractice.

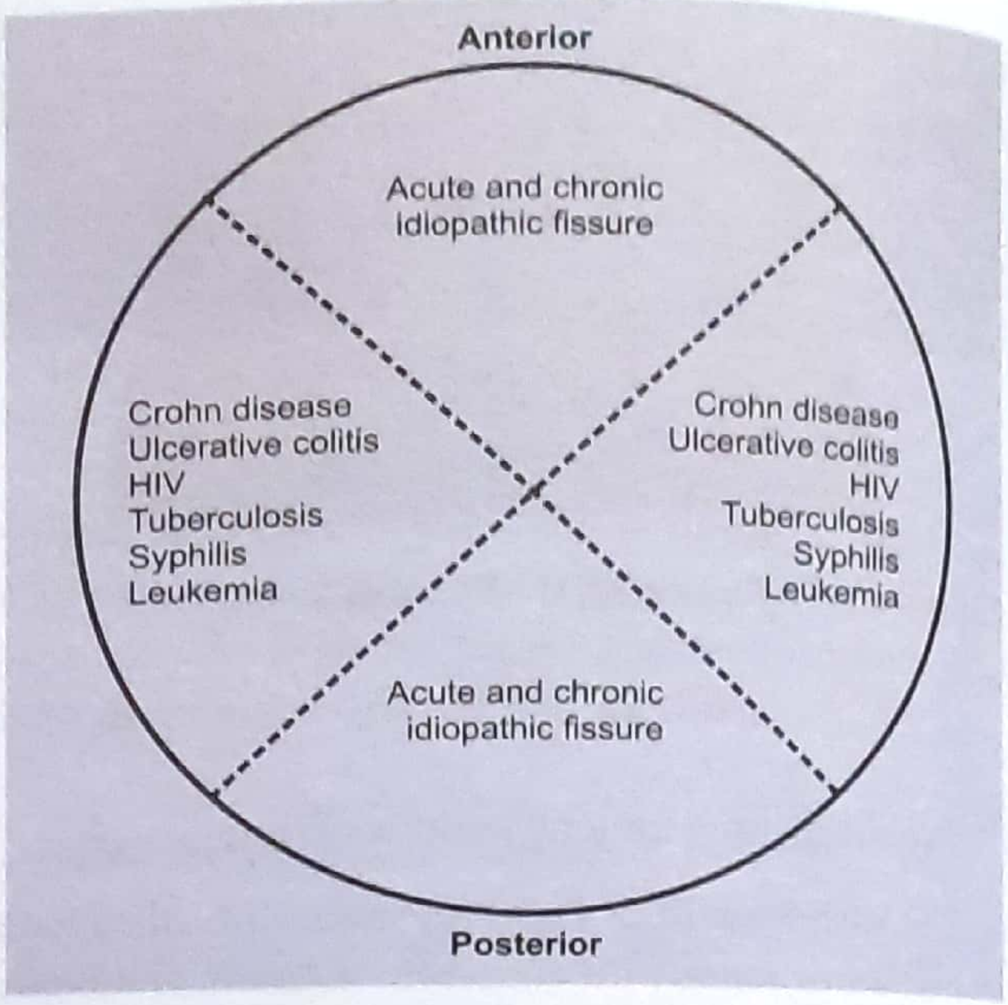

Figure 38.5.1: Common and atypical locations of anal fissure.

Etiology

- Hard feces
- Lack of fibre in diet
- Ischemia
- As a complication of hemorrhoidectomy, when too much skin is removed.
- Inflammatory bowel disease - especially Crohn's disease.
- Anterior fissure is common in women (especially multipara) due to lack of support of the anal mucosa by damaged pelvic floor and an attenuated perineal body.
- Sexual malpractice
- Laxative abuse.

Pathology

Pathologically anal fissure can be classified as acute and chronic.

1. Acute anal fissure

Acute anal fissure is a *deep tear through the skin of the anal margin, extending into the anal canal,* with little inflammatory induration and edema. There is accompanying spasm of the internal sphincter muscles (Internal anal sphincter).

2. Chronic anal fissure

Chronic anal fissure consists of:

- Longitudinal tear from the anal verge to the pectinate line, which becomes a canoe*- shaped ulcer, the floor of which contains the lower third of the internal sphincter. (Figure 38.5.3)

Canoe shaped = small boat shaped, pointed at both ends.*

- Margins are inflamed and indurated.
- An *skin tag* (from perianal skin) develops at the anal verge and is known as a sentinel* pile (because it guards the fissure; fig 38.5.2) (AIIMS 87, MANY PGME)

NOTE: * Sentinel - The literary meaning of sentinel is a soldier or one whose job is to keep watch (ie; a guard). Pile = lying over another.

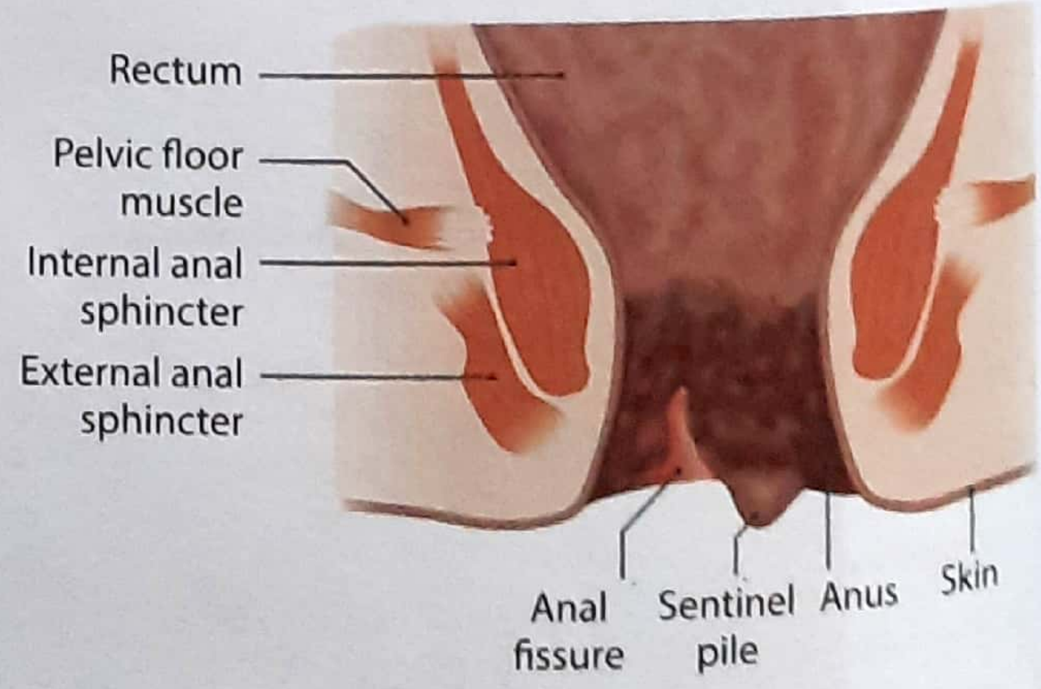

Figure 38.5.2: Chronic anal fissure

Figure 38.5.3: Anal fissure

Triad of chronic anal fissure is (MANY PGME)

- Chronic *ulcer* in anal canal
- *Sentinal pile* (a skin tag)
- *Hypertrophied anal papilla* (see fig. 38.5.2)

Clinical feature

- The condition is more common in young and middle aged women (between 20-40 years).
- It is uncommon in elderly due to atony of sphincter musculature.

Symptoms

1. **Pain:** Pain is the most important symptom. It is sharp, burning in nature and starts during defecation, lasting for 1 hour or more. As a rule, pain is relieved suddenly and the patient feels comfortable until the next act of defecation.
2. **Constipation**
3. **Bleeding per rectum:** This is usually slight and consists of bright streaks on the stool.
4. **Mucous discharge:** Slight mucous discharge accompanies fully established cases.

Signs (AI 08)

1. Sentinel pile (discussed above)
2. Tightly closed and puckered anal opening
3. Gentle eversion of the anus will show the lower end of ulcer (crack).
4. Digital examination - is very painful and should be avoided (JIPMER 90) and if at all done; should be done with topical anesthesia (5% Xylocaine).
5. Proctoscopy is contraindicated, if at all it has be done; should be done under general anesthesia.
6. *Best diagnosed by history & superficial clinical examination.* (NEET)

Treatment

The Basic principle for treatment of fissure-in ano is to dilate the anal canal and relaxation of anal sphincter.

1. Conservative (Medical)

- Dietary adjustments-encourage high fibre diet, avoid fried foods
- Mild laxatives.
- Topical anesthetic creams - Xylocain ointments.
- Antibiotics
- Sitz bath (described on page 697)
- **Agents causing relaxation of anal sphincter**
  - (i) Glyceryl trinitrate ointment (.2%) - major side effect is headache.
  - (ii) Nifidipine ointment or in oral form.
  - (iii) Purified *botulinum toxin* - injection of botulinum toxin produces anticholinergic effect and causes temporary paresis of sphincter muscle. (MANY PGME)

Please read Key box 38.4

2. *Operative treatment*

(a) Anal dilatation

Under general anesthesia, the index and middle finger of each hand are inserted simultaneously into the anus and carefully pulled apart (outwards). Great care and judgement had to be exercised; so that anal sphincters are not over stretched. The risk of incontinence following this procedure has now made it unpopular.

(b) Lateral anal sphincterotomy

The internal sphincter is divided away from the fissure, usually in right or left lateral position and is **best in acute cases.** (NEET) There is a small risk of incontinence with this procedure too. This is procedure of choice in case of acute on chronic anal fissure.

KEY BOX 38.4

Summary of Treatment of Anal Fissure

↓

Basic pathology consist of

- An Ulcer (Anal fissure) → Fissurectomy
- Spasm of anal sphincters → Relieving the spasm of anal sphincter
  - **Medically** → By
    - Smoth muscle relaxants like
      - Glycerine trinitrate
      - Nifidipine ointment
      - Purified botulinum toxin (anticholinergic effect)
  - **Surgically**
    - Anal delatation under GA
    - Lateral sphincterectomy
    - Fissurectomy
    - Anal advancement flap

(c) Dorsal fissurectomy and sphincterotomy

along with excision of the sentinel pile. The disadvantage is the prolonged healing time. Therefore this method is reserved for chronic and recurrent anal fissures.

(d) Anal advancement flap

This technique has become popular recently as there is low risk of damage to the underlying internal sphincter and incontinence is unlikely. Kindly revise the treatment from key box 38.4.

*****

HEMORRHOIDS (PILES)

Hemorrhoids are "cushions" of submucosal tissue containing venules, arterioles and smooth muscle fibres that are located in anal canal.

Three hemorrhoidal cushions are normally found; located at: (figure 38.6B)

(i) Left lateral - 3 O'clock position
(ii) Right anterior - 11 O'clock position
(iii) Right posterior - 7 O'clock position

Hemorrhoidal tissues are part of the *normal anatomy* of the distal rectum and anal canal and thought to function, as part of the continence mechanism and aid in complete closure of anal canal at rest.

However, clinically term "Hemorrhoids" should be restricted in situation in *which these "cushions" are abnormally dilated and cause symptoms, like:-* bleeding, prolapse and pain. Hemorrhoids occur at superior rectal vein.

Hemorrhoid is a Greek word, made from *haima = blood, rhoos = flowing,* ie; A disease associated with flowing blood. Bleeding is often the chief complain of a patient with hemorrhoid.

For Hindi speaker Hemorrhoid is called as "Babaseer" in local language.

Classification

(a) External hemorrhoids

External hemorrhoids are located distal (below) to dentate line and are covered with anoderm. (MANY PGME). Because the anoderm is pain sensitive (supplied by somatic nerves), thrombosis of an it may cause significant pain. (AIIMS 06, AI 07)

A thrombosed external pile is commonly termed as **perianal hematoma**. In majority of cases resolution or fibrosis occurs and the condition has been called a *"five day, painful self curing lesion"*. (NEET, AP 97)

(b) Internal hemorrhoids

These are located proximal (above) to the dentate line and is covered by pain insensitive anorectal mucosa, that is why they are **usually painless**; (NEET) unless thrombosis and necrosis develop. *Internal hemorrhoids are graded according to extent of prolapse.* (MANY PGME)

Grading of internal hemorrhoids

Internal hemorrhoids are classified into 4 ***grades*** (MANY PGME)

I^st degree

Painless bleeding, *no prolapse*

IInd degree

Prolapse through the anus on straining, but *reduce* spontaneously, (reduce*- goes back in anal canal)*

IIIrd degree

Prolapse through the anal canal, and require *manual reduction by the patient*

IVth degree

Permanently prolapsed and *cannot be manually reduced*

KEY BOX 38.4.1

Classification of internal hemorrhoids

Grade of internal hemorrhoids	Description
Grade 1	No prolapse; hemorrhoidal bleeding
Grade 2	Hemorrhoids with bleeding and protrusion; reduce spontaneously
Grade 3	Hemorrhoids with bleeding and protrusion; manual reduction required
Grade 4	Prolapsed hemorrhoids that cannot be reduced

(c) Combined internal and external hemorrhoids

Straddle the dentate line and have characteristics of bothinternal and external hemorrhoids. See figure 38.7 & 38.8

Please read Key box 38.4.1 and 38.5

Etioiogy

The majority of patients have primary hemorrhoids (piles) and there is no obvious cause. In the secondary variety the hemorrhoids are secondary to pressure effect caused by some pathology.

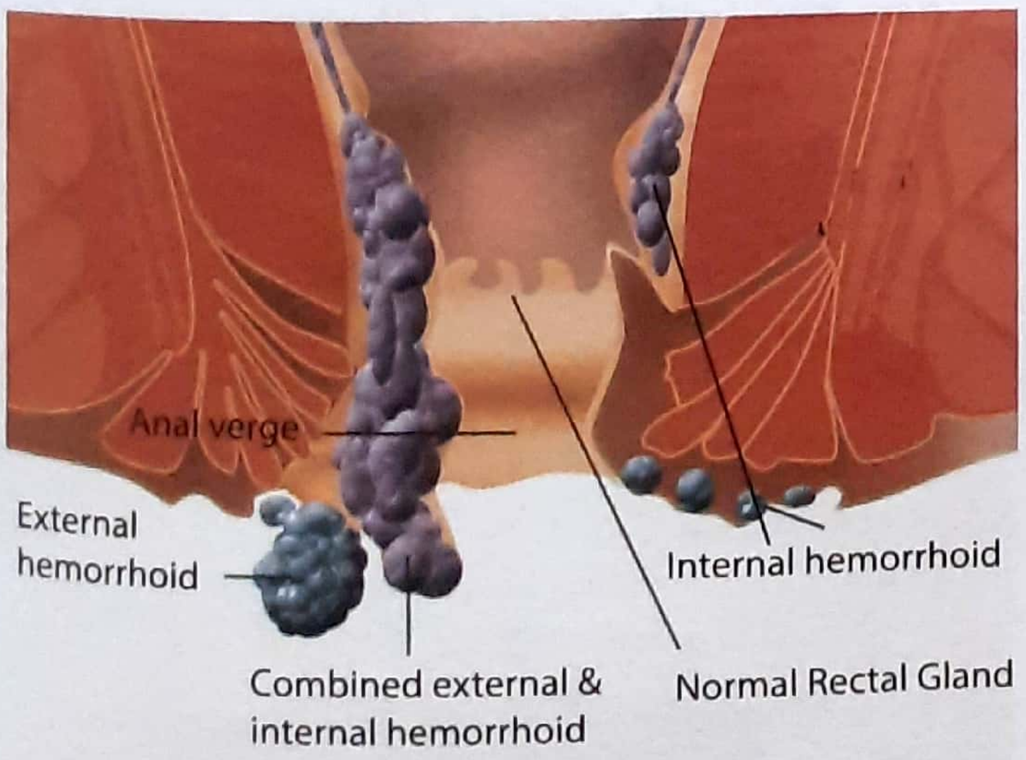

Figure 38.6: Hemorrhoids (A). The varicosed tributaries of the superior and inferior rectal veins giving rise to internal and external hemorrhoids, respectively (B). The common sites of internal hemorrhoids

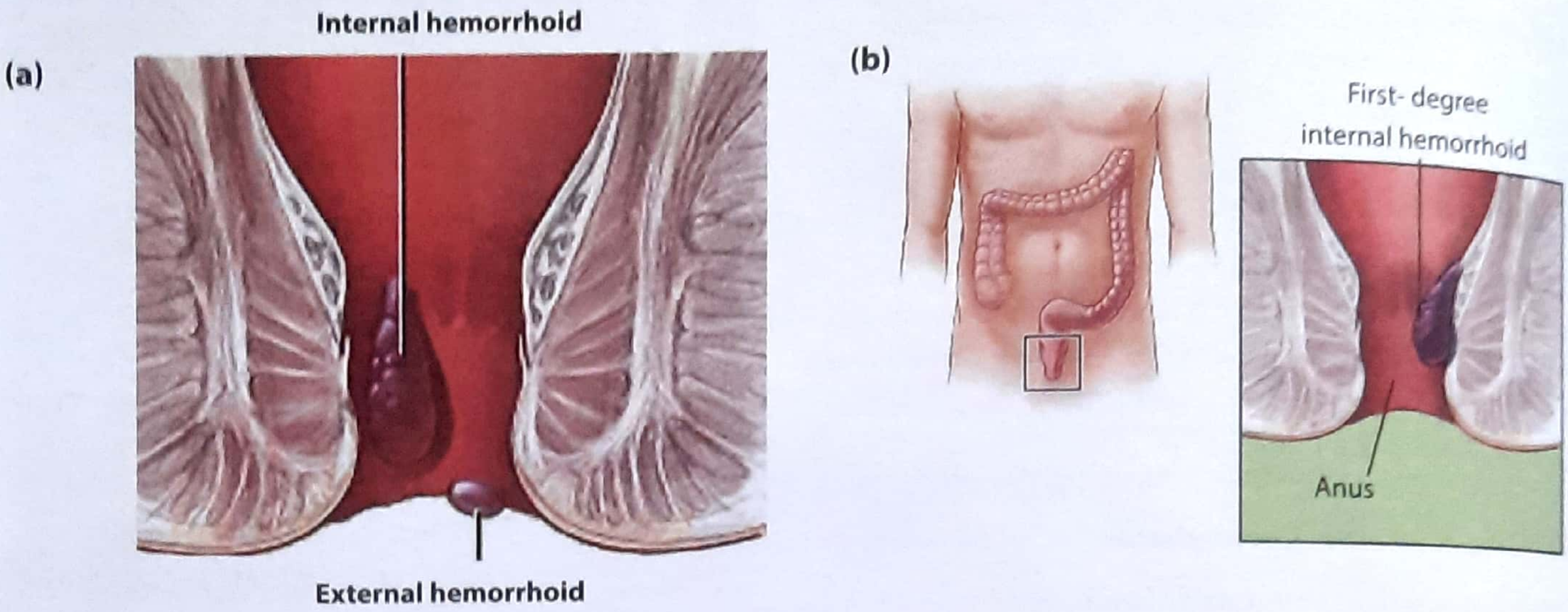

Figure 38.7: Internal and external hemorrhoid

1. Primary Hemorrhoids

This is most common variety; where there is no obvious cause, but a number of precipitating factors may play their role, which are:

- Familial
- Gravity action due to upright posture
- Loose submucous coat
- Congenital weakness of venous wall
- Low fibre diet

2. Secondary Hemorrhoid

These are far less common than primary hemorrhoid (piles). The causes are:

- Pregnancy
- Increased resting pressure in anal canal.
- Prolonged straining in the act of defecation.
- Carcinoma of middle third of rectum.
- Conditions causing increase in intra abdominal pressure.
- Urethral stricture, BPH.
- Big pelvic tumour pressing on the superior rectal vein.

NOTE: Portal hypertension was long thought to increase risk of hemorrhoidal bleeding, because of the anastomosis between the portal venous system (middle and upper hemorrhoidal plexus) and the systemic venous system (inferior rectal plexus).

It is now understood, that hemorrhoidal disease is no more common in patients with portal hypertension than in the normal population.

Pathology

1. *Internal hemorrhoids in association with superior rectal vessels, are located at 3, 7 and 11 O'clock positions* (NEET) (with patient in lithotomy position) corresponding to left, right posterior and right anterior branches of these vessels. Please see figure 38.6 once again.
2. The pedicle of each hemorrhoid is situated above anorectal ring and consists of large tributaries of superior rectal vein and artery covered with smooth pink mucosa.
3. Internal hemorrhoids extend from anorectal ring to dentate line and are covered by mucosa and appear bright red or purple. (IMP. POINT)
4. External hemorrhoid, extends from dentate line to anal orifice and are covered by skin and appears blue. (IMP.

KEY BOX 38.5

Classification of hemorrhoid

Internal Hemorrhoids	External Hemorrhoids	Combined
- Located proximal (above) the dentate line	- Located distal (below) to the dentate line	(Interoexternal)

Grading of internal hemorrhoids

Internal hemorrhoids are classified into 4 grades

Ist degree → Painless bleeding, no prolapse

IInd degree → Prolapse of hemorrhoid through the anus, on straining but hemorrhoid reduce spontaneously.

IIIrd degree → Prolapse of hemorrhoid through the anal canal and require manual reduction by the patient

IV degree → Permanently prolapsed hemorrhoid, that cannot be manually reduced

All four degrees may be associated with bleeding

Combined internal and external hemorrhoids

Straddle the dentate line and have characteristics of both internal and external hemorrhoids.

Clinical features

Symptoms

1. Bright red bleeding per rectum (M/C): Initially the bleeding is slight, bright red and occurs during defecation (a 'splash in the pan')
2. Prolapse of piles, depending on degree (see box: 38.5)
3. Mucous discharge and pruritus ani.
4. Pain (when complications develop in internal hemorrhoid) while **external hemorrhoids are always painful. Nerve mediating this pain is pudendal nerve.** (NEET)

Signs

1. Skin tags.

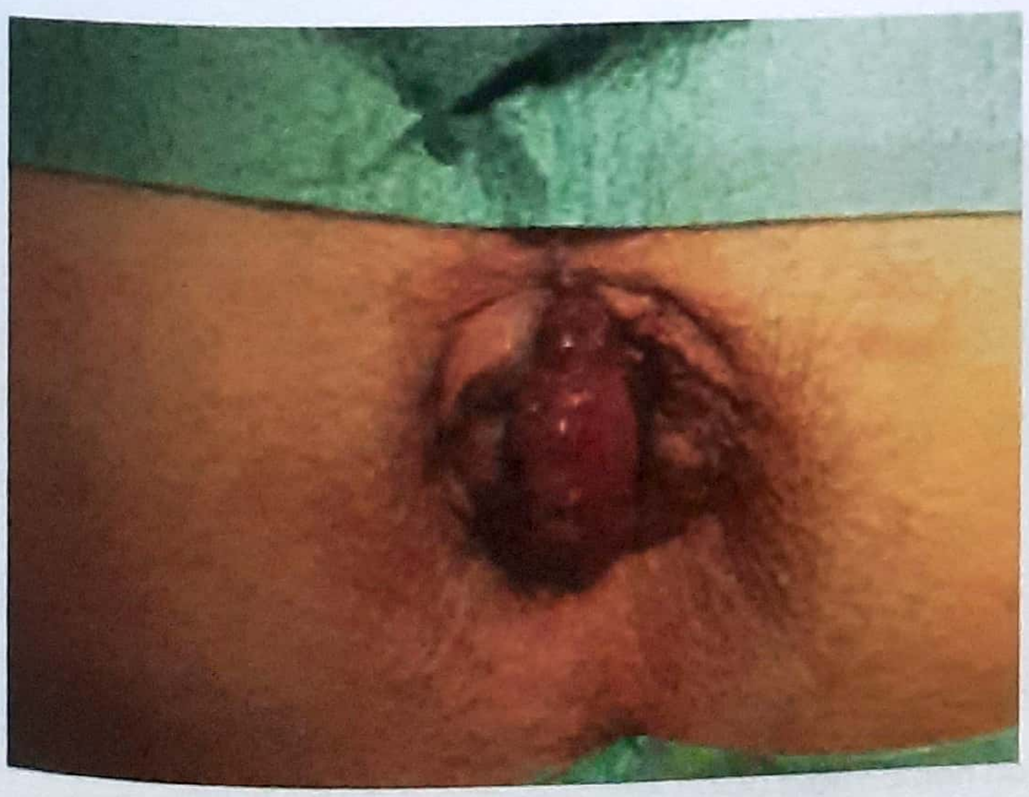

Figure 38.8.1: Prolapsed hemorrhoids

Figure 38.8.2: Thrombosed external pile

2. Prolapsed hemorrhoids (fig 38.8.1)
3. *Proctoscopy demonstrates hemorrhoids and is investigation of choice.* (PGME)
4. Anemia due to persistent profuse bleeding from hemorrhoids

Complications

(Mnemonic-Hemorrhoid is GUTS For HIP)

1. Gangrene
2. Thrombosis and pain (fig 38.8.2)
3. Ulceration
4. Strangulation
5. Fibrosis
6. Hemorrhage
7. Infection
8. Pylephlebitis and portal pyemia- very rare.

Treatment

A. Medical treatment

Initially medical management is recommended for all but the most advanced cases. Dietary alteration, including elimination of constipating foods (eg; fatty food, bananas) and the addition of bulking agents such as fibre, stool softeners and increased intake of liquids are advised. Some drugs like calcium dobesilate; both in oral or cream application may be useful in grade I hemorrhoid.

B. Surgical treatment

First and second degree hemorrhoids generally respond to medical treatment. Hemorrhoids, that fail to respond to medical management are treated surgically:- by sclerotherapy, elastic band ligation, photocoagulation, cryosurgery, and excisional hemorrhoidectomy. Surgical treatment options are:-

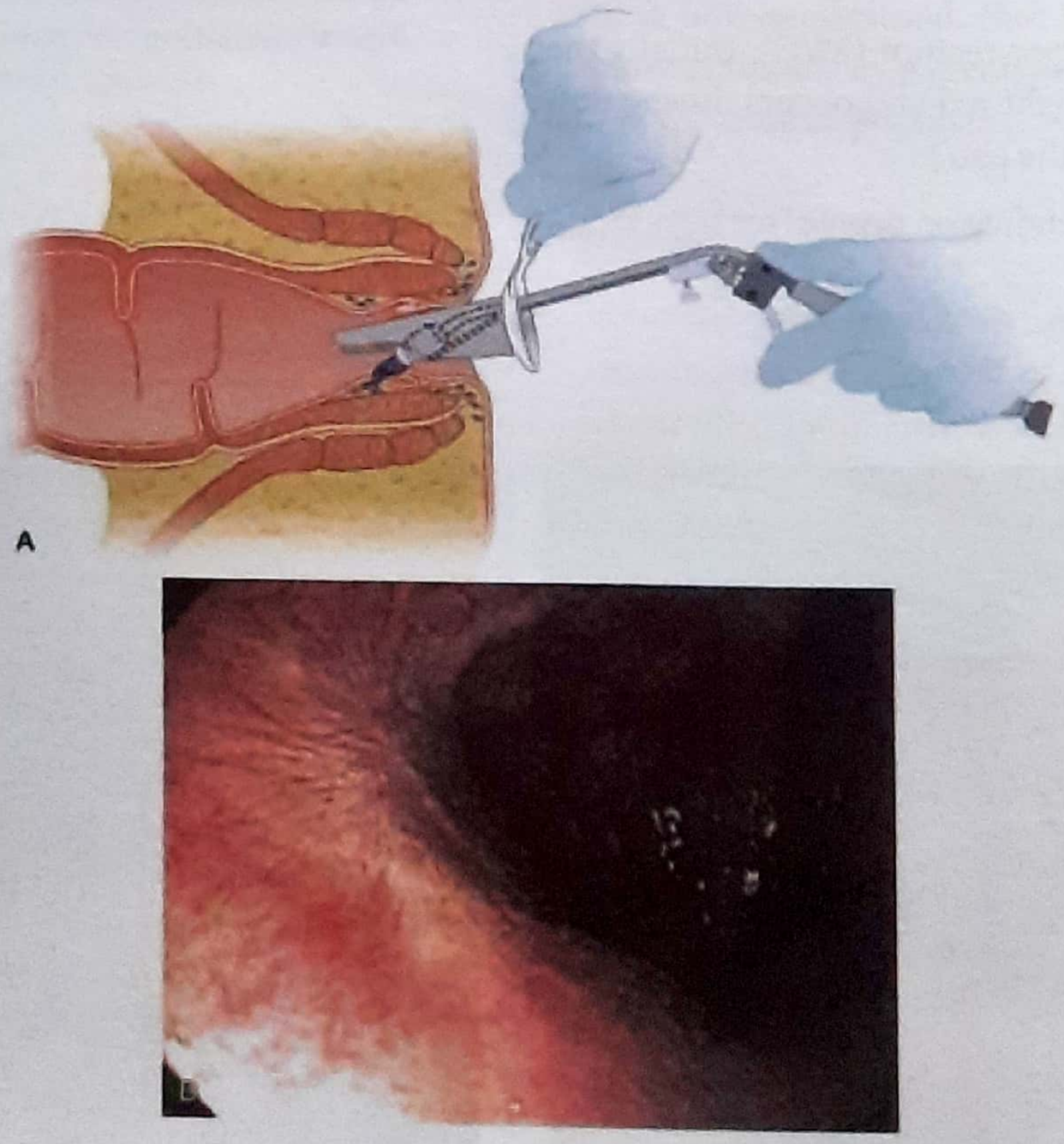

Figure 38.9.1: (A) Placement of band on hemorrhoid using specially designed applicator. (B) Mucosal scarring after rubber band ligation, colonoscopic retroflexion.

1. Injection sclerotherapy (AI 04, AIIMS 96, PGI)

This is often tried *for first and second degree hemorrhoids and some third degree* that continue to bleed despite medical measures. About 1-2 ml of sclerosant is injected, into the loose submucosal connective tissue above the hemorrhoidal complex; which causes inflammation and scarring.

2. Elastic band ligation (Barron's banding)

Elastic band ligation is safe and effective in the treatment *of first degree, second degree* and *selected third-degree hemorrhoids.* (MANY PGME) Hemorrhoidal tissue, 1-2 cm above the dentate line is grasped, pulled into the barrel of an elastic band applicator and two bands are placed at the base of the hemorrhoidal complex, which causes ischemia of hemorrhoid. After 7-10 days; the hemorrhoid sloughs away removing a portion of the offending redundant tissue and leaving a scar that inhibits further prolapse and bleeding of the remaining tissue. (Figure 38.9.1)

3. Cryosurgery (Freezing the hemorrhoids with a cryoprobe)

This consist of application of **liquid nitrogen** at minus 196°C. Extreme cold, causes coagulative necrosis. The technique is painful and *main complication with this is, water mucous discharge.* (PGME) (cryo: means very cold)

CO_2, Argon, Diethyl ether also used. (NEET)

CRYO SURGERY? The application of a freezing probe* to living tissues is termed as eryosurgery. Tissue freeze at around -3°C, but cell death does not occur until -20°C is reached. Tissue frozen to -20°C and below, for 1 minute will under go irreversible change leading to destruction.

* PROBE: A blunt ended surgical instrument

4. Photo coagulation

This consist of application of infrared coagulation by a specially designed instrument. This is an effective and painless method of treatment.

5. Hemorrhoidectomy

Indication (PGME, AI 88, UP 2000)

- Third and fourth degree hemorrhoids
- Failure of medical treatment of second degree hemorrhoids.

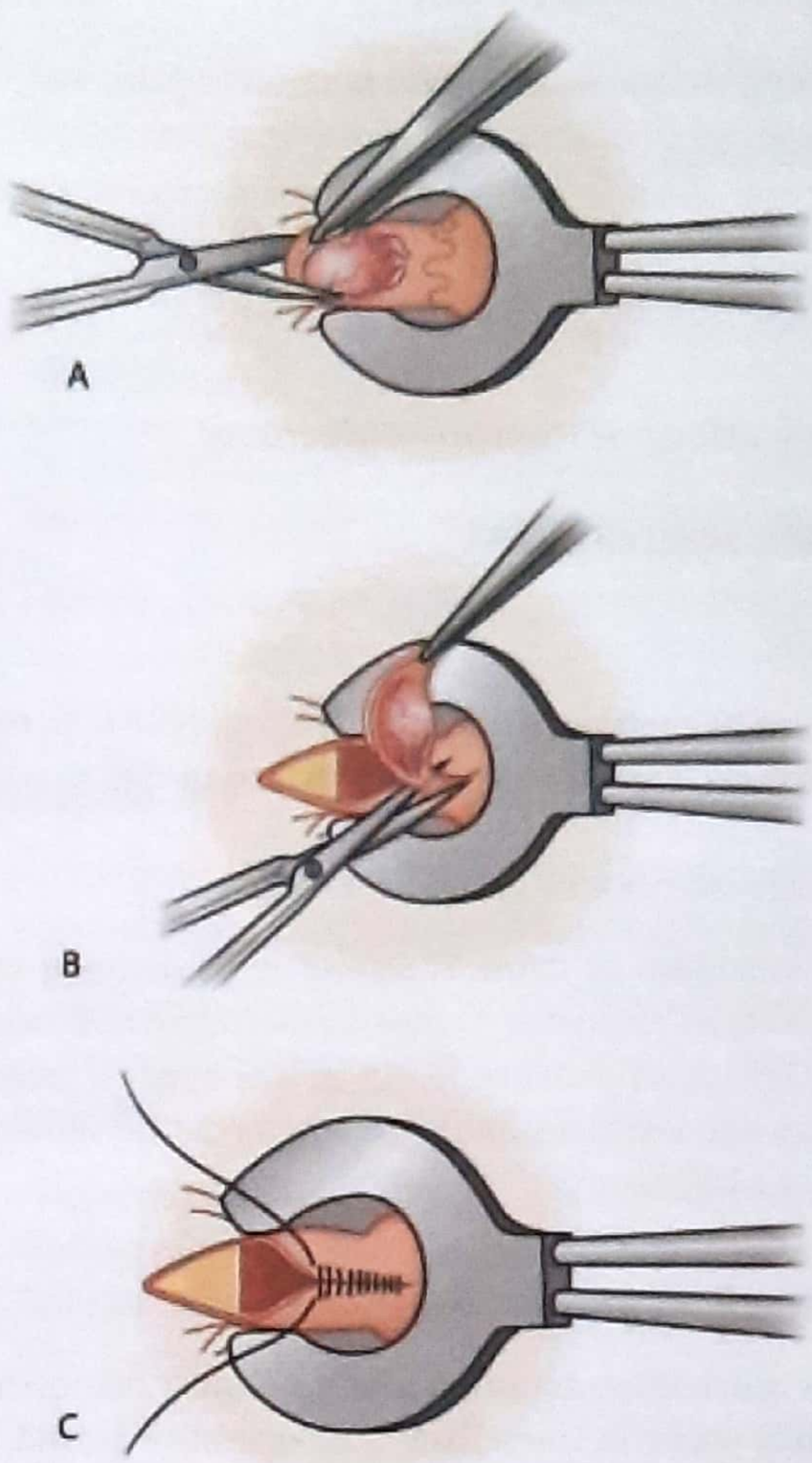

Figure 38.9.2: Closed hemorrhoidectomy (Ferguson)

- Mixed internal and external hemorrhoid.
- Incarcerated and fibrosed hemorrhoid.

Technique (Types of Hemorrhoidectomy)

Hemorrhoidectomy can be performed using an open or a closed technique:

(i) Open technique (Milligan -morgan operation)

It involves ligation and excision of the hemorrhoids. In this technique the anal mucosa and skin are left open to heal by secondary intension.

(ii) Closed technique (Hill-feurguson operation)

It also involves ligation and excision of the hemorrhoids, with anal mucosa and skin closed by suturing. (Figure 38.9.2).

Post operative management

- Strong analgesics are given to reduces pain.
- Antibiotics
- Stool softeners are given to avoid constipation.
- Sitz bath twice daily (See page, no 697)

Complications of Hemorrhoidectomy (IMP FOR PGME)

A. Early complications

(a) Pain:

Pain is *most common* early complication. NSAIDS, muscle relaxants, topical analgesics are often useful.

(b) Acute retention of urine (PGME)

Acute retention of urine is *second most common* early complication following hemorrhoidectomy and occurs in 10-30% of all patients. It can be managed by treating the pain and warm water bath. Catheterization should be done as a last resort.

(c) Reactionary hemorrhage

This is much more common than secondary hemorrhage and may occur in immediate post operative period (often in recovery room) as a result of inadequate/incorrect ligation of vascular pedicle, (revise reactionary hemorrhage & secondary hemorrhage on page no. 33)

B. Late complications

(a) Secondary hemorrhage:

Secondary hemorrhage is uncommon; when it occurs, it occurs between 7 to 10 days after operation; when a necrotic mucosa overlying the vascular pedicle sloughs.

(b) Fecal Incontinence

(c) Anal stenosis and anal stricture: due to extensive resection of perianal skin.

(d) Anal fissure

6. Stapled hemorrhoidopexy

This is a technique that utilizes a circular stapling device to devascularise the hemorrhoidal tissue, reduce the mucosal prolapse, and perform an anopexy. The technique is safe, with improved postoperative pain control reported, but the cost of the device may limit its use.

KEY BOX 38.6

Complication of Hemorrhoidectomy (AIIMS 92)

Early	Late
1. Pain (M/C)	1. Secondary hemorrhage
2. Acute retention of urine (2nd M/C)	2. Fecal Incontinence
3. Reactionary hemorrhage	3. Anal stenosis & stricture
	4. Anal fissure

7. Whitehead's hemorrhoidectomy

This involves circumferential excision of hemorrhoidal cushion just proximal to dentate line, but now has been abandoned because of the risk of **ectropion** (Whitehead's deformity). (PGME)

*****

FISTULA-IN-ANO

Fistula : An abnormal tubelike passage from a normal cavity or tube to a free surface or to another cavity.

Fistula in ano is an abnormal fistulous tract which has an external opening (secondary opening) in the perianal skin & an internal opening (primary opening) in the anal canal or rectum. This tract is lined by unhealthy granulation tissue.

Types (UPSE 08)

1. Low fistula

When *internal opening* (primary opening) is **below** the *anorectal ring.*

2. High fistula

When *internal opening* (primary opening) is **above** *the anorectal ring.* Clinical importance of high and low fistula is because high fistulas are at a higher risk of post operative fecal incontinence due to sphincter damage than low fistulas because high fistulas have their internal opening above the ano rectal ring; which is chiefly responsible for anal continence. During surgery for high fistula the ano rectal ring may get damaged and lead to fecal incontinence. (AI 01, UP)

Classification

(a) Standard classification

(i) Subcutaneous
(ii) Submucous fistula
(iii) Low anal
(iv) High anal

(b) Park's classification

(i) **Intersphincteric fistula:** This is most common type, and runs between the internal & external sphincters. *(MANY PGME)*

(ii) **Trans sphincteric:** Extends through both internal & external sphincter.

(iii) **Suprasphincteric fistula:** Originates in the intersphincteric plane and tracks up & around the entire external sphincter.

(iv) **Extrasphincteric fistula:** Originates in the rectal wall and tracks lateral to both sphincters.

Please see figure 38.10.1 and 38.10.2 very very carefully and lock every fistula in your memory.

Etiology

1. They occur due to a persistent anal gland infection, which results in perianal abscesses. When these abscesses rupture inside, as well as outside, it results in a fistula formation.
2. Tuberculosis is a common cause of fistula formation in our country.
3. In western countries; Ulcerative colitis, Crohn's disease are responsible for multiple fistulae formation.
4. Colloid carcinoma of rectum may some time present as multiple fistula in ano.

Clinical feature

- Often patient gives a history of burst perianal abscess or inadequately drained abscess few days back.
- Commonly; the principal symptom is a persistent seropurulent discharge; that irritates the skin in the neighbourhood and cause discomfort.
- Frequently there is a solitary external opening (secondary opening); usually situated with in 3.5-4cm from the anal orifice presenting as a small elevation with granulation tissue.

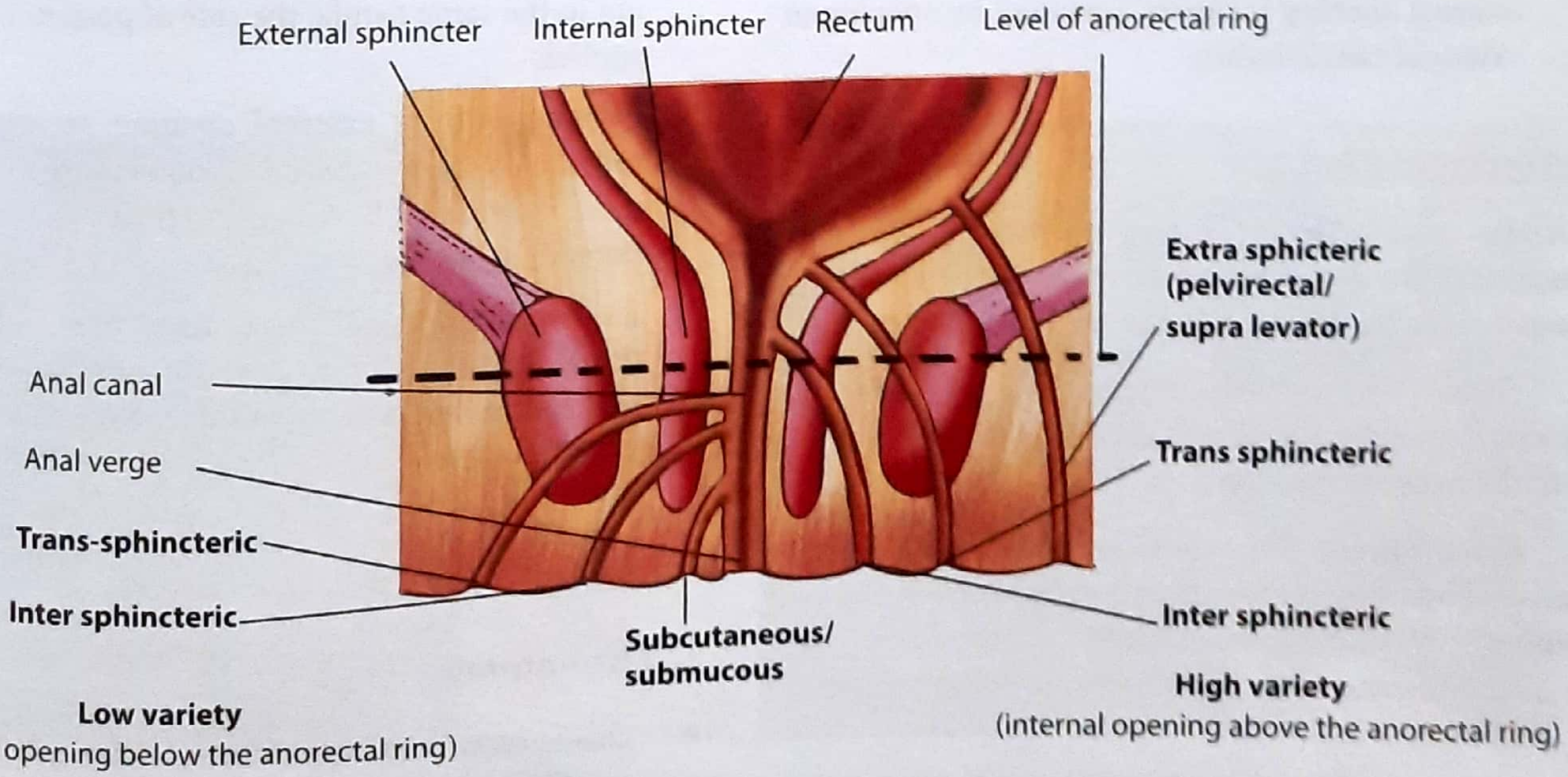

Figure 38.10.1: Classification of fistula In ano, left side-low variety, right side-high variety

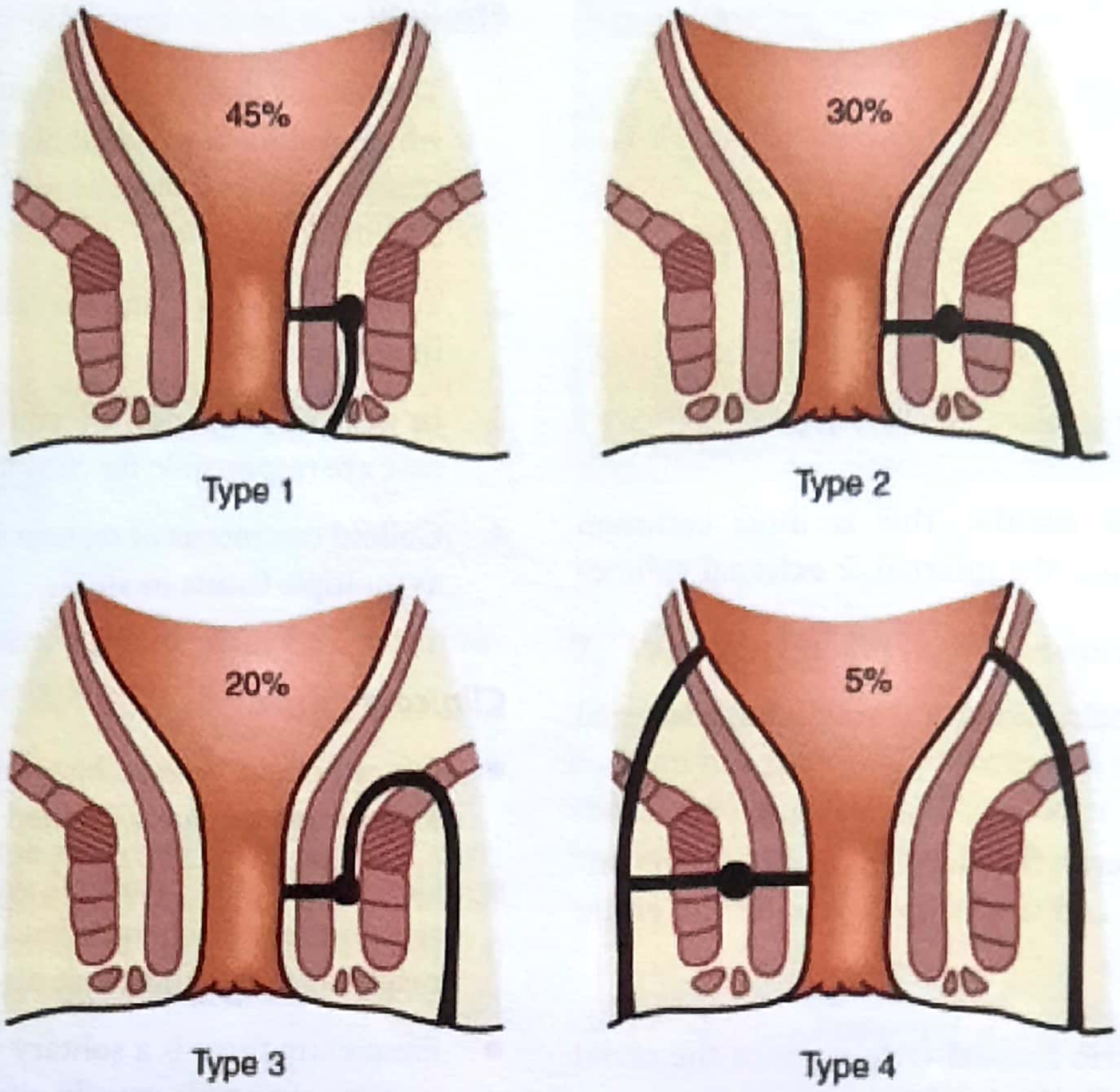

Figure 38.10.2: Park classification of fistula-in ano: Type 1 - Intersphincteric; Type 2- Trans-sphincteric; Type 3- Suprasphincteric and Type 4- Extrasphincteric

Goodsall's Rule *(VERY IMPORTANT) (MANY PGME, UP 2000)*

- Goodsall's rule is used to determine the location of internal opening (primary opening), ie; opening inside anal canal/rectum.

According to this rule

Fistulas with *external opening anterior* to horizontal imaginary line drawn across the mid point of anus is *connected to the internal opening by short straight tract.*

Fistulas with external opening, posterior to the horizontal line run a curvilinear course and open internally into the posterior midline.

Exceptions to this rule often occur, if an anterior external opening is more than 3cm away from the anal orifice, *(NEET)* such fistulas track to the posterior midline in a curvilinear course. Please see figure 38.11.1.

Note

1. When there is an anterior and also a posterior opening in the same fistula, the rule of posterior opening applies.
2. Fistulae with an external opening or openings in relation to the posterior half of anus are more common and usually have curving tracks and may be of horseshoe variety.
3. Posteriorly situated fistulae may have multiple external opening, which always connect to a solitary internal orifice; usually midline. Note this in figure 38.11.1; above.

Treatment

1. Fistulotomy

- This is *most commonly done operation for fistula-in-ano.* *(NEET)*

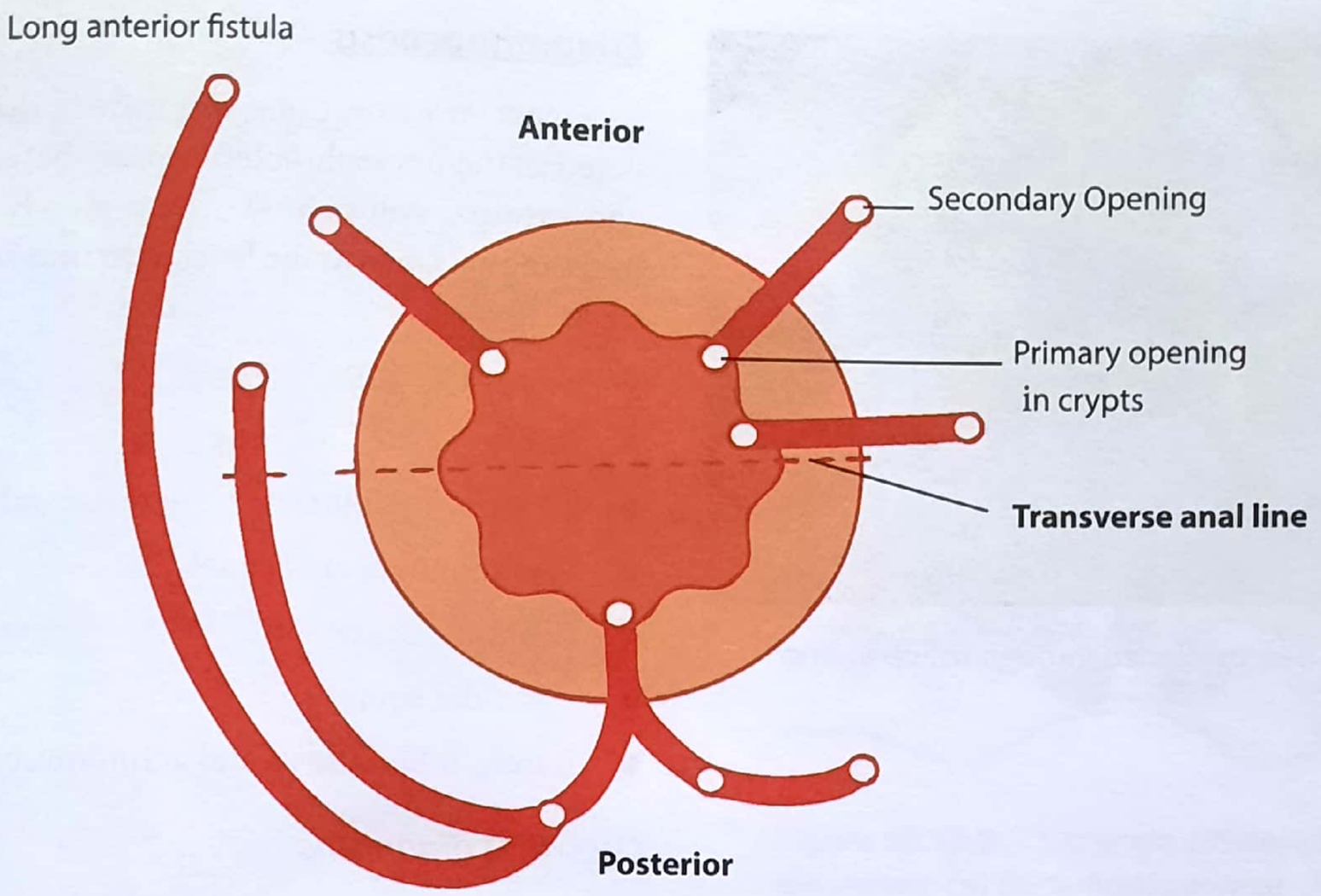

Figure 38.11.1: Salmon-goodsalls rule. (See text for details)

- This is indicated in low fistula; ie. internal opening below the anorectal ring. *(JIPMER 87)*
- In this operation, a probe is passed through the external opening; which traverse through tract; and is brought out from internal opening, and then the entire tract is deroofed for drainage (ie; is entire tract is laid open.) *(PGME)* (figure 38.11.2)
- The wound is left open and allowed to heal by secondary intension.
- The chances of incontinence is very low.

2. Fistulectomy

- All low type chronic fistula are treated by fistulectomy. In fistulectomy; the entire fistulous tract and dirty tissue is excised.

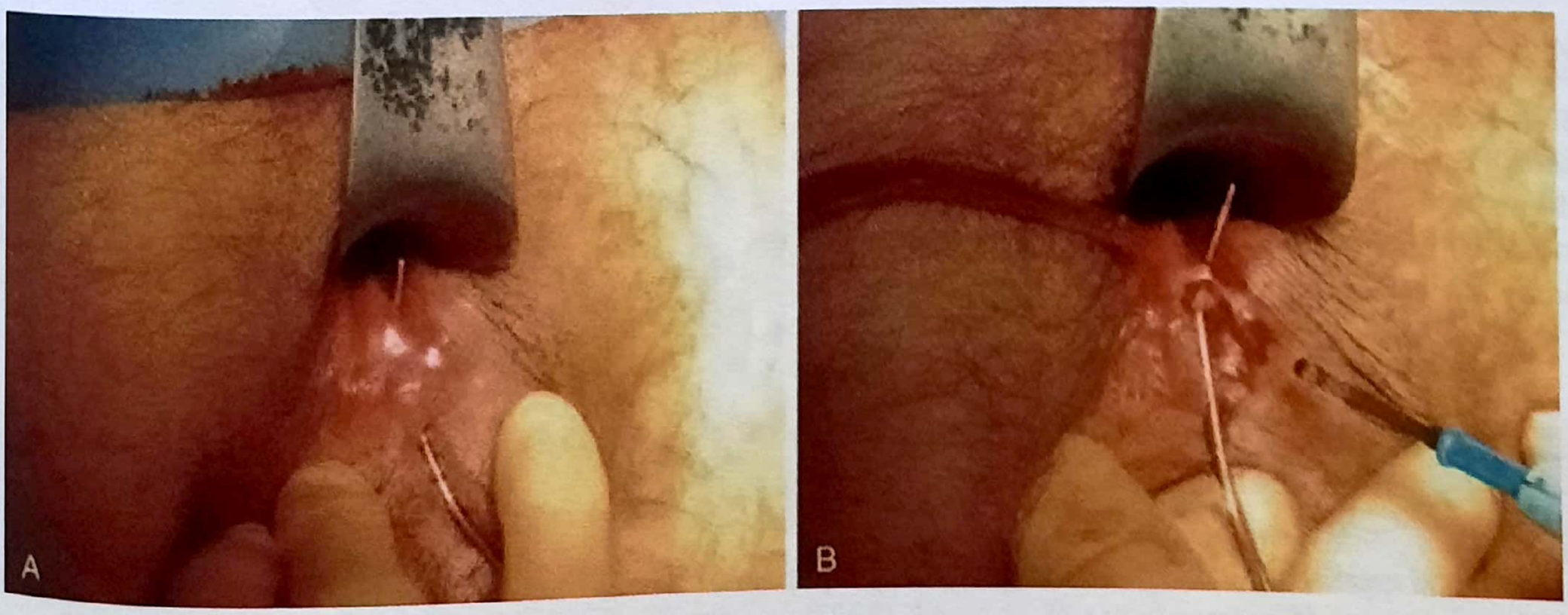

Figure 38.11.2: (A) Lay-open fistulotomy. Fistula probe inserted through the fistula track. (B) Incision over the fistula probe to lay-open fistula track.

Figure 38.11.3: Setons placed through fistula-in-ano tracks.

3. Seton

- High transsphincteric and suprasphincteric fistulas (supralevator) are treated safely by initial placement of a seton. (a steel wire, thread, linin or suture material).
- Draining setan & cutting seton. (figure 38.11.3)

A seton is a type of drain; placed through a fistula to maintain **drainage** and to induce fibrosis.

4. Defunctioning colostomy

- This may be required as a preliminary procedure in high fistula in ano to clear up infection. Later fistulous tract is defined and excised. When the healing is complete (usually at least 3 months) colostomy is closed.

Malignant changes in a fistula in ano (PGI JUNE 05)

Both adenocarcinoma and squamous cell carcinoma are known to arise within chronic fistulous tract. Adenocarcinoma can arise from anal glandular tissue, while squamous cell carcinoma arises from the squamous epithelial lining the wall of fistulous tract.

*****

ANORECTAL ABSCESSES

As the name speaks, these are abscesses in relation to anal canal and rectum. Please see figure 38.12.1 and 38.12.2, key box 38.7.

Etiopathogenesis (MAHE 07, MAHE 08)

In almost 90% infections, originate in the anal glands situated in the intersphincteric space (between the internal and external sphincters). These glands normally drain into the anal canal at the level of the anal valves. The chief causes are:

- Diabetes
- AIDS
- Penetrating injuries of the rectal wall
- Carcinoma of anal canal
- Crohn's disease
- Pilonidal sinus
- Rarely, tuberculosis and actinomycosis

Causative organisms

Main etiological agents are *E.coli* (60%), *S.aureus* (23%), *Bacteroides, Streptococcus, Proteus.* In many cases the infection is mixed.

- A large percentage (50%) of abscesses are associated with future fistula in ano. (IMP. POINT, MAY BE FUTURE PGME Q)

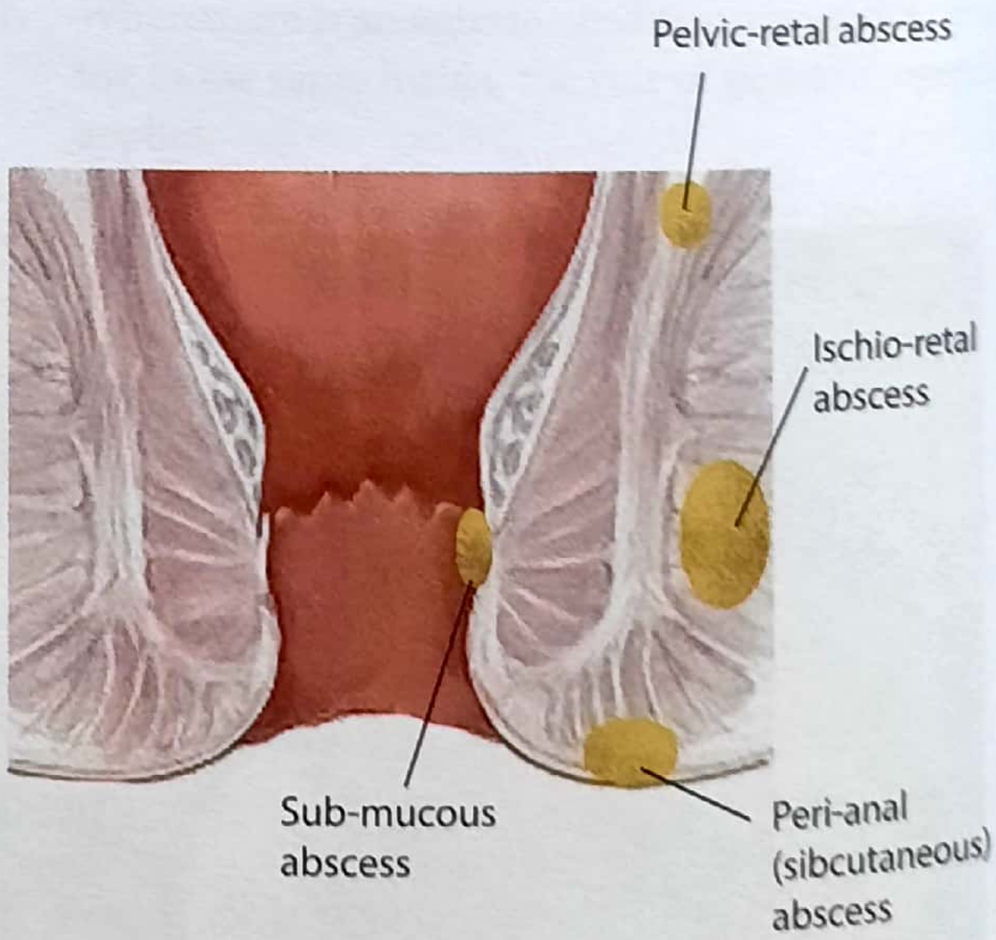

Figure 38.12.1: Various sites of anorectal abscess

Classification *[SEE BOX 38.7 BELOW]*

1. Perianal abscess (60%) *(NEET, AIIMS 85, UP 2000, MANY PGME)*

- This is *formed mainly due to suppuration of the peri-anal gland* and lies in the superficial portion of the external sphincter.
- It may also be due to the infection of the thrombosed external pile, if the hematoma has not been evacuated.
- Persons of all ages are affected.
- Patient usually presents with a very painful inflamed lump adjacent to the anal margin, below dentate line.

Treatment

It is by immediate incision and drainage, usually using a cruciate (cross like x) incision [X] and excising some of the skin edges to deroof the abscess *(UP 99)*. Healing is rapid and is encouraged by daily saline baths. Please see figure 38.13.1 & 38.13.2.

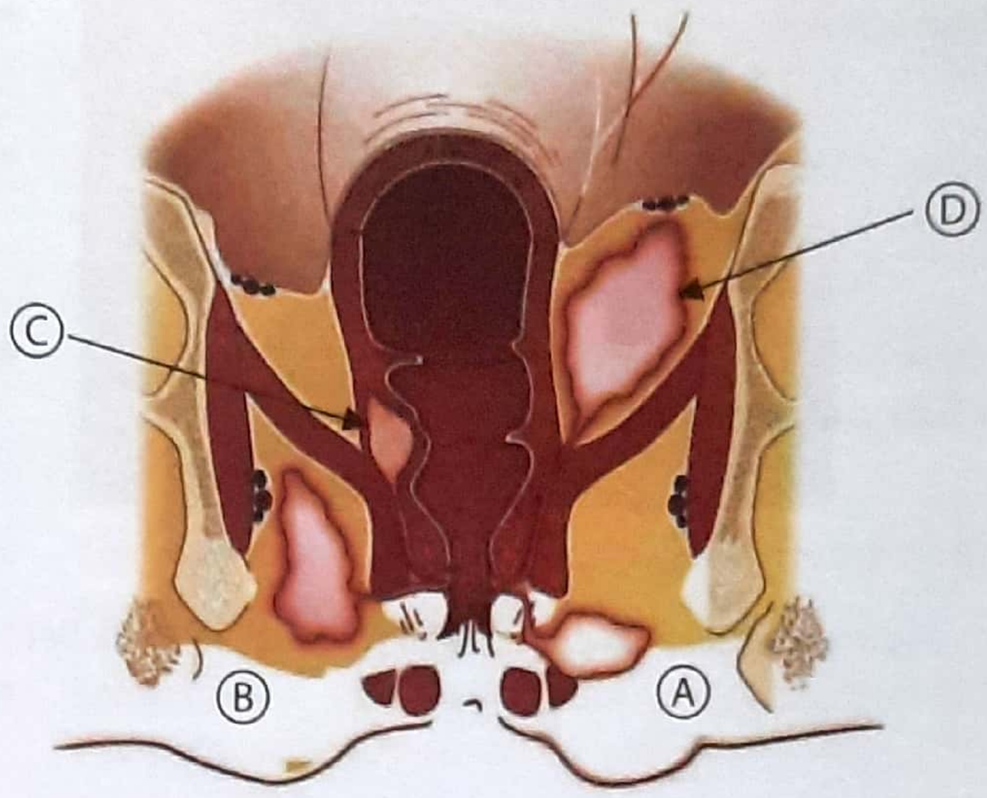

Figure 38.12.2: Common extensions of anorectal abscesses: (a) Superficial perianal, (b) Ischiorectal, (c) Intersphincteric, and (d) Supralevator.

2. Ischiorectal abscess (30%)

- This is more extensive and more serious condition and is usually accompnied by constitutional symptoms (fever >102°F)
- When involves both ischiorectal spaces (usually with a fistula in the deep post anal space) it is called as *horse shoe fistula,* (fig 38.14; ischiorectal space)
- Men are affected more often than women.
- The fat that fills the ischiorectal fossa is particularly vulnerable to infection; because of its poor blood supply. *(AI 89),*
- Patient presents with throbbing pain, disturbing sleep which is aggravated by defecation.
- On examination tender, brawny swelling is palpable on the corresponding side of anal canal over the ischiorectal fossa.
- Fluctuation is **late finding** in ischiorectal abscess.

Treatment

As abscesses any where in the body should be drained, the basic of treatment of ischiorectal abscess is incision and drainage. Treatment is done in two stages.

Stage I

A cruciate incision is made, evacuation all pus is done after breaking all septations.

Stage II

When acute infection has subsided, a careful exploration of any fistulous tract is done and if found they are treated accordingly. The area is packed and daily dressings (T bandage) are done and healing is allowed to occur with granulation (secondary intension).

KEY BOX 38.7

Anorectal abscess

- Peri-anal (60%) [M/C]
- Ischio-rectal (30%)
- Submucous (5%)
- Pelvi-rectal (5%)

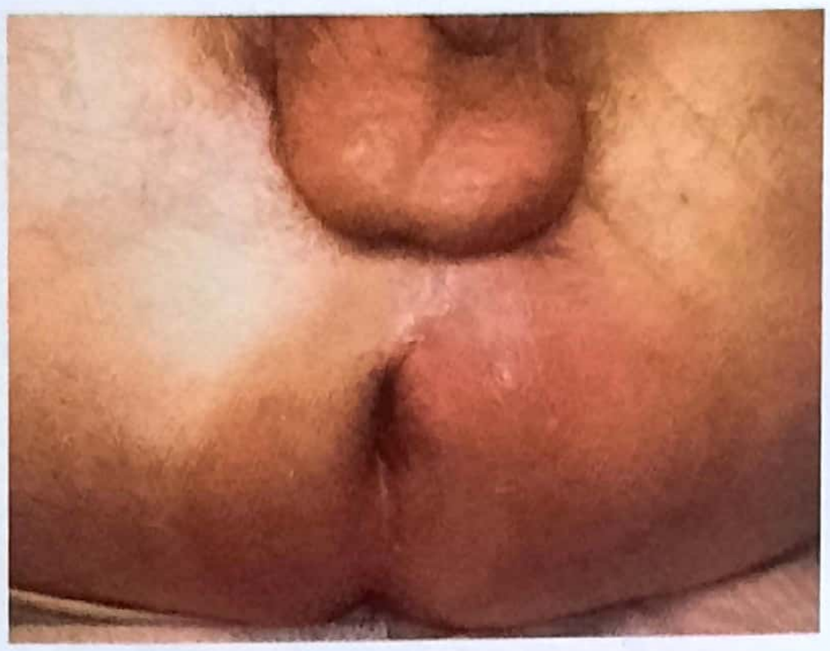

Figure 38.13.1: A patient with Perianal abscess (left)

Figure 38.13.2: Cruciate incision for perianal abscess

3. Sub mucous abscess (5%)

- This occurs above the dentate line and may occur following injection therapy for hemorrhoids. When it occurs after injection therapy; it almost always resolves.
- Abscesses are felt per rectum as a tense cystic bulge in rectal wall.

Treatment

It is opened with a sinus forceps through a proctoscope.

4. Pelvirectal abscess (5%)

- It is nothing but a pelvic abscess and is situated between the upper surface of levator ani & pelvic peritoneum.
- It occurs secondary to appendicitis, salpingitis, diverticulitis, parametritis or extension of ischiorectal abscess.
- Patient presents with fever, pain, mucous diarrhea.
- Urinary symptoms such as dysuria and strangury* may be present due to irritation of urinary bladder.

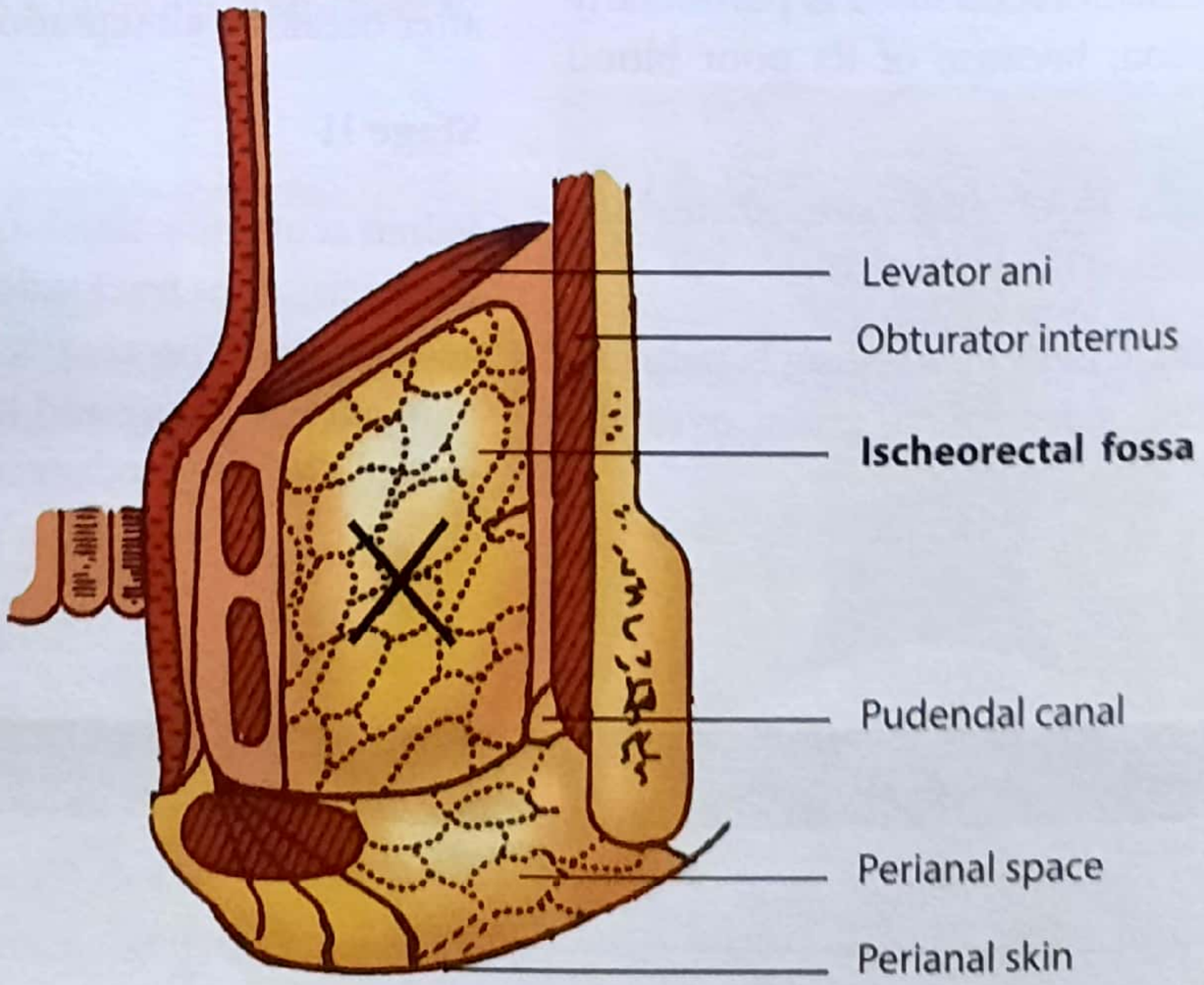

Figure 38.14: Ischiorectal fossa

Treatment

- Broad spectrum systemic antibiotics.
- Incision and drainage through anterior rectal wall in male or posterior fornix in female. (imp. point)

STRANGURY: Painful and interrupted urination in drops due to spasmodic muscular contraction of the urethra and bladder.

*****

Non-Malignant Anal Strictures

Stenosis of the anal canal lead to increasing difficulty and straining at stool with small, painful bowel movement.

Causes

1. *Postoperative:* Hemorrhoidectomy, Operation for imperforated anus in infancy.
2. *An anal fissure* causes spasm of anal sphincter which in time may become fibrotic and may lead to stricture.
3. *Irradiation:* exposure during treatment of malignant lesion of the pelvis.
4. *Lymphogranuloma inguinale*
5. *Inflammatory bowel disease:* Both ulcerative colitis and Crohn's disease result in rectal stricture.

Clinical feature

- Increasing difficulty in defecation is the leading symptom.
- In an inflammatory stricture, secondary to Ulcerative colitis or Crohn's disease, tenesmus, bleeding and passage of mucus is the main symptom.
- Digital examination of rectum reveals narrowing.

Treatment

1. Specific treatment of the primary disease.
2. Conservative treatment include bulk purgative and high fibre diet.
3. Regular anal dilatation may be required.
4. For severe stricture excision of the scar and anoplasty may be performed.
5. Colostomy may be needed when stricture is too tight and causing intestinal obstruction.

Proctalgia Fugax

- This disease is characterized by intermittent attacks of severe pain arising in rectum.
- The pain is described as cramp like, often occurs when the patient is in bed at night, usually lasts only for few minutes and disappears spontaneously.
- It seems to occur more commonly in patients suffering from anxiety or undue stress and is **also said to occur in young doctors.**
- The pain is possibly **due to segmental cramp in the pubococcygeus muscles.**
- Symptomatic treatment in form of analgesics and anxiolytics are beneficial.

*****

PRURITUS ANI

Perianal itching is a common problem in adults. In most cases; inadequate personal hygiene is the cause of pruritus ani and is **usually seen in the presence** of skin tags, perianal warts, hemorrhoids, anal fissures and fistulas, colloid carcinoma of rectum and carcinoma of anal canal.

Other causes

1. Fungal infections
2. Parasitic infestation with thread worms, intestinal tinea

Management

Treatment depends on the cause and to improve the personal hygiene. Idiopathic pruritus ani requires hygienic measures to keep anus and perianal regions clean and dry. Cotton underwear should replace nylon ones. If symptom's persist a carbolic lotion (1:100) should be applied with cotton wool; twice daily.

*****

CARCINOMA OF ANUS AND ANAL CANAL

- Malignant tumour of anal canal include **Squamous cell carcinoma** and a rare malignant melanoma.
- About 70% of anal tumours arise in anal canal and 30% at the anal verge.

- Carcinoma of anus and anal canal commonly occur in 6th-7th decade of life.
- **Predisposing conditions** are anal condyloma (caused by Human papilloma virus 16 and 18), HIV infection, crohn's disease and Anal Intra epithelial Neoplasia (AIN).
- There are three grades of AIN. Grade 1 is low-grade squamous intraepithelial lesion; grades 2 and 3 are often grouped together as high-grade squamous intraepithelial lesions and are associated with a higher risk of invasive cancer.
- Current treatments for AIN include ablative and topical therapies. Topical therapies include immunomodulators such as imiquimod, podophyllin, or 5-FU. Ablative therapies include surgical excision, IRC, and thermal ablation.

Pathology

- **Squamous cell carcinoma** of the anal canal arise in association with chronic irritation and poor hygiene.
- Chronic anal wounds (eg. fistula in ano), infections or radiation may expose to an increased risk of anal malignancy.
- *Squamous cell carcinoma is most common malignancy of anal canal.* (AIIMS JUNE 97)
- Human papilloma virus (HPV) and herpes simplex virus (HSV) type 2 has also been linked to malignant changes in anorectal region.
- Anal cancers tend to be locally aggressive with early invasion of the anal sphincters. Once the sphincter is invaded, the tumor can spread into the ischiorectal fossae, the prostatic urethra and bladder in men, and the vagina in women . Anal canal cancer grows circumferentially and may result in narrowing and stenosis of the anal sphincter. Lymphatic spread occurs in 10%.
- **Bowen's disease** is an example of Squamous cell carcinoma in situ, that rarely invades.
- **Basaloid carcinoma** is a form of nonkeratinizing Squamous carcinoma and can be highly malignant.
- Mucoepidermoid carcinoma arises near the squamocolumnar cell junction.
- **Verrucous carcinoma** is also referred to as *giant condyloma accuminata* or *Buschke-Lowenstein* tumour and is slow growing. (PGME)
- Melanoma presents as blue-black soft mass and is likely to be confused with a thrombosed piles.
- **Adenocarcinoma** of the anal canal **is rare** and originates from the anal ducts.
- Other tumours; such as lymphoma, leiomyosarcoma, rhabdomyosarcoma, carcinoid tumours can be found in relation to anus and anal canal.

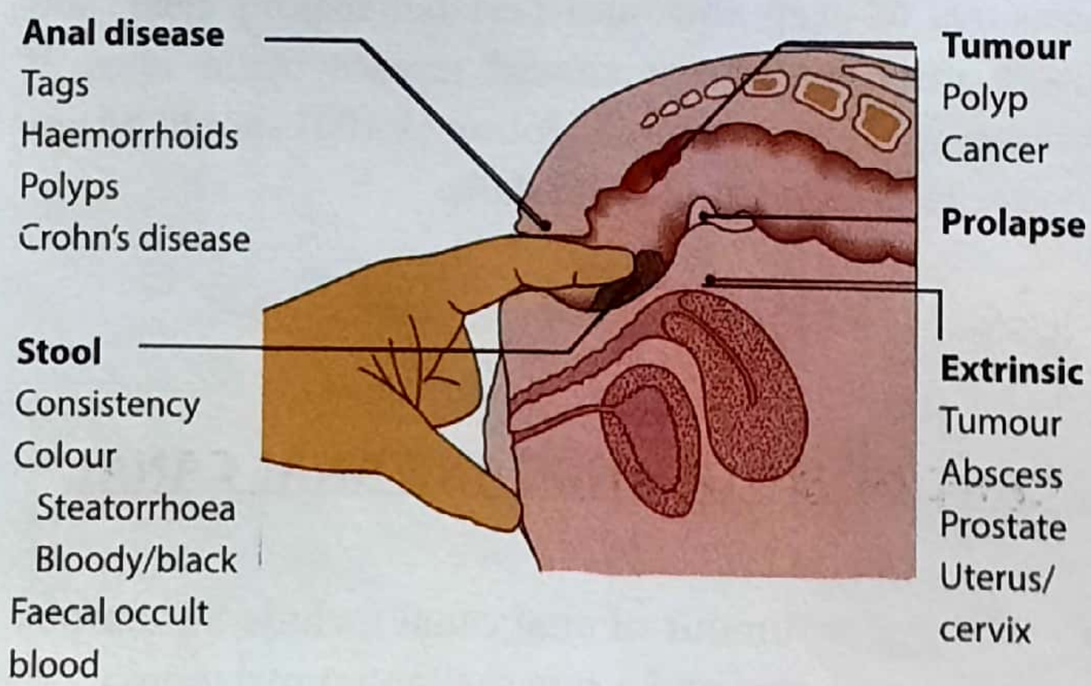

Figure 38.15: Per rectal examination

Figure 38.16: Squamous cell carcinoma of anal canal

Clinical feature

1. Symptoms are *rectal bleeding, mucus discharge, tenesmus,** sensation of a **lump** in the anus and a *change in bowel habit*. Occasionally; there may be a mass in the inguinal region due to metastases in the lymph nodes.
2. On digital rectal examination (DRE)* ulcerating hard, tender, bleeding mass in the anal canal or at anal verge can be noticed. (Fig. 38.16)

* DRE-digital rectal examination = (PR examination)

TENESMUS: Spasmodic contraction of anal canal with pain and persistent desire to empty the bowel but with out resultant evacuation. Patient often describes 'I feel, I want to go, but nothing happens'.

For Hindi speakers: Lagti hai par hotee nahee.

Treatment

(AIIMS NOV 02, AI 03,06,AIIMS FEB 97, AIIMS NOV 97, JUNE 98)

1. Tumours of the anal verge

For small lesions

Wide local excision leaving a margin of at least 2.5 cm of tissue all round *(PGME)* with block dissection of the inguinal nodes; if they are involved.

2. Tumours of the anal canal

- ***Nigro regimen*** *(NEET)*:- Organ presenation therapy by chemoradiation in anal canal cancers.
- **Chemoradiation is now the preferred initial therapy for all anal canal tumours** *(NEET, MANY PGME)*. The drugs used are 5-FU, mitomycin or combination of Adriamycin, Bleomycin & Cis-Platin (A+B+C). See box 38.8.
- In frail patients with an advanced lesion; a defunctioning colostomy may be the only available therapy.
- More than 80% are cured by chemoradiation. If any residual tumour is left behind after chemoradiation; then an abdominal perineal resection (APR) is performed. APR has been described on page no 687.

KEY BOX 38.8

Nigro's **protocal** -*(PGME)* 5 fluro-uracil, Mitomycin-c and 3000 cGy external beam radiation, other chemotherapeutic agents used are A , B, C. ie; **A**driamycin, and **B**leomycin and **C**is-platin.

NOTE: Chemotherapy is followed by radiotherapy and never reverse. This is a type of Neoadjuvant chemotherapy

Perianal Paget Disease

- Perianal Paget disease is thought to correspond to an intraepithelial adenocarcinoma arising from dermal apocrine sweat glands. Patients with this condition tend to present with nonspecific symptoms such as pruritus, discharge, or bleeding. The lesion appears as an erythematous plaque, which may be ulcerative and crusty or papillary. (Figure 38.17) Perianal Paget disease may represent primary (intraepidermal/intradermal) or secondary disease. Secondary disease is associated with anorectal adenocarcinomas. Approximately 50% of patients with anal margin Paget disease harbor a synchronous colorectal neoplasm, mandating full colonoscopy for complete evaluation. Patients with perianal Paget disease also frequently develop synchronous or metachronous malignancies of the adnexa and viscera. Wide local excision is recommended for most patients. The surgical defect created may require reconstruction with a cutaneous or myocutaneous flap. In the setting of a locally invasive lesion or a synchronous anorectal adenocarcinoma, abdominoperineal

Figure 38.17: Perianal Paget disease

resection with neoadjuvant chemoradiotherapy is usually indicated. The recurrence rate can be as high as 30% to 60% at 5 years. The frequent association with synchronous and metachronous malignancies and high recurrence rate highlight the importance of long-term follow-up.

*****

Sample Questions for Prof Examination

1. Describe the pathology, clinical features and management of suppurative conditions of anal canal.
2. How will you classify the perianal abscess & out line its management?
3. Classify various types of hemorrhoid, and how will you manage a case of IIIrd degree hemorrhoid.
4. Write short notes on

   Fistula in ano

   Pilonidal sinus

39 Trauma, Assessment and Management

Contents

- Death following trauma
- Mechanism of injury
- Triage
- Scoring system of injury severity
- Management of trauma patient

INTRODUCTION

Trauma, the leading cause of death and disability is equally prevalent in both developed and developing country. Today industrialization & urbanization and increased number of vehicles have brought trauma to door step of every strata of health care system. Whether it is thrasher injury; which lands up in PHC or an industrial accident; coming to an urban center or multiple injuries following road traffic accident brought to metro surgeon; the responsibility of surgeon remains the same.

Effective trauma management hinges on speed, accuracy and appropriate prioritization of surgical intervention.

*****

DEATH FOLLOWING TRAUMA

1. Immediate Death (50%)

Occurring immediately or within first few minute of injury due to widespread injury of brain, upper spinal cord, heart or major vessels. Little can be done in their management. Prevention is the only measure, which can effect out come of this phase.

2. Early Death (30%)

Occurring within first few hours after injury (called as golden hour of trauma). These are preventable death, occurring due to airways obstruction, disruptions of breathing mechanism, massive blood loss in body cavity and dysfunction of CNS. This became basis of ABCDE approach of trauma management. (Discussed later in this chapter)

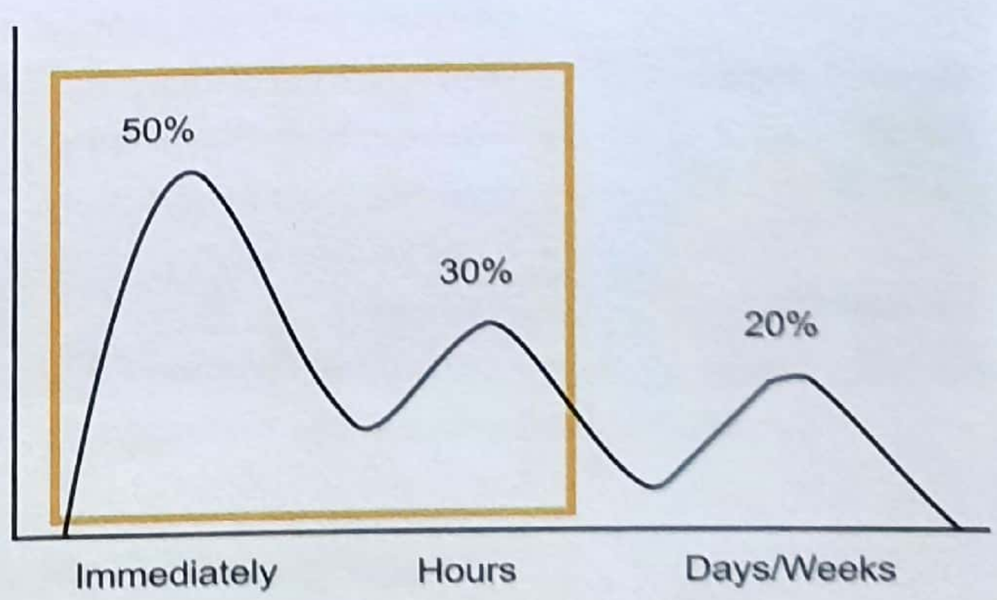

- Three peaks are observed
- 80% of deaths occurs in 1st hour after injury (golden hour)

Death following trauma (Trimodal distribution)

MECHANISMS OF INJURY AND SUSPECTED INJURY PATTERNS			
MECHANISM OF INJURY	**SUSPECTED INJURY PATTERNS**	**MECHANISM OF INJURY**	**SUSPECTED INJURY PATTERNS**
BLUNT INJURY			
Frontal impact, automobile collision • Bent steering wheel • Knee imprint, dashboard • Bull's-eye fracture, windscreen	• Cervical spine fracture • Anterior flail chest • Myocardial contusion • Pneumothorax • Traumatic aortic disruption • Fractured spleen or liver • Posterior fracture/dislocation of hip and/or knee • Head Injury • Facial fractures	**Rear impact,** automobile collision	• Cervical spine Injury • Head injury • Soft tissue Injury to neck
		Ejection from vehicle	• Ejection from the vehicle precludes meaningful prediction of injury patterns, but places patient at greater risk for virtually all injury mechanisms.
Side impact, automobile collision	• Contralateral neck sprain • Head Injury • Cervicalspine fr-acture • Lateral flail chest • Pneumothorax • Traumatlc aortic disruption • Diaphragmatic rupture • Fractured spleen/liver and/or kidney. depending on side of lm pact • Fractured pelvis or acetabulum	**Motor vehicle impact with pedestrian**	• Head Injury • Traumatic aortic disruption • Abdominal visceral injuries • Fractured lower extremities/ pelvis
		Fall from height	• Head injury • Axial splne Injury • Abdominal visceral injuries • Fractured pelvis or acetabulum • Bilateral lower extremity fractures (including calcaneal fractures)
PENETRATING INJURY		**THERMAL INJURY**	
Stab wounds • Anterior chest • Left thoraco-abdominal • Abdomen	• Cardiac tamponade if within "box" • Hemothorax • Pneumothorax • Hemopneumothorax • Left diaphragm injury/spleen injury/hemopneumothorax • Abdominal visceral injury possible if peritoneal penetration	**Thermal burns**	• Circumferential eschar on extremity or chest • Occult trauma (mechanism of burn/means of escape)
		Electrical burns	• Cardiac arrhythmias • Myonecrosis/compartment syndrome
Gunshot wounds (GSW) • Truncal • Extremity	• High likelihood of Injury • Trajectory from GSW/retained projectiles help predict Injury • Neurovascular injury • Fractures • Compartment syndrome	**Inhalational burns**	• Carbon monoxide poisoning • Upper airway swelling • Pulmonary edema

3. Late Death (20%)

Days or weeks after injury; due to sepsis or multiple organ failure (MOF).

*****

MECHANISM OF INJURY

1. Penetrating injury: It may be further divided into stab injury, bull horn injury, gun shot injury & missile injury.
2. Blunt injury.
3. Blast injury.
4. Thermal injury.
5. Chemical injury.
6. Others: Crush injury, barotrauma, seat belt injury.

Penetrating Injury

Penetrating injury of low velocity and low kinetic energy produces less tissue damage, where as high velocity injury with potential for high energy transfer causes extensive tissue damage. Penetrating injury from fire arm are related to ballistics of weapon, trajectory of missile and the target organ, wounding property of projectile depend on its kinetic energy and efficiency of energy transfer to tissue. Low velocity weapon are thought to produce injury predominantly by crush and tearing mechanism, where as high velocity missile in addition also produces tissue cavitation.

Blunt Injury

These injury result from combination of crushing, deforming, stretching and shearing forces. Injury result when sum of all these forces exceed the cohesive strength of tissue eg; fall from height, motorcycle injury, hit by some object.

Blast Injury

Explosion in open air produces blast pressure waves, which result from compression of air by explosive gases. These pressure waves move out ward from the site of detonation at very high speed and damage what ever come to its way. Hollow organs are more readily and extensively damaged by pressure wave, in the order of middle ear > Lungs > bowel > spleen. *(AIIMS 10)*

Thermal and chemical injuries have been discussed in chapter 9, [Burn; page 76-91] please read it from there.

*****

TRIAGE

Triage means; to *sort out causalities on the basis of severity of injury, chances of their survival and need of care, so* *that available resources can cope with situations.*
It is dynamic process; which needs to be repeated at each level of trauma care.

Goal of Triage

1. Identify high risk patients; who would be benefited from trauma care.
2. To limit excessive and unnecessary burden.

Triage is based on rapid assessment of four components simultaneously:

A. Physiological response of patient.
B. Injury anatomy
C. Mechanism of injury.
D. Co-morbid factors.

A. Physiological response of patients

Include evaluation of following factors.

- Systolic BP
- RR (respiratory rate)
- Revised trauma score

B. Injury Anatomy

Include evaluation of following situation; whether they are present or not.

- Penetrating injury to head, neck.
- Flail chest/tension pneumothorax.
- Pelvic fracture.
- Amputation of limb proximal to wrist.

C. Mechanism of Injury

Include of following mode of injury

- Ejection from automobile.
- High speed motor crash.

KEY BOX 39.0	
Red Flag	Immediate medical care
Yellow Flag	Urgent medical care
Green Flag	Whom treatment can be delayed
Blue Flag	No treatment is required
White/Black flag	For dead patients

- Fall from height.
- Gun shot injury
- Bomb blast injury
- Missile injury
- Stab/Blunt injury of abdomen.

D. Co-morbid Factors

- Age
- Cardiac/Respiratory disease.
- Diabetes mellitus, cirrhosis, obesity, pregnancy.
- Immunocompromised patient.

Colour Coding in Triage

Red Flag: For those who require **immediate medical** care, otherwise will die with in few minutes. *Example:* **Obstructed airway** *(AIIMS MAY 17)*, **tension pneumothorax, Cardiac temponade**.

Yellow Flag: For those, who **require urgent medical care** *(AIIMS NOV 17)*. These patients will die if not attended within 1-2 hours, eg; Craniocerebral injury, massive bleeding.

Green Flag: For those patient, in whom treatment can be delayed. Example; minor fractures.

Blue Flag: For those patient, no treatment is required, and any attempt to treat them at site of accident may cause unnecessary delay in the treatment of those patient who require medial attention.

White/ black flag: for. dead patients.

*****

SCORING SYSTEM FOR INJURY SEVERITY

Glasgow coma scale (GCS)

Level of consciousness is most important single parameter, which indicate severity and prognosis of head trauma. There are several classification scale available for recording the state of consciousness. The one, which is most commonly used all over world is GCS, which provides a practical guideline for initial and subsequent evaluation. It also help in finding out whether patient is static, improving or deteriorating. *(AI 06, 07) (PGI 09)*

1. Eye opening

Spontaneous	4
To voice	3
To stimulation	2
None	1

2. Motor response

To command	6
Localizes	5
Withdraw	4
Flexion	3
Extension	2
None	1

3. Verbal response

Oriented	5
Confused	4
Inappropriate	3
Incomprehensible	2
None	1
Total	15

By evaluating GCS score of a trauma patient, the severity of head trauma can be assessed clinically and prognosis can be predicted as follows *(AIIMS NOV 06, AI 07, AIIMS 10)*

GCS Score	Severity of head injury	Mortality
13-15	Mild	10%
9-12	Moderate	20%
3-8	Severe	70%

Revised Trauma Score (RTS)

This is a physiological scoring system; with high reliability and demonstrated accuracy in predicting death. It is

scored from the first set of data obtained on the patients and consists of Glasgow coma scale, Systolic blood pressure and respiratory rate.

GCS	BP (syst.)	RR	Coded Value
13-15	>89	10-19	4
9-12	76-89	>29	3
6-8	50-75	6-9	2
4-5	1-49	1-5	1
3	0	0	0

RTS = 0.9368 × GCS + 0.7326 × Syst BP + 0.2908 × RR

Trauma and injury severity score (TRISS) → Determines probablity of survival of a trauma patient using following variables :

(a) ISS (Injury severity score)

(b) RTS (Revised trauma score)

(c) Age

Mangled extremity severity score (MESS) → This system grades the injury on the basis of :

(i) The energy that caused the injury

(ii) Limb ischemia

(iii) Shock

(iv) The patients age

Values of the RTS are in the range 0 to 7.8408. A threshold of RTS < 4 has been proposed to identify those patients who should be admitted & treated in a special trauma center.

MANAGEMENT OF TRAUMA

Advanced Trauma Life Support (ATLS) Approach

(NEET)

ATLS management is based on treat lethal injury first, then reassesses the condition and treat again the minor injury, strategy. ATLS steps are as following:

1. Primary survey and resuscitation
2. Secondary survey
3. Definitive care

Now lets take them one by one:-

1. Primary Survey and Resuscitation

Primary survey is designed to identify life threatening conditions and treat them in order they are identified. The only investigations; that are permitted in this phase are following:

- Blood test for hematocrit and cross matching.
- X-ray cervical spine
- X-ray chest
- X-ray pelvis

Primary survey approaches, C, A, B, C, D, E sequences.

C. Control of massive external hemorrhage external hemorrhage from massive arterial bleeding needs to be controlled immediately even before airway is managed by packs and pressure directly on bleeding wound & artery.

A. Airway management & cervical spine control

Assuring the integrity of airways is highest priority in trauma care. Loss of airway function causes irreversible brain damage within minutes. During handling of airway

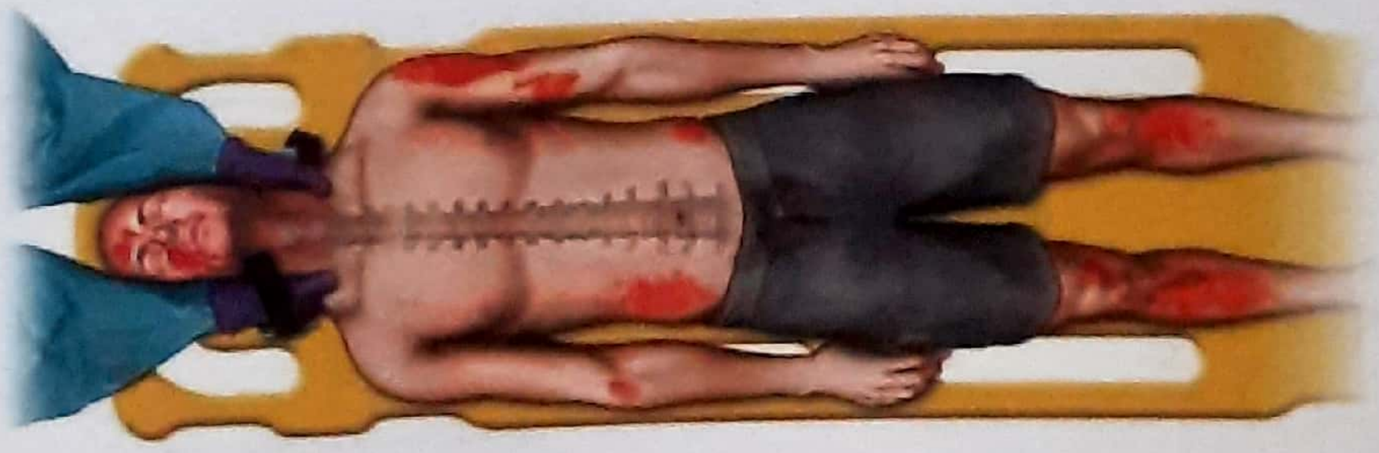

Figure 39.1: Cervical spine motion restriction technique

management cervical spine injury must be suspected until it is excluded. **Therefore priority is to establish airway with utmost care of cervical spine**. Following steps are taken in order to secure airway: (Figure 39.1)

- Suction of mucous and vomitus.
- Jaw thrust maneuver.
- Endotracheal intubation
- Crico-thyrotomy; if necessary
- ***Cervical spine is immobilized*** in neutral position by well fitting neck brace, sand bag or head tape, (**most imp step in management**) *(NEET, MANY PGME)* (Figure 39.1)
- Patient is shifted for X-ray on same trolley with neck collar & stabilization. *(AIIMS MAY 17)*

B. Breathing (Ventilation)

Once airway is established, trachea should be ventilated with 100% oxygen. Neck and chest are exposed. Examination involves inspection, palpation, percussion & auscultation of chest.

(i) Inspection: Observe for following:-

- Any external injury
- Condition of neck veins
- Evidence of tracheal injury
- Respiratory rate and effort
- Chest symmetry
- Any abnormal movement.

(ii) Palpation: for any rib fracture or depressed skull fractures.

(iii) Percussion: For any evidence of hemothorax or pneumothorax.

(iv) Auscultation: for air entry in chest.

C. Circulation

Initial assessments of circulation include characterization of following vital parameters.

- Pulse rate, blood pressure.
- Skin perfusion assessed by capillary refill time.
- Organ perfusion assessed by urine output and mental status.
- Tachycardia in cold patient indicates shock.
- Following *type of shock* can exist in poly traumatized patient.
  - *Hypovolemic:* due to external or internal bleed
  - *Cardiogenic:* due to cardiac tamponade, tension pneumothorax or myocardial contusion.
  - *Neurogenic:* due to spinal injury.

Early management of shock begins with assessment of degree of blood loss. (This has been discussed in detail in chapter 2; shock).

Treatment of shock is an emergency, which start with access of two large bore venous line, obtain blood specimen for cross matching and infusion of balanced salt solution (RL). In adults 1 lit. *(AIIMS NOV 18)* of solution is recommended as initial fluid challenge. In children it is calculated as 20ml/kg/24hr.

Patient should now be reassessed for response. Three types of response may be observed :

- *Immediate and sustained return to normal vital:* These patients have likely less than 20% of blood loss and bleeding would have ceased spontaneously.
- *Transient response with later deterioration:* These patient may have continuous intra-abdominal or intrathoracic bleed and surgical intervention is required.
- *Non-responder:* These patients are either bleeding actively or shock is nonhemorrhagic in nature. Hypovolemic patients who have lost more than 40% of blood volume demand urgent surgical intervention. Adequacy of shock therapy is best judged by assessment of end organ perfusion.
- ***Urine out put is the best indicator of assessing the end organ perfusion on going resuscitation*** *(NEET, MANY PGME)*. In general; resuscitation should continue until an adult produces 50-75ml of urine/hour (for children 1-2ml/kg/hr).

D. Disability assessment

It is result of dysfunction of central nervous system and these are responsible for preventable traumatic death and disability. Hence; an accurate and early assessment of neurological status forms key element of primary survey.

Two critical parameter, which must be assessed through out resuscitation are level of consciousness and lateralizing sign.

Level of consciousness is assessed quickly by using the **AVPU system** (ascertaining whether the patient

is Awake, open eyes to Voice, opens eyes to Pain or Unarousable).

Other sign of significant neurological injury are gross asymmetry of limb motion in response to painful stimulus and asymmetry of pupils in the response of light.

E. Exposure (of patient)

Last component of primary survey is exposure with environmental control. Patient may be completely undressed by cutting away of clothes.

A visual inspection of entire patient including back and perineum should be done. The resuscitation room should be kept as warm as possible. Fluid administered to the patient should be warm and warm blanket should be provided to keep warm.

Polytrauma patient back examination done by log roll method.

It is a method used to move patient to prevent spine injury but should not be used untill pelvic fracture has been radiographically ruled out at it may dislodge any pelvic blood clot. Minimum 4 peoples are required for log rolling.

Patient are shifted on supine position.

RECAP: We were discussing primary survey of a trauma patient, now we will discuss secondary survey with definitive care of the patient. Please go to page 722; once again and revise.

Before proceeding further, kindly go through key box 39.2.

2. Secondary Survey (With Definitive Care)

Secondary survey is often described as head to toe examination with insertion of tube and finger into each orifices in a stable patient. During this phase detailed radiographic procedures including CT scan and USG may be performed and even MRI should be performed, if indicated.

This phase is actually a phase of surgical decision making based on detailed head to toe examination and diagnostic protocol. Diagnostic protocol of a polytrauma patient is summarized in chart given below (key box 39.2). Examination may be conducted in an order. The description here starts with head and proceeds distally.

Assessment of Head Trauma

Assessment of head trauma should be done in following order:

- History-History of unconsciousness, history of vomiting, convulsion, ENT bleeding.
- Inspections and palpation.

KEY BOX 39.1

Physical examination of a trauma patient (Primary surgery)

Stable vitals

- Base line investigations
- **X-ray cervical spine**
- X-ray skull, **CT scan** *(AIIMS MAY 17)*

Unstable vitals

- Head injury-X-ray skull, CT scan
- Spinal injury-X-ray spine
- **Thoracic injury-X-ray chest**, ECG, ECHO, blood gas analysis, aortogram.
- Abdominal injury- DPL, USG, CT scan, proctosigmoidoscopy, analysis of RT aspirate.
- Genitourinary injury-urinalysis, IVP, retrograde urethrogram, CT scan.
- **Pelvic injury-X-ray pelvis**, CT scan, angiogram.

KEY BOX 39.2

Tablular representation of initial evaluation with simultaneous diagnostic and therapeutic intervention in poly traumatized patient

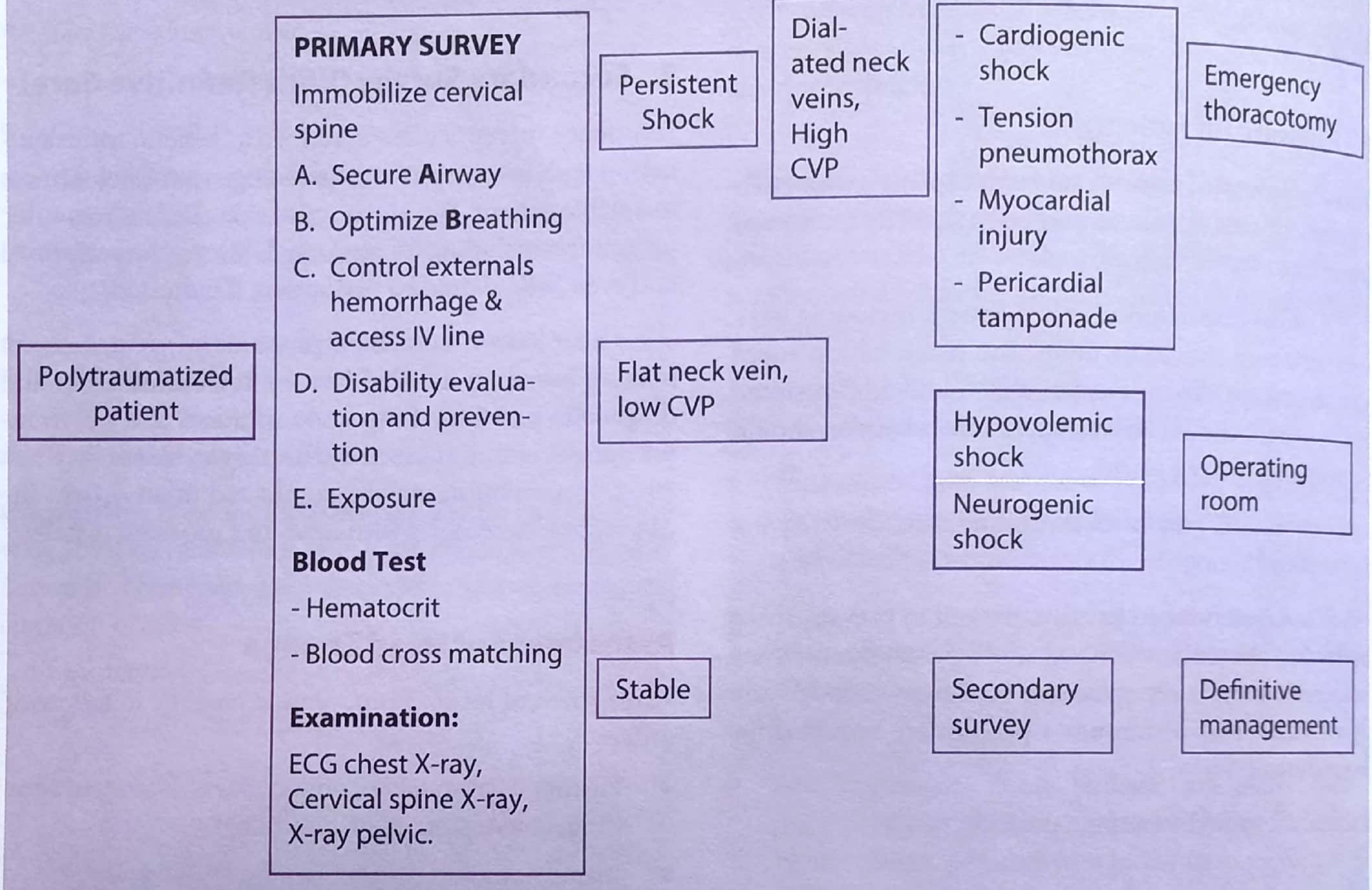

- Level of consciousness-by GCS score.
- Pupil- it's size and reaction to light.
- Extra-ocular movement.
- Examination of sensory and motor system.
- Various reflexes, sphincter tones.
- Systemic causes of mental status impairment.

Types of Head Injury

1. ***Scalp injury*** In form of laceration, abrasion and hematoma.
2. ***Skull injury***
   A. *Simple linear fracture* - needs no specific treatment.
   B. *Depressed skull fracture* may occur as a result of blunt trauma. Dura & brain may be lacerated. Surgery is indicated to prevent risk of infection, to prevent mass effect and for cosmetic purpose.
   C. *Base of skull fracture*- These are diagnosed on clinical grounds. Anterior fossa fracture present with sub-conjunctival hematoma, epistaxis and CSF rhinorrhea. Middle fossa fracture presents with CSF otorrhea, rhinorrhea, hemotympanum and **battle sign**. (Periorbital hematoma indicate subgaleal hemorrhage and not necessarily base of skull fracture). These injuries can be managed nonoperatively with antibiotics. If leaking of CSF continues or recurs; then lumbar drain or surgical repair may become required.

3. ***Brain injury***

A. ***Cerebral concussion*** - It is manifested as temporary dysfunction and resolve after variable period of time. Amnesia for events, lethargy, irritability and memory dysfunction is hallmark of these injuries.

B. ***Cerebral contusion/laceration***- These injury usually produces neurological deficit and persist for longer than 24 hours.

C. ***Diffuse axonal injury*** - This is as a result of shearing forces on brain. Severity vary from mild confusion to coma or even death.

D. ***Intra cerebral hematoma***- These appear as hyperdense lesion on CT with associated mass effect and mid line shift.

E. ***Extra dural hematoma*** - Result of fracture of temporal bone with laceration of *middle meningeal artery,* (MANY PGME). There is typically a *lucid interval* following trauma (MANY PGME). Frequently patient present in coma and required urgent evacuation.

F. ***Sub dural hematoma*** - Result from torn bridging veins (MANY PGME). This is associated with high velocity trauma with poorer outcome.

G. ***Chronic sub dural hematoma***- *Most* commonly seen in infant and old person. They present with progressive neurological deficit more than two weeks after trauma.

H. ***Cerebral swelling (edema)***- Results from vascular engorgement probably due to loss of autoregulation.

I. ***Cerebral ischemia***- Results in severe head trauma and caused by combination of cerebral hypoxia and impaired cerebral perfusion.

- All above conditions have been discussed in detail in chapter 14 page 148-155.

Management of Head Trauma

Management of head trauma with ABCDE approach of ATLS guides line.

- Recording of base line parameters.
- Head elevation.
- IV line and Foley's catheter to be inserted.
- IV fluids to maintain normovolemia & electrolyte balance.
- Normothermia to be maintained.
- Antibiotic prophylaxis indicated in following situation:
  - Patient with low GCS (<8)
  - Patient on artificial ventilation.
  - Unconsciousness of more than 24 hours.
  - Compound head injury.
  - Associated co-morbid factors.
  - Patients below 5 year or more than 60 years of age.
- ***Prophylactic anticonvulsant*** - indicated in following:
  - Known epileptics
  - H/O convulsion
  - Compound head injury
  - Depressed skull fracture
  - Prolonged unconsciousness
  - Intracranial hematoma
  - Intracranial infection
- **Management of elevated ICP** (MANY PGME) Best method to monitor ICP is by an *intraventricular catheter.* (IMP. POINT). Drugs; which are used to lower ICP are:
  - MANNITOL- Reserved for life threatening condition.
  - STEROID: can reduce increased ICP resulting from vasogenic edema, however it's use is controversial.
  - FURSEMIDE: reduces ICP by reducing cerebral edema and CSF production.
  - HYPER VENTILATION - reduces cerebral blood flow, and thereby reduces ICP. (IMP. POINT)
- Endo tracheal intubation and controlled ventilation should be instituted in patient's with poor respiratory effort or with GCS 8 or below.

Assessment of Chest Trauma

Secondary survey of thorax, start by repeating the steps on thoracic assessment performed in primary survey, re-inspect the position of the trachea. Observe for symmetric excursions of the chest, palpate for fracture and subcutaneous emphysema and auscultate for quality and location of breath sounds.

- Lacerations that do not enter the chest wall are handled in usual fashion.
- Visible punctures into the pleural space constitute an open pneumothorax and are treated with a combination of partially occlusive dressing and immediate tube thoracostomy.
- Emergent needle insertion and intercostal tube drainage introduced laterally and directed to apex of pleural cavity is done to treat tension pneumothorax.
- ***Flail Chest***: This occur when several adjacent ribs; (≥ 3 ribs) fracture in two places either on one side of chest or either side of sternum. If it is small and not causing respiratory embarrassment, patient may be treated with good analgesia, strapping and blood gas analysis. In severe cases ET (endotracheal) intubation with positive pressure ventilation is required for up to 3 weeks. Please see key box 39.3.
- ***Hemothorax:*** Usually treated by tube thoracostomy. However patient who initially drain more than 1500 ml of blood (following the initial evacuation of blood) or have an ongoing blood loss that will exceed 100ml/hr for 6 continuous hours required prompt thoracotomy, for controlling bleeding in the operation theatre (OT). Please see key box 39.3.
- Ruptures of Bronchus, esophagus, diaphragm or cardiac tamponade also require open thoracotomy, if needle aspiration is failed.
- ***Pulmonary contusion:*** It is the most common consequence of blunt thoracic trauma. This usually resolves with time, but laceration with persistent leak may require exploration of thorax. The contused site is often well perfused but hypoventilated. This V-P mismatch causes severe hypoxemia. If saturations con not be maintained above 92%; the patient should be intubated and ventilated; maintaining continuous positive airway pressure.
- ***Rib fractures***:- Fracture of the first rib alerts a serious chest injury and may be associated with injuries of great vessels, abdomen, head and neck. Fracture of the lower rib on left side may be associated with spleen injury and on right side; liver injury. In fracture of sternum there is a real risk of myocardial injury and patient should be monitored in hospital with constant ECG monitoring, analgesia and serial cardiac enzymes. All such fractures trigger a progression of pain, atelectasis and hypoxemia. It is important to prevent this progression through the use of adequate analgesia. Where multiple fracture are present; consideration should be given to intercostal blockade with local anesthetics. Once the pain is controlled; vigorous breathing exercise will reverse atelectasis and hypoxemia. (PGI 08)
- Best approach to thoracic trauma is anterolateral thoracotomy.

KEY BOX 39.3

Immediate life threatening Thoracic conditions	Immediate treatment
Tension pneumothorax	Needle thoracocentesis
Massive hemothorax	Vigorous support of circulation followed by tube thoracostomy
Open pneumothorax	Dressing secured on the side, followed by tube thoracostomy
Flail chest	Strapping & may require endo tracheal intubation. (PGI JUNE 07)
Cardiac Tamponade	Needle pericardiocentesis

Assessment of Abdominal Injury

The purpose of secondary survey of abdomen is to answer whether the intra abdominal injury has occurred or not. Abdominal trauma patient can be divided in two groups based on mechanism of injury :

- Penetrating injury of abdomen
- Blunt injury of abdomen

Penetrating Injury of Abdomen

This may be either due to stab injury or gun shot injury. There is 90% probability of significant intra abdominal injury & plans should be made for immediate operation. Stab wounds are classified is 3 groups

- One third do not penetrate into peritoneal cavity.
- One third penetrate but do no damage to viscus.
- One third penetrate and causes significant injury. Please see Key box 39.4.

Blunt Injury of Abdomen

These patients are evaluated according to three scenarios:

1. Unstable patients whose injuries are confined to abdomen may required urgent laparotomy.
2. Critically ill and unstable patients with multiple injuries and uncertainty whether the site of injury is abdomen or not. In this case DPL is preferred.
3. Multiple injured patients with relatively stable vital in whom an abdominal injury even present does not constitute immediate life threat. These patients are kept under observation.

Details of abdominal trauma is discussed in next chapter.

Please see key box 39.5, on next page

Notes on DPL

Diagnostic Peritoneal Lavage (DPL)

Here, I will like to describe DPL, I have described it in detail because you may not get enough text on this in various text book.

Routine abdominal investigations including CT scan and ultrasound have certain limitations including availability of equipment and expertise. These are time consuming procedures as well. Some times it becomes necessary to safely rule out any internal injury to the abdomen before the patient is taken to surgery for other problems like intracranial and skeletal injuries. The most sensitive & specific test that will indicate the presence or absence of intra-abdominal trauma is "diagnostic peritoneal lavage (DPL)".

Objective

- To find out if there is enough blood in the peritoneal cavity to suspect a bleeding viscus.
- To find if there is any injury to the intestine.

Procedure

As a first step, the urinary bladder is decompressed bypassing a foley's catheter and a nasogastric tube is passed to empty the stomach.

- Preparation of the entire abdomen is done using povidone Iodine solution
- 1% xylocaine with adrenaline is injected in the midline between the umbilicus and suprapubic area about 1/3rd of the distance from the umbilicus. In

KEY BOX 39.4

Decision Algorithm for Evaluation of Penetrating Abdominal Trauma

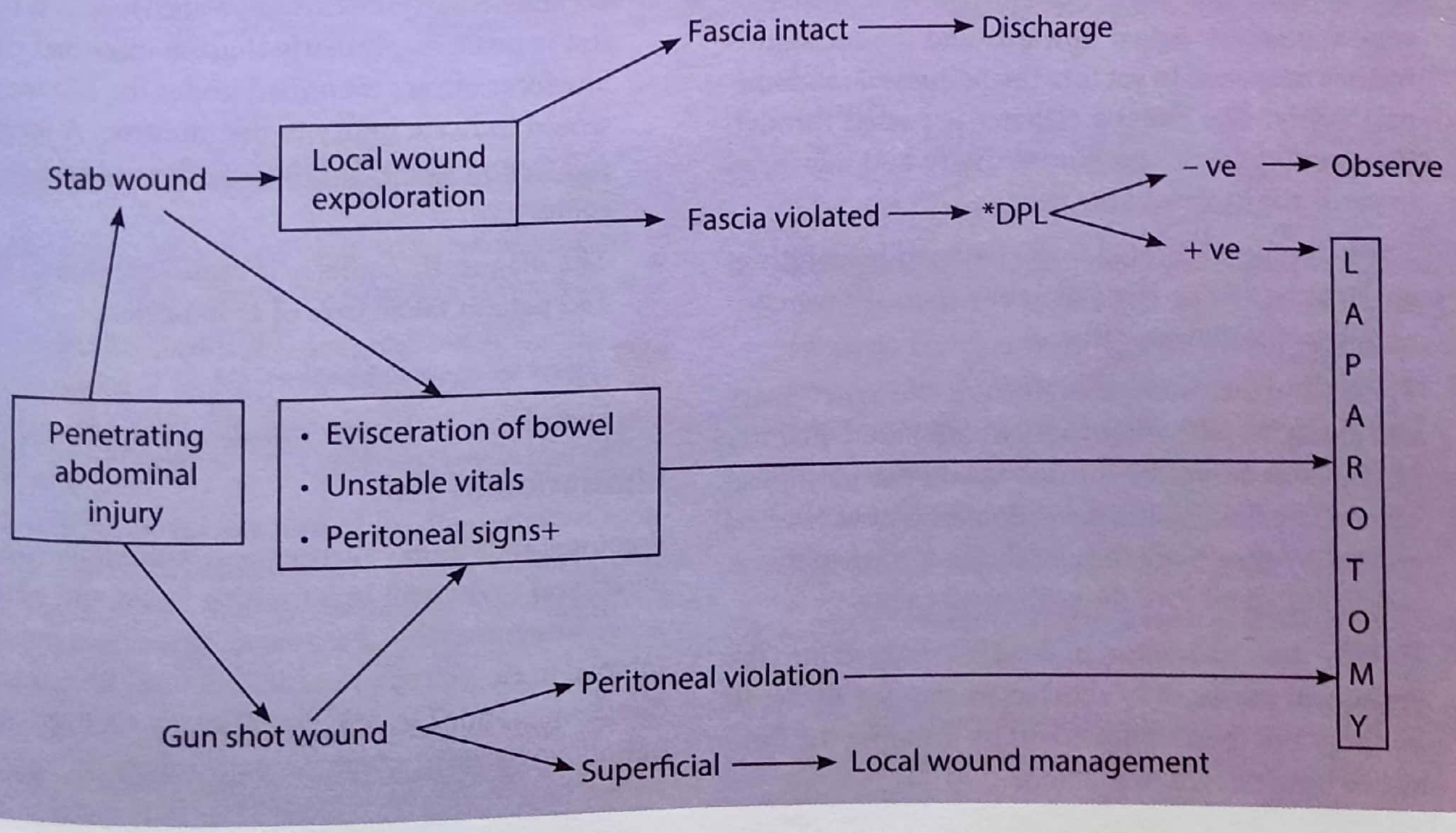

KEY BOX 39.5

Decision Algorithm for Evaluation of Blunt Trauma Abdomen

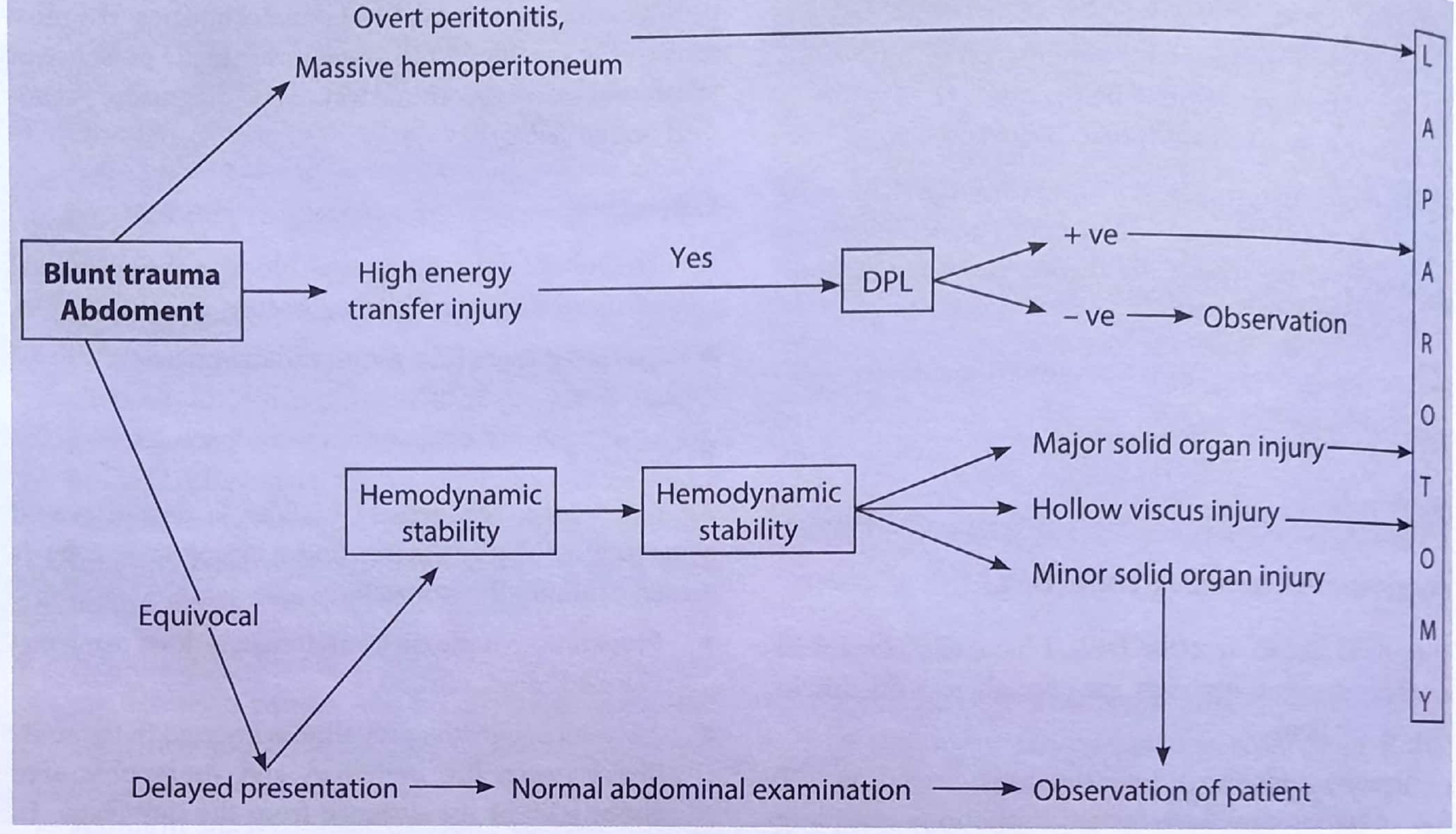

the anesthetized area of the middle a vertical skin incision is made with a 15 blade knife for about 2 cm and dissection is carried down to the fascia. At this point, fascial edges are grasped with *Alice* forceps and gently pulled upwards and the incision is further deepened to get into the peritoneal (abdominal) cavity. The dialysis catheter is passed through the opening in the peritoneal cavity and advanced towards the hollow of the pelvis.

- The I.V. tube connected to the bottle or bag of Ringers lactate (RL) or Normal Saline (NS) is now connected to the dialysis catheter.
- The wound is closed with a stitch or two as necessary and about 10-ml/kg-body weight measured quantity of the fluid is rapidly infused inside the peritoneal cavity. The fluid inside the abdomen is now swished around by gentle agitation of the abdomen so that it is distributed all over the peritoneal cavity.
- One the desired amount of fluid has entered into the peritoneal cavity, it is allowed to stay for up to 10 minutes and then siphoned off by bringing the fluid bag or bottle down to the floor.
- If the returning fluid is clear, obviously there is no gross internal injury to the abdomen and no major hemorrhage. Counts more than 100,000 RBCs or 500 leukocytes/cumm would indicate that the test is positive. Similarly if gross intestinal contents like feces etc are identified under the microscope, it would indicate injury to the intestine. *A positive result wound mean that the patient would require laparotomy*
- The diagnostic catheter is removed, wound dressed and patient taken care of as indicated.

Please see figure 40.1, page no. 732

Limitation of Test

Previous abdominal surgery and adhesions inside the peritoneal cavity will be a limiting factor and render the procedure unreliable. Peritoneal lavage does not rule out injuries to the retropentoneal structures like pancreas or duodenum and (D2, D3, D4) also any small perforation of hollow viscus or diaphragmatic injury.

Comparison of DPL, FAST, and CT in Abdominal trauma			
	DPL	**FAST**	**CT SCAN**
Advantages	• Early operative determination • Performed rapidly • Can detect bowel injury • No need for transport from resuscitation area	• Early operative determination • Noninvasive • Performed rapidly • Repeatable • No need for transport from resuscitation area	• Anatomic diagnosis • Noninvasive • Repeatable • Visualizes retroperitoneal structures • Visualizes bony and soft-tissue structures • Visualizes extraluminal air
Disadvantages	• Invasive • Risk of procedure-related injury • Requires gastric and urinary decompression for prevention of complications • Not repeatable • Interferes with interpretation of subsequent CT or FAST • Low specificity • Can miss diaphragm injuries	• Operator-dependent • Bowel gas and subcutaneous air distort images • Can miss diaphragm, bowel, and pancreatic injuries • Does not completely assess retroperitoneal structures • Does not visualize extraluminal air • Body habitus can limit image clarity	• Higher cost and longer time • Radiation and IV contrast exposure • Can miss diaphragm injuries • Can miss some bowel and pancreatic injuries • Requires transport from resuscitation area
Indications	• Abnormal hemodynamics in blunt abdominal trauma • Penetrating abdominal trauma without other indications for immediate laparotomy	• Abnormal hemodynamics in blunt abdominal trauma • Penetrating abdominal trauma without other indications for immediate laparotomy	• Normal hemodynamics in blunt or penetrating abdominal trauma • Penetrating back/flank trauma without other indications for immediate laparotomy

Damage control surgery

- Is one of the major advances in surgical practice in the last 20 yrs in the management of trauma.
- It defers the traditional surgical teaching that, the first chance of any surgical intervention is the best chance for any definitive repair or reconstruction with good result.
- The **conventional method of management of trauma patients** was to bring the patients to the operating room after initial resuscitation, and to operate for **complete repair of the injuries**. Even patients with multiple complex injuries were operated aggressively over a **prolonged period of time for definitive primary repair**. Subsequently these patients were sent to the ICU where a good number of them died due to **metabolic derangements**.
- Recognising that the cause of death in the major trauma victims was **not due to failure of the initial surgery**, but due to metabolic derangements or the physiological alterations in the body following severe exsanguinating polytrauma, a new method of management evolved called as Damage Control Surgery or Staged Laprotomy.
- In Damage control surgery, there are 3 phase:

  Ist Phase – only abbreviated laprotomy is done for life saving measure, then in

  IInd phase – patient is sent to ICU for the correction of metabolic disorders

IIIrd phase – following satisfactory correction of metabolic disorders, the patient is brought again to the operating room – this time for planned definitive surgery.

- The initial focus is haemorrhage control, followed by control and limitation of contamination, achieved using a range of abbreviated techniques including simple ligation of bleeding vessels, shunting of major arteries and veins, drainage, temporary stapling of bowel and therapeutic packing. Following the above, the abdomen is closed in a temporary fashion using a sheet of plastic over the bowel, an intermediate pack to allow suction and a further sheet of adherent plastic drape to the skin to form a watertight and airtight seal. Suction is applied to the intermediate pack area to collect abdominal fluid. As soon as control has been achieved the patient is transferred to the intensive care unit where resuscitation is continued. The next stage following damage control surgery and physiological stabilisation is definitive surgery. The team should aim to perform definitive anastomoses, vascular reconstruction and closure of the body cavity within 24–72 hours of injury. However, this must be individualised to the patient, the response to critical care resuscitation and the progression of injury complexes.

The stages of damage control surgery	
Stage	
I	Patient selection
II	Control of haemorrhage and control of contamination
III	Resuscitation continued in the intensive care unit
IV	Definitive surgery
V	Abdominal closure

- The abdomen is closed as soon as possible, bearing in mind the risks of abdominal compartment syndrome (ACS). The closure is not without its own morbidity. Successful closure may require aggressive offloading of fluid and even haemofiltration to achieve this if the patient will tolerate it. The best situation is closure of the abdominal fascia, or, if this cannot be achieved, then skin closure only. Occasionally, mesh closure can be used, with skin grafting over the mesh and subsequent abdominal wall reconstruction.

*****

Indications for damage control surgery	
Anatomical	Inability to achieve haemostasis Complex abdominal injury, e.g. liver and pancrease Combined vascular, solid and hollow organ injury, e.g. aortic or caval injury Inaccessible major venous injury e.g. retrohepatic vena cava Demand for non-operative control of other injuries, e.g. fractured pelvis Anticipated need for a time-consuming procedure
Physiological (decline of phsiological reserve)	Temperature <34°C pH <7.2 Serum lactate >5 mmol/L (normal: <2.5 mmol/L) Prothrombin time (PT) >16 s Partial thromboplastin time (PTT) >60 s > 10 units blood transfused Systolic blood pressure <90 mmHg for >60 min
Environmental	Operating time >60 min (core temperature loss in usually 2°C/h) Inability to approximate the abdominal incision Desire to reassess the intra-abdominal contents (directed relook)

40 Abdominal Trauma

Contents

- Mechanism of injury
- Diagnosis of abdominal injury
- Blunt abdominal trauma
- Penetrating abdominal trauma
- Abdominal compartment syndrome

Civilian trauma remains the fourth leading cause of death and is the most frequent cause of mortality in person under 45 years of age. More than half of these trauma related deaths are as a result of motor vehicle accident; other common causes include fall from height, gun shot or stab wounds. 15-20% patients following blunt trauma require operative intervention, additionally, as many as one-third of these patients require urgent abdominal exploration, (laparotomy)

BLUNT ABDOMINAL TRAUMA

Mechanism of injury

Blunt trauma to abdomen may be caused by motor vehicle accident, motorcycle accident, fall from height, interpersonal violence. Please see key box 40.1.

Diagnosis

Upon survival to hospital, history and physical examination are usually helpful in determining the intra-abdominal injury; in awake and responsive patients. The history of the traumatic event is particularly important in determining the likelihood of an intra abdominal organ injury. Many patients with moderate intra-abdominal bleed are seen in compensated hemodynamic condition (i.e; near normal blood pressure) and do not have peritoneal signs. Further more retro-peritoneal and pelvic injury cannot be ruled out based only on physical findings. An objective abdominal evaluation is necessary and should be obtained by using any of the available diagnostic modalities in addition to the physical examination. The test of choice depends upon the hemodynamic stability of the patient, and severity of associated injuries.

Hemodynamically stable patients sustaining blunt trauma abdomen are adequately evaluated by abdominal USG or CT-scan, unless other severe injuries take priority and patient needs to go to operative room before abdominal evaluation. In these patients a DPL is usually performed in operating room on operating table.

Read DPL on page no, 727

1. Plain Radiographs

The chest X-ray, is a useful test to reveal pneumo-perito-neum, abdominal content in chest (ruptured hemidiaphragm) or lower rib fractures. This later sign increase the probability of splenic and hepatic injury.

KEY BOX 40.1	
Blunt abdomen and pelvic injury pattern	
• Direct impact energy	• Associated regional injury
• Lower right rib fracture	• Liver disruption
• Lower left rib fracture	• Splenic disruption
• Mid epigastric contusion	• Duodenal perforation/ intestinal transaction
• Lumbar transverse process fracture	• Renal injuries
• Pelvic fracture	• Bladder & urethral injury

2. Abdominal paracentesis* and Diagnostic Peritoneal lavage-(DPL)

A four quadrant tap has been found to be better than bilateral flank approach. The overall accuracy for four quadrant tap has been found to be about 80%. A positive tap consists of obtaining 0.1 ml of blood or more, however; a negative tap does not rule out intra-abdominal hemorrhage. (Figure 40.1)

This has led to diagnostic peritoneal lavage (DPL). DPL is rapid and accurate test to identify intra abdominal injury after blunt trauma. Anterior abdominal and flank wound can be accurately evaluated by DPL.

DPL has been despribed in detail on page of previous chapter, do read it from there.

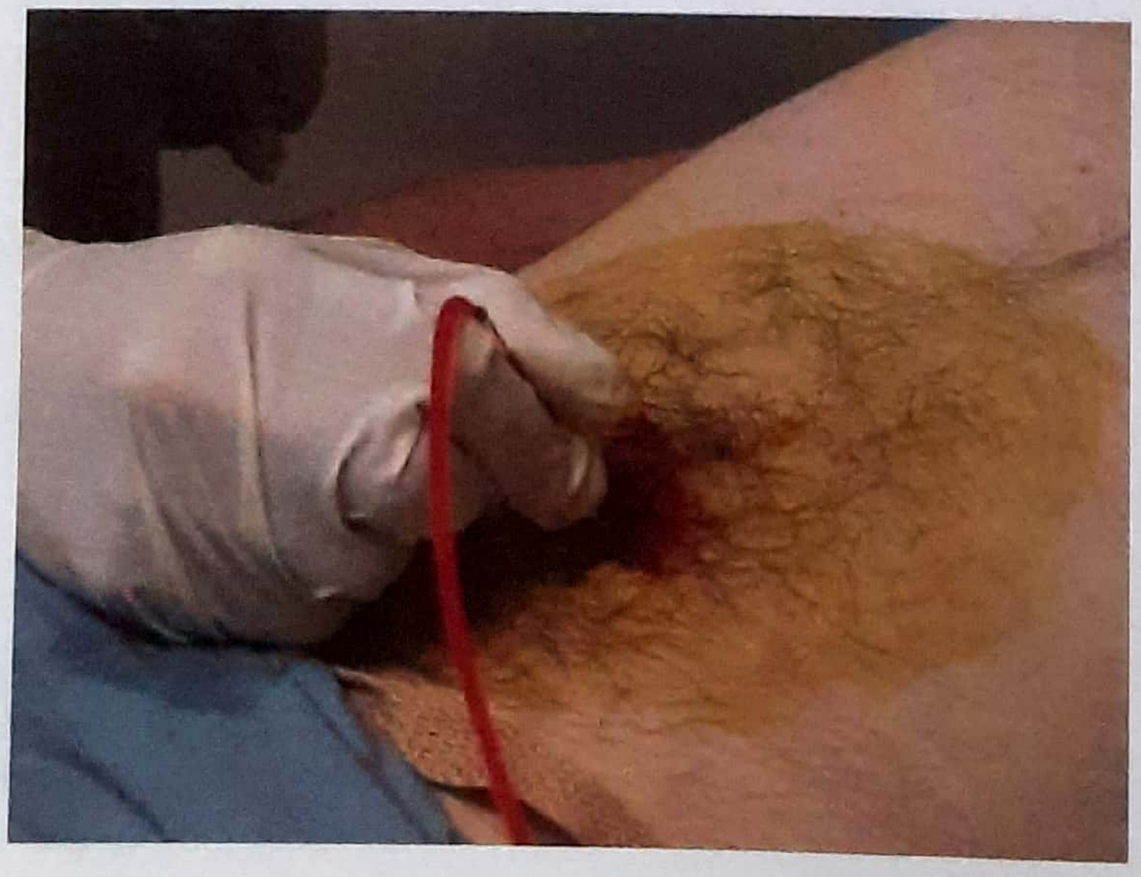

Figure 40.1: Diagnostic peritoneal lavage (DPL)

PARACENTESIS: Puncturing abdominal cavity by a needle and syringe and doing aspiration of fluid.

3. Ultrasound

USG is more frequently used in recent years in the evaluation of blunt trauma abdomen and is often the first investigation. The objective of USG evaluation is to search for free intraperitoneal fluid. It can also evaluate the liver and the spleen, once the free fluid is identified. The sensitivity ranges from 85-99% and specificity from 97-100%.

It is 1st investigation in abdominal trauma.

e-FAST - e-FAST is extended FAST.

Areas scanned in e-FAST are -

1. Sub Xiphoid region - heart & pericardial cavity.
2. RUQ (Right upper quadrant)
3. LUQ (Left upper quadrant)
4. Pelvis
5. Bilateral thoracic area

e-FAST is least useful in diagnosing retroperitoneal hematoma. *(AIIMS JUNE 20)*

4. Focussed abdominal sonography for trauma (FAST) *(NEET, AIIMS JUNE 20, AIIMS 09)*

This is a modification of the conventional USG abdomen to identify intraperitoneal free fluid.

It can rapidly identify any source of hemorrhage in the peritoneal cavity in trauma patients, who are too unstable to undergo CT scan. *(NEET)* It is useful to evaluate those patients without major risk factors for abdominal injury, who do not require more extensive evaluation of abdominal cavity.

It is 90% sensitive 99% specific and 98% accurate for intra-abdominal injury. It is portable, non invasive, rapid and easy. It can detect as little as 100 ml fluid in the peritoneal cavity. It uses a 3.5 MHz transducer and one can complete the abdominal examination in 2 1/2 minutes. It detects free fluid in pericardial sac, hepatorenal (morrison's) pouch, splenorenal recess and pelvis.

Standard practice is to keep the transducer at 4 different positions. *(IMP. POINT)*

1. Sub xiphoid region to check; heart and pericardial cavity
2. Right mid axillary line between 11th and 12th ribs

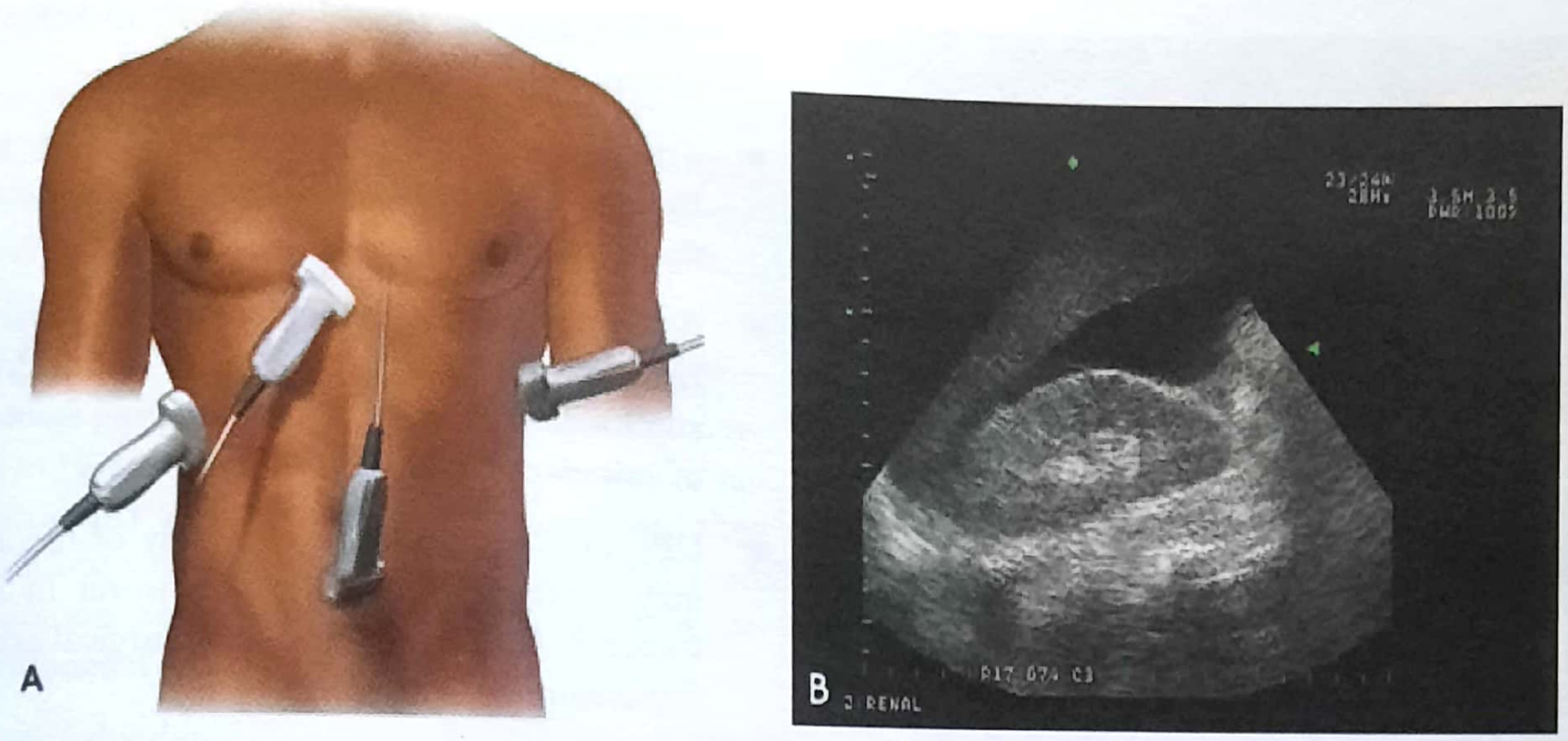

Figure 40.2: A. Probe locations, B. FAST image of the right upper quadrant showing the liver, and free fluid.

3. Left posterior axillary line between 9th and 10th ribs
4. 4 cm above the pubic symphysis

5. Abdominal CT-scan

CT-scan is now the most frequently used method to evaluate the *stable* blunt abdominal trauma. *(NEET)* **The retroperitoneum is best evaluated by CT-scan** *(PGME)*. The ***drawback*** **of CT-scan** is that the patient need to be transferred to the radiology department, which at times may be dangerous due to dislodgment of an organized hematoma; resulting in massive bleeding. Other drawback of CT is that; it is expensive as compared to other tests.

CT-scan also evaluates solid organ injury and in stable patients with a positive ultrasound, it is indicated to grade injury and to evaluate contrast extravasation.

Usually presence of free abdominal fluid in CT-scan without solid organ injury should raise the suspicion of mesenteric, intestinal or gall bladder injury and an exploratory laparotomy is warranted. The accuracy of CT-scan ranges from 92-98%.

CT is most sensitive investigation in hemodynamically stable patient *(IMP POINT)*.

6. Laparoscopy

Despite the initial enthusiasm the use of diagnostic laparoscopy in the blunt trauma abdomen is very limited. It is invasive and expensive method and does not seem to be superior to other methods used for decision making except in few cases with blunt abdominal trauma.

7. Contrast studies

Contrast studies can aid in the diagnosis of specifically suspected injuries, but they should not delay the care of hemodynamically abnormal patients. These studies include:

- Urethrography
- Cystography
- Intravenous pyelogram
- Gastrointestinal contrast studies.

8. Laprotomy

Indications for laparotomy surgical judgment is required to determine the timing and need for laparotomy. The following indications are commonly used to facilitate the decision-making process in this regard:

- Blunt abdominal trauma with hypotension, with a positive FAST or clinical evidence of intraperitoneal bleeding, or without another source of bleeding.
- Hypotension with an abdominal wound that penetrates the anterior fascia.
- Gunshot wounds that traverse the peritoneal cavity.
- Evisceration
- Bleeding from the stomach, rectum, or genitourinary tract following penetrating trauma.

Figure 40.3: Laparotomy. Surgical judgment is required to determine the timing and need for laparotomy.

- Peritonitis
- Free air, retroperitoneal air, or rupture of the hemidiaphragm.
- Contrast-enhanced CT that demonstrates ruptured gastrointestinal tract, intraperitoneal bladder injury, renal pedicle injury, or severe visceral parenchymal injury after blunt or penetrating trauma.
- Blunt or penetrating abdominal trauma with aspiration of gastrointestinal contents, vegetable fibers, or bile from DPL, or aspiration of 10 cc or more of blood in hemodynamically abnormal patients.

Discussion

BLUNT ABDOMINAL TRAUMA can be divided into three parts for discussion.

A. Intra peritoneal organ injury

B. Retro peritoneal organ injury

C. Pelvic organ injury

Now lets discuss them one by one

A. Intra Peritoneal Organ Injury

1. Gastric injury *(AI 07)*

- Less than 1% of such wounds are due to blunt trauma caused by motor vehicle accident, fall from height, cardiopulmonary resuscitation or inter-personal violence.
- The stomach is partially protected by rib cage, making blunt injury rare occurrence and relatively difficult to diagnose.
- Blunt gastric trauma includes a wide range of injuries, from mucosal laceration to full thickness disruption and gastric necrosis resulting from avulsion of vascular pedicle.
- DPL or CT-scan and erect X-ray of the abdomen may confirm the diagnosis, however in most instance diagnosis is made during surgical exploration (laparotomy).
- X- ray examination will show gas under diaphragm.

Management of gastric injury

Primary repair of the stomach is usually safe. Because of the rich blood supply, simple perforation of the stomach are closed with standard technique in either one or two layers.

NOTE: When word "primary closure" is used, it means closing the intestinal/gastric wound (perforation) by simply approximating the cut edges of wound and stitching it.

2. Injury to duodenum

- Blunt injuries to duodenum are difficult to diagnose because patients may have subtle finding upon admission. The instance of blunt duodenal injury varies from 3-5%.
- A motor vehicle accident causing a steering wheel blow to the epigastrium is most common mechanism of blunt duodenal injuries.
- Isolated injury to duodenum is rare and initially does not cause significant clinical sign of peritonitis or hemodynamic instability.
- Plain X-ray abdomen in erect posture may show gas under diaphragm.
- A negative DPL does not rule out duodenal injury. DPL is useful in hemodynamically unstable patient with blunt duodenal rupture.
- Definitive diagnosis requires Gastrografin upper gastrointestinal series (contrast X-ray) or CT-scan of abdomen with oral and intravenous contrast in hemodynamically stable patients. Extravasation of contrast material is an absolute indication for laparotomy.

Management of duodenal injury

- The appropriate repair of duodenal injuries depends on injury severity and elapsed time from injury to treatment. Approximately 80-85% of duodenal wound can be primarily repaired ie; simply stitched. The remaining 15-20% are severe injuries that require more complex procedures. See flow chart 40.2.
- *Duodenal hematomas* if present are expected to resolve in 10-15 days. The management consists of nasogastric suction until peristalsis resumes, and then slow introduction of liquid followed by solid food. Exploration (laparotomy) is indicated; only if persistent duodenal obstruction is present.
- Extensive duodenal injury may require one of a variety of patch (Graham's patch) and bypass procedures for safe closure, Specific indications for these (bypass) protective measures include -
  1. Free perforation with delay in surgery of > 24 hour.
  2. Injury involving > 75% of the wall in first & second part of duodenum.
  3. Associated injuries of pancreatic head or distal common bile duct.
- These procedure vary from a side to side patch duodenojejunostomy or gastrojejunostomy with duodenal exclusion and attempted closure of duodenum to rouxen-Y duodenojejunostomy with duodenal resection or division.
- Extensive resectional procedure (ie; pancreaticoduodenectomy) are performed only in massive pancreatico-duodenal injury.

3. Small intestine injury

- Following blunt trauma, the incidence of small bowel injuries ranges from 5-20% of patients, who require surgical exploration. The postulated mechanism of injury include:
  1. Crushing injury of bowel between the vertebral bodies and the blunt object.
  2. Deceleration causes shearing of small bowel *at fixed points such as:* (MANY PGME).
     (i) *ligaments of treitz,*
     (ii) *ileocecal region and*
     (iii) *around mesenteric artery.*
  3. Close loop rupture caused by sudden increase in the intra-abdominal pressure.
- *Most common site of small intestine disruption is proximal jejunum followed by distal ileum. near ileocecal junction.* (MANY PGME).
- The most important feature of operative management is complete inspection of gastrointestinal tract and adjacent mesentery. Primary repair (simply stitching by approximation) of small bowel is usually safe because of rich blood supply and relatively modest bacterial contact. Please see key box 40.3.
- All defects in the gut should be identified before repairing an apparent isolated injury.
- Intestinal wound should be temporarily sealed with non-crushing intestinal clamp, while awaiting formal closure of other wound to avoid additional peritoneal contamination due to spillage of intestinal content in abdominal (peritoneal) cavity.

KEY BOX 40.2

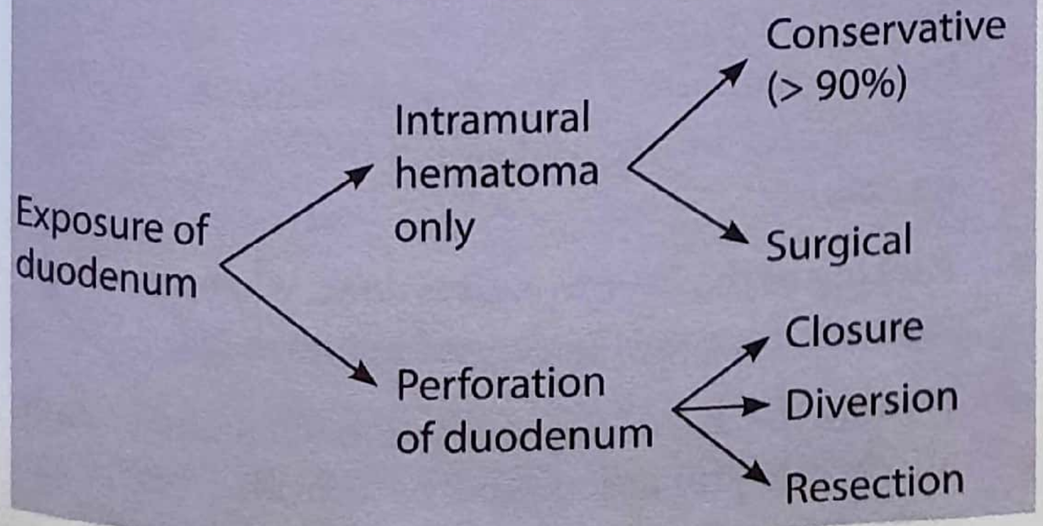

KEY BOX 40.3

Blunt Trauma to the Small Bowel

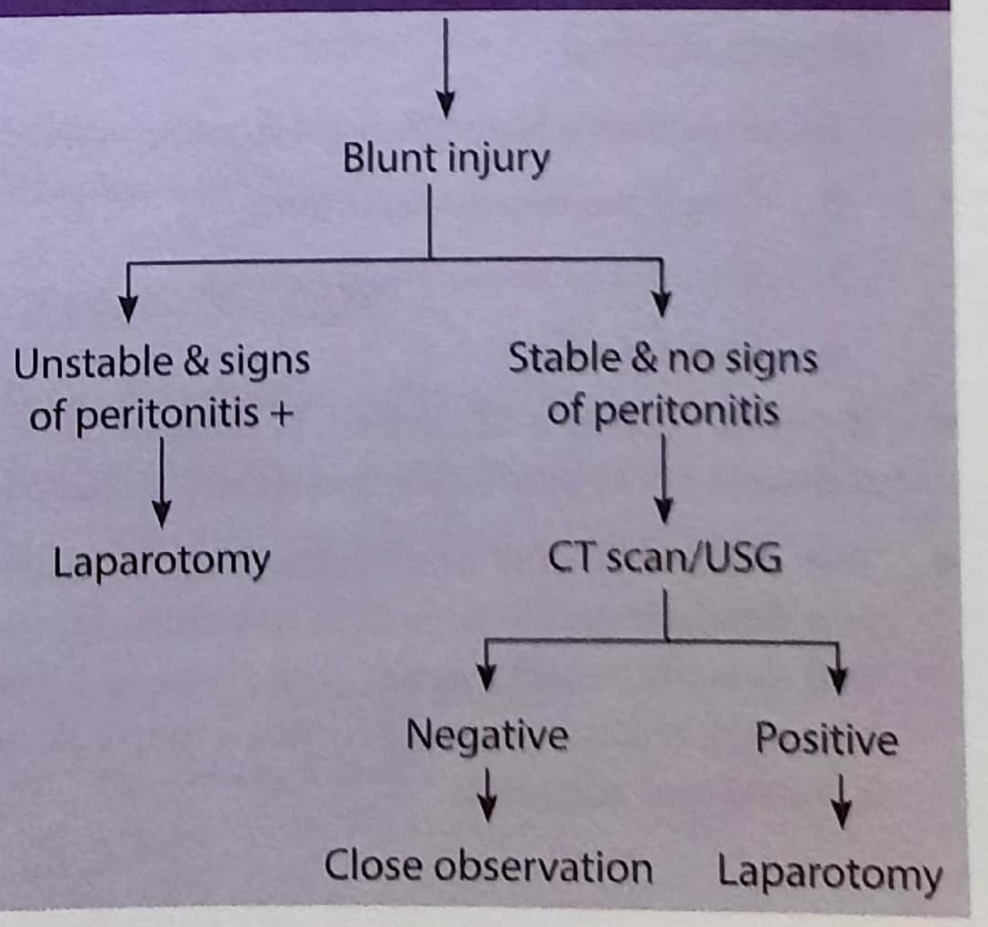

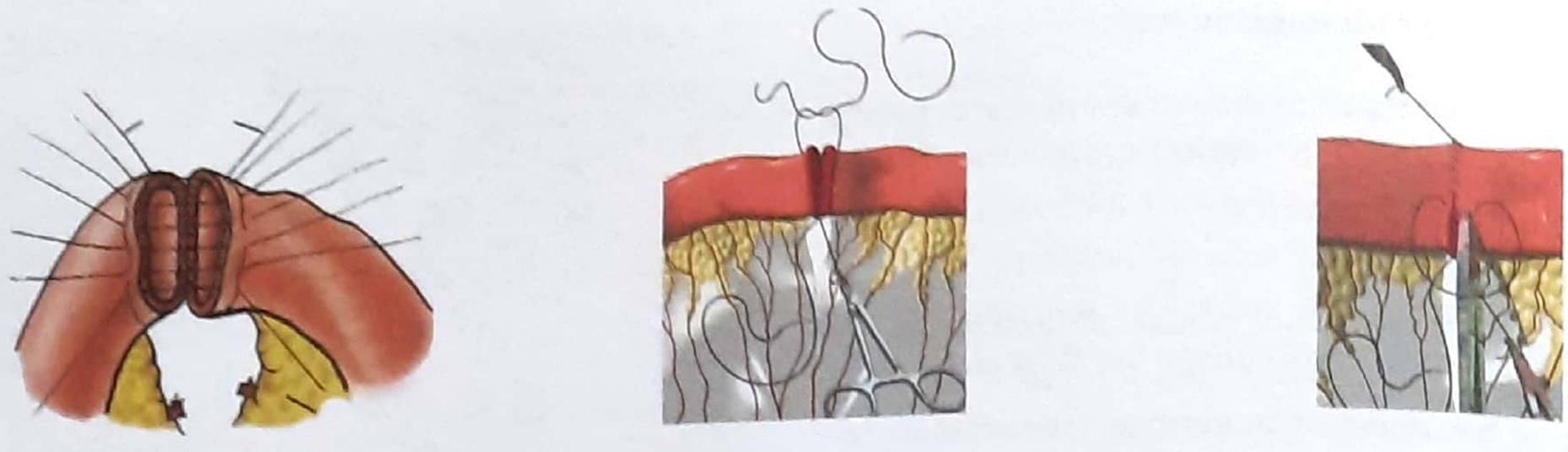

Figure 40.4: Resection and anastomosis

- Simple perforation of the small bowel should be closed with standard technique in either one or two layers.
- Mesenteric bleeding should be controlled by individual vessel ligation; as close to bowel as possible.
- In rare cases of extensive ischemic gut; caused by proximal superior mesenteric artery injury, the remaining viable bowel end can be brought out on anterior abdominal wall as temporary enterostomy (eg; ileostomy).

4. Colonic injury

- Blunt trauma accounts only for 5% of colonic injury.
- Blunt disruption and hemorrhagic contusions can result from high energy transfer.
- Operative management of colonic perforation has changed dramatically during last 25 years. *The practice of mandatory colostomy has given way to primary colonic repair.* (MANY PGME)
- Primary closures of the intraperitoneal colon can be achieved safely in at least 70% patients. *Criteria for primary repair are* :- (IMP. POINT)
  1. Less than 6 hours interval from injury.
  2. Single intraperitoneal injury
  3. Absence of hemorrhagic shock
  4. Stable patient
- If primary repair is ill advised, because of clinical or technical reasons; colostomy is clearly indicated.
- The colostomy and non-functioning mucous fistula should exist close to each other on abdominal wall to facilitate subsequent take down and closure. When the colonic wound permits; a loop colostomy is considered adequate.
- If the colon has to be divided for technical reasons, the distal colon can be simply stapled, rather than fashioning as a mucous fistula, especially if the distal colon is too short to bring out on the anterior abdominal wall.

5. Liver injury

- Because of its size and location in the abdominal cavity, liver is frequently injured in blunt trauma to abdomen. In fact it is second most common solid organ to be injured after spleen (MANY PGME).
- Although most liver injuries can be properly managed with simple procedure, control of profuse bleeding from deep hepatic laceration remains a formidable challenge for surgeons.
- Instant hemostasis is observed in more than 50% of small hepatic lacerations at the time of laparotomy.
- This involve control of bleeding, removal of devitalized tissues and establishment of adequate drainage. Sub-capsular hematomas can be simply observed, if there is no associated parenchymal injury.
- Simple lacerations, which are not bleeding at the time of surgery, do not require treatment/drainage unless they are deep into parenchyma.
- Lacerations that continue to bleed despite attempt at local control require more extensive approach, by usually opening liver wound and directly approaching liver; a procedure known at **tractotomy**. Bleeding vessels and biliary radicals should be individually ligated.
- Packing of the liver wound is done, when the foregoing technique fails to control hemorrhage.
- Despite the use of any method to obtain hemostasis, all necrotic tissues should be debrided before closure.

KEY BOX 40.4

Operative management of liver trauma

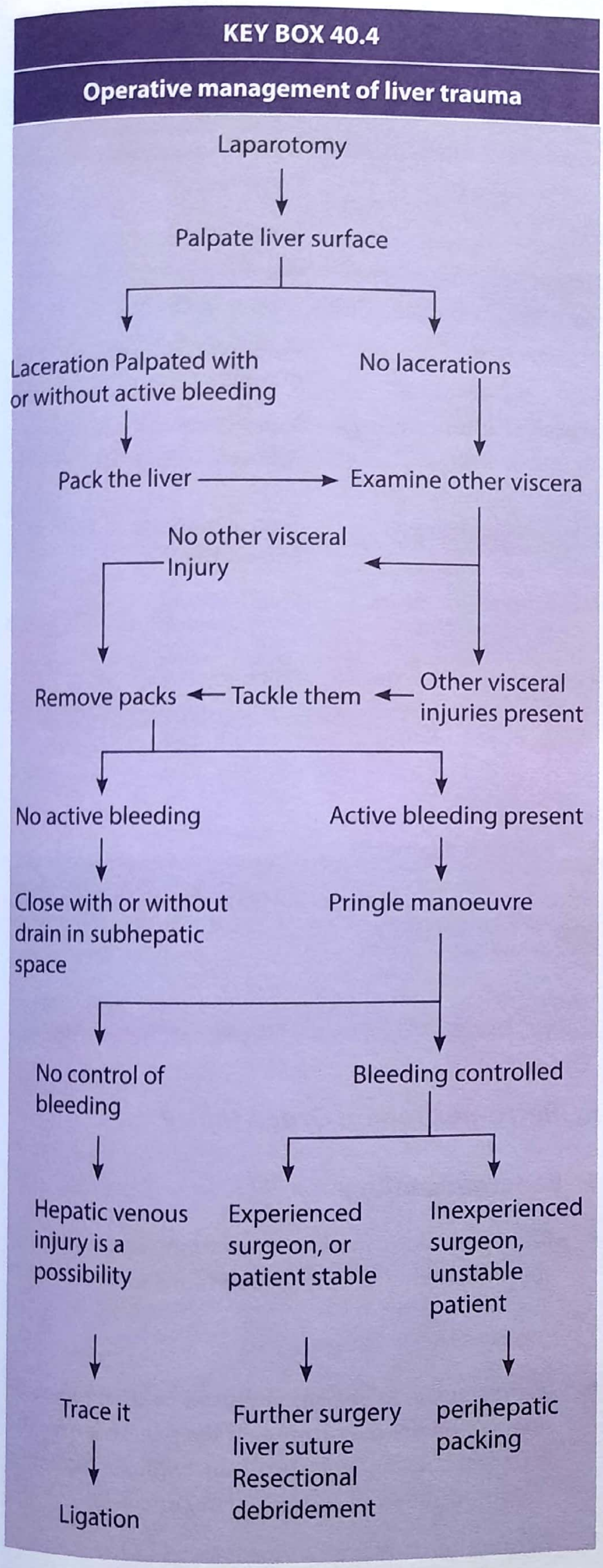

- Formal hepatic resection is unusual after liver injury and the technique has been mostly abandoned because of high mortality and morbidity rate following this procedure.
- Another technique described recently; that the use of an absorbable mesh, individually wrapping each lobe of liver and attaching the mesh to falciform ligament. This technique is useful in multiple superficial laceration of liver with active bleeding, but is not effective when major vascular injuries are present.

6. Splenic Injury

- The **spleen is the most frequently injured organ in blunt abdominal trauma.** *(NEET, MANY PGME).*
- Suspicion of a splenic injury should be raised in any patient with blunt trauma to abdomen.
- Hemodynamically stable patients should undergo ultrasound examination. If ultrasound is positive for free fluid and the patient remains stable, an abdominal CT-scan is obtained to identify the source of bleeding. Evaluate for contrast extravasation and other intra-abdominal injuries. In hemodynamically unstable patient DPL is indicated.
- The diagnosis is confirmed by abdominal CT-scan in hemodynamically stable patients or with DPL during exploratory laparotomy in the unstable patient; at operation table.
- Operative management of injured spleen has changed radically over the past decade. *The danger of overwhelming sepsis has provided the current enthusiasm for splenic salvage procedure.* *(PGME)*
- **More than 70% of all stable patients are currently being managed by means of Selective non-operative management** (SNOM). *(NEET)* The criteria for non-operative treatment includes hemodynamically stability, negative abdominal examination, absence of contrast extravasation on CT-scan, absence of other clear indications of exploratory laparotomy.
- Splenic artery embolization if contrast blush in grade III splenic injury. *(NEET)*

Who is eligible for SNOM

1. Hemodynamically stable
2. Awake, alert and responding
3. No signs of peritoneal irritation/peritonitis.
4. Single organ injury (hollow viscus excluded)
5. No other indication for surgery
6. No coagulation defects.

KEY BOX 40.5

Spleen injury Scale *(AI 10, PGI 2010)*

Grade	Description of injury		Management
I	Hematoma	Subcapsular <10% surface area	Conservative
	Laceration	Capsular tear, < 1 cm parenchymal depth	Conservative
II	Hematoma	Subcapsular, 10 - 50% surface area, intraparenehymal, <5 cm diameter	Conservative
	Laceration	Capsular tear, <1 cm parenchyma! depth which does not involve a trabecular vessel	Conservative/ Splenorrhaphy
III	Hematoma	Subcapsular, >50% surface area or expanding ruptured subcapsular or parenchyma! hematoma > 5 cm or expanding	Topical haemostatic agents/ Splenorrhaphy
	Laceration	>3 cm parenchyma! depth or involving trabecular vessels	Topical hemostatic agents/ Splenorrhaphy
IV	Laceration	Involving segmental or hilar vessels producing major devascularisation (>25% of spleen)	Splenectomy
V	Laceration	Completely shattered spleen, hilar vascular injury which devascularises the spleen	Splenectomy

Where is selective non operative management (SNOM) possible!

1. Level I/II trauma centers/teaching hospitals.
2. ICU monitoring available
3. Repeated physical examination possible.
4. Lab/X -ray /OT support available round the clock.

SNOM consists of

1. Strict bed rest
2. Nil orally
3. Naso gastric aspiration
4. I.V. Fluids
5. Broad spectrum antibiotics
6. Repeated physical examination
7. 12 hours hematocrit.
8. USG daily and CT scan before shifting out from ICU.

SNOM is a abandoned when there is:

1. Deterioration of vital signs
2. Clinical signs of peritonitis.
3. Continued need for blood transfusion
4. Falling hematocrits

(Friends ! for more on this, please also read this topic in chapter spleen).

Please see key box 40.5

RECAP: Till now we were discussing blunt intraperitoneal organ injury. Now lets discuss blunt retroperitoneal organ injury.

B. Retro-peritoneal Organ Injury

1. Pancreatic injury

- Blunt pancreatic injury is uncommon accounting for approximately 1-2% of all abdominal injury.

Key box 40.6

- Blunt trauma to abdomen caused by direct blow or seat belt injury may compress the pancreas over the vertebral column and cause pancreatic disruption, a condition called as pancreatic fracture.
- Because of its retroperitoneal location the pancreas is well protected organ and signs and symptoms may appear late, thus delaying diagnosis.
- DPL is not sensitive enough for diagnosis of retroperitoneal injury.

- Contrast duodenography may reveal widening of 'C' loop.
- **The diagnosis is confirmed often by CT- scan, which is investigation of choice for pancreatic pathology.** *(NEET, MANY POME)*
- Isolated pancreatic injuries are rare. Diagnosis is difficult to make and patient may complain of vague abdominal pain radiating to back; several hours after the incidence. A delay in diagnosis correlate with increased incidence of severe complications.
- At laparotomy a careful examination of pancreas should be carried out, all retro-peritoneal hematomas surrounding pancreas should be explored.
- Pancreatic injury may be divided into proximal or distal according to location on right and left side of superior mesenteric vessels respectively.
- Operative decision for pancreatic trauma are based on injury site and status of ductal system.
- Most injuries are superficial contusions & laceration and often main duct injury is usually not in question. Peripancreatic drain is a routine for such minor lesion because disrupted parenchyma may result in pancreatic fistula.
- Major injury in the body and tail (ie; distal injury) of pancreas warrants distal resection.
- *Surgical treatment* of injuries to the right side of superior mesenteric vein (proximal injuries) is generally conservative (non-operative).

2. Injury to Kidneys

- Kidney is the most commonly injured part of the urinary tract.
- **Hematuria is cardinal sign** of damaged kidney but it may not appear until some hours after injury. Profuse bleeding may be accompanied by clot colic. *(PGME)*
- Blunt renal injury are divided as major and minor injuries. Minor injuries make up approximately 85% of cases. *(MANY PGME)*

KEY BOX 40.6

Pancreatic Trauma

Grade	Description	Injury	Modified Lucas Classification	Management
I	Hematoma	Minor contusion without ductal injury	Class I	Nonoperative management external drainage
	Laceration	Superficial laceration without duct injury		
II		Major contusion without duct injury Major laceration without duct injury		Non operative management with external drainage
III	Laceration	Distal transaction (body and tail) or parenchymal injury with duct injury	Class II	Conservative management distal pancreatectomy if transacted at neck, emergency pancreatectomy should be avoided
IV	Laceration	Proximal transaction or parenchymal injury involving ampulla	Classs II	External drainage, intraoperative pancreatogram and if indicated, head resection
V	Laceration	Massive disruption of pancreatic head, combined pancreaticoduodenal injury, minor or severe duct disruption	Class IV a & b	External drainage if minor, whole area is covered with an open end of Roux-en-Y loop without any attempt to repair the injury • Whipple's procedure

- *Renal contusion** accounts for the most common form of renal trauma and almost invariably be treated non-operatively. (*Renal contusion ie; when renal capsule is not breached).
- Major renal trauma include deep corticomedullary laceration with extravasation, large perinephric hematoma and vascular injury of renal pelvis. These injuries should be explored because of high incidence of complication such as bleeding, abscess formation & hypertension.
- During surgery **approach to the kidney should be transperitoneal** (MANY PGME), so as to examine the possibility of damage to other abdominal organs. However, the danger in this is that release of temponading effect produced by a perirenal hematoma may result in massive uncontrolled hemorrhage.
- Small tears can be sutured over a hemostatic sponge or a piece of detached muscle. Large single rents in kidney are best dealt by passing a tube nephrostomy, through the defect and suturing the renal tissue around it. If laceration is confined to one pole of kidney, partial nephrectomy should be done.
- When kidney is massively ruptured or avulsed from its pedicle, nephrectomy is only course.

(Friends! Also read this topic in chapter 'The kidney Chapter 44; page 804 for details).

3. Ureteral injury

- The injury to ureter after blunt trauma to abdomen is uncommon. The presence of hematuria in ureteral injury is exception rather than the rule.
- In most cases, intravenous pyelography confirms the diagnosis. In about 15-20% of ureteral injury, a retrograde ureterography is required to confirm diagnosis.
- If there is no loss of length and the cut ends of ureter can be brought together without tension; end to end anastomosis should be done.
- If the division is very low down, the bladder wall may be hitched up so that the ureter can be reimplanted into it. Extra length may be obtained by mobilizing kidney.
- If there is marked loss of length, transuretero-ureterostomy or nephrectomy is advisable. Kidney autotransplantation into ipsilateral iliac fossa can also be done by an experienced transplant surgeon or skilled urologist.

C. Pelvic Organ Injury

1. Bladder Injuries

- Most bladder injuries are as a result of blunt trauma. The association of bladder rupture & pelvic fracture is frequent.
- Approximately 70% of patients with bladder rupture have associated pelvic fracture. (MANY PGME)
- Hematuria is *most frequent sign* and in the presence of a pelvic fracture should increase the suspicion for bladder injury, (IMP. POINT)
- Bladder rupture may be extraperitoneal or intraperitoneal; of which former is more common (about 80%)
- Extra-peritoneal rupture usually result from perforation by adjacent bony fragments.
- Intraperitoneal rupture of the bladder results from injuries located in the dome, which occurs when a full bladder sustain a direct blow.
- Diagnosis is usually made by cystography.
- Intraperitoneal injuries are primarily repaired by way of transabdominal approach including a three layered closure. A supra-pubic cystostomy may be necessary in large wound. (See figure 47.10; page 877)
- The management of extra-peritoneal rupture of the bladder is primarily non-operative by leaving foley's catheter in bladder for 10-14 days. (MANY PGME)

2. Injury to Urethra

- Disruption of urethra is rare injury in women. It is mostly found in men, frequently following either pelvic fracture or straddle injury. Posterior urethral injury is present in about 10% of pelvic fractures.
- Currently; patient sustaining urethral injury should be managed by bladder decompression by way of supra-pubic cystostomy and delayed urethroplasty.

(Friends ! It is very important PGMEE topic, must read this in detail in chapter "The urethra' Chapter no. 47, page 874).

3. Injury to Rectum

Blunt rectal injuries are uncommon; the digital rectal examination (DRE=PR) may reveal blood or even an injury may be palpable.

- Intraperitoneal rectal injury may be usually managed by primary closure and a diverting sigmoid colostomy.
- For extraperitoneal rectal injuries, particularly those located in inferior one-thirds of rectum, a diverting colostomy, with washout of distal rectal stump and wide presacral drainage are mandatory.

4. Injuries to Uterus

The injury to uterus and other reproductive organs after blunt trauma is very uncommon. Most injury to uterus and adnexa can be treated with simple suture repair. Hysterectomy is occasionally required.

*****

PENETRATING ABDOMINAL TRAUMA

- Initial management can be simplified to-
  - (a) Aggressive resuscitation
  - (b) Direct physical examination
  - (c) Related diagnostic studies and therapeutic interventions.
- Hemodynamic stability, nature of the penetrating object and location of wounds are key factors in decision algorithm. Please have a look on box 40.7, next page.
- Patients with massive hemoperitoneum or persistent hemodynamic instability are promptly intubated, volume loaded (IV fluid) and shifted to operating room for abdominal exploration (laparotomy).
- Hemodynamically stable patients are managed according to injury mechanism.
- Selective non-operative management (SNOM) is becoming the standard approach for some patients with abdominal trauma, including those with blunt injuries and stab wounds.
- Even selected patients with gunshot wounds to the abdomen can be safety treated with a selective rather than a mandatory operative approach, (study on this is going on)
- Penetrating abdominal trauma and its management is divided into three parts for further discussion:
  - (A) Intra-peritoneal organ injury
  - (B) Retroperitoneal organ injury
  - (C) Pelvic organ injury

A. Intra-Peritoneal Injuries

1. Stomach and small bowel injuries

- *Stomach and small bowel perforations are second in frequency after liver following penetrating abdominal trauma.* (AIIMS 98, AI 07).
- Primary repair of stomach and small bowel is usually safe due to rich blood supply and modest bacterial content.
- Bowel is closed (stitched *transversely* to avoid narrowing of the lumen.
- If questionable area of viability or multiple perforations are found in a short segment of small bowel, then segment should be resected and ends of healthy bowel is anastomosed to each other. (Fig 40.4 Page 736 and Key box 40.7)

2. Duodenal Injury

- Mostly caused by penetrating trauma.
- The retro-peritoneal location of duodenum (2nd & 3rd part) exerts a protective effect against injuries, but it also delays in an early diagnosis.
- Limited perforations and simple lacerations of duodenum are closed primarily.
- Small non-deep bleeding lacerations are easily controlled with simple sutures or hemostatic agents.
- Extensive duodenal injury may require one of a variety *of patch (Graham's patch)* and *bypass* procedures for safe closure.
- *Bypass procedures* include side to side duodenoje-junostomy or gastrojejunostomy with duodenal exclusion and attempted closure of duodenum or Roux-en-Y duodenojejunostomy with duodenal resection or division.
- Specific indications for these (bypass) protective measures include

KEY BOX 40.7

Penetrating trauma to the small Bowel

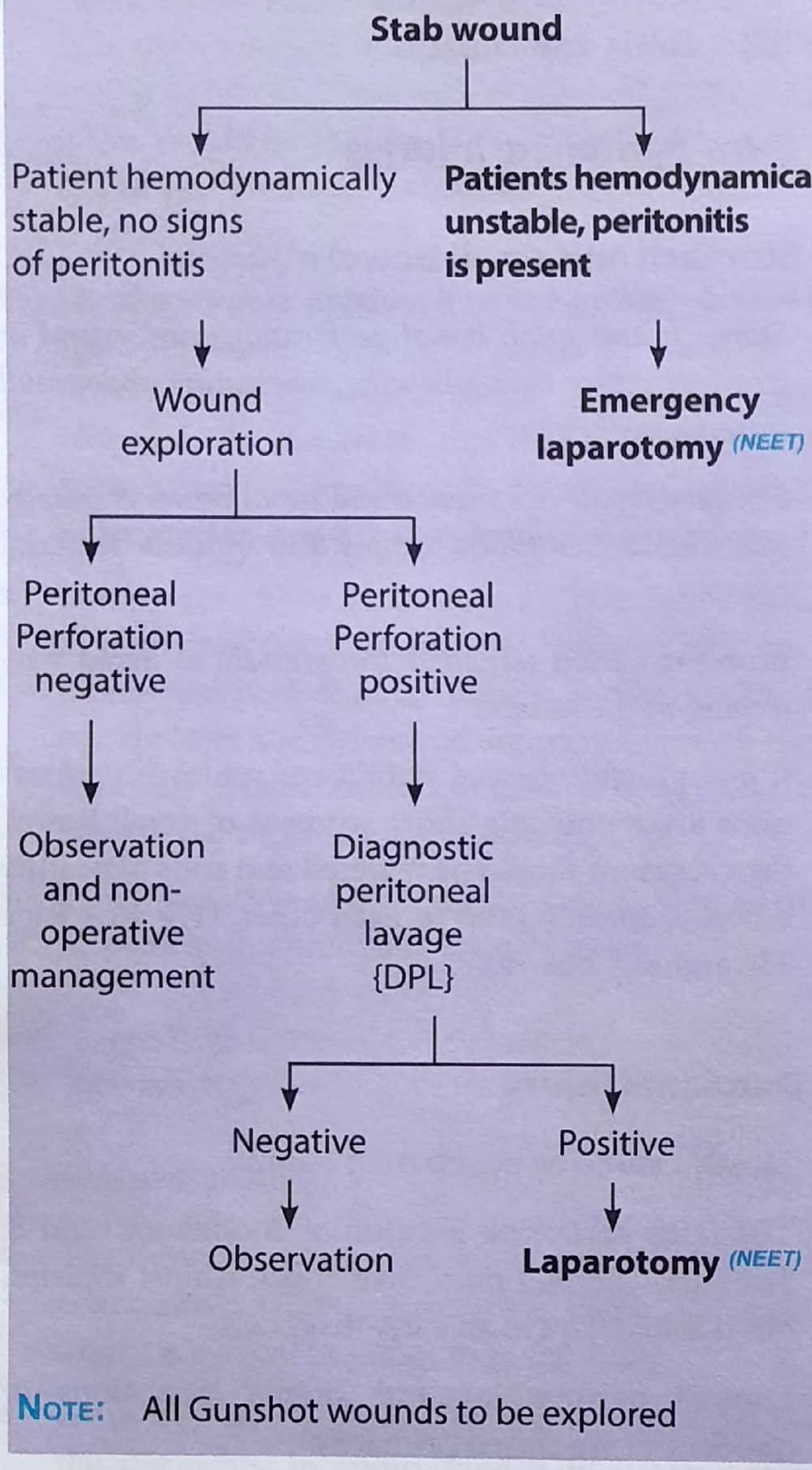

NOTE: All Gunshot wounds to be explored

1. Free perforation with delay in surgery of > 24 hour.
2. Injury involving > 75% of the wall in first & second part of duodenum.
3. Associated injuries of pancreatic head or distal common bile duct.

NOTE: When word "primary closure" is used, it means closing the intestinal wound by simply approximating the cut edges of wound and stitching cut edges with each other.)

3. Colonic Injuries

- Operative management of colon perforations have changed dramatically.
- *The practice or mandatory colostomy has given way to a selective policy of primary colon repair.* (IMP. POINT)
- *Primary closure of intra-peritoneal colon can be achieved safely in at least 70% of cases,* (MANY PGME)
- Criteria for primary repair are :
  1. < 6 hours from initial injury
  2. Less than two associated intraperitoneal injuries
  3. Absence of hemorrhagic shock.
  4. Stable patient
- Colonic injury of more than 2 cm. with ragged edges and gross fecal contamination should not be primarily closed; and then a colostomy should be *done.* (PGME)
- Exteriorization* of the sutured colon is a alternative to colostomy.

Exteriorization, means bringing out the sutured bowel (colon) from abdominal cavity, on anterior abdominal wall after making a hole on anterior abdominal wall.

- If surgeon believes primary repair or exteriorization is ill advised due to clinical or technical reasons, colostomy is clearly appropriate.
- Please read box 40.8 and must see figure 40.5 on next page.

4. Liver Injuries

- **Liver is most commonly injured organ in penetrating injury to abdomen.** (NEET, MANY PGME)
- Small non-deep bleeding lacerations are easily controlled with simple sutures or hemostatic agents.
- More severe liver injuries require more complex procedures, for example deep mattress suture, packing, debridement, resection & mesh hepatorrhaphy.

5. Splenic Injuries

- Uncommon in penetrating trauma abdomen.
- The criteria for non-operative management of splenic injury includes-
  1. Hemodynamic stability
  2. Negative abdominal examination

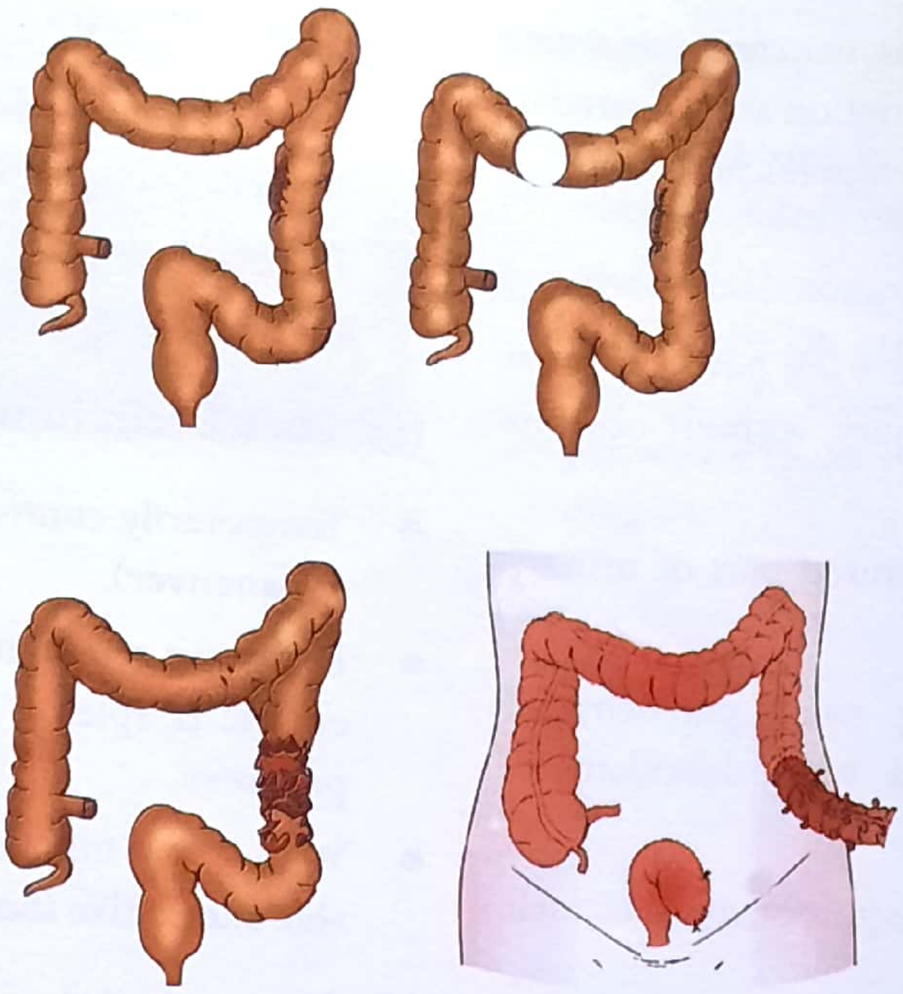

Figure 40.5: Management of colonic injury (A) Minor injury (B) Major injury

3. Absence of contrast extravasation on CT-scan
4. Absence of other indications for laparotomy.

- Splenectomy may rarely be required in some patients.

B. Retro-peritoneal Organ Injuries

1. Pancreatic Injury

- Major abdominal vascular injuries are present in more than 75% cases of penetrating pancreatic trauma.
- Persistent elevated level of serum amylase suggests pancreatic injury.
- Pancreatic injuries are divided as proximal or distal, according to location on right of left of superior mesenteric vessels respectively.
- Most of the penetrating wounds of pancreas should be treated with debridement and direct suture ligation of areas of bleeding.

KEY BOX 40.8

Colon injury Scale

Grade	Description/injury		Management
I	Hematoma	Contusion/hematoma without devascularisation	Conservative
	Laceration	Partial thickness, no perforation	Observation
II	Laceration	<50% of circumference	Primary suture without colostomy
III	Laceration	>50% of circumference	Primary suture with or without colostomy (colostomy is done if peritoneal cavity is grossly contaminated or patients condition is not good)
IV	Laceration	Complete transaction of colon	Primary suture with proximal colostomy

- In extensive injuries to pancreas, pancreatic drainage seems to be the best treatment option as compared to proximal pancreatectomy or whipple's procedure.

2. Renal Injuries

- Penetrating injury to flank or back have potential to cause significant renal injury without obvious clinical manifestations.
- Kidney is most commonly injured part of urinary tract.
- Penetrating wounds causing small parenchymal injury are generally treated with debridement, primary repair & drainage.
- More extensive wounds may require a partial or total nephrectomy.
- Injuries involving hilum usually require total nephrectomy.

3. Ureteral Injuries

- Ureteral injuries are uncommon.
- In most cases intravenous pyelography confirms the diagnosis.
- Surgical options include; ureteroureterostomy for injuries located in upper & middle third of the ureter.
- More distal injuries require ureteral reimplantation in bladder.

4. Major abdominal vascular injuries

- Vascular trauma is responsible for most immediate deaths following penetrating trauma to abdomen.
- Most lethal injuries are those in retrohepatic vena cava, abdominal aorta and main portal vein.

(a) Abdominal aortic injuries

- When feasible closed by lateral arteriorrhaphy.
- For large caliber gun shot wound, autogenous vein patching may be appropriate.
- For complete transaction synthetic graft interposition is used, eg; dacron graft.

(b) Inferior vena cava injuries

- They are usually repaired primarily; even if luminal diameter is compromised.
- For massive tissue loss, *infrarenal vena cava ligation can be done* with little hemodynamic change.

(c) Portal vein injuries

- Temporarily controlled by digital pressure (**pringle's maneuver**).
- Definitive repair at the confluence of superior mesenteric & splenic vein may necessitate division of pancreas.
- With severe injuries, portal vein ligation is a reasonable alternative that is tolerated by > 80% of patients.

(d) Iliac arterial and venous injury

- It is usually serious due to lack of tamponade in pelvis and extensive interconnecting collateral.
- Common & external iliac arteries should be repaired.
- Iliac veins are usually ligated, if venorrhaphy is not feasible.

Abdominal Compartment Syndrome

Caused by acute increase in intraabdominal pressure.

Seen in patients with -

- Massive abdominal trauma.
- Operation for massive intraabdominal infection.
- Undergone a complicated abdominal operation.

Grading

Normal IAP is 5 mm kg			
	[AP (mmHg)]	(Cm H_2O)	Signs
I	10-15	13-20	No signs
II	16-25	21-34	↑ PAWP + Oliguria
III	26-35	35-48	Anemia, ↓ Co ↑ PAWP
IV	>35	>48	Anemia, ↓ Co ↑ PAWP

Decreased	Increased
Cardiac output (Co)	Cardiac Rate
Venous Return	PCWP
RBF	CVP
GFR	Intrapleural pressure
Visceral Blood Flow	Vascular Reisistance

Management

- Diagnosis made by measing bladder pressure (through foley's catheter).
- Abdominal compartment syndrome is a surgical emergency & treatment includes opening of abdominal wound, However Intra abdominal pressure <15 cm H_2O don't require decompression/ surgery.

*****

41 Abdominal Wall and Umbilicus

Contents

- Abdominal wall layers
- Burst abdomen
- Incisional hernia
- Divercation of recti
- Neoplasm of abdominal wall
- Abdominal incision
  - Vertical incisions
    - Midline
    - Paramedian
  - Transverse/Oblique
    - Kocher's
    - Gridiron/McBurney's
    - Rockey davis
    - Rutherford morison's
    - Lanz's
    - Pfannenstiel
- Diseases of umbilicus
  - Omphalitis
  - Umbilical granuloma
  - Umbilical calculus (umbolith)
  - Umbilical fistula
  - Patent urachus
  - Neoplasm of umbilicus

ABDOMINAL WALL

There are nine layers in abdominal wall; from outer to inner side: skin, subcutaneous tissue (camper's fascia and scarpa's fascia), superficial fascia, external oblique muscle, internal oblique muscle, transversus abdominis muscle, preperitoneal (extra peritoneal or properitoneal) adipose tissue and peritoneum. See figure 41.0, 41.1 & 41.3 on next page.

*****

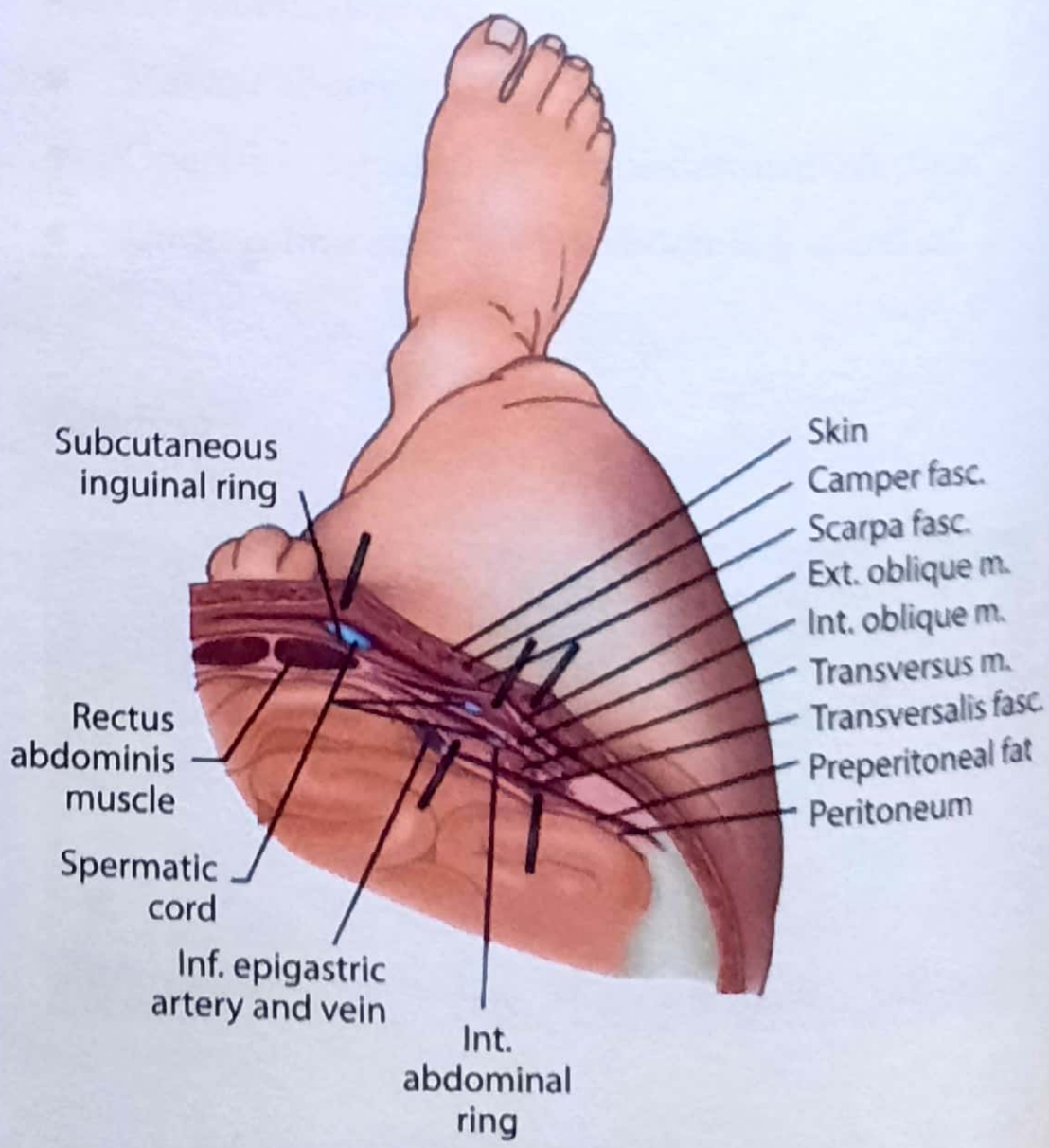

Figure 41.0: Layers of Abdominal wall

BURST ABDOMEN

synonym Abdominal Wall Dehiscence

- By definition; **abdominal dehiscence** (NEET) is the separation of fascial layers of anterior abdominal wall in early post operative period, **usually between 5-8 days** (NEET, JIP 86). This is an event that usually leads to emergency action.
- Dehiscence is of greatest concern because of the possibility of evisceration; which is protrusion of the small intestine through the fascial layers; to come out on the anterior abdominal wall surface. Figure 42.2.
- The incidence of burst abdomen is higher after an emergency laparotomy than elective laparotomy.
- Wound dehiscence occurs in approximate 1-2% of patient, who undergo an abdominal operation.

Presentation

Usually present as a sudden, dramatic drainage of relative large volume of clear, salmon (pink) coloured fluid through abdominal incision. Patients presents with pain and shock.

Causes of Disruption

- Hasty closure of abdominal wall incision.
- Too small bites of fascial layers; during closure of anterior abdominal layers.
- Use of short lived absorbable suture material, such as catgut.
- Violent or persistent cough, particularly as the patient comes off the operating table.
- Straining to cough or vomit, post operatively.
- Malnutrition, jaundice, malignant disease, hypoproteinemia and steroids predispose to this condition.

Management

A. Non operative treatment

- When disruption is seen and the omentum and gut are firmly adherent within the abdominal cavity.
- When there is an associated fistula of small or large bowel, in presence of gross infection.
- All sutures are removed and the abdominal incision is allowed to open. The skin is cleaned and saline moist pads are applied. About three to five layers are applied. Dry wool is then placed over the gauze and secured in place by adhesive plaster.

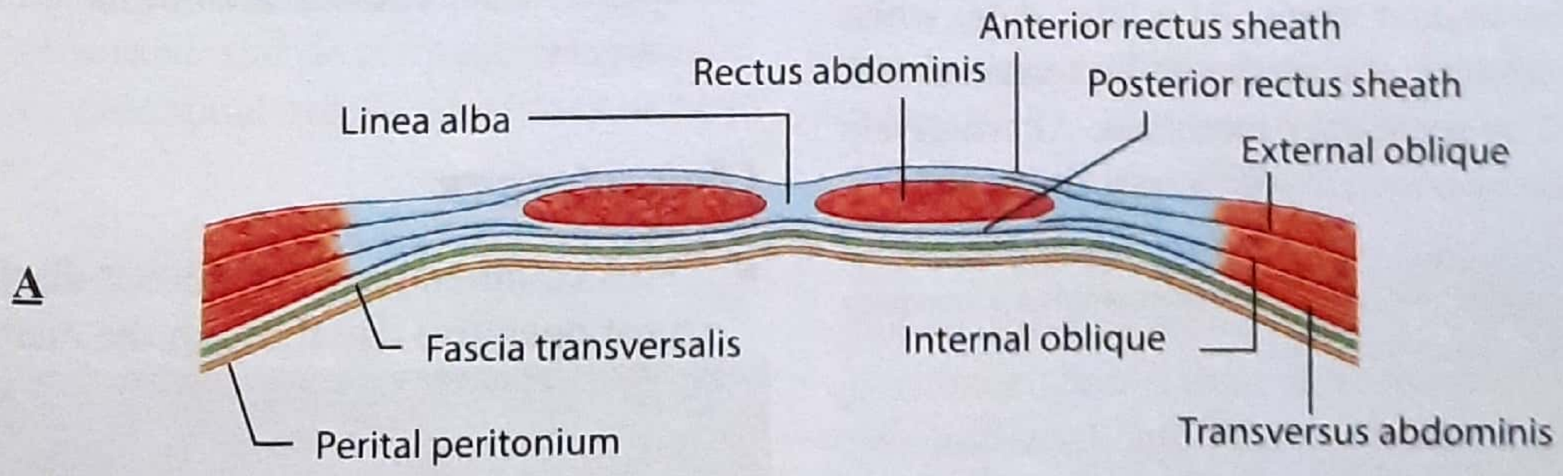

Figure 41.1: Anterior abdominal wall (A) Transverse section through the upper three- quarters of rectus sheath (B) transverse section through the lower one-quarter of the rectus sheath

Figure 41.2: Abdominal wall dehehiscence (Burst abdomen)

B. Operative Treatment

Skin is cleaned and prolapsed intestine washed with warm saline. Wound is completely opened. The abdomen is not routinely explored, unless there is suggestion of deeper corruption (such as, leakage from a suture line or abscess formation). The objective is to clear the edges of incised abdominal wall to a sufficient distance to permit sutures of heavy mono-filament material, which are inserted at least 1.5-2 cm away from the wound edges; at interval of 1cm; through all layers of the abdominal wall excluding the skin. If there is any difficulty in getting the wound edges together, then a polypropylene mesh should be inserted, which is sutured to the fascial edges of the wound using interrupted heavy mono filament material. The superficial part of the wound is then left open and dressed with saline soaked gauze. At a later date; when the patient has recovered, the mesh can be removed and wound left to heal by secondary intention. Alternatively the wound can also be covered with a split skin graft.

Mesh is a net of suture material, can be compared to a mosquito net. See figure 42.14 page no. 773

Prevention

The technical details of fascial closure including proper spacing of the suture, adequate depth of bite of the fascia and relaxation of abdominal muscles during fascial closure.

Reduction of massively distended bowel by milking air and fluid back up into the stomach and then out of the GI tract by Kyle's tube aspiration; may also facilitate a tension free closure of fascial layers of anterior abdominal wall.

*****

INCISIONAL HERNIA

(Post Operative Hernia Or Ventral Hernia)

As discussed above; that in abdominal dehiscence (burst abdominal) there is complete (total) disruption of abdominal wall layers; in incisional hernia there is partial disruption of the deeper layer of abdominal wall but the skin wound (ie; operative incision) remains intact. In incisional hernia; herniation of abdominal content occurs at the site of previous surgical incision. See figure 41.4 on next page.

Etiology

- Incisional hernia occurs most often in *obese* female.
- A persistent postoperative cough & post operative abdominal distention are it's precursors.
- There is high incidence of incisional hernia following operation for peritonitis, because in most of the cases, the abdominal (closure) wound is *infected* from inside; making it more prone to disrupt.
- The placement of drainage tube through same laparotomy wound leads to more chances of disruption.
- As a result of increased intra-abdominal pressure.
- Poor selection of suture material.
- Lower midline incision:- Lower abdomen is especially weak, in midline because of absence of posterior rectus sheath below arcuate line. It is because of this reason; incisional hernias occur more commonly after LSCS, lower abdominal surgery and pelvic surgery.

Clinical feature

- Pink coloured serosanguinous* discharge, on the 4th post operative day through the main suture line is a strong signal of dehiscence.
- There is a bulge/swelling in relation to the suture line.
- Expansile impulse on coughing and reducibility may be present.
- After reduction (ie; pushing back the content in peritoneal cavity manually), a defect (gap in the abdominal wall) can be palpated.
- Most cases of incisional hernia are asymptomatic and has wide neck, however attacks of partial intestinal obstruction and strangulation can occur.

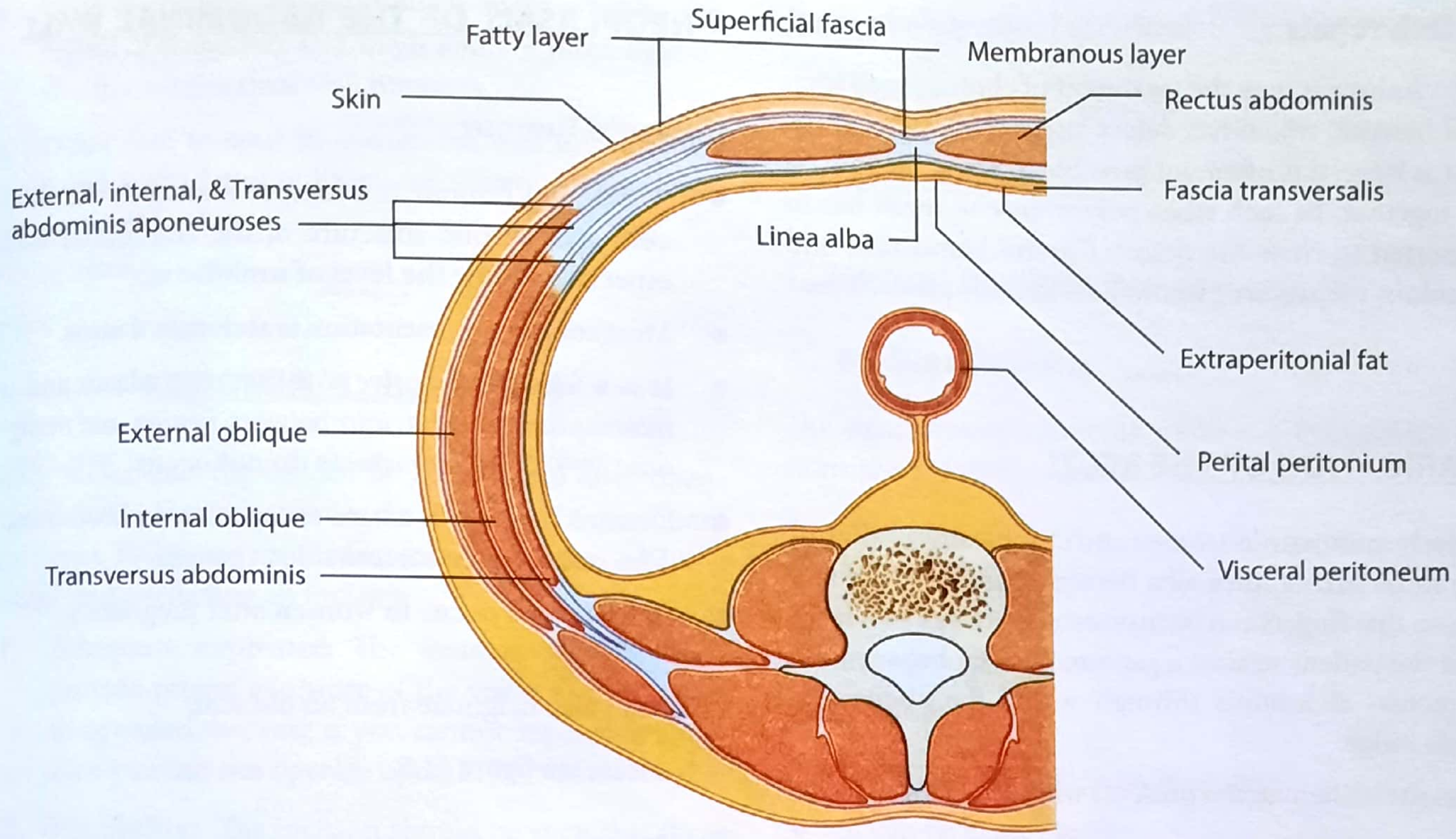

Figure 41.3: Transverse section through abdominal wall

Sero-Sanguineous = Serous + Sanguineous, ie;- Containing both serum + blood.

Treatment

- As the most cases of incisional hernia are asymptomatic and broad necked; and do not require treatment. Application of abdominal belt (binder) may be helpful.

Figure 41.4: Large incisional hernia after previous LSCS

- Surgical treatment is necessary, if the defect is narrow, if there is discomfort to the patient or if there is danger in form of obstruction or strangulation.

Operative technique

Three techniques has been described:

1. Simple apposition

The hernial sac is dissected and opened. After opening the sac {by making an incision over it}, we will enter the peritoneal cavity, the contents (most commonly omentum and small intestine) are reduced (pushed back in abdomen). Now the abdominal layer are repaired (closed) by bringing them in apposition (apposition; means bringing side by side). First the peritoneum ,is closed and then the fascial (aponeurotic) layer are closed with non-absorbable sutures.

2. Complex apposition

Keel's operation and mayo's operation: These consist of layered closure and are not done now.

3. Mesh repair

This technique is now the treatment of choice for all incisional hernias, which has defect larger than 4 cm. If the defect is large, it is often not possible to bring the muscle edge together. In such cases polypropylene mesh has to be inserted to close the defect. Careful hemostasis and meticulous asepsis are essential during this procedures.

*****

DIVARICATION OF THE RECTI

In elderly multiparous women and chronically weak children; some part of linea alba becomes stretched out and weak, so that fingers can be insinuated between two recti. When the patient strains; a gap can be seen between the two rectus- abdominis through which the abdominal content bulge.

Rectus sheath hematoma presents with firm painful mass.

Treatment

An abdominal belt is all that is required. There is no risk of strangulation of intestinal content. Surgery is not indicated, surgical approximation of rectus muscle is done for cosmetic purpose on patient's request.

*****

NEOPLASMS OF THE ABDOMINAL WALL

Desmoid Tumour (JIPMER 87)

- A desmoid tumour is a tumour arising in the musculo aponeurotic structure of the abdominal wall, especially **below the level of umbilicus.** (NEET)
- **Most common presentation is abdominal mass.** (NEET)
- **It is a *locally aggressive*** soft tissue neoplasm and is *intermediate in behaviour between benign and malignant* (MANY PGME). **Metastases do not occur.** (NEET, PGME)
- Desmoid tumour is a hard encapsulated fibroma and does not undergo sarcomatous changes.
- **80% of cases occur in women** after pregnancy. (NEET, PGME)
- It can also originate from an old scar.

Please see figure 41.5.

Treatment

- Desmoid tumours characteristically infiltrate the surrounding skeletal muscle making, a ***wide excision*** (NEET) ***taking at least 2.5cm (1 inch) of healthy tissue,*** *necessary.* (AIIMS NOV 93, AIIMS 85, 09, UPSC 08)
- Recurrence is common. (IMP. POINT)
- These tumour are ***moderately radio sensitive*** (NEET, PGME).

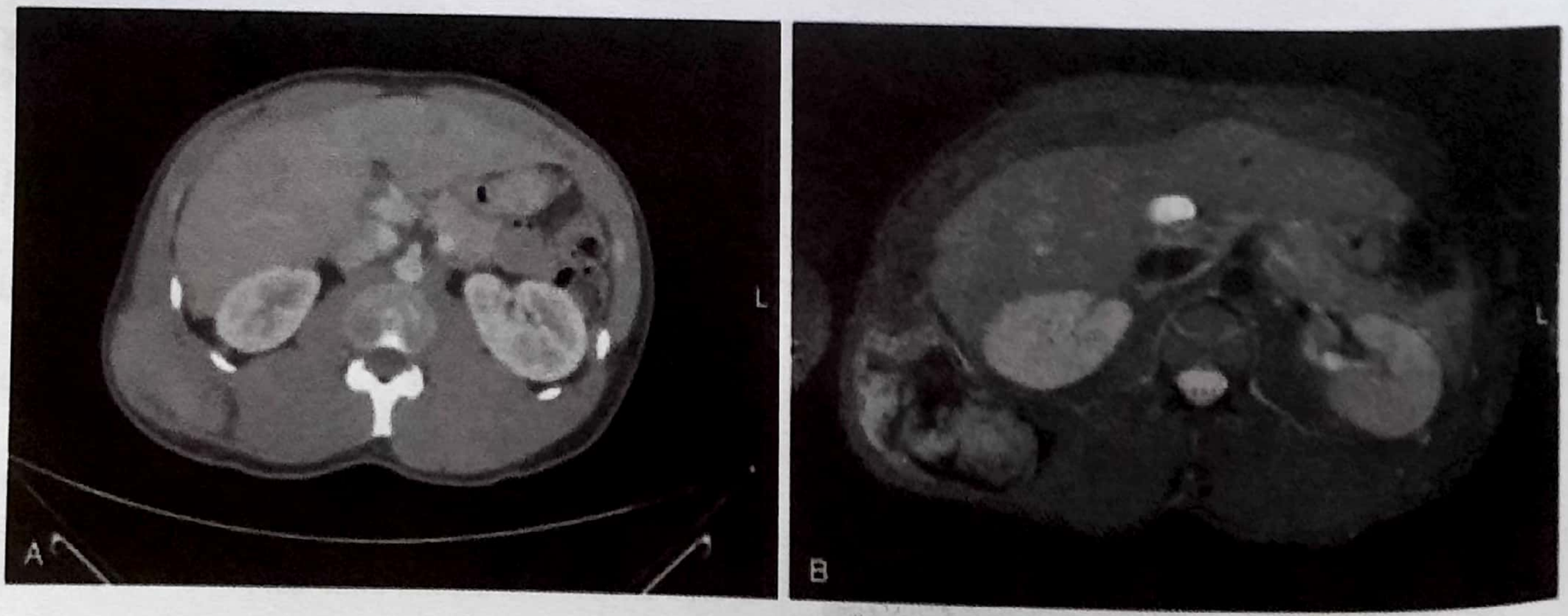

Figure 41.5: Desmoid Tumour

- Extra abdominal desmoid occur most often in the region of shoulders and thigh and are more aggressive than abdominal wall tumours.
- Other rare tumour of abdominal wall are fibrosarcoma and adenocarcinoma of viscera invading abdominal wall.

*****

ABDOMINAL INCISIONS

Intra abdominal organs can be approached after opening abdominal cavity (laparotomy) through a number of incisions. Following are the factors which must be kept in mind while selecting an incision.

1. **Adequate exposure:** The incision selected must provide proper exposure of the viscera one is going to operated, because if you cannot see inside abdomen you can not operate upon it.
2. **Flexibility:** The incision should be such that it can be extended, if needed.
3. **Reliability of closure:** should be easy to close so that wound is secure and not libel to dehiscence.

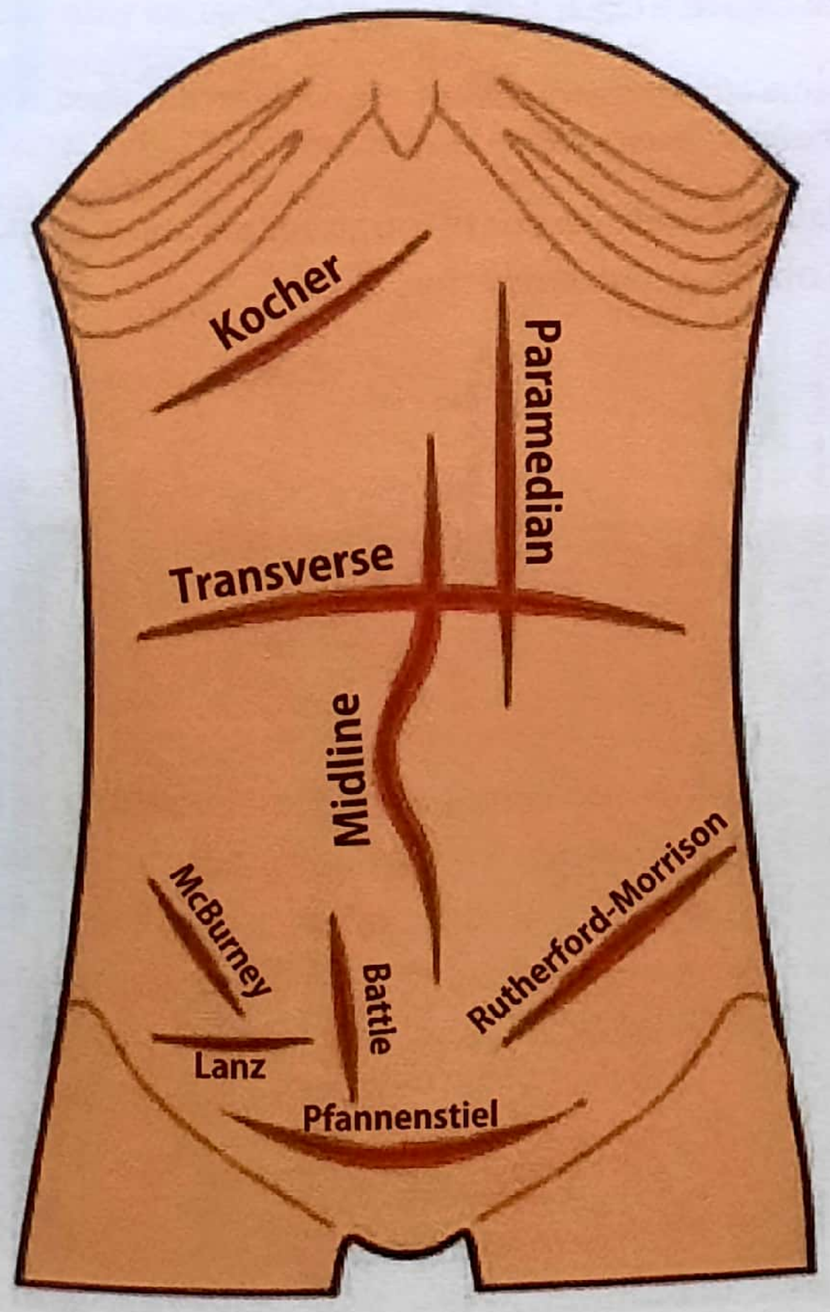

Figure 41.6.1 : Abdominal incisions

Types of abdominal incisions:

1. Vertical
2. Transverse or oblique
3. Thoracoabdominal

1. Vertical Incisions (See Figure # 41.6.1)

A. Midline incision

The structures encountered while making midline incisions are: Please see figure 41.6.1:

1. Skin
2. Subcutaneous fat
3. Linea Alba
4. Preperitoneal fat and
5. Peritoneum

The ***benefits*** of a midline incision are:-

- It can be made rapidly.
- Provides excellent exposure to almost all parts of abdominal cavity, hence it incision of choice in a case of *blunt abdominal trauma* or when preoperative diagnosis of abdominal pathology is not sure. (PGME)
- Almost bloodless as no muscle fibers are divided.
- Closure is easy, less time taking and satisfactory.

B. Paramedian incision

It is a vertical incision made 2.0 to 4.0 cm lateral to the midline the structures encountered during the incision are (Please see figure 41.1 & 41.61 and help your self)

1. Skin
2. Subcutaneous tissue
3. Anterior rectus sheath
4. The rectus muscle is not divided. Instead it is retracted laterally
5. The posterior rectus sheath; only in upper half of abdomen as it is absent below the semicircular line of Douglas (arcuate line)

The *important feature* of this incision are:-

- Blood loss is greater in comparison to mid line incision
- Proper wound closure and provide a strong scar.
- Preserves the rectus muscle that resumes its place after closure there by protecting the incision on ante-

rior and posterior rectus sheath, thus minimizing the chances of incisional hernia and wound dehiscence. However this advantage is only theoretical and not seen in practice.

2. ***Transverse or Oblique Incisions***

- They can be horizontal or curved.
- Usually made along the skin tension lines (langer lines) to *allow good cosmetic results*
- The exposure provided is usually limited.
- After closure; they have more strength than a vertical incision. Hence wound dehiscence and incisional hernia are rare with it. Various types of transverse/ oblique incisions are:-

1. Kocher's incision

- Right sub costal incision, used for operation on bile duct and gall bladder.
- Placed 2.5 to 4.0 cm below and parallel to right costal margins. See figure 41.6.1 & 41.6.2C.
- The structures encountered are:-
  1. Skin
  2. Subcutaneous tissue
  3. Anterior rectus sheath
  4. The rectus muscle is divided; and the three lateral abdominal muscles are also divided
  5. Posterior rectus sheath
  6. Peritoneum; & then we reach abdominal cavity.

2. Gridiron incision/McBurney's incision

- Most *common incision used for appendicectomy*
- Incision is made perpendicular to line joining the anterior superior iliac spine to umbilicus centered at the McBurney's point (junction of medial two third and lateral one third). Figure 41.6.1, 41.6.2E.

3. Rockey Davis incision

- Used for appendicectomy and operations like cecostomy.
- It is a transverse incision with its center at McBumey's point.
- It gives a better postoperative scar than the conventional McBurneys incision. *The muscles encountered during the incision are split along the direction of their fibers.*

4. Rutherford Morison's muscle cutting incision

As the name suggests this is a muscle cutting incision, otherwise it is similar to the McBurney's Gridiron incision. The muscles are cut along the line of the incision to get access to the peritoneal cavity.

5. Lanz's incision

This incision is the cosmetic counterpart of McBurney's incision & is commonly performed for appendicectomy. The incision is made on midclavicular line on interspinous line. Figure 41.6.2F (incision shown in right iliac fossa is lanz's incision).

6. Pfannenstiel incision

- Curved horizontal incision with center approximately 5 cm above the symphysis pubis
- The rectus sheath is incised along the line of incision.
- The rectus muscle is not incised rather it is retracted laterally
- The peritoneum is opened vertically
- Used mostly for gynecologic procedures
- See figure 41.6.1

Some other incisions which have not been described in text are shown in figure 41.6.2

7. Maylard incision cut through rectus abdominis, used in obs & gynae surgeries.

*****

UMBILICUS

Omphalitis

This is infection of umbilicus. The incidence is much higher in communities that do not practice aseptic measures, while dividing umbilical cord, just after birth. In severe cases infection may spread along hypogastric arteries or umbilical vein and may lead to complication, such as:

1. Abscess of anterior abdominal wall.
2. Septicemia due to entry of bacteria in the blood stream via umbilical vein.

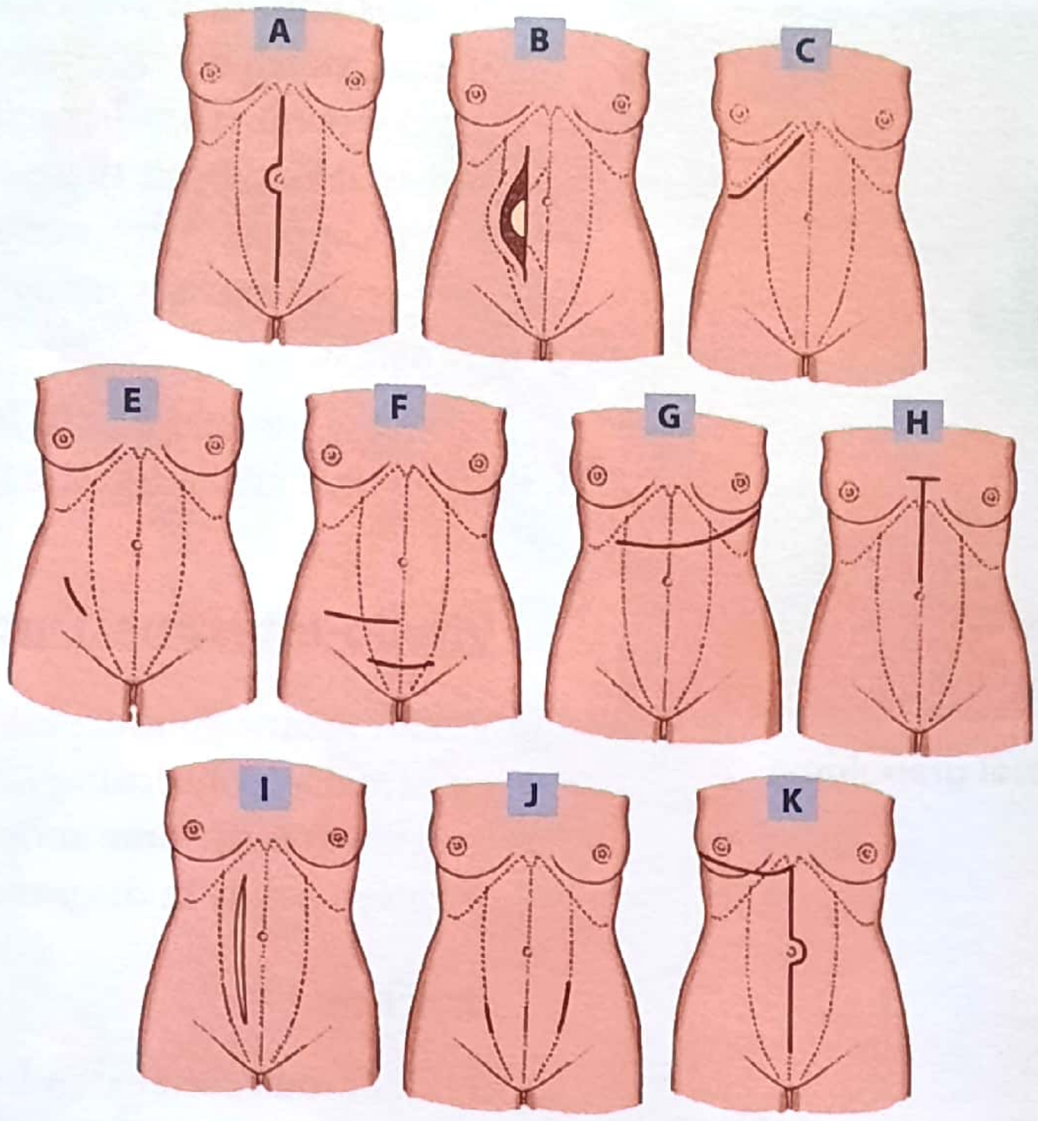

Fig 41.6.2: Different types of abdominal incision

3. Ulceration of anterior abdominal wall.
4. Jaundice:- infection reaching the liver via portal vein and may cause cholangitis and jaundice between 3-6 weeks after birth. *(PGI 81, KERELE 90)*
5. Portal vein thrombosis and subsequent portal hypertension.
6. Infection may reach peritoneal cavity and cause peritonitis.
7. Development of umbilical hernia.

Treatment

- Prophylaxis is the main treatment, as once it happens, it is a dreadful condition. 0.1% chlorhexidine should be applied daily to the stump of the umbilical cord for few days.
- Omphalitis in adult is not uncommon. Patients complain of umbilical discharge, pain is very common symptom. If the infection spread into the sub cutaneous tissues, the opening of the umbilicus becomes narrowed by edema, the whole umbilicus can turn into an abscess. This is known as ***umbilical abscess,*** which requires incision and drainage.

Figure 41.7: Omphalitis

Umbilical Granuloma

It results due to chronic inflammatory process affecting stump of umbilical cord causes excessive granulation tissue formation. The baby presents with a pouting umbilicus covered with bright red, friable mass of bleeding granulation tissue.

Figure 41.8: Umbilical granuloma

Treatments

By destruction of umbilical granuloma by single application of silver nitrate followed by dry dressing.

Umbilical Dermatitis

This condition may be seen at any age. The condition may arise as a result of discharge from the umbilical or parasitic infection.

Umbilical Calculus (Umbolith)

- Desquamated epithelium from umbilicus, its sebaceous secretion, mixed with hairs are sucked into umbilicus and if not properly cleaned may form a hard stone, which is known as umbilical calculus or umbolith.
- They are black in colour and may give rise to inflammation. Umbilicus feels stony hard and is swollen.

Treatment

The condition is treated by dilating the orifice and extraction of the calculus. To prevent recurrence, it may be necessary to excise umbilicus (umbilectomy is done):

Umbilical Fistula

NOTE: Fistula is tubular connection between two cavities

Besides umbilical veins and arteries, there are two more structures which pass through the umbilicus during fetal development. These structures are vitello-intestinal duct and urachus. Both these structures normally obliterate and disappear. Very occasionally; the vitello-intestinal duct or the urachus remain patent, giving rise to umbilical fistula.

Now I would like to help you in understanding the two terms: vitello intestinal duct and urachus.

Vitello-Intestinal Duct

Vitello means yolksac, intestinal-intestinal tract. Vitello intestinal ie; concerning with the embryonic yolk sac and intestinal tract. Some anomalies of vitello intestinal duct are given below in diagram 41.9 and 41.10.

Urachus

It is a fibrous cord extending from apex of urinary bladder to the umbilicus in embryo.

Revision

The urinary bladder develops from the upper end of urogenital sinus, which is continuous with allantois. The allantois is fibrosed, forming a fibrous cord called *Urachus. In* adult; the urachus becomes the median umbilical ligament. If the allantois fails to fibrose, it forms a direct connection between the bladder and out side the body at the umbilicus, this is called as ***Uracal fistula***. Clinically it present as:- urinary discharge from umbilicus. Please see figure 41.10.

Persistent Vitello- Intestinal Duct

The vitello intestinal duct occasionally persist and gives rise to one of the following condition.

1. Vitello- intestinal fistula: discharges mainly mucus and rarely feces through umbilicus, which may be noticed in first few month of life. Figure 41.9 (C) and 41.10 A.
2. Some times both the ends of duct is closed but the mucus membrane of middle portion remains intact & results in, an intraabdominal cyst (Urachal cyst) development. Figure 41.9 (G) and 41.10 (B)
3. It may provide an intra peritoneal band (Fig; 41.9 F) which may be a cause of acute intestinal obstruction.
4. Such a band may contract and pull a meckel's diverticulum. (Fig. 41.9 B, E)

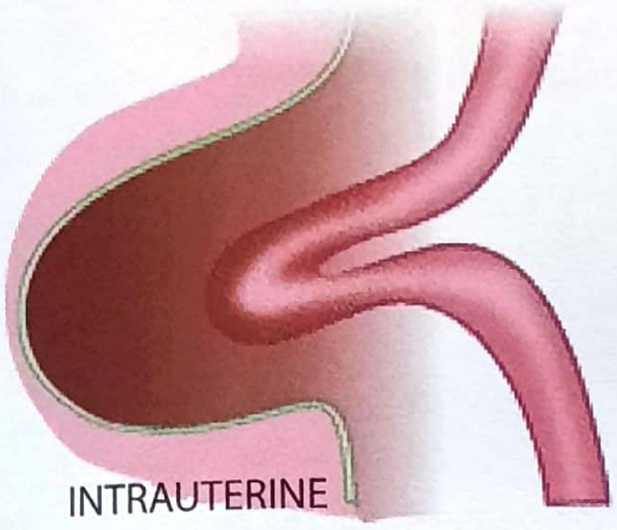

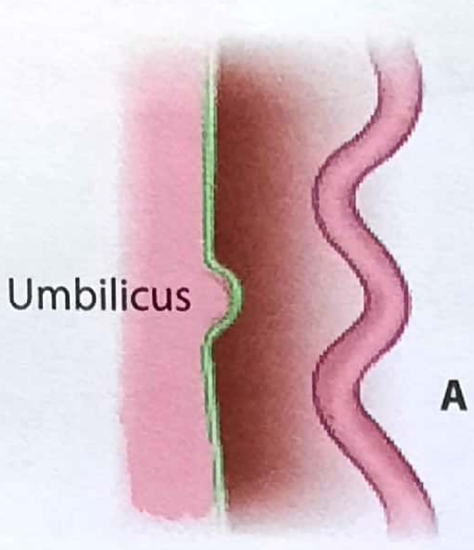

Normal

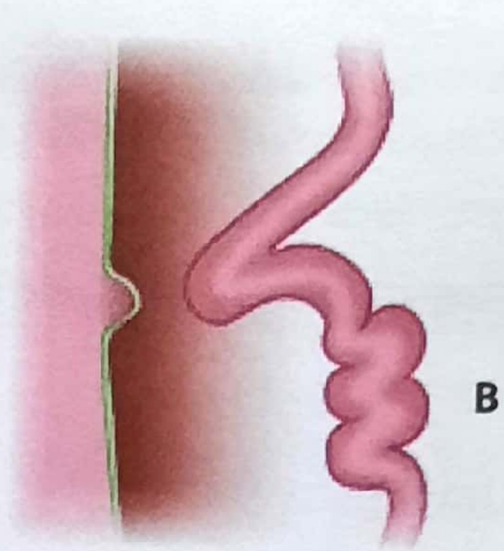

Meckel's diverticulum

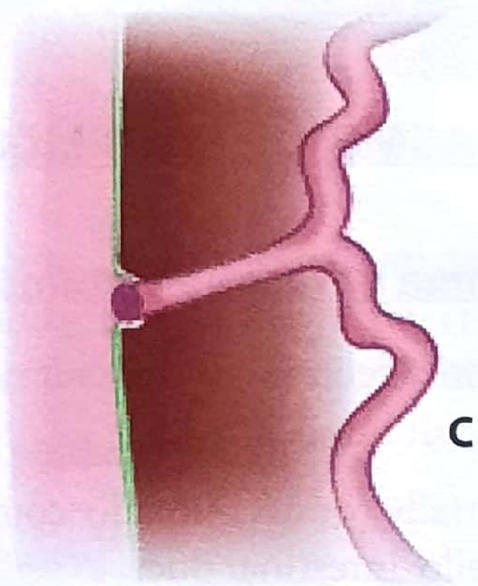

Patent vitellointestinal duct

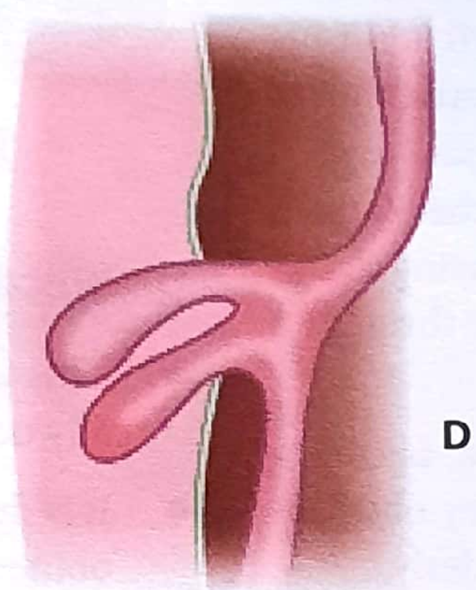

Bowel prolapse

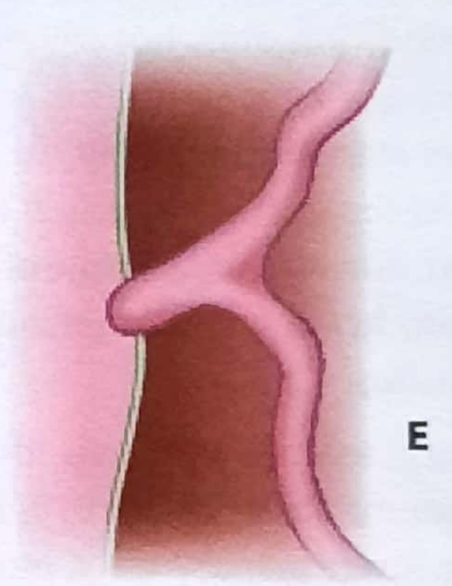

Bowel attached to umbilicus

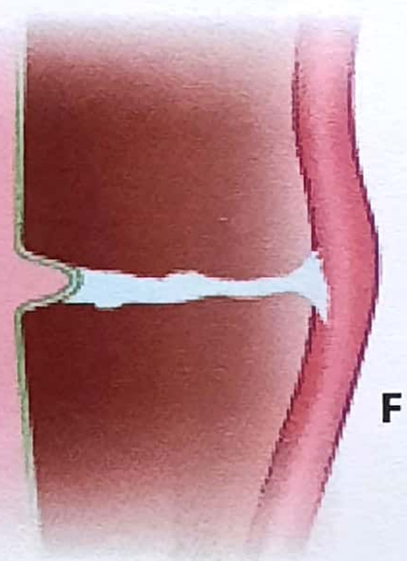

Fibrous band

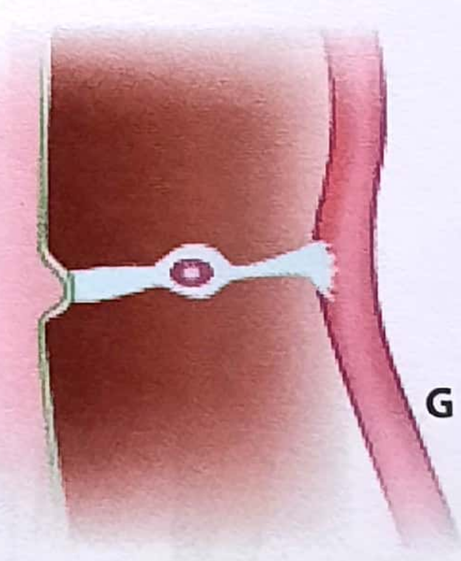

Omphalomesenteric cyst

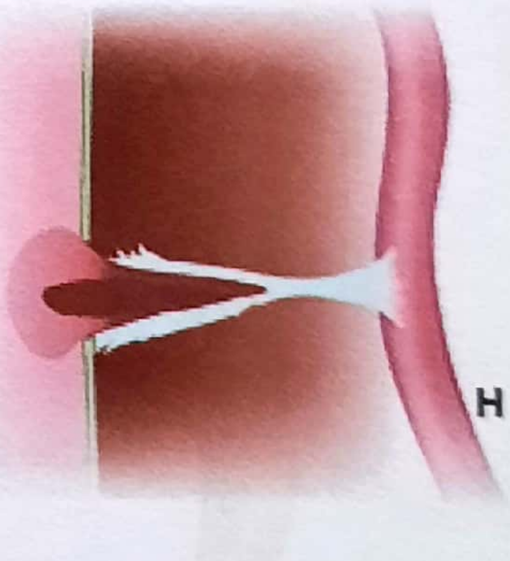

Omphalomesenteric sinus

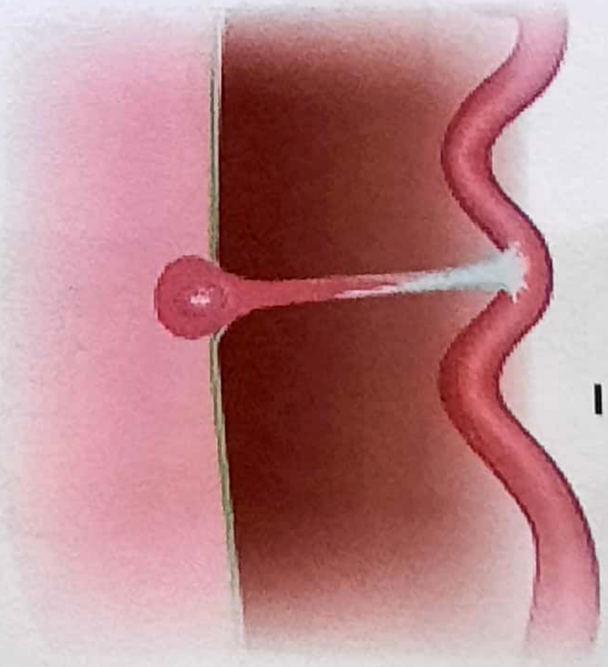

Mucosal polyp

Figure 41.9: Anomalies of vitellointestinal duct

Treatment

- *A patent vitello intestinal duct should be excised preferably at 6 month of age* (PGI 80,81 AMU 89)
- For cyst:- excision is treatment of choice.
- An intraperitoneal band should be divided near both ends.

Patent Urachus (UP 08)

A patent urachus permits leak of urine through the umbilicus due to its connection with urinary bladder, but this condition does not present itself until adult life or even old age. Reason for this is that the contraction of the bladder start at the apex of the organ and pass toward the base. As the urachus opens at the apex of the bladder, it is closed during contraction of bladder during act of micturition; hence urine does not come out through a patent urachus.

Urinary leakage through the umbilicus becomes only symptomatic; when there is some urinary obstruction in the lower urinary tract, like BPH in elderly.

Treatment

Since urinary leakage due to patent urachus is not possible without an obstruction in lower urinary tract, the treatment is directed to get rid of such obstruction. If still the leak persist, the treatment is excision of the umbilicus with excision of urachus down to the apex of bladder.

Urachal cyst (Fig.41.10 B and 41.9 G) is a immobile swelling in the hypo-gastrium. The treatment of this condition is excision of cyst.

*****

NEOPLASMS OF UMBILICUS

Umbilical adenoma or raspberry tumour (NEET)

- This is commonly seen in infants, but can occasionally occur in adult hood.
- It is due to partially (or occasionally completely) unobliterated vitello-intestinal duct. (JIPMER 98)

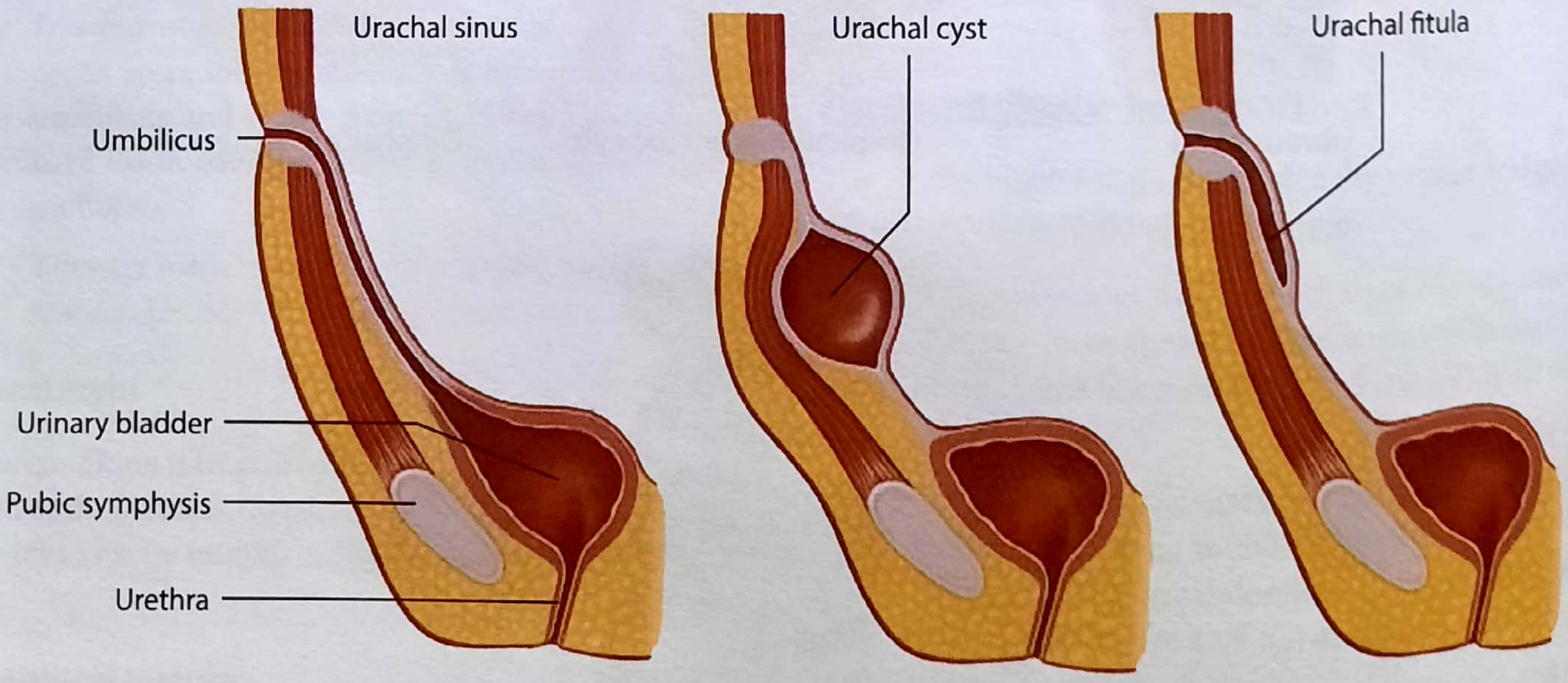

Figure 41.10: (A) Urachal sinus (B) Urachal cyst (C) Urachal fistula

Figure 41.11: Umbilical fistula

- The mucosa of patent duct prolapse through the umbilicus and gives rise to a raspberry- like appearance-hence raspberry tumour. *(PGI, BHU 85).*
- **It often tends to bleed.** *(MANY PGME)*

Treatment

1. If the tumour is pedunculated (ie; tennis racket like), a ligature can be tied at its base (ie;-at the base of handle of tennis racket), so that the arterial supply of the tumour is cut off; and it falls off with in few days, however there are chances of recurrence.
2. **Definitive treatment**: is Umbilectomy (i.e; excision of umbilicus) with excision of the vitello-intestinal duct:-For this abdomen should be opened and if a meckel's diverticulum is also found; it should be excised at the same time.

Note - A cystic mass at base of umblical cord in a neonate. Could be allantoic cyst.

*****

Sample Questions for Prof Examination

1. Write short notes on:
   (i) Burst abdomen
   (ii) Incisional hernia
   (iii) Desmoid tumour
   (iv) Raspberry tumour

42 Hernia

Contents

- Incidence
- Etiology
- Classification of hernia
- Inguinal hernia
  - Indirect inguinal hernia
  - Direct inguinal hernia
- Obstructed and strangulated inguinal hernia
- Rare varieties of inguinal hernia
- Femoral hernia
- Umbilical hernia
  - Exomphalos
  - Umbilical hernia of infant
  - Paraumbilical hernia of adult
- Epigastric hernia
- Rare external hernia
  - Spigelian hernia
  - Sciatic hernia
  - Gluteal hernia
  - Lumbar hernia
  - Obturator hernia
  - Perineal hernia
  - Peterson hernia

Hernia is derived from the Latin word for rupture. **A hernia is defined as an abnormal protrusion (projection) of an organ or tissue through a defect in its surrounding wall.**

Just for understanding: anterior abdominal wall surround the small intestine, omentum & other organs of abdominal cavity. If any point or part of anterior abdominal wall becomes weak (or is congenitally weak),- what will happen?- Intestine or other organs of abdomen will try to come out (protrude) through this defect, resulting in a hernia formation. Do not confuse that the organs will come out (protrude) through skin, instead they will remain beneath the skin, but out of the fascial layers of anterior abdominal wall.

Although hernia can occur at various sites of the body, these defects most commonly involve the anterior abdominal wall, particularly the inguinal region. Abdominal wall hernia occur only at site where the aponeurosis and fascia are not covered by abdominal muscles & hence are weak.

INCIDENCE

Hernia is a common problem. It is estimated that 5% of the population in their life, will develop an abdominal wall hernia.

- **Approximately 75% of all hernia occur in inguinal region and about 80% of all inguinal hernias are indirect inguinal hernia** *(MANY PGME)*
- Incisional hernias account for 10-15% of all abdominal wall hernia. They are twice as common in women than men.

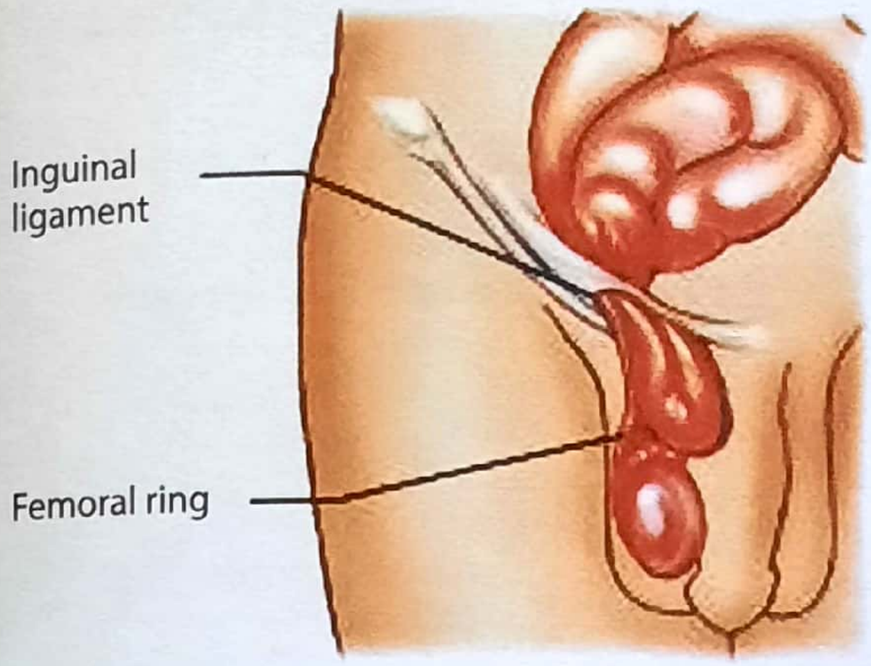

Figure 42.1: Inguinal hernia

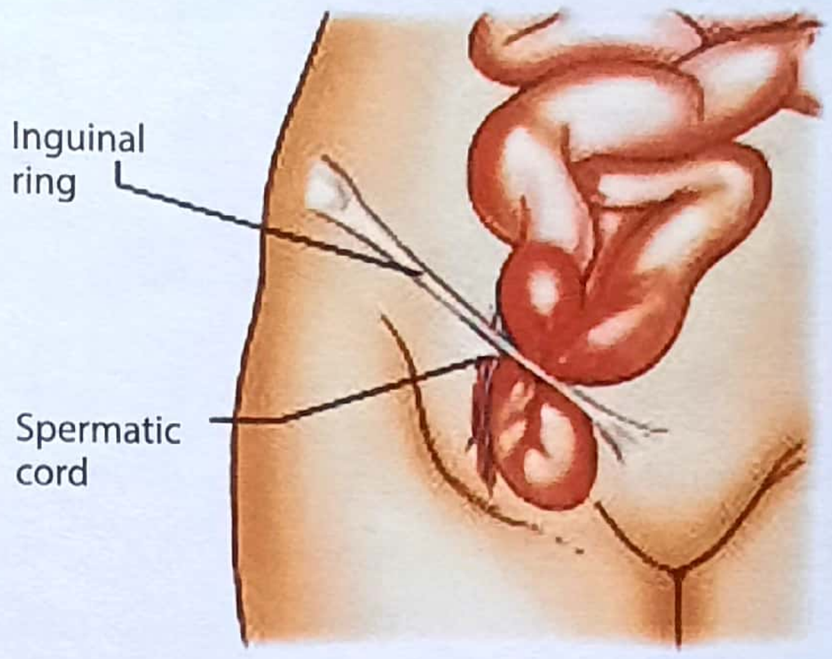

Figure 42.2: Femoral hernia

- Umbilical and epigastric hernias constitute about 10%-15% of hernias. Please see key 42.1 below.
- Femoral hernias account only 5% of all hernia. *(PGI 07)*
- Men are 25 times more likely to develop a groin (inguinal) hernia than female.
- **Indirect inguinal hernia is most common hernia not only in male, but also in female.** *(MANY PGME)*
- There is female dominance in femoral and umbilical hernia of approximately 10 to l and 2 to l respectively.
- Although femoral hernia occur more frequently in women than in men, *inguinal hernia remains the most common hernia even in women.* Femoral hernias are very rare in men. *(PGME, PGI 03)*
- *Both inguinal and femoral hernias,* **occur more commonly on right side.** *(MANY PGME)*
- The prevalence of hernias increases with age, particularly of inguinal, femoral and umbilical hernias.
- The chances for **strangulation is the most serious complication of hernia** and occurs in about 1-3% of groin hernias.
- Most strangulated hernias are indirect inguinal hernias, however, *femoral hernias have the highest rate of strangulation* (15-20%) of all hernia. *(MANY PGME)*

ETIOLOGY

(See flow chart in key box 42.3 on next page)

Mainly 2 factors; play in producing a hernia

1. Weakness in the abdominal wall.
2. Increased intra-abdominal pressure which forces the abdominal content out. Now lets take each factor one by one:

KEY BOX 42.1

Common external abdominal hernias

- Inguinal hernia - 75% *(PGME MANY TIMES)*
- Umbilical hernia - 15%
- Femoral hernia - 8.5%

The rarer form comprise 1.5% excluding- incisional hernia, are:

- Lumbar hernia
- Spigelian hernia
- Obturator hernia
- Gluteal hernia

KEY BOX 42.2

Note: Friends, this is a very important PGME question. Do not get confused.

- Most common strangulated hernia is Inguinal (indirect). The chances for stangulation increases with age.
- Highest rate of strangulation: (Meaning there by number of hernia undergoing strangulation to total number of hernia) is for Femoral hernia, and it is for this reason it is recommended that all femoral hernia should be treated (repaired), at the time of diagnosis.

KEY BOX 42.3

ETIOLOGY OF HERNIA

Weakness in abdominal wall

Congenital

- Persistence of processus gaginalis (in males) Inguinal hernia)
- Patent canal of Nuck (In females)
- Incomplete obliteration of umbilicus (umbilical hernia)

Acquired

- Smoking
- Connective tissue disorders
- Obesity
- Multiple pregnancy
- Surgical Incision (post appendicectomy)

Increased abdominal pressure

- Persistent cough
- BPH and BOO
- Urethral stricuture
- Heavy weight lifting
- Chronic constipation
- Intra-abdominal malignancy

1. ***Weakness in The Abdominal Wall***

It can be either:

A. Congenital or

B. Acquired;

Now lets take each one by one.

(A) Congenital weakness

(*i*) *Persistence of processus vaginalis* This a peritoneal out pouching and is an important cause for indirect inguinal hernia. This is a sort of *preformed sac;* through which the abdominal contents herniate. (Read key box 42.4)

(*ii*) Similarly patent canal of NUCK in female causes indirect inguinal hernia.

(*iii*) Incomplete obliteration of umbilicus; at birth may lead to umbilical hernia in infants.

KEY BOX 42.4

***Processus Vaginalis**

Processus vaginalis is a *pouch of peritoneum* which is pulled down in scrotum during descend of testis from posterior abdominal wall to scrotum during fetal development. This (processus vaginalis) obliterates soon at/or after birth, but some times it remains patent, and works as a preformed sac and increases chances (likelihood) of hernia formation.

(B) Acquired Weakness

(i) Destruction of connective tissue as a result of smoking, aging, connective tissue disease and systemic illness reduces the strength of transversus abdominis muscles and transversalis fascia.

(ii) Muscle weakness may also follow multiple pregnancy.

(iii) Incisional hernia may develop through weak abdominal muscle in lower abdomen following LSCS and other lower abdominal operations.

(iv) Excessive fat in the abdominal musculature predispose to hernia formation; because fat separates muscle fibers and thus causes weakness. *(PGI 07)*

(v) Surgical incision may lead to division of nerve fibres and causes muscle weakness- It is because of this reason that hernia are more common on right side after appendicectomy due to division of ilio Hypogastric nerve.

Just to remember: H for **H**ernia, **H** for (ilio) **H**ypogastric nerve.

2. ***Increased Abdominal Pressure***

Causes of increased abdominal pressure may be due to:

(i) Persistent cough *(PGI 07)*

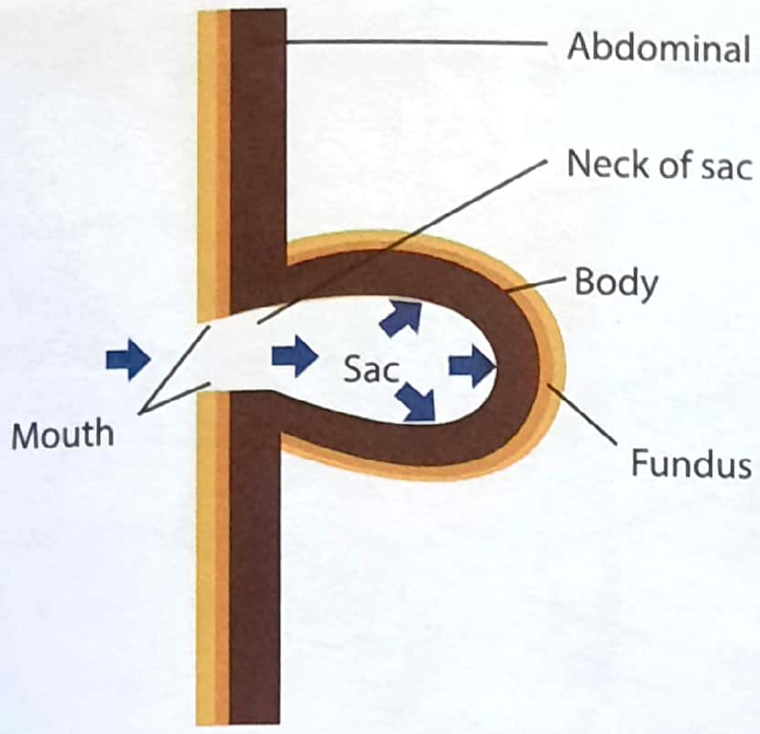

Figure 42.3: Parts of hernia

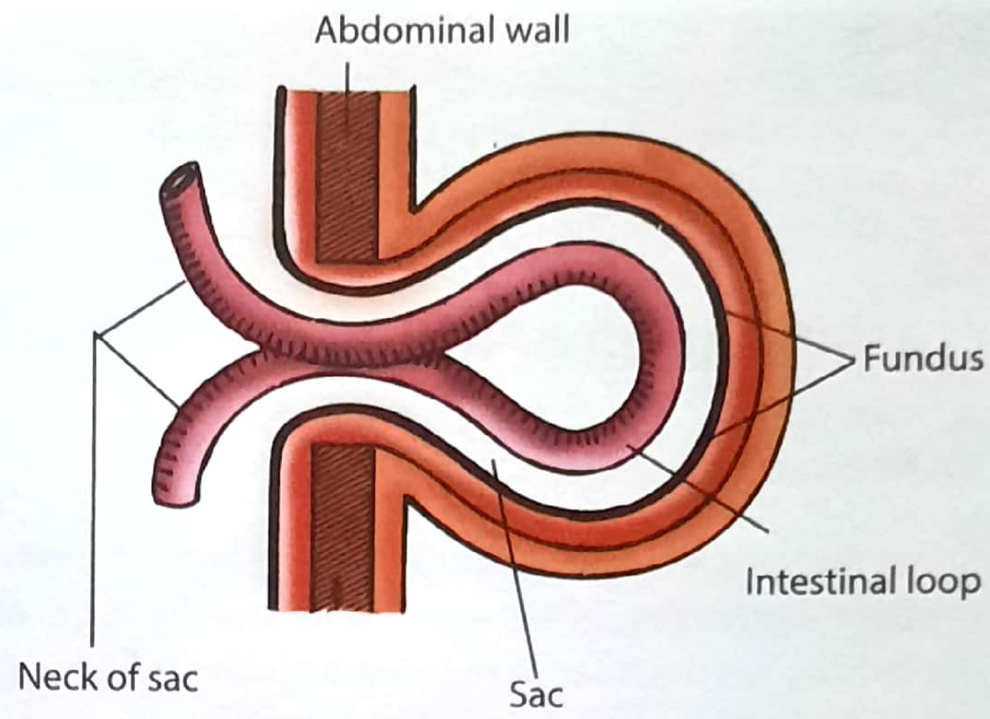

Figure 42.4: Parts of hernia

(ii) Bladder neck obstruction (eg; BPH) or urethral stricture-leading to straining on micturition and increase in intra-abdominal pressure.

(iii) Heavy weight lifting *(PGI 07)*

(iv) Chronic constipation:- causes straining at defection hence increases intra abdominal pressure.

(v) Intra abdominal malignancy.

(vi) Peritoneal dialysis.

PARTS OF HERNIA

The hernia consists of three parts

1. The sac
2. The contents of the sac
3. Covering of hernia (See figure 42.3 & 42.4)

1. *The Sac*

It is **an out pouching of the peritoneum (peritoneal bulge),** which comes out through the abdominal wall musculature. The sac can be divided in four parts. (Fig. 42.3)

(i) Mouth

This is opening of the sac through which the abdominal content (small intestine, omentum etc.) enter the sac.

(ii) Neck of the sac

This is most constricted or narrowest part of sac.

(iii) Body of the sac

This is the wide cavity in which the hernia content remains.

(iv) Fundus

It is the lowest part of the sac. (fig. 42.3 and 42.4)

2. *Content of the Sac*

The abdominal organs which lie within the sac is called as content of the hernial sac.

Depending upon the content in the sac; the hernia is named as:-

(i) When the content in the sac is omentum; the hernia is called as ***omentocele***

(ii) When the content in the sac is a loop of intestine; the hernia is called as ***enterocele.***

(iii) When the content in the sac is a portion of the circumference of the intestine [**Note:** Only circumference of the intestine, (not the whole loop it)] is called as: ***Richter's hernia.***

(iv) When content of a sac is meckel's diverticulum:- the hernia is called as ***littre's hernia.***

(v) When two loops of small intestine remains in the manner of 'W' the hernia is called as ***maydle's hernia.*** (Figure 42.6, at page no. 764). There occurs strangulation of internal loop.

In fact all the abdominal viscera except pancreas are known to have herniated into the sac.

Revise with the help of key box 42.4, figure 42.5a & b.

3. *Covering*

The covering of the hernia is derived from the layers of the abdominal wall through which the sac traverses.

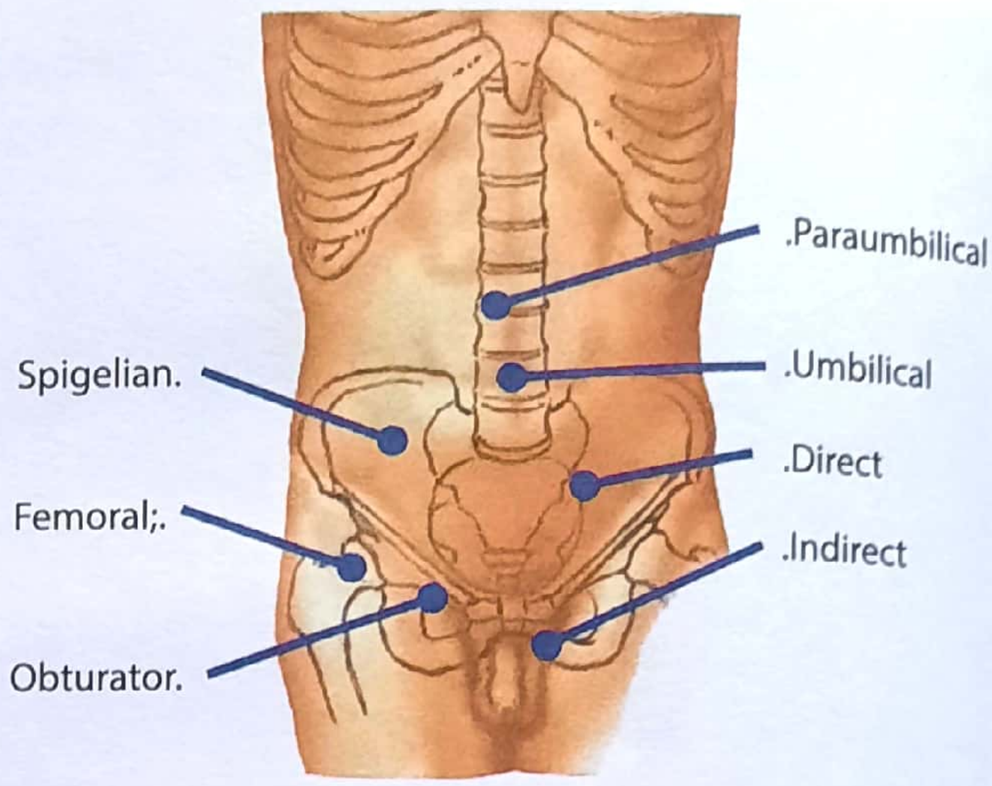

Figure 42.5a : Sites of various hernia

CLASSIFICATION OF HERNIA

1. Reducible hernia

Reducibility of a hernia means returning back of a hernia in abdominal cavity. When a hernia reduces by itself soon the patient lies down, or is reduced by patients himself or by surgeon, it is called as reducible hernia.

2. Irreducible hernia

When the contents of the hernia **cannot be returned back** in the abdominal cavity, it is called as irreducible hernia.

Causes of irreducibility may be:

- Adhesion between sac and its content.
- Over crowding of content in sac often causes irreducibility.
- When the content of sac is large intestine.
- Femoral and umbilical hernias are often irreducible.
- Irreducibility of a hernia is directly proportional to chances of stangulation.

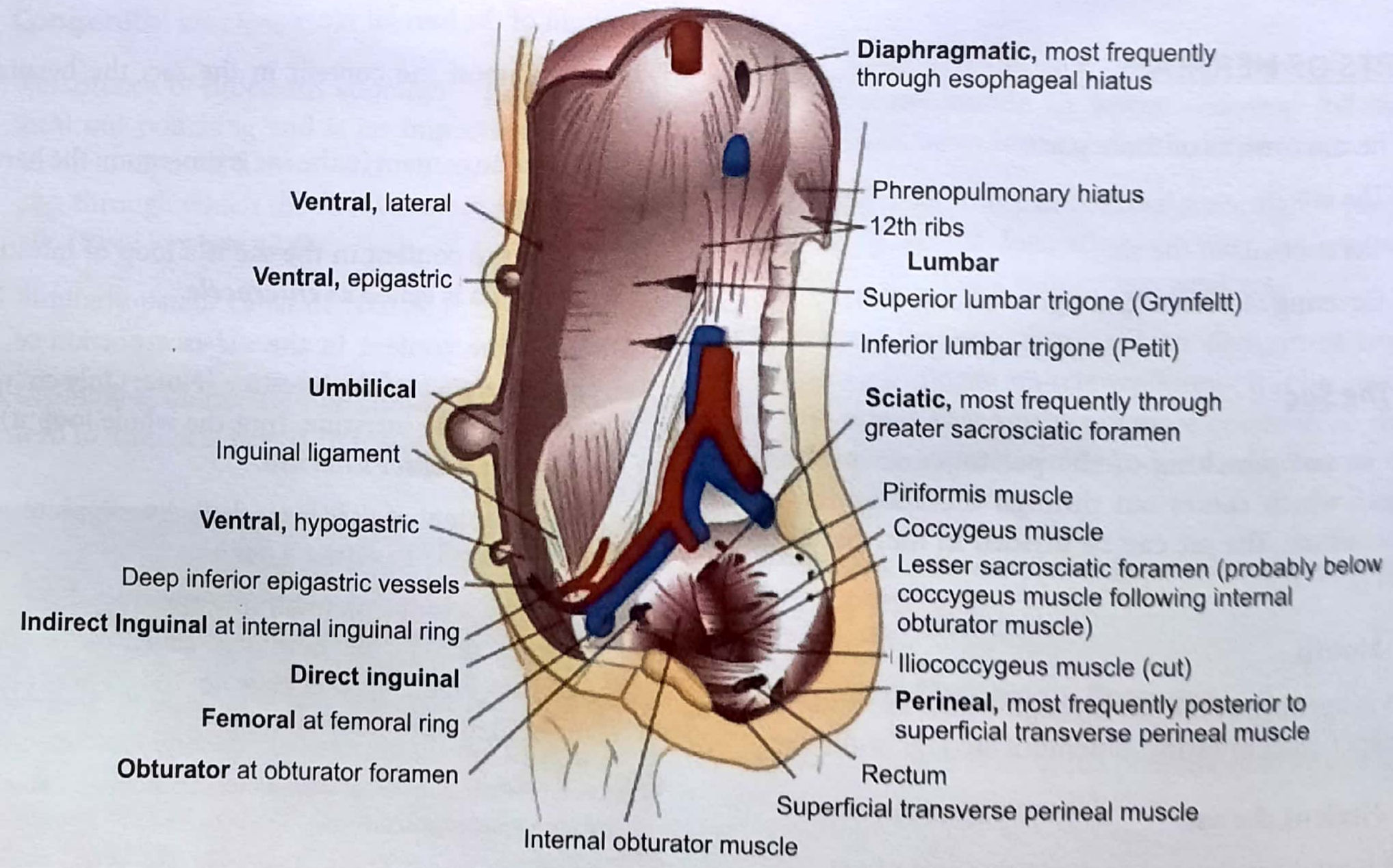

Figure 42.5b: Sites of various hernia

KEY BOX 42.4.1

Parts of Hernia

Sac

- Mouth
- Neck
- Body
- Fundus

Content

- Loop of intestine -***enterocele***
- Omentum - ***Omentocele/Epiplocele***
- Circumference of intestine -***Richter's hernia***
- Mickel's diverticulum - ***Littre's hernia***
- Two loop of intestine when remain in 'W' manner - ***Maydl's hernia***

Covering

- Derived from the layers of the anterior abdominal wall

3. Obstructed hernia

When an irreducible hernia containing intestine present with intestinal obstruction, *but there is no interference to the blood supply to the intestine;* present in the hernial sac. The features of obstructed hernia are-

- Expansile cough impulse is not present.
- The hernia is irreducible.
- The symptoms like:- Colicy abdominal pain & tenderness over the hernia sac are present, but less severe & onset is more gradual than in the strangulated hernia.

KEY BOX 42.5

Primary abdominal wall hernias

Groin

- Inguinal
  - Inguinal
  - Indirect
  - Direct
  - Combined
- Femoral

Anterior

- Umbilical
- Epigastric
- Spigelian

Pelvic

- Obturator
- Sciatic
- Perineal

Posterior

- Lumbar
  - Superior triangle
  - Inferior triangle

4. Incarcerated hernia

The term 'incarcerated hernia' is often used as an alternative name to obstructed hernia but more precisely speaking; the *content of hernid sac is colon & is blocked by feces.*

5. Strangulated hernia

A hernia is said to be strangulated when the *blood supply of its content is seriously impaired and ultimately the contents becomes gangrenous.* This condition develops when the neck of the sac is very much narrow. Femoral hernias often strangulate, because of the narrowness of the neck and its rigid surrounding.

6. Inflamed hernia

Inflammation can occur from inflammation of the contents of the sac, eg. if the content is inflamed appendix or an inflamed ovary.

Friends this classification is often asked in examination either MBBS final prof, in viva or PGME examination. I have simplify this classification, so that you can remember it at the time of death. Please read key box 42.6, 42.4.1

KEY BOX 42.6	
Reducible hernia	Contents can be returned back in abdominal cavity
Irreducible hernia	Contents cannot be returned, back to abdominal cavity
Obstructed hernia	Irreducible hernia with intestinal obstruction
Strangulated hernia	Irreducible hernia with intestinal obstruction with arrest (obstruction) to blood supply to the content
Incarcerated hernia	Irreducible hernia with intestinal obstruction which has colon as the content of sac.
Inflamed hernia	Inflammation of contents of sac.

DIFFERENT CLASSIFICATION

European hernia society classification of hernia

Midline incisional hernia

M1 - Subxiphoid
M2 - Epigastric
M3 - Umblical
M4 - Infraumblical
M5 - Suprapubic

Lateral incisional hernia

L1 - Subcostal
L2 - Flank

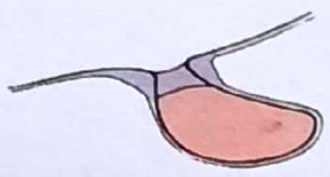

A.

Neck of sac

This tight ring of peritoneum is usually the site of any strangulation

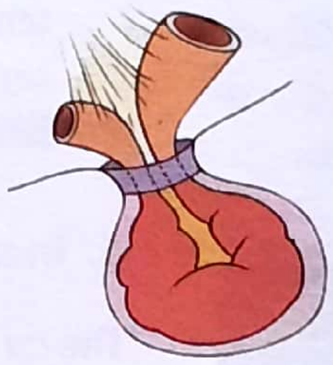

B.

A strangulated hernia

The blood supply of the contents of the hernia is cut off. When a loop of gut is strangulated there will also be intestinal obstruction

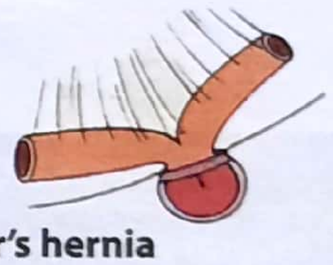

C. Richter's hernia

If the sac is small, a knuckle of bowel can be caught in the sac and strangled without causing intestinal obstruction. this is called a Richter's hernia

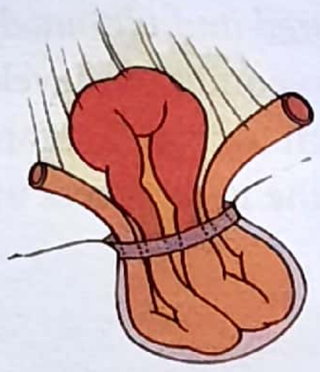

D.

Maydl's hernia

When two adjacent loop of bowel are in the sac, the intervening portion in the abdomen is the first to suffer if the neck of the sac is tight, because it is the centre of the whole loop involved. Thus the strangulated piece is intraabdominal. This is a rare variety of strangulation

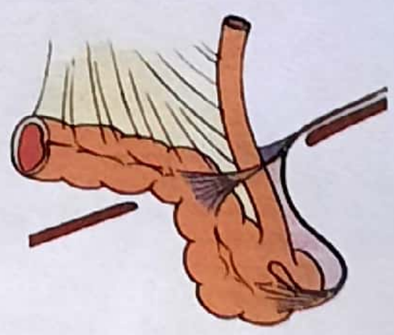

E.

Sliding hernia

If **bowel which is normally extraperitoneal forms one side of the sac,** (NEET) it is thought to have slide down the canal pulling peritoneum with it, hence the name hernia-en-glissade. The sac can contain other loops of bowel, and the gut forming the wall of the sac can be strangled by the external ring

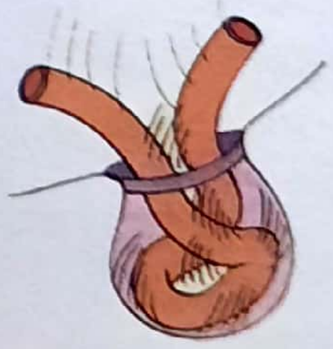

F.

Incarceration

The contents are fixed in the sac because of their size and adhesions. The hernia is irreducible but the bowel is not strangulated or obstructed

Figure 42.6: Various types of hernia

L3 - Iliac

L4 - Lumbar

Please see figure 42.6E.

Nyhus classification

Type I - Indirect hernia; internal abdomen ring normal, typically in infants, children, small adults.

Type II - Indirect hernia, internal ring enlarged without impingament on floor of inguinal canal. Does not extend to scrotum.

Type IIIA (NEET) - Direct hernia, size not taken into account.

Type IIIB - Indirect hernia that has enlarged anough to encroach upon the posterior inguinal wall, indirect sliding or scrotal hernia, pantaloon hernia.

Type IIIC - Femoral hernia.

Type IV - Recurrent hernia

A - Indirect

B - Direct

C - Femoral

D - Mixed

European Hernia Society Incisional Hernia Classification			
Midline	Subxiphoidal	M1	
	epigastric	M2	
	umbilical	M3	
	infraumbilical	M4	
Lateral	suprapubic	M5	
	subcostal	L1	
	flank	L2	
	iliac	L3	
	lumbar	L4	
Recurrent incisional hernia?			Yes O No O
length	cm	width	cm
Width	W1	W2	W3
cm	< 4 cm	≥ 4-10 cm	≥ 10 cm

*****

Now lets come to the point i.e., **Inguinal Hernia**

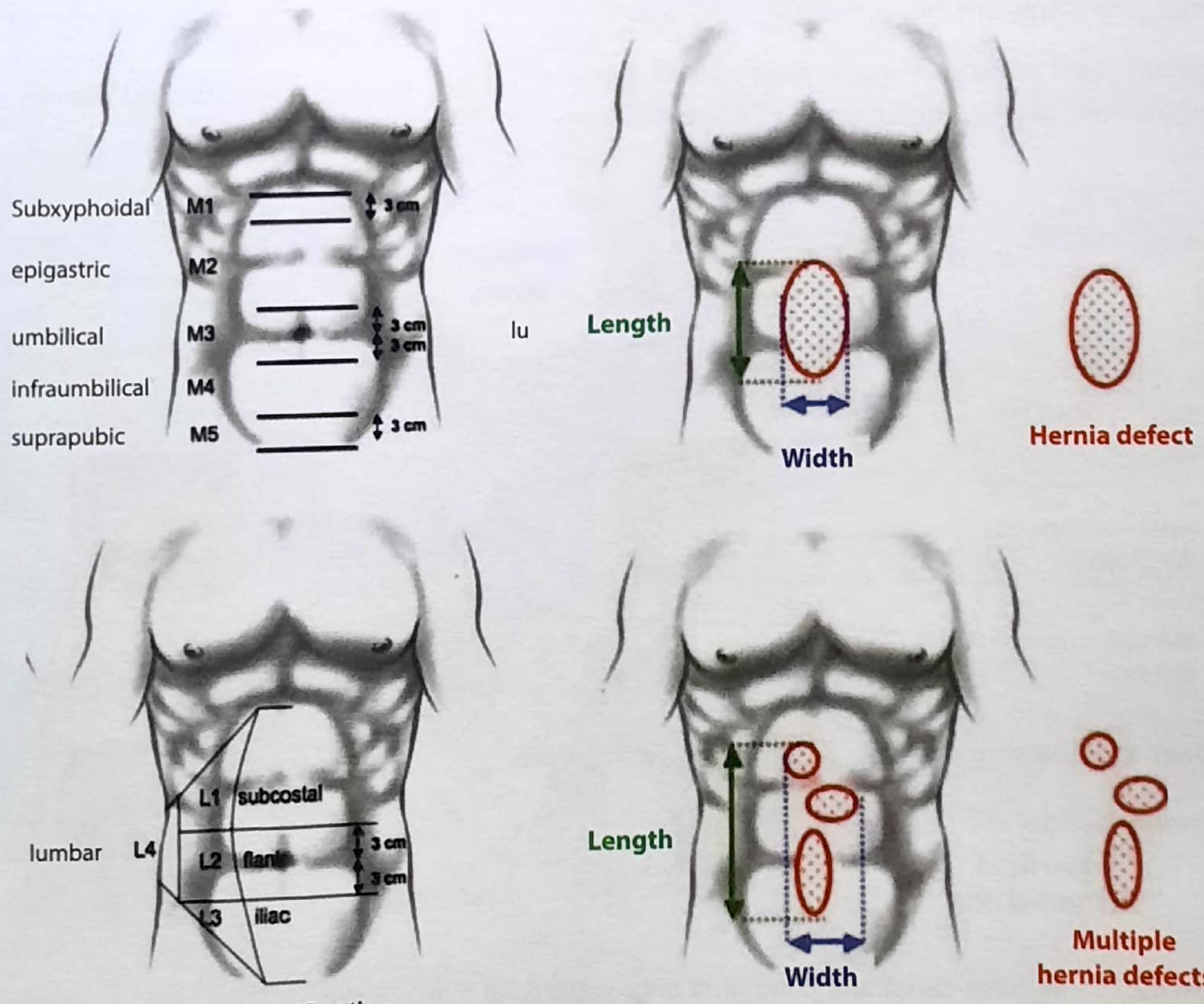

Figure 42.6E: European hernia society classification

Nyhus Classification

Type 1	Type II	Type III	Type IV
Indirect Inguinal Hernia : (Normal Sized Deep Ring)	Indirect Inguinal Hernia : (Dilated Deep Ring) Intact Posterior Wall	▪ A - Direct Inguinal Hernia ▪ B - Indirect Inguinal Hernia (Dilated Deep Ring encroaching onto Hesselbach's Triangle) ▪ **Femoral Hernia**	Recurrent Hernia ▪ A - Direct Hernia ▪ B - Indirect Hernia ▪ C - Femoral Hernia ▪ D - Combined

INGUINAL HERNIA

Anatomy of inguinal canal

- It is an oblique canal situated in the lowest part of anterior abdominal wall and runs parallel to the medial half of the inguinal ligament. *(MANY PGME).*
- This canal is formed due to passage of testis and spermatic cord in males and round ligament of the uterus in females in embryonic life.
- Inguinal canal is 4 cm long obliquely placed, passing forward medially and downward. (Figure 42.7)
- **Inguinal canal extends from deep inguinal ring to the superficial inguinal ring.**

Deep (Internal) Inguinal Ring

(also called as Internal inguinal ring) is situated about 1cm above the middle of the inguinal ligament. *It is an opening in fascia transversalis* *(MANY PGME)*. The deep ring in males transmits, spermatic cord, which contains the following structures:

1. Vas deference
2. Testicular vessels and nerves

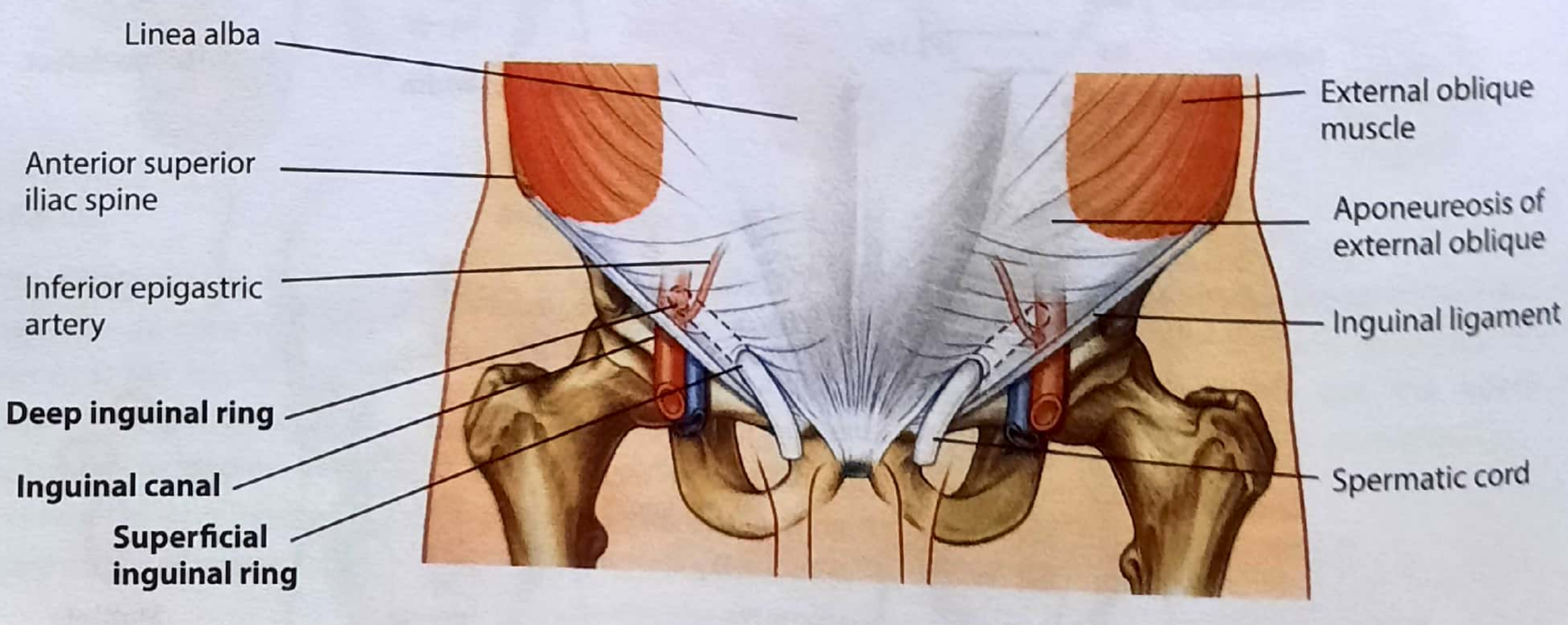

Figure 42.7: Inguinal canal, deep inguinal ring, superficial inguinal ring

KEY BOX 42.7

Revision *(PGME-MANY TIME)*

- **External (superficial) inguinal ring:** an opening in External oblique aponeurosis.
- **Internal (deep) inguinal ring:** Opening in most Internal (deepest) fascia of abdominal wall i.e. fascia Transversalis.

3. Venous plexus (pampiniform plexus)
4. Artery to the vas
5. Cremasteric branch of inferior epigastric artery
6. Ilio inguinal nerve.
7. Genital branch of genito femoral nerve.
8. Processus vaginalis.

Above mentioned structures enter the inguinal canal through the deep (internal) inguinal ring and come out through superficial (external) inguinal ring.

Please see figure 42.7, and locate deep inguinal ring:

Superficial (External) Inguinal Ring

It is the end of the inguinal canal and is just superior to public tubercle. It is a triangular shaped ***opening in ex(S)lternal oblique aponeurosis*** *(MANY PGME)*. The structures passing through inguinal canal come out down to scrotum, through Superficial ring. (note "S" in text)

Friends this is one; you will forget most of the time

JUST TO REMEMBER: Spell eXternal inguinal ring as eSternal inguinal ring. Superficial (eSternal) inguinal ring is an opening in eSternal oblique aponeurosis. Deep inguinal ring is an opening in the Deepest layer of anterior abdominal wall; that is fascia transversalis.

KEY BOX 42.8

Boundaries of Inguinal Canal

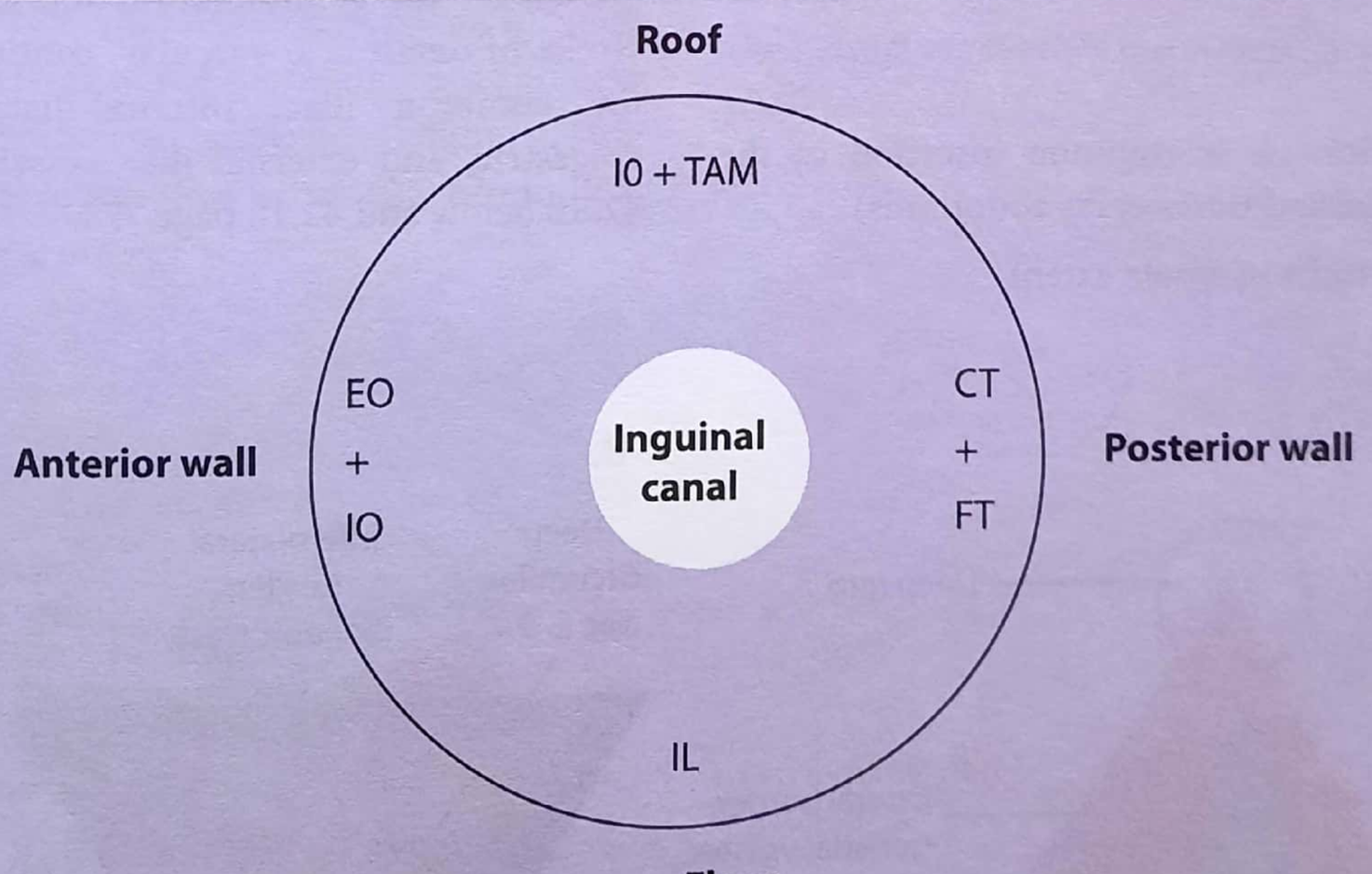

Schematic diagram of boundaries of inguinal canal

EO - External oblique aponeurosis
IO - Internal oblique muscle
CT - Conjoint tendon (common tendon of internal oblique and transversus abdominis
FT - Fascia transversalis
TAM - Transversus abdominis muscle
IL - Inguinal ligament

Figure 42.8A: A patient with left inguinal hernia

Boundaries of Inguinal Canal *(MANY PGME)*

Anterior wall:

It is formed by

1. Aponeurosis* of external oblique in whole extent.
2. Some fibers of the internal oblique muscle laterally.

Posterior Wall

1. Conjoint tendon (It is common insertion of the internal oblique and transversus abdominis)
2. Fascia transversalis in whole extent.

Roof

It is formed by the arched fibers of the *internal oblique and transversus abdominis* muscles.

Floor

It is formed by *inguinal ligament* (see fig 42.7 and key box 42.8)

REVISION : Aponeurosis?: A flat fibrous sheet of connective tissue that attaches muscle to bone, which may some time serve as a fascia.

The preperitoneal anatomy seen in **laparoscopic hernia repair led** to characterization of important anatomic areas of interest, known as the triangle of doom, the triangle of pain, and the circle of death. The **triangle of doom** is bordered medially by the vas deferens and laterally by the vessels of the spermatic cord and peritoneal fold inferiorly. The contents of the space include the external iliac vessels, deep circumflex iliac vein, femoral nerve, and genital branch of the genitofemoral nerve. The **triangle of pain** is a region bordered by the iliopubic tract and gonadal vessels, and it encompasses the lateral femoral cutaneous, femoral branch of the genitofemoral and femoral nerves. The **circle of death** is a vascular continuation formed by the common iliac, internal iliac, obturator, inferior epigastric, and external iliac vessels. Please see figure 42.8B below and 42.16 page 774.

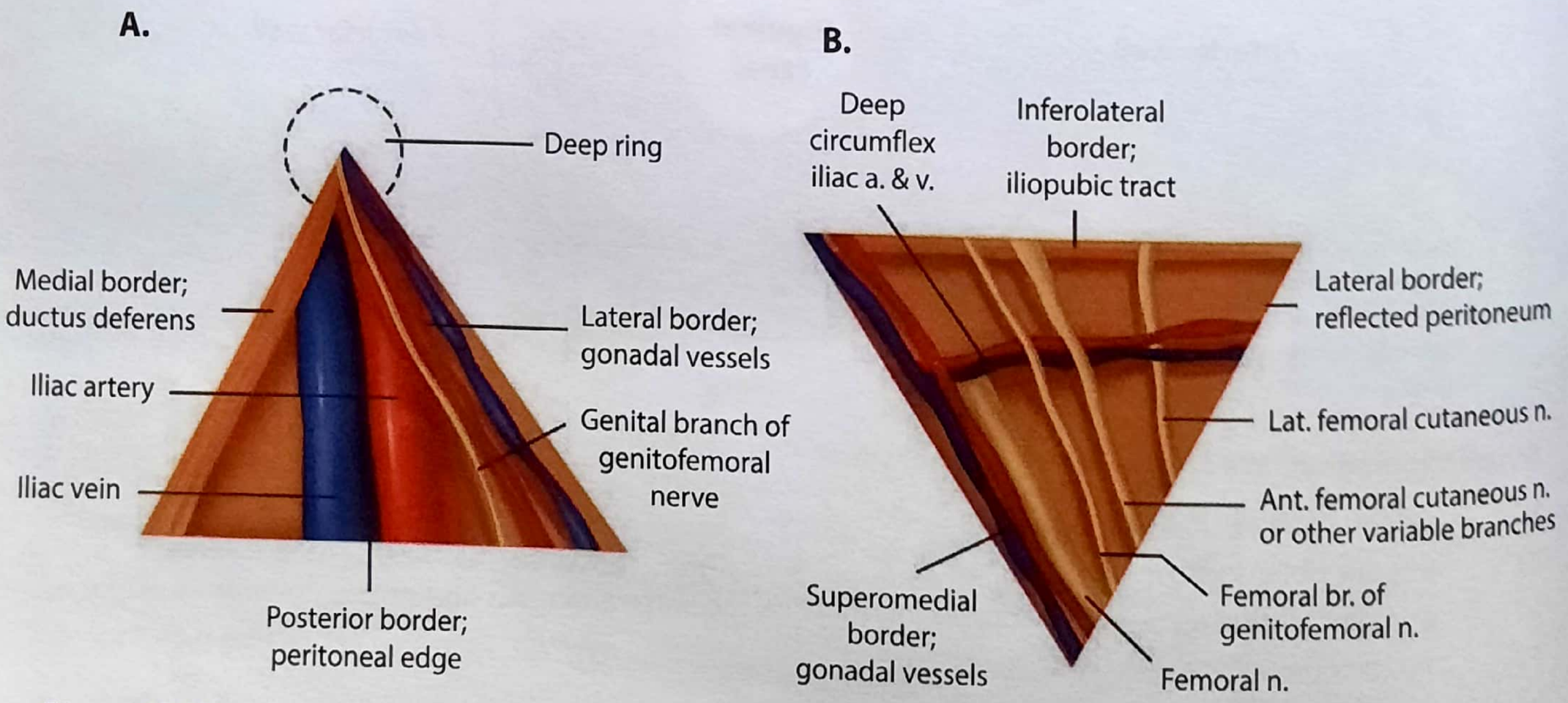

Figure 42.8B : Borders and contents of the (A) triangle of doom and (B) triangle of pain. a. = artery; Ant. = anterior; br. = branch; Lat. = lateral; n. = nerve; v. = vein;

Laparoscopic inguinal hernia repair requires a thorough knowledge of inguinal anatomy from a posterior perspective. Intraperitoneal points of reference are the five peritoneal folds, bladder, inferior epigastric vessels, and psoas muscle. Two potential spaces exist within the preperitoneum. Between the peritoneum and the posterior lamina of the transversalis fascia is Bogros's (preperitoneal) space. This area contains preperitoneal fat and areolar tissue. The most medial aspect of the preperitoneal space, that which lies superior to the bladder, is known as the space of Retzius. The posterior perspective also allows visualization of the myopectineal orifice of Fruchaud, a relatively weak portion of the abdominal wall that is divided by the inguinal ligament.

*****

TYPES OF INGUINAL HERNIA

1. Indirect (Oblique) Inguinal Hernia

In an indirect inguinal hernia, the sac enters the inguinal canal through the deep (internal) inguinal ring, just lateral to the inferior epigastric artery, passes through the inguinal canal in front of the spermatic cord and may come out through the external (superficial) inguinal ring to descend into the scrotum (See figure 42.9 carefully & note inferior epigastric artery)

This is the **most common** of all forms of hernia and is most common in young adult male *where as a direct hernia is more common in elderly male.* (MANY PGME)

There is higher incidence of failure of closure of the processus vaginalis* on the right side, may be due to later descent of right testis; as a result of which indirect inguinal hernia are more common on right side.

Types of Indirect Inguinal Hernia

Three types of indirect inguinal hernia occurs:

1. Bubonocele

The hernia is limited in the inguinal canal. The sac of hernia does not extend beyond the external (superficial) inguinal ring. Kindly see figure 42.10 A.

2. Funicular (NEET)

The hernial sac conies out of external (superficial) inguinal ring to reach to the top of testis. The contents of the sac can be felt separately from the testis which lie below the hernia. Kindly see figure 42.10 B.

3. Complete (Scrotal)

The hernial sac reaches the bottom of scrotum. See figure 42.10 C.

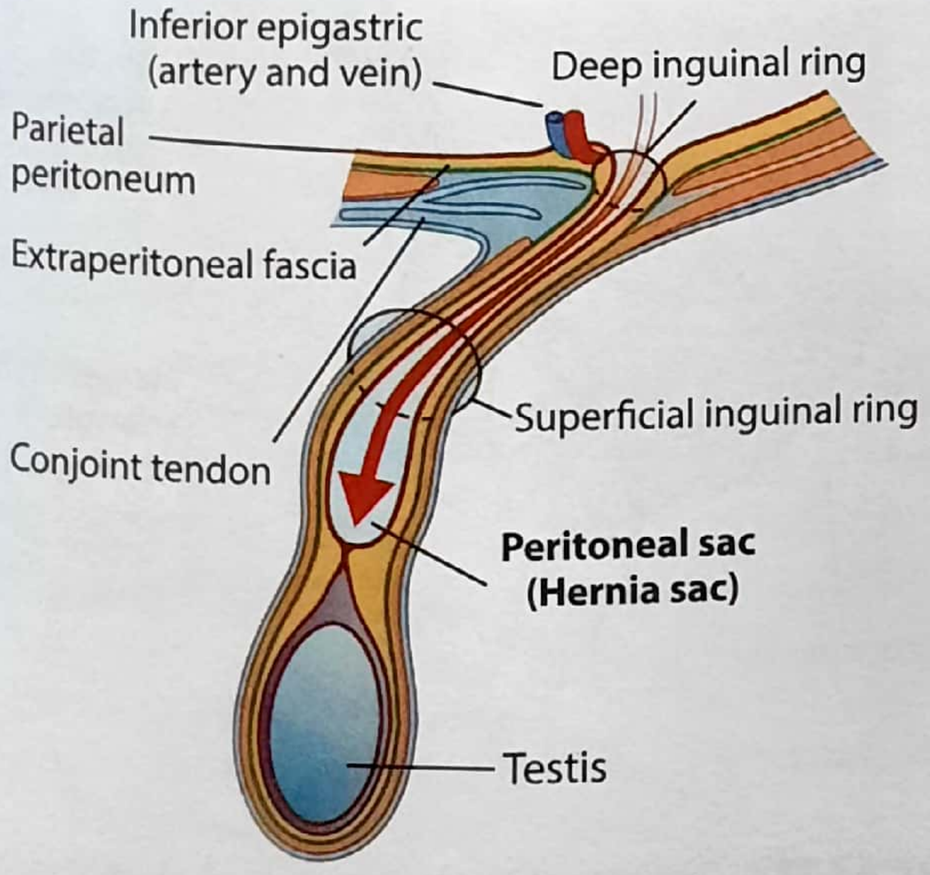

Figure 42.9: Left Indirect inguinal hernia

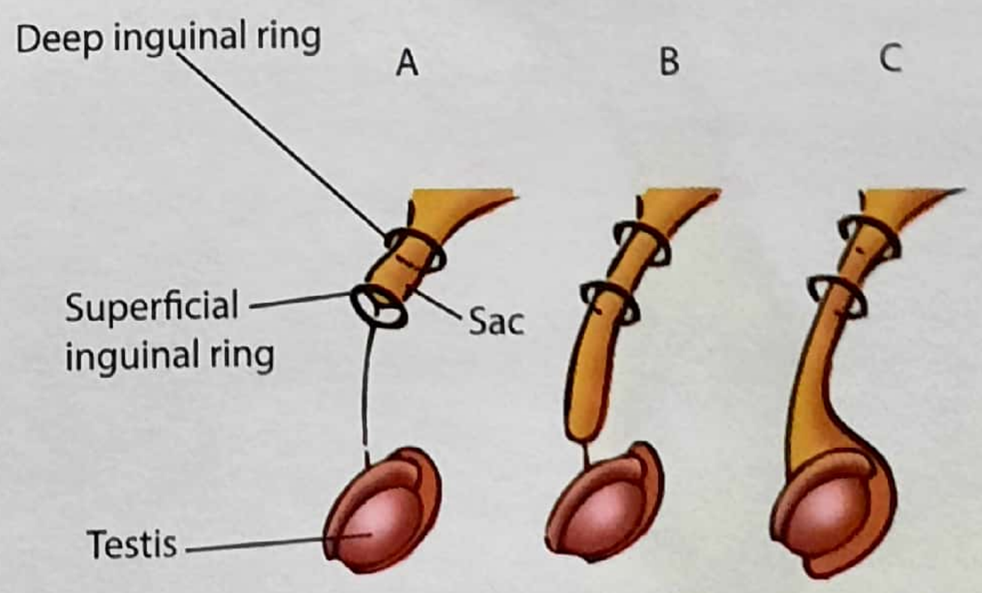

Figure 42.10: Types of indirect (oblique) inguinal hernia

2. Direct Inguinal Hernia

In adult males; about 35% inguinal hernia are direct. A direct hernia is altnost always acquired in old age (PGI DEC 03) (except Ogilvie hernia) .

A direct inguinal hernia *protrudes through the posterior wall of the inguinal canal* medial to the inferior epigastric vessels ie; through **Hesselbach's triangle***.(NEET, PGME) (Figure 42.12)

- Such hernia lie outside the spermatic cord; behind the cord. (IMP. POINT)
- *Neck of direct hernia lies medial to the inferior epigastric vessels, where as the neck of the indirect hernia lies lateral to the inferior epigastric vessels.* (MANY PGME)
- When a direct hernia encircles around the inferior epigastric vessels, it gives an appearance of two limbs of a pontoon (pant) and then this is known as pantaloon hernia or saddle bag hernia, which has both medial and lateral component. (MANY PGME)
- Direct inguinal hernia rarely attain a large size, and if at all it comes through the external inguinal ring, it does almost never descends up to the bottom of scrotum, (imp. point to remember)

• Hessel bach's triangle (figure 42.12)

It is a weak area of anterior abdominal wall through which direct inguinal hernia protrudes. It is a triangle which is bounded*

Medially - by lateral border of the rectos abdominis muscle.

Laterally - by the inferior epigastric vessels.

Below - by the medial part of inguinal ligament.

Floor of this triangle is formed by fascia transversalis. Through this triangle most of the direct hernia come out

- As *the **neck of a direct hernial sac is wide**, they rarely get strangulated.* (PGI JUNE 03, AIIMS NOV 93).
- Please read key box 42.9 on page no 771.

Clinical Features (of hernia)

- Most of the patient has no symptom other than a bulge (swelling) in inguinal region.

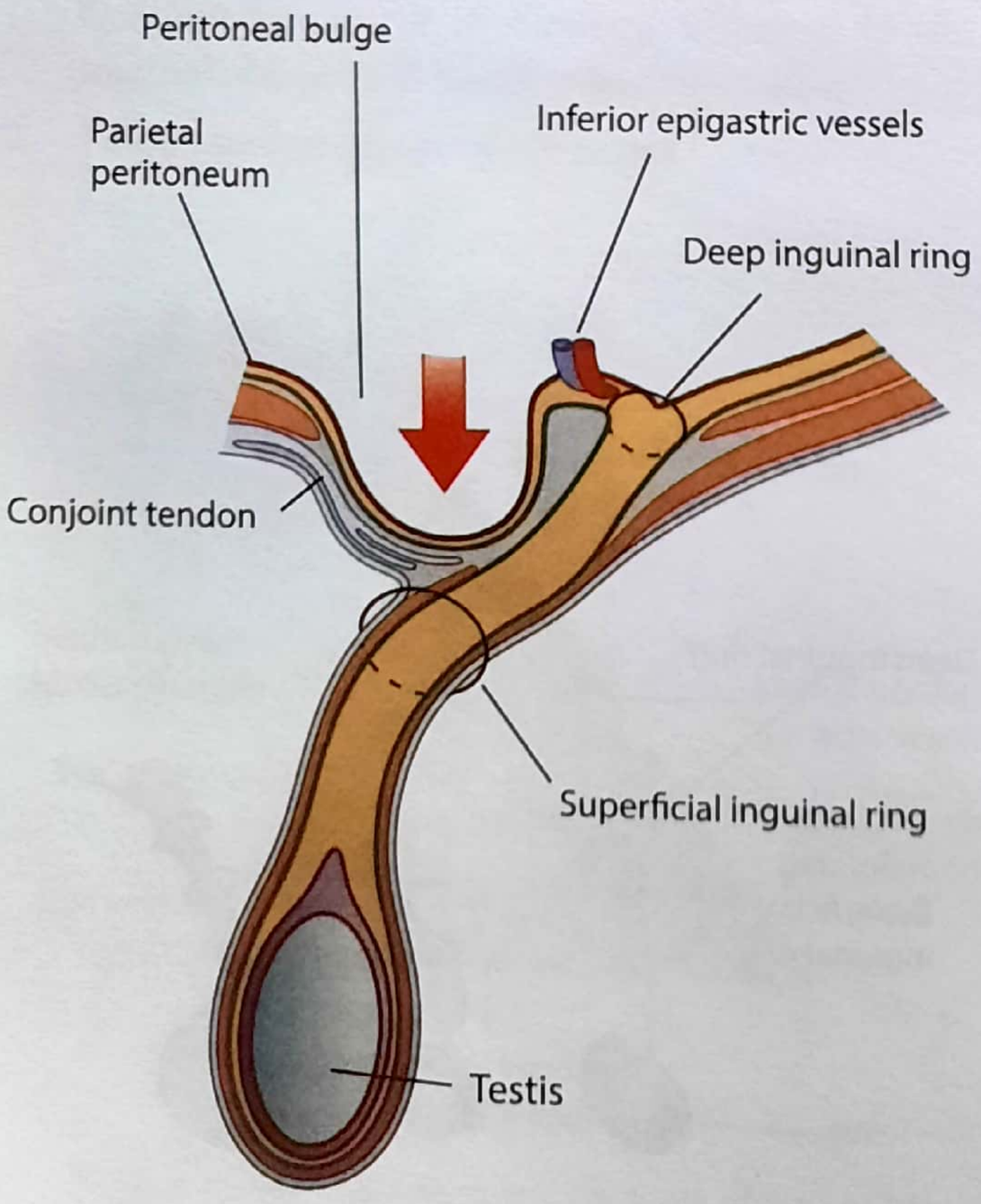

Figure 42.11: Direct inguinal hernia

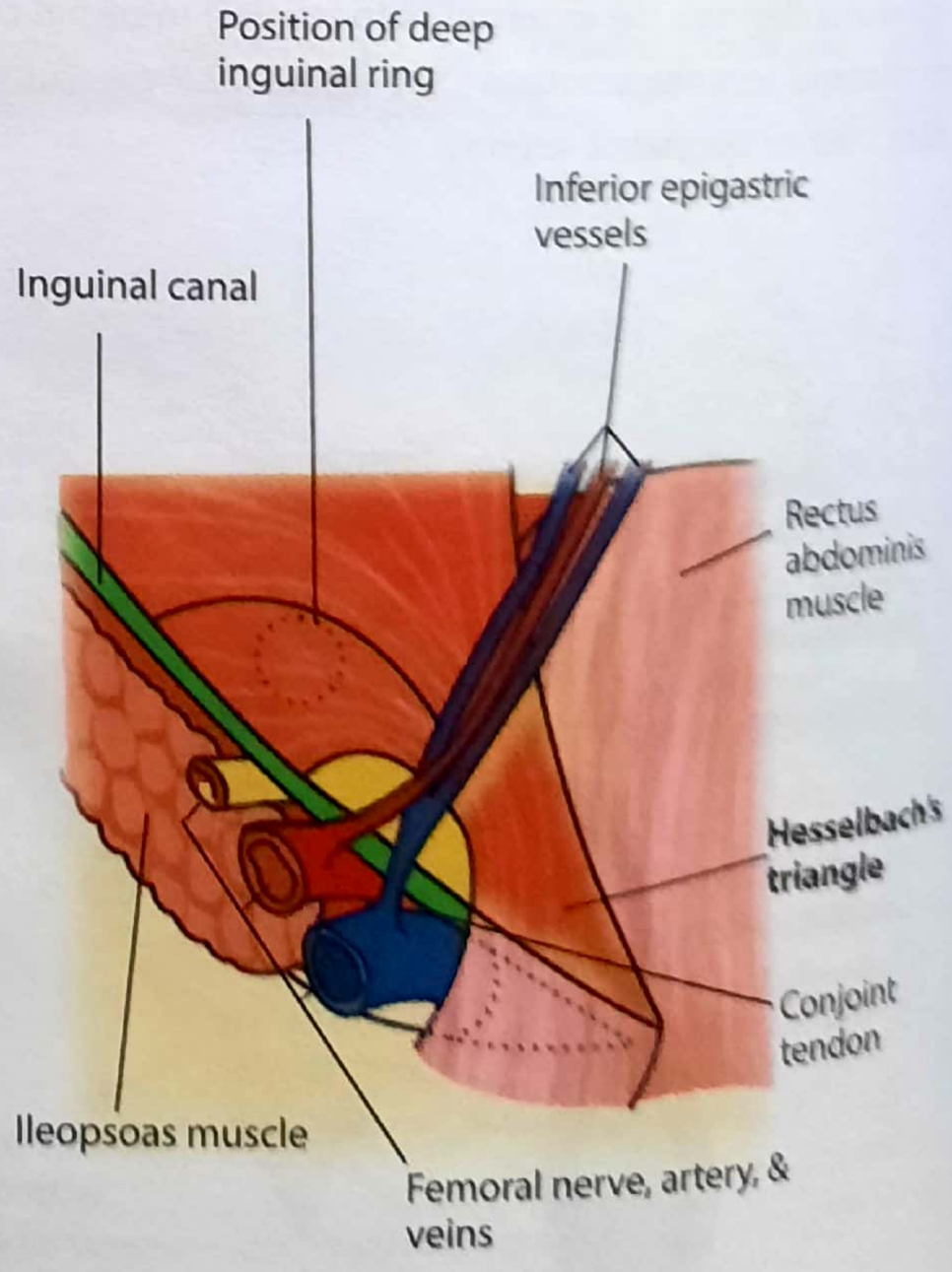

Figure 42.12: Digramatic representation of Hesselbach's triangle

- Some times, patient complains of pain in the groin or pain referred to testicle.
- When asked to cough, a small transient bulging may be seen and felt together with an expansile impulse.
- In large hernias, there is a sensation of weight and dragging on the mesentery, which may some times produce epigastric pain.
- In infants the swelling appears when the child cries.
- The *diagnosis of inguinal hernia is usually made on clinical examination* (IMP. POINT) .

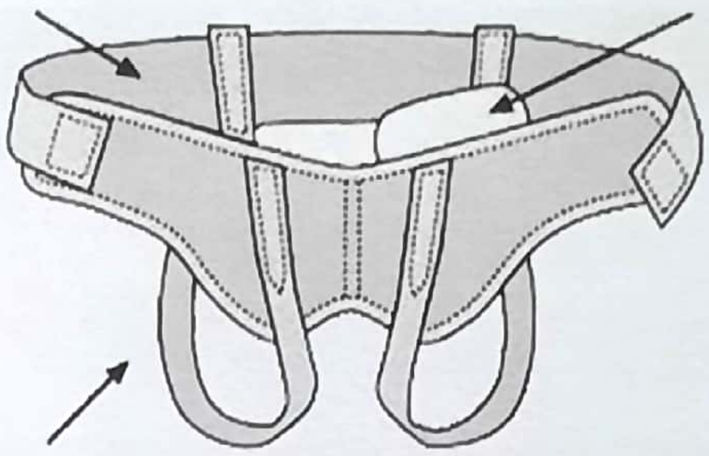

Figure 42.13: Hernia truss (belt)

Differential diagnosis

In Male

- A vaginal hydrocele
- An encysted hydrocele of the cord
- Spermatocele
- Femoral hernia
- Lipoma of cord
- An incompletely descended testis.
- Tumour of spermatic cord
- Varicocele
- Epididymoorchitis

In Female

- A hydrocele of canal of nuck
- A femoral hernia.

KEY BOX 42.9

Differentiating Features Between Indirect and Direct Inguinal Hernia

Indirect inguinal hernia	Direct inguinal hernia
1. It *can* occur at any age, but is more common in young adults and children.	1. Elderly patients are usually affected.
2. Males are affected 25 times more than females.	2. Females are not affected by direct hernia.
3. In 2/3rd of cases it is unilateral and in 1/3 it is bilateral.	3. More than 50% of cases are bilateral.
4. The shape of hernia is pyriform or oval.	4. Shape of hernia is spherical.
5. An indirect hernia may descend in scrotum (ie; may become complete).	5. A direct hernia is almost always incomplete. (does not descent to bottom of scrotum).
6. This hernia has to be reduced by the patients or the doctor and it does not reduce by itself.	6. They automatically reduce when the patient lies down.
7. **Ring occlusion test-** In this test the hernia is reduced "first. And deep ring is occluded by pressing 1.25cm above the mid inguinal point, now the patient is asked to cough. An indirect hernia will not come out, because the deep ring is occluded- hence no bulge can be left in inguinal region.	7. A patient with direct hernia will show a bulge medial to occluding finger, because these hernia comes directly from the posterior wall, medial to deep ring.
8. **Examination- Impulse an coughing-** Surgeon puts his index finger over the deep inguinal ring 1.25 cm above the mid inguinal point (AIIMS 81, PGI 83) and the middle finger over superficial inguinal ring (just above an lateral to pubic tubercle). The patient is asked to cough or do Valsalva's maneuver. If a bulge is felt on the index finger- it is an indirect hernia.	8. If a bulge is felt on the middle finger it is a direct hernia.

KEY BOX 42.8E2

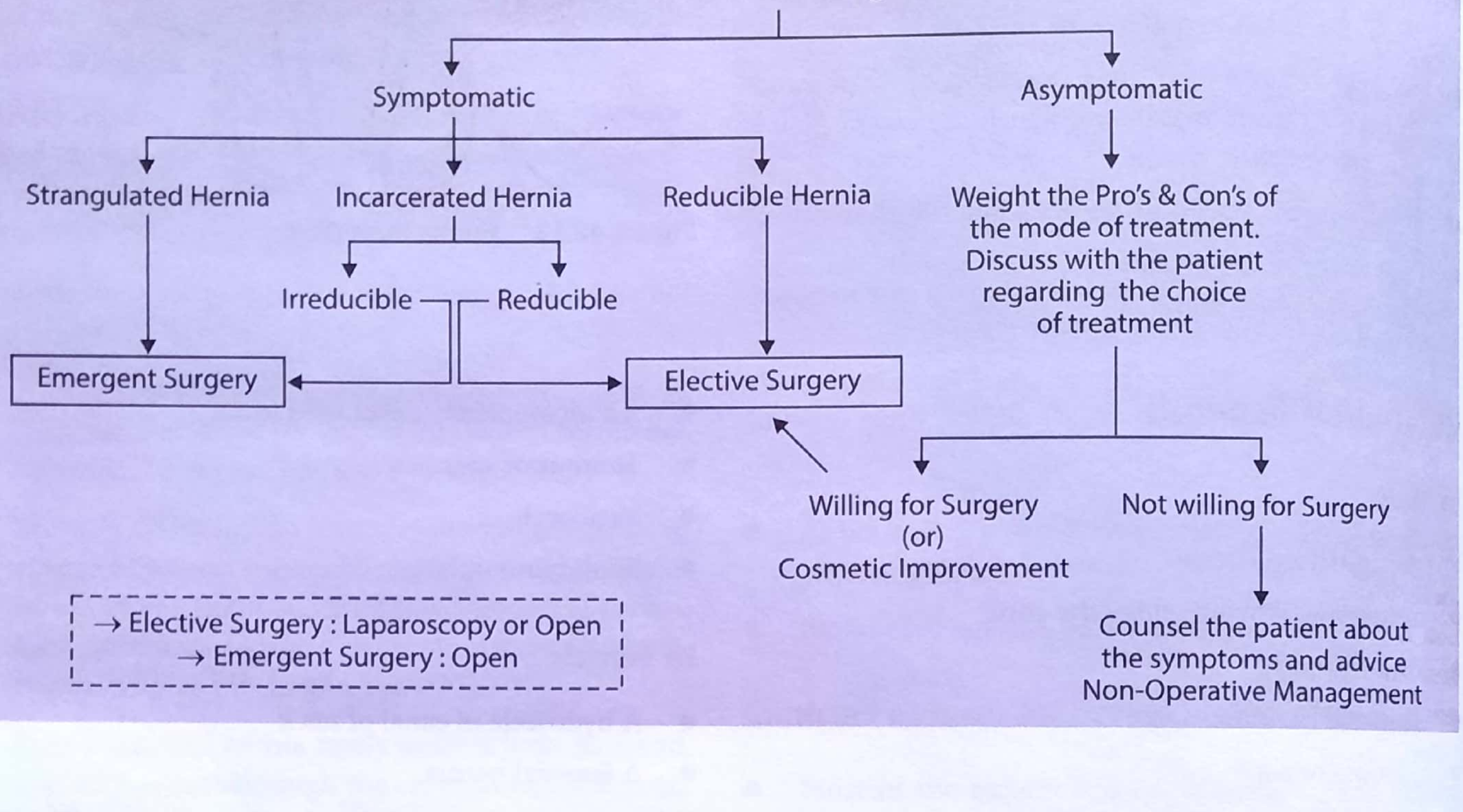

Treatment (of hernia)

Operation is the only treatment for a case of inguinal hernia.

Please read key boxy 42.8E2 above and 42.8E3 below.

1. Hernia truss (Hernia belt)

In infants, the use of a truss can cure the hernia, and this is especially true for an umbilical hernia. In case of an inguinal hernia, the truss is only indicated for patient not

KEY BOX 42.8E3

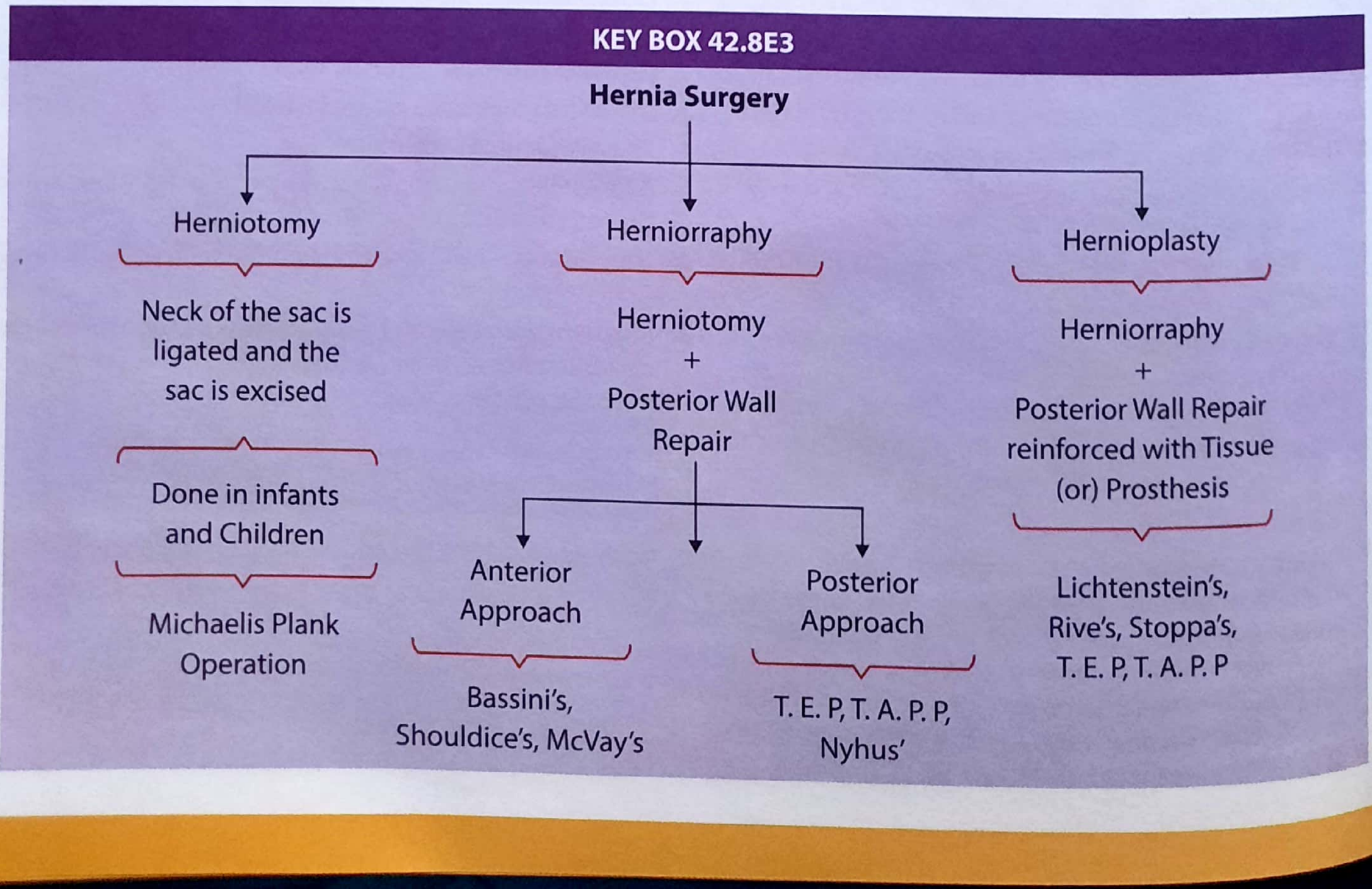

fit for surgery or anesthesia. A truss is used to prevent hernia to come out of superficial inguinal ring. (Figure 42.13)

Also know: Bassini is said to be father of modern hernia surgery

2. Surgical Procedure

(a) Herniotomy (PGME)

Herniotomy is simple excision of the hernial sac after reducing the contents of hernial sac. This procedure is enough for infants and children, where the hernia is due to congenital defect in the peritoneal cavity (processus vaginalis) and the muscles are not weak. (Friends! when we use term reduction or reducing hernia, it means:- pushing back the contents present in hernial sac into abdominal cavity.)

(b) Herniorrhaphy

This is excision of the sac, with repair of the defect in the musculature. In case of a inguinal hernia, the repair (strengthening) of inguinal canal floor is done by joining (approximating) the inguinal ligament (below) to the conjoint tendon (above) by using non- absorbable suture like proline, besides excision of sac {herniotomy}.

(c) Hernioplasty

This includes excision of sac, *with repair of the posterior wall defect of inguinal canal, by filling the gap between conjoint tendon (above) and inguinal ligament (below) by either autogenous material* (eg; a strip of fascia lata or external oblique aponeurosis, split skin graft etc) or by *heterogenous materials like proline mesh, marlex mesh** (see figure 42.14).

NOTE: Filling of this defect is important as to reduce future recurrence of hernia because in most of cases with hernia, posterior wall of inguinal canal is weak, which may increase chances of recurrent inguinal hernia.

Most common nerve damaged during hernia repair is ilioinguinal nerve.

(d) APP repair

Now a days many surgeons are doing inguinal hernia repair by this procedure. APP means:- Anterior- Pre Peritoneal. In this procedure anterior preperitoneal space is identified and is reinforced, using a mesh* prosthesis, after reducing the sac.



Figure 42.14: Mesh

(e) Laparoscopic hernia repair

Now a days hernias are repaired laparoscopically. Two procedures are more popular

TEP - Total Extra Peritoneal approach

TAPP - Trans Abdominal Pre Peritoneal approach. Of these two TEP has become more popular.

Stoppa's hernia repair uses pascal law. It is tension free reapir. (NEET) It is performed by wrapping the lower part of the perital peritoneum with prosthetic mesh and placing it at a preperitoneal level over fruchaud's myopectineal orifice.

MESH? It is a net, made of proline (can be compared to a mosquito net for understanding). The size of mesh can be 6" x 6" or 6" x 4". It is kept over the wakened posterior wall of inguinal to prevent protrusion (herniation) of the abdominal content; thus reducing recurrence of hernia. See figure # 42.14.

Best mesh is lightweight mesh with large pores. (AIIMS JUNE 20)

Some Important Concepts in Laparoscopic/Endoscopic Hernia Surgery (MAY BE FUTURE PGME Q)

1. Triangle of doom (INICET NOV 20)

Boundaries	**Medially**	**Vas deferens**
	Laterally	Gonadal vessels
	Apex	Deep inguinal ring
	Base	Peritoneal reflection

- External iliac artery and vessels pass through it. *Clinical significance* of this triangle is because; no dissection is carried out during lap. hernia surgery in this region; as it may cause injury to iliac vessels.

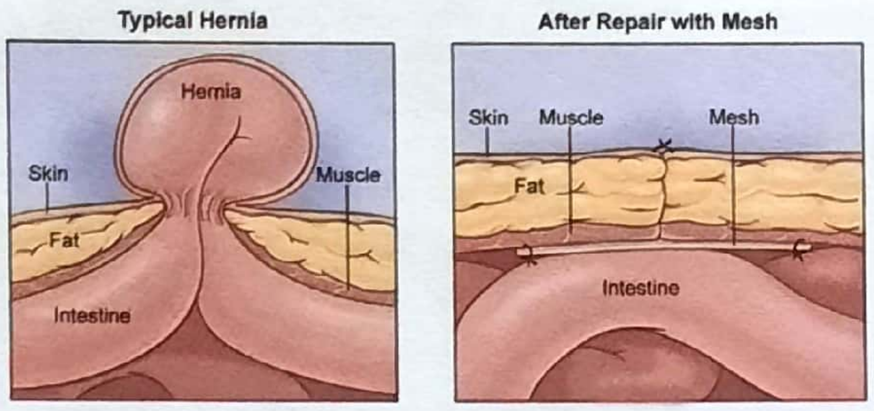

Figure 42.15: Figure showing placement of mesh

- Genital branch of genitofemonal nerve also lies in this area.

2. Triangle of pain: Boundaries

Medially	Gonadal Vessels
Laterally	Iliopubic Tract
Base	Inferior edge of skin incision
Contents:	Femoral br. of Genitofermoral nerve
	Lateral cutaneous nerve of thigh
	Anterior femoral cutaneous nerve

Stapling/Tacker insertion in this area can cause nerve entrapment causing neuralgic pain in lateral side of thigh. (**M/C Lateral cutaneous nerve of thigh**). *(PGME)*

3. Corona Mortis (Circle of death)

Lies medial to triangle of doom. (Figure 42.16)

An arterial arcade formation sometimes encountered in surgery for inguinal hernias, with an aberrant branch of the obturator artery arising from the inferior epigastric or external iliac artery, crossing the pectineal ligament, and anastomosing with the obturator artery; this vessel can encircle the neck of a hernial sac and become damaged during surgery, causing torrential hemorrhage.

4. Myopectineal orifice *(INICET NOV 20)*

Medially - lateral border of rectus sheath

Above - by 10 & TA (Internal oblique and transversus abdominis)

Lateral - by iliopsoas, below - pectin pubis & fascia

Please see figure 42.16 and 42.8B.

Complications of groin hernia repairs

Open hernia repair

Chronic groin pain

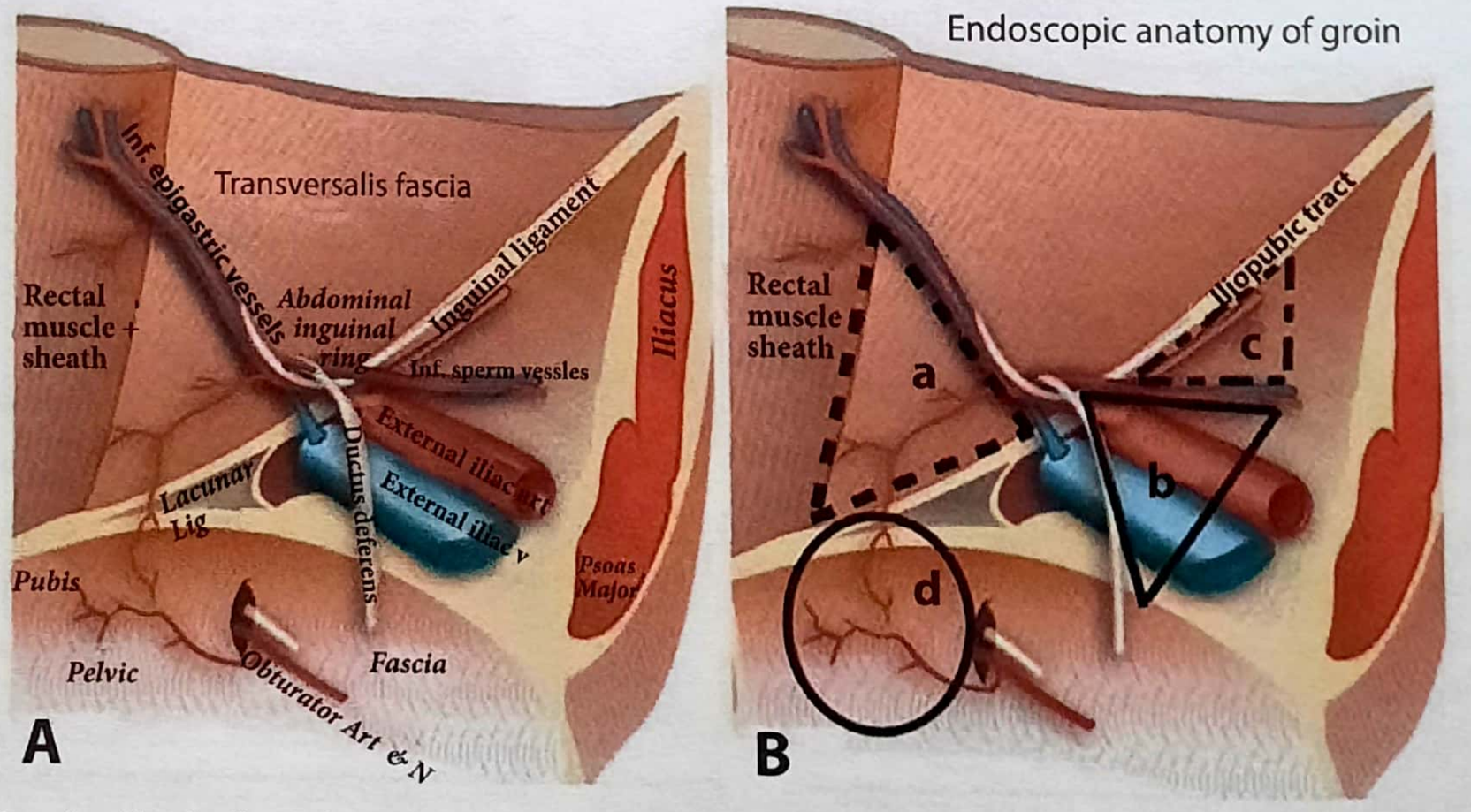

Figure 42.16: **A -** Illustration of surgically relevant structures around the internal inguinal ring. **B -** Outlines of Has selbach's triangle **(a)** and the triangle of doom **(b)** and pain **(c)** The latter two triangles constitute the trapezoid of disaster (square of doom). The circle of death **(d)** is also demonstrated. Imagges adapted from Laparascopic Hernia Repair : A step by step approach

- **Nociceptive**
  - Somatic
  - Visceral
- **Neuropathic**
  - Iliohypogastric
  - Ilioinguinal
  - Genitofemoral
  - Lateral cutaneous
  - Femoral

Cord and testicular

- Hematoma
- Ischemic orchitis
- Testicular atrophy
- Dysejaculation
- Division of vas deferens
- Hydrocele
- Testicular descent

Bladder injury

Wound infection

Seroma

Hematoma

- Wound
- Scrotal
- Retroperitoneal

Osteitis pubis

Prosthetic complications

- Contraction
- Erosion
- Infection
- Rejection
- Fracture

Complication of Laparoscopic hernia repairs

- **Vascular injury**
  - Intra-abdominal
  - Retroperitoneal
  - Abdominal wall
  - Gas embolism

KEY BOX 42.8E1

Differential diagnosis of groin hernia

- Malignancy
  - Lymphoma
  - Retroperitoneal sarcoma
  - Metastasis
  - Testicular tumor
- Primary testicular
  - Yaricocele
  - Epididymitis
  - Testicular torsion
  - Hydrocele
  - Ectopic testicle
  - Undescended testicle
- Femoral artery aneurysm or pseudoaneurysm
- Lymph node
- Sebaceous cyst
- Hidradenitis
- Cyst of the canal of Nuck (female)
- Saphenous varix
- Psoas abscess
- Hematoma
- Ascites

- **Visceral injury**
  - Bowel perforation
  - Bladder perforation
- **Trocar site complication**
  - Hematoma
  - Hernia
  - Wound infection
  - Keloid
- **Bowel obstruction**
  - Trocar or peritoneal closure site hernia
  - Adhesion
- **Miscellaneous**
  - Diaphragmatic dysfunction
  - Hypercapnia

General

- Urinary

- Paralytic ileus
- Nausea and vomiting
- Aspiration pneumonia
- Cardiovascular and respiratory insufficiency

*****

OBSTRUCTED AND STRANGULATED INGUINAL HERNIA

A reducible inguinal hernia may become irreducible or obstructed or; when blood supply of herniated structures get interrupted; and then it is called as strangulated hernia. *The constriction mostly occurs at the neck of the sac, but could occur any where.* (PGME)

The constricting band first interferes with the venous return, leading to congestion of the contents. Subsequently, the arterial supply is also occluded; results in the gangrene of the obstructed segment of intestinal loop or omentum (what ever present in the sac) and subsequent perforation of the intestinal loop (if it is content of sac). Intestinal perforation; result in migration of bacteria and fluid in the sac.

Clinical feature

1. Patient will almost always give history of a reducible hernia in past, which has now suddenly become irreducible.
2. In strangulated hernia pain is intense.
3. In obstructed hernia, there will be feature of intestinal obstruction, viz; colicy abdominal pain, absolute constipation and vomiting.
4. The patient has sings of dehydration; weak pulse, tachycardia, low blood pressure and dry coated tongue.

Treatment

Steps

- Immediate operation (KERLA 94) is essential to save the life of the patient.
- Fluid and electrolyte imbalance should be corrected.
- The basic treatment is same as with hernia repair.
- Once the sac is opened after making an *incision on fundus of the sac,* fluid in the sac is sucked out, (AIIMS NOV 96, AIIMS JUNE 04). The intestinal loops are wrapped by warm normal saline soaked sponges and repeatedly examined.
- Patient is given 100% oxygen.
- The changes in the colour of the intestinal loops are noticed and the peristaltic movement of gut is observed.

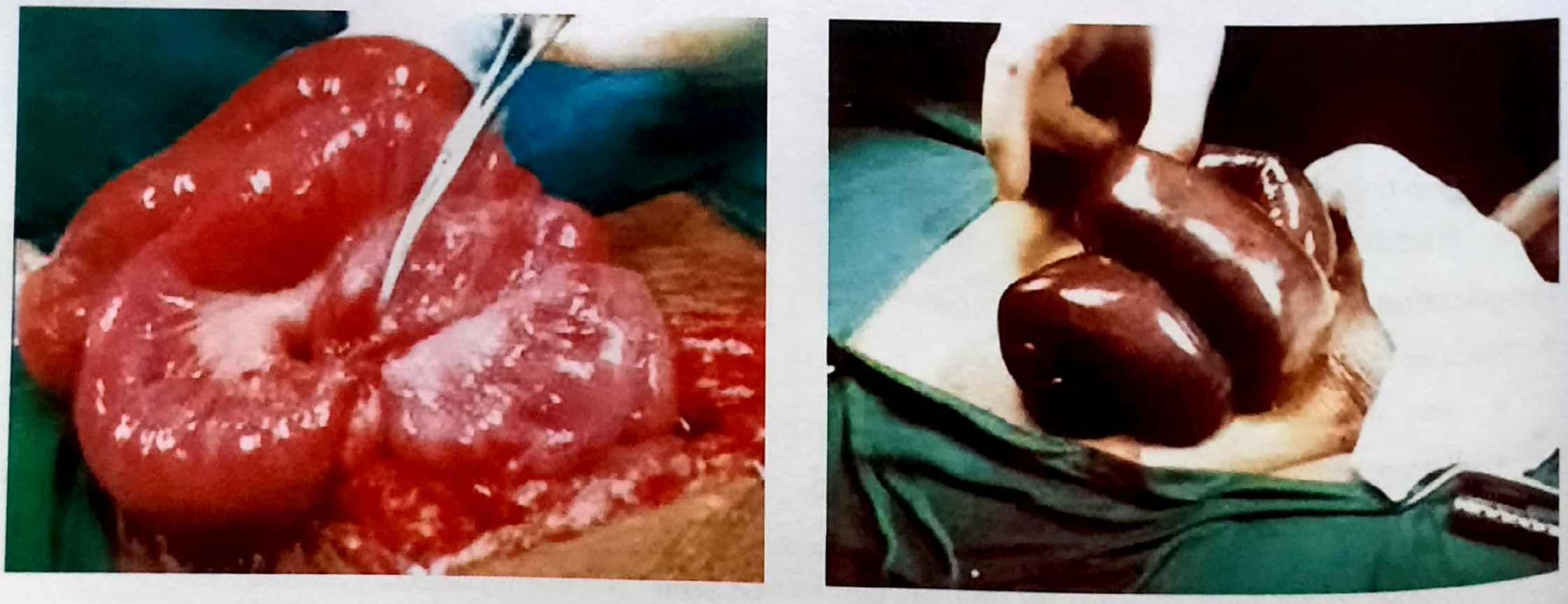

Figure 42.17: (a) A Viable shiny bowel (B) Non viable dull, dark bowel

KEY BOX 42.10		
Differentiation of healthy (viable) and strangulated (non-viable) bowel at laparotomy		
Intestine	**Viable**	**Non-viable**
• Apperance of bowel at laparotomy	Colour is lighter and pinkish	Dark brown in colour (figure 42.17)
• Mesentery	Bleeds if pricked	Does not bleed if pricked
• Peritoneum	Shiny	Dull or lusterless
• Intestinal musculature	Firm, peristalsis may be observed	Flabby, thin and friable, no peristalsis.

Figure 42.18: Sliding hernia: posterior wall of the sac is not formed by the peritoneum, *but by the organ wall (on left side by sigmoid colon, on right side cecum & appendix)*

Two situations will be encountered:-

1. If the gut is pink and pulsation in blood vessels in the mesentery is present and peristaltic movement appear on tapping the bowel - it means that the intestine (content) is viable and should be returned to abdominal cavity; and rest of the operative procedure should be performed as in herniotomy or herniorrhaphy.
2. If the gut has turned dark or violet in colour or is perforated, pulsation in the mesenteric vessel is absent, and does not show any peristaltic movement on tapping or does not show any change in colour even after 10 minutes; then the gut should be considered as gangrenous and non-viable and that part should be resected and end to-end anastomosis should be done between viable segment of bowel. After completing anastomosis bowel is returned back to the abdominal cavity and rest of the procedure of hernia repair is completed.

*****

RARE VARIETIES OF INGUINAL HERNIA

1. Sliding hernia (syn: Hernia-en-glissade)

- This is a hernia in which a portion of **extraperitoneal bowel** slides down into inguinal canal, pulling a sac of peritoneum with itself. The extraperitoneal organ may be:

  On the Left side (more common) Sigmoid colon *(PGI JUNE 96 AI 95)* and

  On the Right side Cecum and appendix *(NEET)*. Urinary bladder may be present on either site.

- Sliding hernias are very large globular hernias descending well into scrotum.
- Left sided sliding hernias are more common than right side. The ratio of left to right is 5:1. *(PGME)*
- The *peculiarity of this type of hernia, is that the posterior wall of the sac is not formed by the peritoneum,* but by the organ wall *(PGI DEC 99)* which lies behind it. viz; cecum on the right side and pelvic colon (sigmoid colon) on left side or urinary bladder on either side.
- It should be clearly understood; that if cecum or sigmoid colon is *wholly* with in the hernial sac, it does not constitute a sliding hernia.
- A sliding hernia occurs almost exclusively in male and are more common on left side. *(PGI JUNE 96, AI 95)*. Most common content being sigmoid colon. *(PGME)*
- Bilateral sliding hernias are rare.
- Patient is always over 40 years of age; and the incidence rise with the age.

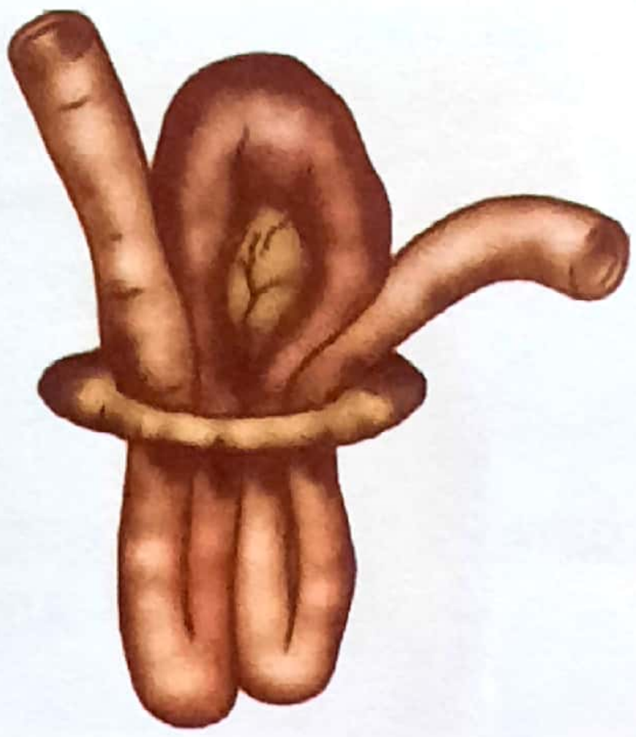

Figure 42.19: Maydl's hernia (Hernia in W)

2. Interstitial hernia

In this hernia, the hernial sac lies between the muscle layer of the abdominal wall.

3. Richter's Hernia (UPSC 05, 07)

When content of hernial sac is circumference of bowel loop, it is called as Richter's hernia. Patient often present with clinical features simulating acute gastroenteritis (IMP. POINT). Please see 42-6 C, page 764.

In this, stangulation without obstruction is seen.

4. Littre's hernia

In this condition **meckel's diverticulum** (NEET) is content of the hernial sac.

5. Ogilvie's Hernia

Very rarely a hernial sac may appear through a *circular congenital defect in conjoint tendon called as ogilvie hernia.*

6. Maydl's Hernia (Hernia-En-W) Or Retrograde Strangulation

In this hernia two loops of bowel remain in the sac and connecting loop remains with in abdomen and may become strangulated. The two loop in hernia sac look like a 'W shape. Please see figure 42.19 & 42.6 D.

NOTE: That in this the loop in of intestine present in abdominal cavity is strangulated first and not that in the sac. (PGME)

7. Pantaloon hernia

Also called dual hernia, saddle bag hernia.

*****

FEMORAL HERNIA

- Femoral hernia is the third most common type of primary extra-abdominal hernia (other two being inguinal hernia, and umbilical hernia respectively).
- *Femoral hernias are more common in female than male* (PGI JUNE 03). It accounts for about 20% of hernias in women and 5% ill men.
- [Do not get confused **most common type of hernia even is female is indirect inguinal hernia** (NEET, AIIMS 97)}.
- The most serious complication with a femoral hernia is that, **of all hernias it is the most liable to get strangulated,** (NEET, PGI DEC 95, PGI DEC 03) mainly because of *narrowness of the neck of the sac* and rigidity of femoral ring.
- Strangulation is the first presentation in femoral hernia in as much as 40% patients. (IMP. POINT)

Surgical Anatomy

Femoral Canal

Femoral canal is the most medial compartment of the femoral sheath. This *canal is conical in shape,* being wide

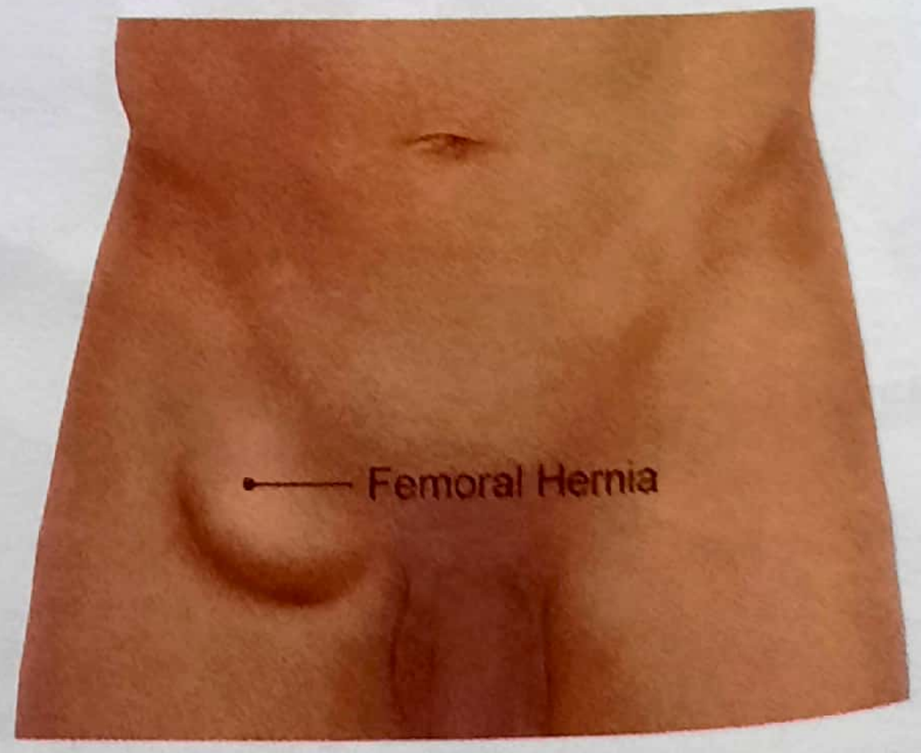

Figure 42.20: Site of femoral hernia

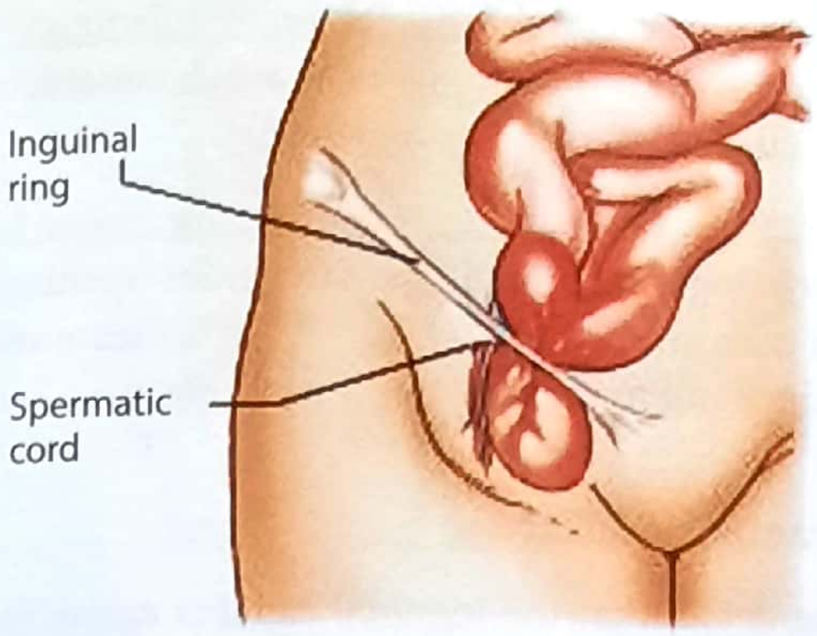

Figure 42.21: Coils of intestine in sac of femoral hernia

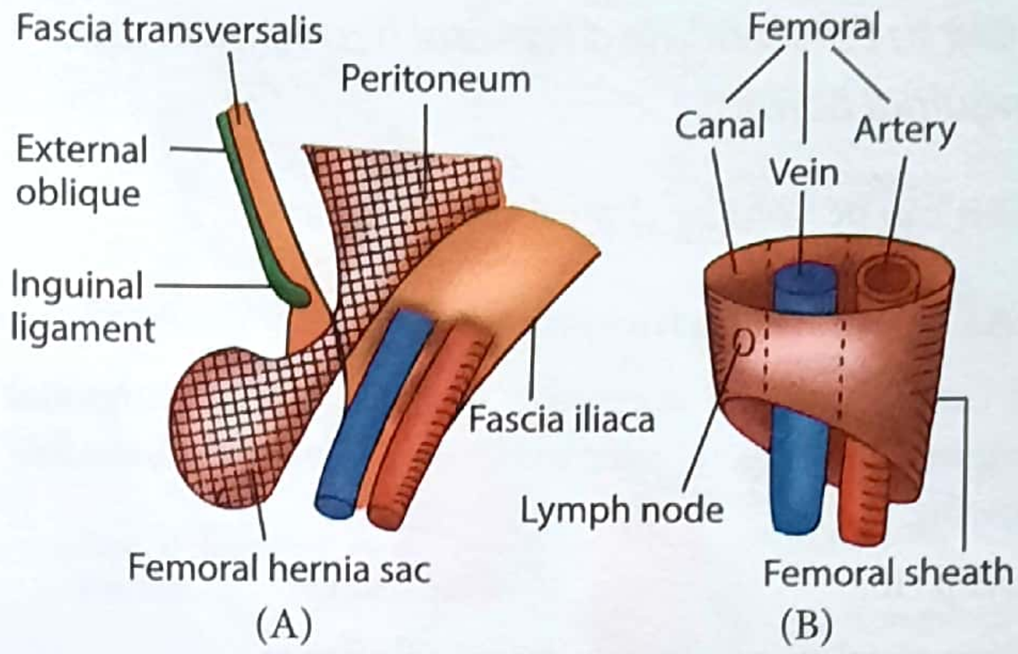

Figure 42.23: Anatomy of femoral canal (B) & Hernia (A)

above (base) and narrow below. It is about 1.5 cm long and about 1.5cm wide at the base. *(AIIMS 81, UPSC 87)*.

- The base or upper end of femoral canal is called the femoral ring.
- In femoral hernia the abdominal content pass through the femoral ring, traverses the femoral canal and comes out through the saphenous opening. The **boundaries** of the femoral ring is important. (Figure 42.23)

Anteriorly: by Inguinal ligament

Posteriorly: Cooper's ligament (iliopectineal ligament) pectineus muscle and its fascia.

Medially: Concave edge of lacunar (Gimbernat's ligament)

Laterally: thin septum separating it from femoral vein.

Clinical feature

- The female to male ratio is about 2:1 and patient is usually an elderly multipara female between 60-80 years.
- Patients present with swelling in the groin, which increase in size on coughing, standing or straining.
- Femoral hernias are more common on right side; and in 20% cases; the condition is bilateral.
- Dull aching pain or discomfort over the swelling is often present. The pain is worse or becomes more severe once the hernia gets obstructed or strangulated.
- The swelling lies below the inguinal ligament and lateral to pubic tubercle. Fig. 42.23 & 42.24.

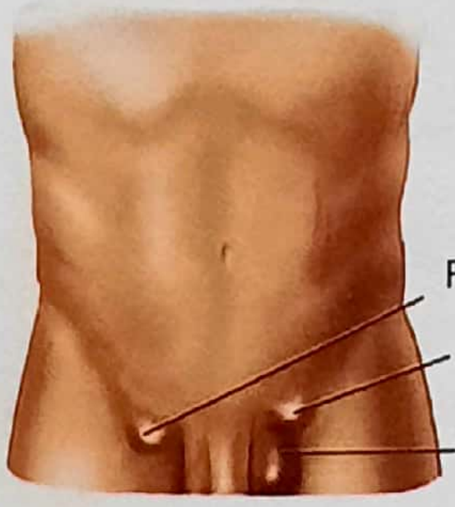

Figure 42.22: Site of groin hernia; note the neck of protrusion of hernia lies above and medial to pubic tubercle in inguinal hernia where as in femoral hernia neck of protrusion lies below and lateral to pubic tubercle.

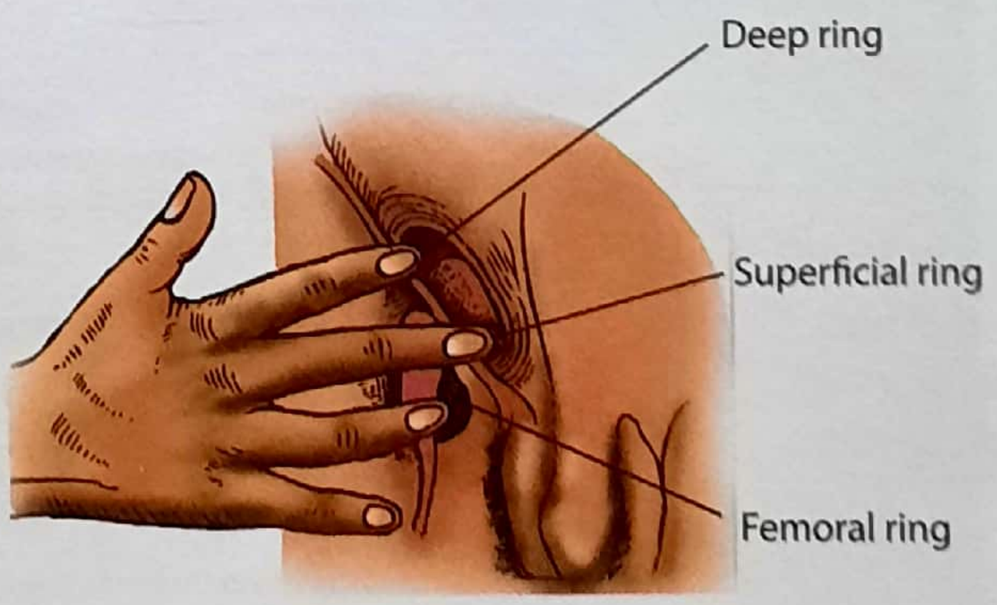

Figure 42.24: Zeiman's technique

How to differentiate a femoral hernia from an inguinal hernia:

This can be done by clinical examination

(A) Zieman's technique

It can be done by occluding 3 rings present in inguinal region by 3 fingers, after reducing the hernia, in the following way:-

Deep ring	-	by Index finger
Superficial ring	-	by middle finger
Femoral ring	-	by ring finger

Now patient is asked to cough. On coughing 3 situations are encountered:

1. If impulse on coughing is felt on **Index finger** that means hernia is coming out through deep ring - this is the case in **Indirect inguinal hernia**.
2. If impulse on coughing is felt on middle finger - this means hernia is coming out through superficial inguinal ring - direct inguinal hernia.
3. If impulse of coughing is felt on ring Finger hernia is coming out through the saphenous opening; this is a case in femoral hernia, (IMP. POINT). Please see and understand figure 42.24 very carefully.

B. Invagination test

One can detect that the inguinal canal is empty in case of femoral hernia, as they come but (herniate) through femoral canal, (see fig 42.25 next page)

C. Position of hernia (AIIMS 98, PGI 03, TN 89)

This is the most important point. *The neck of the hernial sac in femoral hernia lies* ***below the inguinal ligament and lateral to pubic tubercle,*** (NEET) where as an inguinal

FOURTY TWO

○ **Ring Occlusion Test :**

Swelling is reduced and then the **Thumb** is pressed upon Deep Inguinal Ring and patient is asked to cough

- Bulge Medial to Thumb → Direct Inguinal Hernia
- If Femoral Canal Occluded & No Bulge → Femoral Hernia
- No Bulge → Indirect Inguinal Hernia

○ **Three Finger Test (Zieman's Technique) :**

- **Index Finger -** Deep Inguinal Ring (1/2 Inch above Mid Inguinal Point) → Indirect Inguinal Hernia
- **Ring Finger -** Saphenous Opening (4 cm lateral and below Pubic Tubercle) → Femoral Hernia
- **Middle Finger -** Superficial Inguinal Ring (1 cm above Pubic Tubercle) → Direct Inguinal Hernia

○ **Finger Invagination Test :**

The **Little finger** is pushed and rotated through the Superficial Inguinal Ring gently

- Finger Directed Backward
- Cough impulse felt on Pulp of Finger

→ Direct Inguinal Hernia

- Finger Directed Upward, Laterally and Backward
- Cough impulse felt at the Tip of Finger

→ Indirect Inguinal Hernia

Figure 42.25: Fingure invagination test (read text)

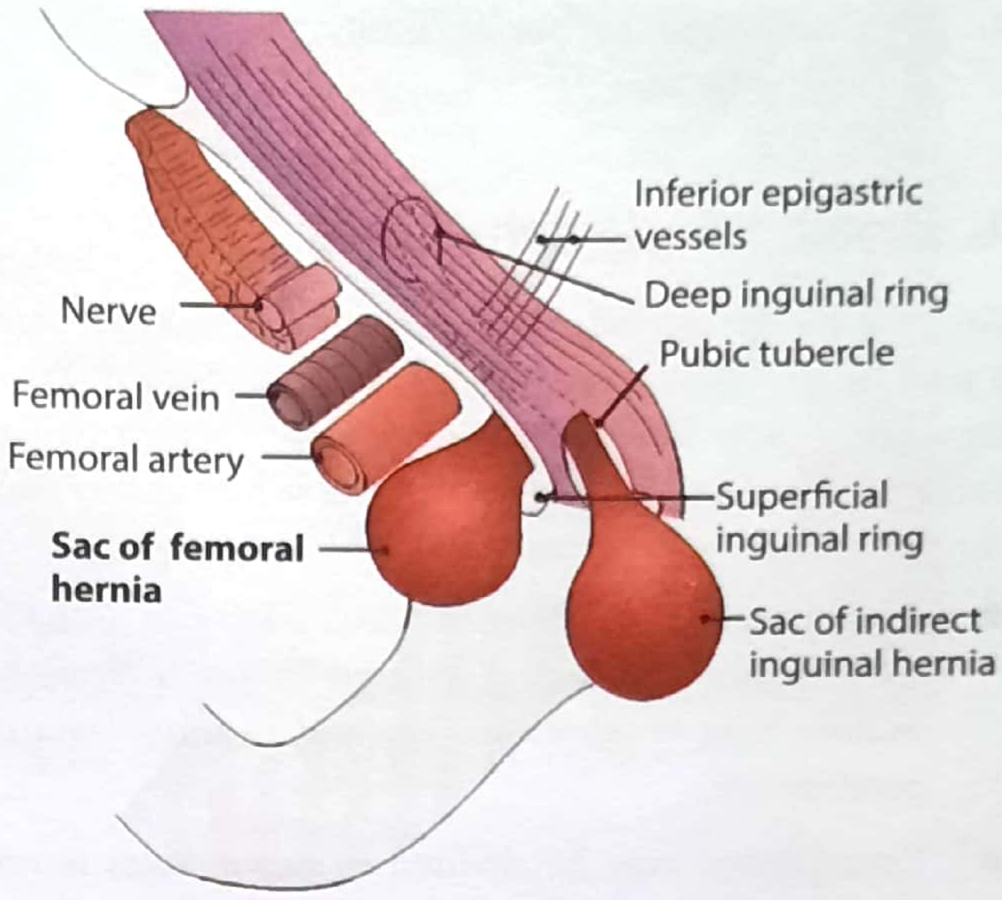

Figure 42.26: Note the position of sac in inguinal and femoral hernia with respect to pubic tubercle

hernia is always above the inguinal ligament and medial to pubic tubercle. *(MANY PGME)* [Figure 42.26 & 42.22]

Please see box an previous page.

Treatment (of femoral hernia)

There is high risk of strangulation in case of a femoral hernia and operative treatment should be carried out soon the diagnosis has been made. Several procedures for femoral hernia repair has been advocated, these are [LML]

- Low-Operation = Lockwood *(PGME)*
- High-Operation = Me Evedy
- Inguinal-Operation = Lotheissen

(Friends! only remember the names and don't go into details.)

Differential Diagnosis *(of Femoral Hernia)*

Femoral hernia has to be distinguished from the following:-

1. Inguinal hernia
2. Saphena varix - it is a *saccular dilatation* of the termination of the long saphenous vein.
3. An enlarged femoral lymph node.
4. Lipoma
5. A femoral artery aneurysm
6. Psoas abscess

Some Rare Type of Femoral Hernia

Narath's hernia

This type of hernia occurs in patients with congenital dislocation of the hip due to lateral displacement of the psoas muscle.

Laugier's Hernia

Hernia through a gap in the lacunar (Gimbernat's) ligament.

Cloquet's hernia

In this case hernia passes behind the femoral vessels, between the pectineus muscle and its fascia.

*****

UMBILICAL HERNIA

Umbilical hernias are second most common cause of external abdominal hernia (most common being inguinal hernia). **Three types of umbilical hernia are seen in surgical practice** - namely:-

1. Exomphalos (omphalocele)
2. **Umbilical hernia of infants and children** *(NEET)*

3. Para umbilical hernia of adult. **Now lets discuss them one by one**

1. Exomphalos (omphalocele)

An exomphalos is a variety of *congenital hernia* in which, a **part of mid gut fails to return to the abdominal cavity during early fetal life due to normal developmental failure.** (NEET) The basic defect is in the failure of fusion of the anterior abdominal wall (KERELA 91).

- Abdominal organs remains protruded out side the abdominal cavity, **being covered by a membrane,** a middle layer of wharton's jelly and an inner layer of peritoneum.
- Exomphalos may be divided in *exomphalos minor* and *exomphalos major* depending upon the size of defect of anterior abdominal wall.
- Generally; **if the defect is less than 4 cm it is called as exomphalos minor and if the defect is more than 4 cm it is called as exomphalos major.**

Now lets discuss them one by one:

(a) Exomphalos minor

- In this; the defect in anterior abdominal wall is small (less than 4cm).
- Only a loop of the small intestine comes out through the defect. Umbilical cord is attached ***at the tip*** of the sac in examphalos minor.

Treatment

Treatment of exomphalos minor is non-operative. It consist of twisting the cord, reducing the contents into peritoneal cavity and strapping the wound firmly for two weeks.

(b) Exomphalos major

- In this; the defect in the anterior abdominal wall is large (more than 4 cm).
- The sac may consist of small intestine, large intestine, liver, spleen, pancreas and urinary bladder. The intestine lies freely mobile within the sac without any evidence of adhesion.
- The umbilical cord is attached *at the lower end* of sac. (Figure 42.27). If left untreated, the membrane dries and sloughs off leading to rupture.
- Neonate dies of peritonitis and sepsis, due to rupture of intestine, resulting in peritonitis.

Figure 42.27: Baby with exomphalos major

Treatment

Exomphalos major is a life threatening situation and requires **immediate surgery** (NEET). The treatment options include [**SSP**]

(a) Skin flap closure

(b) Staged closure

(c) Primary closure

2. Umbilical Hernia of Infant and Children

- This is a hernia through a weak umbilicus and is due to a defect in development of abdominal muscle.
- The hernia is often symptomless; but increases in size on crying and assumes a classical conical shape. Please' see figure 42.28.

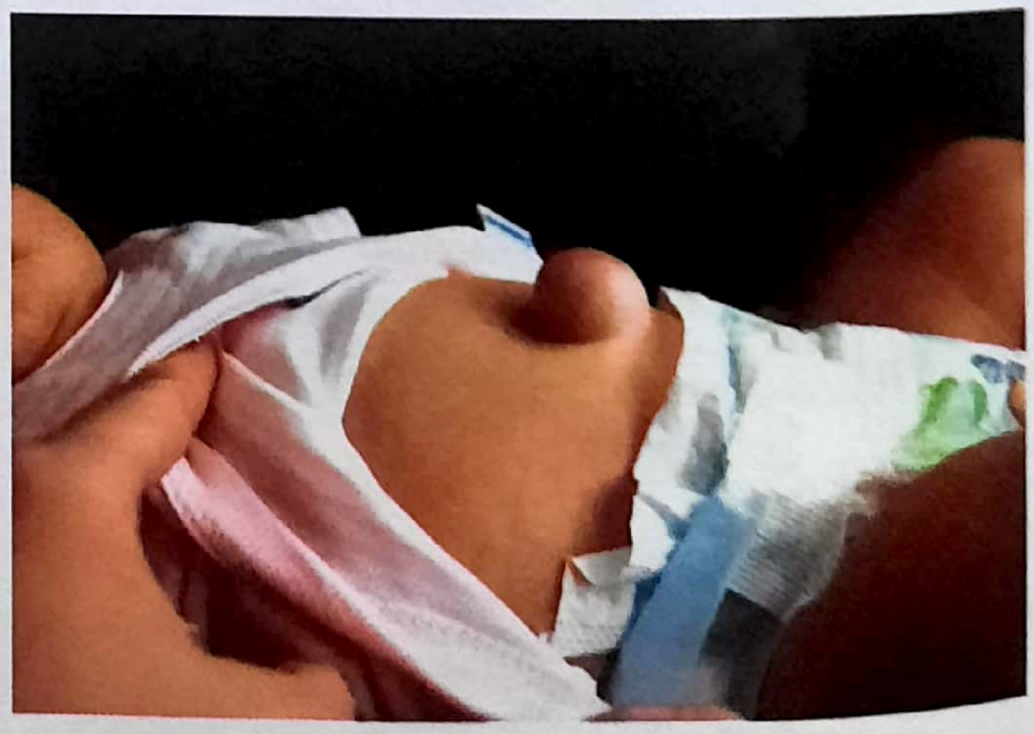

Figure 42.28: Umbilical hernia in an infant

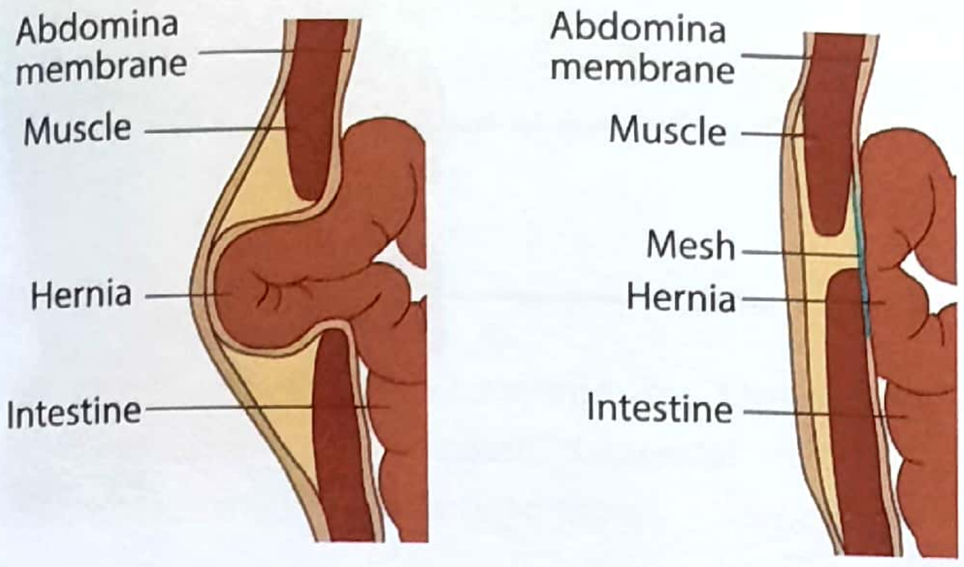

Figure 42.29: Umbilical hernia and its mesh repair

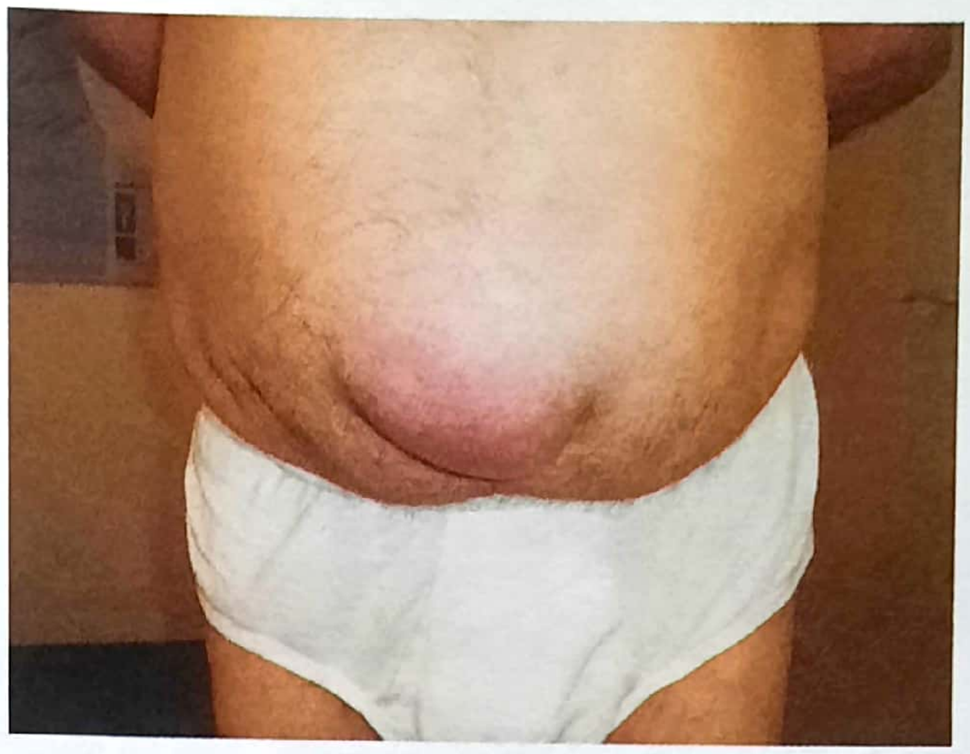

Figure 42.30: Para-umbilical hernia

- Strangulation in this hernia is extremely rare; because the neck is wide.

Treatment

- **No treatment is required in about 95% cases with umbilical hernia** *(NEET, MANY PGME)*, reassurance to the parents is all that is required .
- Most of them are spontaneously cured (closed) by the age of 12-18 months. *(UP 08)*
- To hasten the disappearance of hernia, 3-4 coins (50 paise ke sikee) covered by cotton is placed over the hernia and is strapped with leucoplast. This strapping is maintained for three weeks.
- If the hernia does not disappear by itself at 2 years of age or older- then herniorrhaphy is indicated. *(MAHE 07)*
- Surgery for umbilical hernia done at Surgery of age.

3. Para-Umbilical Hernia of Adults

- In adults the hernia can not protrude through the firm umbilicus. In para-umbilical hernia, there occurs protrusion through the linea alba just above the umbilicus (supra umbilical; Fig 42.30). *(MANY PGME)*
- Because these are in close relation to umbilicus, they are called as para-umbilical hernia.
- The *contents of the hernia are usually greater omentum, often with a loop of small intestine or transverse colon.* *(IMP. POINT; MAY BE FUTURE PGME Q)*
- Sac of a para-umbilical hernia is loculated.
- Most of the paraumbilical hernias *are irreducible* due to adherence of omentum to fundus of the sac.

Clinical feature

- These hernias usually occur in fatty women between 40-50 years of age. Female to male ratio being 5:1.
- A bulge most commonly in supra-umbilical region and less commonly in infra-umbilical region is felt.
- **On palpation the consistency of lump is firm and it contains most commonly omentum.** *(PGME)*
- Usually the contents within the sac are adherent to the fundus; making hernia *irreducible and impulse on coughing absent* *(IMP POINT)*
- Strangulation is a frequent complication with a large para-umbilical hernia. *(IMP. POINT)*

Treatment

1. **Herniorrhaphy - Mayo's operation** *(PGI 97, AI, UP 87)*
2. Para umbilical hernioplasty.

*****

EPIGASTRIC HERNIA (SYN: FATTY HERNIA OF THE LINEA ALBA)

- When a hernia protrudes in the midline through the inter lacing (crossing over) fibres of the linea alba, between umbilicus and xiphisternum (most often in epigastric region), it is called as epigastric hernia.

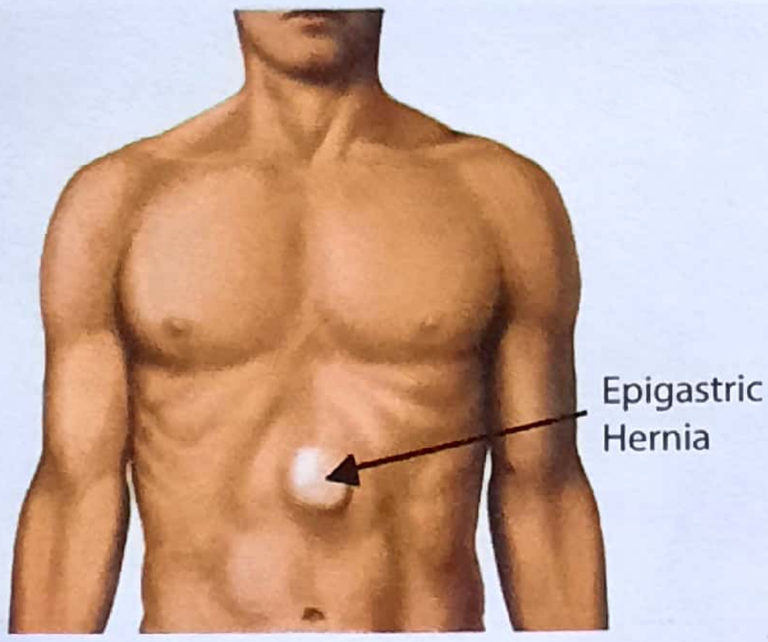

Figure 42.31: Site of Epigastric hernia

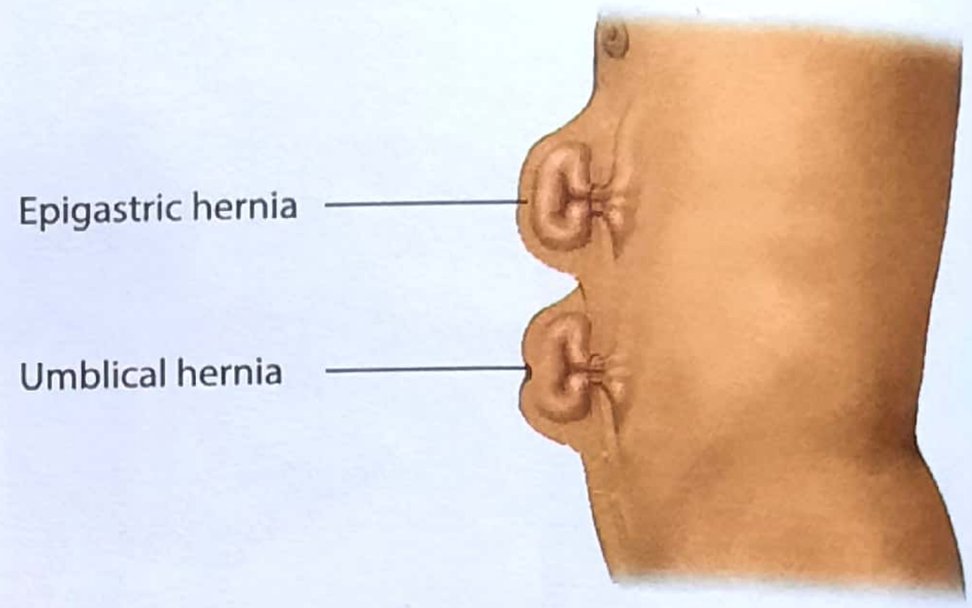

Figure 42.32: Epigastric & umbilical hernia (lateral view)

- Such type of hernia begins as a protrusion f extra peritoneal fat *(MANY PGME)* that is why they are also called as "fatty hernia of the linea alba"-at this stage it is not a true hernia, because there is no true sac.
- As the hernia grows larger, it pull a pouch of peritoneum (sac) and becomes a true (epigastric) hernia.
- The *mouth of the hernial sac is very narrow* and it does not allow any viscus to enter the hernial sac. Only rarely a-small portion of greater omentum may enter it.

NOTE: Please see fig. 33.16 on page 588 to understand pre-peritoneal (extraperitoneal) fat and space.

Clinical feature

1. Symptomless

Most of the epigastric hernias are asymptomatic; *(PGME)* some patient may notice a small pea size swelling in epigastric region. Please see figure 42.31 and 42.32.

2. Pain

Some times pain may be felt in the region of hernia due to strangulation of preperitoneal fat, between margins of the gap in linea alba.

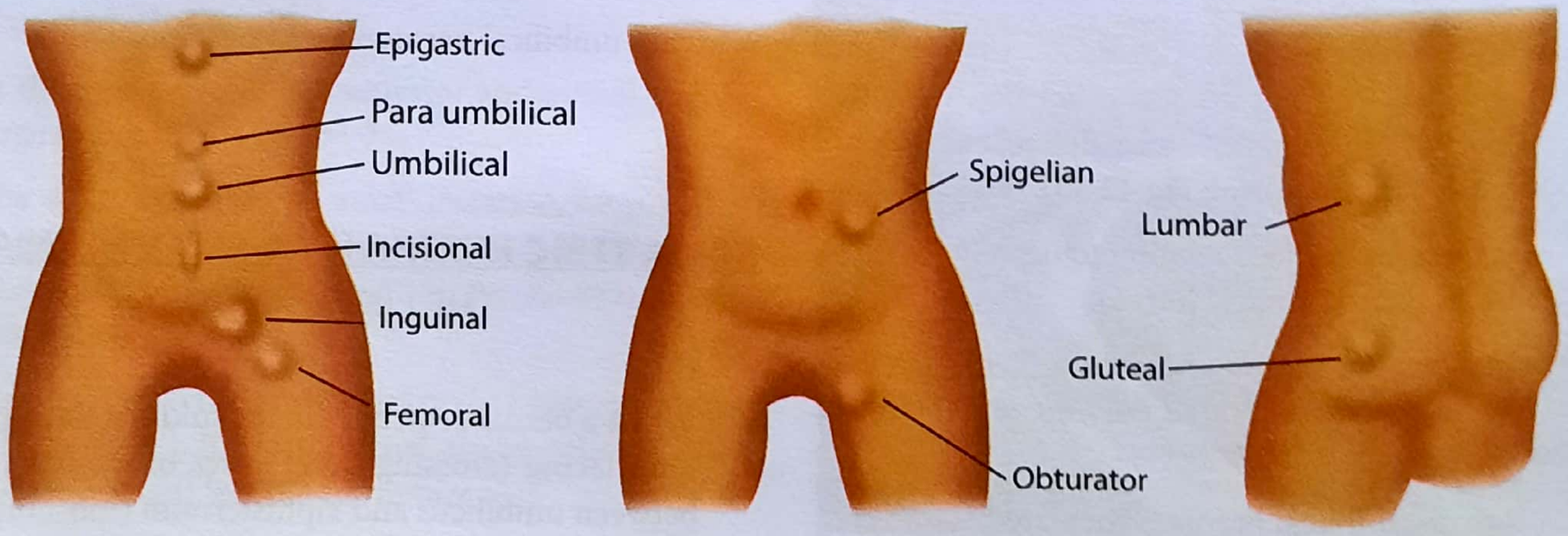

Figure 42.33: Various hernial sites

3. Dyspepsia

A small number of patient may present with dyspepsia and may give symptoms, that mimics peptic ulcer disease. This is due to dragging of omentum due to gastric fullness after meals. *(KARN 94)*

Treatment

If the hernia is giving rise to symptoms, Operative treatment should be under taken. Classical operation for epigastric hernia is mayo's type repair.

*****

RARE EXTERNAL HERNIA

Spigelian Hernia

- It is a rare variety of inter parietal hernia, occurring at the level of arcuate line in middle aged men& women.
- The extraperitoneal fat along with sac lie just deep to the internal oblique muscle or may advance to lie in the gap between external and internal oblique muscles. (Figure 42.35)
- Typically; a soft reducible mass is encountered *lateral to the rectus muscle* *(PGI JUNE 95 JUNE 2004)* *below the umbilicus* *(AL 99)*
- Diagnosis is usually made by CT Scan or USG.
- **Treatment** is operative repair.

Sciatic Hernia

This hernia occurs through the *lesser* sciatic foramen.

Gluteal Hernia

This hernia occurs through the *greater* sciatic foramen, either above or below pyriformis muscle.

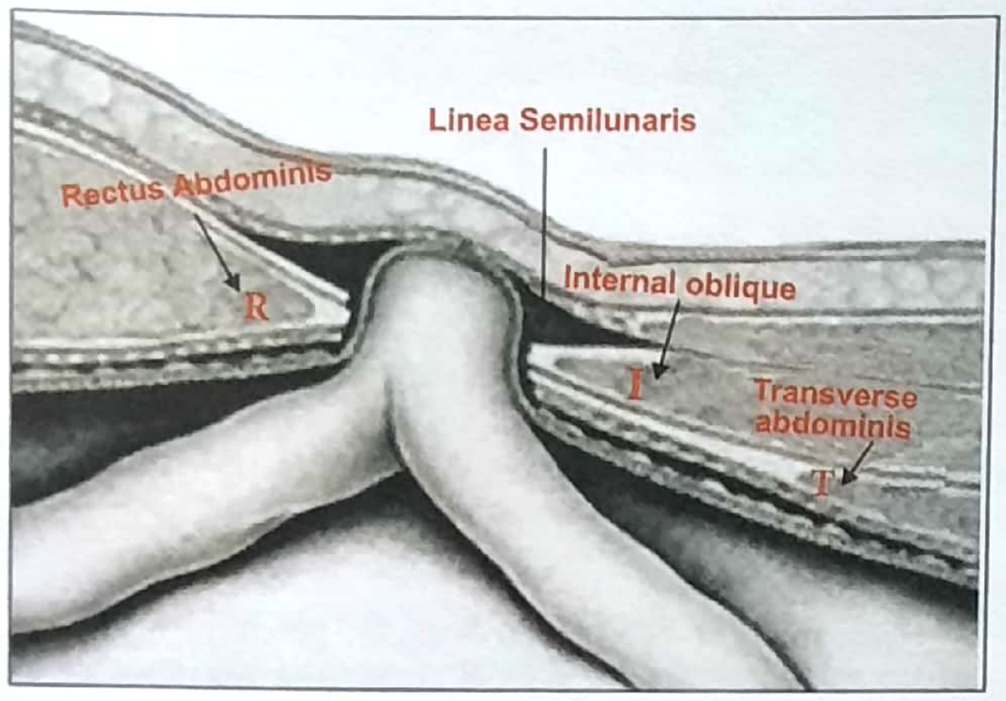

Figure 42.35 : Spigelian hernia

Lumbar Hernia

This hernia occurs through the lumbar triangle. Inferior lumbar hernia is more common than the superior lumbar hernia. (Figure 42.34)

Obturator Hernia

The obturator canal is situated between obturator groove and upper border of the obturator membrane. A pouch of peritoneum may herniate through this canal resulting in an obturator hernia. Obturator hernia is 6 times commoner in women. (Figure 42.36)

Perineal hernia

In this case, hernia occurs through the pelvic floor due to weakness of levator ani muscles.

Peterson hernia

Type of internal hernia occuring in potential space posterior to a gastrojejunostomy.

*****

Figure 42.34 : Bilateral lumbar hernia

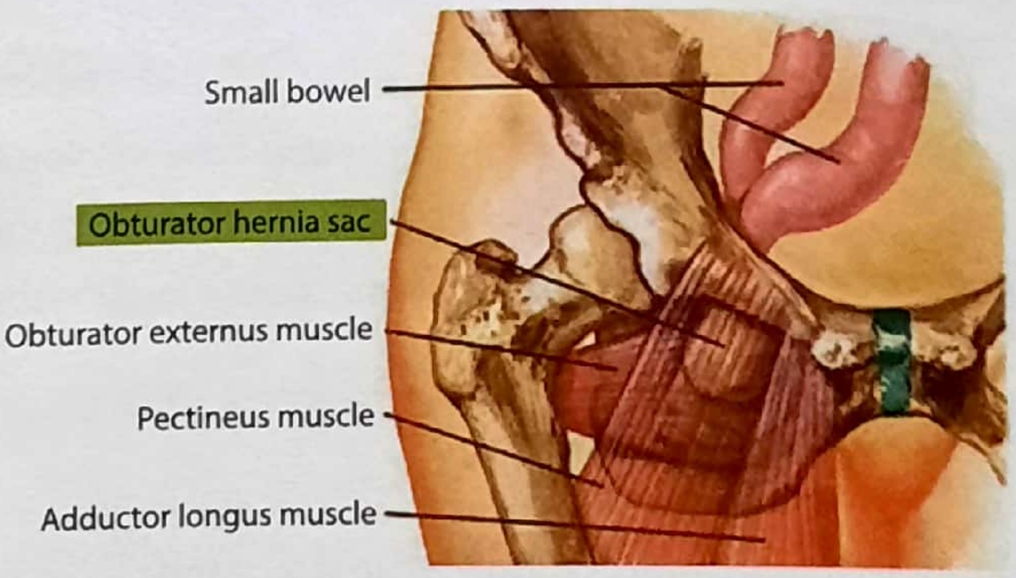

Figure 42.36 : Obturator hernia causes

KEY BOX 42.11

Hernia name	Location	Diagnostic imaging features
Inguinal direct	Hesselbach's triangle	Medial to the inferior epigastric artery
Inguinal indirect	Hesselbach's triangle	Lateral to the inferior epigastric artery
Pantaloon	Hesselbach's triangle	Contains both direct and indirect inguinal hernias
Spigelian	Along linea semilunaris	At junction of lateral abdominal muscles and rectus sheath
Paraurnbilical	Defect in the linea alba	Associated with diastasis of the rectus muscles
Femoral	Medial aspect of the femoral canal	Hernia sac with femoral vein compression
De Garengeot	Femoral canal	Contains the appendix
Amyand	Inguinal canal	Contains the appendix
Littre	Any location	Contams Meckel's diverticulum
Richter	Any location, though usually along anterior abdominal wall	Contains only antimesenteric side of a loop of bowel
Obturator	Obturator canal through obturator foramen	Between pectineus and obturator externus muscles; often presents with incarceration
Grynfeltt-Lesshaft	Upper lumbar triangle	Location
Petit	Lower lumbar triangle	Location

Sample Questions for Prof Examination

1. Write short note on femoral hernia, how will you differentiate it from inguinal hernia?
2. Discuss the differential diagnosis of an indirect inguinal hernia.
3. Discuss the differential diagnosis of an inguinoscrotal swelling.
4. Write short notes on:

   Exomphalos

   Epigastric hernia

   Differentiating point between direct and indirect inguinal hernia.

43 Investigations of Urinary Tract

Contents

- Surgical anatomy of kidney
- Methods of evaluating renal structure and function

SURGICAL ANATOMY OF KIDNEY

- The kidneys are a pair of excretory organs situated on the posterior abdominal wall one on each side of the vertebral column, behind the peritoneum. They remove waste products of metabolism and excess of water and salts from the blood and maintain pH.
- Each kidney is bean or reniform in shape and has upper and lower pole, medial and lateral borders and anterior and posterior surfaces.
- The lateral border is convex. The medial border is concave and middle part shows a depression called as hilum. The following structures are seen in hilum (from anterior to posterior side-**VAP**).

Renal **V**ein	Anterior
Renal **A**rtery	to
Renal **P**elvis	Posterior

TO REMEMBER: **P**elvis is **P**osterior most structure] Owing to the presence of liver, right kidney is 1-2 cm lower than the left kidney. The right kidney extend from L_1-L_3 and left kidney extend from T_{12}-L_2. The left kidney is slightly nearer to the midline than the right.

- The normal adult kidney measures 12 × 6 × 3 cms and weight about 120 grams.
- The anatomic unit of the kidney is the nephron; which is composed of glomerulus, proximal convoluted tubules, loop of Henle, distal convoluted tubules and collecting tubules.
- Each kidney contains approximately 1.3 million nephron. *(PGME)*
- The parenchyma of each kidney usually drains into seven calyces, three in the upper and two each in middle and lower calyces (Figure 43.1 & 43.2) Each of these segments represent an anatomical and physiologically distinct unit; with its own blood supply.
- Left kidney has longer renal vein than right kidney thats why it is preferred for renal transplantation. *(NEET)*
- During Renal transplantation, Renal vessels are connected to external iliac vessels.

METHODS OF EVALUATING RENAL STRUCTURE AND FUNCTION

1. Physical Examination

The kidneys are difficult to palpate. *When the kidney is enlarged* (e.g; in hydronephrosis, cystic disease or neoplasm), *it is bimanully palpable and ballottable.*

2. Examination of Urine

Routine urine examination should be part of every complete physical examination. Most of the chemical tests and microscopic examination of the sediment should be done. The specific gravity of the urine is fixed and low

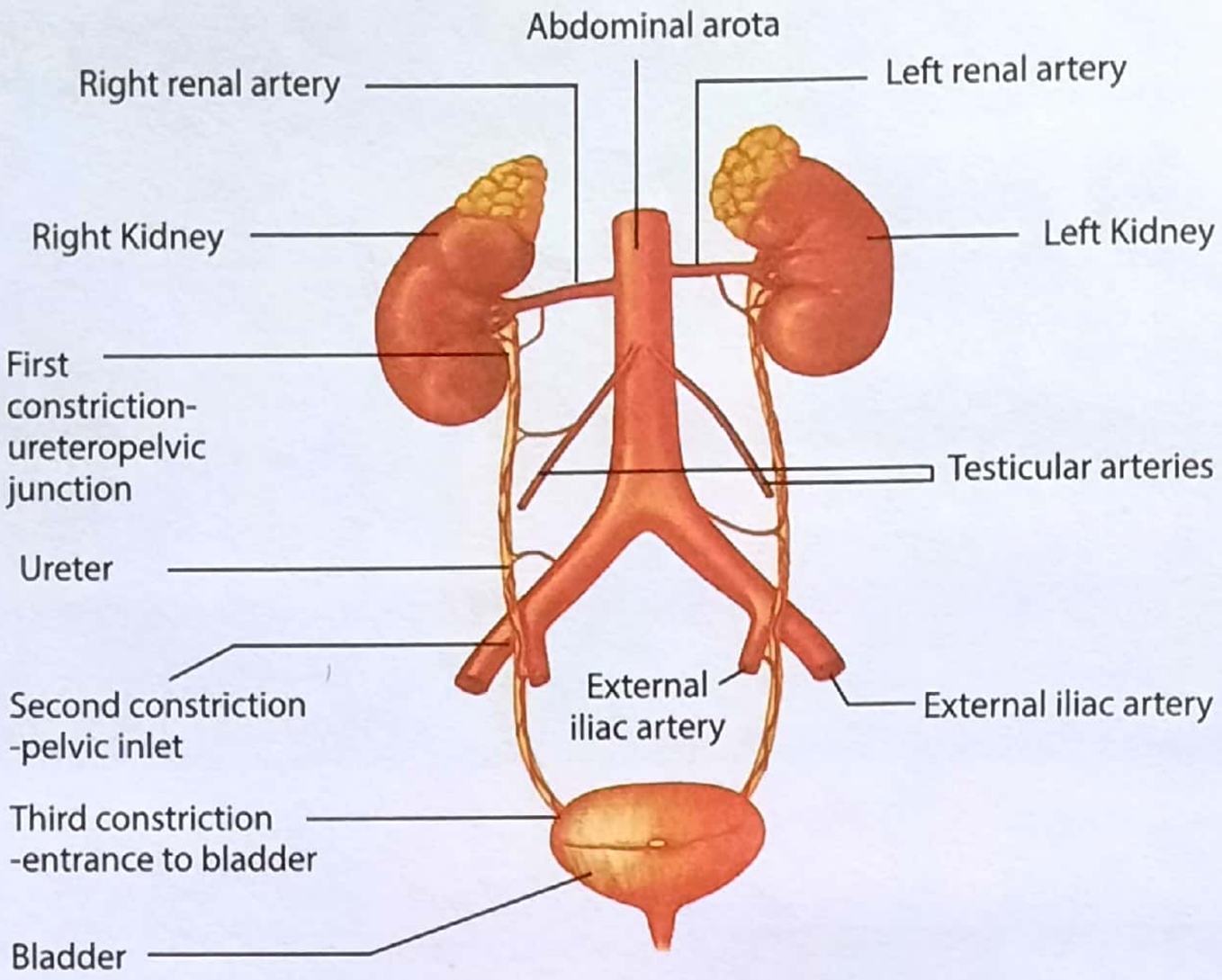

Figure 43.1: The Anatomy of Urinary system

when the kidney loses the power to concentrate; because of renal tubular dysfunction as in chronic renal failure. *(PGME)* Please see key box 43.1; next page.

3. Examination of Blood

Renal disease commonly results in abnormalities in serum level of urea, creatinine,,protein and electrolytes. Changes in red cell count, hemoglobin and platelet function may occur in chronic renal failure.

4. Imaging Study

Many radiological procedures are available for evaluation of renal structure.

(a) Plain abdominal X-ray

Plain abdominal X-ray provides an estimate of kidney size and shape. Plain X-ray abdomen can demonstrate nephro-calcinosis.

- An enlarged kidney from hydronephrosis, polycystic disease and renal cancer can be diagnosed.

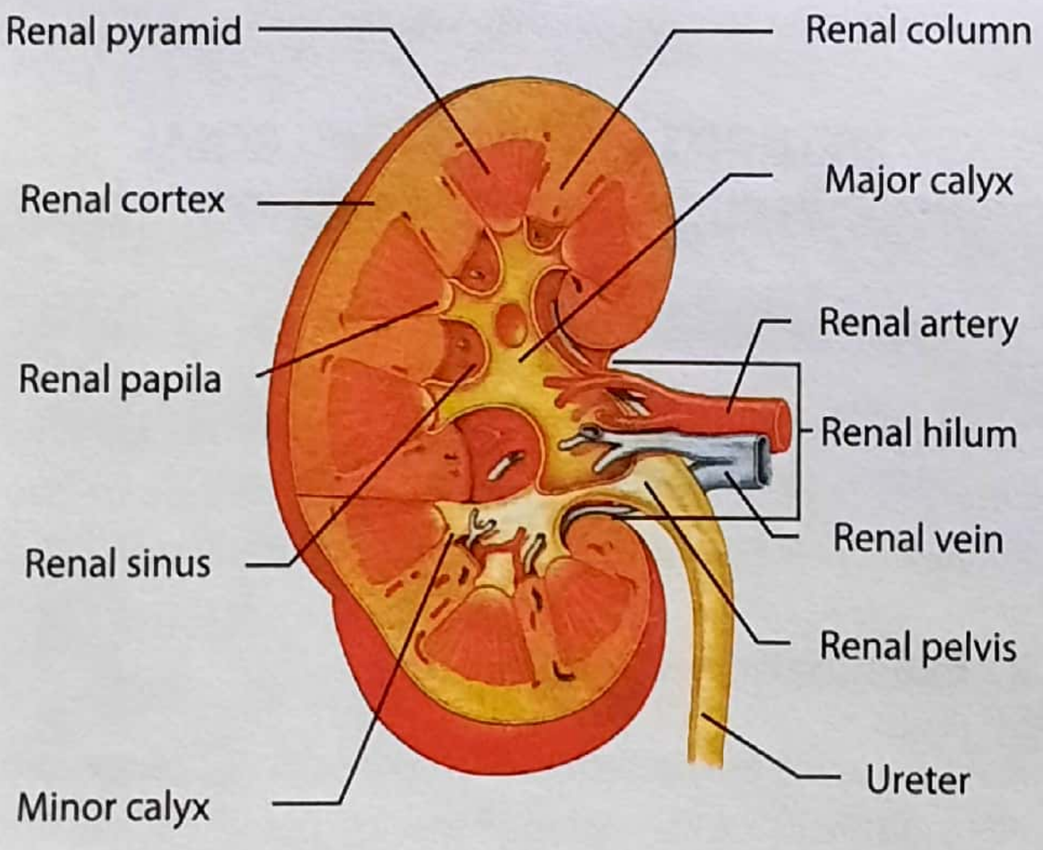

Figure 43.2: Internal structure of kidney

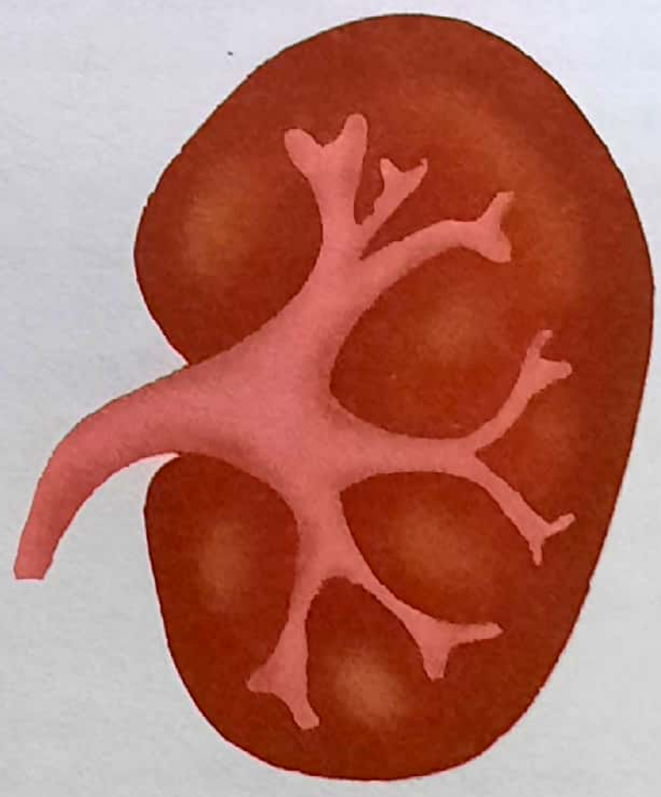

Figure 43.3: Arrangement of renal calyces; note 3+2+2 arrangement of calyces

KEY BOX 43.1	
Physical evaluation	
Colourless	Polyuria; normal
Cloudy	Phophates, carbonates, whites blood cells, lipid; may be normal
Dark	Bilirubin, blood
Red, red-brown	Blood hemoglobin; porphyrins
Black	Homogentisic acid
Various	Drugs, food, dyes
Odour	
Foul, amraonical	Probable infection with urea-splitting bacteria.
Various unusual odours	Possible metabolic disorders such as phenylketonuria (mousy) or isovaleric acidemia (sweety).
Volume (24 hour)	Polyuria, oliguira; normal range is about 600-2000 ml/24 hrs for an adult. Nocturia, 400 mL or more at night.
Specific Gravity	Normal range is 1.005-1.025 consistent value of 1.010 is isosthenuria and indicates inability to concentrate urine, as in chronic renal failure. pH Dietary factors, renal tubular disorder, chronic renal failure, acidosis, alkalosios.
Chemical evaluation	
Protein	Normally traces only. Numerous causes-must exclude renal failure
Blood	Chemical test may detect myoglobinuria and hemoglobinuria. Microscopy should always be used to confirm hematuria.
Glucose	Glycosuria strongly suggests diabetes mellitus.
Bilirubin	Obstructive jaundice, liver disease.
Ketones	Starvation, diabetic ketotic coma.
Urobilinogen	Increased in hemolytic or hepatocellular jaundice; absent in obstructive jaundice.
Porphobilinogen	Positive in porphyria.
Examination of sediment (Microscopic evaluation)	
Red blood cells	Various causes
Casts: red cell, white cell, epithelial	Many renal diseases.
White blood cells	Pyelonephritis, cystitis, other renal disease.
Malignant cellls by cytologic examination	Cancer; especially of the bladder.
Crystals	Various types often present. Little diagnostic significance.
Bacteriologic Examination (culture)	Specific organisms, pyelonephritis, cystitis, urethritis

Figure 43.4: Renal stone as shown on X-ray

Figure 43.5: IVP

- **About 90% or renal stones are radio-opaque and** can be seen on X-ray. *(JIPMER 86, MANY PGME)*

(NOTE: **Only 10% Gallstone are radio-opaque).**

(b) Contrast Urography

The collecting structures of the kidney, ureters and bladder can be demonstrated radiologically with contrast media by following methods.

Contrast medium (Barium) is used to enhance the visibility of organs on X-ray film.

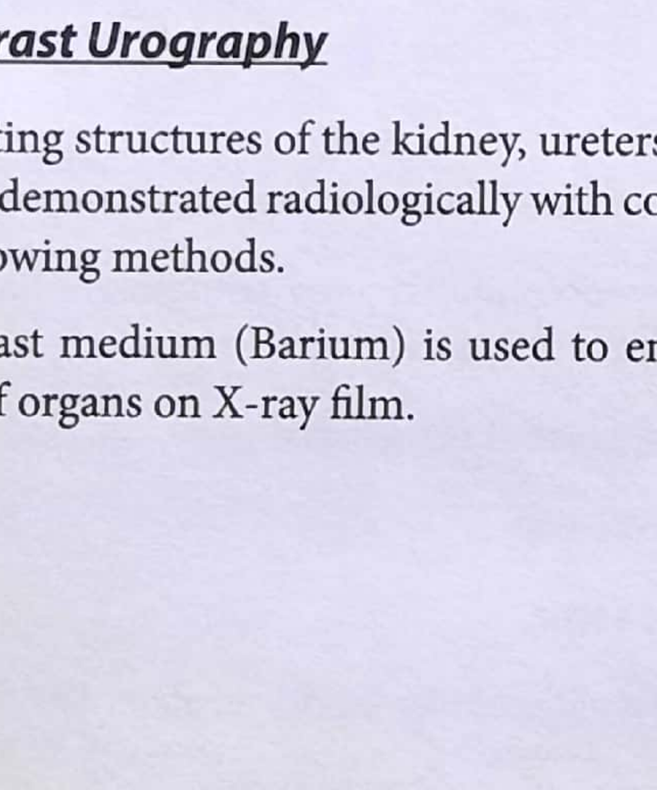

Figure 43.5.1: Diagram of Bladder stone

(i) Intravenous urography (IVU) *Syn:*

Excretory urography (EU) or Intra venous pyelography (IVP), excretory urography (EU) or intravenous pyelography (IVP)

It can demonstrate a wide variety of urinary tract lesions, and is simple to perform and well tolerated by most patient.

Principle

- As the name intravenous urography itself suggest, a urograph (ie;-X-ray of renal system) is taken after injecting a radio-opaque dye intravenously.
- Generally, hypaque (sodium diatrizoate) or urograffin is used for injection. *(IMP. POINT)*
- The dye is concentrated and excreted by kidney and then the dye reaches different part of collecting system at different time in normal individual and then X-rays of entire urinary system are taken in supine position at 5 minutes, 10 minutes and 15 minutes, which demonstrates the various areas of urinary system (see box 43.2).
- Intravenous urography is a physiological as well as anatomical test, since it not only determines the excretory function of the kidney but also clearly demonstrate the contour of renal pelvis, the calyces, the ureters and urinary bladder. A stone in these structure will produce a filling defect (ie; defect in filling of that part of renal system by dye and hence not visualized).

Figure 43.5.2: IVP

- Delay in the excretion of dye will indicate towards impaired renal function and decreased excretory capacity of kidney.

Contrandication of IVU (IVP) *(AI 96, MANY PGME)*

1. Allergy to dye
2. Multiple myeloma The dye precipitate Bence-Jones protein and blocks the renal tubules.
3. Hyperuricemia
4. Diabetes type II
5. Primary hyperparathyroidism
6. Sickle cell anemia
7. Renal failure
8. Dehydration

(ii) Retrograde urogram (RGU)

- In this, dye is introduced in retrograde fashion ie; dye is introduced in ureter from below (urethra):- This requires cystoscopy and placements of catheter in the ureters.
- RGU may be required if IVU (IVP) is unsatisfactory or patient has a history of allergy to intravenous contrast media or due to impaired renal function which has failed to show the pelvis and calyces.

KEY BOX 43.2	
Time	**Structures visualized**
1st minute	Nephrogram (kidney)
5 minutes	Calyces and pelvis (Pelvi-calyceal system)
10 minutes	Ureters
15 minutes	Urinary-bladder

(iii) Antegrade Urogram

In this; under fluoroscopic or ultrasonic guidance an 18 guage needle is introduced directly in calyx or pelvic of kidney. Radio-opaque dye is then injected in kidney and appropriate films are taken.

5. Micturating Cystourethrography (MCU)

In this procedure, dye is injected in bladder through a urinary catheter or by a supra-pubic puncture. It helps in dem-onstrating:-

- Vesico ureteric reflux in children
- Posterior urethral valve
- Vesical trauma
- Vesico vaginal or vesico colic fistula.

6. Ascending urethrography (ASU)

In the diagnosis of urethral stricture, ASU may be very helpful.

- A contrast medium; usually Conray is instilled per urethra and a -X-ray is obtained.

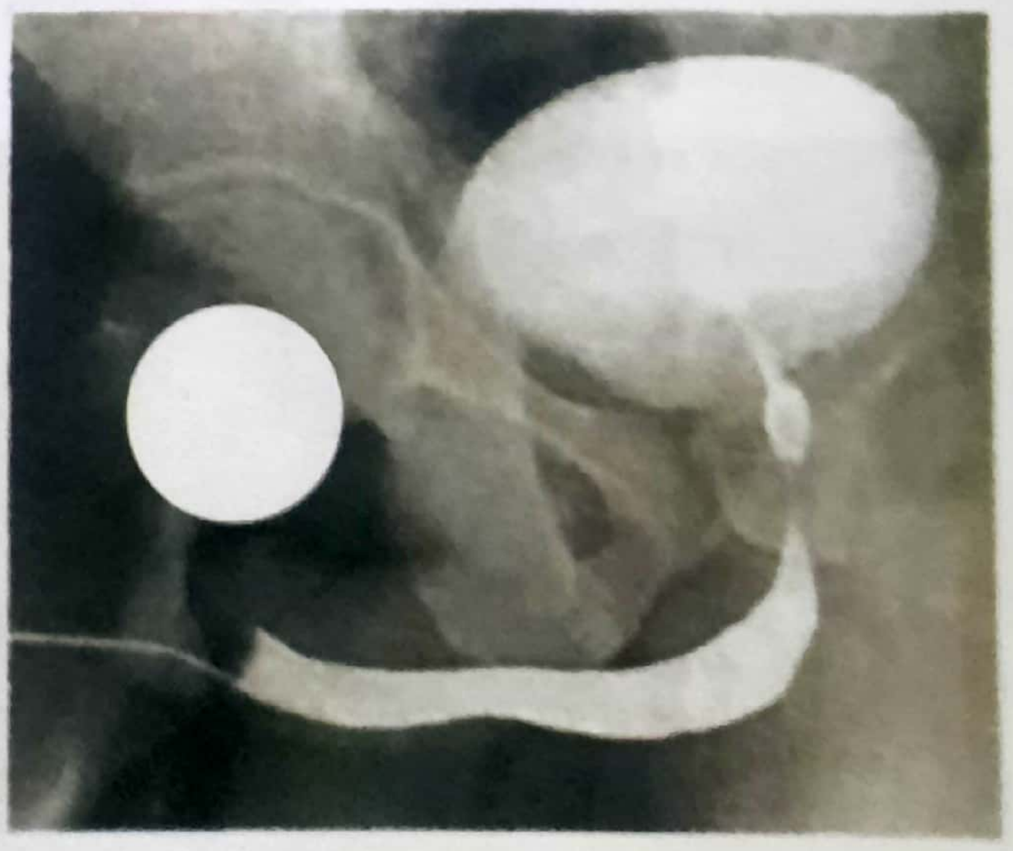

Figure 43.6: Micturating cystourethrography

- It is demonstrate the length of stricture, proximal dilatation or diverticulum in urethra.

7. Digital Subtraction Angiography

This has now replaced the old translumbar aortography and satisfactory imaging of renal vessels can be achieved by intravenous injection of contrast medium. More precise information can be obtained by intra-arterial injection through a fine catheter inserted into femoral artery using the seldinger technique.

8. Ultrasonography

Ultrasonography is the most widely used imaging technique in urology *(AIIMS NOV 2000)*. The size of the kidney, the thickness of its cortex and the presence and degree of hydronephrosis can be diagnosed with accuracy. Intra renal cyst and solid masses (tumours) can be diagnosed. The volume of urine before and after micturition(ie residual volume) can be calculated. Stones in kidney, ureters and urinary bladder can be demonstrated by Ultrasonography.

9. Transrectal Ultrasonography

This is to investigate suspected carcinoma of the prostate. lt is very useful in diagnosing carcinoma of prostate.

10. CT Scan

CT Scan is particularly useful to assess structures in the retroperitoneum *(IMP. POINT)*. In Renal cell carcinoma, CT shows the size and site of tumour, the presence of enlarged lymph nodes at the hilum and invasion of renal vein and vena cava by the tumour. CT scan is also helpful in staging of bladder, prostate and testicular cancer.

Figure 43.7: Ascending urethrography

Figure 43.8: Contrast urography

11. Magnetic Resonance Imaging (MRI) & Positron Emission Tomography (PET)

These newer techniques produce stunning images of urinary tract and give functional information as well. It is likely that they will replace many of the routine imaging technique in future.

12. Radio Isotope Scanning

Gamma camera screening following of Technetium 99^m will give information about proximal tubular function. Two isotopes are usually used, namely- Diethylene Trio Pentaacetic Acid (DTPA) or DiMercapto Succinic Acid (DMSA). These isotopes are filtered and succinic Acid tubular lumen and images are taken by using Gamma camera.

- DT**P**A - Principally done for **P**hysiological function of kidney [Remember with **P**→**P**]
- D**M**SA - For **M**orphology and function. DMSA is used more commonly for assessing morphology of kidney (eg; cortical imaging, renal parenchyma).

13. Renal Biopsy

Percutaneous renal biopsy is a safe procedure that provides a core of renal tissue for histological examination. Samples are also processed for electron microscopy and immunofluorescence. These studies have provided

an objective method of diagnosis of renal diseases and have increased our understanding of many pathologic processes. Before biopsy is under taken; it is necessary to demonstrate that both kidneys are present and that there is no bleeding disorder. (Figure 43.9)

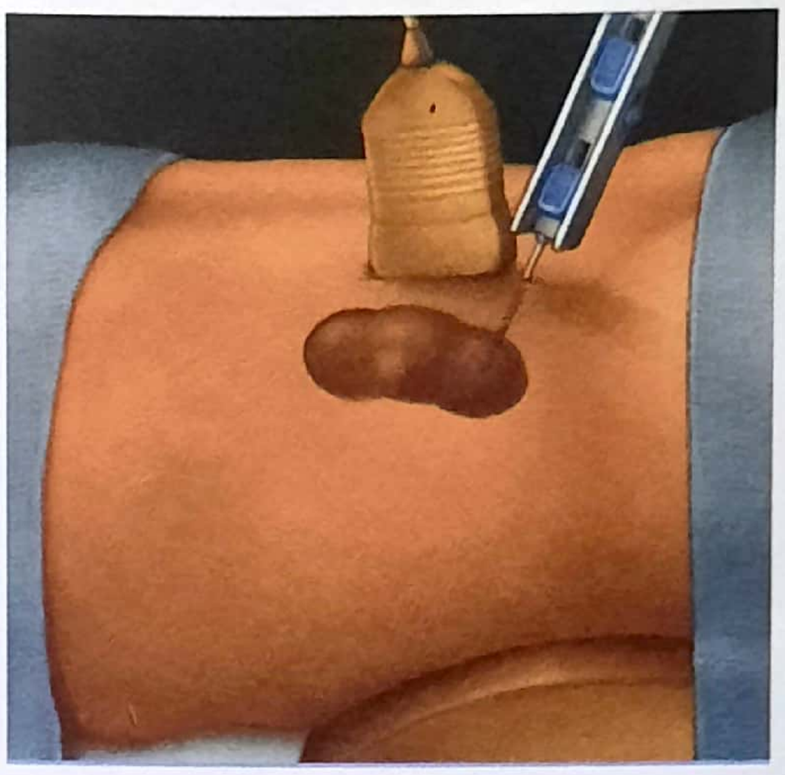

Figure 43.9: Renal biopsy

14. Cystoscopy

Cystoscopy is a procedure that allows to look inside of the urinary bladder and the urethra using a thin, lighted instrument called a cystoscope.

The cystoscope is inserted into your urethra and slowly advanced into the bladder. Cystoscopy allows to look at areas of bladder and urethra that usually do not show up well on X-rays. Tiny surgical instruments can be inserted through the cystoscope that allow to remove samples of tissue (biopsy) or samples of urine.

Small bladder stones and some small growths can be removed during cystoscopy. This may eliminate the need for more extensive surgery.

It is best investigation to visualise posterior urethra.

Why It Is Done

Cystoscopy may be done to:

- Find the cause of symptoms such as blood in the urine (hematuria), painful urination (dysuria), urinary incontinence, urinary frequency or hesitancy, an inability to pass urine (retention), or a sudden and overwhelming need to urinate (urgency).
- Find the cause of problems of the urinary tract, such as frequent, repeated urinary tract infections or urinary tract infections that do not respond to treatment.
- Look for problems in the urinary tract, such as blockage in the urethra caused by an enlarged prostate, kidney stones or tumors.
- Evaluate problems that cannot be seen on X-ray or to further investigate problems detected by ultrasound or during intravenous pyelography.
- Remove tissue samples for biopsy.
- Remove foreign removal.
- Place ureteral catheters (stents) to help urine flow from the kidneys to the bladder.

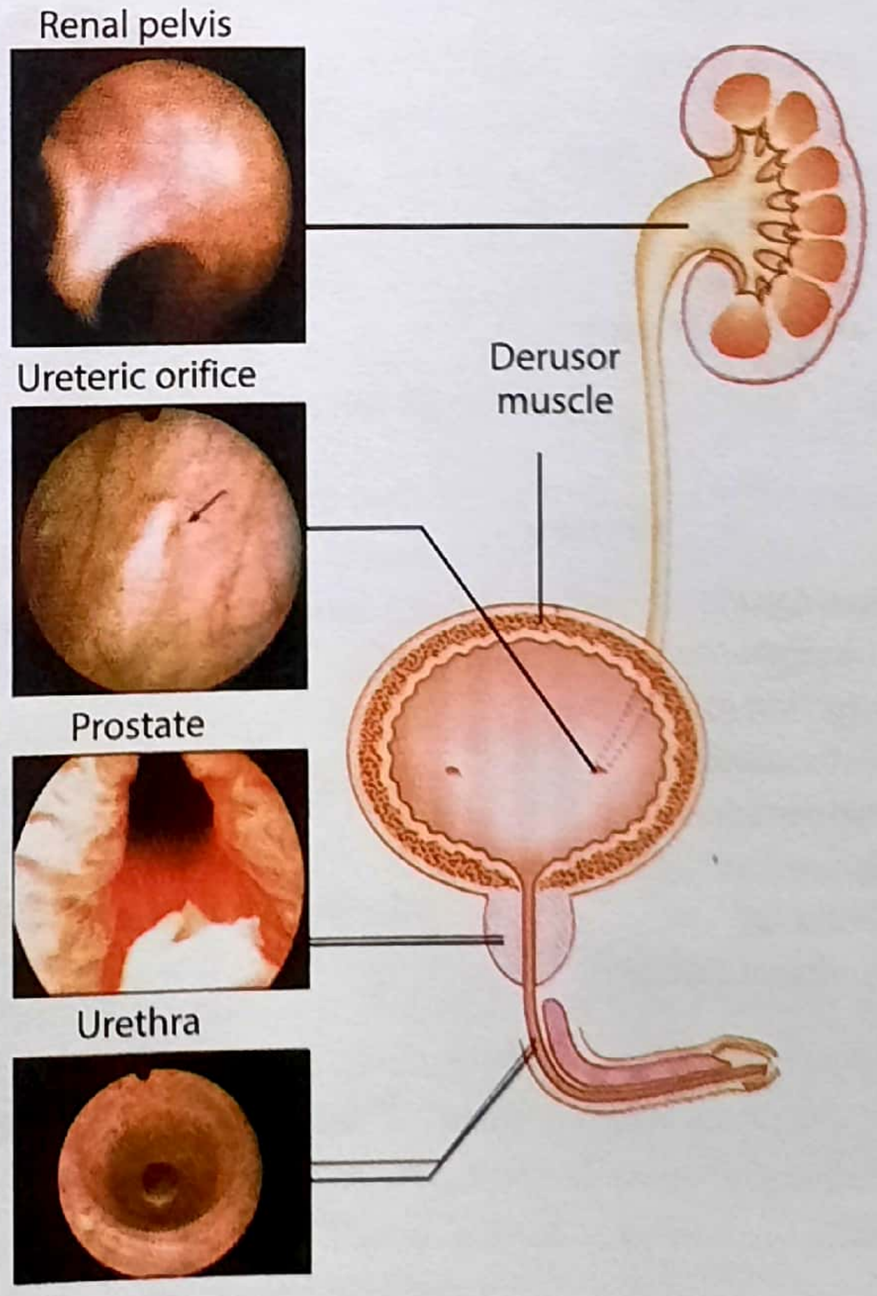

Figure 43.10 Cystoscopic view of different parts of urinary system

Before moving to next chapter kindly go through this figure

PRE-RENAL

Effects of pre-renal conditions

- Loss of renal function, e.g. from hypoperfusion
- Effects on other organs, e.g. 'shock' liver

Renal vasculature

- Hypertension
- Loss of renal function

POST-RENAL

Ureter

- Haematuria
- Loin pain 'renal colic'
- Loss of renal function (on the side of an obstruction)
- Ureteric stone
- Tumours

Penis

- Phimosis
- Paraphimosis
- Carcinoma of penis

Urethra

- Haematuria
- Urinary retention—obstruction
- Infection (urethritis)
- Metal stenosis
- Hypospadias
- Epispadias
- Urethritis
- Uretheral stricture

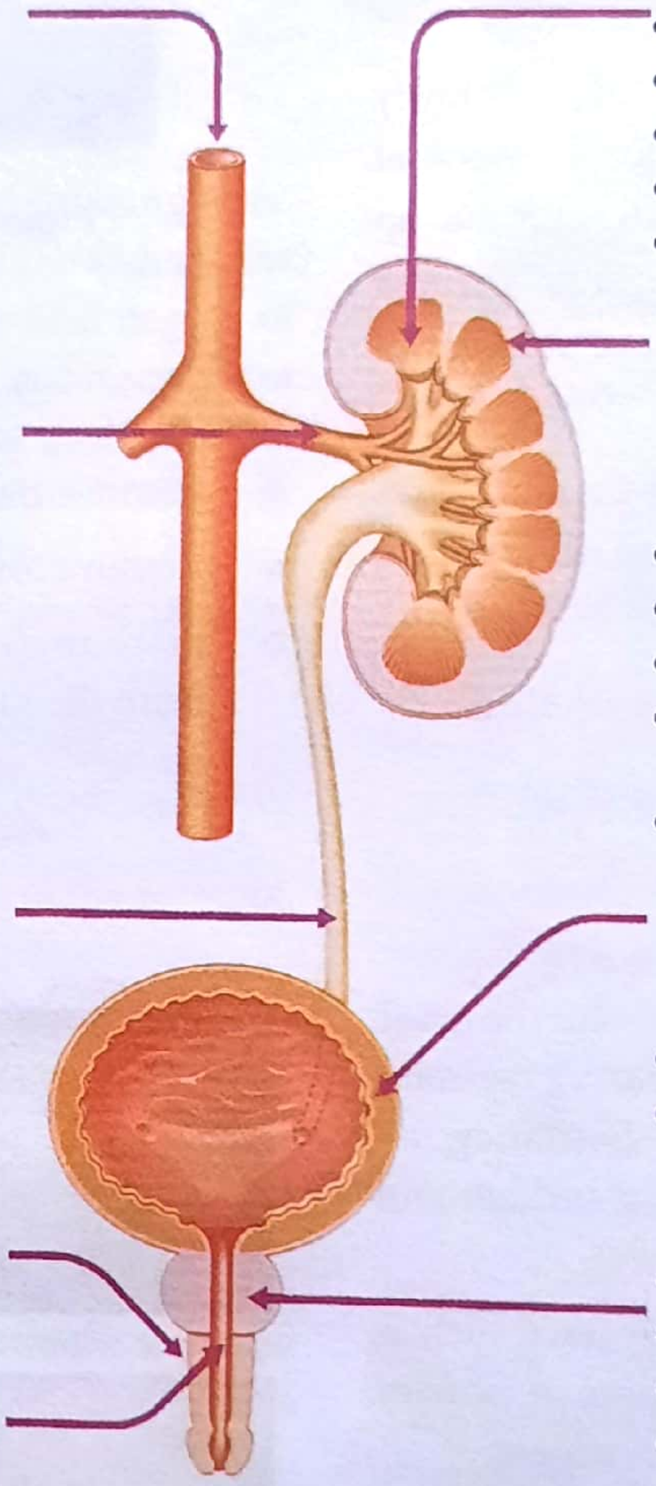

RENAL

- Haematuria
- Proteinuria
- Oedema (nephrotic syndrome)
- Hypertension
- Loss of renal function
- Renal stone
- Hydronephrosis
- Tumours
- Renal infection

Interstitial disorders

- Leucocyturia
- Haematuria
- Proteinuria
- Loss of renal function—especially tubular/medullary
- Loin pain, e.g. infection—pyelonephritis

Bladder

- Haematuria
- Acute retention—obstruction
  - suprapubic pain/discomfort
  - oligo/anuria
- Incontinence
- Infection (cystitis)
- Bladder stones
- Carcinoma

Prostate

- Symtoms of obstruction
- Hesitancy,l dribbling, poor stream, frequency, urinary retention
- Infection (prostatitis)
- Carcinoma

Figure 43.11 Disease affecting urinary system

44 The Kidney and Ureter

Contents

- Congenital abnormalities of kidney
- Injuries to kidney
- Hydronephrosis
- Renal stone
- Ureteric stone
- Kidney infections
  - Acute pyelonephritis
  - Chronic pyelonephritis
  - Xanthogranulomatous pyelonephritis
  - Renal abscess (Renal carbuncle)
  - Infected hydronephrosis and pyonephrosis
  - Perinephric abscess
  - Renal tuberculosis
- Wilm's tumour
- Renal cell carcinoma (Hypernephroma)
- Papillary transitional cell tumours of renal peWs and ureters.
- Squamous cell carcinoma of pelvis

CONGENITAL ABNORMALITIES OF KIDNEY

A. Renal agenesis

Renal agenesis is failure of development of the renal anlage, resulting in a complete absence of the kidney. Renal agenesis may be bilateral or unilateral.

(i) Bilateral renal agenesis

It is a rare anomaly, resulting in death in utero or soon after birth. Infants have renal failure associated with characteristic facial features, with wide-set eyes and prominent inner canthi, a broad flattened nose, large and low set ears and a receding chin (*Potter's facies*).

(ii) Unilateral renal agenesis

It is more common; occurring in 0.1 % of the population. It is asymptomatic because the single kidney is capable of serving normal fenal function. The frequency of unilateral renal agenesis makes confirmation of the presence of 2 kidneys obligatory before nephrectomy or even biopsy is performed. (Figure 44.1)

B. Renal Hypoplasia

Renal hypoplasia is defined as a small kidney with <50 grams in an adult (normal weight of a kidney is about 120grams) with six or fewer calices (normal:7-13) but otherwise normal in structure. The anomaly is rare and usually unilateral. Renal failure occurs only when hypoplasia is extreme and bilateral.

KEY BOX 44.1

Associated findings in patients with unilateral renal agenesis

- **VACTERL** anomalies
- 30% will have VUR in contralateral kidney

Males

- Can have abnormal ipsilateral Wolffian structures (vas deferens, seminal vesicle)
- Testes are normal

Females

- Can have abnormal ipsilateral Mullerian structures (uterus, fallopian tubes, upper vagina-Mayer-Rokitansky syndrome)
- Ovaries are normal

VACTERL: Vertebral, Anorectal, Cardiac, Tracheo Esophageal, Renal, (VUR, vesicoureteral reflux), Limb defect

C. Ectopic kidney

Ectopic position of one or both kidneys is not unusual. The *most common location being at the pelvic brim* (PGME) or in the pelvis. The incidence of ectopic kidney in general population is about 1:1000. Renal ectopia is usually asymptomatic but may cause obstruction and infection, if there is kinking of the ureter. Renal ectopia is more commonly on left side (PGME).

For repair of UPJ obstruction a side to side ureteropyelostomy, or ureteroneocystostomy to a dilated lower pole calyx is sometimes required to obtain dependent drainage.

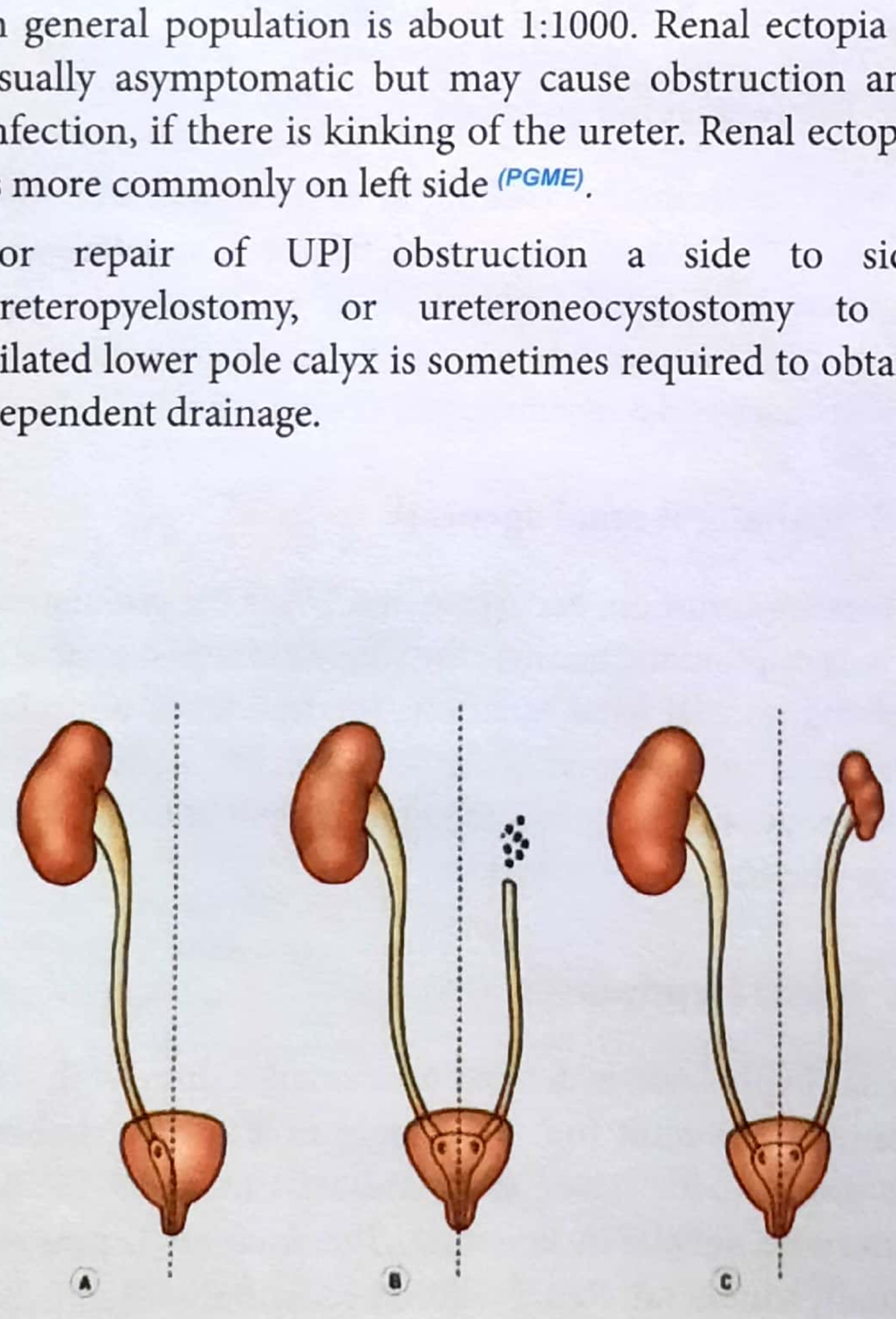

Figure 44.1: Renal **(A)** agenesis, **(B)** dysplasia, and **(C)** hypoplasia

D. Horseshoe Kidney (AIIMS 92, IMP. PGME TOPIC)

- Horseshoe kidney is abnormal fusion of the 2 kidneys at the lower poles; which is fused across the midline by a broad band of renal tissue. It occurs in 0.4% of individuals.(fig. 44.2)
- The ureters pass anterior to the isthmus of the horseshoe kidney and may be narrowed. Most patients are asymptomatic.
- There is a higher incidence of urinary infection and renal calculi, possibly due to urinary stasis due to angulation of ureters. (MANY PGME)
- This condition is more common in male.
- Horseshoe kidney is **usually a radiological diagnosis.** ie; diagnosis is confirmed on radiological examination done for some other disease. (MANY PGME)
- Most frequently **IVP** shows the **lower pole calyces** on both side being **directed towards the midline.** (PGME)
- The ureters characteristically have **vase-like curve** (PGI 80, AIIMS 84) [NOTE: Vase-means; a flower pot]

Horse shoe kidney is not a C/I to pregnancy.

Treatment

No treatment is necessary unless obstruction or infection is present. Urinary drainage of a horseshoe kidney may be improved by dividing its isthmus. If one pole of the horseshoe is badly damaged it may require heminephrectomy.

E. Unilateral Fusion (Crossed dystopia)

- Unilateral fusion (synonym: *Crossed dystopia*) is rare.
- Both kidney are present on one side of loin and are usually fused giving a unilateral 'S' **shaped appearance.** See figure 44.3.
- The ureter of the lower kidney crosses the midline to enter the bladder on the contralateral side. (fig. 44.3).

(f) Adult Polycystic Kidney Disease (APKD) (AIIMS JUNE 01, AIIMS NOV 97)

- Adult polycystic kidney disease is a relatively common inherited disorder affecting one of every 1000 individuals and is **almost always bilateral** (95% of cases) (AI 91).

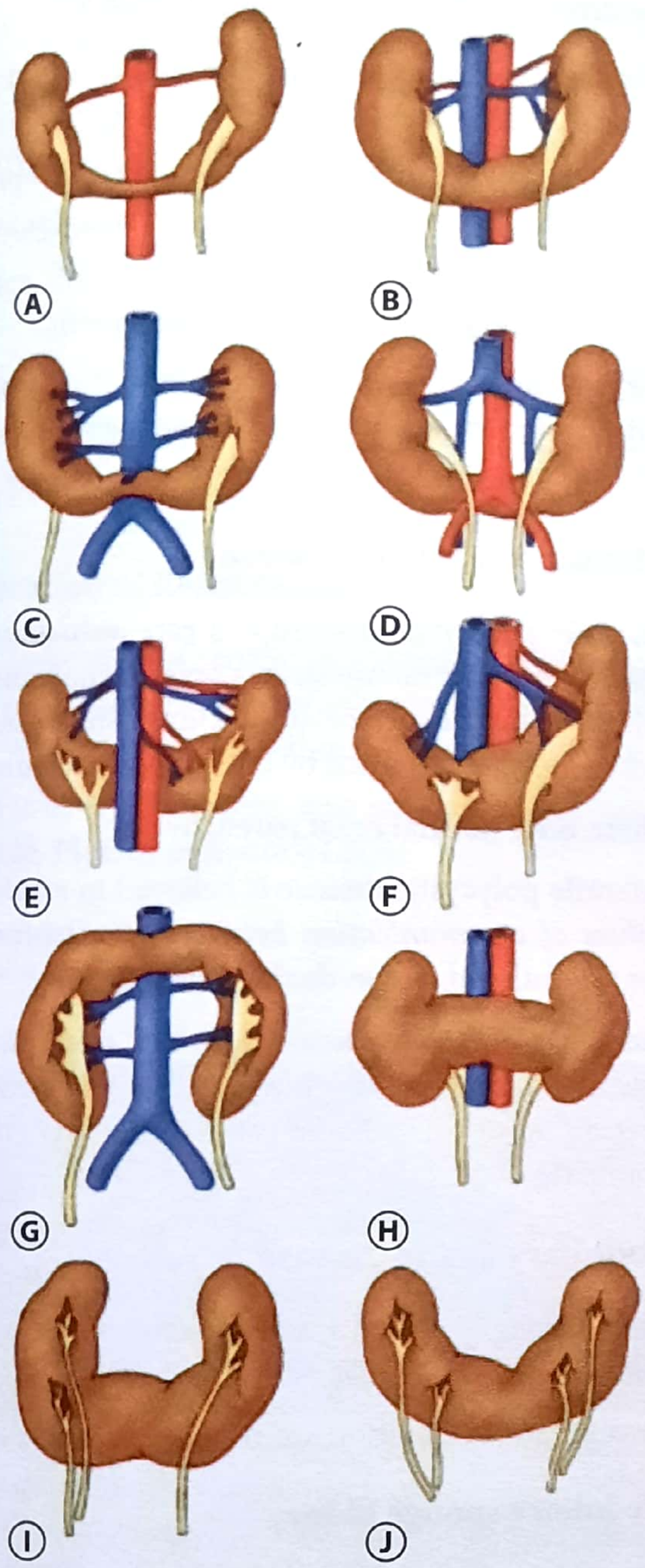

Figure 44.2: Variations of horseshoe kidney

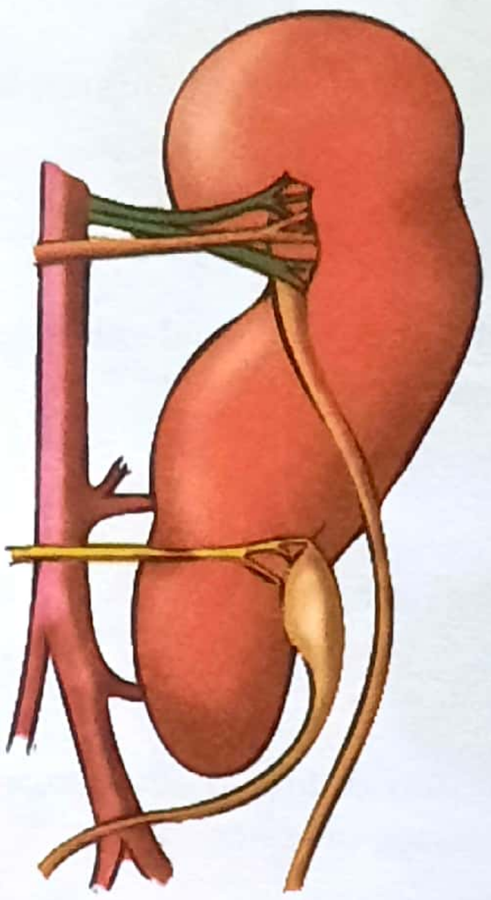

Figure 44.3 Unilateral fusion (crossed dystopia)

Figure 44.4 Polycystic kidney

- Polycystic kidney is hereditary and is transmitted by either parent as an **autosomal dominant trait** (AIIMS NOV 97). The defective gene is situated on the **short arm of chromosome 16.**
- Though it is a congenital condition; it usually does *not manifest itself, clinically before the age of 30 years.* (UP PGME)

Pathology

- Grossly; both kidneys are greatly enlarged and by a mass of cysts, involving both cortex and medulla. (Figure 44.4)
- Microscopically; the cysts are lined by proximal and distal tubular epithelial cells. Residual nephrons are progressively destroyed.
- Patients with adult polycystic disease have increased frequency of **cysts in the liver** (in about 20% of cases), **pancreas and spleen** and *in 15%* of cases congenital **(berry) aneurysms** of cerebral arteries and coarctation of aorta. (AIIMS NOV 97, AI 91, UP, MP PGME)

Clinical Features

The condition is slightly more common in women than men. There are six important features.

1. Renal enlargement

Bilateral knobby or nodular renal enlargement is noticed during abdominal palpation.

2. Pain

(a) Dragging dull ache in the loin due to stretching of the capsule or by the weight of the kidney dragging on the pedicle.

(b) Severe pain may occur due to hemorrhage in a cyst or due to passage of stone.

3. Hematuria

Hematuria occurs due to rupture of the cyst into the renal pelvis, which is typically moderate and lasts for few days.

4. Infection

It is common because of urinary stasis and may leads to pyelonephritis.

5. Hypertension

Hypertension is present in *75%* of cases over the age of 20 years with APKD. *(IMP. POINT, MAY BE FUTURE PGME Q)*

6. Uremia *(AIIMS 97)*

Patients pass large quantities of urine of low specific gravity (1.010 or less) with traces of albumin, but no casts or cells. CRF develops as functioning renal tissue is replaced by cyst.

Investigation

1. Ultrasound and CT Scan

Both ultrasound and CT will show multiple cysts in kidneys and sometimes in the liver and other organs as well.

2. Excretory Urography (EU)

Polycystic kidneys have a typical appearance on excretory urography. These are *(VERY IMP. FOR PGME)*

(a) Enlargement of renal shadows in all directions.

(b) Compression, stretching and elongation of the renal calyces over the cysts giving **"spiders legs"** or bell like appearance. *(AP 84, KERALA 86, 88).*

Treatment

1. The only available treatments is dialysis and renal transplantation.
2. The renal failure may be managed with a low protein diet, to postpone the need for renal transplantation.
3. Infection, anemia and disturbances of calcium metabolism need appropriate management.
4. Surgery to uncap the cysts ***(Rovsing's operation)***, is indicated in rare cases. This is now being done laparoscopically.

G. Infantile Polycystic Disease

- Infantile polycystic disease is a rare **autosomal recessive** disorder manifested as severe renal failure in infancy. The cut surface of the kidney shows numerous fusiform cysts lined by cuboidal epithelium.
- There is no normal renal parenchyma.
- Infantile polycystic disease is believed to *result from failure of communication between the nephron and the pelvicaliceal system during development.* *(PGME)*
- Many patients have associated bile duct dilations (microhamartomas) as well as portal fibrosis (congenital "hepatic fibrosis). In some patients; the liver changes dominate.

H. Medullary Cystic Disease

- Medullary cystic disease affects the medulla selectively.
- Two separate condition are recognized, these are:-

(i) Medullary sponge kidney

It is relatively common, occurring in one or both kidneys of older patients (30-60 years).

- Small cysts are present in the renal papillae.
- The pathogenesis is unknown and there is usually no symptoms except lump in abdomen.
- The frequency of urinary calculi is increased due to increased UTI.

(ii) Uremic medullary cystic disease

It is a rare disease of children and young adults characterized by the presence of multiple cysts in the medualla, cortical tubular atrophy and interstitial fibrosis with cylindrical dilatation. The pathogenesis is no known. Chronic renal failure progresses and death occurs in 5-10 years.

I. Solitary Renal Cyst (Syn. Simple cyst of kidney)

- Simple cortical cysts are present in over 50% of patient after age 50. They may be multiple and large. They are of no clinical significance.

Please read key box 44.2, very carefully.

*****

CONGENITAL ABNORMALITIES OF THE RENAL PELVIS AND URETER

Duplication of Renal pelvis

- Duplication of renal pelvis is the ***most common congenital abnormality*** *of the upper urinary tract* (MANY PGME) and is found in about 4% of the patients.
- It is usually unilateral and more common on the left side. Please see figure 44.5(A).

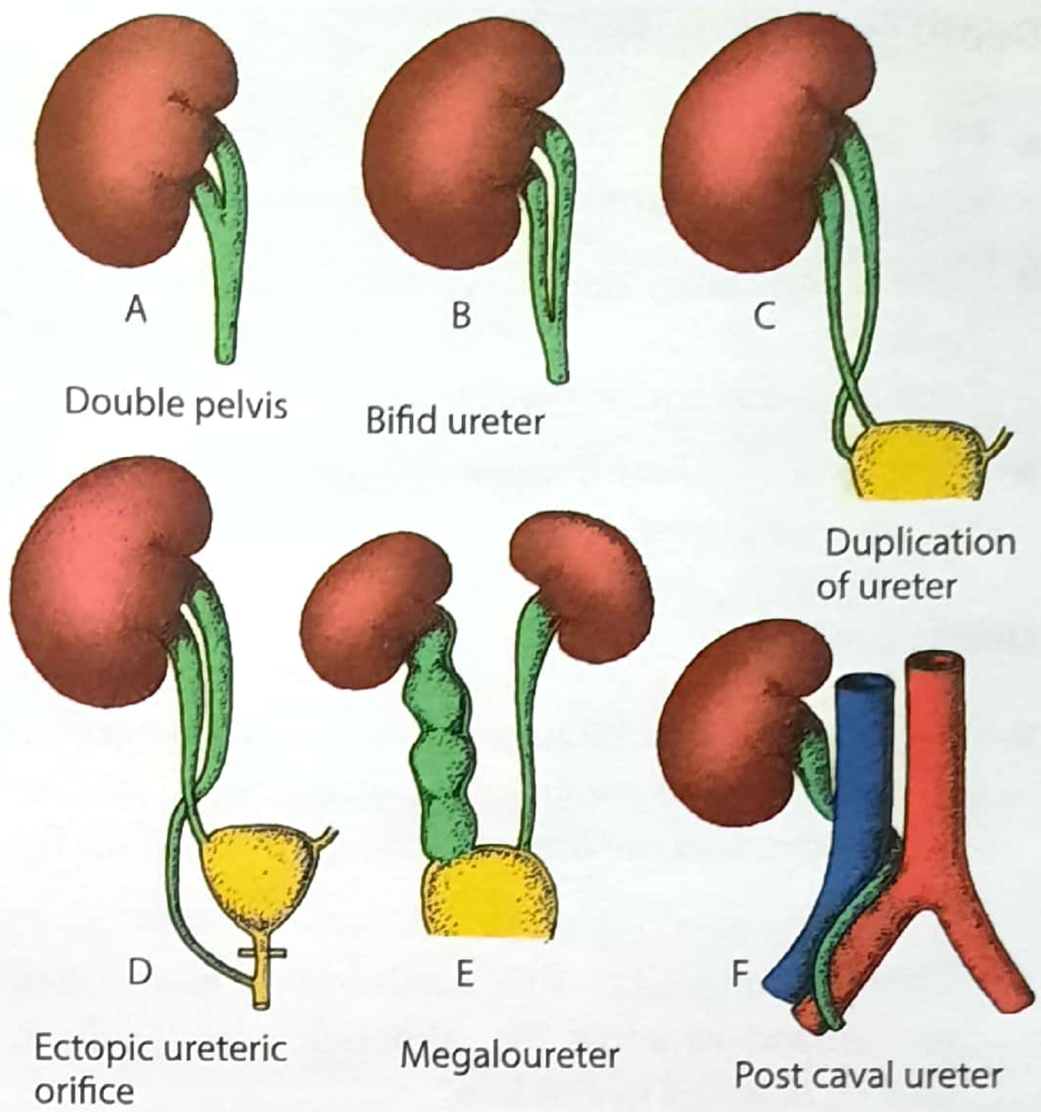

Figure 44.5 Various anomalies of ureter & pelvis

KEY BOX 44.2

Cystic Disease of the Kidney

Disease	Heredity	Age	Unilateral/ Bilateral	Gross Feature	Associated Malformation or Disease
Polycystic renal disease					
Adult polycystic disease	Autosomal doimnant	Adult; rarely children	Bilateral	Large, bosselated reniform; cysts in cortex and medulla	Cysts of liver, pancreas, lung & cerebral (berry) aneurysms
Infantile polycystic	Autosomal recessive	Infants, children	Bilateral	Large smooth kidney with radial fusiform cysts in cortex and medullar	Congenital hepatic fibrosis
Medullary cystic disease					
(i) Medullary sponge kidney	None	Any age; usually adults	Either	Cysts at tip of papillae	Renal stones
(ii) Uremic Medullary cystic disease	Variable	Older children and adolescents	Bilateral	Small coarsely scarred kidney with 1-to 20-mm cysts at corticomedullary junction	None
Simple cysts	None	Adults; rarely children	Usually unilateral	Single cyst or few cysts usually in the Cortex	None

Duplication of Ureter

- Duplication of ureter is found in about 3% of excretion urogram.
- The ureters often joins before they reach the bladder, usually in the lower third of their course and have a common ureteric orifice. Please see figure 44.4(C).
- This is *second most common congenital abnormality of upper urinary tract.*

Ureterocele

- This condition is characterized by a *cystic enlargement of the intramural portion of the ureter* caused by congenital atresia of the ureteric orifice, *(MANY PGME)* See fig. 44.6.
- Though congenital; this condition is more often **recognized in adult life**, although occasionally it may be detected in children.
- This condition is usually unilateral, but in about 10% of cases it may be bilateral.
- Females are more often affected than males.
- Excretory urogram typically show **'adder head' appearance** *(MANY PGME, UP 05)* (Figure 44.6A)

  (**NOTE:**- adder means-snake).
- **Treatment** is usually avoided, unless there are symptoms arising from infection and/or stone formation.
- *Endoscopic diathermy* incision usually treats the symptomatic ureterocele. *(MANY PGME)*
- Only in advanced unilateral cases where the kidney is almost destroyed by recurrent infection, hydronephrosis or pyonephrosis:- Nephrectomy should be considered.

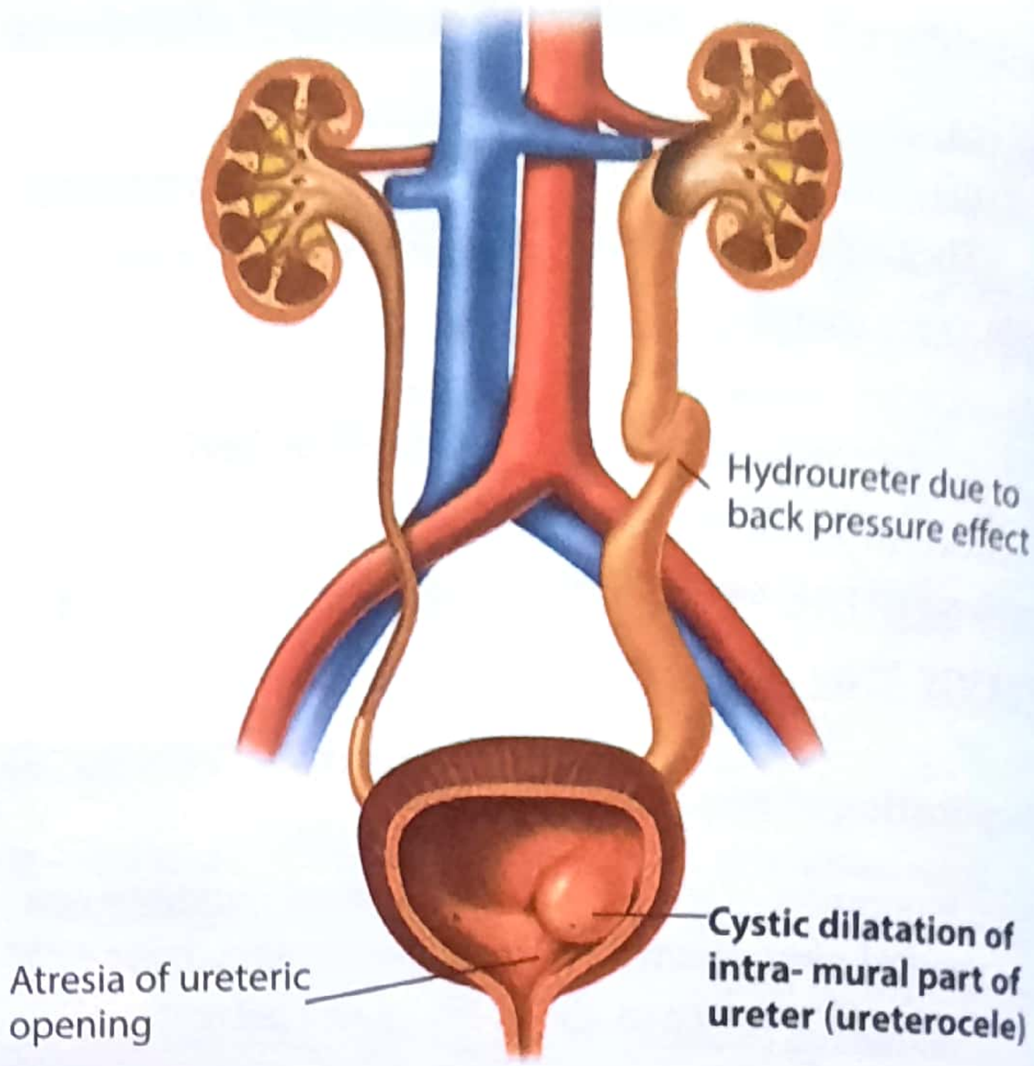

Figure 44.6B Ureterocele

JUST TO UNDERSTAND: The last part of terminal ureter passes through the urinary bladder wall; before opening in urinary bladder. This is called as intramural part of ureter. This terminal intramural part of ureter undergoes fusiform dilatation due to congenital atresia or stenosis of ureteric orifice. This is called as ureterocele. Please see figure 44.6

Figure 44.6A : Excretory urogram of ureterocele

*****

INJURIES TO KIDNEY

Renal injury is uncommon but potentially serious and often involve multi-organ trauma. Renal injuries are uncommon but when they occur, they are potentially serious.

Mechanism of Injury

- Direct blow or fall on the loin.
- Road traffic accident
- Gun shot injury or knife wound injury

KEY BOX 44.3 Organ injury scaling system			
GRADE	INJURY DESCRIPTION (pathology classification) *(AIIMS NOV. 19)*		AIS-90
I	Contusion	Microscopic or gross hematuria, urologic studies normal	2
	Hematoma	Subcapsular, nonexpanding, without parenchymal laceration	2
II	Hematoma	Nonexpanding perirenal hematoma confied to renal retroperitoneum	2
	Laceration	<1 cm parenchymal depth of renal cortex without urinary extravasation	2
III	Laceration	>1 cm depth of renal cortex without collecting system rupture or urinary extravasation	3
IV	Laceration	Parencymal laceration extending through the renal cortex, medulla and collecting system	4
	Vascular	Main renal artery or vein injury with contained hemorrhage	5
V	Laceration	Completely shattered kidney	5
	Vascular	Avulsion of renal hilum, which devascularizes kideny	5

Clinical Feature

- There may be evidence of laceration or bruising of overlying skin of the abdominal wall.
- Local pain and tenderness is always present.
- Associated fracture of lower ribs or vertebral bodies may be present.
- Closed renal injuries are almost *always extraperitoneal* except in infants *(PGME)* Chief features are:-

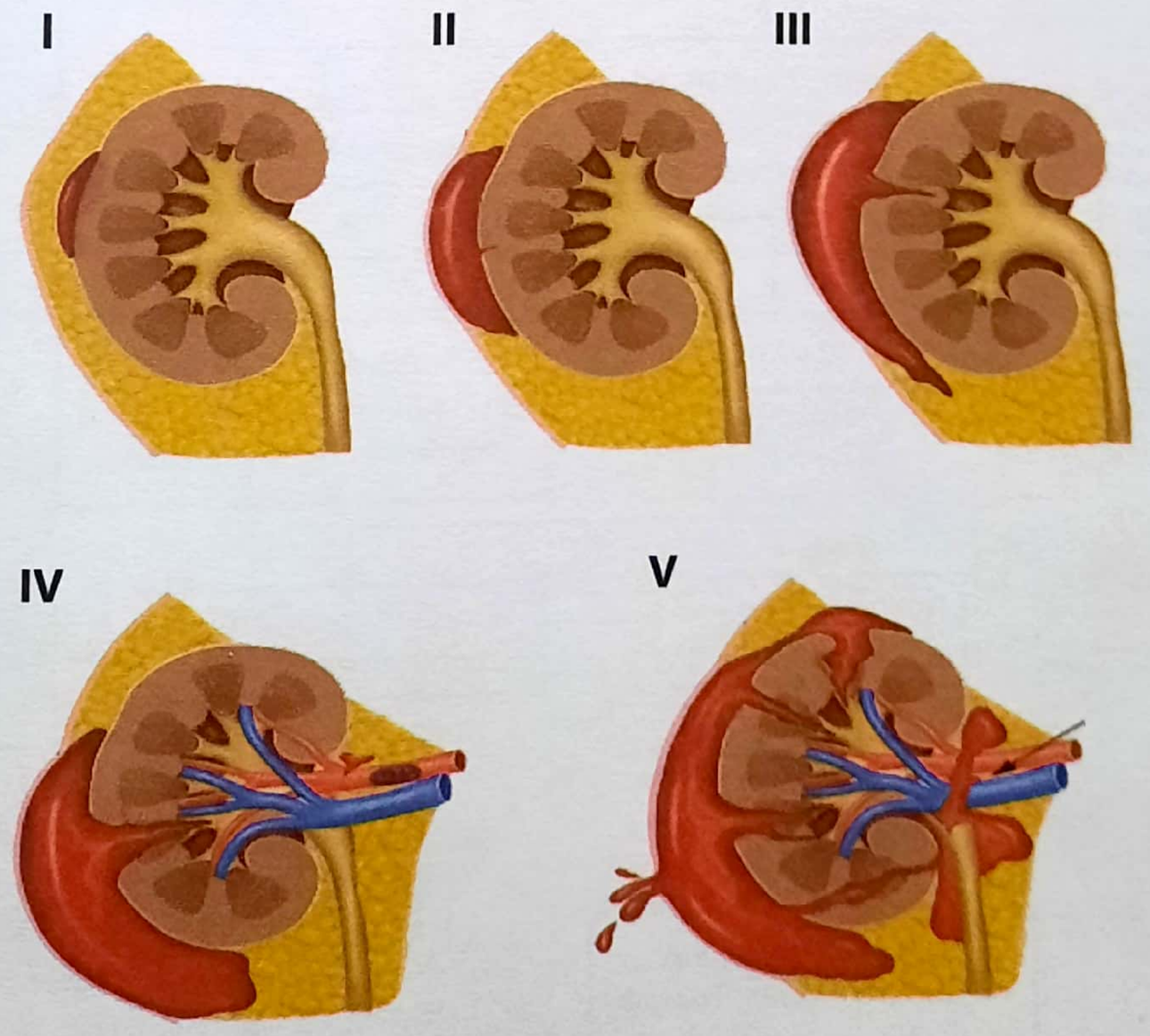

Figure 44.7 Grade of renal trauma (please read text)

1. Hematuria

Hematuria; gross or microscopic is the cardinal feature of a damaged kidney. The degree of hematuria may not correlate with severity of injury. Profuse bleeding may be accompanied by a clot colic.

2. Severe delayed hematuria

This can occur between the third day and the third week, probably due to a dislodged clot.

3. Meteorism

This is abdominal distension (after 24-48 hours of injury) probably due to retroperitoneal hematoma compressing the splanchnic nerves.

One of most common complication following renal trauma is persistent urinary extravasation with urinoma formation which is managed by urinary stenting & antibiotics. *(AIIMS NOV. 19)*

KEY BOX 44.4

Algorithm of management of blunt renal injury

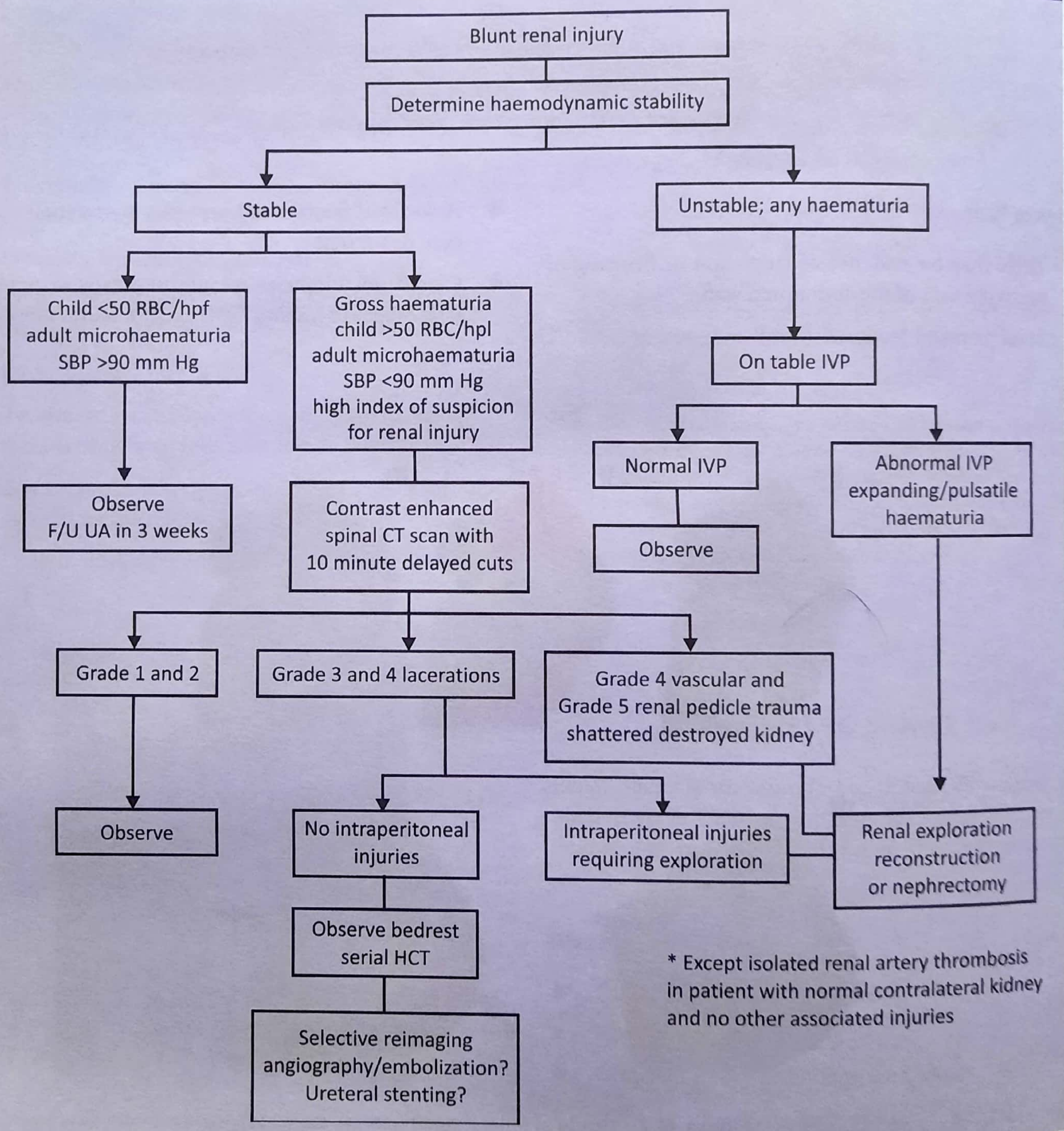

Management

Initial management is **principally conservative;** which includes:-

- Intravenous fluid and blood transfusion, if there is evidence of hypovolemic shock or continuing hemorrhage.
- Intravenous pain killers and antibiotics.
- Hourly blood pressure and pulse rate charting.
- An *intravenous urogram (IVU) should be obtained urgently* (AT 95, AIIMS 95)
  - (i) to assess the damage of the kidney
  - (ii) to show status of other kidney.

USG and CT scan can demonstrate the extent of injury.

Please go through key box 44.4 and 44.5.

Surgical Exploration

Surgical exploration is necessary in only less than 10 percent of injuries. (AI 95, AIIMS 95)

- The approach to the kidney should be **trans-peritoneal*** (AI 95)
- The operative options depend upon the findings:
  - (i) Small laceration:- Sutured
  - (ii) Laceration confined to one pole of kidney:- partial nephrectomy

KEY BOX 44.5

Algorithm of management of penetrating renal injury

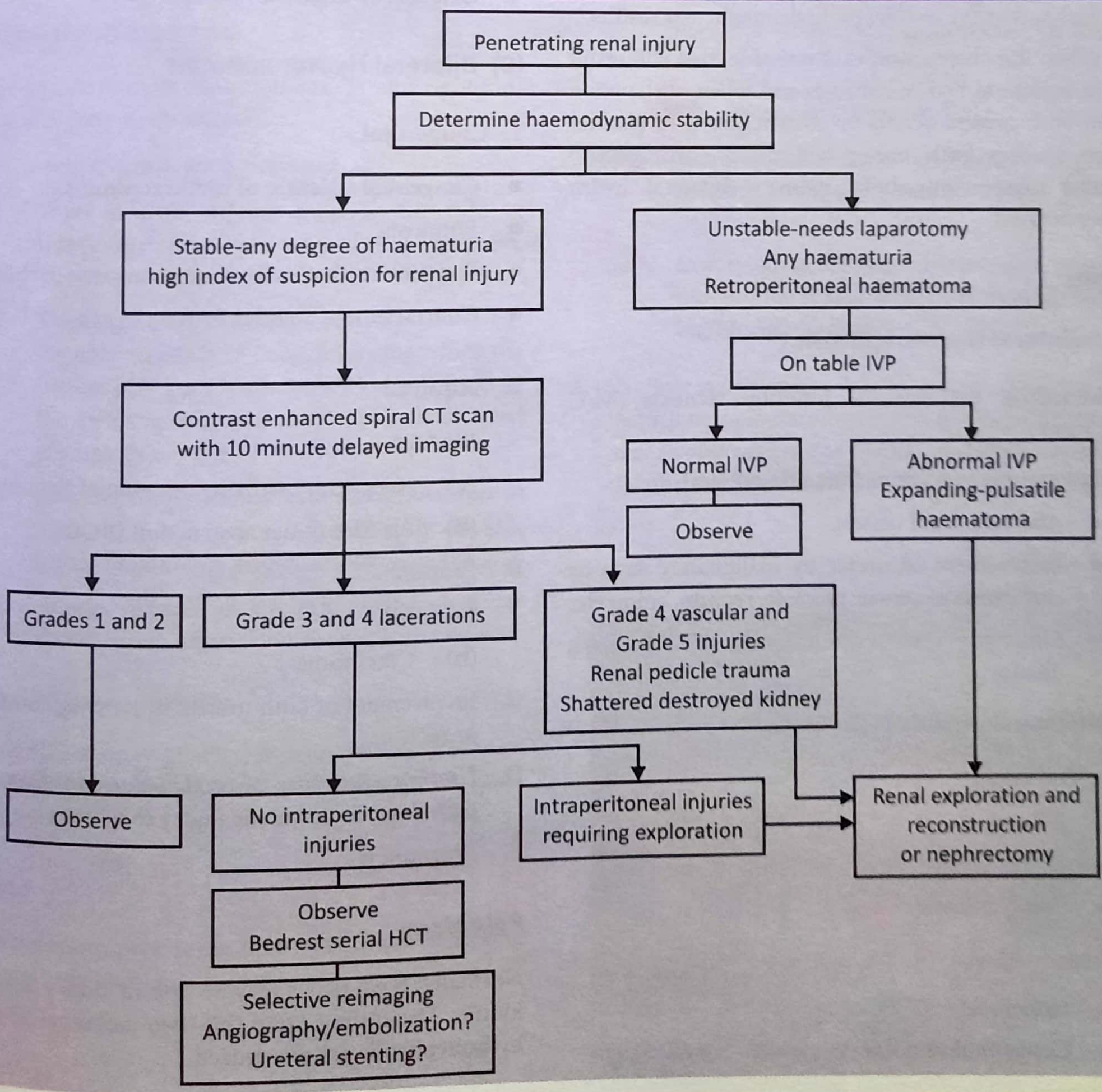

(iii) When kidney is severely ruptured or avulsed from its pedicle - Nephrectomy

TRANSPERITONEAL APPROACH* means through peritoneum ie; Reaching kidney after opening the anterior abdominal wall and peritoneum. This will help in identifying other intraperitoneal organ injury and concurrent management, and also provides better access of renal pedicle.

*****

HYDRONEPHROSIS

- Hydronephrosis is an **aseptic dilatation** of the whole or part of the kidney due to partial or intermittent obstruction of urine outflow. It may be unilateral or bilateral. (Figure 44.8)
- When there occurs obstruction in the outflow of kidney, kidney swells and hydronephrosis results.
- When the obstruction is at one side, this will result in unilateral hydronephrosis and when obstruction of both ureters occurs or obstruction is in bladder or urethra both ureter will dilate (hydroureter) and subsequently both kidneys (bilateral hydro nephrosis).

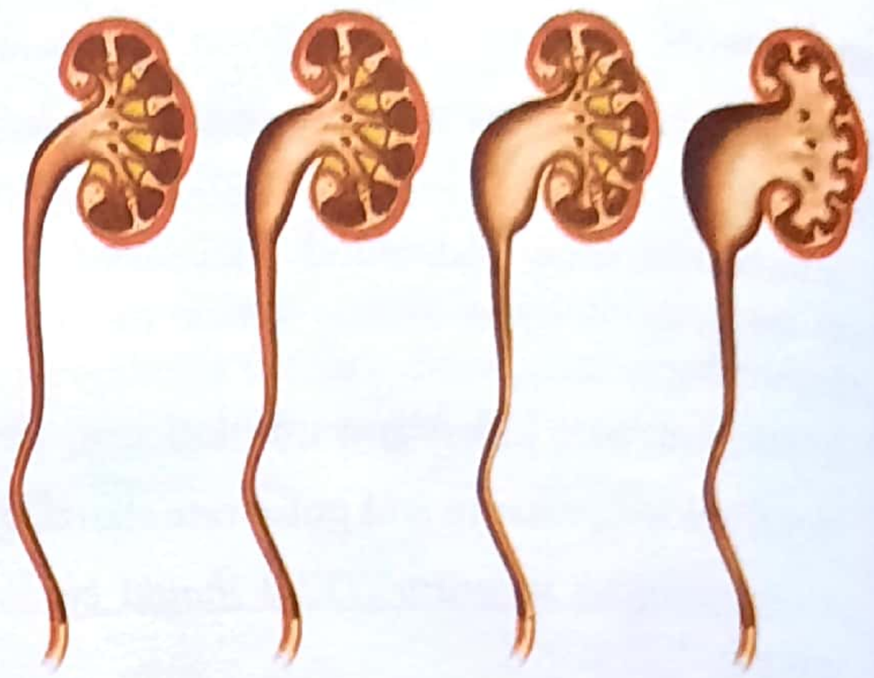

Figure 44.8 Hydronephrosis

Causes

(A) Unilateral Hydronephrosis *(MANY PGME)*

1. **Idiopathic pelviureteric junction stenosis** (M/C cause)
2. **Extramural conditions (out side ureters)**
   - Aberrant renal vessels.
   - Involvement of ureter by malignancy such as carcinoma of cervix, prostate, rectum, colon etc.
   - Idiopathic retroperitoneal fibrosis (Mondor's disease)
3. **Intermural conditions (In the wall of ureters)**

(a) Ureteric stricture

- Inflammatory
- Post operative (after ureterolithotomy)
- Post traumatic

(b) Ureteric orifice

- Ureterocele *(AMC-99)*
- Congenital stenosis
4. **Intramural conditions** (M/C cause in adults)
   - Calculus in ureter or renal pelvis.

(B) Bilateral Hydronephrosis

1. **Congenital**
   - Congenital stricture of urethral meatus.
   - Phimosis
   - Posterior urethral valve (Common cause in children)
   - Contracture of bladder neck
2. **Acquired**

A. *Bladder:*
   (a) Neoplasm involving opening of both ureters
   (b) Bladder outlet obstruction (BOO)

B. *Prostate:*
   (a) BPH
   (b) Carcinoma

C. Involvement of both ureters by *carcinoma* of cervix or rectum.

D. *Urethra* : Stricture of urethra due to inflammatory pathology or traumatic injury to urethra

E. *Pregnancy*

Pathology

Normally; renal pelvis may be with in kidney or out side kidney. Depending upon this, two pathological type of hydronephrosis are recognized.

1. Pelvis hydronephrosis

Occurs in extrarenal types of pelvis and causes dilatation of pelvis; which in turn results in dilatation calyces and subsequent renal atrophy.

2. Renal hydronephrosis

Renal hydronephrosis occurs when the pelvis is intrarenal. Rapid dilatation of pelvis and calyces occurs and renal parenchymal damage is more severe and pronounced due to pressure atrophy. See figure 44.8.

A kidney destroyed by long standing hydronephrosis is a thin walled lobulated sac containing pale, uriniferous fluid of low specific gravity.

Clinical Features

Unilateral Hydronephrosis

- The female to male ratio is about 2:1 and right kidney is slightly more affected.
- Presenting **features** are as follows:-

1. There is **dull, aching pain in the loin** of insidious onset with a sensation of heaviness. The pain worsens with excessive fluid intake.
2. **Swelling in the loin:** Some patients have swelling after an attack of colic, following which the patient may pass large quantities or urine and the swelling disappears **(Dietl's crisis)**, read key box 44.6 *(PGME MANY)*
3. The swelling presents with all the features of a kidney swelling, ie;- *It is present in the loin and is bimanually palpable and is ballottable.*
4. Attacks of renal or ureteric colic may occur due to spasm of renal pelvis or ureteric muscle.

Bilateral Hydronephrosis

The clinical features of bilateral hydronephrosis is similar to unilateral hydronephrosis and are usually due to causative factors.

Imaging

1. **Ultrasonography** is the best non-invasive imaging modality of choice.

KEY BOX 44.6

Dielt's Crisis

Pain in Loin

↓

Palpable renal lump in loin

↓

Passage of large quantity of urine

↓

Disappearance of lump and pain

2. **Intravenous urography (IVU/IVP)**
   (i) In hydronephrosis, there is gradual dilatation of major calyces (which are normally cupped) becomes, clubbed*:- ie; **clubbing of calyces** occurs. *(MANY PGME)*

   clubbed = baseball-bat like

   (ii) In advanced cases; poorly functioning renal parenchyma appears as a thin rim - rim sign *(AIIMS NOV 98)*

   (iii) In very advanced cases; the thin rim of poorly functioning renal parenchyma **may give- Soap bubble appearance.**

3. **Isotope renography:** *It is the most helpful test to establish that dilatation of the renal collecting system is due to obstruction and the* stance commonly used is Diethylene Triamine Penta Acetic acid (DTPA).

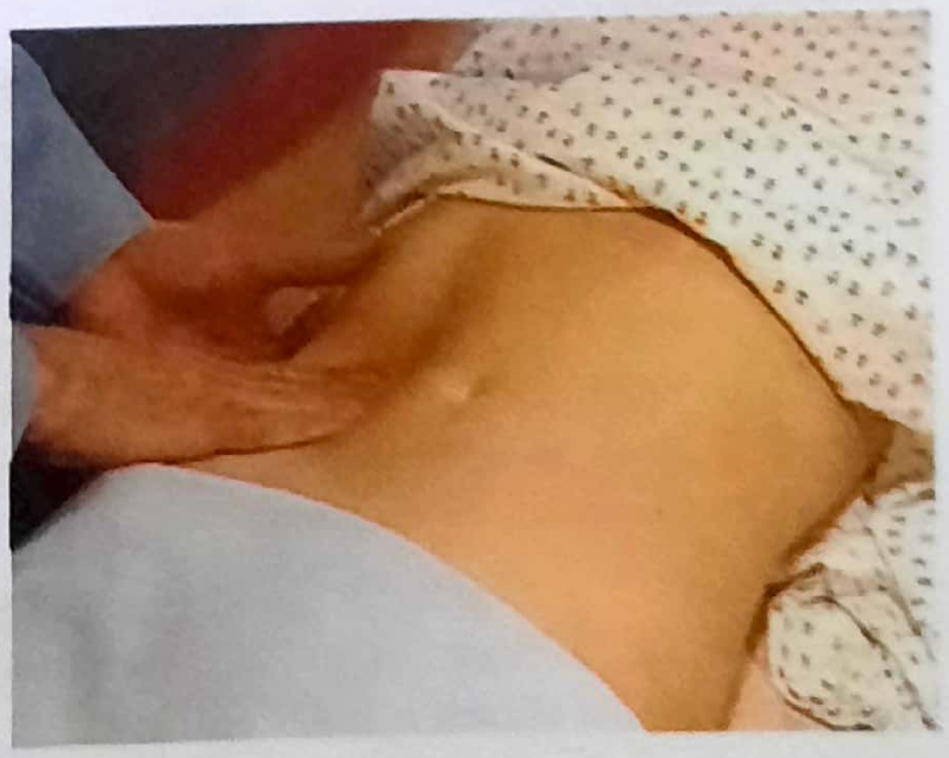

Figure 44.9 : Method of examination of a renal lump

KEY BOX 44.7

Differentiation of Renal Lump & Splenomegaly

Features	Renal Lump	Splenomegaly
INSPECTION		
Situation and extent	Loin; upwards and downwards	Left hypochondrium, towards umbilicus
Loin fullness	Present	Absent
Movements with respiration	Slightly present	Markedly present
PALPATION		
Edge	Rounded	Sharp
Notch	Absent	Present
Insinuation of fingers between lump & costal margin	Possible	Not possible
PERCUSSION		
Anteriorly	Resonant	Dull
Over the renal angle	Dull	Resonant
Ballottement	Present	Usually absent (except in huge splenomegaly)

4. **Whitaker test:** Urodynamic study combined with ureteric antegrade pyelography. (NEET) It detects subtle obstructions.

Treatment

1. The aim of treatment is preservation of renal tissue. *Nephrectomy* is considered only when renal parenchyma has been significantly destroyed.
2. **Indications for surgery are:-** recurrent attack or renal pain, increasing size of lump, evidence of parenchymal damage and pyonephrosis.
3. The *Anderson-Hynes operation* is appropriate in cases of pelvi-ureteric junction obstruction, where a reasonable thickness of functioning parenchyma remains. It is a type of pyeloplasty.
4. *Endoscopic Pyelolysis* - Disruption of the pelvi-urer teric junction by inflating a specially designed balloon is helpful to treat idiopathic pelviureteric junction obstruction.
5. *Nephrectomy-* A grossly nonfunctioning hydronephrotic kidney should be removed; provided opposite kidney is functioning.

*****

RENAL STONES

The incidence of renal stone is 1-3% in adult population.

Etiology

1. Deficiency of Vitamin A

Deficiency of vitamin A causes desquamation of epithelium. The cells form a nidus around which; stone is formed.

2. Altered urinary solutes and colloids

Dehydration leads to increase concentration of urinary solutes and tend to precipitate them.

3. Decreased urinary citrate

Citric acid tends to keep relatively insoluble calcium phosphate and calcium citrate in solution. A decrease in urinary citric acid cause stone formation.

4. Renal infection

Infection favours the formation of urinary stone. Most common organism being *Proteus* and *Staphylococcus.*

5. Urinary stasis

Obstruction in free passage of urine like in BPH, stricture urethra may cause stone formation.

6. Disturbed oxalate metabolism

Oxalates are the most common stones formed in the urinary tract. Food rich in oxalate such as spinach, tea, coffee, cola drinks and citrus fruits and juice may increase the urinary excretion of oxalate and increase the tendency for their precipitation and stone formation.

NOTE: In a normal person the dietary oxalate binds to calcium in the small intestine (Ileum) and is excreted in the feces.

In certain disease where ileum is malfunctioning (eg. Crohn's disease) or after extensive Ileal resection, calcium binds to fat and allows free oxalate to be absorbed into the blood stream; causing stone formation. (MANY PGME)

7. Hyper parathyroidism

Hyper parathyroidism should be suspected when stone are multiple and are in both kidneys and recurrent.

8. Prolonged immobilization

Due to prolonged immobilization, there is skeletal decalcification and increased calcium excretion in urine, which forms calcium phosphate calculi.

Figure 44.10: Note large left renal stone

9. Randall's plaque theory

According to Randall the earliest lesion in pathogenesis of stone formation is an erosion at the apex of one of the renal papilla and subsequently urinary salts are deposited on this; which is now called a Randall's plaque.

10. Carr's theory

Intrarenal calcific deposits or tubular debris is removed by intrarenal subendothelial lymphatics. If these lymphatics get blocked then the calcified deposits form a stone and later on erode overlying endothelium to becomes intracalyceal.

Complication

1. Recurrent infections, eg;- pyelonephritis.
2. Hydronephrosis
3. Calculous anuria
4. Malignancy:- long standing stone may cause *epidermoid carcinoma of* renal pelvis due to squamous metaplasia.
5. Chronic renal failure.

Types of Renal Calculus

(1) Radiolucent stones

- Urice Acid Stone
- Triamterene
- Indinavir
- Xanthine

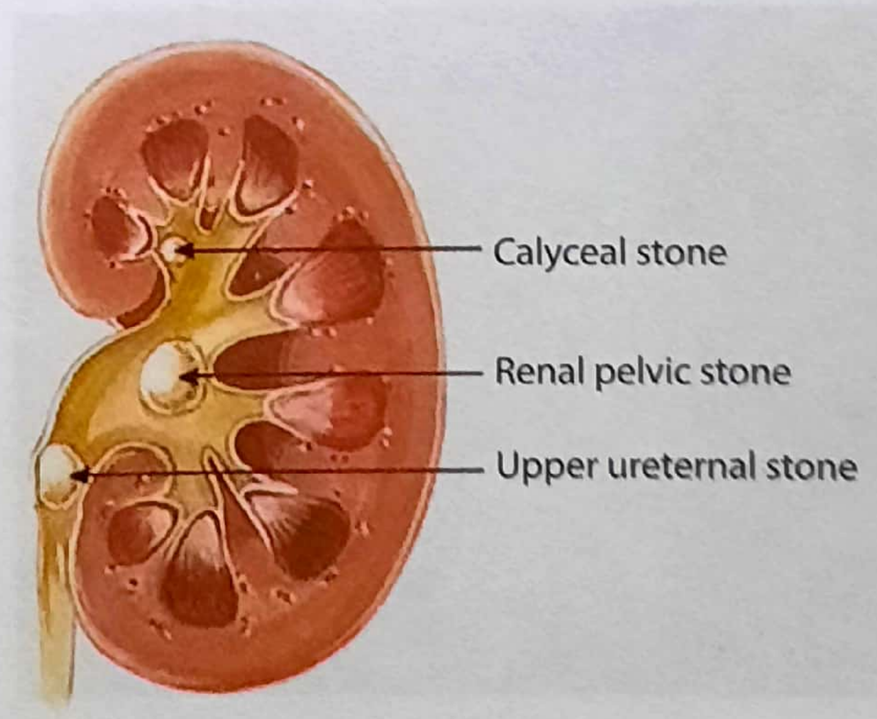

Figure 44.11: Nephrocalcinosis/stone in kidney

(2) Rest are Radiopaque

Now lets take some common stones.

1. OXalate stones

- They are the **most common** type of renal stones and accounts for 70% of all renal stones. *(MANY PGME)*
- OXalate stones are Xtremely common in kidney; ie most common type of stone.
- OXalate stones are **irregular in shape and covered with sharp projections,** which tend to cause **bleeding.** *(MANY PGME, NEET)*
- The surface of the calculus is discoloured by the pigments of altered blood.
- Most of the OXalate stones are radio-Opaque and hence can be seen easily on radiograph, *(MANY PGME)*. [Just to remember: oXalate stone, compare X with two arrows]

X = Irregular shape

↓

Sharp projection (arrow)

↓

damage to renal tissue

↓

Causes bleeding

- OXalate stones are easily seen on X-ray (ie; radioopaque)

2. Phosphate Calculus *(AIIMS NOV 01, AIIMS NOV 97)*

- Phosphate stones are formed in the **infected and *alkaline* urine.** *(MANY PGME, AI 09, 11)* (Proteus infection)
- *To remember:* Phosphate stones are formed at **high P_h** ie; in alkaline urine
- They are usually ***triple*** phosphate stones-**Calcium Ammonium Magnesium phosphate (CAM phosphate).** *(NEET)*
- The deposition of normal urinary phosphate into triple Phosphate probably results from liberation of ammonium carbonate from urea, brought about by the infecting organism; most commonly by Proteus.
- They account for about 15-20% of all renal stone.
- PhoSphate stones are large and fill most of the collecting system, forming a **Stag-horn calculus,** Fig 44.12, 44.13 *(also called as* **Struvite stone)** *(UPSC 97, NEET)*
- They are white, large and are easily seen on X-ray films.

Stag-horn; refers to a branching stony coral.

3. Uric Acid and Urate Stone

- They account for about 10% of stone.
- **Uric *acid*** stones are *formed in* ***acidic*** *urine,* *(MANY PGME)*

Figure 44.12: Staghom calculus



Figure 44.13: Large staghom calculus

- They are *very hard, smooth,* multiple, and yellow in colour.
- They may be associated with gout, however most of them are idiopathic and are associated with normal serum uric acid levels.
- Pure Uric acid stones are radiolUcent. *(NEET, AIIMS JUNE 2000, PGI85, UP 05)* ie; not visible on X-ray

4. Cystine stones

- They account for less than 3% of stones.
- They may result from an inherited defect of the renal tubule, causing loss of cystine, ornithine, arginine and lysine in the urine.
- They occur in *acidic urine* and are often multiple, *hard* and fairly radio-opaque.
- These stones are very hard & resistant to lithotripsy. *(NEET)*

5. Xanthine calculi

- These are smooth, brick red in colour and show lamel-lation on cross section.
- They are extremely rare. **Please see key box 44.4{next page}.**

6. Ammonium urate stones

- Chronic laxative abuse can result in such type of stone.

Clinical Features

1. Majority of patients with renal stone are between the age of 30-50 years.
2. The male, female ratio is 4:3.
3. **The symptoms** are variable and the diagnosis sometimes remains obscure until discovered incidently on a radiograph.

A. Asymptomatic stone

- Some stones, even large stag-horn calculi cause no symptoms for long periods during which they cause progressive destruction of renal parenchyma.
- If the calculi are bilateral, uremia may be some times the first indication of their presence.

B. Symptomatic stone

1. Pain

(a) Fixed renal pain:

It is located in ipsilateral lumbar region or hypochondrium anteriorly or both. Rarely there may be pain in contralateral lumbar region (Reno-renal reflex). Pain is typically felt at renal angle. Please see figure 44.14.

(b) Ureteric colic:

Ureter tries to get rid of calculus by increased peristasis resulting in coliky pain. *(AI 08)* Agonizing pain of sudden or gradual onset initially in the lumbar region and later radiating to groin. Pain is accompanied by vomiting, profuse sweating and strangury*.

2. Hematuria

3. Pyuria

STRANGURY: Painful and interrupted urination in drops produced by spasmodic muscular contraction of urethra and bladder. For Hindi speakers:- "Su-Su lagte to hai, par only 2-4 drop he hote hai, us se jyada nahe hotee".

Investigation

1. **Urine examination: For**
   - RBC, Pus cells, Albumin and Casts
   - Culture & sensitivity to antibiotics, if pyuria is present.

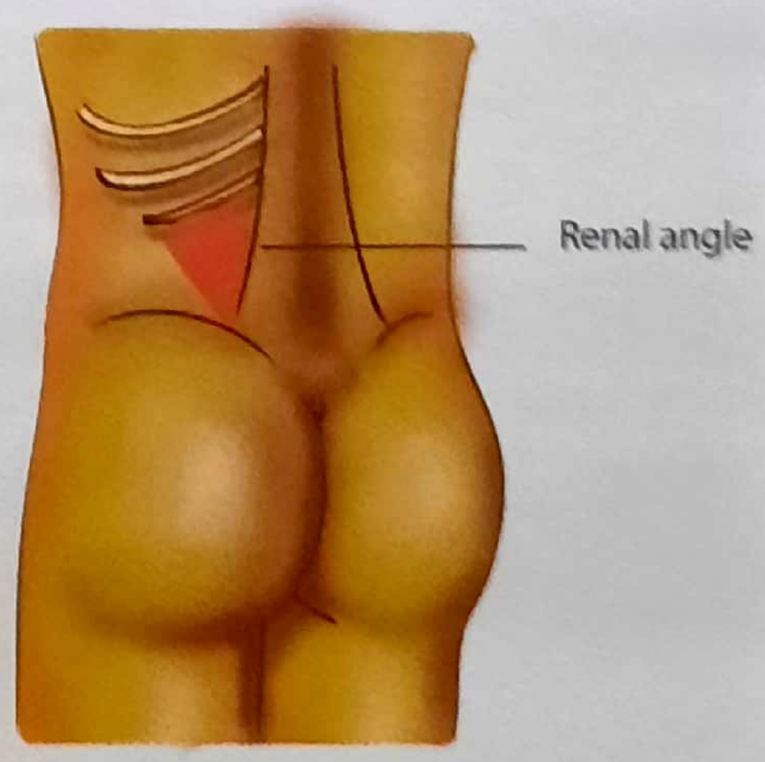

Figure 44.14: Note typical site of renal pain at renal angle

KEY BOX 44.8

Stone type	Morphology of Associated Crystals (Urine Microscopy)		Urinary Risk Factor	Clinical settings
Calcium oxalate monohydrate	Dumbbell		Hypercalciuria	Hyperparathyroidism immobilization, vitamin D excess, sarcoidosis, Cushing syndrome, high sodium intake, genetic disorders (eg. Dent disease), idiopathic, etc
			Hyperoxaluria	• Increased oxalate absorption (eg, bowel pathologies) • Primary hyperoxaluria • Excess vitamin C intake
Calcium oxalate dihydrate	Envelope (X) shaped		As outlined for calcium oxalate monohydrate	As outlined for calcium oxalate monohydrate
Calcium phosphate	Flat shaped or wedge-shaped prisms; prisms often in rosettes		• Hypercalciuria • Hypocitraturia • Urine pH > 7	• As outlined for calcium oxalate monohydrate • Distal renal tubular acidosis • Drugs with carbonic anhydrase inhibitory function (eg, topiramate, acetazolamide)
Struvite	Coffin-lid		High levels of ammonium and bicarbonate	Urinary tract infections with urease-splitting microorganisms
Uric acid	Rhomboid football-shaped; multiple forms possible; often yellow/brown		• Urine pH < 5.5 • Hyperuricosuria	Patients with metabolic syndrome, insulin resistance type-2 diabetes
Cystine	Hexagonal		Cystinuria	Genetic disorder

2. **Blood examination** : For serum calcium, phosphorus and electrolytes.

3. **Renal function tests :** Like serum urea and serum creatinine. Creatinine clearance is the effective method of determining total renal function.

4. Plain X-ray

About *90% of renal calculi are radio-opaque.* (NEET) The X-ray shows the number, size and location of all stones. The conditions, which mimic renal calculus on X-ray, are :-

(a) Gall stones: are multiple, faceted, have central translucency and peripheral density. In a lateral X-ray, they are more anteriorly placed.{note: only 10% gall stone are radiopaque; while 90% of renal stone are radiopaque}

(b) Calcified mesenteric lymph nodes.

(c) Tablets or foreign bodies in the GI tract.

(d) Phlebolith: Calcification in the walls of the veins; especially in the pelvis.

(e) Calcified tuberculous lesion in kidney.

(f) Ossified tip of 12th rib.

(g) Calcified adrenal gland.

5. Intravenous pyelography (IVP/IVU)

1. To know radiolucent or radio-opaque stones, which will cast filling defects.
2. To know function of kidneys.
3. To know any obstruction or stones in lower urinary tract.

6. Ultrasonography

Renal calculi larger than 1cm cast a specific acoustic shadow, and is useful in locating stones before ESWL.

7. CT Scan

CT scan also shows the precise location of calculi with in kidney and stone density. It also helps in distinguishing it from a clot or tumours.

Treatment of Renal Calculi

1. Conservative Management (Medical)

Calculi which are less than 0.5 cm (5mm) are likely to pass spontaneously unless they are impacted and any surgical intervention in these carries the risk of complication. The conservative management include high fluid intake, urinary alkalizers, diuresis and treatment of medical disease if present (eg: hyper parathyroidism). For renal pain diclofenac is drug of choice (KERALA 98).

2. Operative Treatment of Renal Stone

Surgical treatment

A. Open Surgery	**B. Modern methods** (Minimally invasive)
Options	**Options**
• Pyelolithotomy	• Extra corporeal Shock Wave Lithotripsy (ESWL)
• Extended pyelolithotomy	• Per Cutaneous Nephro Lithotomy (PCNL)
• Nephrolithotomy	
• Partial nephrectomy	
• Nephrectomy	

Now lets discuss surgical treatment, one by one:

A. Open surgery for renal calculi

Today in India, we still generally employ open surgical technique for removal of renal stones. In most developed countries; open surgery for renal stone is uncommon. In developed countries, most stones are treated by urologists using modern minimally invasive techniques - ESWL and or PCNL. Open surgical options are:- (depending up on location of stone in kidney)

(1). Pyelolithotomy

This is removal of stone *through an incision in the pelvis of kidney.* This is done when there is a stone in the pelvis which is extrarenal. [Note: mostly pelvis is extrarenal].

(2). Extended Pyelolithotomy

This is done when stone is situated deeply in calyx along with a stone in pelvis.

KEY BOX 44.9

Urinary tract calculi

Type	Frequency	Predisposing Factors	Urine pH	Morphology
Calcium Oxalate (most common)	70%	*Hypercalcemia* • Primary hyperparathyroidism • Metastatic neoplasms in bone *idiopathic hypercalciuria* • Hyperoxaluria; • Inherited • Intestinal diseases (Crohn's ileitis, ileal resection) • High dietary intake of green vegetables, coffee and tea • High vitamin C intake • Ethylene glycol poisoning (PGI)	Any pH	Hard, small (< 5mm), multiple stones, • Irregular, sharp Projections may lead to hematuria • Radio opaque
Phosphate calculi (mixture of calcium phosphate and magnesium ammonium phosphate	15%	Urinary infections by urea-splitting bacteria, commonly ***proteus***	Alkaline	Soft, gray-white; often large and solitary, filling the pelvi caliceal system ("staghorn calculus"); radiopaque
Uric acid (urates)	10%	Most cases occur in patients with normal serum uric acid levels Gout; frequency has decreased after allopurinol therapy	Acidic	Yellow-brown; small, hard smooth; often multiple; radiolucent - not visible on plain x-ray.
Cystine stones	3%	Cystinuria	Acidic	Yellowish; soft, waxy, small; smooth, round, multiple;
Xanthine stones	Rare	Xanthinuria		Xanthine stones are **radiolucent** (NEET)

(3). Nephrolithotomy

Nephrolithotomy means removal of stone through incision made on renal parenchyma. This is done for complex calculus branching into the most peripheral calyces.

(4). Partial Nephrectomy

It is done is cases of stone in lower most calyx associated with parenchymal damage.

(5). Nephrectomy

Nephrectomy is done only when the other kidney is functioning and the affected kidney is grossly destructed by multiple calculi or gross infection such as pyonephrosis.

B. Modern Method (Minimal invasive, Endoscopic procedure)

1. ESWL (ExtraCorporeal Shock Wave Lithotripsy)

[Extracorporeal + shock wave + Lithotripsy* = From outside the body + high energy shock wave thrown + to break the stone.]

- It has become a popular non operative method in which the stone is crushed into small piece by shock wave source placed away from the body. These small pieces are then flushed with the urine to come out of body.
- As shock waves are poorly transmitted through air, hence both patient and shock wave generator are immersed in water bath.

Figure 44.15:

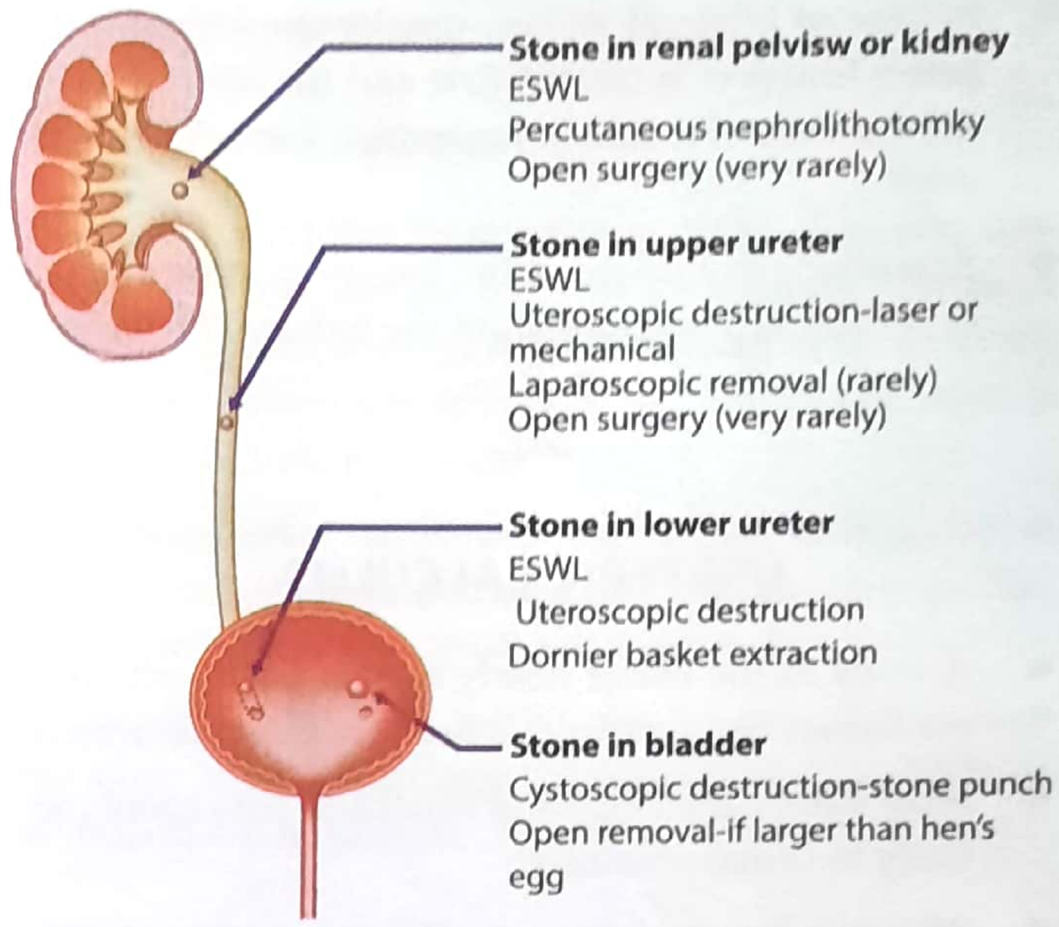

Figure 44.16: Treatment options for urinary tract stone

- Modern ESWL machine do not have a water bath; but the *fluid is only confined to the path that follows to reach the kidney.*
- For ESWL the size of stone should be less than 2.5-3cm. **For larger stone (>2.5 cms) PCNL is better option than ESWL.** *(NEET, PGME)*
- When ESWL is successful, the stone fragments are passed down to ureters → bladder → Urethra → out. Urine provides vehicle for these small, crushed and fragmented stones.
- As the stone passes through ureters, Ureteric colic is common after ESWL. *(IMP. POINT, MAY BE FUTURE PG Q)*

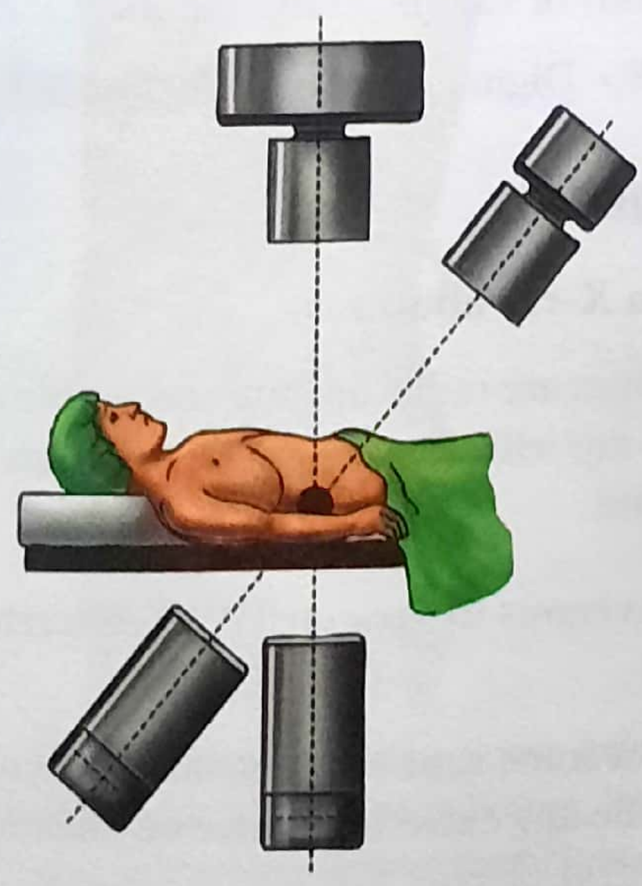

Figure 44.17: Patient taking ESWL treatment

- In addition to pain, the principal complication of ESWL is infection, because many calculi contain bacteria in their centre; and those are released when the stone is broken. Hence prophylactic antibiotics are given before ESWL.
- Most oxalate and phosphate stones are fragmented well, but result with harder stones; especially cystine stones are less satisfactory. *(IMP. POINT, AIIMS 07, 10, AI 10)*

[for Hindi speaker - ESWL makes "choora" of a stone; which is passed through bladder and urethra to out side along with urine]

*LITHOTRIPSY : The production of shock waves, by use of an external energy source, in order to crush renal calculi.

2. PerCutaneous Nephro-Lithotomy (PCNL)

- This involves placement of a hollow needle into the renal collecting system through the skin (hence:- named as percutaneous) soft tissue (muscles) of the loin, and the renal parenchyma and then inserting dilators and a nephroscope* in kidney. Small stones may be grasped under vision and extracted as a whole; while larger stones are broken and fragmented by an ultrasound probe and removed piecemeal.
- The complications are hemorrhage, perforation of the collecting system, colon and pleural cavity.
- Nephroscope is an endoscope to visualize the in side of kidney.

- In case of bilateral stones, usually the kidney with better function is treated first and the operation on the contralateral side is postponed for 2-3 months. *(PGME)*
- Exceptions to this are, if the kidney is more painful or if there is pyonephrosis in the kidney. *(IMP POINT)*

*****

URETERIC CALCULUS

- A stone in the ureter nearly always has its origin in the kidney from where it is dropped down in ureters.
- Most stones are single and small and pass spontaneously in urinary bladder.
- All stones less than 5 mm in diameter and most stone with size 5-7 mm passes spontaneously into bladder, other stones which are more than this *size* may get impacted in the ureter. Sites of impaction is given in fig. 44.15, please read it carefully.

Clinical features

Symptoms

1. Ureteric colic

Ureteric colic* is usually the most common symptom of ureteric stone *(AIIMS 91)*.

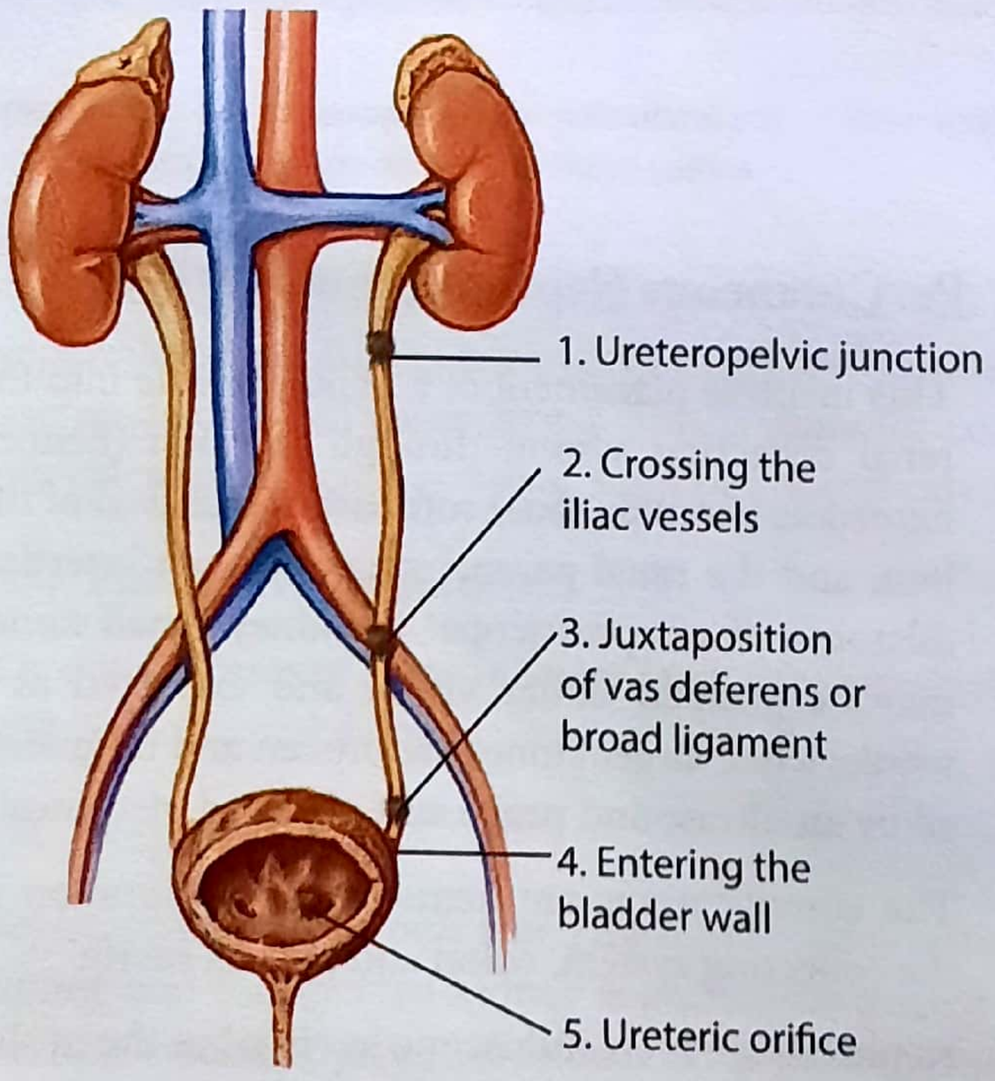

Figure 44.18: Sites of impaction of ureteric stone

KEY BOX 44.10

Sites of impaction

1. Pelvi-ureteric junction.
2. Crossing of the iliac artery.
3. Juxtaposition of vas deferens or broad ligament
4. Entrance in bladder wall
5. Ureteric orifice

The site of pain depends upon the position stone in ureter, please see key box 44.10 & 44.11 and figure 44.19.

2. Hematuria

It is usually microscopic and lasts for day or two. Profuse bleeding is uncommon.

COLICKY PAIN: A colicky pain occurs when the muscular wall of a hollow tubular organ is attempting to expel content in the tube. A Colicky pain appears suddenly and it goes off as suddenly as it came.

Usually four types of colicky pain are seen in surgical practice:-ureteric colic, biliary colic, intestinal colic and appendicular colic. *(AI 08)*

Friends! Some where you may get written 'renal colic' but it is a misnomer because kidney is not a tubular structure.

Abdominal Examination

- Tenderness and some rigidity over the course of the ureters.
- Some times patient may present with paralytic ileus.
- Testis may get retracted due to cremasteric spasm.
- A Stone impacted in lower 1/3 of ureter can rarely be felt on digital rectal examination (*DRE = PR examination) or vaginal examination.
- DRE = Digital rectal examination/PR examination.

Investigations

1. Plain X-ray abdomen

Most stones are radio-opaque and visible on a plain film. Plain X-ray will show site and size of an impacted ureteric stone.

2. Intravenous urography (IVU) /Excretory urography (EU)

During & some times after an attack of colicy pain, there will not be any excretion of dye on affected side.

But late radiographs, taken up to 36 hours after injection of contrast dye, may show dilatation of ureter up to the

KEY BOX 44.11	
Position of stone *(NEET)*	**Site of Pain**
• At PUJ* or upper ureter	Pain radiates to the testicles
• At middle of the ureter (ie.; at crossing of gonadal vessels and ureter	Pain is referred to Mc Burney's point on the right side resembling appendicitis and on left side simulates diverticulitis
• At lower ureter or at pelvic brim	Pain is referred to inner of thigh, groin
• In the intramural ureter	Strangury (painful & fruitless desire to micturate

PUJ = Pelvi-ureteric junction.

obstructing calculus and a radiolucent uric acid stone may give a filling defect in the contrast media.

3. CT scan and Ultrasonography

Treatment

(i) Treatment of Pain

NSAIDs like diclofenac, Piroxicam and indomethacin are first line of treatment for ureteric colic (pain).

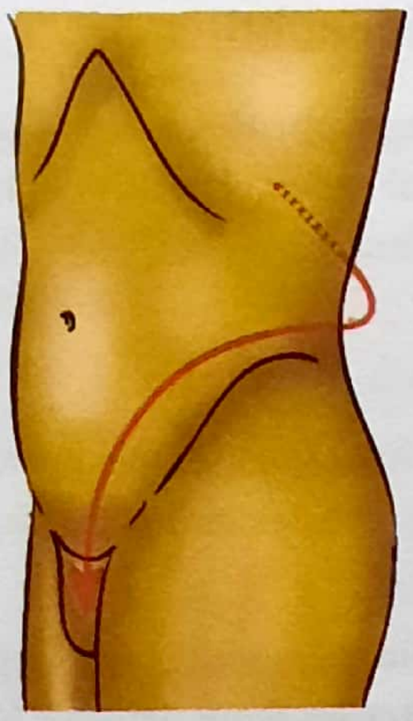

Figure 44.19: Ureteric colic radiates down from renal angle, along a line parallel to inguinal ligament, into base of the penis, scrotum or the inner site of thigh/ labia majos (depending up on impaction of stone; see key box 44.11)

(ii) Removal of Stone

A. Conservative Treatment

Expectant treatment is appropriate for small stones, (between 5-7 mm) that are likely to drop down in bladder and pass spontaneously. Repeated X-ray is taken every 6-8 weeks, which will tell about the descend of stone is ureter and it's change in size.

Conservative treatment should be abandoned if there is increase in size of stone or if the stone is impacted and there is recurrent attacks of colicy pain.

Surgical treatment should also be considered when the stone is causing complete obstruction or is too large to drop down in bladder.

Now lets discuss surgical treatment → Endoscopic removal; Open surgical removal

B. Surgical Treatment

1. Endoscopic/Instrumental removal

Options depend up on location of stone in ureter; kindly see figure 44.16 page 813

(a) **Push bangs:** A stone that is lying in upper 1/3 or middle l/3 of ureter is pushed back in kidney by a ureteric catheter. The repositioned calculus in kidney is secured by a J stent, which is later removed by ESWL.

(b) **Ureteroscopic stone removal** *(UPSC 09)*: A ureteroscope is a long endoscope which can be passed through urethera → Bladder → into ureter → hold the stone → takes out the stone.

Ureteroscopic removal is primarily used for impacted stone in lower 1/3 of ureter.

(c) **Dormia basket:** Endoscopic stone removal with dormia basket is ideal for stones in lower 1/3 of ureter ie., 5-6 cm from the ureteric orifice *(JIPMER 85)* [note - length of ureter is about 25 cm]

(d) **Ureteric meatotomy:** Stones are often lodged in the intramural part of ureter (ie; at ureteric orifice), careful endoscopic incision at ureteric orifice by a diathermy knife* enlarges the opening and frees the stone, which can then be taken out through cystoscope**.

Diathermy knife - a knife which cuts, when heated.

Cystoscope is an endoscope used to visualize the interior of urinary bladder]

2. Open Surgery

Ureterolithotomy

Ureterolithotomy means opening ureter by making an incision on ureter and extracting the stone, and then closing the ureter by simple suturing.

The incision made on ureter must be appropriate for position of stone, eg:-

- Loin approach for stones in the upper third of ureter.
- Access to mid-ureteric stones is through a muscle cutting iliac fossa incision.
- Pfannenstiel or iliac incision for lower third of ureters.

*****

KIDNEY INFECTION

Etiology

Renal infection arise in the following ways.

Ascending infection *(AI 93)*

From the lower urinary tract is the ***most common route*** and is most likely to occur *when there is vesico-ureteric reflux*. Urinary, stasis and the presence of calculi are common contributory factors. *(MANY PGME)*

KEY BOX 44.12
Vesico-ureteric Reflux:
Under normal circumstances, the vesico ureteric junction allows urine to enter the bladder but prevents urine from regurgitating into the ureter, particularly at the time of voiding. In this way, the kidney is protected from high pressure in the bladder and from contamination by infected vesical urine. When this valve is incompetent, the chance for development of urinary infection is significantly enhanced and pyelonephritis is then inevitable. With few exceptions, pyelonephritis:- acute, chronic or healed is secondary to vesicoureteral reflux.

Hematogenous infection

Hematogenous infection from tonsil or carious teeth, or from skin infection, particularly boil or a carbuncle.

Bacteriology

E.coli and other gram negative organism are commonly responsible. Other organisms may be *Streptococcus fecalis* and *Proteus species.*

Pathogenesis

Infection ascends from the bladder to the kidney

↓

Pyelonephritis

↓

Bacteria invades renal parenchyma (from medulla to cortex)

↓

Abscess formation rupturing into perinephric space tracking may occur through the Gerota's fascia into:

1. Psoas or transversalis muscles
2. Anterior peritoneal cavity
3. Subdiaphragmatic space
4. Pelvis

Common renal infection are:-

1. Acute Pyelonephritis

The term 'Pyelo nephritis' means inflammation of the kidney and renal pelvis. [Pyelo+nephsos+itis= Pelvis + kidney + inflammation]

Etiology

- Ascending infection: Acute pyelonephritis is more common in females and is more common on right side.
- In *most of the cases* acute pyelonephritis is due to ***ascending infection from urinary bladder.*** *(MANY PGME)*
- Acute pyelonephritis is quite common after marriage ***(honeymoon pyelitis)*** and during second trimester of pregnancy.

- In majority of cases pyelonephritis is associated with vesico-ureteric reflux.
- *In children most common cause of recurrent urinary tract infection is vesico-ureteric reflux.* (AI, AIIMS, PGI)

For vesico-ureteric reflux kindly read box 44.12.

Clinical Feature

- Constant ache over affected kidney is most frequent complaint. *Pain is mainly caused by distension of renal capsule due to edema.*
- Prodromal symptoms eg; headache, lassitude*, nausea, vomiting are common complaints. (lassitude* = tired)
- Rigor along with high temperature is common feature.
- Increased urinary frequency, urgency, nocturia, burning micturition are common features.

Treatment

Treatment is generally symptomatic.

- Bed rest and plenty of oral liquid.
- Urine should be sent for microscopic examination, culture and sensitivity test.
- Pain and fever should be controlled by analgesics and antipyretic. Broad spectrum antibiotics should be started immediately, even when culture and antibiotic sensitivity reports are awaited. Once the culture and sensitivity report arrives, specific antibiotic should be started in high dose for 10-14 days.

(2). Emphysematous Pyelonephritis

- Severe renal parenchymal infection with accumulation of gas in tissue.
- Mostly seen in uncontrolled diabetics with or without uninary tract obstruction
- Most common causative organisms are E. coli and Klebsiella.
- It is a potentially fatal condition.
- May present with mild abdominal pain to septic shock in severe cases.

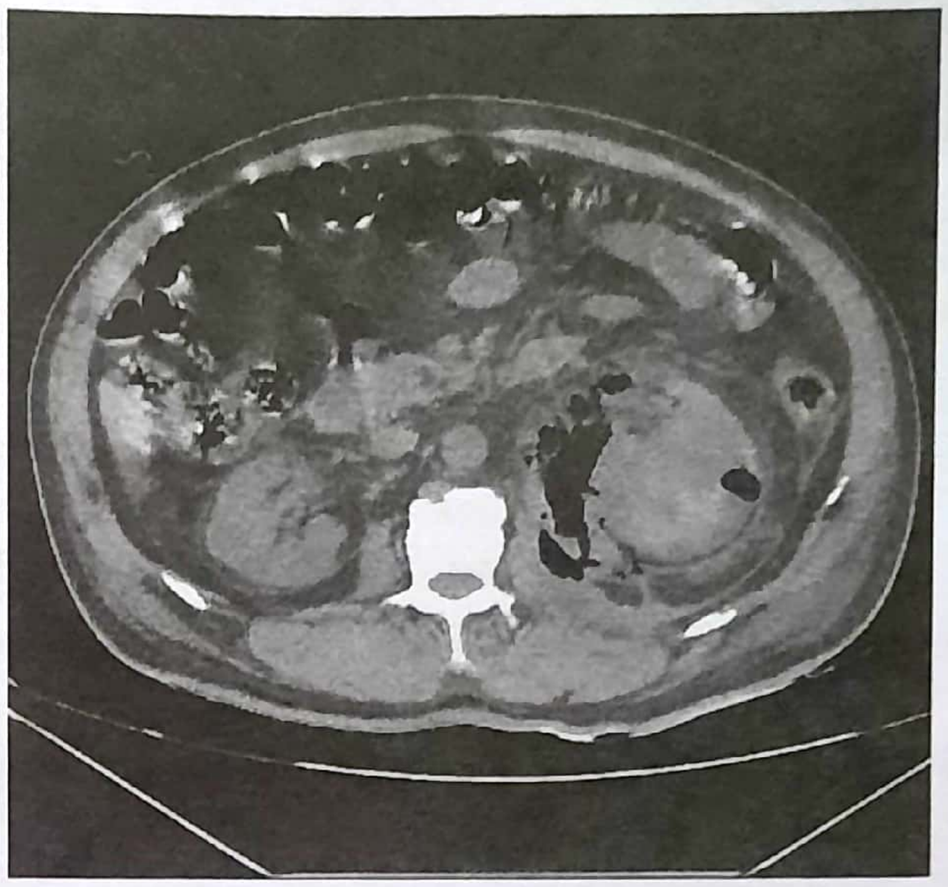

Figure 44.20: Emphysematous pyelonephriti

- Treatment of choice is immediate nephrectomy after appropriate resuscitation.

(3). Chronic Pyelonephritis

- The term chronic pyelonephritis is misleading and should be more correctly named as 'reflux nephropathy', because *it is* ***almost always associated with vesico-ureteric reflux.*** (NEET) *(Please see box* 44.12)
- There is interstitial inflammation and scarring of the renal parenchyma with a patchy distribution.
- The condition is almost three time more common in females than males, between 40-60 years.
- Microscopically - Thyroidization & fibrosis of kidney.
- Some patients presents with end stage renal failure but in majority chronic lumbar pain, increased urinary frequency and dysuria are common.
- Hypertension is present in 40% of cases.
- Constitutional symptom like lassitude*, malaise*, anorexia, nausea and headache are complaints in about 30 percent cases. (*malaise = feeling of uneasiness)
- **Treatment** is difficult and is aimed at eradicating the contributory factors. Surgical treatment is only indicated when the disease is confined to one kidney.

(4). Xanthogranulomatous Pyelonephritis

- It is a form of chronic pyelonephritis, seen most commonly in middle aged ***diabetic women,*** (PGME) and rarely in children.
- The disease is usually unilateral and is associated with long standing obstructing nephrolithiasis.
- The symptoms are vague, but similar to those of acute pyelonephritis. Some patients may present with a renal lump often indistinguishable from tumour. (IMP. POINT)
- The most common bacteria associated is **proteus**. (NEET)
- Nephrectomy is usually the treatment of choice, through partial nephrectomy may be sufficient for focal disease.
- After nephrectomy, the kidney is sent for histopathological examination and presence of *foamy lipid laden macrophages will confirm* the diagnosis (PGME). (Figure 44.21)

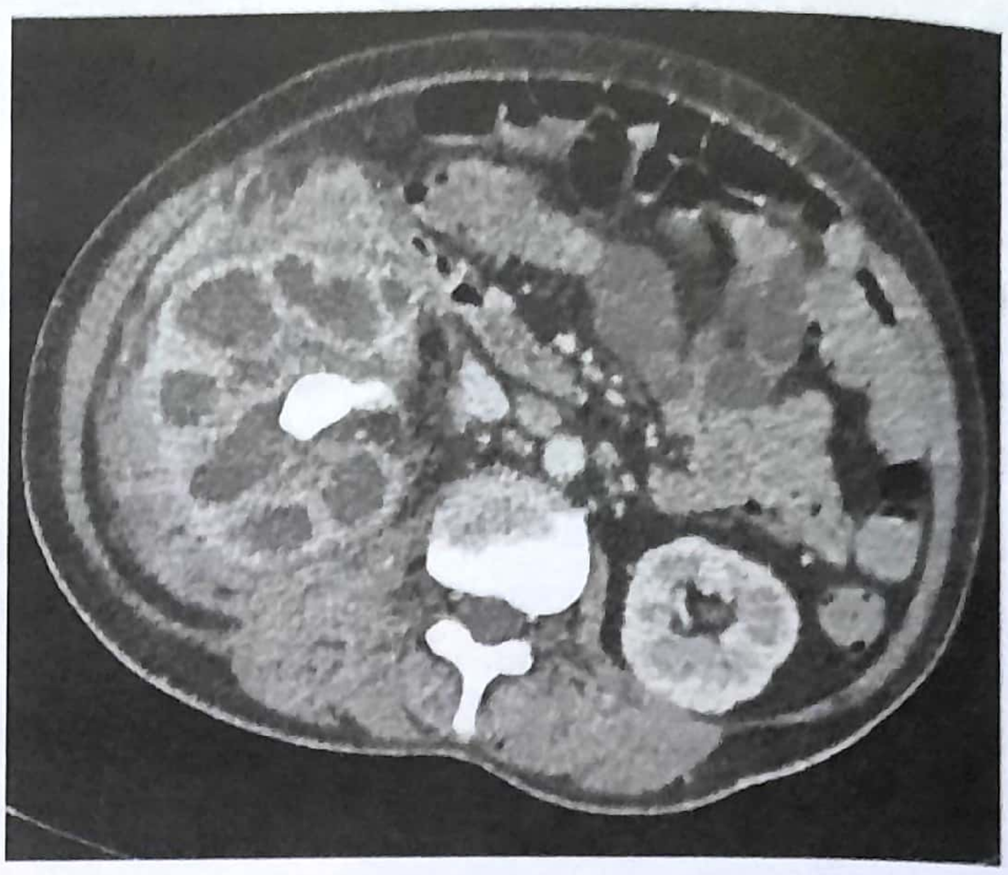

Figure 44.22: Xanthogranulomatous pyelonephritis on CT

(5). Renal Abscess (Renal carbuncle)

Kidney abscess is a collection or purulent material confined to renal parenchyma.

Etiology and Pathogenesis

- During the past two decades gram -ve organism have been implicated in the majority of patients with renal abscess. Hematogenous renal seeding by gram -ve organism may occur, but this is not likely to the primary pathway for gram -ve abscess formation.
- Ascending infection associated with tubular obstruction from prior infection or calculi appears to be the primary pathway for establishment of gram -ve abscess.

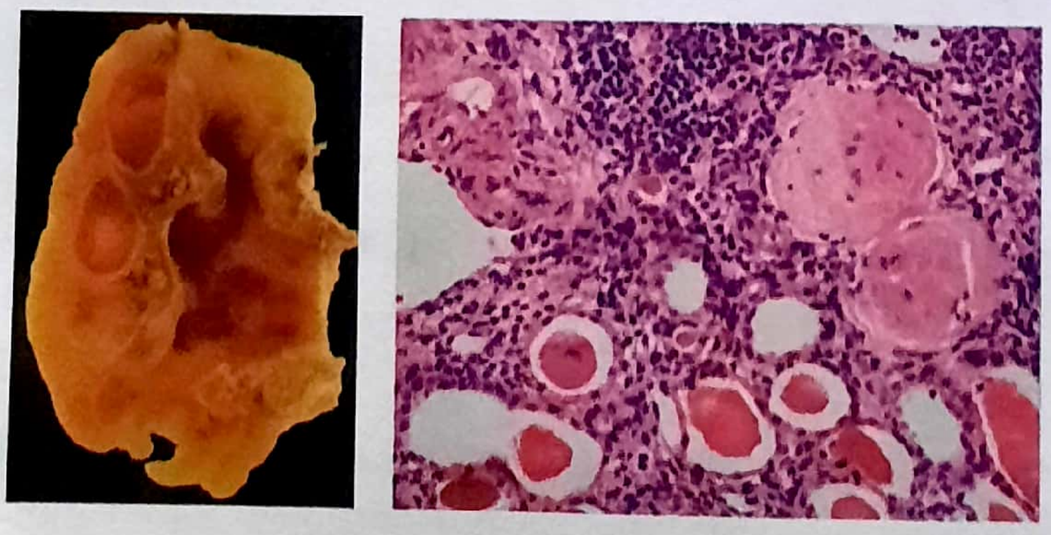

Figure 44.21: Histopathology of Xanthogranulomatous pyelonephritis

- Abscesses that form in the *renal cortex (carbuncles)* probably arise from hematogenous spread. Cortico medullary abscesses in contrast are more often caused by coliform bacteria in conjugation with underlying urinary tract disease.

Predisposing factors

The risk factors for abscess formation include:-

1. Nephrolithiasis (60%)
2. Urinary tract abnormalities
3. Surgery on urinary tract
4. Trauma
5. Diabetes mellitus

Clinical presentation

The presentation of renal abscesses is quite non-specific. Fever, chills and flank pain are typical presenting signs. Nausea, vomiting, weight loss, malaise are common.

Symptom of cystitis, costovertebral angle tenderness, and abdominal tenderness-may be present.

Diagnosis

1. Laboratory

- Marked leukocytosis
- Blood culture usually positive
- Urinalysis may show pus cells and bacteria.

*2. Plain X-ray KUB**

Obliteration of corresponding psoas shadow, scoliosis, with a concavity of the curve facing the affected kidney and renal fixation on inspiratory and expiratory film may be present.

KUB= Kidney, Ureter, Bladder.

3. USG

It is quickest and least expensive method to demonstrate a renal abscess. An echo free or low echo density, space occupying lesion with increase transmission is found at the abscess site.

4. CT Scan

CT with or without contrast enhancement is the *diagnostic procedure of choice for renal abscess.*

Management

- Appropriate antibiotic therapy constitute the first step in therapy of renal abscess.
- Although surgical drainage has been recommended in the past, several studies have shown that IV antibiotics begun early enough may be sufficient management.
- If no favorable clinical response appears even after 48 hours of antibiotic therapy, percutaneous (CT or USG guided) aspiration and drainage should be employed.
- Follow up imaging is necessary to documents resolution of the abscess. If the abscess still does not resolve, then open surgical drainage becomes the definitive treatment.

(6). Infected Hydronephrosis & Pyonephrosis

- Infected hydronephrosis is bacterial infection in a preexisting hydronephrosis.
- The term pyonephrosis refers to hydronephrosis associated with suppurative destruction of parenchyma of the kidney, in which there is total or near total loss of renal function.
- Rapid diagnosis & treatment of pyonephrosis are essential to avoid permanent loss of renal function and to prevent sepsis.
- Kidney is converted into a multilocular sac containing pus or purulent urine.

Clinical Presentation

- The patient is usually very ill, with high grade fever with chills, flank pain and abdominal tenderness.
- **The classical triad** of symptoms of pyonephrosis is **anemia, fever and a swelling in the loin.**
- A previous history of UTI, calculi or previous urological surgery are commonly present.

Investigation

1. Urine culture

The bacterial pathogen can usually be isolated except in those cases where the ureter is completely obstructed.

2. Radiology

Excretory urography shows a poorly or non-functioning kidney in about 50% cases.

3. USG

It will show a dilated collecting system, with dependent echoes suggesting of the accumulate of purulent sediment.

Management

- Appropriate antibiotics therapy combined with drainage of purulent material is mainstay of treatment.
- Drainage can either be transurethral with a ureter drainage catheter or percutaneous drainage via nephrostomy tube (percutaneous nephrostomy* see below).
- If pus is too thick to be aspirated through a large percutaneous nephrostomy (described below), it may then become necessary to consider open nephrostomy.
- **Nephrectomy** : If pyonephrosis with non functioning kidney is present and function of the other kidney is good then nephrectomy should be done.

Percutaneous Nephrostomy (PGI 2010)

Passage to pelvicalycial system through percutaneous route with a tube stent or cathater.

Indication

1. Urinary diversion — if kidney could not be accessed through lower urinary tract a double J stent can't be placed.
2. Calculus — > 2.5 cm/resistant to ESWL
3. Antegrade radiography.

4. Tumor resection and chemotherapy.
5. Treatment for renal cysts, fungal bezoars, fibroepithelial polyps.
6. Access for other procedures — benign stricture dilatation, antegrade ureteral stent placement, stone retrieval, pyeloureteroscopy, endopyelotomy.

(7). Perinephric Abscess

Perinephric abscess are collection of purulent material within the perinephric space, which lies between the kidney and Gerota's fascia. If the abscess extend beyond the Gerota's fascia, it becomes a paranephric abscess.

Etiology and Pathogenesis

- Renal abscess can rupture out into the perinephric space and this probably represents the primary way in which perinephric abscess develop. As a result, the bacteriology resembles that of renal abscess.
- Ascending aerobic gram -ve enteric infection *(E.coli)* is more common than *Staphhylococcus* infection from hematogenous spread.
- Factors that predispose to development of renal abscess, such as urinary stasis or obstruction, calculi, neurogenic bladder and diabetes also predispose to perinephric abscess formation.

Clinical Presentation

- Patient presents with fever with chills, flank pain and dysuria. These symptom will often been present for more than one week before presentation.
- **On physical examination :** Abdominal or costovertebral angle tenderness, a flank mass with overlying skin erythema may be present.

Investigation

1. **Laboratory: Leukocytosis**
2. **Urinalysis**

Normal in 25% cases otherwise it generally shows pyuria, proteinuria with hematuria being rare.

- Urine culture identified the infecting pathogen in one third cases.
- Percutaneous aspiration of the abscess content* under ultrasound/CT guidance allows for absolute identification of the infecting organisms.

3. **Radiology**

Plain X-ray is normal in 40% cases with perinephric abscess. Findings are:- missing psoas shadows, apparent renal masses, absent renal outlines, calculi, retroperitoneal gas, reactionary scoliosis with the concavity towards the abscess, elevation and immobility of the diaphragm on the affected side.

(i) *IVP (Intravenous pyelography)*: Normal in 20% of cases with perinephric cases findings are, decrease excretion of the affected side, renal displacement, calyceal stretching or calyactasis, abnormal or obliterated renal outline and renal calculi.

(ii) *Ultrasound:* It is less sensitive than CT scan.

(iii) *CT:* is much sensitive & gives excellent anatomic details.

Management

- Antibiotics therapy combined with abscess drainage is the mainstay of the therapy. Drainage can be of two types:

(i) *Percutaneous drainage* - Under ultrasound or CT guidance of perirenal collection.

(ii) *Open surgical drainage* - It is indicated if the abscess cavity is large and filled with thick purulent material and patient's clinical course worsen or does not improve following percutaneous drainage.

(iii) *Nephrectomy* - It should be done, if kidney is non-functioning and severely infected.

(8). Renal Tuberculosis

- In India genitourinary tuberculosis is now comparatively rare.
- Most common site of genitourinary tuberculosis is kidney.
- Tuberculosis of urinary tract **almost always arise from hematogenous infection from a distant focus** (NEET) usually from the lung or lymph node (AI 93), however the primary lesion often remains unrecognized.
- The lesion are usually confined to one kidney at renal papilla (PGI 86, JIPMER 81).

Figure 44.23: X-ray of patient with renal stone in a patient with renal tuberculosis

- Renal tuberculosis is usually confined to one kidney and is more common on the right side.
- It is common is early adult life, between 20-40 years and rare in childhood and old age.
- The disease is more common in males.
- It is often associated with tuberculosis of bladder and tuberculous epididymo-orchitis in males.

Clinical Features

Constitutional symptom, such as evening pyrexia, weight loss is usual. Classical features of renal tuberculosis are:-

1. Urinary Frequency

It is often the ***earliest symptom*** *(NEET, AIIMS 78, AMU 88)*, both diurnal (day time) and nocturnal frequency is increased.

2. 'Sterile' Pyuria *(PGI, DEC 96):*

The patient passes pale and slightly opalescent urine. The urine shows pus cells but shows no bacteria on routine culture (hence - 'sterile' pyuria).

3. Painful micturition

This is due to tuberculous cystitis, the patient complains of suprapubic pain and burning micturition.

4. Hematuria

Painless hematuria is present in 5 % cases.

5. Renal pain is usually minimal.

Investigation

1. **Urine examination** will show 'sterile' pyuria
2. **Plain X-ray abdomen** shows calcification in renal area (pseudocalculi)
3. **Intravenous urography (IVU) -**
   It is helpful in detecting morphological changes in kidney due to tuberculosis. There may be evidence of calyceal stenosis and hydronephrosis.
4. **Cystoscopy -**
   Cystoscopy means visualization of urinary bladder by an endoscope. There may be tubercles ulcer around the ureteric orifice and reduced capacity of the bladder (systolic bladder). *Bladder wall is scarred, fibrosed and is also called as* **'thimble bladder'.** *(NEET, PGI DEC 97).*

- Contraction of the fibrosed ureters pulls the bladder and ureteric orifice upward and its mouth wide opens - so called **Golf-hole** ureteric orifice *(KARN 94)*
- CT - most sensitive in detecting early renal TB.

KEY BOX 44.13

Tuberculosis of Kidney

- **Tuberculoma**
  - Calcification → Cement Kidney
  - Tuberculous abscess
- **Tuberculous pyonephrosis**
- **Perinephric abscess** (due to extension of pyonephrosis or abscess)
- **Putty Kidney** (when kidney is replaced by caseous material)

Treatment

- The mainstay of treatment is a full course of ATT (Antitubercular treatment). If complication has occurred; they should be dealt accordingly.

Please go through key box 44.13 (page 821) before concluding this topic.

*****

WILMS' TUMOUR
(NEPHROBLASTOMA)

This is a very important topic :- For final prof as well as PGME, you will definitely get question on it.

- Wilms' tumour is the most common intra-abdominal tumour of childhood and contains epithelial and connective tissue elements arising from embryonic nephrogenic tissue.
- It is most common **between the age 1-4 years.** *(PGME)*
- Male and female children are equally affected and disease is ***bilateral in about 8% cases.***

Genetic features *(PGI DEC 01, AIIMS FEB 97)*

- All bilateral and approximately one third of unilateral wilm's tumours are hereditary.
- Many patients have *deletions in short arm of chromosome 11,* including loss of cancer suppressor gene WT-1. *(IMP. POINT; MAY BE FUTURE PGMEE Q)*
- Hereditary Wilms' tumour is associated with aniridi

Aniridia: congenital absence of all parts of iris.

- Most *significant associated congenital anomalies* constitute **'WAGR'** syndrome i.e; Wilm tumour, Aniridia, Genitourinary abnormalities (horse shoe kidney) and Retardation (mental) *(MANY PGME)*

Pathology

- The tumour usually starts at one pole of the kidney.
- Tumour tends to be large and may breach capsule with invasion of perinephric fat, adrenal gland, renal vein.
- The cut surface of the tumour is greyish or pinkish white in colour.

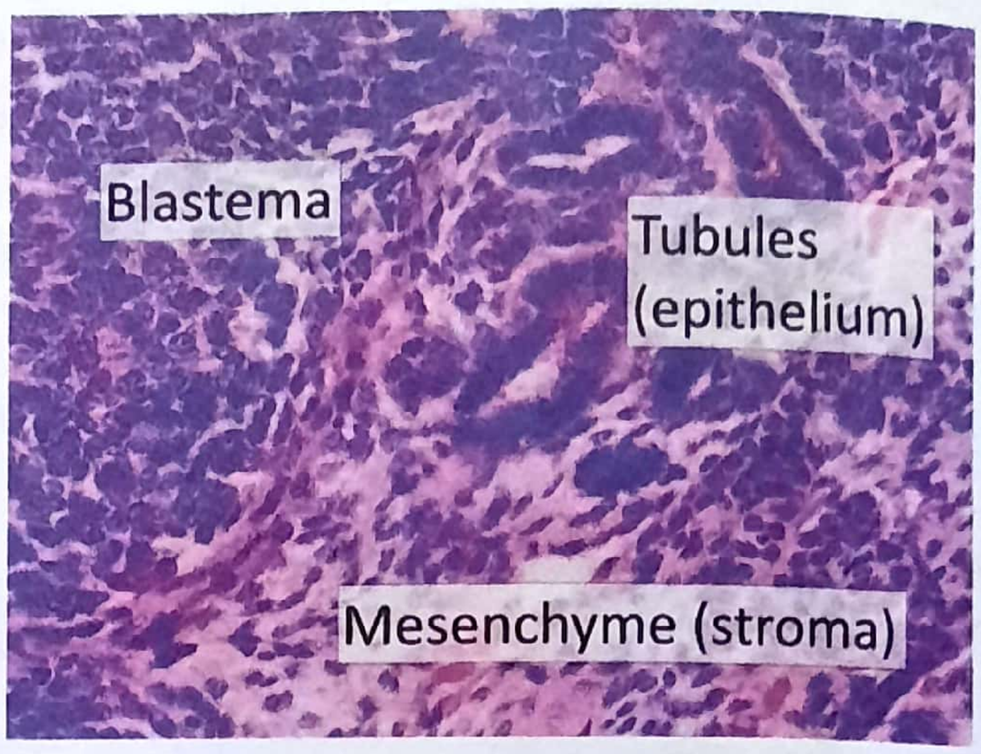

Figure 44.24: Wilm's tumor on histopathology

- *Microscopically* the tumour is composed of epithelial and connective tissue cells, occasionally with islands of bone, cartilage and muscle fibre.
- Consistency of the tumour depends upon the rate of progression of growth ie, a rapidly growing tumour is softer and slow growing tumour is firm in consistency.

Clinical Feature *(PGI 88, MANY PGME)*

1. Asymptomatic abdominal lump

- This is the **most common symptom** and is usually noticed by the mother while bathing the child *(AIIMS NOV 95, JIPMER 85, UP 02)*
- The lump may be very large as compared to size of the patient built.
- The lump is usually non-tender, soft to firm and *usually does not cross the midline.* [very imp. point]

A neuroblastoma, an important D/D crosses mid line].

2. Fever

Fever may be present in 50% of the patients and disappears when the tumour is removed.

3. Hematuria

Hematuria is present in about 10% of patients and denotes extrusion of tumour into renal pelvis and carries a poor prognosis.

Life expectancy after first episode of hematuria is about 18 months.

Figure 44.25: Surface marking of wilms tumour lump

4. Pain

May be a feature in about 20% of patients and is usually due to sudden increase in size of tumour or hemorrhage within the tumour.

5. Hypertension

This may be present in about 25-60% of children.

Metastasis

- Occurs **early,** mainly through ***blood stream to the lungs*** *(AIIMS 94)*
- **Liver and bone metastasis are uncommon.**
- Lymphatic metastases are present in about 20% cases at the time of presentation

Staging

Staging	Criteria
Stage I	• Confined to kidney • Complete excision with renal capsule intact and negative resection margins • Lymph nodes negative for Wilms tumor spread
Stage II	• Regional extension beyond kidney capsule, but confined to flank May include: ▪ Tumor penetration through capsule but confined to Gerota's fascia, infiltration into renal vein ▪ Complete excision with negative resection margins ▪ Lymph nodes negative for Wilms tumor spread
Stage III	• Residual tumor, but confined to abdomen May include: ▪ Regional lymph node involvement ▪ Peritoneal contamination: • Biopsy • Pre or intraoperative tumor rupture • Tumor growth through perito-neal surface • Positive resection margins
Stage IV	• Distant metastases: Lung, liver, bone, brain
Stage V	• Involvenent of bilateral kidneys at diagnosis

Investigation

1. X-ray imaging

Historically, IVU was the initial diagnostic study of choice to assess a suspected renal lump, but it has now been replaced by newer modalities like ultrasonography. CT scan and MRI. However chest X-ray remains the initial examination of choice to evaluate for presence of lung metastases *(cannonboll secondaries)*. X-ray will show:-

- **Egg-shell pattern** (Curvilinear calcification): *Crescent shaped, discrete* and peripherally placed calcification is seen on X ray. *(MANY PGME)*

  In *case of neuroblastoma, stippled calcifiction is seen, MANY PGME)*

- In Wilm's tumour calcification is seen in about 10%cases.

2. Ultrasonography

Ultrasonography is the current **initial investigation of choice** to evaluate palpable abdominal lump because it is accurate, widely available and cost effective.

3. CT scan and MRI

CT Scan of the abdomen can be useful in providing information regarding tumour extension, the status of contralateral (opposite) kidney and the presence of regional lymph adenopathy.

- **It is most helpful in staging the disease** *(PGME)*
- MRI can provide important information in defining the extent of tumour into inferior vena cava. *(IMP. POINT)*

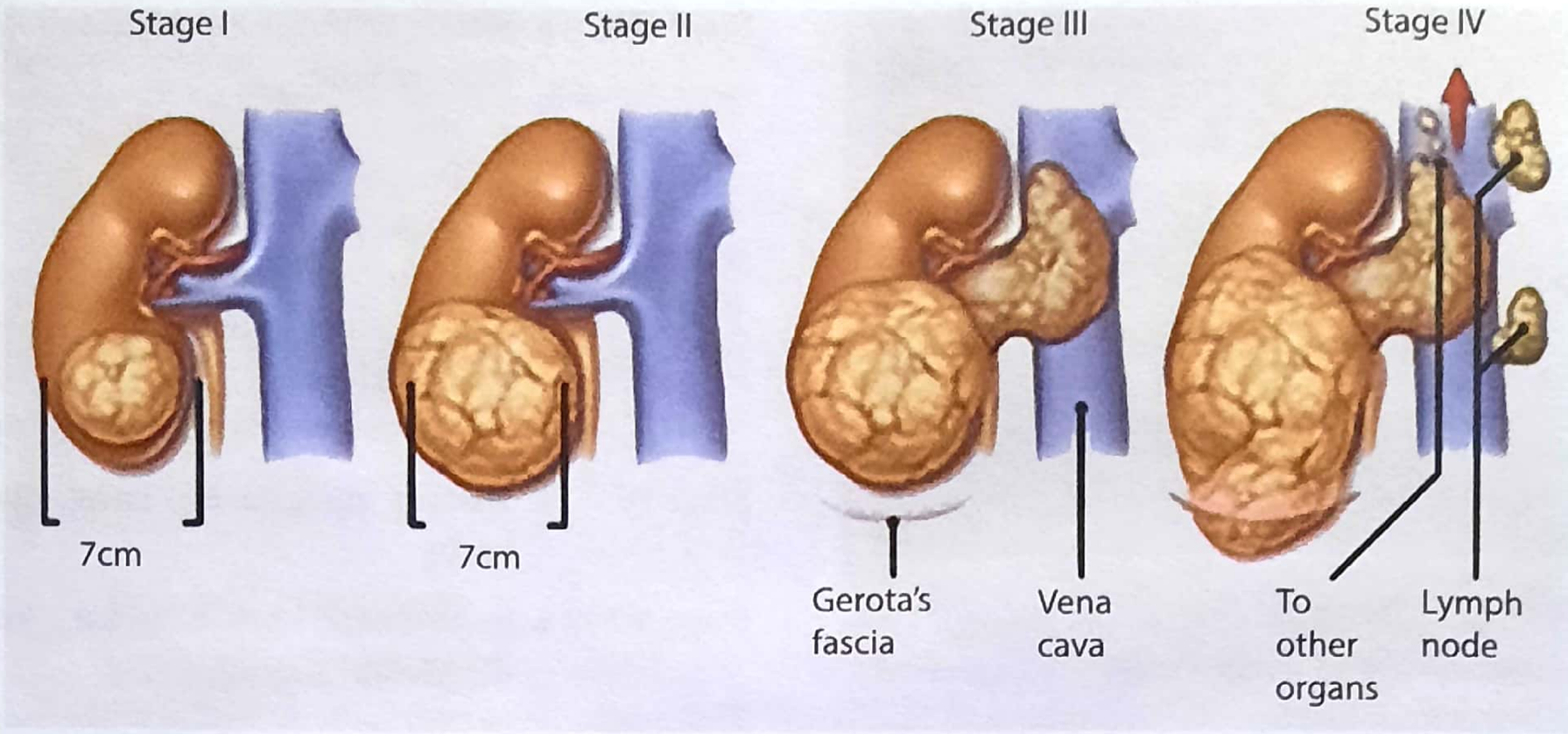

Figure 44.26: Stages of Wilms tumour

Treatment

Surgical Measures

- For patients With unilateral disease and surgically resectable ie; tumours not crossing midline or involving adjacent visceral organs:- **Radical nephrectomy via a trans abdominal (transperitoneal)*** approach is the procedure of choice. *(MANY PGME)*
- Tumours extending into inferior vena cava should also be removed unless there is evidence of total obstruction.
- Involvement of renal vein or IVC is not a contraindication for nephrectomy) *(MANY PGME)*
- Partial nephrectomy should be done if possible in patients with bilateral disease, *(IMP. POINT)*
- Please read key box 44.14.

Chemotherapy *(AIIMS 92)*

Wilm's tumours has been long recognized as a **chemosensitive neoplasm.** Patients with stage I to IV with favorable histology should undergo surgical resection and have postoperative chemotherapy. The most commonly drugs used in adjuvant chemotherapy are **Vincristine** and **Dactinomycin** (Actinomycin-D).

Radiotherapy:

It is usually given post operatively. *(AIIMS)*

Prognosis

Under 1 year of age- 80% survive for 5 years, but the prognosis is less good in older children. **Overall prognosis is good.** *(PGME)*

*****

KEY BOX 44.14

Nephrectomy For RCC & Wilm's Tumour

Nephrectomy can be performed either, through a loin or an Transabdominal approach but the transabdominal approach is preferred because through this approach the renal pedicle, which include renal artery and renal vein are better exposed *(AIIMS 89)*. The vascular pedicle should be ligated before the kidney is mobilized (handled) to avoid malignant cells to be released into the circulation. The first step in doing nephrectomy should be ligation of renal vein *(AI, PGI)* because by doing so, one can prevent the accidental rumour emboli dissemination into venous system however when nephrectomy is planned for benign disease (e.g. trauma, infection) renal artery should be ligated first *(PGME)*.

Trans-abdominal approach is also called as transperitoneal approach ie. we reach the kidney after opening the anterior abdominal cavity and peritoneum.

Loin approach - In it peritoneum is not opened. We reach kidney from behind; after opening posterior abdominal wall.

RENAL CELL CARCINOMA (HYPERNEPHROMA, GRAWITZ TUMOUR)

Very important PGME topic

- This is an **adenocarcinoma** and is the **most common neoplasm** (85%) **of the kidney** (KAR 98)
- It arises from renal tubular cells (proximal convulated tubule) and is located *more commonly on upper pole of kidney.*
- Multiple terms has been used to describe eg; *hypernephroma, grawitz tumour, clear cell carcinoma and alveolar carcinoma.*

Types of RCC

Various subtypes of RCC are described below -

1. **Clear cells** - This is most common subtype.
   - Associated with deletion of short arm of chromosome 3 & chromosome 8.
   - Most commonly arises from PCT.
   - It is associated with VHL.

VHL - Von Hippel Lindau Disease.

2. **Papillary RCC** - It is associated with psammoma bodies (CMET mutation).
   - Site of origin is PCT > DCT.
   - Grossly-mixed solid & cystic component.
   - Micro-papillary variant is seen in long term dialysis therapy.
   - Associated with gain of 7, 8q, 12q, 16p, 17 & 20.
3. **Chromophobe RCC** -
   - Cytogenic abnormality is loss of multiple chromosome (1, 2,6, 10, 13, 17 & 21).
   - **Birt-Hogg Dube syndrome** is associated with chromophobe RCC and skin lesions.
   - Plant like cells are seen.
   - Cytokeratin (+)
   - Best prognosis among subtypes.
4. **Collecting Duct RCC** - Also known as **Bellini carcinoma.**
   - Worst prognosis
   - Associated with loss of 1p, 16p, 9p & 8p and gain of 13q.
5. **Medullary RCC** - Seen in patients with Sickle cell anemia.
   - Poor porgnosis.

Syndromes Associated with RCC

- Von Hippel-Lindau Disease & B/L RCC
- Cowden syndrome
- Hereditary papillary kidney cancer
- SDH associated kidney cancer.
- Tuberous sclerosis
- Birt-Hogg Sube syndrome
- Bellini carcinoma

Predisposing conditions (MANY PGME)

1. Cigarette smoking
2. Coffee
3. Obesity
4. Occupational exposure to Cadmium, Asbestos
5. Adult polycystic kidney disease (APKD).
6. Genetic factor: Deletion on short arm of chromosome 3 and HLA DW-44 and HLA DR-8

Pathology

- The cut surface of the tumour is usually yellowish or dull white with semitransparent areas of hemorrhage and necrosis.
- Stippled* or plaque like calcification may be present.

Stippled* =means, marks with many small dots.

Spread

1. Local spread

This may be directly through the renal capsule to the adrenal gland, colon, liver or spleen. Spread along the renal vein into inferior vena cava may produce acute scrotal varicocele and lower limb edema in about 12% cases, (MANY PGME)

2. Blood spread

Most commonly to lungs 60%, (AIIMS FEB 97) and grow to form cannon ball secondaries. Bony metastases may occur in 30-40 %. They are some times very vascular

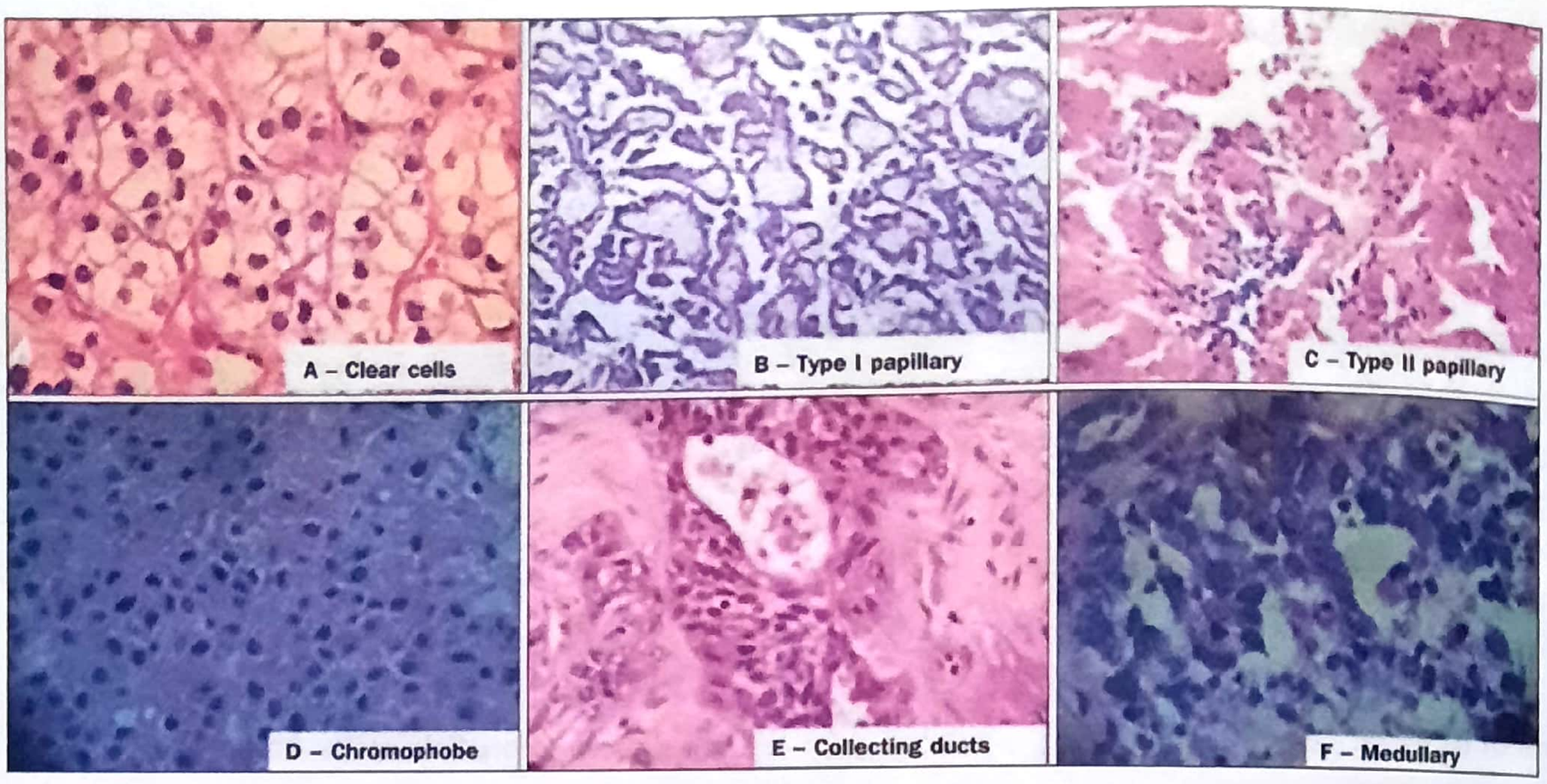

Figure 44.27: Histopathology of various images of RCC

and may pulsate ie;- **pulsatile bony secondaries** *and is very characteristic findings of metastatic disease of hypernephroma.* *(PGME)*

[NOTE: Though it is carcinoma, hematogenous spread is most common mode of spread] *(PGME MANY TIMES)*

RECAP: Carcinoma mainly spread through lymphatic route, where as sarcoma through blood (hematogenous)

3. Lymphatic spread

When the tumour extends beyond the renal capsule, it may involve lymph nodes at hilum and para aortic nodes.

TNM Staging Of RCC

T0 - No evidence of 1° tumor

T1 - Tumor < 7 cm in greatest dimenstion limited to kidney

T_{1a} - Tumor < 4 cm limited to kidney

T_{1b} - Tumor > 4 cm but < 7 cm limited to kidney

T2 - Tumor > 7 cm in greatest dimension limited to kidney

T3 - Tumor extends into major veins or invades adrenal gland or perinephric tissue but not beyond gerota's fascia.

T_{3a} - Tumor invades adrenal gland or perinephric tissue but not beyound gerota's fascia.

T_{3b} - Tumor grossly extends into renal vein or vena cava below diaphragm.

T_{3c} - Tumor grossly extends into vena cava above diaphragm.

T4 - Tumor invades beyound gerota's fascia.

N_0 - N0 LN

N_1 - (+) LN (First drained by para aorta LN)

M_0 - N0 metastasis

M_1 - Distant metastasis (Lung are M/C site).

Robson's Staging For RCC

Stage I: Tumour confined with in renal capsule

Stage II: Tumour invasion through renal capsule and perinephric fat but confined with in gerota fascia.

Stage III: III_A - Renal vein or IVC involvement

III_B - Lymphatic involvement.

III_C - III_A + III_B

Stage IV: Distant metastasis to lung or involvement of adjacent organs (liver, colon, pancreas).

Clinical Features

Clinical features are divided as typical presentation and atypical presentation

A. Typical presentation

RCC is two time more common in males than females. The ***triad of symptoms*** are hematuria, flank pain and palpable lump. Please see key box 44.15.

1. **Painless hematuria** (AI 94): *Occurs throughout the urinary stream; and is seen in 60% of cases,* (ie;-total hematuria). This *is most common symptom*. The degree of hematuria is not related to the size or stage of the tumour, (very important point)
2. **Dragging Pain:** In the later stages an enlarged tumour may cause dragging type of pain in the loin.-
3. **Mass in the loin**: This is present in 20-40% of cases.

However, this triad is present in only about 10% cases.

B. Atypical presentation (AIIMS NOV 94, JUNE 95):

Certain atypical presentation are the following:

- A rapidly developing **left side varicocele** is uncommon, but is an impressive sign, (MANY PGME)
- *Secondary deposits:*
  - To bone may manifest as pathological fracture, and headache or hemiparesis. (UP 03)
  - To lung as cough or hemoptysis.
  - **Pyrexia of unknown origin (PUO)** possibly due to tumour pyrogens. (UP 03)
  - Amyloidosis
  - **Anemia** is a sign of advanced disease.
  - Polycythemia may be present in about 4% due to secretion of an erythropoietic stimulating substance from the tumour. (UP 03)
- **Endocrine effects** (AIIMS NOV 93, JIPMER 95) ***are due to secretion of various hormones by renal cell carcinoma.***

  These are: (AIIMS NOV 11)
  - Raised ESR is **most common** para-neoplastic finding. (MANY POME)
  - *Other para-neoplastic features are:*

Hormone	Clinical effect
Renin	Hypertension
Parathormone	Hypercalcemia
Erythropoietin	Polycythemia vera
Prolactin	Galactorrhea
Insulin	Hypoglycemia
Gonadotropins	Gynecomastia, hirsutism
Various hormones	Neuromyopathy

- Other rare features may be nephrotic syndromes, palmar erythema, CHF, non-metastatic hepatic dysfunction ***(Stauffer's syndrome).***

Investigation

1. Plain X-ray

This may show abnormal calcification in the tumour. A chest radiograph to detect cannon ball lung secondaries (AIIMS 01).

2. Intravenous urography (IVU)

IVU is still an important diagnostic tool. It shows :

- Filling defect in one or more of minor and major calyx due to invasion by tumour.
- Elongation and compression on one or more calyces and pelvis leading to **'spider leg deformity'.** (UPPGME, PGI)
- Down ward displacement of renal pelvis and calyces by upper pole growth.

3. Ultrasonography

Ultrasonography is a non invasive, relatively inexpensive technique able to further locate a renal mass seen on IVU.

4. CT Scan

CT *scan has been shown to be more sensitive than USG or IVU for renal cancer detection.*

KEY BOX 44.15
Traid of RCC (NEET)
• Pain
• Hematuria
• Lump in abdomen
Mnemonic = PHL = Premier Hockey League

Figure 44.28: Specimen of Renal Cell Carcinoma

- CT scan is **diagnostic procedure of choice** (NEET) for a renal cell carcinoma. (PGME)
- CT also helps in:
  - (i) Staging of the tumour,
  - (ii) Involvement of local hilar lymph nodes or
  - (iii) Involvement of renal vein and inferior vena cava.

5. MRI

- MRI is equivalent to CT for staging of RCC. It primary advantage is in the evaluation of patients with ***suspected vascular extension,*** (IMP. POINT). Note that RCC metastasize early to renal vein; as hematogenous spread is common and early.

Treatment

1. For stage I, II and IIIA

Treatment of renal cancer up to stage I to IIIA (renal vein or IVC involvement) is **radical nephrectomy.** (NEET) which involves removal of:

- Entire kidney with surrounding gerota's fascia (including adrenal).
- Renal hilar lymph node
- Proximal - half of ureter.

Approach for nephrectomy should be transperitoneal (Please see key box 44.14 on page 824 given earlier in this chapter. (Very important, please read it once again)

NOTE :(VERY VERY IMPORTANT)

- Involvement of IVC or renal vein is not a contraindication for surgery. (AI, PGI 01)
- There is no role for localized pre-or post operative radiation therapy. (AIIMS NOV 01).

2. For advanced (metastatic) tumours (III_B -IV)

Chemotherapy

This is not very successful in the management or renal cell carcinoma. It may have a role for symptomatic bone metastases and for stages IIIB and IV; the *drugs used is vinblastine.*

Hormone therapy

Use of medroxyprogesterone acetate have a 10-15% response rate.

Immunotherapy

Methods available are:

(a) Interleukin - *2* (IL-2)

(b) Interferon

(c) Lymphokine-activated killer (LAK cells).

(d) Tumour infiltrating lymphocytes (TILS); These methods of treatment are currently under evaluation and are associated with a high morbidity.

Radiotherapy

Adenocarcinoma of the kidney **does not respond conventional radiotherapy.** ie; RCC is **radioresistant.** (NEET, AIIMS NOV 93) however some recent studies has shown effective palliation of metastatic disease to brain, bone and lung.

Please see flow chart in key box 44-16 before concluding this topic.

*****

KEY BOX 44.16

Summary of t/t of renal cell carcinoma

Localized Renal cell CA (Stage I-IIIA)

Tumour **size more than 4 cm**

Radical nephrectomy
Which involves removal of
- Entire kidney with surrounding gerota's fascia (including adrenal gland)
- Proximal half of ureter

Tumour **size less than 4 cm** *(AIIMS NOV 04)*

Partial nephrectomy *(NEET 20)*

Advanced renal cell CA (III B-IV and metastatic disease) Only palliative treatment

Treatment Options are:
1. Chemotherapy (vinblastine)
2. Hormone therapy (Medroxy progresterone acetate)
3. Immuno therapy
   - IL-2
   - Interferon alfa
   - LAK cells

PAPILLARY TRANSITIONAL CELL TUMOURS OF RENAL PELVIS AND URETERS

- These are uncommon tumour of the kidney arising from the pelvis and resemble those of the urinary bladder and are much less common.
- These are the most common carcinoma of renal pelvis and upper ureter. *(NIMHAS 87)*
- Renal pelvis carcinoma accounts for 5-10% of renal cancer with the mean age at the diagnosis being 65 years and male: female ratio is 3:1.

Etiology

1. **Balkan nephropathy**

In Balkan region (ie; Greece, Bulgaria, Romania) where a special form of interstitial inflammation is prevalent, this carcinoma accounts for about 40% of renal tumour.

2. **Smoking**
3. Chemical and dye exposure like, THOROTRAST
4. ***Analgesic nephropathy:*** caused by phenacetin.

Clinical Feature

- Hematuria is most common symptom.
- The growth may occasionally produce colic.
- There may be associated loin pain, anorexia & weight loss.
- Palpable mass may be present in only 5%.

Treatment

Conventional surgical treatment is by **nephro-ureterectomy, along with a cuff of bladder wall.** *(NEET)*

*****

SQUAMOUS CELL CARCINOMA OF RENAL PELVIS

Squamous cell carcinoma is produced by chronic irritation with renal calculi, schistosomiasis, chronic low grade infection and consequent squamous metaplasia of pelvic epithelium. These tumours are **radio Sensitive. S** for **S**quamous, **S** for **S**ensitive (ie; radio**S**ensitive).

*****

Sample Questions for Prof Examination

1. Describe the cause of unilateral hydronephrosis. Discuss the diagnosis and treatment of congenital hydronephrosis.
2. Describe the pathology, clinical features and management of a case of renal calculi.
3. What are the varieties of the malignant tumours of the kidney? Describe the clinical features and treatment of wilm's tumour.
4. Describe the pathologcial features and diagnosis and treatment of wilm's tumour.
5. Discuss the pathology, clinical features and management of hypernephroma.
6. Define hydronephrosis, write its types. Mentions treatment of idiopathic hydronephrosis?
7. Write short notes on

   IVP

   Horse shoe kidney

   Renal tuberculosis

45 The Urinary Bladder

Contents

- Surgical anatomy
- Ectopia vesicae
- Rupture of bladder
- Retention of urine
- Cystitis
- Bilharzial cystitis
- Bladder stone
- Carcinoma of the bladder
- Hematuria
- Urinary incontinence

SURGICAL ANATOMY

- The urinary bladder is situated immediately behind the pubic bones, within the pelvis.
- It is a reservoir for storage of urine *and in the adult has maximum capacity of about 500 ml.* The bladder has a strong muscular wall.
- Its shape and relation, vary according to the amount of urine in bladder. The empty bladder in the adult lies entirely within the pelvis, but as the bladder fills, its superior wall rises up into hypogastric region.
- The empty bladder is pyramidal in shape, having an apex, a base and a superior and two inferolateral surface and has neck. The apex of the bladder points anteriorly and lies behind the upper margin of the pubic symphysis. The base or posterior surface of the bladder, faces posteriorly and is triangular in shape.
- The superior surface of the bladder is completely covered with peritoneum and is related to coils of ileum or sigmoid colon. Along the lateral margins of this surface, the peritoneum is reflected onto the lateral pelvic wall.
- The mucous membrane of the greater part of the empty bladder is thrown into folds, but these disappear when the bladder is full. The *area of mucous membrane covering the internal surface of the base of the bladder is referred to as the* ***trigone***. Here, the mucous membrane is always smooth, even when the bladder is empty, (fig. 45.1, 45.2)
- The *muscular coat of the bladder* is composed of smooth muscle and is arranged as three layers of interlacing bundles, *known as the* ***detrusor muscle***. (IMP)
- At the neck of the bladder, the *circular component of muscle coat is thickened to form the sphincter vesicae.*
- **The *uvula vesicae*** (UP 99) is a small elevation situated immediately behind the urethral orifice, that is produced by the underlying median lobe of the prostate.

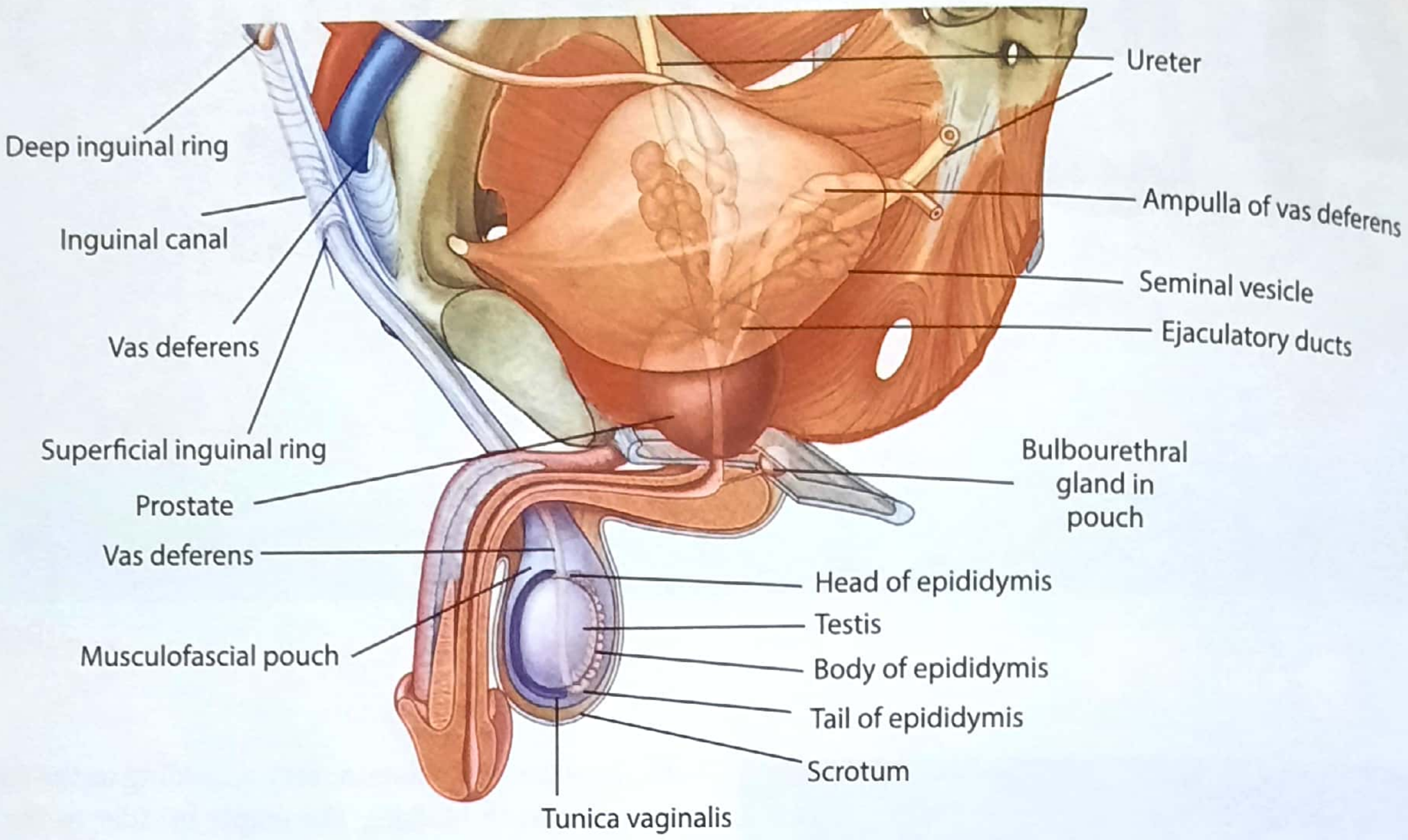

Figure 45.1: Anatomy of genitourinary symptom (lateral view)

FOURTY FIVE

Blood Supply

Arterial supply

The arterial supply to the bladder is from *superior & inferior vesical arteries,* which are branches of *internal iliac arteries.*

Venous drainage

The veins from the vesical venous plexus which communicates below with the prostatic plexus and is drained into the internal iliac veins.

Nerve Supply

- The nerve supply to the bladder is *from the inferior hypogastric plexus.*
- **The *sympathetic*** postganglionic fibers originate in the first and second lumbar (L_{1-2}) ganglia and descend to the bladder via the hypogastric plexus.
- **The *parasympathetic*** preganglionic fibers as the pelvic splanchnic nerve from second, third and fourth sacral nerve (S_{2--4}) pass through the inferior hypogastric plexuses to reach the bladder wall.

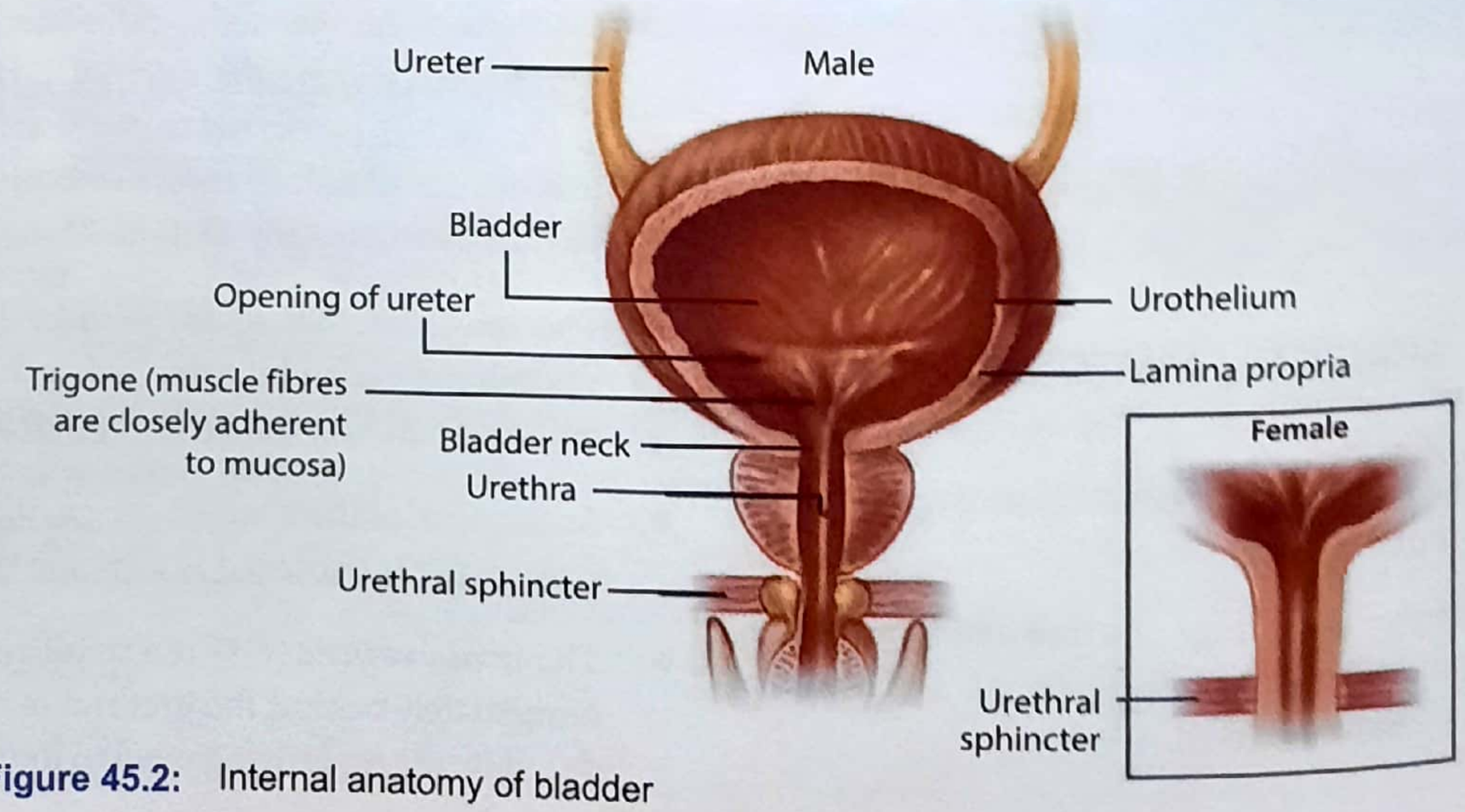

Figure 45.2: Internal anatomy of bladder

1. Parasympathetic efferent fibers (S-2, 3, 4):

These fibers are *motor to the detrusor muscle* and *inhibitory to the sphincter vesicae,* hence stimulation of these are responsible for normal act of micturition, because they will contract detrusor and inhibit sphincter vesicae.

2. Sympathetic efferent fibers (Ll-2)

These are said to be inhibitory to the detrusor and motor to sphincter vesicae (internal urethral sphincter).

3. The Somatic

Pudendal nerve (S2,3,4) supplies the sphincter urethrae (external urethral sphincter) which is voluntary.

Till now we were discussing brief surgical anatomy, now lets discuss diseases related to Urinary bladder.

*****

ECTOPIA VESICAE

(SYN : EXSTROPHY OF THE BLADDER)

- This is thought to be caused by *incomplete development of the infra-umbilical part of the anterior abdominal wall,* associated with incomplete development of the anterior wall of the urinary bladder. *(MANY PGME)*
- The condition affects one in 50,000 newborns and thought; due to delayed rupture of the cloacal membrane.

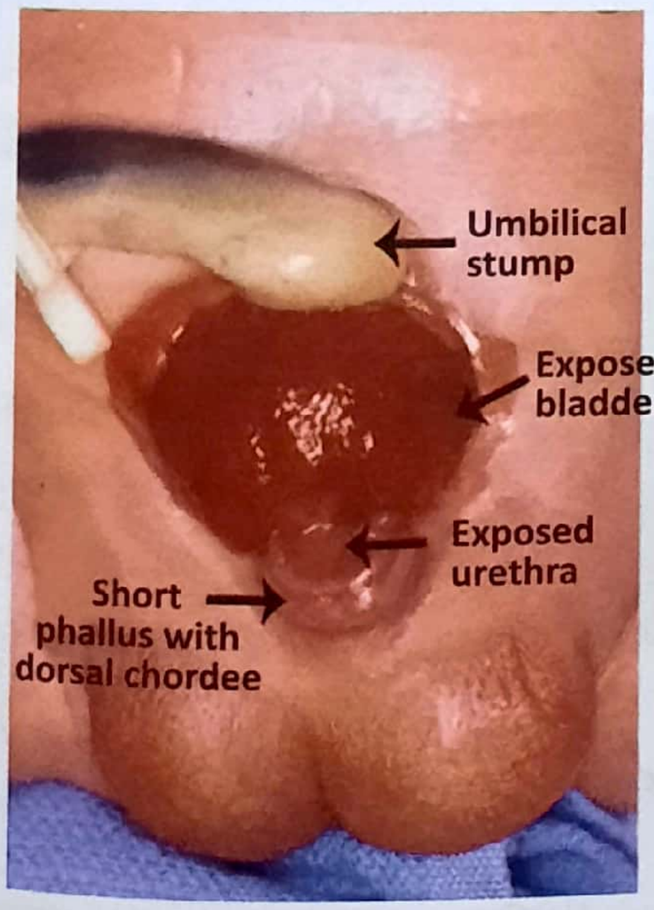

Figure 45.3: Ectopia vesicae

Clinical Feature

1. The condition is more common in males, and male : female ratio is 4:1.
2. On palpation the edges of the abdominal wall can be felt.
3. The umbilicus is absent and linea alba is broad.
4. Because anterior wall of the bladder is not developed, the posterior wall of the bladder protrudes through the anterior abdominal wall defect and urine over flows on the anterior abdominal wall.
5. In the **male;** the completely *epispadias penis is always present, which* is broader and shorter than normal (Figure 45.3). Bilateral inguinal hernia may be present. *Testes are normal and well descended.* Prostate, seminal vesicle and scrotum are rudimentary. *(IMP. POINT)*
6. In the **female:** the clitoris is bifid and the labia minora are separated anteriorly, exposing the vaginal orifice.
7. In both sexes, there is *separation of the pubic bones,* which are connected by a strong ligament. *(PGME)*

Treatment

1. **Iliac osteotomy, with closure of bladder and abdominal wall** *(MANY PGME)*. In the first year of life, the bladder is closed following iliac osteotomy of both bones, just lateral to the sacroiliac joints. Later; reconstruction of the bladder neck and sphincters are done, followed by closure of the abdominal wall.

However; reconstructed bladder remains small and may require augmentation.

2. Another option is **Urinary diversion** This may be necessary, if continence is poor following bladder reconstruction. It can be done by means of a *uretero-sigmoid* anastomosis* (ureterosigmoidostomy) or by the formation of ileal conduit, colonic conduit or continent urinary diversion. (Figure 45.4)

Complication of ureterosigmoidostomy are

(a) Stricture with bilateral hydronephrosis and infection.

(b) Hyperchloremic metabolic acidosis. *(MANY PGME)*

(c) Increased risk of tumour (adenoma & adenocarcinoma) at the site of the ureterocolic anastomosis.

(d) Hyperammonemia.

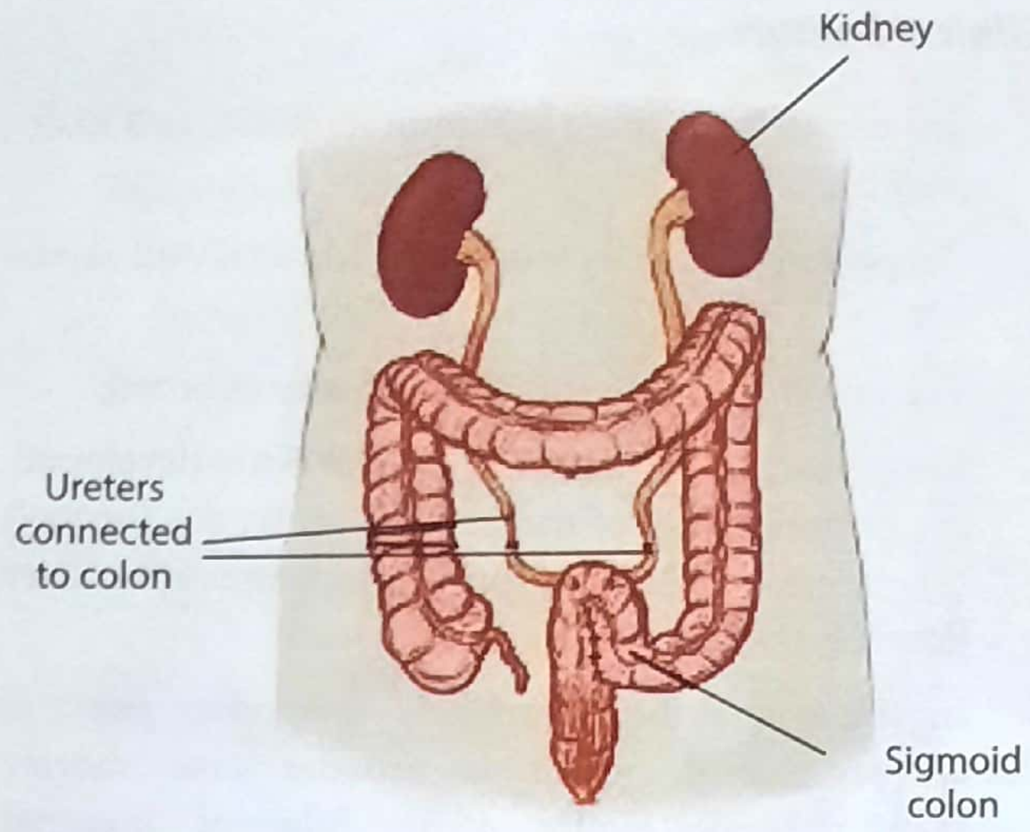

Figure 45.4: Uretero-sigmoid colon anastomosis (Ureter-sigmoidostomy, i.e; ureters stitched to sigmoid colon)

*****

RUPTURE OF THE BLADDER

Injury to the bladder must be suspected in any patient with pelvic fracture or with a history of lower abdominal trauma; either blunt or penetrating.

Clinical Types

Rupture of the bladder may *be intraperitoneal is 20 % and extraperitoneal in about 80%.* (MANY PGME)

1. Intra Peritoneal Rupture (20%)

In intraperitoneal rupture of bladder; the urine extravasate in peritoneal cavity and causes urinary peritonitis.

Intraperitoneal rupture almost always occurs after injury to a full bladder. (IMP. POINT) {fig 45.4}

Clinical features

- A patient with intraperitoneal rupture of bladder presents with agonizing pain in hypogastrium, often accompanied with shock.
- Distension of abdomen due to peritonitis.
- Inability to pass urine.

2. Extra Peritoneal Rupture (80%) (NEET)

It is difficult to differentiate it from a rupture of the posterior urethra. It is discussed in detail in next chapter.

Treatment (MANY PGME)

1. **Intra Peritoneal rupture:** This requires laparotomy, and repair of ruptured urinary bladder and drainage.
2. **Extraperitoneal rupture:** It is usually managed by *carefully passing a urinary catheter (Foley's catheter) in the bladder.* (AI, AIIMS, PGI)

*****

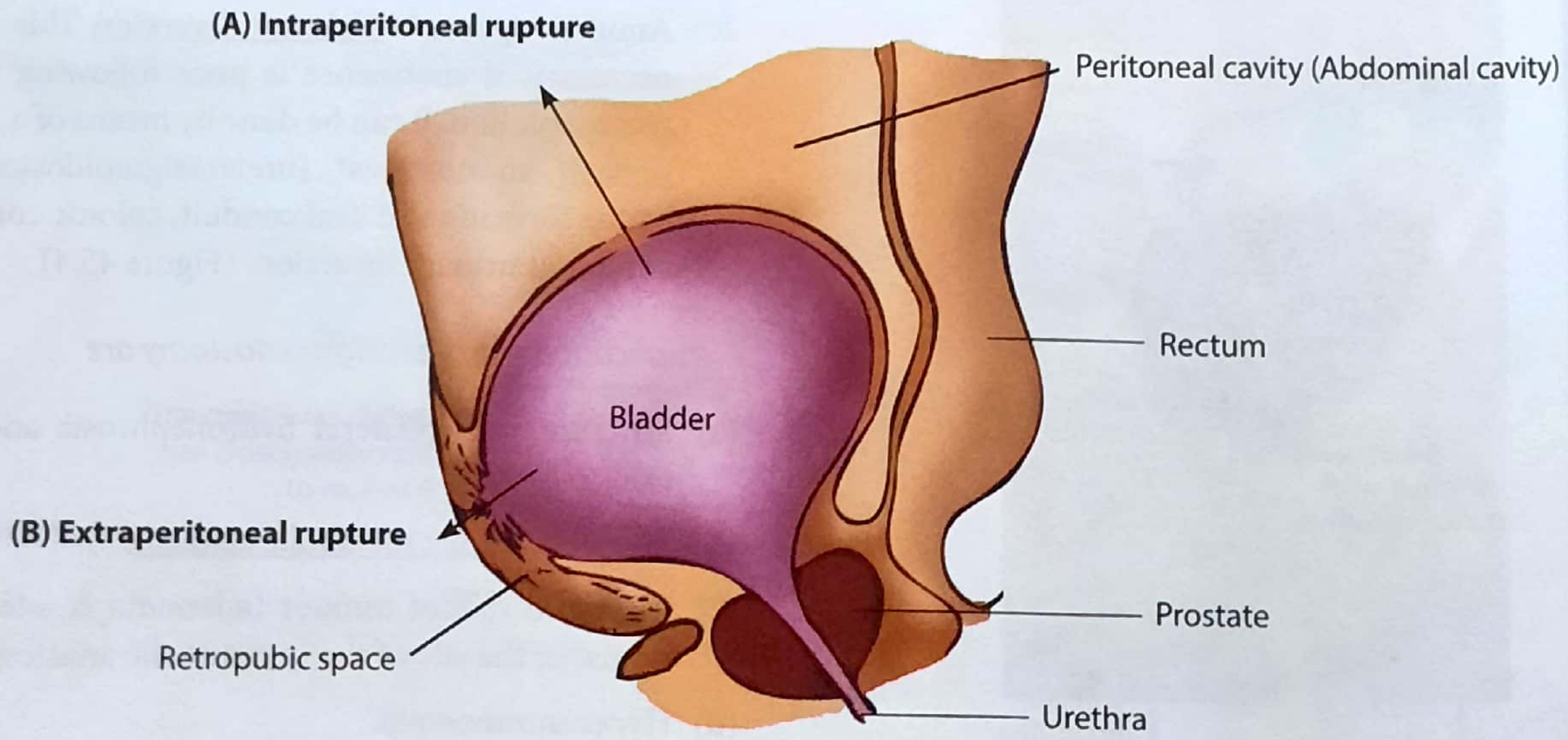

Figure 45.5: Rupture of urinary bladder (A): Intraperitoneal rupture (B): Extraperitoneal rupture of bladder

RETENTION OF URINE

Retention of urine means, accumulation of urine in urinary bladder, yet patient is unable to pass urine. It should be differentiated with anuria. Anuria is a condition, in which kidneys fail to excrete (form) urine and there is no urine in urinary bladder, while in retention of urine the bladder is full with urine. **Retention of urine can be of two types:**

1. **Acute retention:** This means sudden inability to pass urine and is a **painful** condition. *(UP 89)*
2. **Chronic retention:** This is gradual, **painless** retention of urine and patient is often unaware of the distended bladder. In both cases; on examination of abdomen a distended bladder presents as a hypogastric lump.

Causes *(DELHI 09)*

A. Mechanical - i.e; due to obstruction in the out flow of urine. Causes from bladder to prepuce are :

1. **Vesical (Bladder)**
   - Stone
   - Growth (tumour)
   - Blood clot
   - Rupture
   - Cystitis
2. **Prostate**
   - Infections:-acute prostatitis, prostatic abscess
   - BPH
   - Carcinoma prostate
   - Prostatic calculi
3. **Urethra**
   - Stricture of urethra
   - Rupture
   - Impacted stone in urethra
   - Acute urethritis
4. **Prepuce**
   - Severe phimosis
5. **Extraurinary causes**
   - Retroverted gravid uterus (compress bladder)
   - Fecal impaction in rectum (compress bladder neck)
   - Large fibroid, ovarian cyst (compress bladder)
   - Carcinoma of cervix and rectum (Involving bladder neck)

B. Neurogenic

- Spinal injury
- Disease of spinal cord and spinal column (eg. Tabes dorsalis, transverse myelitis)
- Drugs such as anticholinergics, anti-histaminic smooth muscles relaxants, antihypertensive.
- Hysteria
- Senile atony of bladder
- Spinal anesthesia
- Post operative (pelvic surgery & hemorrhoidectomy)

Treatment

- Reassurance and warm bath may be helpful in many cases.

1. To relieve retention

- In acute retention of urine a foley's catheter is passed in bladder, through urethra under strict aseptic condition and catheter is connected to a collecting urinary bag *(urobag)*. (fig. 45.6)
- In case of chronic retention the bladder is decompressed slowly, because rapid decompression may lead to; hemorrhage & shock, due to rupture of vesical piles.

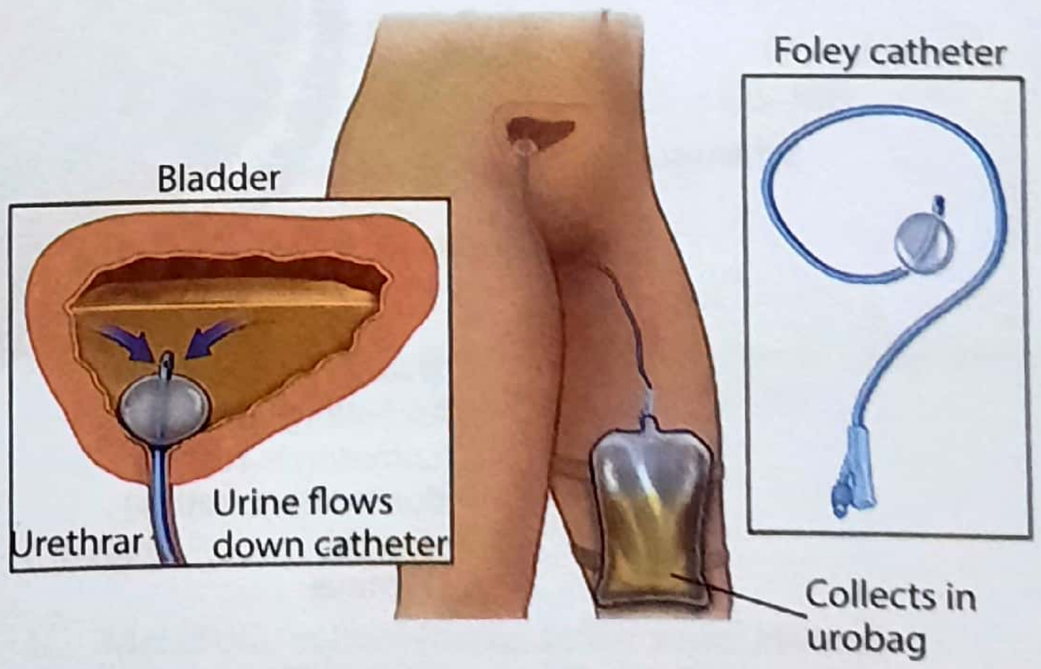

Figure 45.6: Foley's catheter and its placement in bladder

- If catheterization fails or is not possible due to block or stricture in urethra, then suprapubic bladder puncture or suprapubic bladder catheterization should be done, (See fig. 47.10; page 877)

2. Treatment of cause

Treat the underlying cause of retention eg; prostatectomy for BPH, cysto-lithotomy for vesical calculus, dilatation for stricture of urethra.

*****

CYSTITIS

Etiopathogenesis

- Cystitis is *inflammation of mucosa of urinary bladder.* In majority of cases, this condition is caused by bacteria, which are present in the patients own fecal flora.
- *Ascending infection is the primary source of infection.* (AI, AIIMS, MANY PGME)
- Men are some what protected from ascending infection because of - (i) Long urethra.(ii) Antibacterial action of prostatic secretion. Please see fig. 45.7.

Microbiology

E. coli accounts for about 75% of urinary tract infection. Less common pathogens are *Proteus, Klebsiella, Staphylococcus* etc.

Clinical Feature

- Irritative symptoms like; **frequency of micturition, urgency** and **dysuria (painful micturition)** are common.
- Some patients may complaints of low back pain and supra pubic discomfort, hematuria, nocturia.

Management

- *Midstream urine specimen* in both male and female should be sent for microscopic examination and for culture and sensitivity. (PGME)
- Antibiotic therapy based on culture and sensitivity report should be started for a period of 7-10 days.
- Patient is advised to drink plenty of fluid.

*****

Rare causes

Radiation

Cytotoxic drug

Tuberculosis

Schistosomiasis

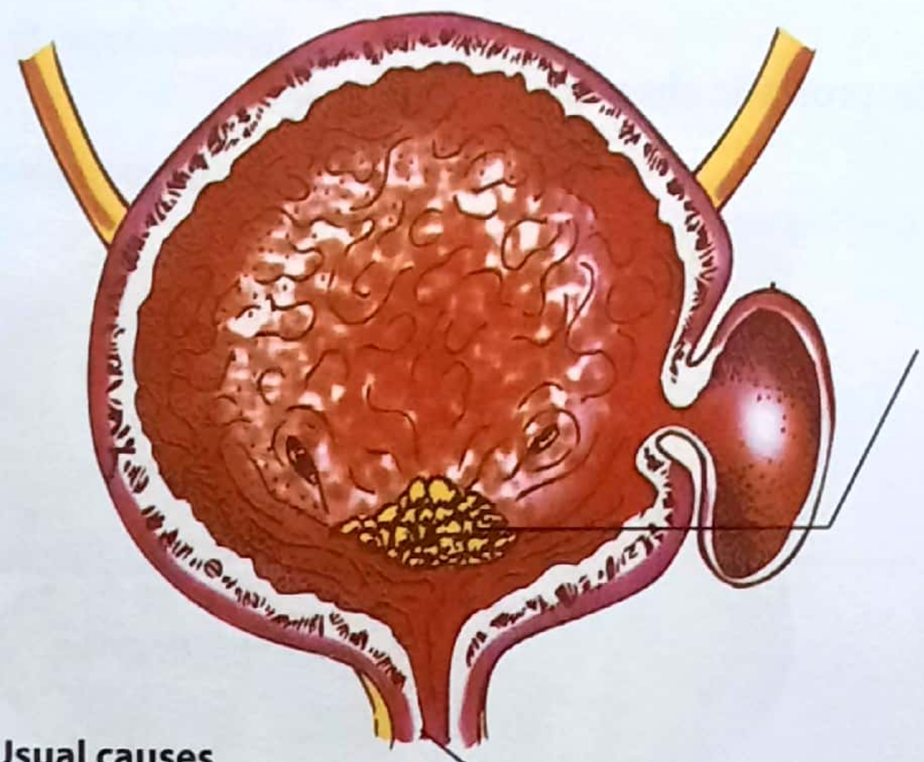

Predisposing factors

Anatomical abnormalities
- Diverticula
- Intestinal- vesical fistula
- Extrophy of bladder

Stasis of urine
- Obstruction (BPH)
- Neurogenic bladder
- Pregnancy
- Calculi
- Neoplasms

Sexual intercourse
(Honeymoon cystitis)

Usual causes
Ascending infections
(common in female due to short urethra)
- E. coli
- Proteus

- Catheterization
- Cystoscopy

Figure 45.7: Causes and predisposing factors for bladder infection

BILHARZIAL CYSTITIS (SCHISTOSOMIASIS)

- The *perivesical venous plexus* is the favoured habitat of *Schistosoma hematobium.* (PGME)
- The ova of this passes through the bladder wall to enter the lumen and are excreted in urine. Finding of typical ova in urine is diagnostic.
- Vesical schistosomiasis is associated clinically with fever, frequency, dysuria and hematuria.
- Marked fibrosis occurs in the chronic stage.
- The bladder epithelium frequently shows *squamous metaplasia.* (PGME) There is greatly increased risk of *Squamous cell carcinoma.* (MANY PGME, ALLMS 93)
- Systemic treatment by antimony compound or other preparations like praziquantel may be helpful.

Nonspecific Cystitis

Chronic nonspecific cystitis is characterised by epithelial hyperplasia and infiltration of the bladder mucosa with lymphocytes and plasma cells. Cystic dilation of epithelial nests in the submucosa (Brunn's nests) may produce multiple epithelium-lined cysts in the mucosa (**cystitis cystica**). Glandular metaplasia may occur (**cystitis glandularis**). These forms of epithelial change have little clinical significance. The cause is not known.

One other form of chronic nonspecific cystitis; characterized by ulceration of the mucosa with submucosal fibrosis, vasculitis and infiltration by eosinophils is called **Hunner's interstitial cystitis.** (NEET)

Tuberculosis Of Urinary Bladder

Vesical tuberculosis occurs in 70% of patients with renal tuberculosis and frequency is a common presenting symptom in patients with urinary tract tuberculosis. The ureters and epididymis may also be involved.

The trigone is affected first and the early lesions appearing as small submucosal granulomas. Extensive caseous granulomas may cause nodules and ulceration, while the associated fibrosis may cause retraction of the ureteral orifice into the wall of the bladder (**"golf-hole ureter"**) (PGME) with vesicoureteric reflux. Diffuse involvement of the bladder is associated with marked fibrous contraction of the bladder(**"thimble bladder"**) (PGME). At this stage, urinary frequency is extremely severe. Full course of ATT is treatment of choice.

Foreign Bodies In Bladder

The commonest foreign body in urinary bladder is *fragments of burst catheter balloon* (PGME). The variety of foreign bodies which has be reported from bladder is astonishing, for example; hairpins, hair clasps, fruit seeds. The diagnosis is made by cystoscopy, and in case of a radio opaque foreign body, X-ray will show the foreign body in bladder.

Complication of foreign body in bladder

- Lower urinary tract infection
- Bladder wall perforation
- Bladder stones

Treatment

A small foreign body can usually be taken out through a cystoscope. Occasionally; large foreign bodies are removal by opening bladder by a supra public incision.

*****

BLADDER STONES

Definition

1. Primary bladder stone

It is one; that develops in sterile urine and **often originate in a kidney** and passes down the ureter to reach bladder; where it enlarges.

2. Secondary bladder stone (PGME)

It is one; that is formed in the bladder itself . Such stone may occurs in presence of :

(i) Foreign body* (non absorbable sutures)
(ii) Catheter fragments
(iii) Bladder outflow obstruction (BOO)
(iv) Impaired bladder emptying
(v) Infection (cystitis) (KAR 06)

Commonest foreign body in urinary bladder is a fragment of catheter balloon passed in bladder. (MANY PGME)

Causes

1. Metabolic causes (Same as for renal stones)

2. Urinary stasis
3. Infection
4. Foreign body:
   (i) Suture material from previous surgery
   (ii) Tumour seeding
   (iii) Schistosomiasis

Epidemiology

- *Juvenile bladder stone* is more commonly seen in certain geographical areas of Indian subcontinent.
- There is a higher incidence of vesical stone in *boys from lower socioeconomic status where malnutrition is more common.* (AIIMS NOV 01,OTHER PGME)
- Bladder stone may be related to nutritional factors, such as a low intake of animal protein and a high cereal diet.
- Low socioeconomic status, dry climate or dehydration also play role in formation of bladder stone.

Composition of Bladder Stones

1. OXalate stone

- They are moderate in size and solitary and are usually dropped from above (kidney).
- It's surface is uneven and **spiculated,** giving *jack stone configuration (mulberry type)* (MANY PGME) [Remember as with X in oXalate - X is like two arrow -spiculated; spicule = needle shaped]
- They are white in colour but may be dark brown due to pigmentation.

2. Uric Acid and Urate stone (M/C)

- These are round or oval and may be single or multiple. [Remember with U - oUal and smooth surface]
- Most of the uric acid stones are formed in bladder and **accounts for most of the bladder *stones.*** (PGME)

3. Cystine stone

- They are common in presence of cystinuria and are radio-opaque due to its high sulphur content.

4. Triple 'P'hosphate stone

- These are composed of ammonium, magnesium and calcium phosphates and *occurs in urine infected with urea-splitting organism (eg. Proteus).* These are also called as ***struvite stones****. (MANY PGME)
- They tend to *form in alkaline urine. ie;* at high urinary P_H just to remember pH is high ie alkaline PH . (MANY PGME) .

SRTUVITE?:-It is a crystal of magnesium ammonium phosphate; some times found as a harmless ingredient of canned food, where they can be mistaken to piece of glass.

Location of Stone In Bladder

Bladder stones are usually free to move in bladder and tend to occupy the dependent portion, which are:-

(i) In the sitting or erect position:- at bladder outlet (neck of urinary bladder)

(ii) In the lying down position; behind the Inter ureteric ridge.

- Less commonly the stone may be hidden in a diverticulum of urinary bladder.

Clinical features

- Males are eight times more often affected than females.
- At times stones may be asymptomatic and found incidentally during ultrasound or X-ray of abdomen for some other disease. The chief **symptoms** are:-

1. Frequency of micturition

Frequency is the **earliest symptom** (PGME), and often more common during daytime. Patient may have sensation of incomplete bladder emptying.

2. Painful micturition (dysuria)

- More common in spiculated oxalate calculus.
- Occurs at the end of micturition and is referred to the tip of the penis or to labia majora, or rarely to the perineum or suprapubic region.
- *Screaming and pulling of the penis* with hand is important characteristic in children and then USG becomes necessary to confirm diagnosis. (IMP.POINT)

3. Hematuria

- This is characterized by the passage of a few drops of bright red blood at the end of micturition. (IMP. POINT)

4. Sudden interruption of the urinary stream

- This is due to the stone blocking the internal meatus (bladder neck); which may be relieved by change in posture of the patient.

5. Acute retention of urine

- This is usually seen in children; however can occur infrequently in adults. This occurs due to impaction of stone at neck of bladder or in prostatic urethra.

Investigation

1. *Urine* - Urine should be sent for routine and microscopic examination.
2. *Plain X-ray* - More than 90% of stones are radioopaque and the entire KUB system should be exposed.
3. *Intravenous urography* - A filling defect may be seen in case of radiolucent calculus.
4. *Cystoscopy*- The whole of the bladder can be seen. Nonopaque calculi can be seen and any bladder outlet obstruction can be detected.
5. *Ultrasonography*- It can easily detect bladder stone & associated condition (eg; BPH, Diverticula).

Treatment

1. Litholapaxy

This is method of choice for bladder stone. This is crushing of a stone in bladder by a cystoscopic lithotrite, which is passed in the urinary bladder through urethra. The crushed stone is then removed by an evacuator (Ellik's) connected to the cystoscope.

Contraindication

(i) Stones secondary to BPH, stricture of urethra, or a foreign body
(ii) Age less than 10 years
(iii) Very large stone
(iv) Very hard stone
(v) Contracted bladder

2. Supra pubic Cystolithotomy

[Supra pubic + cysto+lithotomy]

This is removal of a vesical stone; after opening the bladder through a suprapubic approach followed by closure of bladder wall. A foley's catheter is passed in bladder for free drainage of urinary bladder.

3. Percutaneous supra pubic litholapaxy

This is the method of choice, when litholapaxy it is not possible per urethra, because of stricture in urethra.

4. Hydraulic lithotripsy

5. ESWL: This has been discussed in previous chapter on page no. 812-813.

*****

CARCINOMA OF THE BLADDER

Carcinomaof bladder may be of three cell types:-

1. **Transitional cell carcinoma (>90% M/C)** (NEET, MANY PGME)
2. Squamous cell carcinoma (approx 5%)
3. Adenocarcinoma (1-2 %); lets take them one by one

Types

1. Transitional Cell Carcinoma

- **This is most common type of carcinoma of urinary bladder.** (MANY PGME)

Risk factors/etiology (PGI 01, AI 91)

1. **Cigarette smoking** (AI 07, AIIMS 10) **, Tobacco** (NEET)
2. Occupational exposures of chemical : *Aniline dye (2 naphthylamine). Benzidine. Acrolein, thorotrasta.*
3. ***Schistosoma hematobium:*** It is a risk factor for both: Transitional cell carcinoma and Squamous cell carcinoma. (MANY PGME)
4. Drugs such as **Phenacetin** (NEET) & tryptophan metabolite.
5. Chronic cystitis
6. *Cyclophosphamide therapy*
7. Radiation therapy

8. The change in the given of human chromosome 9 is usually responsible for tumour in bladder cancer.

2. Squamous cell carcinoma (PGI 97, 02)

- They constitute 5% of cases of carcinoma bladder.
- It results from **prolonged irritation by infection** (NEET) or stones, and as a result of metaplasia.
- It is most prevalent form of bladder cancer in areas *where Schistosomiasis is endemic.* (MANY PGME)

Schistosomiasis leads to Squamous cell carcinoma

3. Adenocarcinoma

- They constitute 1-2% of cases of carcinoma bladder.
- It usually arises in the fundus of the bladder, **at the site of the urachal remnant** (NEET).
- It may also arise* at other sites; chiefly from areas of metaplasia.
- Such tumours need to be differentiated from secondary cancer from prostate, rectum or cervix.

Pathology

1. Carcinoma in situ

- This accounts for about 5% of cases.
- There occurs dysplastic changes in transitional cell line urothelium, with no involvement of deeper layers.
- These changes are subtle, with comprising loss of polarity and high mitotic index. These may subsequently develop in invasive bladder cancer.

2. Superficial bladder cancer

- These are located most commonly in trigone and lateral wall of bladder. (AIIMS 85)
- These are papillary tumours which have remained confined to the urothelial layer (mucosa) and to the tumours that have penetrated the basement membrane into the lamina propria. (AI 91)
- They have an increased tendency to recur and to become truly invasive and *accounts 50-70%* of all cases of bladder cancer (most common type). (PGME)

3. Invasive bladder cancer

- They are usually solid and account for 25%.
- The tumour invades the muscle either superficially, deeply or through the wall to invade the serosa and may also invade the prostate, uterus or vaginal wall or may become fixed to the wall of the pelvis.
- Metastases occur in the internal iliac lymph nodes and then spread to the para-aortic lymph nodes.

KEY BOX 45.1

Staging of urothelial cancer

PRIMARY TUMOR (T)	
TX	Primary tumor cannot be assessed
T0	No evidence of primary tumor
Ta	Noninvasive papillary carcinoma
Tis	Carcinoma in situ: "flat tumor"
T1	Tumor invades subepithelial connective tissue
T2	Tumor invades muscularis propria
pT2a	Tumor invades superficial muscularis propria (inner half)
pT2b	Tumor invades deep muscularis propria (outer half)
T3	Tumor invades perivesical tissue:
pT3a	Microscopically
pT3b	Macroscopically (extravesical mass)
T4	Tumor invades any of the following: prostatic stroma, seminal vesicles, uterus, vagina, pelvic wall, abdominal wall
T4a	Tumor invades prostatic stroma, uterus, vagina
T4b	Tumor invades pelvic wall, abdominal wall

Please also see figure 45.8

KEY BOX 45.2

REGIONAL LYMPH NODES (N)

Regional lymph nodes include both primary and secondary drainage regions.
All other nodes above the aortic bifurcation are considered distant lymph nodes.

NX	Lymph nodes cannot be assessed
N0	No lymph node metastasis
N1	Single regional lymph node metastasis in the true pelvis (hypogastric, obturator, external iliac, or presacral lymph node)
N2	Multiple regional lymph node metastasis in the true pelvis (hypogastric, obturator, external iliac, or presacral lymph node metastasis)
N3	Lymph node metastasis to the common iliac lymph nodes

DISTANT METASTASIS (M)

M0	No distant metastasis
M1	Distant metastasis

- More distant spread occurs to the liver, lungs & brain.
- Local spread may occlude one or both of the ureters, leading to hydronephrosis and uremia. *(PGME)*

Clinical features

1. **Painless intermittent hematuria is the commonest symptoms*.** It is present in up to 95% of patient, later hematuria may become continuous. *(AIIMS JUNE 97, SEP 96, PGI DEC 95, AIIMS 10, AI 09)*
2. Features of cystitis such as pain, frequency, burning micturition may be present.
3. Renal pain may be present, when growth obstructs ureteric opening.
4. Symptoms of advanced disease include bone pain from bone metastases or flank pain from retroperitoneal metastases or ureteral obstruction.

Investigation

- Urine examination for malignant cells should be generally be the first test. *(IMP. POINT, MANY PGME, AIIMS 06, AI07, AIIMS 10)*
- When malignant cells appear in a urine cytological examination, cystoscopy and biopsy of lesion is indicated. Random biopsies are taken, when no gross lesion appear. Usually biopsy of **six areas** of the bladder is performed, including the trigone, lateral walls and dome.
- **Cystoscopy** is the *mainstay of diagnosis* and allow direct examination of growth and the biopsy can be taken at the same time. *(MANY PGME)*.

Cystoscopy = visualization of interior of urinary bladder by an endoscope.

- Intravenous urography shows filling defect (defect in filling of dye), irregularity of the bladder wall and hydroureter and hydronephrosis; if the same is present.
- CT scan of abdomen and pelvis is done for extension and staging of tumour.
- Tumor marker for Ca UB :
  - NMP 22
  - BTA stat
  - BTA-TRAK

* NMP = Nuclear matrix protein

* BTA = Bladder tumor antigen

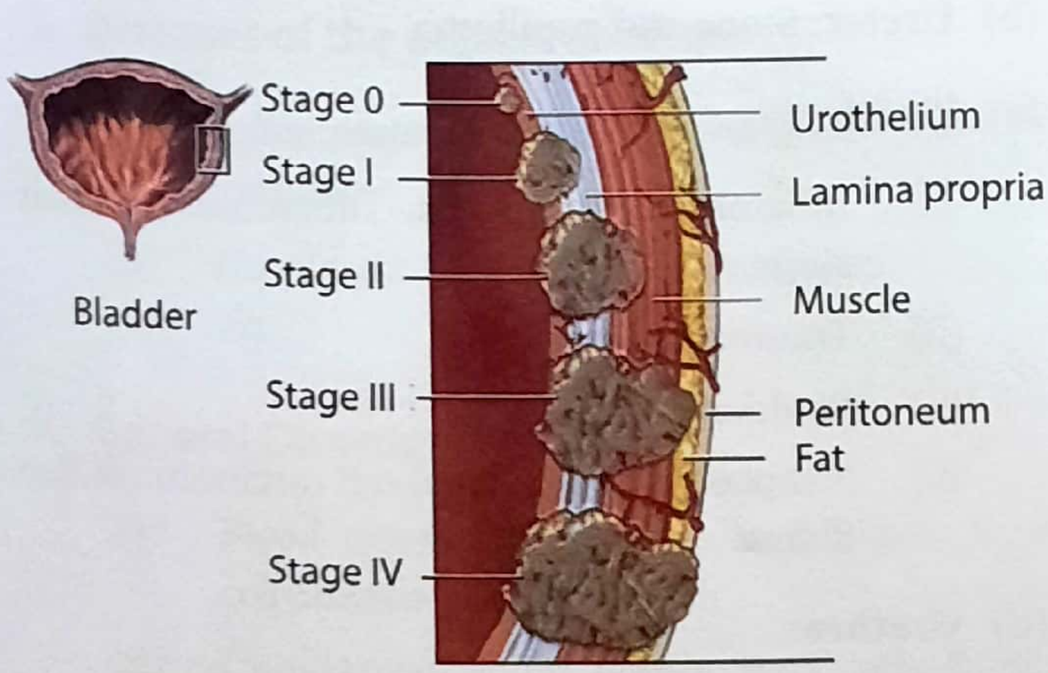

Figure 45.8: Stage of bladder carcinoma (read text)

Management

A. For superficial tumours (Ta, T_1) *(UP 08)*

- Initial treatment of superficial **tumour is by transurethral resection of the tumour**(NEET). However the overall incidence of recurrence is about 50%.
- For those with recurrence; treatment with **intravesical chemotherapy**(NEET) should be considered.
- The therapeutic agents used are ***intravesical*** BCG, mitomycin C, thiotepa. *(PGME, AI)*
- If patient is unresponsive to BCG, radical cystectomy is done.
- Periodic survillance is mandatory in these patients.
- Enhanced cystoscopy using blue light technology with hexaminolevulinate or narrow band imaging can improve detection & lower recurrence rate.

B. For invasive tumours (T_2, T_3, T_4) *(AI 2011)*

- **Radical cystectomy**, followed by some form of continent urinary diversion or a bladder substitution procedure (ileal conduit).
- Ileal conduit is best for urinary diversion after cystectomy.
- **Preoperative radiotherapy with neoadjuvant chemotherapy**(NEET) is now thought to provide a higher 5-year survival rate.

Figure 45.9: Carcinoma bladder specimen

- Typical regimen for neoadjuvant chemotherapy include methotrexate, vinblastine, adriamycin & cisplatin (MVAC) or gemcitabine & cisplatin.

C. For metastatic tumours

- Systemic chemotherapy followed by selective surgery or irradiation.

*****

HEMATURIA

- Hematuria is appearance of erythrocytes or red blood cells (RBCs) in the urine. The urine may appear bright red to coffee coloured, depending upon the age and number of RBCs in the urine.
- Five hundred RBCs per high powered field are necessary for human eye to perceive gross hematuria. Hemoglobinuria, myoglobinuria and other causes of red urine must be separated from hematuria.

Causes of Hematuria

1. Lesions of the urinary tract

(a) Kidney

(i) Congenital: Polycystic kidney disease.
(ii) Traumatic: renal trauma
(iii) Inflammatory glomerular nephritis, Tuberculosis.
(iv) Stone
(v) Neoplastic: Angioma, Transitional cell carcinoma, Wilm's tumour, Hypernephroma, Papilloma.
(vi) Others: Infarction

(b) Ureter: Stone and papilloma.

(c) Bladder:

(i) Inflammatory: Cystitis, Tuberculosis, Bilharziasis.
(ii) Traumatic: Rupture.
(iii) Bladder stone
(iv) Neoplastic: Transitional cell carcinoma & Papilloma

(d) Urethra:

(i) Traumatic: Rupture.

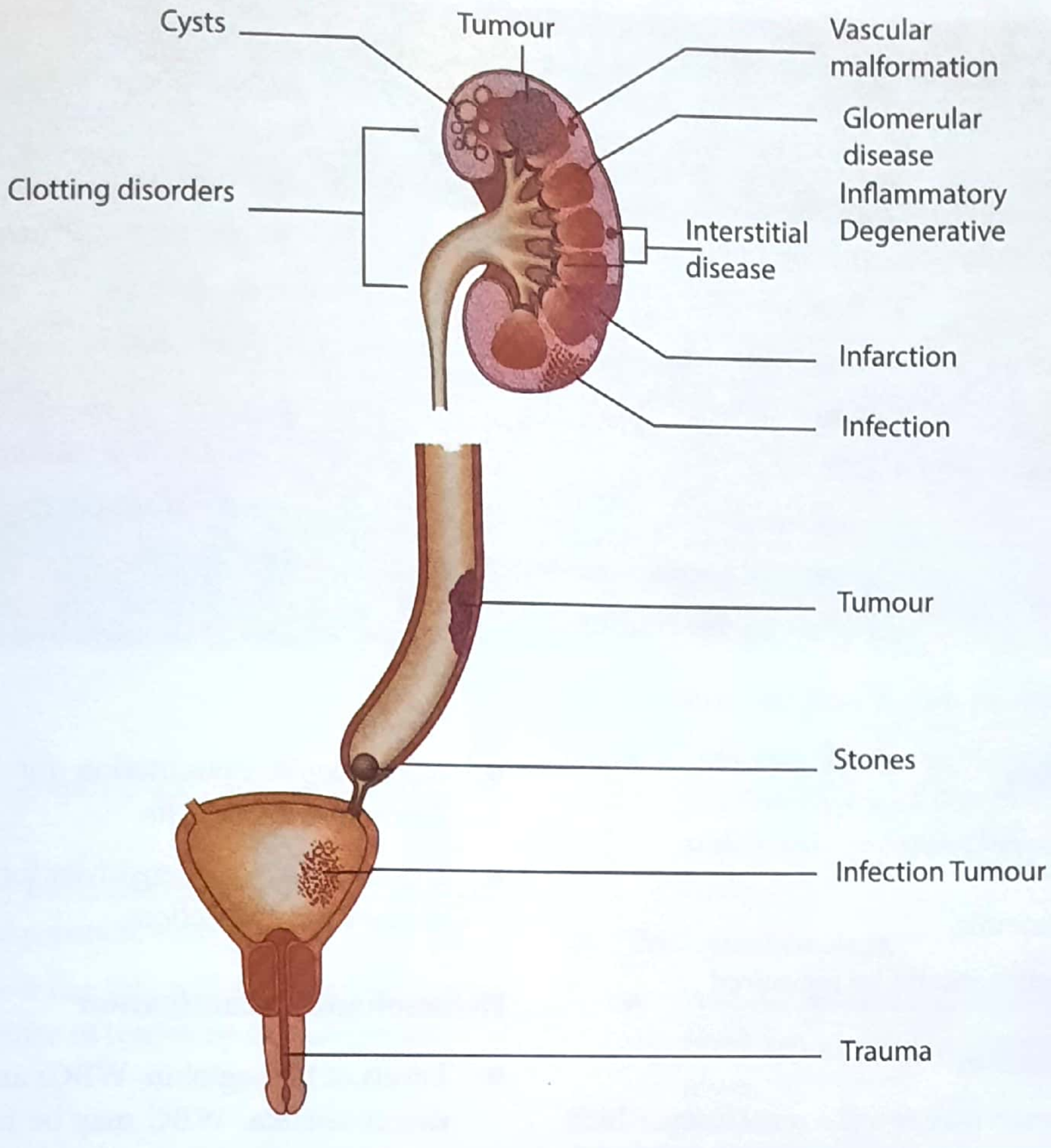

Figure 45.10: Common causes of hematuria

(ii) Inflammatory: Acute urethritis
(iii) Transitional cell carcinoma.
(iv) Stone

(e) Prostate: BPH and Ca Prostate

2. Diseases of the adjacent viscera

(a) *Inflammatory:* Acute appendicitis, Acute salpingitis.
(b) *Neoplastic:* Carcinoma of the rectum and cervix

3. General Disorders

(a) *Blood disorders:* Hemophilia, Malaria, Sickel cell anemia
(b) Congestive cardiac failure, renal vein thrombosis.

4. Drugs

Anticoagulants, Sulphonamides, NSAIDS:

NOTE: Common causes of hematuria are given in a tabular form in key box 45.3 next page and in figure 45.10.

What should the patient be asked about hematuria:

- The physician must determine whether the hematuria is initial (meatal and urethral) or total (bladder or renal origin) or only terminal (from bladder neck, the prostatic urethra and prostate) Please see box 45.3, 45.4; on next page 844.

- Painless gross hematuria with passage of clots in a patient older than 50 year indicate carcinoma of bladder until proved otherwise *(PGME)*

KEY BOX 45.3		
Causes of Hematuria in Various Age Groups		
Child (<15 year)	**Young Adult**	**Older (>50 years) Adult**
• Infection of urinary tract • Exercise • Glomerulonephritis • Trauma • Congenital anomaly • Drug ingestion • Stone • Neoplasm	• Infection of urinary tract • Trauma • Drug ingestion • Stone • Exercise • Neoplasm • Abnormal hemoglobin level • Renal vascular disorder	• Infection of urinary tract • Neoplasm • Medication • Stone • Enlarged prostate (in males) • Renal vascular disorder

Physical Examination

1. General examination

(a) Check for anemia

(b) Blood pressure should be measured

2. Physical examination

Examination of abdomen may reveal a renal lump, which is bimanually* palpable and ballottable **. Figure 45.11.

Some times a distended bladder may be palpable, especially when there is bladder outflow obstruction.

3. Examination of external genitalia.

4. Digital rectal examination (DRE) may reveal a carcinoma of prostate, BPH or a rectal growth, if present.

* *Bimanually palpable lump?:* Relating to, or performed by both hand.

** *Ballottable lump?:* A maneuver in which the kidney is moved up by pushing from behind (post abdominal wall), allowing it to be felt on the hand placed on anterior abdominal wall (Figure 45.11). The size, shape and mobility can be determined.

Investigations

Urinary examination

- Dipstick Test: It is a useful test for diabetes and renal and hepatic disease.
- The urinary P_H, levels of glucose, protein, ketones and blood should be checked.
- Microscopic examination for RBC, WBC, Casts, Crystals and pus cells.
- Urine culture and sensitivity for bacteria involved to urinary tract infection.

Hematological examination

- Levels of hemoglobin, WBCs and platelets may help detect anemia. WBC may be raised in presence of urinary tract infection.
- Serum urea and creatinine are raised in patients with renal failure.
- Serum Calcium, phosphates, uric acid are used for screening metabolic disorders in patients with renal calculi.
- Serum acid phosphatase, prostate specific antigen (PSA) are tumour markers for prostatic cancer.
- Carcino-embryogenic antigen (CEA): The level is raised in adenocarcinoma of the kidney.

Imaging study

- Abdominal radiograph especially kidney, ureter and bladder (KUB) to detect urinary calculi.

KEY BOX 45.4	
Hematuria (with respect to micturition)	
Initial	Meatal and/or urethral origin
Total	Bladder or renal origin
Terminal	Bladder neck and prostatic origin (UP 04)

Figure 45.11: Method of examination of a renal lump

- Intra venous Urography (IVU) will delineate the entire urinary tract.
- Ultrasonography for assessment of urinary tract calculi, tumour and prostatic enlargement
- CT Scan will show the size and site of urogenital tumours and presence of lymph node metastases.

Treatment

Definitive treatment of the hematuria depends upon the cause, which have been discussed in this book in respective sections, some of them are listed here:

Renal stone - ESWL or PCNL or Nephrolithotomy

Renal tumour (if operable) -radical nephrectomy / chemotherapy

Ureteric stone - Endoscopic treatment or ureterolithotomy

Bladder stone - ESWL or Litholapaxy or Cystolithotomy

BPH- TURP/ Open prostatectomy

Ca prostate- Radical prostatectomy/ Hormone ablation.

URINARY INCONTINENCE

- It is leaking of urine which can't be controlled. Continence is dependent on normal mobility & brain function.

(1) **Overactive bladder** - Phasic increase in pressure give rise to urgency & urge incontinence (detrusor overactivity) found in patients with neurogenic bladder dysfunction. Idiopathic detrusor overactivity is common.

(2) **Genuine stress incontinence (GSI)** - Urinary leakage recurring during increased bladder pressure due to increased abdominal pressure. It is more common in women.

(3) **Bladder outflow obstruction**
- Increased voiding pressure, decreased flowrate
- Overflow incontinence

Causes of incontinence

Male incontinence

1) **Chronic urinary retention with overflow**
- This may be due to benign prostatic hypertrophy, carcinoma of the prostate, urethral stricture and, in younger men, hypertrophy of the bladder neck.

2) **Post-prostatectomy**
- Post-prostatectomy incontinence may result from injury to the external sphincter mechanism.

Female incontinence

Stress incontinence

- The most common cause is GSI (Genuine stress incontinence) although, in some parts of the world, vesicourethral fistulae as a result of neglected labour are common.

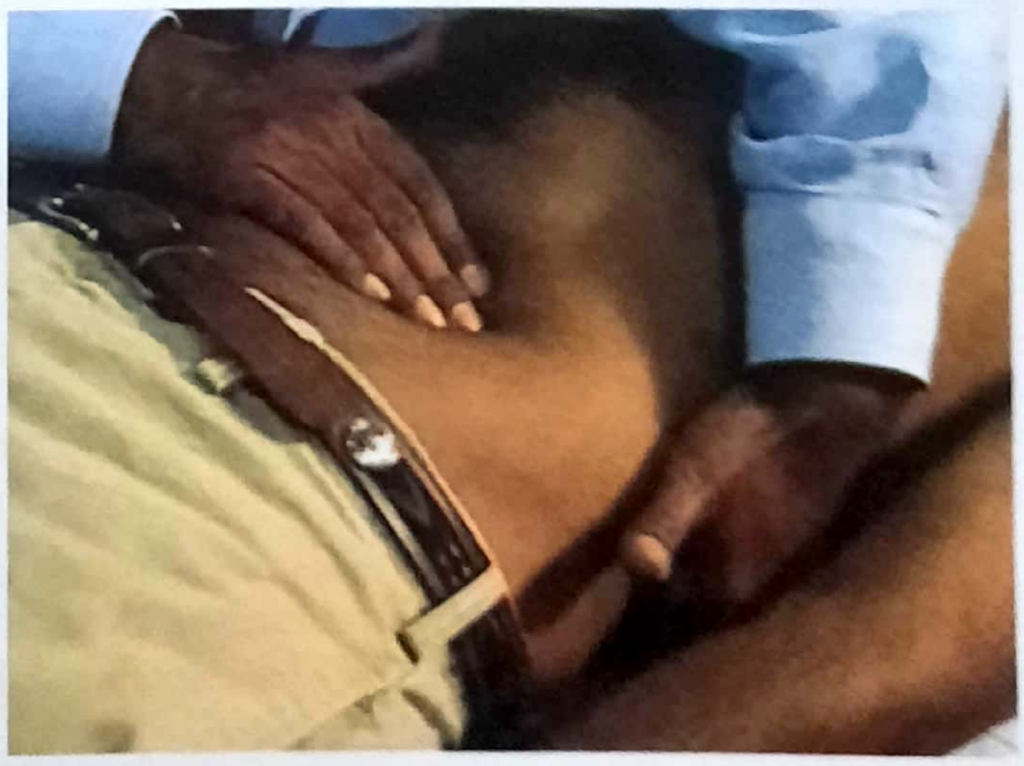

Figure 45.12 : Method of palpation of kidney from behind

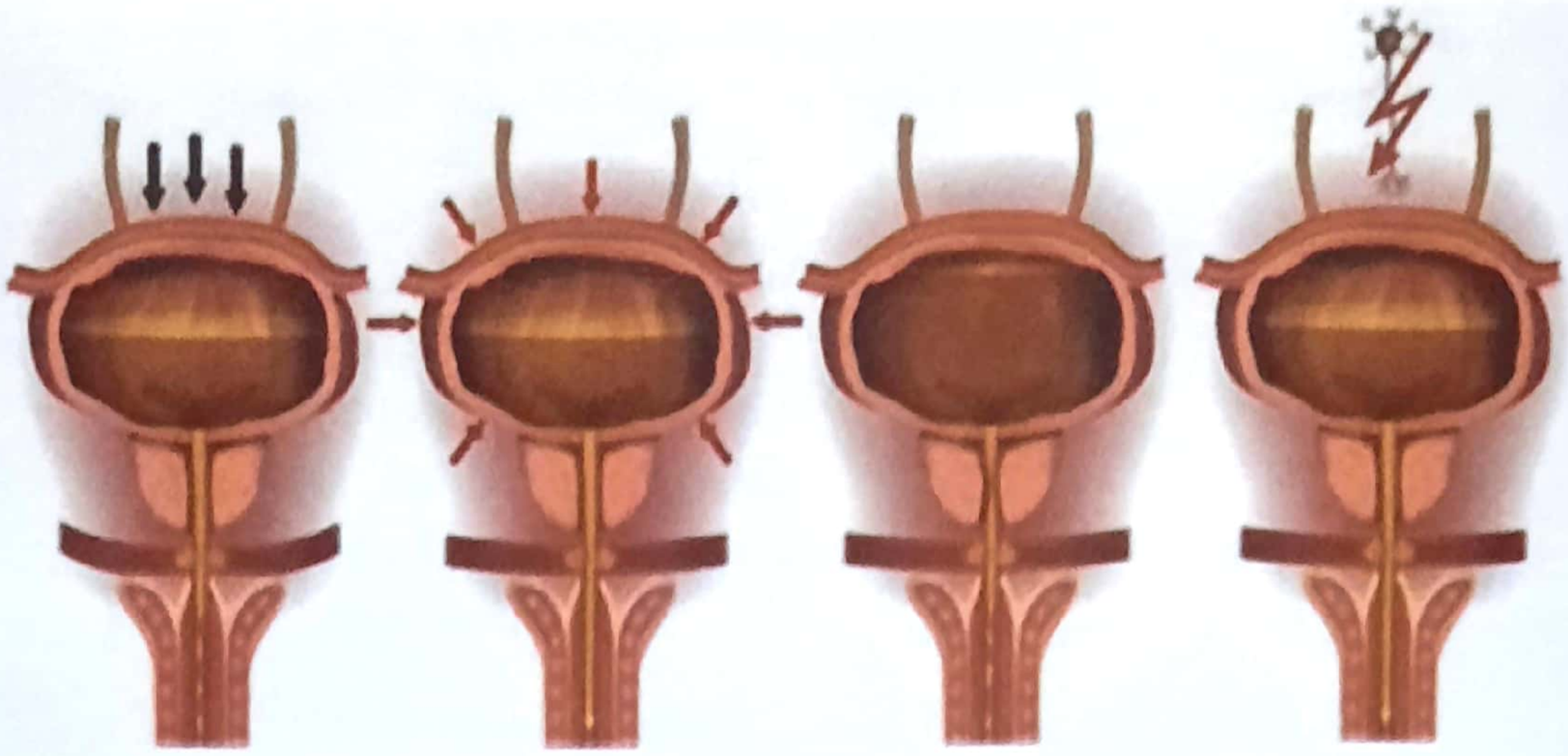

Stress Incontinence due to increased abdominal pressure under stress (weak pelvic floor muscles)

Urge Incontinence due to involuntary contraction of the bladder muscles

Overflow Incontinence due to blockage of the urethra

Neurogenic Incontinence due to impaired functioning of the nervous system

Figure 45.13 : Types of Incontinence (Incontinentia vesicae)

- Idiopathic detrusor instability can mimic GSI and coexist with it. It is important to make a correct preoperative diagnosis by urodynamic measurements, because the outcome of surgery is suboptimal in women with idiopathic detrusor instability. Minor-to-moderate stress urinary incontinence can be controlled by pelvic floor exercises. However, if this fails, surgery is indicated. Standard operations include open colposuspension or the use of a minimally invasive approach involving the insertion of a transvaginal tape (TVT procedure).

Incontinence common to both sexes.

Idiopathic detrusor overactivity

Phasic increases in bladder pressure may occur during filling in otherwise normal patients (idiopathic) or it may be found in neurogenic bladder dysfunction (when it is known as detrusor hyperreflexia) and bladder outflow obstruction.

Ageing

Ageing can result in smooth muscle cell dysfunction, which can cause combinations of small functional capacity, detrusor overactivity, impaired bladder emptying and symptoms of lower urinary tract dysfunction.

Congenital

Congenital causes include ectopic vesicae and severe epispadias. The abnormal entry of an ectopic ureter distal to the sphincter complex or into the vagina in a female patient should theoretically result in total urinary incontinence.

Trauma

Trauma, whether from pelvic surgery or associated with pelvic fracture, may result in disruption of the nerve supply to the bladder or urethra, or in fistula formation.

Infection

Lower urinary tract infection (UTI) may be sufficient to induce urinary incontinence.

Neoplasia

Other causes

(1) Constant dribbling of urine coupled with normal micturition

- This occurs when there is a ureteric fistula or an ectopic ureter associated with a duplex system opening into the urethra beyond the urethral sphincter in females or into the vagina.

(2) Nocturnal enuresis

- This is a condition of young children and young adults. Of course, the time at which children become dry at night varies and, in some, nocturnal enuresis is merely a delayed onset of continence.
- Primary nocturnal enuresis occurs in patients with nocturnal symptoms alone, which are absent during the day. Often, they have been dry for a period, and the vast majority of patients will eventually become dry. In the meantime, a sympathetic approach to these children is essential. They often respond to a system of rewards using a 'star' chart. In addition, the use of DDAVP (a vasopressin analogue) can produce increased urinary concentration at night with a decrease in nocturnal incontinence. Other treatments include the use of an alarm that wakes the child (or at least the child's parents) when incontinence occurs and medication in the form of an anticholinergic drug such as oxybutynin.

Diagnosis

Careful history & examination, urodynamic testing in all patients. Urine culture to exclude infection.

Treatment

Treatments for incontinence can be summarised as follows:

(1) Conservative measures such as lifestyle interventions, pelvic floor muscle and bladder training.

(2) Devices for collection: external penile condom or an indwelling urethral or suprapubic catheter.

(3) Drugs: to decrease the strength of the bladder neck (e.g. adrenergic blockers); with mixed action on the bladder neck and central nervous system (e.g. tricyclic drugs); to inhibit bladder activity (e.g. anticholinergic drugs). Botulinum toxin A is used in selected patients. Duloxetine can be used as medical treatment for GSI – it is a serotonin– noradrenaline reuptake inhibitor.

(4) Intermittent self-catheterisation: to improve emptying.

(5) Increasing outlet: pelvic floor physiotherapy; resistance colposuspension or TVT tapes or slings; periurethral injections of 'bulking agents' such as cross-linked collagen or other particles; use of the artificial urinary sphincter.

(6) Denervation of bladder: S3 sacral nerve blockade, neurectomy or surgical transection of the bladder to inhibit bladder activity and improve functional capacity. These are rarely used nowadays because of the use of botulinum toxin and the clam cystoplasty or S3 nerve stimulation (see point 7).

(7) Sacral nerve stimulation devices can improve incontinence. They involve percutaneous insertion of electrodes through the sacral foramina under radiological control and implantation of an electronic stimulator.

(8) Augmentation of bladder: ('clam' enterocystoplasty), bladder capacity substitution with detubularised bowel segment.

(9) Urinary diversion: ileal conduit, continent urinary diversion.

*****

Sample Questions for Prof Examination

1. What are primary and secondary urinary stones.
2. Describe the clinical features investigation, and treatment of a case of vesical calculus.
3. What are the type of calculi that occur in the urinary bladder?
4. Define primary & secondary bladder stones. How will you manage a case of 10 mm stone at V.U. junction on Right side?
5. Discuss the causes and investigation of a case of hematuria.
6. Discuss etiology, pathology, clinical features, diagnosis and management of a case of Ca urinary bladder?

46 The Prostate

Contents

- Surgical Anatomy
- Benign Prostatic Hyperplasia
- Carcinoma of prostate
- Bladder out flow obstruction due to bladder neck disease
- Acute Prostatitis
- Chronic Prostatitis
- Prostatic Calculi
- Chronic pelvic pain syndrome
- Retention of urine

NOTE: Only two organs in the body are broader than they are long; these are (i) prostate and (ii) cecum

- The *prostate is composed of three elements; the fibrous, muscular and the glandular element.*
- The prostate is incompletely divided into **five lobes:** Anterior, Posterior, 2 lateral and one middle (or median lobe).
- The anterior lobe lies in front of the urethra and is devoid of glandular tissue. The median or middle lobe is situated between the urethra and ejaculatory ducts. The posterior lobe is situated behind the urethra and below the ejaculatory ducts and also contains glandular tissue, (help your self with fig. 46.1 & 2)
- The right and left lateral lobes lie on either side of the urethra and are *separated from one another by a shallow vertical groove (sulcus)* on the posterior surface of prostate. The lateral lobes contain many glands in is often the site of benign hyperplasia.

SURGICAL ANATOMY

- The prostate is an accessory gland of the male reproductive system. The secretion of this gland adds bulk to the seminal fluid.
- Prostate lies in the pelvis, below the neck of the urinary bladder & surrounds the first 3cm of the urethra.
- It resembles an inverted cone; measuring about 4 cm transversely, 3cm vertically and 2cm anteroposteriorly, ie; 4×3×2 and it's weight is about 10-15 grams.

Zonal Anatomy of The Prostate

- McNeal in 1968 has popularized the concept of zonal anatomy of the prostate. Three distinct zone has been identified, *(KAR 06)*

(i)	Peripheral zone	- accounts for about 70%
(ii)	Central zone	- accounts for 25%
(iii)	Transitional zone	- accounts for 5%

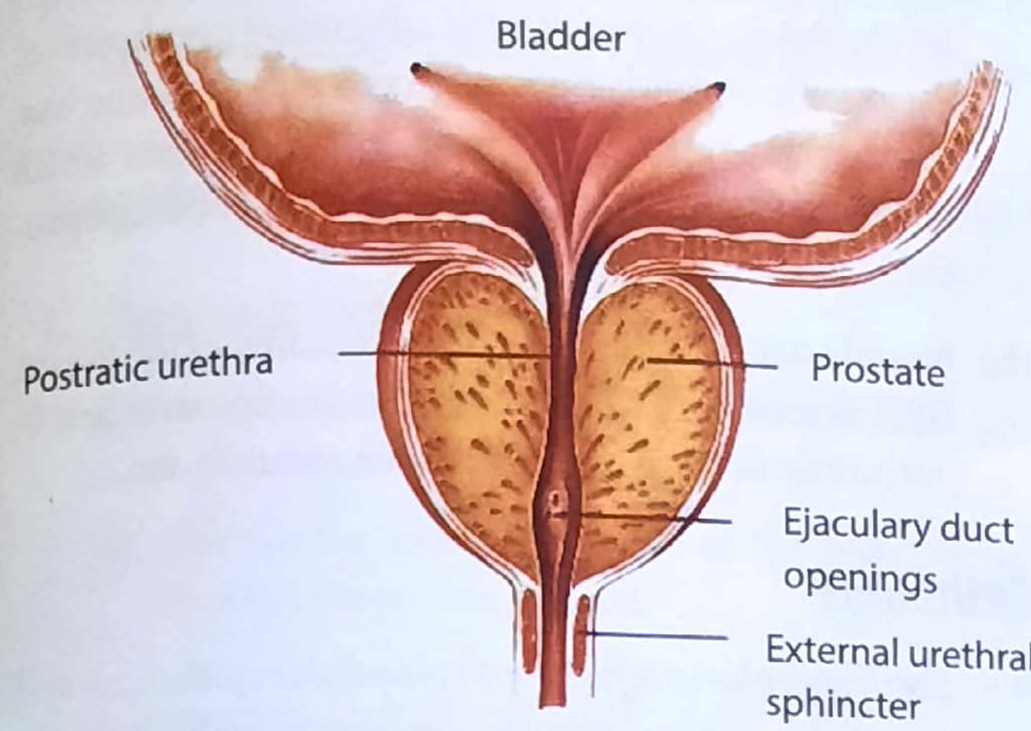

Figure 46.1: Anatomy of prostate in coronal section

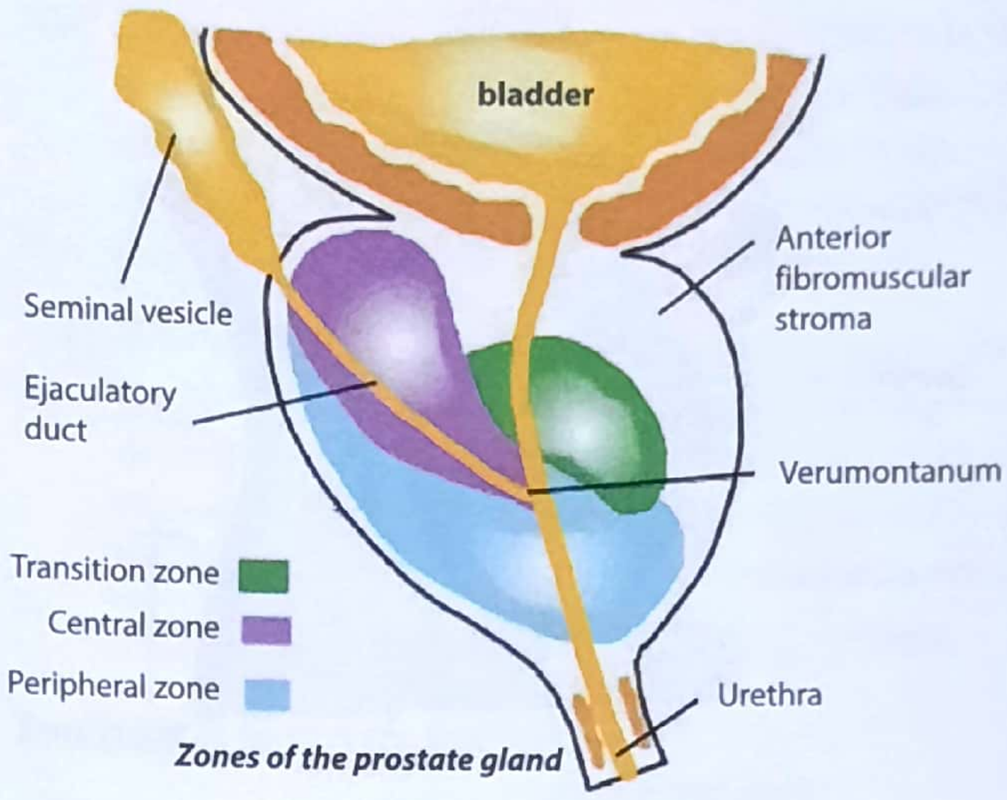

Figure 46.3: Prostate in sagittal section

Capsules of Prostate

There are two capsules of the prostate - true and false.

(i) **True capsule** is formed by condensation of the peripheral part of the gland. It contains no venous plexus.

(ii) **False capsule** is formed by the visceral layer of the pelvic fascia.

- The *prostatic venous plexus (of Bateson)* lies between the two capsules. This plexus receives in front; the deep dorsal vein of penis and ends in the internal iliac veins and has free communication with vertebral plexus, it is because of this communication; prostatic carcinoma metastesize early to lumbar vertibrae. *(IMP. POINT)*

- There is also a capsule known as *surgical capsule,* which develops only in case of benign hypertrophy of the prostate and is formed by the non-adenomatous tissue of the prostate which is pushed to the periphery of the gland (prostate) by the adenoma of the prostate.

*****

BENIGN PROSTATIC HYPERPLASIA (BPH)

FRIENDS! This is a very important topic. You will definitely get questions in final prof exam, or in viva or in PGMEE. Kindly read it carefully. It will require revisions, so revise it for at least 3 times.

- BPH is the most common benign tumour in men and its incidence is age related. The prevalence of BPH at autopsy rises from approximately 20% in men aged 41-50, to 50% in men aged 51-60 and to over 90% in men older than 80 years. Although clinical evidence of disease occurs less commonly.

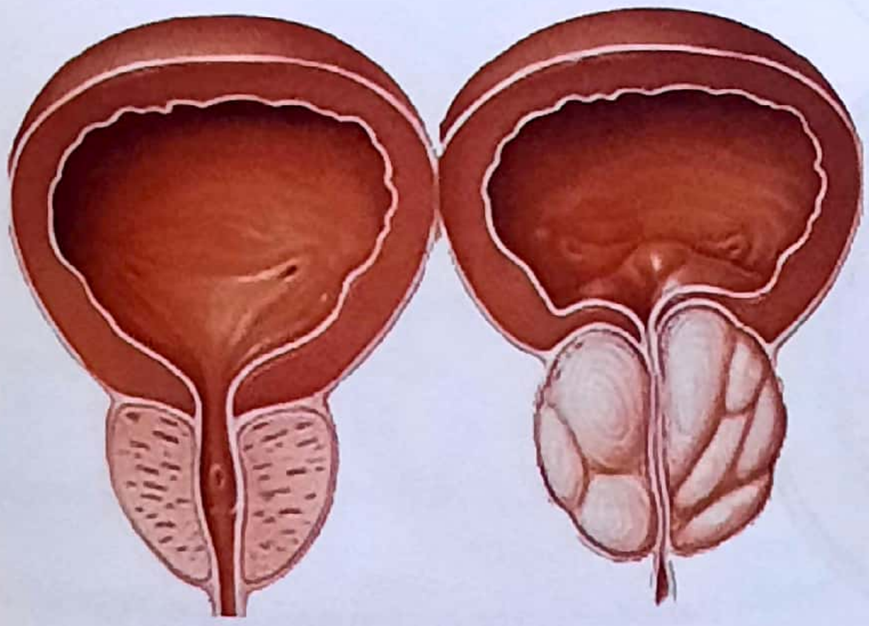

Figure 46.2: (A) Normal prostate (B) Benig prostatic hyperplasia - Coronal section

KEY BOX 46.1

BPH arises most commonly in **transitional zone** and **carcinoma** irises **most commonly In peripheral** *zone.*
(AI 89, MANY PGME)

Remember with this:

CA **P**rostate → **P**eripheral zone

BPH in TZ → BPHTZ

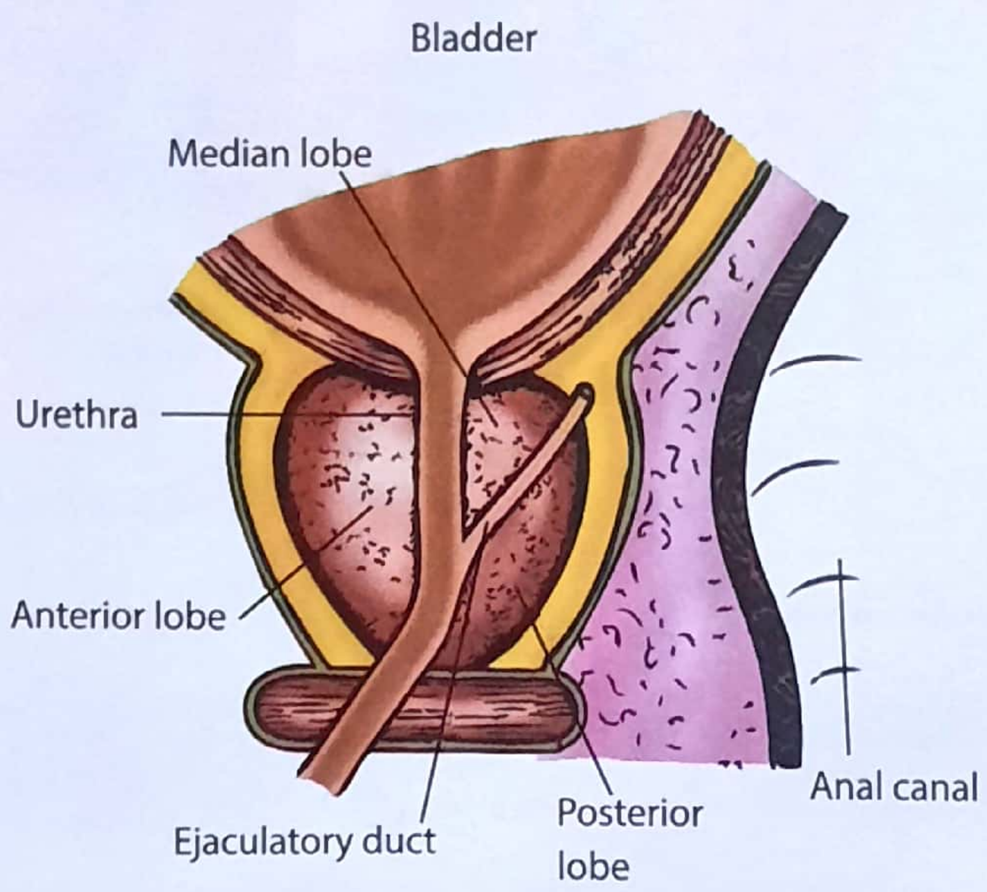

Figure 46.4: Prostate in sagittal section

- At age 55, approximately 25% of men report obstructive voiding symptoms. At age 75, 50% of men complains of a decrease in the force and caliber of their urinary stream.

Etiology

The etiology of BPH is not completely understood, but it seems to be multi factorial and under endocrine control. Two theories have been proposed:-

(a) Hormone theory: The prostate is influenced by both androgen and estrogen. Serum testosterone levels slowly decreases with advancing age; however, estrogenic steroids do not decrease in the same way. So there is relative increase in the estrogen which stimulates the prostate gland and causes benign prostatic hyperplasia.

(b) Neoplastic theory: Like fibroadenoma of the breast, BPH is a benign tumour which usually starts first in periurethral transitional zone or central zone.

Pathology

- The *hyperplasia affects both glandular epithelium and connective tissue stroma* and is similar to hyperplasia occurring in breast (in which adenosis, epitheliosis and stromal proliferation take place)
- **It typically affects submucous group of glands in the transitional zone;** (NEET) forming a nodular enlargement → (median lobe).
- Eventually; when it increases in size, it compresses the outer peripheral zone (lateral lobes) of the prostate, forming a false capsule.
- If it affects the central zone, *a 'middle' lobe develops,* which projects into the bladder within the internal sphincter and causes ball valve type of obstruction.
- Lateral lobes of prostate may project into bladder forming an intravesical prostatic collar. (fig. 46.4 & 46.5)

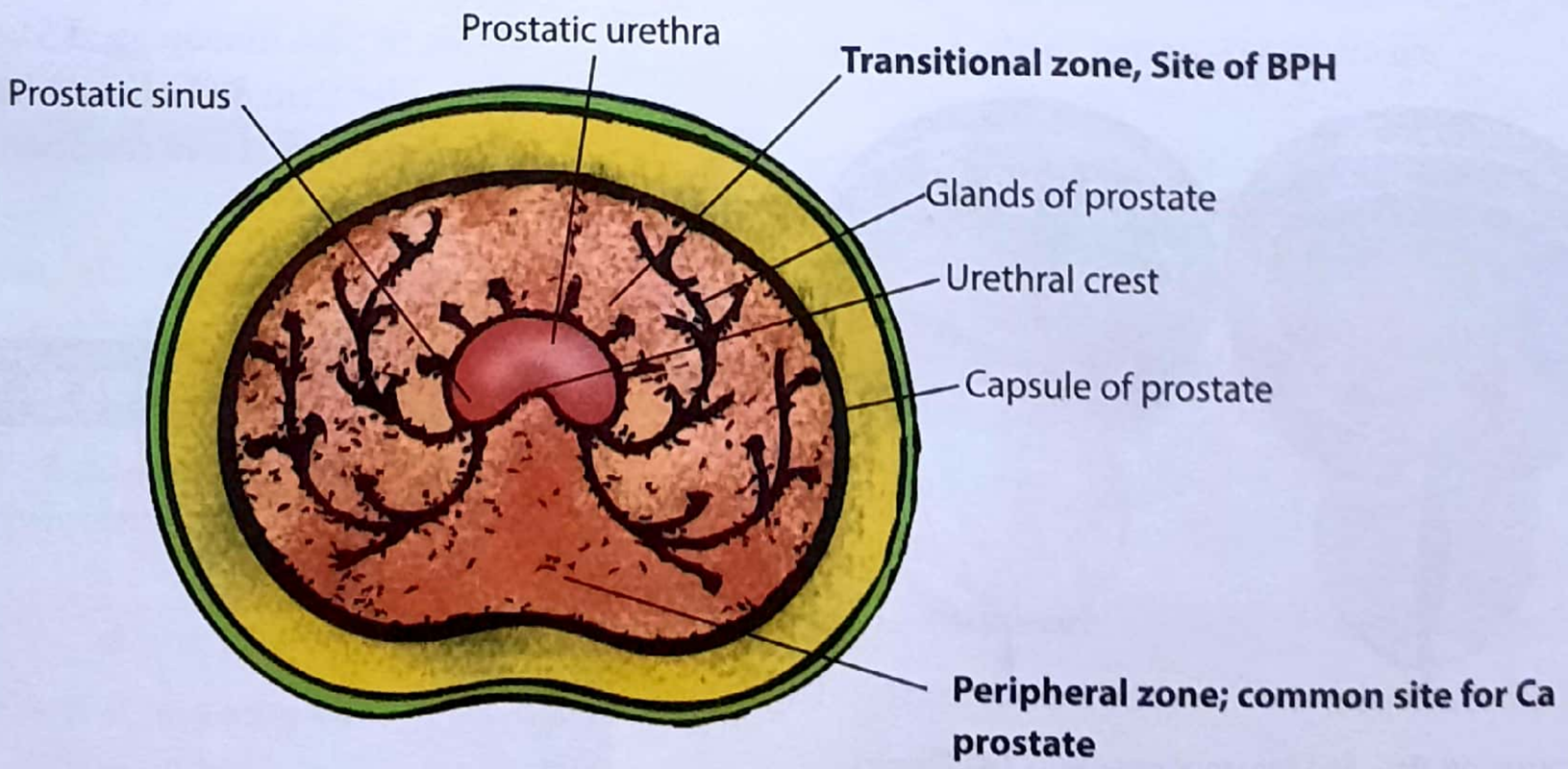

Figure 46.5: Prostate in horizontal section

- Histologically; variable degree of both glandular elements and connective tissue elements are encountered.

Secondary Effects due to Prostatic Enlargement

1. Changes in urethra

(i) As a result of increase in the size of prostate, prostatic urethra is lengthened.

(ii) The normal posterior curve of the prostatic urethra becomes exaggerated.

2. Changes in Urinary Bladder (AIIMS 98, AI 91)

Changes in the bladder are due to bladder **outlet** obstruction, as a result of enlarged prostate obstructing urinary outflow.

(i) As the degree of obstruction increases, the vesical detrusor muscle undergoes compensatory hypertrophy, to overcome the increasing resistance, hence the muscle of bladder wall become thickened & hypertrophied.

(ii) Due to urethral obstruction along with compensatory hypertrophy of detrusor muscle; the interior of urinary bladder under goes anatomical changes, which results in:

(a) *Trabeculation of* the bladder wall
(b) *Sacculation of* the bladder wall
(c) Formation *of diverticula* in bladder wall.

(iii) Vesical diverticula empty poorly and are liable to three important complication: cystitis (sepsis), stone formation and tumour. See key box 46.2.

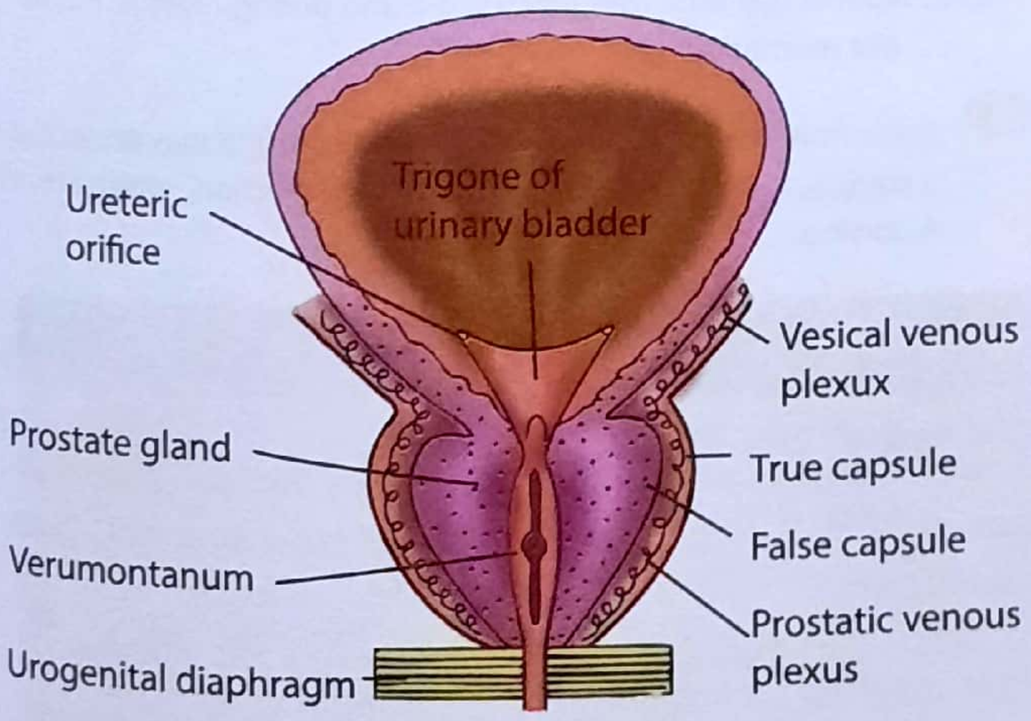

Figure 46.6: Anatomy of prostate, note prostatic venous plexus, true and false capsule

(iv) Enlarged prostate may compress on the prostatic venous plexus; which lies between the true and false capsule of the prostate and may cause congested vein; also called as ***'vesical piles'*** at the base of the bladder (PGME). Rupture of the vesical pile may cause hematuria.

(v) When the median lobe enlarges and projects into the bladder through the internal sphincter, a *pouch develops in bladder and is called as* ***prostatic pouch.*** (Figure 46.7) Urine get collected in this pouch and hence patient cannot evacuate completely. The stagnant pool of urine is called as ***residual volume.***

3. Changes in ureters and kidney

With increasing obstruction in the out flow, the increased pressure in the bladder is transmitted back wards to ureters and kidney:- resulting in hydroureter and hydronephrosis.

KEY BOX 46.2

↑Back Pressure Effects Due to BPH
↓
Degree of bladder outflow obstruction
↓
Bladder muscle (detrusor) hypertrophy
↓
Trabeculation in bladder wall
↓
Sacculation in bladder wall
↓
Diverticula formation in bladder wall
↓
Urinary stasis
↓
Infection and stone formation
↓
Further more High pressure in bladder, is transmitted back to ureters and kidney
↓
Hydro-ureter & Hydronephrosis
↓
May lead to CRF

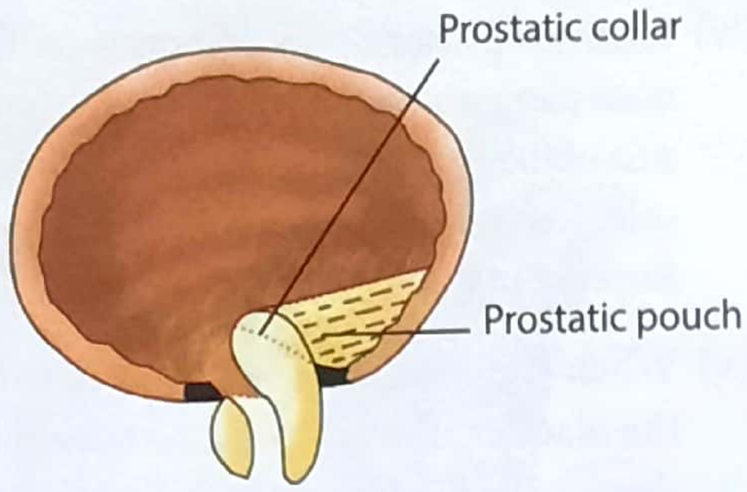

Figure 46.7: Note development of prostatic pouch (collar) in bladder due to enlargement of median lobe of prostate

Clinical Features

- *As* mentioned earlier; benign enlargement of prostate seldom cause symptoms before the age of 50 years. .
- It should be clear to every one, that *there is no direct relation between the degree of prostatic enlargement and severity of symptoms.*
- The symptoms due to enlarged prostate is called as **'Prostatism'.** It can be classified in two groups: ***Obstructive*** and ***irritative.*** Many urologists now prefer the term 'Lower Urinary Tract Symptoms' (LUTS) instead of prostatism.

Symptoms

1. Lower urinary tract symptom (LUTS)/ Prostatism

It is divided as Voiding and Storage symptoms. Now see this flow chart.

LUTS/Prostatism

(a) **Voiding symptoms (Obstructive)** (HI ! DSP)	(b) **Storage symptoms (Irritative)** (FUN)
• **H**esitancy	• **F**requency
• **I**ntermittent urinary stream	• **U**rgency & Urge Incontinence
• **D**ribbling of urine	• **N**octuria
• **S**ensation of poor bladder emptying	
• **P**oor flow of urine (weak stream)	

Remember with HI! DSP Let's (LUTS) have FUN; though the patient does not have any fun; he keeps on running to wash room.

Now lets take each of them one by one:

(a) Voiding (obstructive) symptom

Voiding (obstructive) symptoms are due to enlargement of *lateral lobes.* These are: (Mnemonic HI! DSP)

(i) *Hesitancy* - Patient goes to micturate but he is unable to do so.

(ii) *Intermittent stream* - Urine stops and again starts during the act of micturition.

(iii) *Dribbling of urine* - After the act of micturition some amount of urine dribble.

(iv) *Sensation of Poor bladder emptying*

(v) *Poor flow of urine* - Patient often complains of weakening of the urinary stream.

(b) Irritative (storage) symptom

Irritative (storage) symptoms are due to median lobe enlargement. These are: (Mnemonic: FUN)

(i) *Frequency* - Frequency** of micturition is usually the *first symptom of BPH* (KAR 94,96). In the beginning frequently is mostly nocturnal; but gradually the increase in frequency is experienced in both day and night.

(ii) *Urgency* - There occurs intense desire of micturition and patient go to urinal urgently for voiding.

(iii) *Nocturia* - Nocturia is due to decreased cortical inhibition during sleep and also due to increased urethral tone.

**NOTE:-Normal day time frequency is 4-6 and during night is 1-2, *notice yourself today*

Aside from the symptom of LUTS/Prostatism, BPH may present as a complication of BOO [Bladder out let obstruction], which are as following.

2. Acute retention of urine

Acute retention of urine is some times the first presentation of BPH. Patient presents with severe suprapubic pain and lump.

Precipitating factors may be:

- Postponement of act of micturition (M/C factor)

- Cold weather
- Alcoholic beverage
- Anticholinergic drugs
- Confinement to bed due to illness/surgery
- Infection

3. Chronic retention of urine

In patients in whom the residual volume is more than 250ml or so, the tension in the bladder wall increases owing to combination of large volume of residual urine and increased resting and filling bladder pressure.

- The increased intramural tension results in functional obstruction of the upper urinary tract with development of bilateral hydronephrosis. (See key box 46.2)

4. Urinary tract infection and stone formation

Impaired bladder emptying leads to urinary infection and calculi.

5. Uremia

Sign and symptoms of uremia, such as; headache, drowsiness or vomiting may be present.

6. Terminal hematuria

Terminal hematuria may occur due to prostatic congestion *and rupture of "vesical pile".* (MANY PGME)

Vesical piles= Dilated prostatic venous plexus

Signs

Physical Examination

General examination

Should be carried out to exclude the features of chronic renal insufficiency. Examination of external genitalia for meatal stenosis should be carried out.

Examination of nervous system

Examination of nervous system is important to eliminate neurological lesions; eg. tabes dorsalis, Parkinson's disease, which may give rise to symptoms almost similar to that produced in a patient with BPH.

Abdominal examination

Abdominal examination may only reveal a full bladder at times, when BPH is complicated with acute retention or chronic retention.

The loin should be carefully examined to exclude renal enlargement due to hydronephrosis, as a result of back pressure effect.

Rectal examination: (PR/DRE EXAMINATION)

Rectal examination should be carried out carefully after emptying the bladder. Usually left lateral position (sim's position) is quite good for such examination.

Rectal examination reveals (VERY IMPORTANT)

- Enlarged prostate with a smooth surface. The prostatic enlargement is graded from I-IV depending on its size. Please see key box 46.4 & 46.5.
- The gland is convex and typically elastic, but the fibrous element may give the prostate a firm consistency.

KEY BOX 46.4

By doing a per rectal examination, prostatomegaly can be graded a

Grade I	1 cm bulge into rectum
Grade II	1-2 cm bulge into rectum
Grade III	2-3 cm bulge into rectum
Grade IV	>3 cm bulge into rectum

KEY BOX 46.5

Grading of Prostatic Enlargement (Depending upon USG findings)

Grade I	Less than 25 grams
Grade II	Between 26-50 grams
Grade III	Between 51-75 grams
Grade IV	More than 75 grams

Normal weight of prostate is about 10-15 grams.

KEY BOX 46.6 (NEET, PGI 08)	
Values	**Clinical significance**
Normal serum PSA level (NEET)	**Less than 4ng/ml (NEET)**
1. Levels between **4-10 ng/ml** (NEET)	Can be observed in both BPH & Ca prostate, Normal prostate
2. Levels more than 10 ng/ml	Highly suspicious of carcinoma prostate
3. Levels more than 35 ng/ml	Diagnostic of carcinoma prostate

- Rectal *mucosa can be made to move over the prostate.*
- Residual urine present in urinary bladder may be felt as a fluctuating swelling above the prostate.
- Persistence of median sulcus of prostate is important feature of differentiation between BPH & Ca prostate.

Investigation

1. **Urine examination:** Urine is examined for sugar and blood to exclude diabetes and hematuria.
2. **Serum urea and creatinine-** The raised levels indicate renal failure.
3. **Intravenous pyelography (IVP)-** IVP indicates the state of renal function. The enlarged prostate lying intravesically may be seen as a smooth cap like filling defect. Diverticula of the urinary bladder can be also seen. However; IVP should not be done if the blood urea is high (above 60 mg/100 ml).{Normal: 20-40}
4. **Abdominal ultrasound-** Abdominal ultrasound can accurately measure *prostatic size.* The ***residual volume* of urine can also be evaluated.***
   - The kidneys may be assessed for obstructive changes ie; hydronephrosis due to back pressure.
   - Ultrasonography is a *non-invasive investigation and has now mostly replaced IVP.*

   Residual volume: Urinary volume present (which can not be voided) in bladder after an act of urination.
5. **Trans rectal ultrasound:** Trans rectal ultrasound is done to investigate suspected *carcinoma of the prostate.* If suspicion has arisen because of raised prostate specific antigen (PSA) or digital rectal examination (DRE=PR) suggests abnormality.
6. **Uroflowmetry:** *This is a measure of urinary steam flow rate* [su-su ka flow rate/second]
   - The patient is asked to void urine from his full bladder into the uroflowmeter. Then the flow rate is calculated.

Observation

If 200 ml of urine is voided then

- **A peak flow rate of more than 20 ml/second (NEET) and voiding pressure is <60 cm H_2O is *considered normal.***

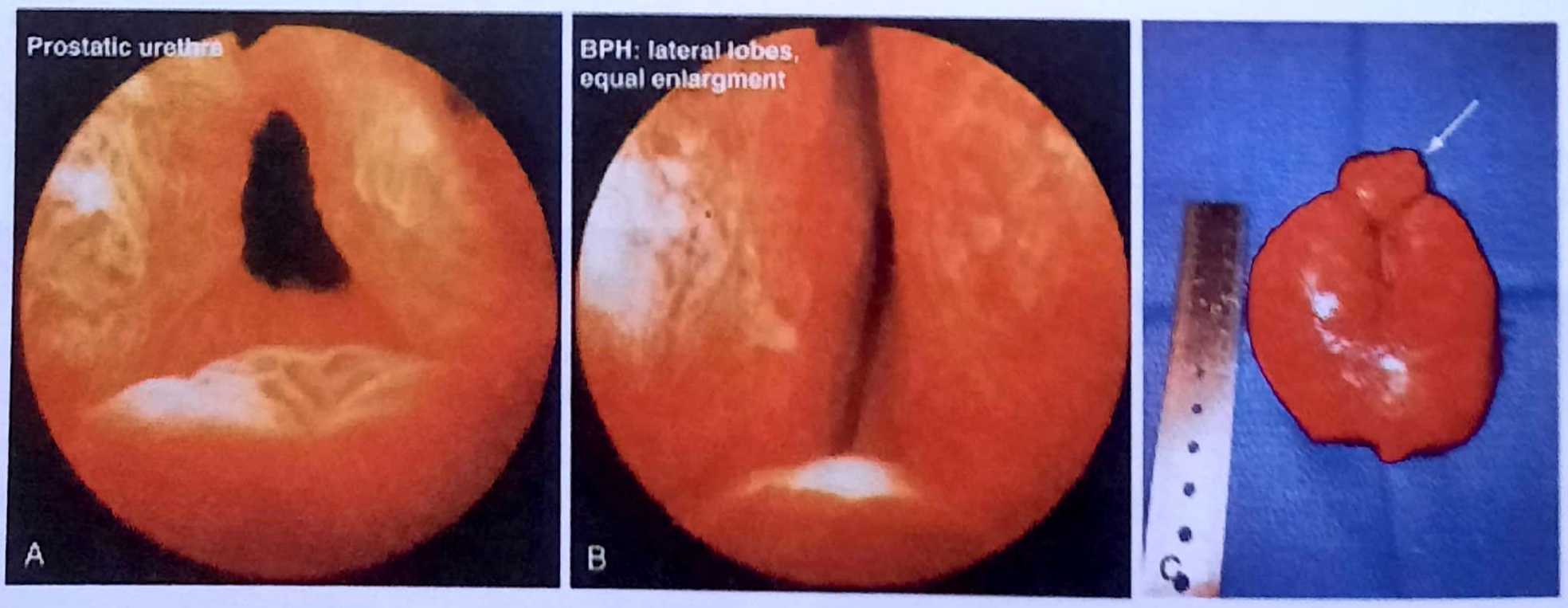

Figure 46.8 : Benign prostatic hyperplasia *(BPH)*. (A) Normal cystoscopic appearance of the prostate in a young man. (B) Moderate BPH, viewed cystoscopically. The size of the prostate correlates poorly with the magnitude of voiding symptoms. (C) Prostatic adenoma after simple open prostectomy.

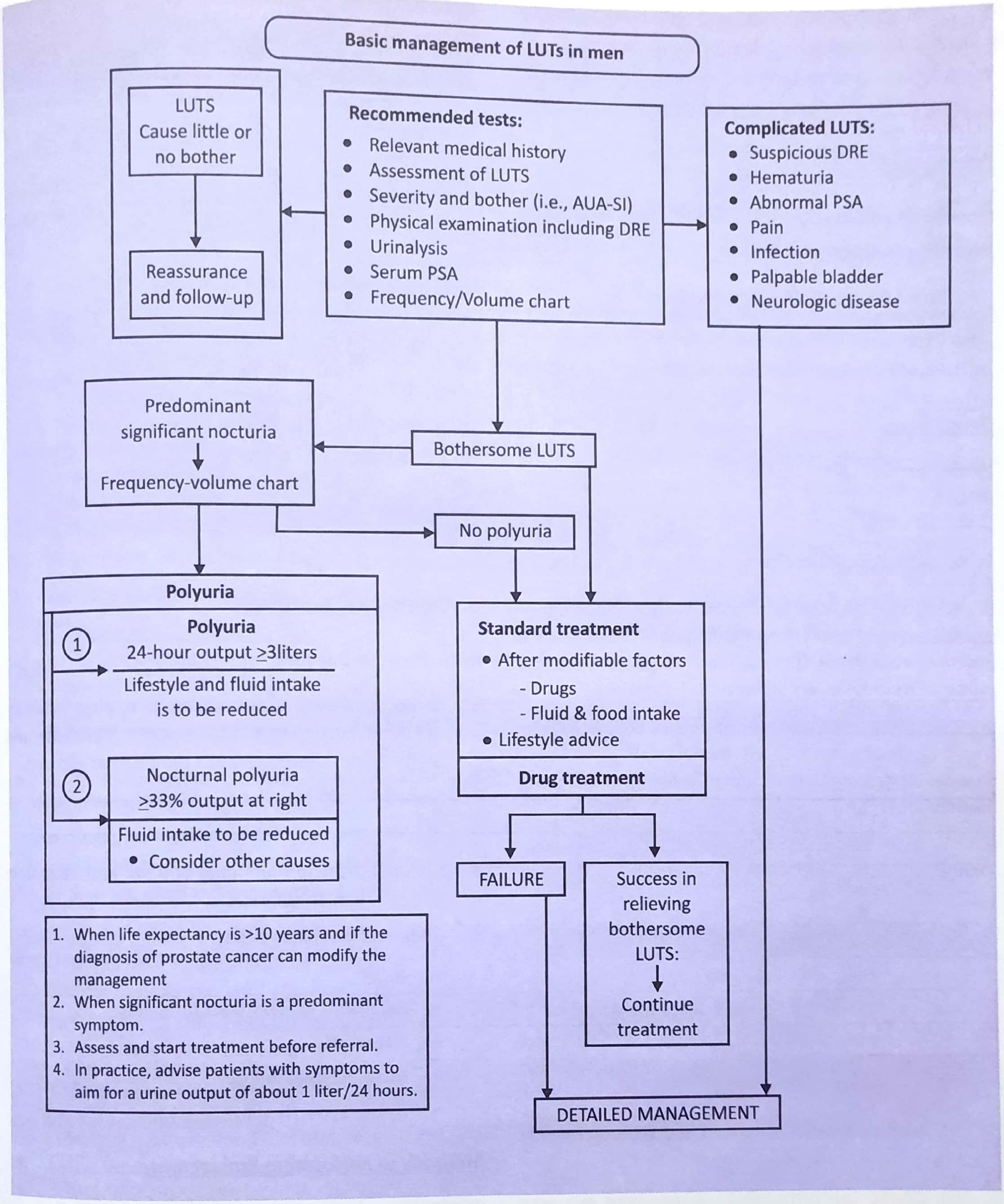

- A peak flow rate between 10-15 ml/second is *equivocal* & voiding pressure is between 60-80 cm H_2O.
- A peak flow rate less than 10 ml/second suggest *definite obstruction in bladder outflow and* voiding pressure is >80 cm H_2O.
- Thus the degree of bladder outlet obstruction (BOO) can be assessed by uroflowmetry in case of BPH.

7. Serum Prostate specific Antigen (PSA)

- It is a **glycoprotein** produced only by the prostatic cells. It facilitates liquefaction of semen.
- It is helpful in making a diagnosis of prostatic disease. (AI,92, AIIMS) Please see key box 46.6:

Treatment

A. Conservative Treatment (Medical treatment)

Indication for medical treatment

(i) Men with relatively mild symptoms

(ii) Reasonable flow rate ie; > 10 ml/second

(iii) Residual volume less than 100 ml.

Drugs used

Please see flow chart in key box 46.7 before going in details.

KEY BOX 46.7

Drugs used in BPH

Which inhibit the contraction of smooth muscle of prostate and bladder neck.	Which result in shrinkage of prostate (**decrease size of prostate**)
↓	↓
α_1 adrenergic blocker	**5α reductase inhibitors (FINASTERIDE)** (NEET, AI 07)
• Prazocin • Terazoncin • Tamulosin & • Alfuzocin (α_{1A}) new drug	↓ Inhibits conversion of testosterone to dihydrotestosteone

1. α_1-Adrenergic blockers

(α_1-adrenergic blocking agents inhibit the contraction of smooth muscles; found in and around prostate and hence improves urinary flow. The drugs have *no effect on the size of prostate.* The drugs used are *Prazocin, Terazocin.*

More recently **α_{1A} adrenergic blockers** like *Tamsulosin and Alfuzocin, which are more uroselective & have no adverse effect on cardiovascular system* (AI 02) are being used. (IMP. POINT)

- The main side effect with use of these drugs is *retrograde ejaculation* (MANY PGME)

2. 5α-reductase inhibitor (Finasteride) (AL 05)

Testosterone is converted to active form 1,5 dihydrotestosterone (DHT) by enzyme 5α-reductase, which is found in prostate. 5α *reductase inhibitors eg; finasteride blocks this conversion and results in shrinkage (decrease in size) of prostate.* (MANY PGME)

The drug most commonly used in this group is:-*Finasteride.* The main side effect is *impotence.* (IMP)

3. Aromatase inhibitors: like *Atamestane* decrease levels of estradiol and estrone, which are responsible for prostatic enlargement.

4. Anti androgen: like Flutamide.

5. Phyto-therapy in form of herbal preparation, like Prosteez, Prostina & Himplasia.

B. Operative Treatment

Indication of Surgery (AP 85, IMP POINT)

1. *Severe symptoms of prostatism*: Increasing difficulty in micturition, considerable frequency; both day and night, delay in starting and a poor urinary stream.
2. *More than two episodes of acute retention of urine.*
3. *Chronic retention* of urine with *renal impairment.*
4. *Residual urine of more than 100 ml,* and peak flow rate less than 10 ml/second.
5. *Complication* due to BPH.
   - Stone
   - Recurrent urinary tract infection
   - Hematuria
   - Chronic renal failure
   - Bladder diverticula

Methods of Performing Prostectomy

The prostate can be approached and resected by following approach:

1. **Trans-urethral:** (Through urethra) Trans Urethral Resection of Prostate (TURP)
2. **Trans-vesical:** through the bladder ie; Trans Vesical Prostectomy (TVP) also called Freyer's prostectomy.

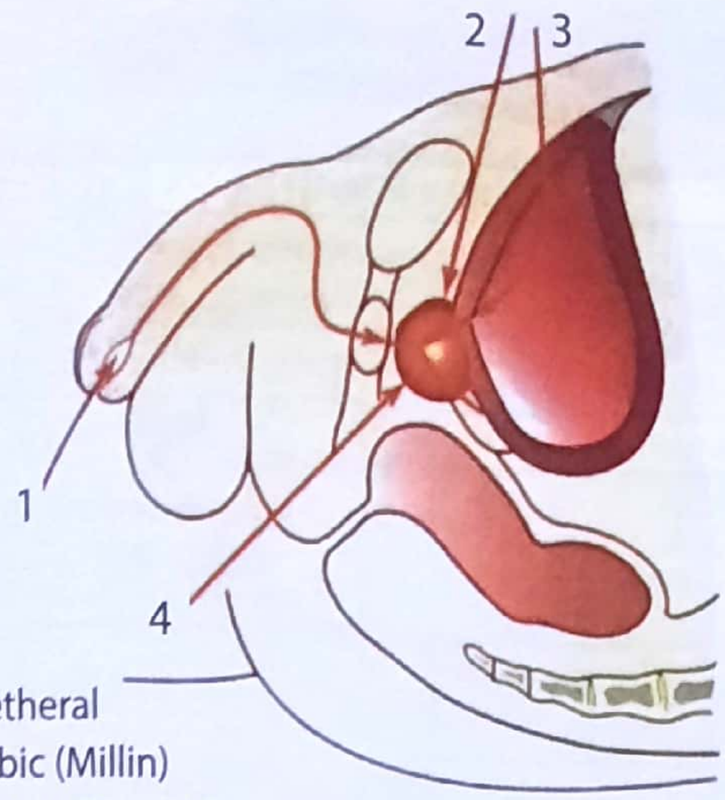

1. Transuretheral
2. Retropubic (Millin)
3. Transvesical (Freyer's)
4. Perineal (Young's) Approach

Figure 46.9(a): The surgical approaches to the prostate

3. **Retro-pubic:** Retro Pubic Prostectomy (RPP)
4. **Through Perineum:** also called as young's operation.

Now lets take each of them one by one

Please see figure 46.9(a)

1. *Trans urethral resection of Prostate (TURP)*

- As the name Trans Urethral Resection of Prostate states itself that resection of prostate is done trans urethrally ie; via urethra. In this procedure a resecting endoscope is passed through urethra to reach up to prostate, then prostate is resected (cut) in small pieces and taken out by an evacuator.
- During TURP strips of prostatic tissue are cut from bladder neck to the level above of the verumontanum to prevent injury to external urethral sphincter, by a high frequency diathermy current.
- The cut prostatic tissue is removed by an evacuator known as Ellik's evacuator.
- *TURP is now the gold standard for treatment of BPH.* *(AIIMS 84, AL, 89, UPPGME).*

Indication in 'TURP'

Urine flow < 10ml/sec.

- Residual urine vol. >100 ml
- Trabeculated urinary bladder

- This procedure is best for smaller to medium sized prostate (20-50 gram) and fibrous hyperplasia of prostate.
- *The **use of continuous flow resectoscope using 1.5% isotonic glycine irrigation has made the procedure safe.*** *(NEET, AIIMS NOV 03, MANY PGME, COMED 08).*
- Distilled water can be used in place of glycine irrigation ; however *normal saline solution should not be used.*
- The ***disadvantage*** with TUPR is that it is not suitable for large prostate (> 50 gram) and if bladder pathology like stone or diverticula has to be treated concurrently, which requires transvesical prostatectomy, in which prostate is approached after opening urinary bladder and bladder pathology is treated at the same time.
- **Complication of irrigating fluid** *(NEET)*
  - Water intoxication
  - Hyperammonemia
  - Hyperglycemia

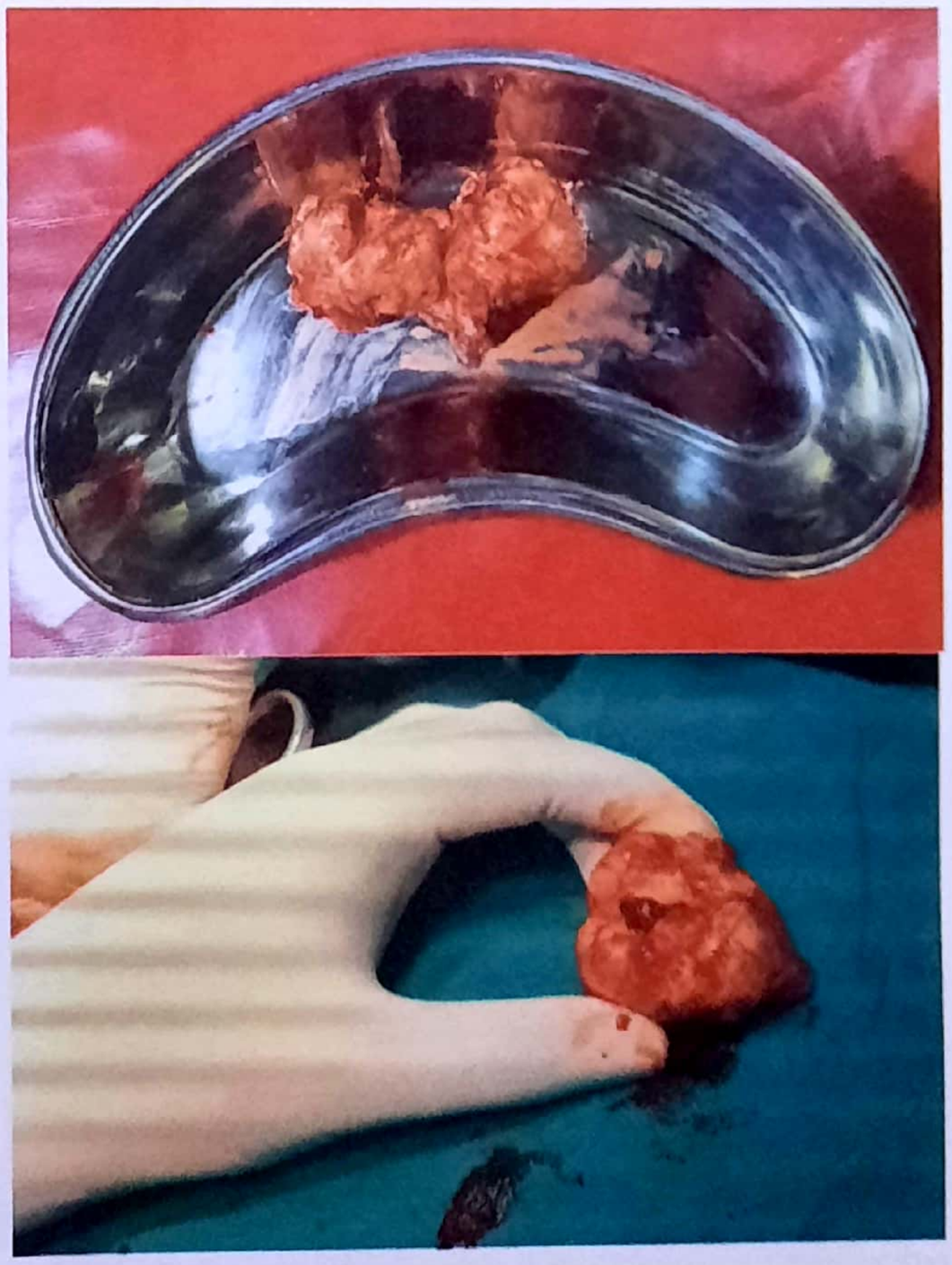

Figure 46.9(b): The specimen of prostate

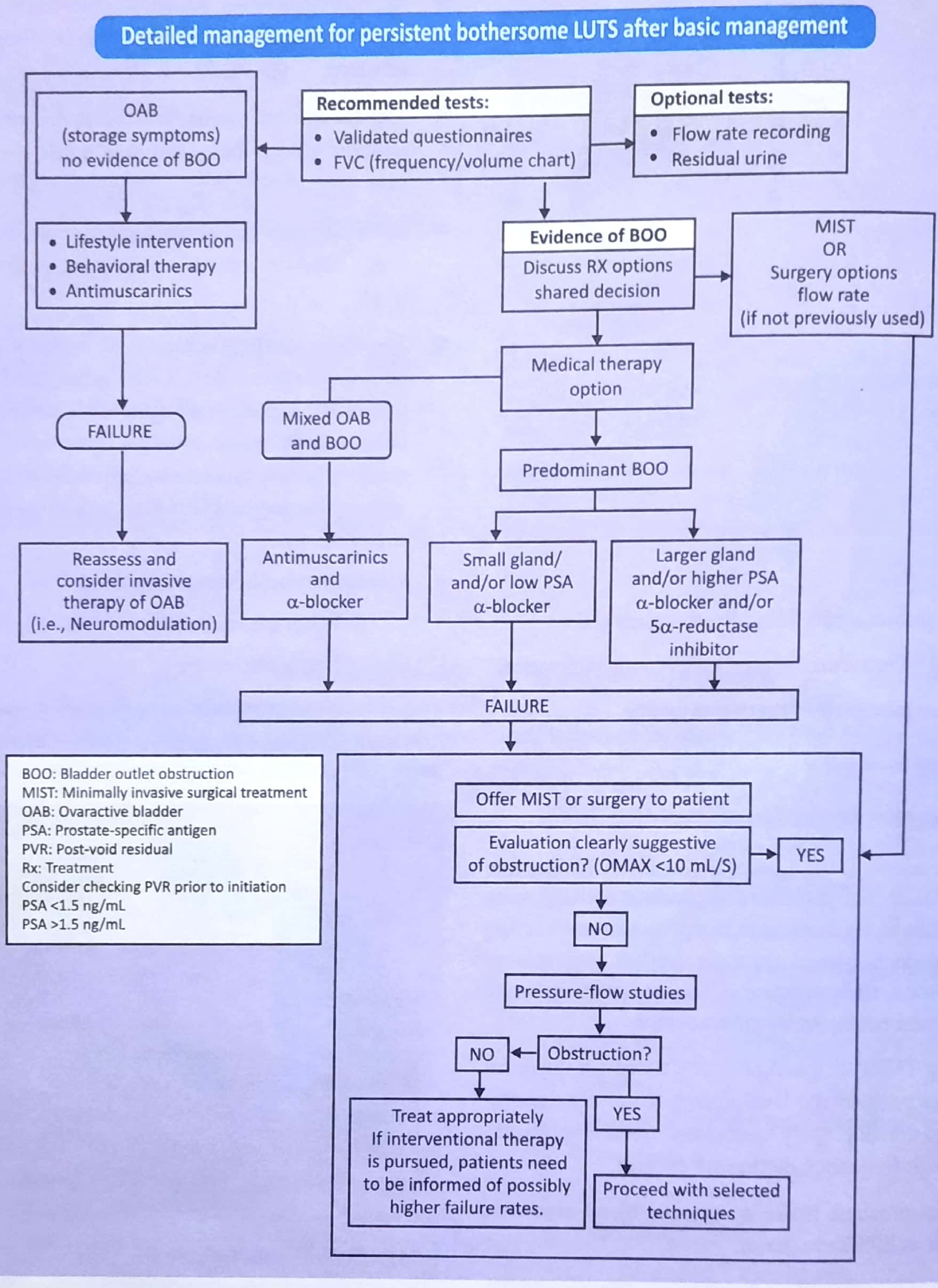

2. *Trans-Vesical prostectomy (TVP) (Freyer's Prostectomy)*

In this, prostate is approached and enucleated after opening urinary bladder [ie; trans bladder, hence named trans vesical] through a suprapubic incision, made in hypogastric region on anterior abdominal wall. Prostate is enucleated from in side the urinary bladder.

This is mainly suitable for large prostate (> 70 grams) and associated bladder pathology such as diverticula or stones which may be simultaneously treated.

3. *Retropubic Prostectomy (Millin's)*

In this procedure; a suprapubic incision is made, but the bladder is not opened instead the prostate is approached

from behind (retro) the pubic bone {hence named} and removed through the anterior aspect of prostatic capsule.

4. *Perineal Prostectomy (youngs)*

Not done now.

Complications of Prostectomy (PGME MANY TIMES)

(a) Local

- Hemorrhage is the major complications: both reactionary and secondary can occur.
- Perforation of the bladder.
- Sepsis leading to bacteremia, septicemia, epididymitis and wound infection.
- Incontinence (if external sphincter is damaged during operation)
- Retrograde ejaculation (common) (COMED 07)
- Erectile impotence
- Urethral stricture
- Bladder neck contracture/Stenosis (AI 2011)
- Reoperation
- Osteitis pubis

(b) General Complication

1. Cardiovascular

Pulmonary atelectasis, pneumonia, MI, CHF and DVT are all life-threatening condition that affect this elderly and often frail group of patients.

2. TUR Syndrome (Water intoxication)

(AIIMS JUNE 99, AIIMS JUNE 01)

- TURP for BPH has a very low mortality rate (0.1-2%).
- TUR syndrome occurs in about 2% of patients due to fluid overload, **hyponatremia** (NEET) **altered sensorium** and in extreme cases hemolysis.
- The absorption of water (used for irrigation of urinary bladder during TURP) may get absorbed in systemic circulation and can give rise to congestive cardiac failure.
- *Dilutional hyponatremia due to absorption of irrigation fluid may manifests as confusion and other cerebral events often mimicking as CVA.* (AIIMS JUNE 01, AL 03, AIIMS NOV 2000, AIIMS MAY 07)
- Water intoxication can also occur in -
  - Gastric lavage
  - Enema for colonic water

Newer Treatments For BPH

- Trans Urethral Incision of the Prostate (TUIP)
- Trans Urethral Electro Vaporisation of the Prostate (TUEVP)
- Laser prostatectomy (becoming very popular of late)
- Trans Urethral Balloon Dilatation of Prostate (TUBDP)
- Prostatic stents
- Thermal therapy for BPH
- Trans Urethral Needle Ablation of prostate (TUNA)

Detail of these procedures are not described, because they are out of scope of this simple literature. Only names of procedures are given; because you may be occasionally asked in VIVA.

*****

CARCINOMA OF THE PROSTATE

This is most common cancer in males above the age of 65 years, and incidence increases with the advancing age.

Etiology

- Race: Common in Europe and USA; but rare in Asia
- Environment
- Dietary fat
- Hormones: It is enhanced by testosterone and inhibited by estrogens or anti-androgens. (UPSC 07)
- Viral infections are some times blamed for causation of carcinoma prostate.

Pathology

- **Most of the prostatic carcinoma arise in the peripheral zone,** (NEET) *so prostectomy done for BPH, which involves enucleation of tranzitional zone does not offer any protection from Ca prostate.* (PGME). (IMP. POINT, UP 07)
- Histologically prostatic carcinomas are *adenocarcinoma,* which arises from glandular epithelium of periperal zone. (MANY PGME).

KEY BOX 46.8
THE BONES INVOLVED *(MANY PGME)* *(In decreasing order of frequency)*
• Lumber spine • Proximal femur • Pelvis • Thoracic spine • Ribs

- The cellular arrangement is described under five grades **(Gleason classification).** The two most common patterns seen are given scores ranging from 1 to 5 (that is; well to poorly differentiated) and the scores are added together to give a single grade on a scale of 2 to 10. Thus a sum score of 8-10 indicates poor differentiation and a score of 2-4 shows a well differentiated tumour. *(AIIMS 08)*

Gleasons score = Note : figure 46.12 page 863

KEY BOX 46.8.1		
Gleason score	**Grade Group**	**Characteristics**
6	**Group 1**	• Less aggressive • Very slow growing • Low risk
3 + 4 = 7	**Group 2**	• Slightly aggressive • Slow growing • Low to intermediate risk
4 + 3 = 7	**Group 3**	• Moderately aggressive • Fast growing • Intermeidate to High risk
8	**Group 4**	• Aggressive • Rapidly growing • High risk
9-10	**Group 5**	• Highly aggressive • Rapidly growing • High risk

Spread

1. Local spread

Due to the presence of the strong fascia of Denonvilliers, the back ward spread of carcinoma of prostate to rectum is prevented for a long time. The spread therefore takes place upward; and the first structure involved is the seminal vesicle.

Involvement of ureters may cause hydronephrosis and hydroureter in advanced cases.

2. Hematogenous spread

- This occurs particularly to bones *(AP 89)*.
- **Most common bony metastasis occurs in (*lumbar spine*), *(NEET)* *proximal femur; pelvis, thoracic spine, ribs,* in that order,** (key box 46.8)
- Bone secondaries are usually *osteoblastic, however some times they may be osteoclastic.* *(PGME)*

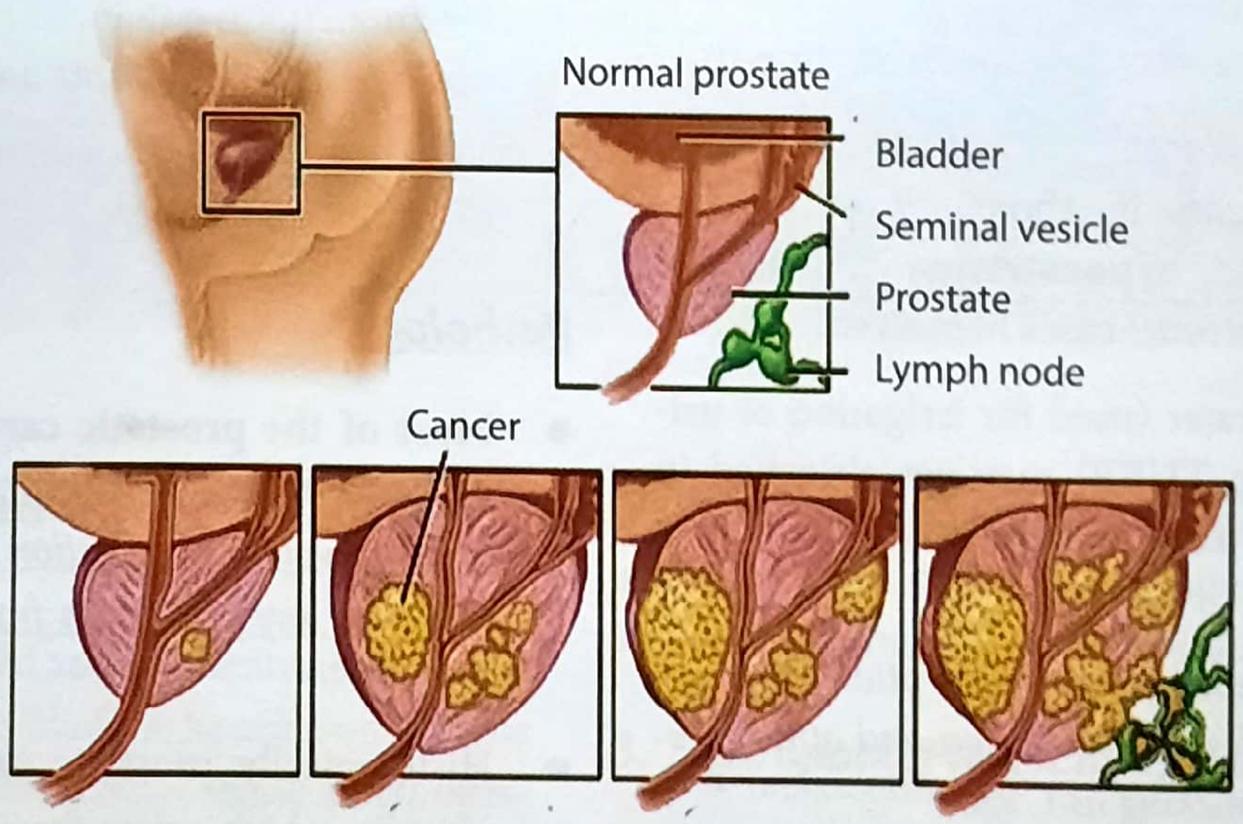

Figure 46.10: Spread of prostate cancer

3. Lymphatic spread

- Lymphatic spread occurs most commonly to **obturator lymph node** *(PGI JUNE 99)*.
- Other lymph nodes involved are; common iliac, presacral, periaortic and sometimes supra clavicular nodes.

* See figure 46.10

Bony metastases are mainly osteoblastic (osteosclerotic) but osteolytic metastases may also coexist. *(VERY IMP.)*

STAGING OF PROSTATE CANCER

Staging

TNM staging system for prostate cancer.

Primary Tumor (T)

Tx	Primary tumor cannot be assessed
T0	No evidence of primary tumor
T1	Clinically inapparent tumor neither palpable nor visible by imaging
T1a	Tumor incidental histologic finding in 5% or less of tissue resected
T1b	Tumor incidental histologic finding in more than 5% of tissue resected
T1c	Tumor identified by needle biopsy (for example, because of elevated PSA)
T2	Tumor confined within prostate
T2a	Tumor involves one half of one lobe or less
T2b	Tumor involves more than one half of one lobe but not both lobes
T2c	Tumor involves both lobes
T3	Tumor extends through the prostate capsule
T3a	Extracapsular extension (unilateral or bilateral)
T3b	Tumor invades seminal vesicles(s)
T4	Tumor is fixed or invades adjacent structures other than seminal vesicels, such as external sphincter, rectum, bladder, levator muscles, and/or pelvic wall

Lymph Nodes (N)

Nx	Regional lymph nodes were not assessed
N0	No regional lymph node metastasis
N1	Metastasis in regional lymph node(s)

Distant Metastasis (M)

M0	No distant metastasis
M1	Distant metastasis
M1a	Nonregional lymph nodes(s)
M1b	Bone(s)
M1c	Other site(s) with or without bone disease

Clinical Feature

The clinical presentation may be divided into the following groups. A patient of Carcinoma prostate may present in either of the following group:

Group I

The patient is operated with the diagnosis of BPH, but histological examination reveals malignancy.

Group II

The patient presents with features of prostatism (frequency, urgency, nocturia) and some times with retention. Suspicion arises about carcinoma of prostate because of the following:

- Comparatively short history of symptoms of prostatism (complaints are for weeks as compared to months in BPH)
- On rectal examination prostate seems to be firm to hard nodular enlargement.

Group III

There are features of prostatism, sometime hematuria and or retention. Rectal examination reveals a typically malignant prostate *which is hard, nodular with obliteration of the median sulcus.* *(IMP. POINT)*

Group IV

The urinary symptoms are absent or minimal and rectal examination is equivocal. There are however, metastases. Patient may present, according to the location of the metastases.

1. Back pain - due to involvement of dorsolumbar spine.

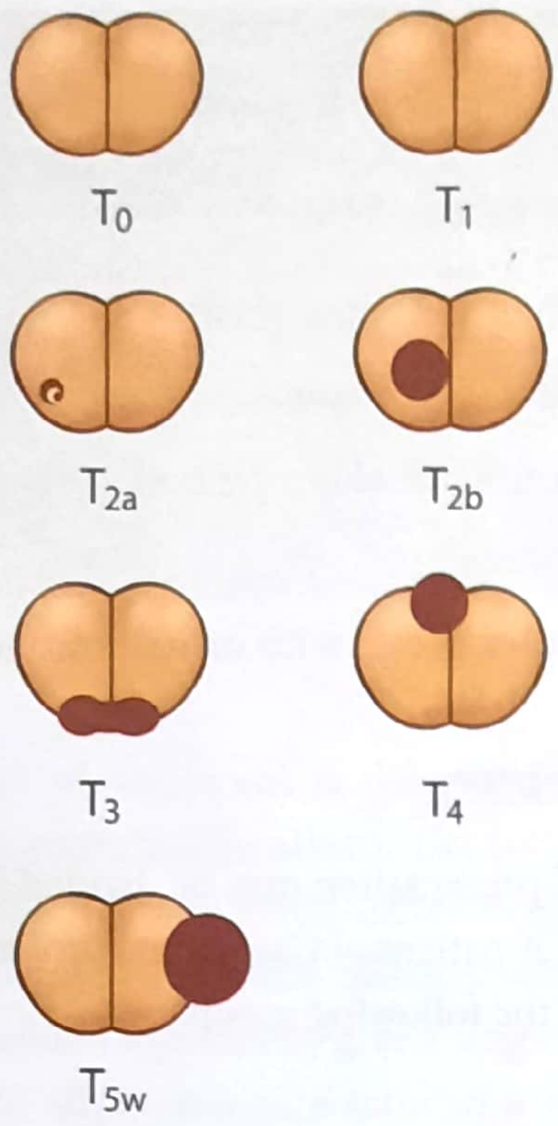

Figure 46.11: Staging system for prostate cancer

2. Bone pain - due to involvement of long bones viz; femur.
3. Cough, hemoptysis, chest pain due to secondaries in the lung.
4. Hard nodular liver with jaundice and ascites due to secondaries in the liver.

Friends you may often get a long case on BPH or CA prostate in your final prof, examination. You must remember points to differentiate between them, kindly see box 46.11 page 864

INVESTIGATIONS

1. Radiological examination

- Chest X-ray may reveal metastasis to lungs and ribs.
- Abdominal X-ray shows metastatic deposits in lumbar vertebrae and pelvic bones. The bone appears dense and coarse; *Osteolitic metastasis may also co-exist with sclerotic (osteoblastic) ones.* (AIIMS 2000)

2. Serum Acid phosphatase (AIIMS NOV 2000, NOV 99)

Acid phosphatase is elevated in approximately three fourths of patients with metastases. It is not a very specific test because it may be elevated in many other conditions. Please also see box 46.9.

KEY BOX 46.9

Increased levels of acid phosphatase may also be found with

- Paget's disease of bone
- After prostatitis
- Prostatic massage
- Urethral instrumentation
- Cirrhosis of liver

3. Prostate specific antigen (PSA)

(AIIMS NOV 03, PGI DEC 99, MAY 05)

Prostate specific antigen (PSA) is a **Superior tumour marker,** (NEET) stage by stage; as a measure of disease activity. A level of PSA > 10 ng/ml is suggestive of cancer and >35 ng/ ml is **diagnostic of advanced prostatic cancer.** (NEET) A decrease of PSA to the normal range following hormonal ablation is a good prognostic Indicator.

KEY BOX 46.10

More On PSA

NOTE : there may be future PGME questions on this

Unfortunately, PSA is not specific for carcinoma prostate, as other factors such as BPH, urethral instrumentation, prostatitis, can cause elevation of serum PSA. cough last two factors can be clinically ascertained, distinguishing between elevation of serum PSA resulting from BPH and those related to Ca Prostate remains the most problematic.

Numerous strategies to refine PSA for cancer detection have been explored. Their common goal is to decrease the number of false-positive test results. Attempts at refining PSA has have included PSA velocity, PSA density, age adjusted PSA reference ranges and PSA forms.

PSA Velocity

PSA velocity refers to the *rate of change in serum PSA.* Patients whose serum PSA increases by 0.75 ng/ml/year appears to be at increased risk of harbouring cancer.

PSA density

The *ratio of PSA to gland volume is termed as PSA density.*

PSA forms

Free- versus protein bound forms of PSA. Patients with prostate cancer demonstrate lower percentage of free PSA than the patients with BPH.

Best in for prostate cancer.

NOTE: Normal serum PSA level is less than 4ng/ml

- Levels between 4-10 ng/ml - Can be observed in both BPH and Cancer
- Levels more than l0ng/mg - Highly suspicious of carcinoma prostate
- Levels more than 35 ng/ml - Diagnostic of carcinoma prostate

Read more on PSA in box 46.10.

Best investigation for prostate CA is serum PSA.

4. Serum Alkaline phosphatase

Alkaline phosphatase may be raised in either hepatic metastases or in secondaries to the bones. (TN 89)

5. Trans rectal ultrasonography (TRUS)

Accurate images of prostate can be obtained by TRUS, in which an ultrasound probe is introduced via the rectum to be adjacent to the prostate. In patient with prostate cancer, a number of ultrasonographic abnormalities are present, including hypoechoic images, extent of extra-prostatic extension and seminal vesicle involvement and for taking guided biopsy. (AI 08)

For more on Trans-rectal ultrasound read this on page 996 Chapter 55.

NOTE: Prostate is just anterior to lower part of rectum.

6. CT scan and MRI

These investigations may show presence and degree of lymph node involvement.

7. Bone scan

99Tc (technetium) is injected intravenously and pelvic bones are more likely to take due to metastatic bone deposits.

8. Prostatic biopsy

Prostatic biopsy is ***done trans-rectally*** (AP 32), using an automated gun under appropriate antibiotic cover.

Gleason score is for prognosis and guidance of treatment of prostate cancer based on histopathological diagnosis. (See figure 46.112)

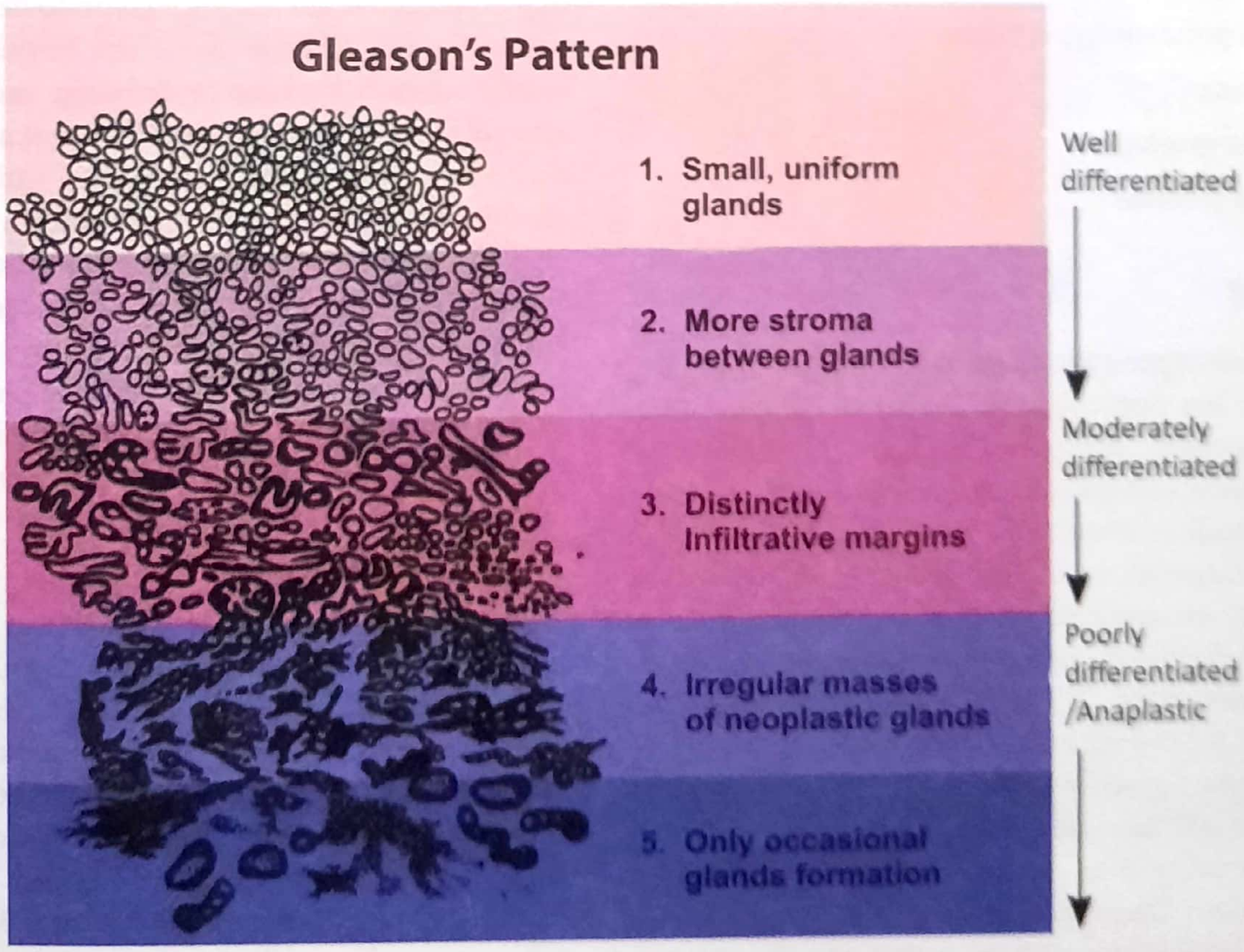

Figure 46.12: Gleason's pattern

KEY BOX 46.11	
BPH	**CA Prostate**
• Patients are usually older ie; more than 70 years	• Patients are relatively younger (50-70 years)
• The history of illness relatively short ie., months to years	• The history of illness relatively short i.e., weeks to months
• No any evidence of metastasis, as this condition is benign	• Patient may have complaints of back pain, dyspnea due to metastases.
• Patient usually does not have weight loss or malaise*.	• Carcinoma often presents with weight loss malaise, and weakness.
* Malaise= uneasiness or discomfort	
Rectal examination : is very important and informative	
• **Size** - The size may be quite big	• The size is usually not very big.
• **Consistency** - It is firm & elastic	• Firm to hard
• **Surface** - smooth	• Irregular and nodular
• The midline sulcus between the two lateral lobes is well felt.	• The sulcus is usually obliterated.
• **The seminal vesicles** - feel normal though very difficult to be felt	• These may be invaded by the tumour and feel hard and irregular
• The rectal mucous membrane moves freely over the enlarged prostate.	• The rectal mucous membrane is adherent and cannot be moved over the prostate.

Differential diagnosis

- Benign prostatic hyperplasia
- Prostatic calculi
- Chronic prostatitis
- Fibrous prostate

Treatment

The treatment of prostate cancer has changed significantly during the last two decades. Shared decision-making takes into account cancer details, patient medical factors, life expectancy, and patient preference to determine the preferred mode of treatment. As most prostate cancer is low risk at diagnosis, many patients (up to 50% in certain centers) are now managed with active surveillance rather than with definitive therapy. In general, men with cancer of low clinical stage (<T2a), low grade (Gleason sum ≤6), low PSA (<10 ng/mL) and low volume on biopsy are candidates for active surveillance. Patients assigned to active surveillance protocols undergo DRE and PSA monitoring every 3 to 6 months, often incorporating MRI at certain intervals and repeated TRUS guided prostate biopsies every 1 to 3 years. Patients with increase in Gleason sum or increase in tumor volume on biopsy typically shift to an active treatment plan, and up to 25% of men on active surveillance go on to definitive therapy within 5 years. *Prostate cancer can be treated with either radical surgical excision or definitive radiation therapy. Radical prostatectomy involves the surgical removal of the entire prostate and seminal* vesicles with anastomosis of the urethral stump to the bladder neck. The extent of bilateral pelvic lymph node dissection is based on extent of disease and risk group of the cancer. Important landmarks for radical prostatectomy are the dorsal venous plexus anteriorly, bladder neck cephalad, prostatomembranous urethral junction distally, and rectal wall posteriorly. The correct plane of posterior dissection in radical prostatectomy is just posterior to the Denonvilliers fascia. *(IMP POINT)*

Patients who do not desire or are not candidates for surgical extirpation may undergo local therapy with either intensity-modulated radiation therapy (IMRT) or brachytherapy. The typical treatment dose for IMRT-based prostate cancer therapy is 76 to 86 Gy. The most common form of brachytherapy is low-dose ultrasound-guided placement of iodine-125 or palladium-103 radioisotope sources into the prostate. Both treatments are commonly used for low-risk prostate cancer. Intermediate and high risk prostate cancer is typically

treated with IMRT coupled with androgen deprivation therapy for up to 2 years.

In advanced prostate cancer, the standard approach with androgen deprivation therapy may become ineffective, with clinical or PSA progression observed in spite of appropriate hormonal blockade. When castrate-resistant disease develops, second-line treatment includes antiandrogens, chemotherapy. After prostate cancer therapy, patients are monitored for posttreatment morbidities (e.g., continence, erectile function, voiding adequacy) and possible cancer recurrence. Other forms of treatment that can be considered for local treatment of prostate cancer include ablation, such as high-intensity frequency ultrasound and cryotherapy, and proton beam therapy.

*****

RECAP: Till now we were discussing two common causes of bladder out flow obstruction- BPH & Ca prostate, now we will discuss two other relatively uncommon diseases, causing bladder out flow obstruction. Kindly see figure 46.9 & Key box 46.12 before moving forward.

BLADDER OUTFLOW OBSTRUCTION DUE TO BLADDER NECK DISEASE

Fibrosis of Bladder Neck Following TURP

The symptoms are similar to those of prostatic enlargement but are as a result of bladder neck fibrosis following TURP. Transurethral incision of the bladder neck is the operation of choice.

Marion's Disease

This is rare condition, which occurs in adult men and have symptoms of outflow obstruction. *It is due to muscular hypertrophy of the internal sphincter.* (AIIMS 81, DNB 90). **Marion's disease is most common cause of bladder outlet obstruction in adult male.**

Please go through figure 46.13 & key box 46.13 before concluding this topic.

*****

INFLAMMATION OF THE PROSTATE

Inflammation of the prostate can be divided into acute and chronic prostatitis.

Acute Prostatitis & Prostatic Abscess

Acute prostatitis is usually caused by *E.coli, Staphylococcus aureus and Streptococcus fecalis.* The infection may be hematogenous from a distant focus or it may be secondary to acute urinary tract infection.

Seminal vasculitis is almost always associated with acute prostatitis. (AIIMS 87)

Clinical Feature

- A patient of acute prostatis presents with fever with rigors and body pain.

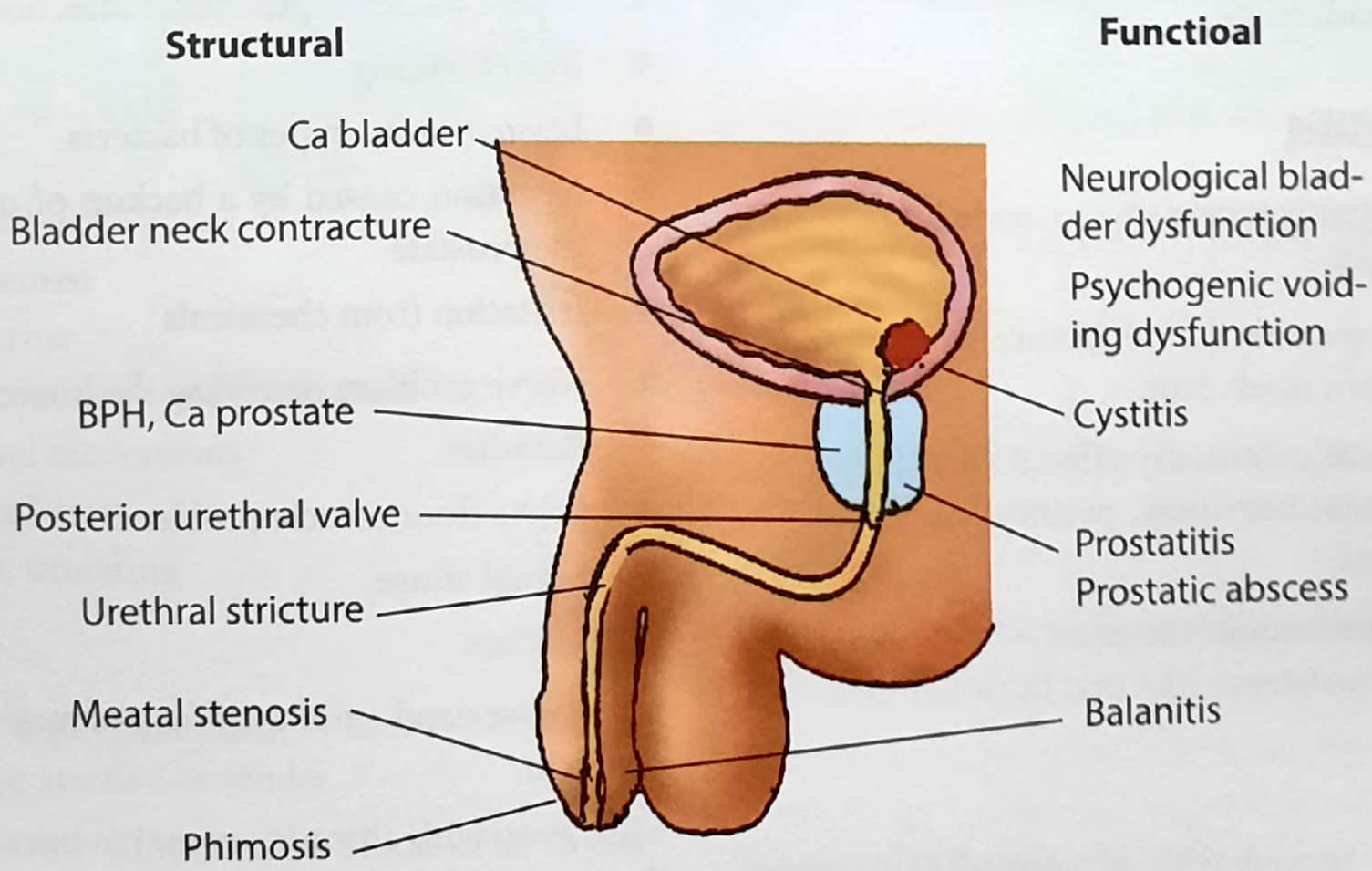

Figure 46.13: Cause of bladder out flow obstruction

KEY BOX 46.12

Urodynamically proven bladder outlet obstruction may result from

- Bladder neck stenosis
- Bladder neck hypertrophy
- Prostate cancer
- Urethral stricture
- Functional obstruction due to neuropathic condition.

- The patient is very uncomfortable and have pain all over the body, more so in the back, which may radiate to thigh and penis.
- Act of micturition is painful. The stream is thin and contains thread; which should be sent for culture and sensitivity.
- Perineal heaviness, rectal irritation and pain during defection may be present.
- Some patients may present with acute retention of urine.
- **Rectal examination:** Reveals a tender, enlarged prostate.

Treatment

- Bed rest, IV fluids and broad spectrum antibiotics are started.
- If **prostatic abscess** has formed, trasrectal ultrasonography or CT scan can be used for *direct transrectal drainage* of the abscess. Transurethral resection and drainage may be required; if transrectal drainage is inadequate.

Chronic Prostatitis

- Chronic prostatitis results due to inadquately treated acute prostatitis.
- There is dull pain in the perineum; which increase after sitting on a hard chair.
- Elderly men are commonly affected and they complain of perineal heaviness, perineal discomfort or pain during sex.
- On rectal examination, the prostate may be tender and hard in consistency like that in carcinoma.

Treatment

This condition is treated with prolonged (3-4 weeks) antibiotics after urine culture and sensitivity test.

Prostatic Calculi

Prostatic calculi develop by *calcification of the corpora amylacea.* Corpora amylacea arise by the deposit of protein and fat from the prostatic secretion, along with **calcium phosphate** (NEET) around the desquamated cells. These are mostly seen in older patients.

- Most of the time, they are **asymptomatic** and are discovered incidentally on X-ray of pelvis or during prostatectomy. They may, some time give symptoms resembling chronic prostatitis.
- On DRE (PR examination) they may be felt as a hard areas and then it becomes very difficult to differentiate it from carcinoma.
- Most of the patients do not require any treatment.
- **Treatment** is only for the symptoms. Treatment of prostatitis by antibiotics may be started. In some cases TURP may be required.

Chronic pelvic pain syndrome (nonbacterial prostatitis)

- Chronic nonbacterial prostatitis causes long-term pain and urinary symptoms. It involves the prostate gland or other parts of a man's lower urinary tract or genital area. This condition is not caused by an infection with bacteria.

Causes

- Possible causes of nonbacterial prostatitis include:
- A past bacterial prostatitis infection
- Bicycle riding
- Less common types of bacteria
- Irritation caused by a backup of urine flowing into the prostate
- Irritation from chemicals
- Nerve problem involving the lower urinary tract
- Parasites
- Pelvic floor muscle problem
- Sexual abuse
- Viruses

Life stresses and emotional factors may play a part in the problem.

Most men with chronic prostatitis have the nonbacterial form.

KEY BOX 46.13

Algorithm for management of a case of retention of urine

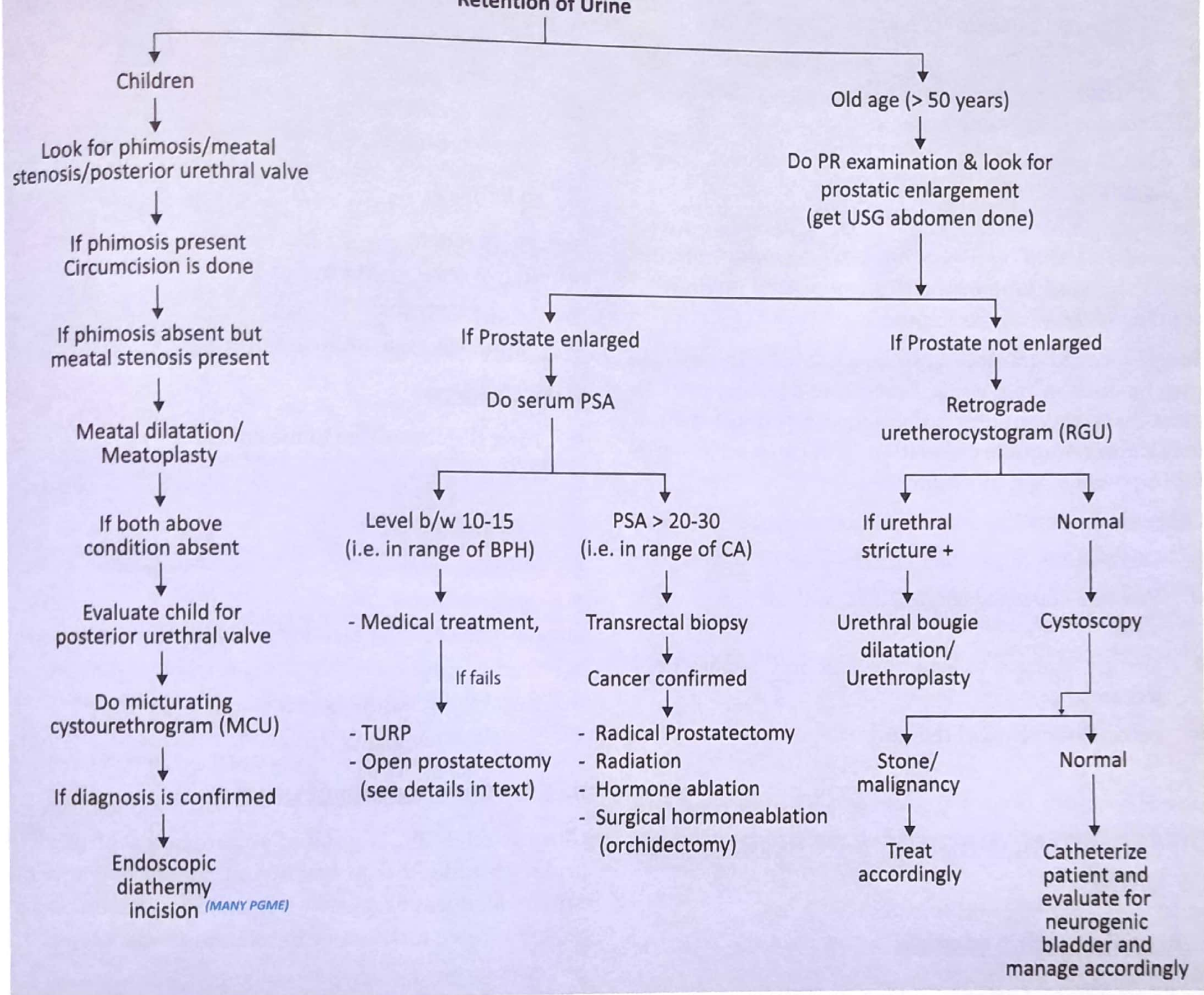

Symptoms

Symptoms may include:

- Blood in the semen
- Blood in the urine
- Pain in the genital area and lower back
- Pain with bowel movements
- Pain with ejaculation
- Problems with urinating

Exams and tests

Most of the time, a physical exam is normal. However, the prostate may be swollen or tender.

Urine tests may show white or red blood cells in the urine. A semen culture may show a higher number of white blood cells and low sperm count with poor movement.

Urine culture or culture from the prostate does not show bacteria.

Treatment

Treatment for nonbacterial prostatitis is difficult. The problem is hard to cure, so the goal is to control symptoms.

Several types of medicines may be used to treat the condition. These include:

- Long-term antibiotics to make sure that the prostatitis is not caused by bacteria. However, people who are not helped by antibiotics should stop taking these medicines.

- Drugs called alpha-adrenergic blockers help relax the muscles of the prostate gland. It often takes about 6 weeks before these medicines start working. Many people do not get relief from these medicines.
- Aspirin, ibuprofen, and other nonsteroidal anti-inflammatory drugs (NSAIDs), which may relieve symptoms for some men.
- Muscle relaxers like diazepam or cyclobenzaprine can help to reduce spasms in the pelvic floor.

Some people have found some relief from pollen extract (Cernitin) and allopurinol. But research does not confirm their benefit. Stool softeners may help reduce discomfort with bowel movements.

Surgery, called transurethral resection of the prostate, may be done in rare cases if medicine does not help. In most cases, this surgery is not done on younger men. It may cause retrograde ejaculation. This can lead to sterility, impotence, and incontinence.

Other treatments that may be tried include:

- Warm baths to ease some of the pain
- Prostate massage, acupuncture, and relaxation exercises.
- Dietary changes to avoid bladder and urinary tract irritants.
- Pelvic floor physical therapy.

*****

DIFFERENTIAL DIAGNOSIS OF RETENTION OF URINE

I. Acute retention of urine

Acute retention of urine is sudden inability to pass urine and is a **painful condition**

A. In Males

- Benign Prostatic hypertrophy (BPH) in elderly patients more than 50 years of age.
- Carcinoma Prostate
- Postoperative retention of urine : Operations like hemorrhoidectomy, fistulectomy, Fistula in ano etc; may cause reflex spasm of internal urethral sphincter; which precipitates retention of urine.
- Stricture urethra: In young patients
- Urethral calculus
- Acute urethritis
- Acute prostatitis

B. In Females

- Psychogenic
- Retroverted gravid uterus
- Urethral stenosis
- Advance CA of cervix, vagina & vulva

C. In children

- Meatal stenosis due to meatal ulcer
- Bladder stone

D. General causes

- Spinal anesthesia
- Spinal injuries
- Blood clot in the bladder following prostatectomy
- Fecal impaction
- Contracture of the bladder neck
- Drugs: Atropine, bethanechol, carbachol

II. Chronic retention of urine

Chronic retention is gradual accumulation of urine in urinary bladder due to inability of patient to empty the urinary bladder completely. It is a painless condition and patient is often unaware of the condition. Causes are:

- Benign prostatic hypertrophy
- Bladder neck contracture
- Stricture urethra
- Posterior urethral valve in children
- Tight phimosis
- Post prostatectomy bladder neck stenosis

*****

Sample Questions for Prof Examination

1. Discuss the pathology, clinical features, investigations and the medical and surgical management of benign enlargement of the prostate.
2. Discuss carcinoma of prostate, how will you investigate and manage it?
3. Discuss clinical picture and management of benign prostatic hyperplasia?
4. What are the causes of bladder outlet obstruction? Discuss management of Ca. Prostate.

47 The Urethra

Contents

- Surgical Anatomy
- Meatal stenosis
- Congenital valve of posterior Urethra
- Hypospadias
- Epispadias
- Injury to male urethra
- Urethritis
- Urethral stricture
- Male urethral carcinoma

SURGICAL ANATOMY

The Urethra

In Men

The urethra is **about 18-20 cm long,** *(MANY PGME)* and bends twice along its course. Beginning at the base of the bladder and passing inferiorly through the prostate, it passes through the deep perineal pouch and perineal membrane and immediately enters the root of the penis.

The urethra in men is divided into:- preprostatic, prostatic, membranous and spongy parts. (Please see figure 47.1; on page 47-2; next page, then only proceed).

1. Preprostatic Part

The preprostatic part of urethra is about **1cm long**, extends from the base of bladder to the prostate and is associated with a circular cuff of smooth muscle fibres (the internal urethral sphincter). Contraction of this sphincter prevents retrograde movement of semen into the bladder during ejaculation.

2. Prostatic part

The prostatic part of urethra **is 3-4 cm** long and is surrounded by prostate. It is the widest and ***most dilatable part*** of the male urethra. *(AI 01, UP PGME)*

- In this region the lumen of the urethra is marked by a longitudinal fold of mucosa called as urethral crest (or *verumontanum).* The depression on each side of the crest is the urethral sinus; the ducts of the prostate empty into these two sinuses, (Figure 46.3 & 4: in prostate, page 871, 872).
- Midway along the length, the urethral crest *(verumontanum)* is enlarged to form a some what circular elevation called as *seminal colliculus.* In men, the *seminal colliculus is used to determine the position of prostate during transurethral resection of prostate* (TURP). *(IMP.POINT)*
- A small blind-ended pouch; the prostatic utricle opens onto the center of the *seminal colliculus.*
- On each side of the **prostatic utricle** is the opening of the ejaculatory duct of the male reproductive system. Therefore, *the connection between the urinary and reproductive tracts in men occurs in the prostatic part of the urethra.* *(MAY BE FUTURE PGME Q)*

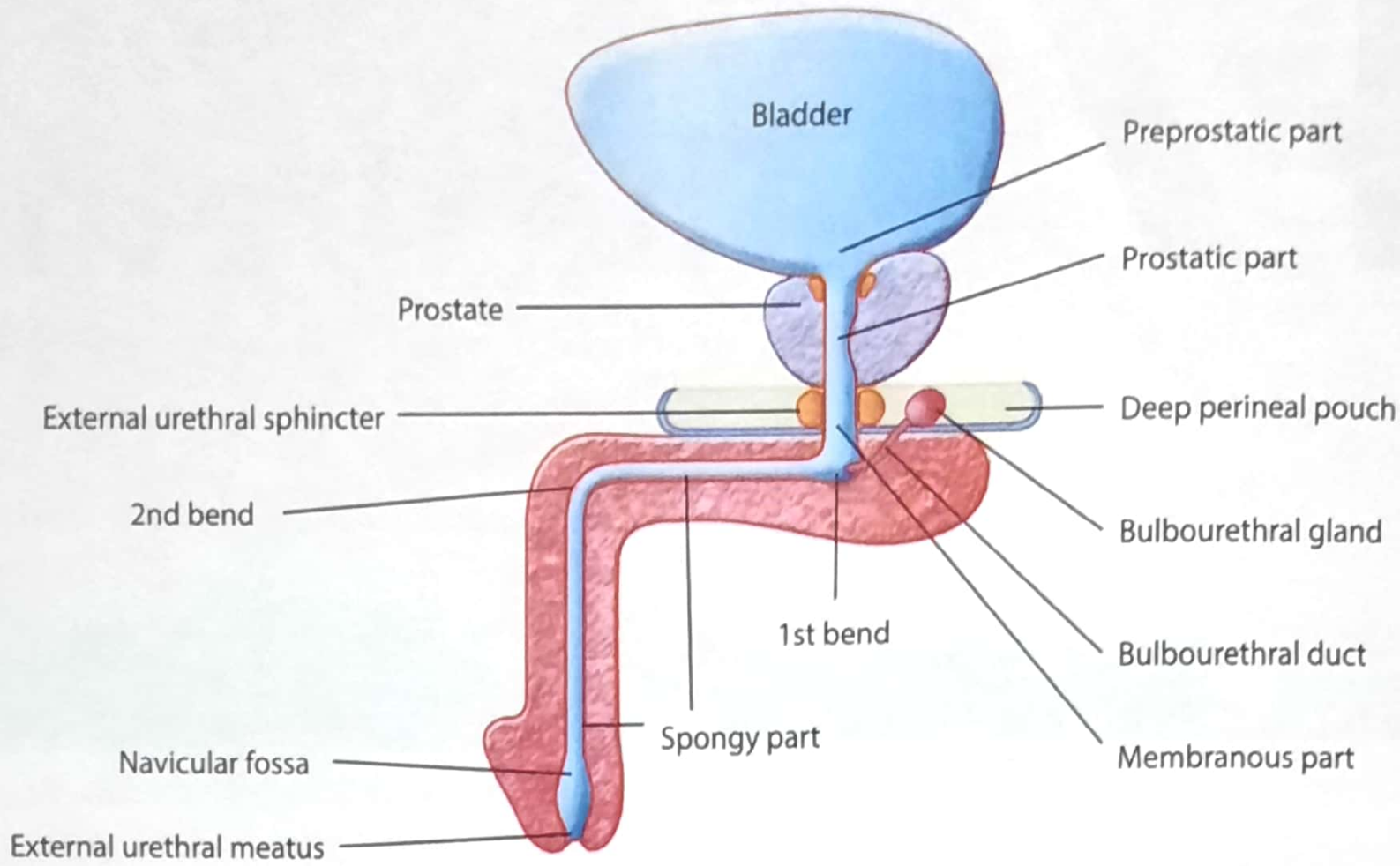

Figure 47.1: Anatomy of male urethera

3. Membranous part

It is about **1.5-2 cm long**, and with the *exception of external urethral* meatus this is the ***narrowest and least dilatable part*** of the male urethra. *(JIPMER 87, AI 89)*

- The membranous urethra is surrounded by the sphincter urethrae (external urethral sphincter).
- The ***bulbourethral glands (of Cowper)*** are **placed** one on each side of the membranous urethra, *although their ducts open into the spongy part of the urethra* *(MANY PGME)* after piercing the perineal membrane. *(VERY IMP. POINT)*
- Numerous urethral glands also open into the membranous urethra.

4. Spongy (Penile) urethra

It is about **15 cm long** and is surrounded by erectile tissue (the **corpus spongiosum**) of the penis. It is enlarged to form a bulb at the base of the penis and again at the end of the penis to form the **navicular fossa.**

The two bulbo-urethral glands in the deep perineal pouch are part of the male reproductive system and open into the bulb of the spongy urethra. The external urethral orifice is the sagittal slit at the end of the penis.

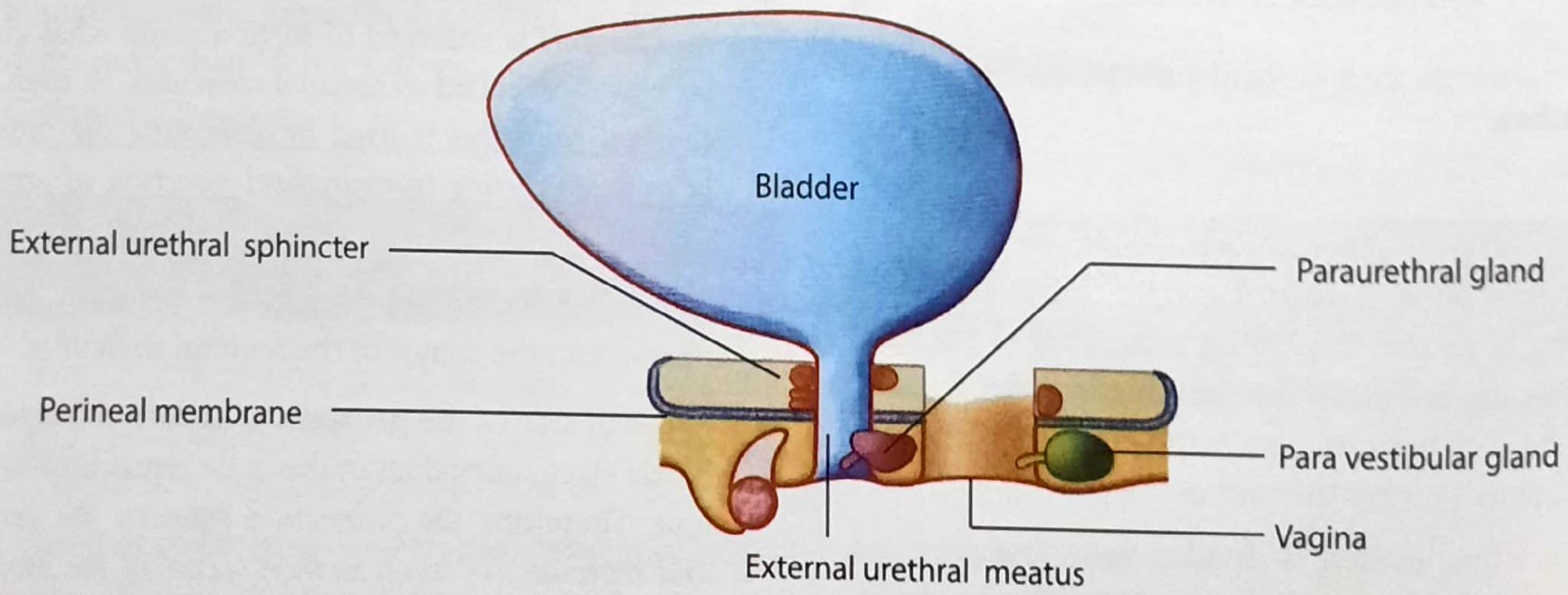

Figure 47.2: Anatomy of female urethera

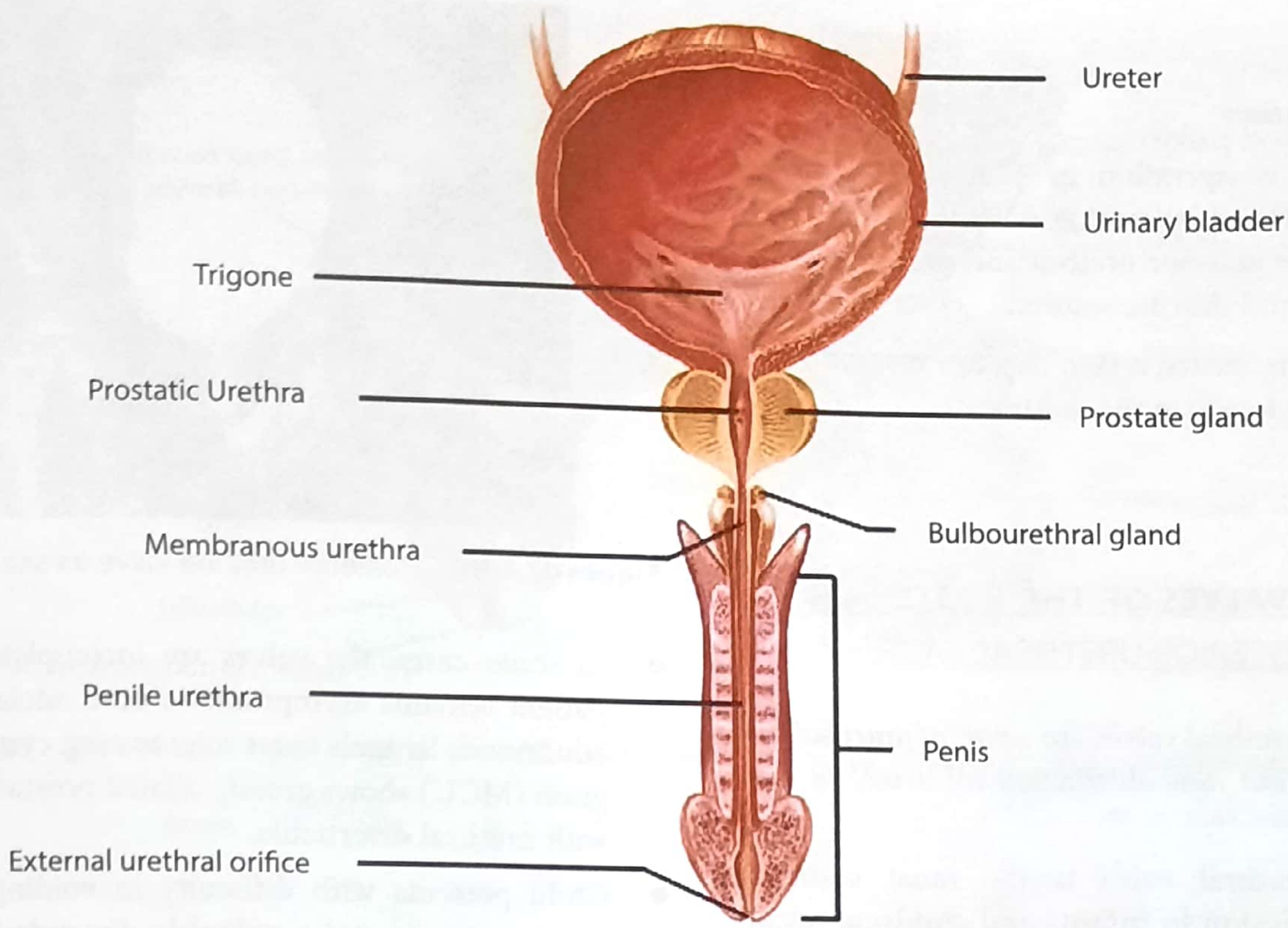

Figure 47.3: Anatomy of male urethera

In Women

In women, the urethra is short, being about 4 **cm long** *(MANY PGME)*. It travels in slightly curved course, as it passes interiorly through the pelvic floor into the perineum; where it passes through the deep perineal pouch and perineal membrane before opening in the vestibule that lies between the labia minora (figure 47.2).

The urethral opening is anterior to the vaginal opening in the vestibule. The inferior aspect of the urethra is bound to the anterior surface of the vagina. Two small paraurethral mucous glands (**Skene's glands**) are associated with the lower end of the urethra. Each drains via a duct that opens onto the lateral margin of the external urethral orifice.

Till now we were discussing brief surgical anatomy of urethra, Now we will discuss diseases related with urethra.

*****

MEATAL STENOSIS

The external urethral meatus is the narrowest part of the male urethra. The stenosis of the external urinary meatus may be congenital or acquired.

Etiology

Congenital meatal stenosis is associated with phimosis. The condition may be acquired due to meatal ulceration, either spontaneously or after circumcision.

Clinical Features

- In lesser degrees of stenosis, there may be weakening of the normal urinary stream, with spraying or dribbling.
- In severe degrees; the meatal opening is reduced to a pinhole and may lead to chronic retention of urine and back pressure changes.
- Later it may lead to back-pressure effects and eventually to hydronephrosis and chronic renal failure.

Treatment

1. *Metal dilatation*
2. ***Meatotomy*** is operation in which the tightened meatus is opened by cutting down on a fine probe placed in the anterior urethra and the cut edges of urothelium and skin are sutured.
3. If the stenosis recurs; a skin flap can be laid in as a **meatoplasty** to widen the meatus.

*****

CONGENITAL VALVES OF THE POSTERIOR URETHRA (POSTERIOR URETHRAL VALVE)

- Congenital urethral valves are a *pair of* ***mucosal fold*** *which cause out flow obstruction (of urine) in male child.* (MANY PGME, AIIMS, AL, UP)
- Posterior urethral valve is the **most common obstructive lesion in infants and children, occurring only in males** (NEET) and are found at the distal prostatic urethra, (MANY PGME). Must see figure 47.4, a & b.
- *These are usually found just distal to verumontanum, within the prostatic urethra.* (PGME, UP 03)
- They work as a one-way valve so, although urine does not flow out normally, however an urethra! catheter can be passed in bladder easily. (***Ball-valve mechanism***)

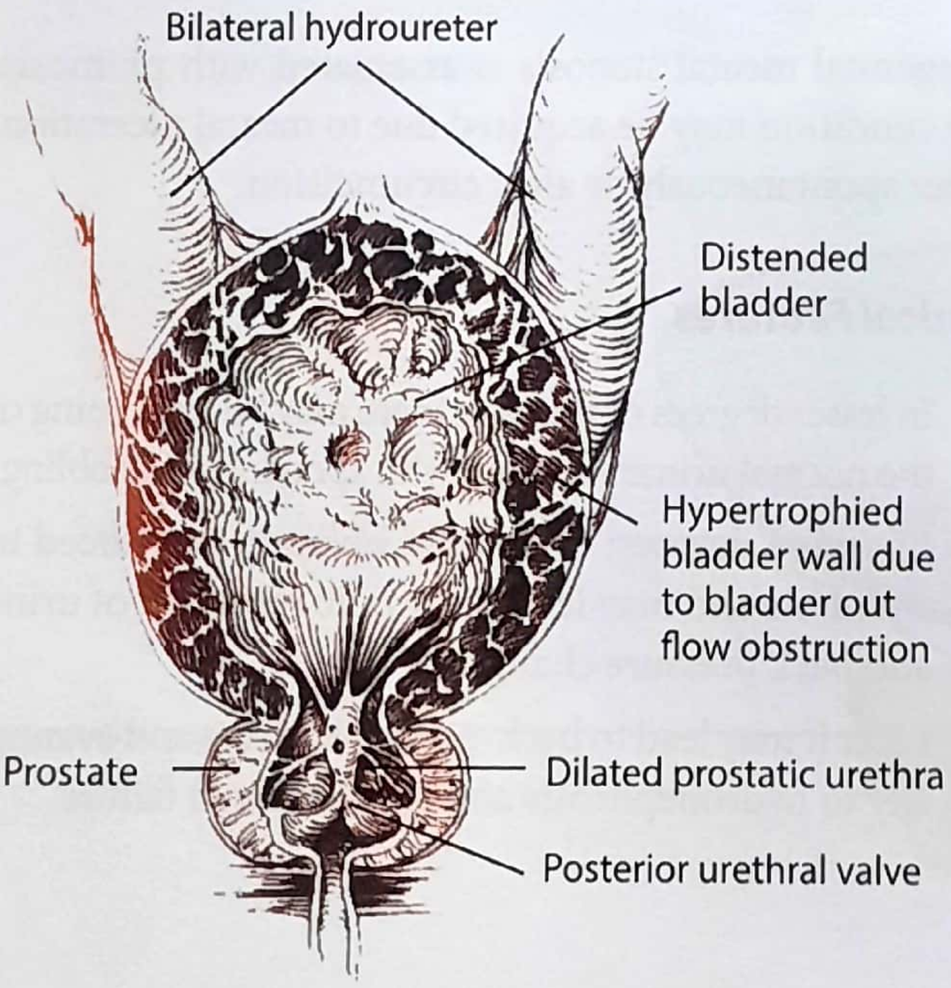

Figure 47.4(a): Post urethral valve

Figure 47.4(b): Posterior urethral valve as seen on MCU

- In some cases, the valves are incomplete and the patient remains asymptomatic until adolescence or adulthood. In such cases micturating cystourethrogram (MCU) shows grossly dilated prostatic urethra with urethral diverticula. (PGME)
- Child presents with difficulty in voiding, a weak urinary stream and a **palpable distended bladder,** which produces dull percussion note. (AIIMS 2006)
- If meatal stenosis and phimosis are excluded; any lower urinary tract obstruction disorder in a male newborn or young child should be considered due to posterior urethral valves until proved otherwise. (AIIMS JUNE03)

Management

The valves are difficult to be seen on urethroscopy, but if the bladder is filled with contrast medium, the dilatation of the urethra above the valve can be demonstrated on a **micturating cystourethrogram** (MCU) (AIMS 97, PGI 02, 03) (figure 47.4b)

- The treatment first consists of improving the impaired kidney function, for this a supra pubic cystostomy is performed. (fig. 47.10 on page 877)
- *Definitive treatment consists of endoscopic transurethral resection of the valves.* (IMP. POINT, MAY BE PGME Q)

*****

HYPOSPADIAS

- Hypospadias occurs in one in 350 male births and is the **most common congenital malformation of urethra**. (NEET, PGI 80, TN 99) It is due to the failure in complete development of distal urethra to varying degrees. (PGI JUNE 03)

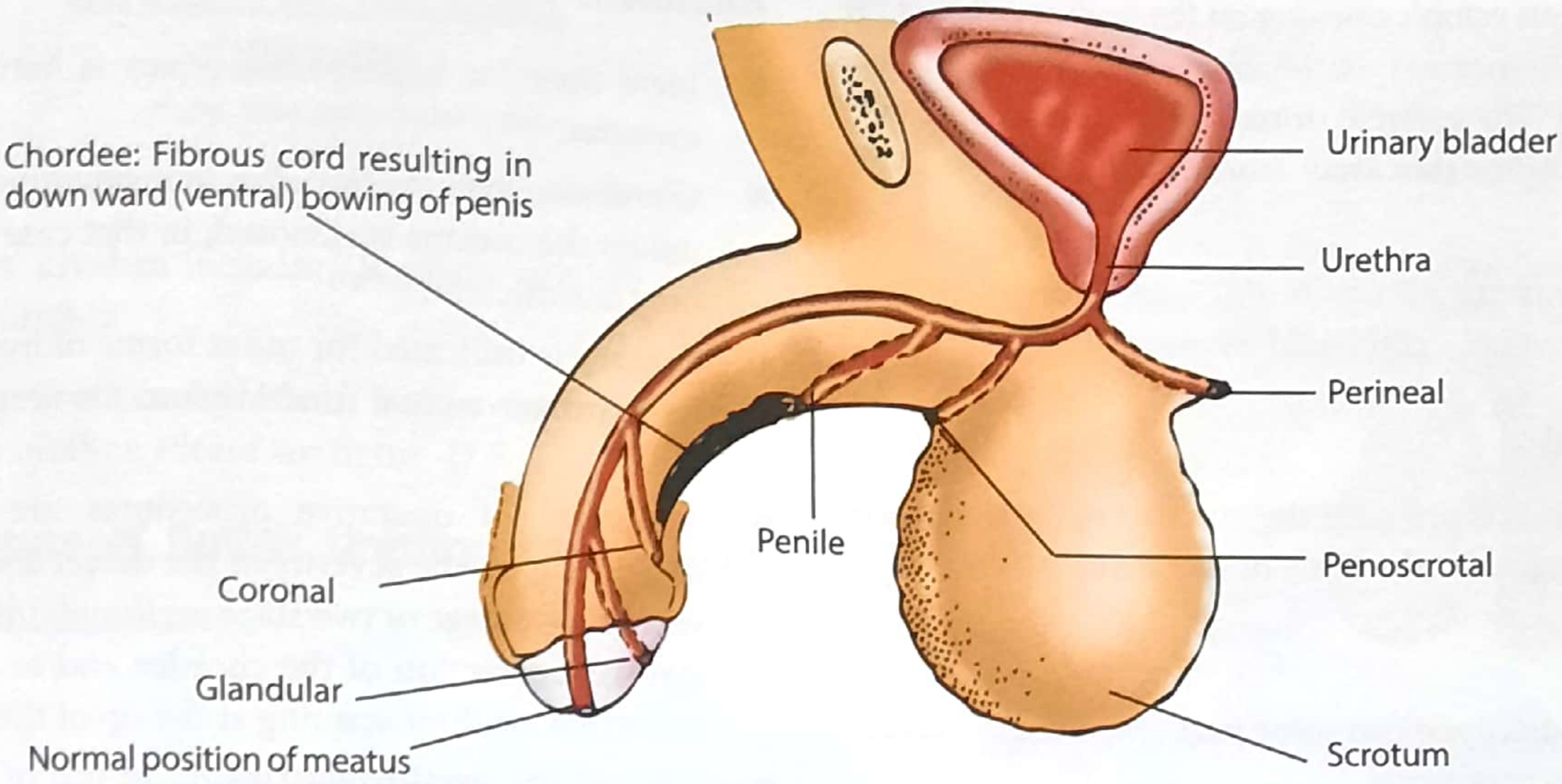

Figure 47.5: Sites of opening of external urethral meatus in various types of Hypospadias in coronal section

- **The external urethral meatus opens on the under-side (ventral side) of the penis** or the perineum and may be **stenosed.** The inferior aspect of the prepuce is poorly developed and is called as ('Hooded prepuce') *(PGI DEC 99)*

[For Hindi speakers: Hooded prepuce means - Saap ke phan jaisi prepucial skin]

- In more severe varieties, there is absence of the: (i) urethral plate and (ii) corpus spongiosum distal to ectopic external meatus opening. These non formed (absent) structures are *replaced by a fibrous cord, which deforms the penis in a down ward direction, resulting in down ward bowing of the penis, called as* ***Ventral chordee*** *(PGI DEC 99)*. Please see figure 47.5.
- The more distant is the abnormal urethral opening from normal urinary meatus (ie; proximal on penile shaft); the more pronounced is the bowing, ie; more severe is the chordee.

In Easy language: The urethra that does not develop distal to abnormal urethral opening on penis; is replaced by a fibrous tissue. This fibrous tissue band produces a down ward bowing of penis; giving penis a shape of "Dhanush (bow)". This bowing of penis is called as ventral chordee. Longer is the fibrous cord; more pronounced is bowing and hence greater is chordee.

Classification

1. Glandular

- This is the **most common variety** *(NEET)* and accounts for about 80% of the cases. *(AIIMS DEC 95, MANY PGME)*

JUST TO REMEMBER: Small *g* appears like **8**, *g*landular hypospadias is found in **80%**

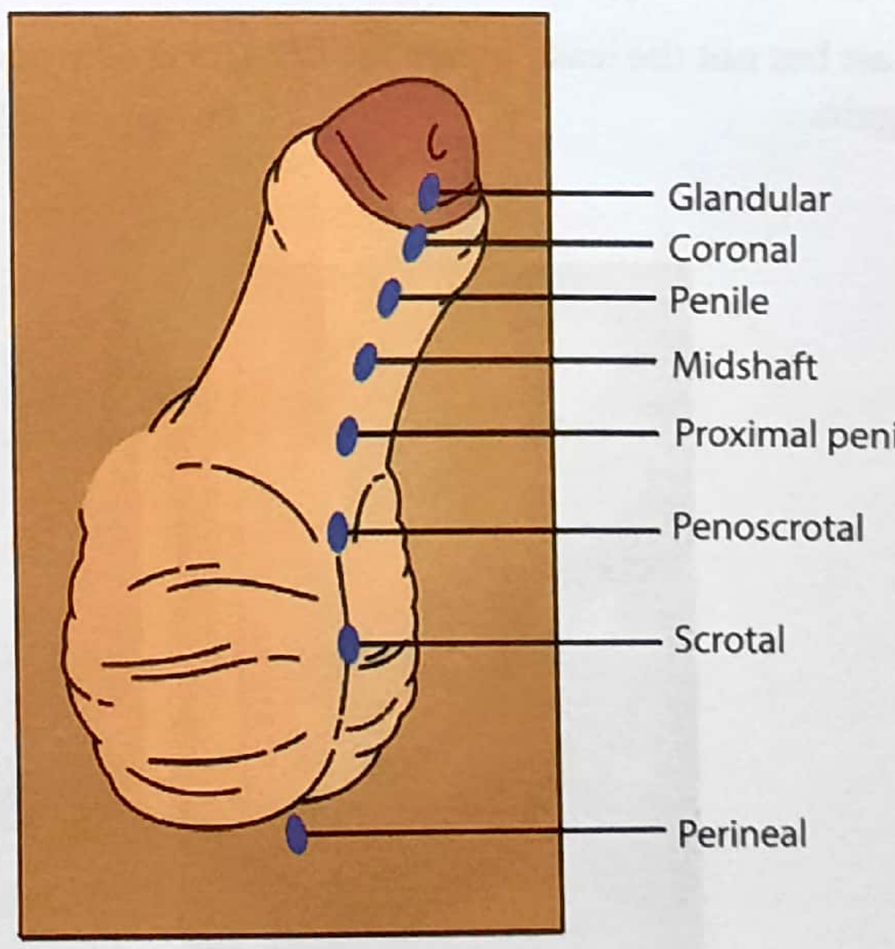

Figure 47.6: Hypospadias. Note: its various types according to the location of urethral orifice on under surface of penis)

- There is an ectopic opening on the *under surface of the* ***glans***. The normal site of the meatus is marked by a blind pit. The external urinary meatus is situated with in **few millimeter away from normal site on glans** *(NEET)*.
- *Chordee is not present in this type, because external urethral meatus is situated on glans* *(PGI 80, AIIMS80)*

2. Coronal

- The meatus is placed at the junction of the underside of the glans and the body of the penis.

3. Penile

- The meatus opens on some part of the under surface of the body of penis.

4. Penoscrotal

- The urethra opens at the junction of the penis with the scrotum.

5. Perineal

- This is the most severe and fortunately rarest form.
- The urinary meatus is found behind a cleft scrotum; there may be testicular maldescent and many times it becomes very difficult to known about the sex of the newborn.
- It is important to differentiate these patients from an intersex. Abdominal ultrasound may be required to identify undescended testes. *Karyotyping is most helpful in identifying the sex* *(AIIMS 81, AMU 87)*
- Last but not the least, please see fig. 47.5 & 47.6 once again.

Treatment

- Ideal time for hypospadias repair is between **6-12 months**. *(NEET, MANY PGME, AIIMS, UP 97)*
- *Glandular hypospadias does not require treatment,* unless the meatus is stenosed, in that case a meatotomy is sufficient. *(UP 97)*
- Surgery is indicated for other forms of hypospadias **to improve:-** sexual function and for cosmetic reasons.
- A variety of operative procedures are available depending on the severity of the defect and may involve single stage or two stage *urethroplasties:-* which involve: correction of the chordee and to bring the abnormal urethral opening at the tip of the penis.
- Most of the **urethroplasties** make use of 'hooded' prepucial skin in fashioning urethral tube; and it is for this reason *circumcision,which involves excision of prepucial skin, should be avoided until* hypospadias has been repaired. *(AI, AIIMS, PGI).*

EPISPADIAS

- Epispadias is *very rare* *(PGI 81, UPSC 86)*
- In this condition the external urethral opening is on dorsum (or upper surface) of penis, associated with upward curvature of the penis, (dorsal chordee). *(AI 08)*
- Epispadias is almost always associated with ectopia vesicae. (note the position of urethral opening fig 47.7)

*****

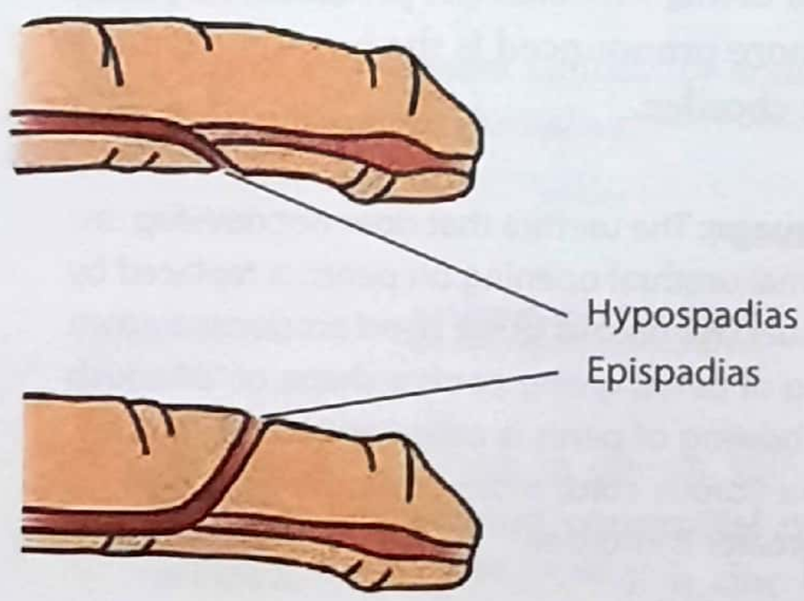

Figure 47.7(a): Types of epispadias

INJURIES OF THE MALE URETHRA

Before discussing injuries to the male urethra; kindly note :

Posterior urethra includes : Prostatic urethra + membranous urethra

Anterior urethra includes : Bulbar urethra + Penile (spongy) urethra. Please see figure 47.7

A. Rupture of Bulbar Urethra (Anterior Urethra)

Etiology

- This is the ***most common*** *urethral injury* (PGME).
- It usually follows a blow to the perineum, as in a fall astride a projecting object, cycling accident, loose manhole covers, gymnasium accidents or instrumentation.
- Blunt force against the sharp inferior margin .of the symphysis pubis tears the bulbar urethra and some times fracturing the bone at the same time.

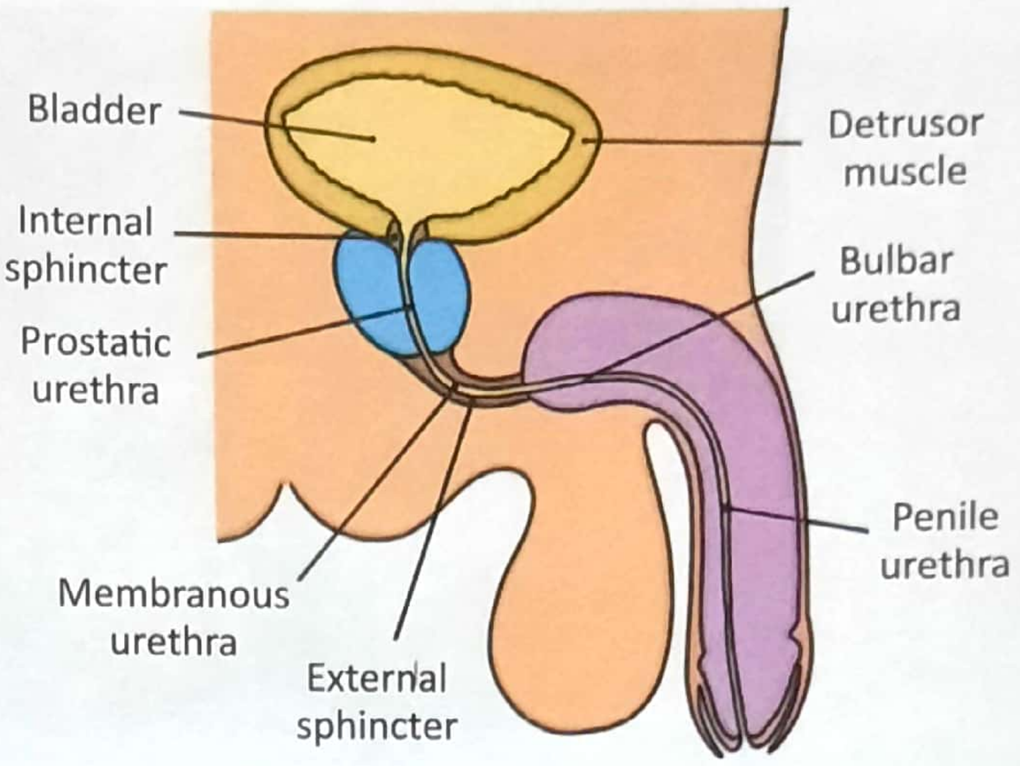

Figure 47.7(b) : Parts of male urethra

Extravasation of Urine

It is almost always the bulbar part of urethra which is injured; while penile (spongy) urethra is rarely injured. Urine and blood may escape from the damaged urethra into the closed space below urogenital diaphragm, enclosed by the fascial layers of Scarpa and Colles.

NOTE: *dotted area denotes area of superficial extravasation of urine in anterior (bulbar) rupture of urethra.*

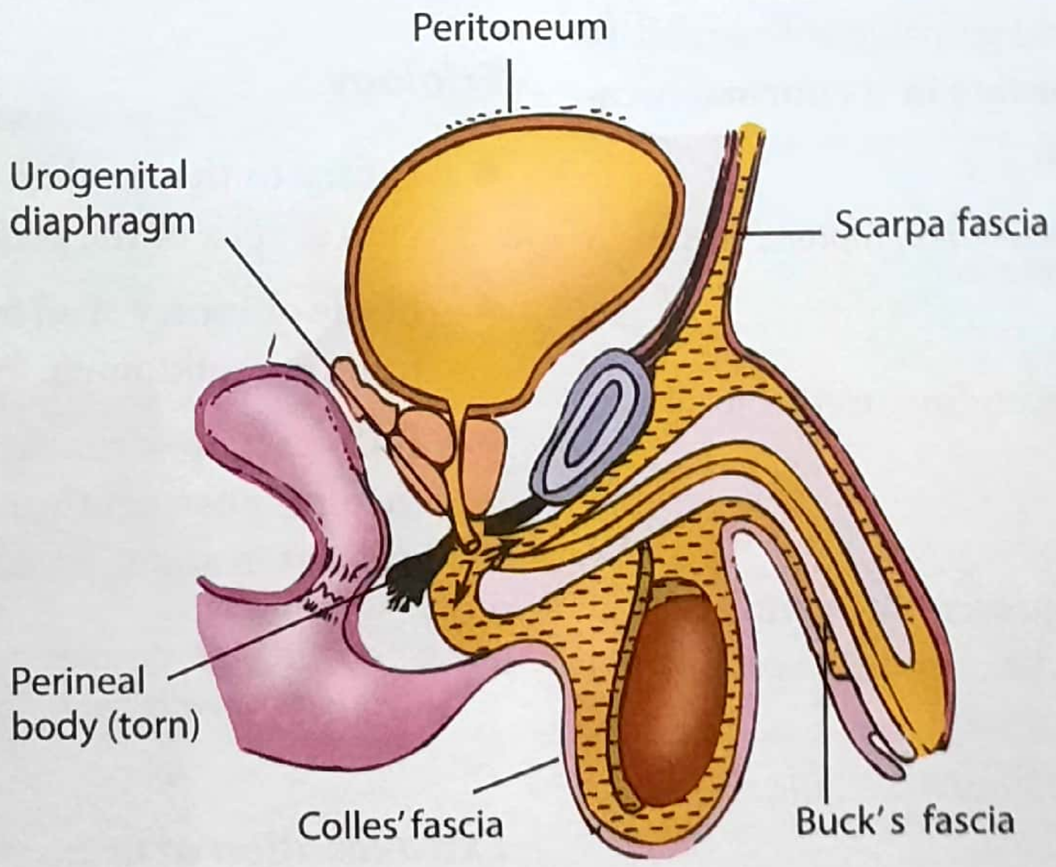

Note: *Dotted area denotes area of superficial extravasation of urine in anterior rupture of urethra.*

Figure 47.8: Superficial extravasation in anterior (bulbar) urethra rupture

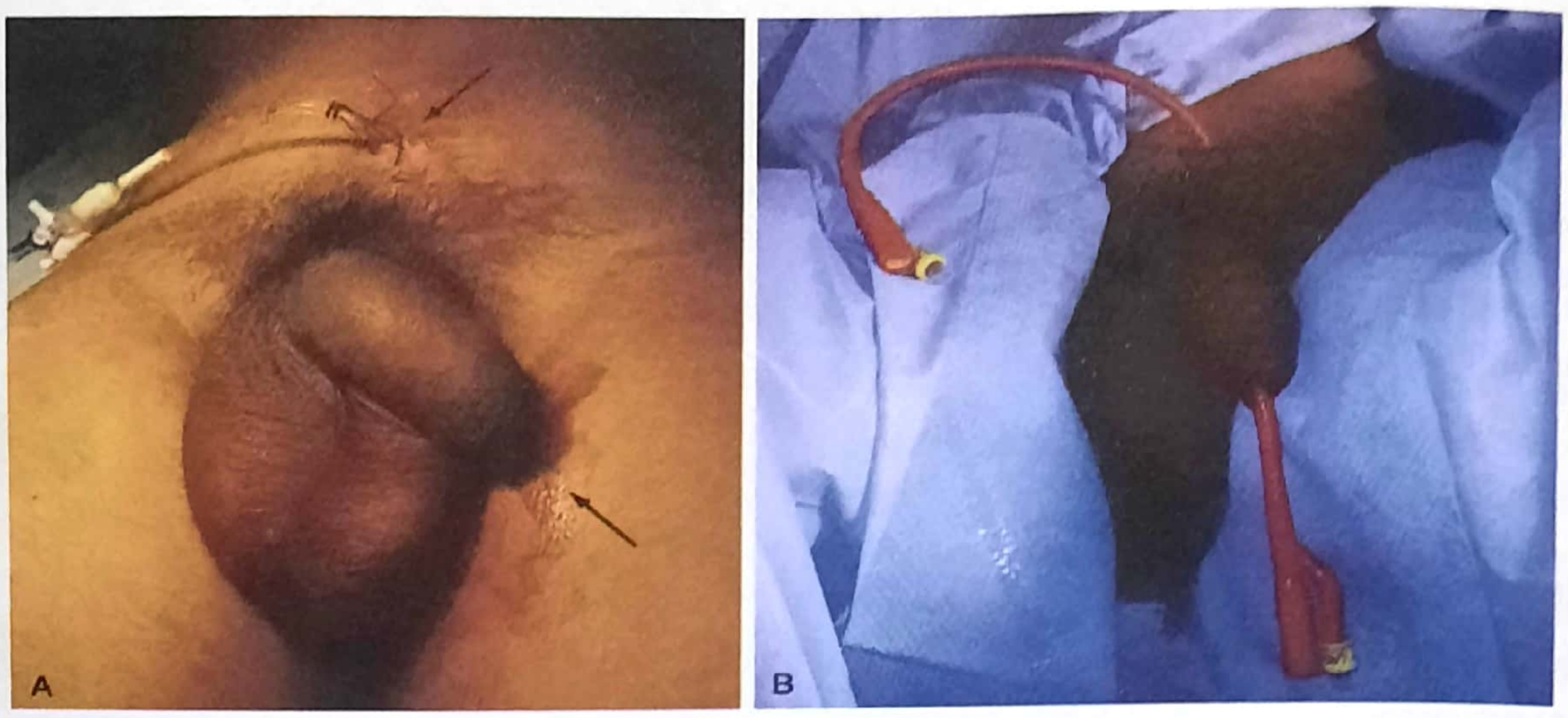

Figure 47.8 Extra (a, b) : Posterior urethral disruption injury. (A) Patient with blood visible at pe meatus is managed with percutaenously placed suprapubic cystostomy tube. (B) Patient initially managed similarly has undergone an endoscopic, fluroscopically guided realignment procedure with placement of urethral urethral and suprapubic Foley catheters.

The extravasation of urine occurs in *superficial perineal pouch* and then passes into scrotum, penis and lower anterior abdominal wall; called as **superficial extravasation,** *(MANY PGME)*. Please see fig. 47.8, very carefully.

Clinical Feature

- **The triad** consist of:-
  1. **Urethral bleeding** *(NEET)*, as few drops at tip of urethral meatus. *(IMP. POINT)*
  2. **Perineal hematoma** *(NEET)* and
  3. **Retention of urine due** *(NEET 20)* to spasm of the vesical sphincter *(AIIMS JUNE 93)*
- The bladder is distended and palpable with **inability to pass urine; with the prostate in its normal location on rectal examination** *(NEET, AIIMS 93, MANY PGME)*.

NOTE: *In membranous urethra (post, urethra) rupture, prostate is high lying and floating (MANY PGME).*

- Investigation of choice is ascending urethrography.

Treatment

The most important thing is to prevent the extravasation of urine, for this a supra pubic cystostomy* is performed and *no urethral manipulation should be done initially; because any urethral manipulation done at this stage will turn a partial rupture to a complete .* *(AIIMS NOV 02, 01)*

After about 10 days the urethra is inspected with an urethroscope and in most cases the laceration has healed well. If stricture formation has occurred; it should be treated by urethotomy or urethral dilatation.

* *Supra pubic cystostomy:* Suprapubic + Cyst + otomy= Supra pubic + bladder + hole ie; A hole is made in bladder after opening bladder through anterior abdominal wall; just above pubic bone and then a foley's catheter is passed in it through supra-pubic puncture. This provides drainage of urine. See figure 47.10, to understand suprapubic cystostomy.

NOTE: word "cyst" here is used for bladder eg; cysto lithotomy (extraction of urinary bladder stone), cystoscopy (endoscopic visualization of urinary bladder).

B. Rupture of Membranous Urethra (Post-Urethra)

Etiology

- **Injury to the urethra with pelvic fracture** *(NEET)* occurs at apex of the prostate. *(MANIPAL 08)*
- **Mode of injury** : Fall from height, car accident, blunt trauma to abdomen. *(AI 03)*
- **Both extra peritoneal rupture of bladder and rupture of post urethra (membranous urethra) are present** in about 10-20 % of cases. *(NEET, IMP. POINT)*

NOTE: *dotted area denotes area of superficial extravasation of urine in membranous (post-urethra) rupture of urethra.*

Extravasation of urine *(AIIMS NOV 03, IMP. POINT)*

Deep extravasation occurs with rupture of membranous urethra (post-urethra) and extraperitoneal rupture of bladder. The urine *gets collected in deep perineal pouch.* *(MANY PGME)*

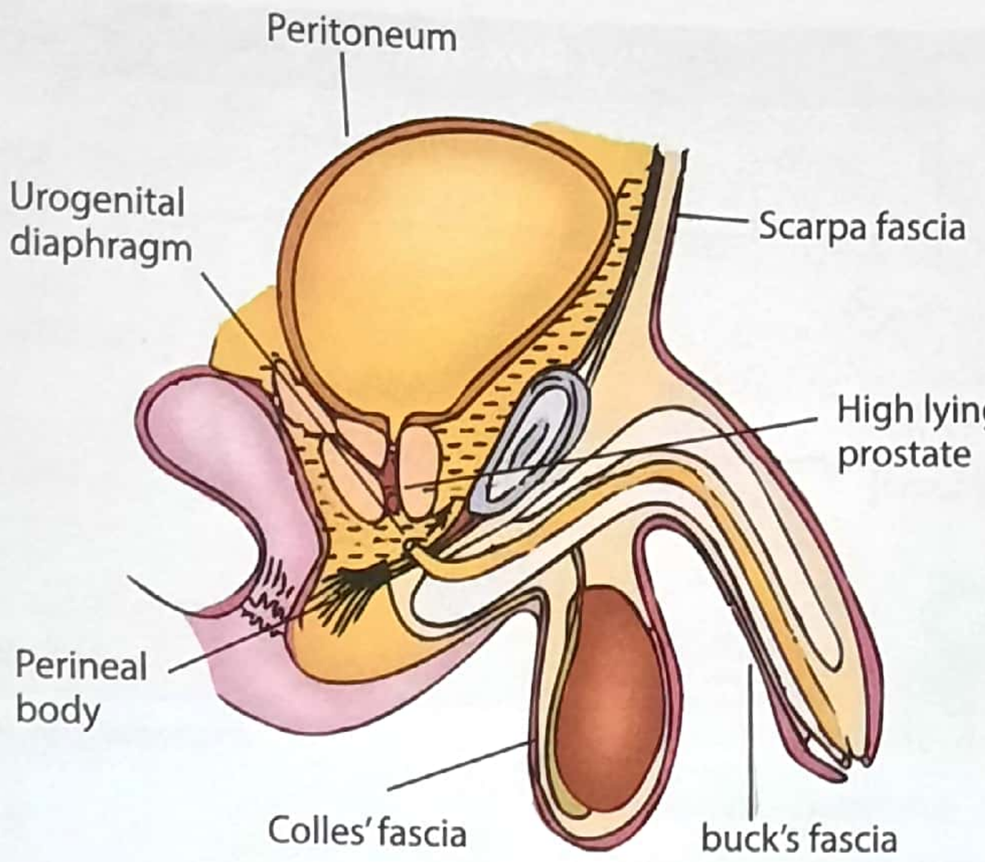

Dotted area denotes area of urinary extravasation in deep extravasation of urine in membranous rupture of urethra

Figure 47.9: Deep extravasation of urine in posterior (membranous) urethra rupture

Clinical Features

The clinical picture depends upon the type of urethral injury. Urethral injury can be incomplete or complete:-

(i) Incomplete type

- Blood may be ***expressed from the urethral meatus.*** (NEET)
- The patient may not be able to pass urine. (AI 07)
- Hematuria

(ii) Complete type

- There may be associated extraperitoneal rupture of the bladder.
- There will be pain, bruising and dulness to percussion below the umbilicus.
- It is usually associated with **pelvic hematoma** (AI, UP).

Note: Anterior (bulbar) urethra rupture is associated with perineal hematoma.

- Rectal examination may reveal *superior displacement of the prostate* (gland may be impalpable on PR examination) due to complete disruption of pubo-prostatic ligament. *Prostate becomes high lying and is also called as floating prostate* (NEET, AIIMS, PGI).

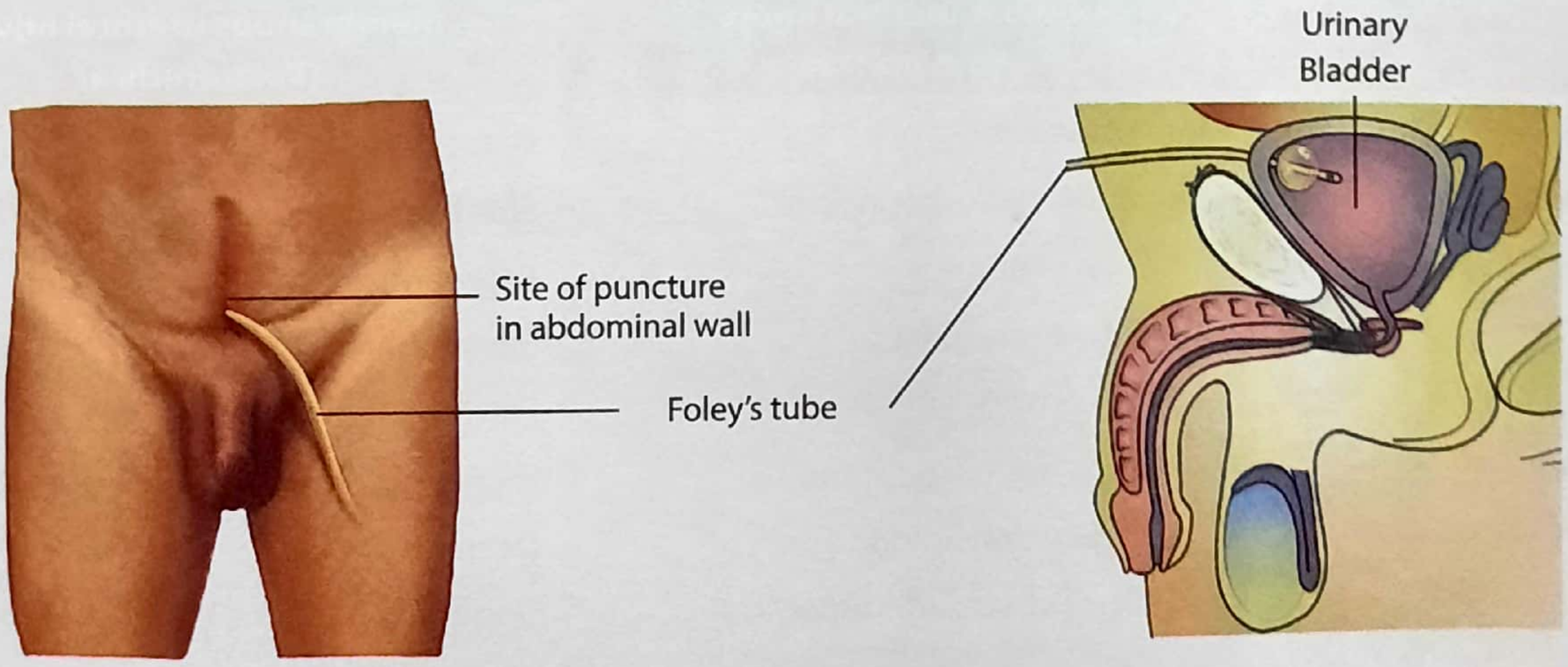

Figure 47.10: Supra pubic cystostomy

KEY BOX 47.1

Definitive management *(NEET 20)*

- **Short segment incomplete stricture**
  - Optical/Visual internal urethrotomy
  - 40-50% cure rates
- **Short segment complete**
  - End to end anastomosis
- **Long segment complete/incomplete**
  - Urethroplasty
  - **Graft** - Buccal mucosal graft
    - Penile foreskin

- The *bladder is distended and become palpable;* because of **inability to pass urine** *(NEET)*; due to the injury to the urethra or because of spasm of the internal sphincter.
- *Complete rupture of membranous urethra is almost always associated with pelvic fracture.* *(AIIMS, AI, UP, MANY PGME)*

Treatment

Rupture of membranous urethra is associated with pelvic fracture. Patient presents with hypovolemic shock due to high loss of blood (about l-2liters) due to fracture of pelvic bone. First and most important step in treatment is correction of shock and hypovolemia. *(AIIMS 84)*

- **An urinary catheter should not be passed** in these cases; as it may convert an incomplete (partial) tear into a complete one. *(AIIMS NOV 01, AIIMS NOV 99, PGI JUNE 03)*
- The **management** of injuries to the membranous urethra is somewhat controversial; There are two school of thoughts:

(I). Immediate exploration of urethra with primary urethral anastomosis: but this may lead to increased incidence of complications like stricture, impotence and incontinence and should be abandoned.

(II) Supra pubic cystostomy without urethral manipulation *(KERALA 95)*: A supra pubic catheter is put in bladder after doing suprapubic cystostomy. The catheter is left in bladder for 6-8 weeks. At that time, a cys-

KEY BOX 47.2

Comparison of Bulbar and Membranous urethral injury

	Bulbar urethral injury (Ant. urethra)	Membranous urethral injury (Post-urethra)
Incidence	More common	Less common
Mechanism of injury	Direct blow to the perineum	Blunt pelvic trauma with fracture pelvis*
Signs and symptoms	Retention of urine Blood at urethral meatus Perineal hematoma	Retention of urine Blood at urethral meatus Pelvic hematoma
PR examination	Prostate at normal position	High lying prostate (floating prostate)
Extravasation of urine	Superficial extravasation Urine first collects into superficial perineal pouch and then passes into scrotum, penis and ant. abdominal wall	Deep extravasation Urine collects in the perivesical space

togram and urethrogram are performed to access the extent of resulting urethral stricture, (fig. 47.10) The stricture is then repaired by excision and anastomosis to the bulbar urethra.

Complication of Rupture Urethra

1. *Stricture* - The **most common** complication of urethral trauma is urethral stricture. (JIPMER 92)
2. *Urinary incontinence*
3. *Erectile impotence*

Please read key box 47.2 very carefully, very important.

*****

URETHRITIS

Urethral infection could be caused by gonococci **(gono-coccal)** or by chlamydia or Mycoplasma **(nongonococcal).** Mixed infections are also common. Usually these pathogens are sexually transmitted. Severe dysuria **(scalding pain during urination)** (NEET) with or without purulent discharge and initial hematuria are characteristic. On examination; meatal hyperemia, mucosal pouting, urethral discharge and tenderness may be detected. Specimen should be obtained from within the urethra and not just from a drop of discharge. A urethral smear shows the characteristic diplococci with multiple pus cells in case of gonococcal urethritis. If no diplococci are seen, nongonococcal urethritis should be suspected.

Ceftriaxone (125 mg; intramuscular) for gonococcal urethritis and azithromycin (1 gm oral, **single dose**) for nongonococcal cases are the current choices. Urethral strictures and infertility may occur as sequelae. The disease, if treated in time, resolves completely. In cases of neglected, acute urethritis, periurethral glands may get involved and may suppurate. Such an event is more frequent when urethritis complicates in a urethral stricture. These abscesses may later rupture in the perineum to form urethral fistulae.

*****

URETHRAL STRICTURE

Stricture of the urethra may be defined as an abnormal constriction of lumen of urethra.

Etiology

1. **Congenital**
2. **Post inflammatory**
   - Post gonococcal urethritis-Commonly involves bulbar urethra (JIPMER 87)
   - Non-gonococcal urethritis
   - Tuberculosis
3. **Post-instrumentation (Most common cause)**
   - Urethral catheterization
   - Bougie dilatation
   - Transurethral endoscopic procedures
4. **Postoperative**
   - Prostatectomy
   - Amputation of penis
5. **Traumatic rupture of urethra** This is second most common cause of urethral stricture. (KAR. 96)

Clinical Feature

- The common presenting symptoms are dysuria, weak stream, deviation of normal urinary stream.
- Most of the patients complain of difficulty in urination.
- Usually the patient is younger than those of BPH.
- *On straining there may be improvement of the stream, while in BPH there occurs further weakening of urinary stream.* (IMP. POINT FOR D/D)

Figure 47.11: RGU for penile stricture urethral

- Back pressure effects like bladder diverticulum, vesicoureteric reflux, hydroureter and hydronephrosis may occur in very late cases.

Treatment

There are three types of treatment. A retrograde urethrogram will delineate the site and degree of stricture.

1. Instrumental dilatation - By Bougies.
2. Endoscopic urethrotomy
3. Urethroplasty.

Complication (KER 96)

1. Retention of urine
2. Urethral diverticulum
3. Periurethral abscess
4. Urethral fistula
5. Increased incidence of hernia, hemorrhoid and rectal prolapse due to abdominal straining to void urine.

*****

Male Urethral Carcinoma

- Rare cancer
- **Etiology** : chronic inflammation due to STD, urethritis, stricture HPV 16.
- **Clinical Features :**
  - Urethral bleeding
  - Urethral mass
  - Obstructed voiding
- Site — bulbo membranous 60% (M/C)

  Penile 30% and Prostatic 10%

Figure 47.12: Foley's catheter (18 french)

- Pathology — Sq. Cell CA (85%) > Transitional cell CA (15%)

Foley's catheter

It used in acute or acute on chronic retention of urine to deflate the urinary bladder. When it is passed through urethra to bladder.

Colour coding is very important:

French (size)	Colour
10	Black
12	White
14	Green
16	Orange
18	Red
20	Yellow

*****

Sample Questions for Prof Examination

Write short notes on

1. Hypospadias.
2. Epispadias

48 The Penis

Contents

- Surgical Anatomy
- Phimosis
- Paraphimosis
- Balano posthitis
- Peyronie's disease
- Priapism
- Carcinoma of penis

SURGICAL ANATOMY

The penis is composed mainly of the two corpora cavenosa and Single corpus Spongiosum, which contains the urethra (Fig 48.1). It has an attached part (root) and a free part (body): The **root of penis** consists of the two crura, which are proximal parts of corpora cavernosa and are attached to the pubic arch & the **bulb of penis;** which is the proximal part of the corpus spongiosum; anchored to perineal membrane.

The body of penis which is covered entirely by skin, is formed by the tethering of the two proximal free parts of the corpora cavernosa and the related free part of the corpus spongiosum.

- Because the *anatomic position of the penis is erect,* the paired corpora are defined as dorsal in the body of the penis and the Single corpus Spongiosum as ventral, even though the positions are reversed in the nonerect (flaccid) penis.
- The *corpus spongiosum expands to form the head of penis* **(glans penis),** over the distal ends of the corpora cavernosa.
- The skin covering the penis is very thin and dark in colour. It is loosely connected with the fascial sheath of the organ. At the neck it is folded to form the prepuce or foreskin which covers the glans to a varying extent and can be retracted backwards to expose the glans. On the under surface of the glans there is a median fold of skin called the *frenulum.*
- The potential space between the glans and the prepuce is known as the *preputial sac.* On the corona

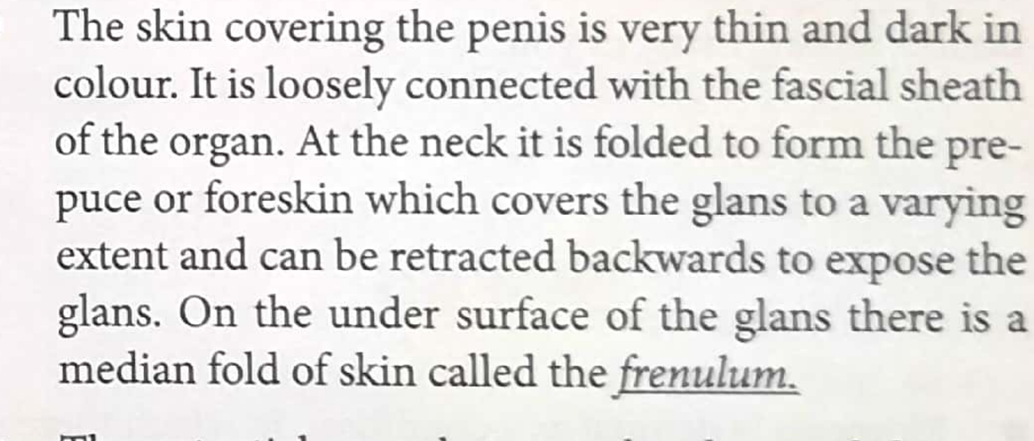

Figure 47.1: Transverse section through body of the penis

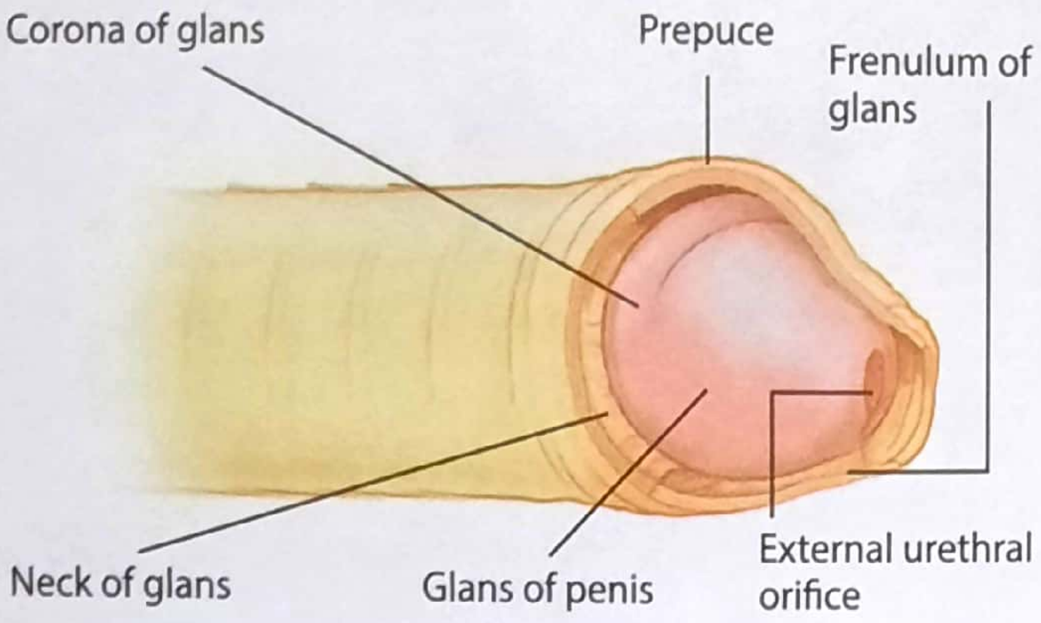

Figure 48.2: Your penis

glandis and on the neck of the penis, there are numerous small preputial (sebaceous) glands which secrete a sebaceous material called **smegma,** which collects in the preputial sac.

- Lymphatic channel from superficial tissue of penis drain into superficial inguinal node. The glans penis drain into deep inguinal node & external iliac nodes.

NOTE: Preputial glands are also called as *tyson's gland.*

Now lets discuss diseases related to penis. But before this please go through key box 48.1, which will remove doubts among many of you.

*****

PHIMOSIS

- Phimosis is defined as a condition, in which there is difficulty to retract the prepuce fully and freely over the glans, up to the coronal sulcus.
- The physiological adhesions between the foreskin and the glans **may persist till the age of 6** (NEET) giving the false impression of phimosis; a condition known as **physiological phimosis.** Fig. 48.3 (a)

KEY BOX 48.1		
This is a key box for those who are much concirned about		
Penile State	**Length (cm)**	**Circumference (cm)**
Flaccid	8.8 (3.4 inch)	9.7
Stretched	12.4 (4.9 inch)	-
Erect	12.9 (5.1 inch)	12.3

KEY BOX 48.2
Causes of Phimosis: 4 "C"
• Carcinoma of penis
• Balanoposthitis
• Preputial stone/calculus
• Paraphimosis

Etiology

1. **Congenital:** This is most common cause and is seen in young children.
2. **Secondary to chronic balanoposthitis:** This is common in elderly and in diabetics.

Balanitis means inflammation of (for hindi speaker: Belaan) glans of penis; posthitis means inflammation of the prepucial skin.

3. **Carcinoma:** Of the penis may some time present as phimosis.
4. **Traumatic injury**

Clinical Features

- Congenital phimosis presents in first few years of life.
- Difficulty in micturition is the main symptom. In a case of typical congenital phimosis, the mother complains; that when the child micturates; there occurs ballooning of prepuce *(Secondary bladder*)* and urine comes out in thin stream. (AIIMS JUNE 03)

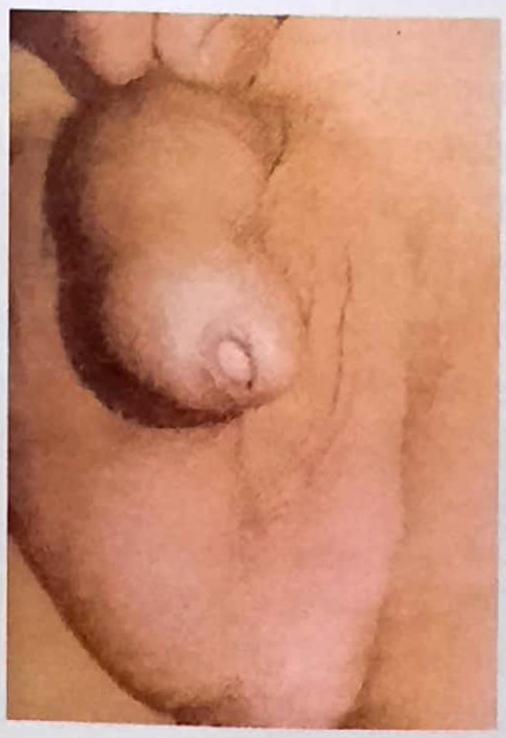

Figure 48.3 (a): Phimosis

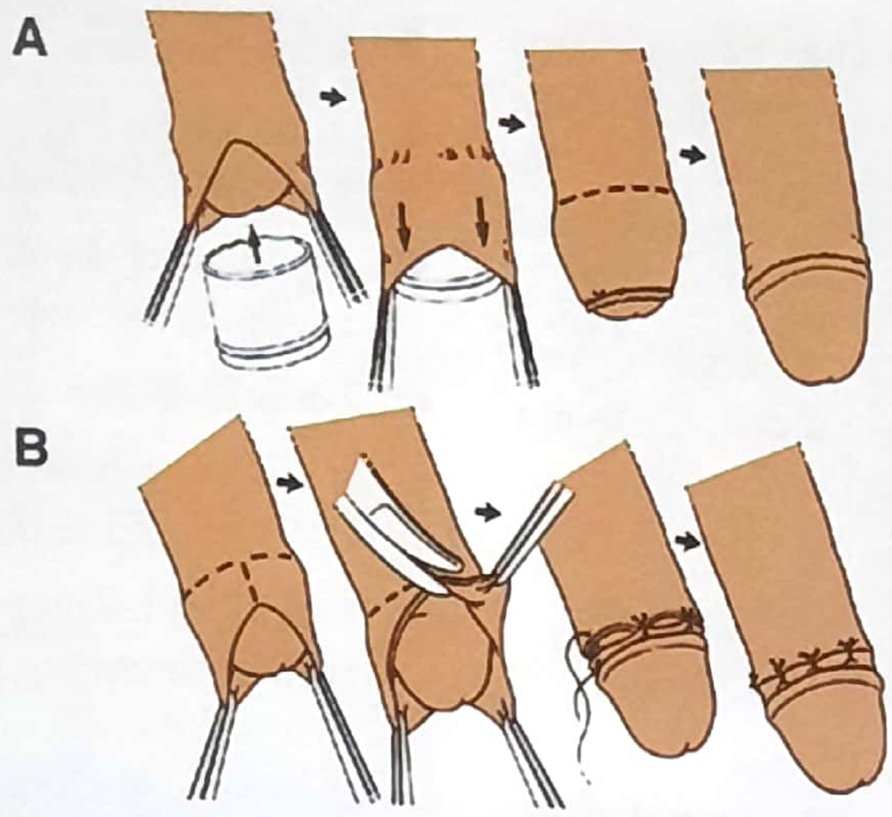

Figure 48.3(b): Steps in circumcision

* NOTE: *Ballooning of preputial skin gives appearance of a saccular bag, called as secondary bladder or neobladder.*

Treatment (AIIMS 05, MANY PGME, AI 2011)

The treatment is circumcision.

Circumcision (Khatna/musalmani)

Circumcision in excision of the preputial skin and thereby exposing the glans of penis.

Indication (TN 91, MANY PGME)

1. **Circumcision is most commonly** (NEET) done for religious reasons; as in Jews and Muslims.
2. **Phimosis.**
3. **Paraphimosis.**
4. Recurrent balanoposthitis.
5. Carcinoma of penis.

Steps (MAY BE ASKED IN FINAL YEAR VIVA)

1. The operation is usually performed under general anesthesia in children, however local anesthesia may be employed in case of adult.
2. Two pairs of artery forceps are applied to the prepuce at 11 O'clock and 1 O'clock position and a dorsal slit is made at 12 O'clock, up to about 5 mm proximal to tip of glans.
3. Then the prepuce (with mucus membrane layer) is divided 5 mm. parallel to corona, laterally till the frenulum is reached (ie., 6 O'clock)
4. All the bleeding vessels are ligated with particular care to secure the ***frenular artery***.
5. Now the skin of cut end of prepuce is sutured to the mucous membrane with fine interrupted catgut suture. {Please see fig. 48.3 (b)}.

*****

PARAPHIMOSIS

- Paraphimosis is the inability to reduce a previously retracted prepuce. The *prepuce becomes fixed in retracted position,* proximal to the coronal sulcus and *can not be replaced* in normal position. (Fig. 48.4)

Figure 48.4: Paraphimosis (Prepuce becomes fixed in retracted position)

- The constricting band of prepuce behind the corona causes the obstruction to the venous outflow, which lead to edema and congestion of glans. Later the preputial constricting band also gets edematous and swollen.
- Paraphimosis may occur due to chronic inflammation, after catheterization; when prepuce is not brought back to normal position and sexual malpractice. *(AIIMS 98)*

Treatment

(PGI JUNE 96, UPPGME)

- Manual reduction (returning back to normal position) can usually achieved by using index finger and thumb.
- Local injection of 150 unit of *hyaluronidase* helps in reducing the edema and helps reduction to be achieved rather easily. *(PGME)*
- If this fails; the constricting ring of the prepuce may be incised on dorsum of the penis *(dorsal slit)* and the fore skin can now be reduced with relative ease.
- Circumcision; the definitive treatment may be performed immediately or later according to the circumstances.

*****

BALANO-POSTHITIS

- An inflammation of the ***p***repuce is known as ***p****osthitis,* where as inflammation of the glans (for hindi speaker belaan) of penis is called ***b****alanitis.* The opposing surfaces of the two structures are often involved-hence the term *balano-posthitis.*
- In mild cases, the only symptoms is itching with little discharge, but in acute cases, there is swollen, red and tender prepuce with pus discharge.
- **Balanoposthitis is more common in diabetics.** *(MANY PGME)*

Causes of Balanoposthitis

- Diabetes
- Fungal infection - Candida
- Herpes virus
- Syphilis
- Drug eruption - sensitivity to tetracycline or sulfonarnide and some other drugs.

Treatment

- Treatment is by broad spectrum antibiotics and local hygienic measures.
- The patient should be investigated for diabetes and treated accordingly.
- Fungal infection should receive appropriate treatment.
- If the lesion heals with secondary phimosis, circumcision should be done.
- Recurrent balanoposthitis in a diabetic patient will require circumcision.

*****

PEYRONIE'S DISEASE

- This is a painful condition of unknown etiology usually affecting older men. *(AIIMS NOV 02, KARN 95).*
- **There is a hard white plaque of fibrous tissue** *(NEET)* **in** tunica and sometimes in the septum between the corpora cavernosa; causing deformity & pain on erection.
- The plaques of fibrous tissue may get calcified and can be seen on X-ray. *(UP 06)*
- There is usually a **dorsal curvature** of the penis.
- The condition may be *associated with* ***Dupuytren's contracture*** *(AIIMS 02, UP 06)* and retroperitoneal fibrosis. Some time an auto immune etiology is suggested.
- It is fibroblastic hyperplasia.

Treatment

- The treatment to this condition is difficult.
- The plaque may resolve spontaneously, in about 50% of cases *(AIIMS NOV 02, UP06).*
- When the deformity of the penis is causing distress cavernoplasty may be done. *(Nesbitt's operation)*

*****

PRIAPISM

- This is **painful penile erection** *(NEET)*, not related to sexual stimulation. The blood in corpora cavernosa become hyperviscous; but not clotted. The glans and corpus spongiosum are not involved and remain flaccid: and it is only corpora cavernosa which is involved. *(PGME)*

KEY BOX 48.3		
	Ischaemic priapism	**Non-ischaemic priapism**
Corpora cavernosa fully rigid	Usually present	Seldom present
Penile pain	Usually present	Seldom present
Abnormal cavernous blood gases	Usually present	Seldom present
Blood abnormalities and haematological malignancy	Sometimes present	Seldom present
Recent intracavernous vasoactive drug injections	Sometimes present	Seldom present
Chronic, well-tolerated tumescence without full rigidity	Seldom present	Usually present
Perineal trauma	Seldom present	Sometimes present

- The condition is commonly found in patients with Leukemia, (PGME) sickle cell disease, trauma, pelvic malignancy or in a patient on hemodialysis, *however in most of the cases cause could not be established.*
- If the erection does not subside, aspiration of pooled blood from corpora cavernosa is done with a wide bore needle. In some cases a surgical fistula is made between corpora cavernosa and corpus spongiosum; which directs pooled blood from corpora cavernosa to corpus spongiosum.
- Other procedures; which are various shunt procedures include caverno-glandular shunt, **saphenous vein-cavernous shunt (Grayhack shunt)**. If priapism persists, impotence results.
- Types of priapism in described in keybox 48.3 above

*****

CARCINOMA OF PENIS

Etiology

Because of the religious practice of circumcision, the disease is almost unknown among jews and rare in muslims.

- In Jews the circumcision is done soon after birth in infancy gives almost complete immunity against Carcinoma penis (KERALA 85, KAR. 87), however the circumcision that is done later is life; as in muslims

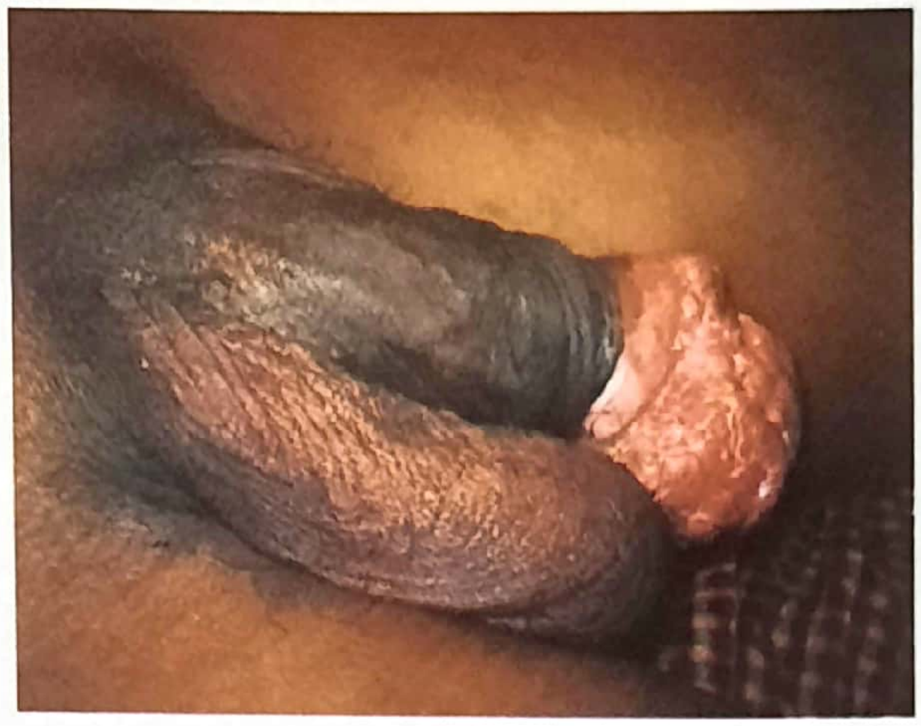

Figure 48.5: Carcinoma penis

(B/W 1-5 years) does not have the same effect.

- Retention of smegma* beneath the prepuce is probably a factor, and most cases belong to lower socio economic class who have poor personal hygiene.
- Phimosis has long been known to be a causative factor.

SMEGMA: Sebaceous material secreted by preputial glands present at corona glandis.

Premalignant Condition (MANY PGME)

1. *Bowen disease:* May involve the shaft of penis and appears as a thickened opaque plaque with ulceration.
2. *Erythroplasia of queyrat :* Red flat indurated patch on glans penis. (AIIMS NOV 01)
3. *Virus:* Herpes simplex
4. *Chronic balanoposthitis*
5. *Paget's disease* of the penis appears as an area of chronic, red eczema of the glans penis or inside the prepuce. This is the intraepithelial stage of squamous cell carcinoma.
6. *Leukoplakia* of the glans penis may present as areas of white, boggy epithelium.
7. *Long standing genital warts* (condyloma-acuminata)
8. *Buschke-Loewenstein tumour:* (giant condyloma) is a verrucous lesion which is locally destructive and invasive. The cause is believed to be viral (human-papilloma virus- HPV)
9. *Balanitis xerotica obliterans:* in which the normal foreskin becomes thickened and does not retract.

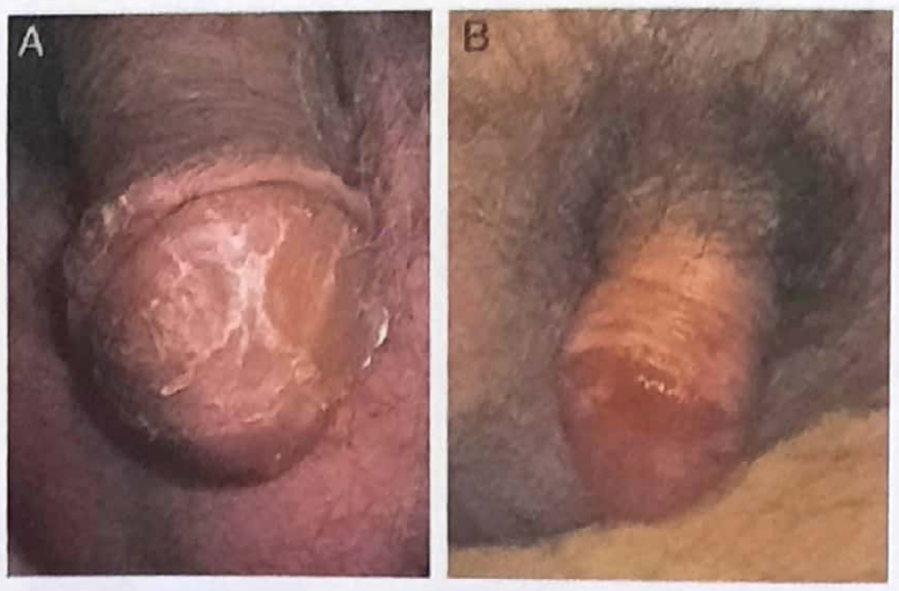

Figure 48.6: Squamous cell carcinoma of penis (A) Cauliflower pattern (B) Ulcerating pattern

Pathology

- Histologically it is **squamous cell carcinoma** (98%) with keratinization *(MANY PGME)*. Rarely it may be adenocarcinoma arising from *littre's and *Tyson's gland.
  - * Littre's gland - Urethral gland
  - * Tyson's gland - Preputial gland
- Macroscopically **two forms** are usually common :-

1. Ulcerative

This is the ***common*** *type* and presents as a large characteristic *malignant painless ulcer with ragged, irregular and everted edges* and necrotic floor.

2. Papilliferous

Which simulates the condyloma and gradually progresses to form a cauliflower-like fungating mass.

Site

Most common site of involvement are:

- **Glans - 48% (M/C site)** *(NEET, UP 03)*
- Preputial & skin -21%
- Both glans and prepuce - 9%
- Coronal sulcus - 6%
- Shaft of penis - 2%

Clinical Feature

- Age : Penile carcinoma occurs most commonly in the sixth decade of life, but may occurs even in patients in their twenties and thirties. In fact 40% of patients are under 40 years of age. *(AIIMS NOV 01)*
- Initially patient has mild irritation and purulent discharge from the prepuce, later on there is blood stained foul smelling discharge.
- Pain is usually not a feature of CA Penis.
- Majority of patient *present with a non healing penile ulcer with everted edges.* *(MANY PGME)* (fig. 48.6 B)
- *Urethra is rarely involved in carcinoma of penis,* because it is protected by the tough buck's fascia, (which is an extention of pelvic fascia).
- In about 60% of patients inguinal lymph nodes are enlarged *(AIIMS NOV 01)*. *However, half of them is due to reactive enlargement due to infection in ulcerative malignant growth.*

Spread

1. **Direct spread:** Involves glans, preputial skin & shaft.

2. **Lymphatic spread** (imp for exams)
   - Lymphatic spread occurs early. *Lymphatics from the glans drain into the deep inguinal lymph nodes* *(IMP.)*
   - Once the shaft of the penis is involved; the iliac lymph nodes may be involved. *(PGI85, KERALA 87)*
   - Enlarging inguinal lymph nodes erode the *femoral or external iliac artery* causing torrential hemorrhage, which is *most common cause of death due to Ca Penis*. *(AIIMS NOV 94, MANY PGME)*
   - (Sentinel lymph node biopsy done for - Carcinoma breast, Carcinoma penis, Malignant melanoma).

Hemorrhage is most common cause of death in Ca penis *(PGME)*

3. Hematogenous spread:

Blood *spread occurs late,* and is rare, and occurs only if the growth is highly anaplastic. Distant organs such as lungs, liver, brain and bones may be affected.

FOURTY EIGHT

TNM staging of penile cancer

Stage	Description
Primary	**Tumor (T)**
Tx	Cannot be assessed
T0	No evidence of primary tumor
Tis	Carcinoma in situ [Penile intraepithelial neoplasia (Pe IN)]
Ta	Noninvasive localized squamous cell carcinoma
Tl	**Glans:** Tumor invades lamina propria **Foreskin:** Tumor invades dermis, lamina propria, or dartos fascia **Shaft:** Tumor invades connective tissue between epidermis and corpora regardless of location **All sites** with or without lymphovascular invasion or perineural invasion and is or is not high grade
T 1a	Tumor is without lymphovascular invasion or perineural invasion and is not high grade (i.e., grade 3 or sarcomatoid)
T 1b	Tumor exhibits lymphovascular invasion and/or perineural invasion or is high grade (i.e.. grade 3 or sarcomatoid)
T2	Tumor invades into corpus spongiosum (either glans or ventral shaft) with or without urethral invasion
T3	Tumor invades into corpora cavernosum (including tunica albuginea) with or without urethral invasion
T4	Tumor invades into adjacent structures (i.e., scrotum, prostate, pubic bone)
Regional Lymph Nodes (N)	
Nx	Cannot be assessed
N0	None
N1	Single mobile unilateral inguinal lymph node
N2	Mobile multiple or bilateral inguinal lymph nodes
N3	Fixed inguinal nodal mass or pelvic lymphadenopathy unilateral or bilateral
Distant Metastasis (M)	
Mx	Cannot be assessed
M0	None
M1	Distant metastasis

ANATOMIC STAGE/PROGNOSTIC GROUPS				
Stage 0	Tis	N0	M0	
	Ta	N0	M0	
Stage I	T1a	N0	M0	
Stage II	T1b	N0	M0	
	T2	N0	M0	
	T3	N0	M0	
Stage IIIa	T1-3	N1	M0	
Stage IIIb	T1-3	N2	M0	
Stage IV	T4	Any N	M0	
	Any T	N3	M0	
	Any T	Any N	M1	

Staging (Modified Jackson's staging)

(i) Tumour confined to the glans or prepuce

(ii) Tumour involving the penile shaft

(iii) Stage I or II with enlarged mobile inguinal lymph node.

(iv) Tumour beyond penile shaft with fixed regional lymph node or distant metastases.

In India most of the patient present, when they are in stage III *(PGME)*

Treatment

Once the diagnosis is confirmed by biopsy the treatment is as follows:

I. Treatment of Primary lesion

1. **Small non-invasive lesions:** Can be managed by:-
   - *Radiotherapy*
   - Fluorouracil cream
   - Laser
2. **Lesions involving the prepuce only:** *Circumcision is all that is required* *(NEET, PGI 98)* with regular follow-up.
3. **Lesions at glans and distal shaft:** Partial amputation of penis with 2 cm of tumour free margin. *(IMP)*
4. **Lesion involving the proximal shaft:** Total amputation of penis with perineal urethrostomy. *(UP PG)*

Role of Radiotherapy

Radio therapy is effective (60-70% survival at 5 years) if growth is small. Before giving radio-therapy, circumcision should be done. Radio therapy is especially very useful in a young patients with small lesions, in whom penis is to be preserved.

II. Treatment of inguinal lymph node secondaries

- Only half of the patients with palpable lymph node actually have metastatic disease, because half of them have lymph node enlargement secondary to infection in the malignant growth.
- Hence, a course of broad spectrum antibiotics is given for 4-6 .weeks, if the nodes are still palpable and does not reduce in size, it is likely due to metastatic disease and block dissection of inguinal lymph nodes is done.

III. Advanced Disease (Stage IV)

Combination of chemotherapy (cis-Platin & 5-Fu) and radiotherapy may cause temporary regression.

Prognosis

Stage	5 year survival
I	96%
II	67%
III	29%
IV	0%

- Survival is influenced by the *positivity of the regional lymph node and numbers of lymph nodes involved (best prognostic marker)* *(NEET)*. If there is no involvement of lymph node, survival is 85-90%, one lymph node involved 70% and if more than one lymph node is involved then 25-40%.
- Disease in the young and with lesser differentiation carries a poor prognosis.
- *Prognosis does not depend on size of tumor but invasion of lesion into corpora or overlying fascial layer, metastasis affect prognosis* *(NEET)*.

*****

Sample Questions for Prof Examination

1. Enumerate the cause of ulcers in the penis. Describe the etiopathogenesis clinical features and management of a case carcinoma of the penis.
2. Write short notes on paraphimosis.
3. Write short notes on phimosis.

49 The Testis and Scrotum

Contents

- Surgical Anatomy
- Idiopathic scrotal gangrene (Fournier's gangrene)
- Filarial scrotum
- Sebaceous cyst of scrotum
- Carcinoma of the scrotum
- Imperfect descent of testis
- Retractile testis
- Testicular torsion
- Varicoele
- Hydrocele
- Chylocele
- Hematocele
- Pyocele
- Epididymal cyst
- Spermatocele
- Epididymo-orchitis
- Tumour of Testis
- Extra gonadal germ cell tumours
- Male infertility

SURGICAL ANATOMY

Friends, Please read anatomy very carefully, otherwise funda will not be clear.

Scrotum

The scrotum can be considered as an out pouching of the lower part of the anterior abdominal wall. It contains the testes, the epididymides and the lower ends of the spermatic cords.

The wall of the scrotum has the following layers:-

Mnemonic - Some Dirty English men Call It Testis

1. Skin
2. Dartos muscle (smooth muscle) replacing fatty layer.
3. External spermatic fascia derived from the external oblique.
4. Cremasteric fascia derived from the internal oblique;
5. Internal spermatic fascia derived from the fascia transversalis.
6. Tunica vaginalis.

- **The skin** of the scrotum is thin, wrinkled and pigmented and forms a single pouch.
- The Superficial fascia is continuous with the fatty and membranous layers of the anterior abdominal wall; the fat is however, replaced by **smooth muscle** called as **dartos muscle.**
- The spermatic fascias, lie beneath the superficial fascia and are derived from the layers of the anterior abdominal wall on each side.

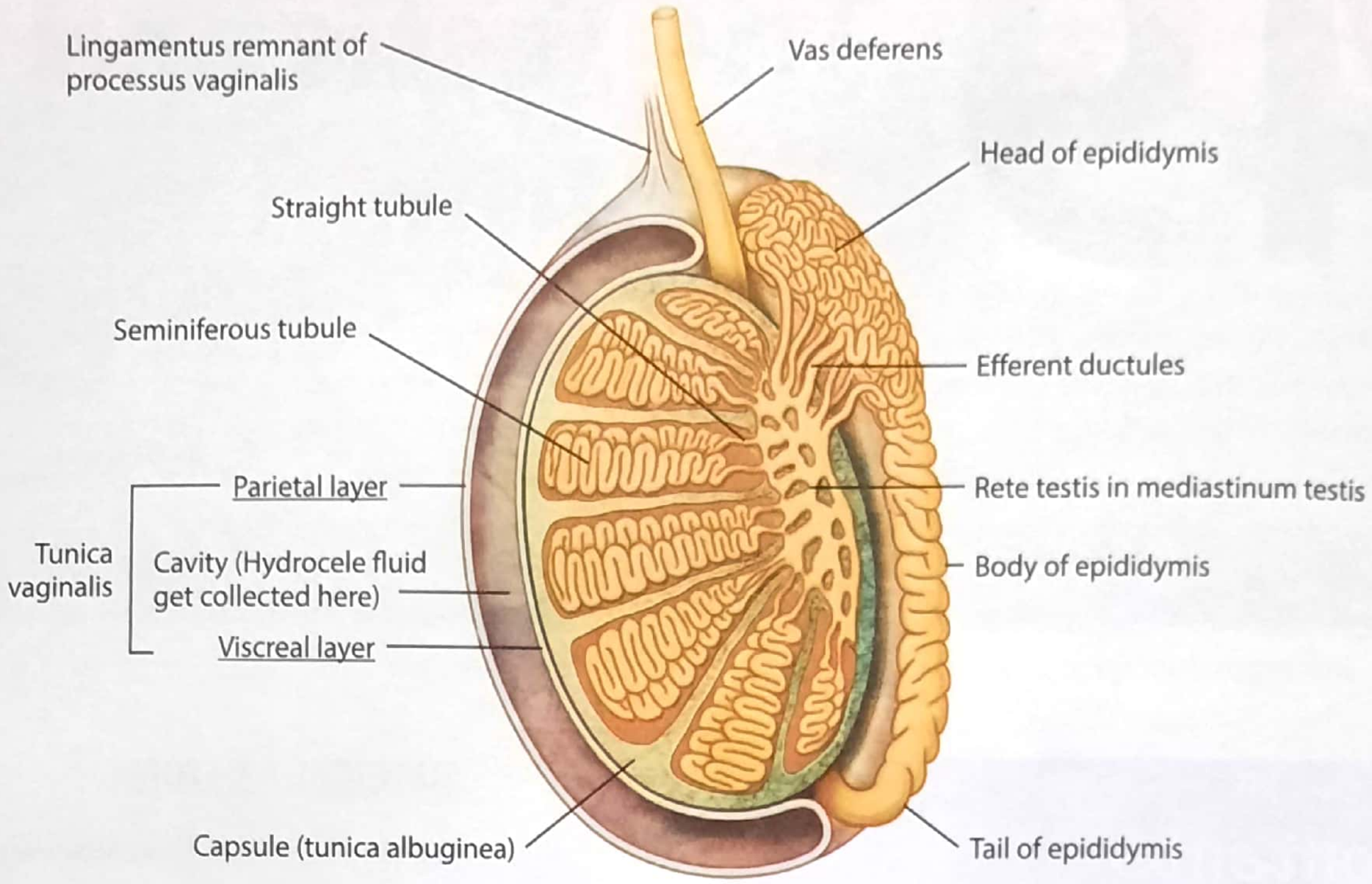

Figure 49.1: The testis

- The External spermatic fascia is derived from the aponeurosis of the External oblique muscle.
- The Cremasteric fascia is derived from the internal oblique muscle; and finally the internal spermatic fascia, which is derived from the fascia transversalis.
- **The Cremaster muscle** is supplied by the *genital branch of the genitofemoral nerve,* (MANY PGME)
- The cremaster muscle can be made to contract by stroking the skin on the medial aspect of the thigh. This is called the **cremasteric reflex.** *The afferent fibres of this reflex arc travel in the femoral branch of the genitofemoral nerve* (L_{1-2}) and the ***efferent motor*** nerve fibers travel in the *genital branch of the genitofemoral nerve,* (MANY PGME).
- The function of the cremaster muscle is to raise the testis and the scrotum upward for warmth and for protection against injury.
- **The Tunica vaginalis** lies within the spermatic fascia and *covers the anterior, medial and lateral surfaces of each testis.* ***It is the lower expanded part of the processus vaginalis*** and normally; just before birth, it becomes shut off from the upper part of the processus and the peritoneal cavity. The tunica vaginalis is thus a closed sac, invaginated from behind by the testis. Please see figure 49.1.

Friends! Read this very carefully, otherwise you will face difficulty in understanding Hydrocele, please help your self with fig. 49.1

Testes

- **Testes** originally develop high on the posterior abdominal wall and then descend, normally before birth, passing through the inguinal canal down into the scrotum. (Key box 49.1)
- During descent from posterior abdominal wall, the testes carry their vessels, lymphatics and nerves; as well as their principal drainage ducts the **ductus deferens (vas-deferens)** with them. The lymph drainage of the testes is therefore to the para-aortic lymph

KEY BOX 49.1

Testicular Descent: (PGME MANY TIMES)

- In the lumbar region - In 2nd month of fetal life
- In the iliac fossa - 3rd month of fetal life
- At the deep inguinal ring - end of 6th months
- Travels through inguinal canal - In the 7th month
- At the superficial inguinal ring-Later part of 7th month and early part of the 8th month.
- Base of scrotum 9th months. (AI. PGI. AIIMS)

nodes in the abdomen and not to the inguinal or pelvic lymph nodes. (VERY IMP. POINT)

- Each ellipsoid-shaped testis is enclosed within the end of an elongated musculo-fascial pouch, which is continuous with the anterior abdominal wall and projects into the scrotum.
- The **spermatic cord** is the tube-shaped connection between the pouch in the scrotum and the abdominal wall. (IMP. POINT)
- The sides and anterior aspect of the testis are covered by a closed sac of peritoneum (the **tunica vaginalis**) which is originally connected to the abdominal cavity. Normally after testicular descent, the connection closes leaving a fibrous remnant.
- Each testis is composed of seminiferous tubules and interstitial tissue surrounded by a *thick connective tissue capsule* called **tunica albuginea.**
- Spermatozoa are produced by the seminiferous tubules. The 400-600 highly coiled seminiferous tubules are modified at each end to become straight tubules, which connect to a collecting chamber (the **rete testis**) in a thick, vertically oriented linear wedge of connective tissue (the **mediastinum testis**), projecting from the capsule into the posterior aspect of the gonad. Approximately 12-20 **efferent ductules** originate from the upper end of the rete testis, penetrate the capsule and connect with the epididymis.

Epididymis

- The epididymis is a single, long coiled duct that courses along the posterolateral side of the testis. It has two distinct components.
- **The efferent ductules,** which form an enlarged coiled mass that sits on the posterior superior pole of the testis and forms the **head of the epididymis;** the **true epididymis,** which is a single, long coiled duct into which the efferent ductules drain and which continues inferiorly along the posterolateral margin of the testis as the **body of epididymis** and enlarges to form the **tail of epididymis** at the inferior pole of the testis.
- During passage through the epididymis, *spermatozoa acquire the ability to move and fertilize an egg* (PGME). *The* epididymis also stores spermatozoa until ejaculation. The end of the epididymis is continuous with the dutus deferens. (See fig. 49.1; once again)

*****

DISEASES OF THE SCROTUM

Idiopathic Scrotal Gangrene (Syn. Fournier's Gangrene)

- The exact cause to this condition is not known.
- It is characterized by sudden appearance of scrotal inflammation in an apparently healthy individual, which rapidly progresses to *gangrene of scrotal skin* (JIP 90).
- Some minor injuries or scratch in the perineum may precede. Some operative procedures eg; urethral dilatation, periurethral abscess or injection therapy for hemorrhoids may also precede this condition.
- The condition is *more common in diabetics.*

Clinical Feature

- Sudden appearance of pain & inflammation in the scrotum is the first symptom. & is often associated with fever.
- Initially only scrotal skin is involved, but gradually cellulitis spreads to involve perineum, lower abdominal wall, penis and inner side of thigh.
- Cellulitis progresses quickly and if untreated scrotal skin sloughs out, exposing the testis. (IMP. POINT)
- **Testis is usually not involved** in fournier's gangrene because of tough barrier of tunica albuginea. (IMP. POINT)

Treatments

- The infecting agents are the hemolytic *Streptococci, E.coli, Bacteroides.*
- Appropriate antibiotic therapy is commenced (Gentamicin and metronidazole are drug of choice).

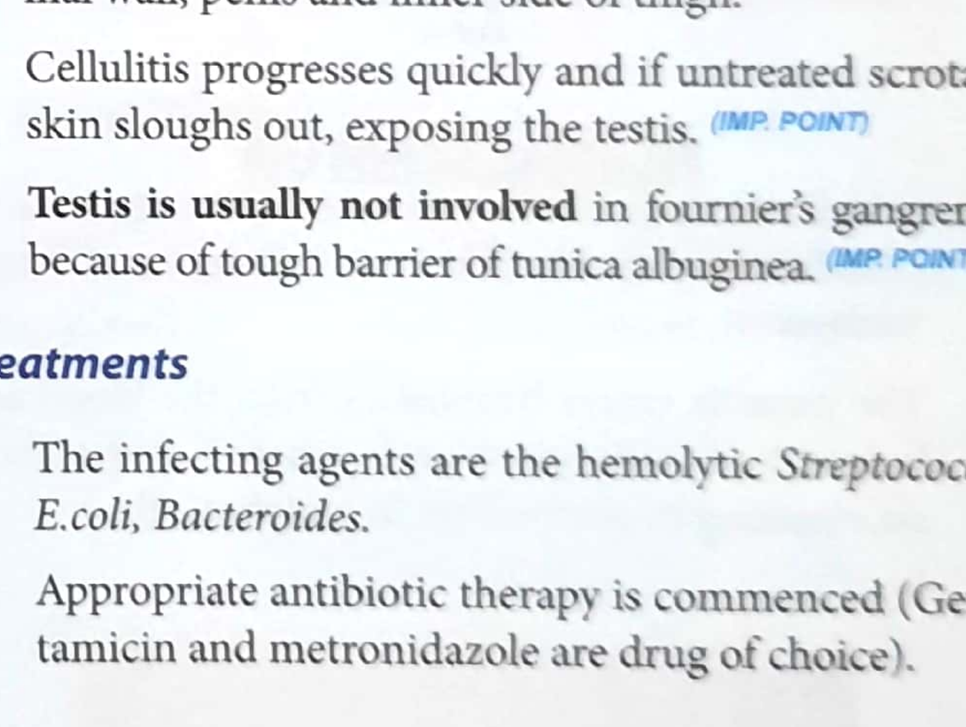

Figure 49.2: Fournier's gangrene

Figure 49.3: Same patient after debridement of scrotal skin

- The gangrenous skin is excised for drainage and stoppage of spread of gangrene.
- When the inflammation has subsided, the tunica vaginalis should be covered with either by remaining scrotal skin, skin grafting, or the testis can be implanted to the medial side of thigh.

*****

FILARIAL SCROTUM

- Filariasis is caused by *Wucheria bancrofti* and *Brugia malaya*.
- The parasite enters lymphatics from the blood and lodges itself in the lymph node, where it causes fibrosis, resulting in obstruction in lymphatic flow.
- In filarial scrotum, the scrotum is enlarged.
- The skin is rough and dry and penis may be found buried in scrotum. See figure 49.4.
- *The median raphe is thickened and prominent.*
- There is no medical treatment to this condition, however a course of DEC can be tried with some success.
- The principle of surgical treatment is the construction of new lymphatic pathway; using plastic surgery. *(AIIMS 01)*

*****

SEBACEOUS CYSTS OF SCROTUM

- Sebaceous glands are present in skin and secrete sebum which keeps the skin soft and oily. Sebaceous cyst develops as a result of obstruction at the opening of a sebaceous gland, hence is a retension cyst (ie; retention of sebum).
- Sebaceous cysts of the scrotum are quite common.
- There are mostly multiple and small in size.
- Sebaceous cyst of scrotum may sometime calcify, and appear stony hard on palpation.
- Removal is indicated if they become infected.
- The treatment of this condition is excision. If sebaceous cysts of scrotum are numerous, it may require partial scrotectomy.

*****

Figure 49.4: Scrotal filariasis

Figure 49.5: Multiple sebaceous cyst of scrotum

CARCINOMA OF THE SCROTUM

Etiology

Occupational: Commonly seen in chimney sweepers and those working in cotton industry; also common in tar and mineral oil workers. It is also known as ***chimney sweeper's cancer.*** (NEET, PGME)

- In the majority of cases there are no obvious etiological factors.
- Rare in India

Pathology

- The growth starts as a small wart or ulcer in scrotal skin.
- It is usually a **Squamous cell carcinoma,** (imp. point)
- It spreads locally to underlying testis and by lymphatic spread to inguinal lymph nodes.
- This malignancy does not has as good prognosis as squamous cell carcinoma in other exposed areas of skin.

Clinical features

1. It presents as a typical epithelioma with everted edges, indurated base, which may bleed on touch.
2. If left untreated, it may involve the underlying testis.
3. Inguinal lymph nodes are always enlarged; which are discrete and hard. (KAR. 96)

Treatment

The treatment consist of wide local excision and radical lymph node dissection. Advanced lesion may respond well to radiotherapy and systemic chemotherapy with Bleomycin, to be followed by lymphadenectomy.

*****

DISEASES OF TESTIS

IMPERFECT DESCENT OF TESTIS

The testis originally develop high in the lumbar region on the posterior abdominal walls and then descend during the fetal life to reach to the scrotum soon before birth. A maldescended testis is one which has failed to reach the normal low scrotal position. *Maldescent may be of two types:*

Types of Maldescent

1. *Incomplete descent (undescended testis)*

When testis fails to descend beyond any point *along the normal course of descent.* This is also called as *cryptorchidism.*

2. *Ectopic testis*

When testis **fails** *to descend in the normal path of its descent* - it is called as *ectopic testis.* The common site of ectopic testis are (in order of frequency). (MANY PGME)

Figure 49.5E: Scrotal cancer



Figure 49.6: A child with undescended testes

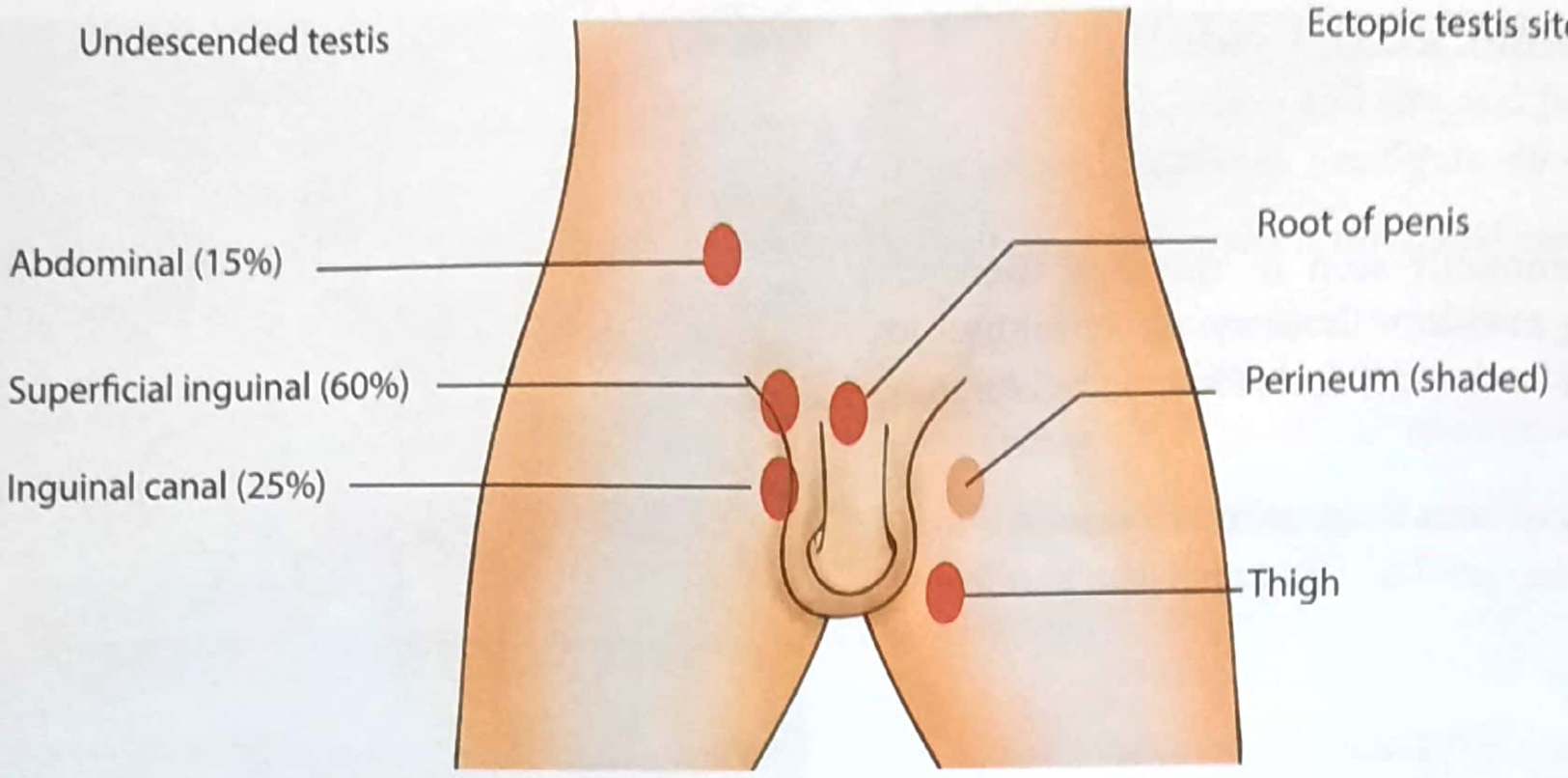

Figure 49.7: Sites at which undescended and ectopic testes are commonly found

- Superficial inguinal pouch (M/C) site
- Perineum
- Femoral triangle
- Supra pubic region

Please see figure 49.6, 49.7 and key box 49.2, 49.4, 49.5.

Incidence

About 4% of full term newborn boys (NEET, MANY PGME) *have undescended testis at birth.* By the age of one month this figure drops down to 1.8% and 0.8% by the age of 9 months.

About 30% of pre-term boys has undescended testis (MANY PGME).

Etiology

Incidence of maldescent is higher in LBW (low birth weight child), premature babies. Spontaneous descent is rare after 1 year.

The causes of maldescent are:-

(i) Abnormality of the gubernaculum testis

Gubernaculum plays a major role in descent of testis and abnormality of this structure may result in undescended testis.

(ii) Testicular defect

The testis may be insensitive to gonadotrophins and may not act to it. This may lead to undescended testis.

(iii) Endocrinal factors

Lack of adequate maternal gonadotrophins may be a cause of incomplete descent.

(iv) Obstruction due to adhesions of the testis.

(v) Short vas deferens

(vi) Short testicular vessels or pampiniform plexus.

KEY BOX 49.2
Common site of maldescended testis (In decreasing order of frequency) PGME
• Superficial inguinal pouch • Perineum • Femoral triangle • Supra pubic region

KEY BOX 49.3	
Complication of undescended testis	
Mnemonic : TESTIS	
T	- Trauma
E	- Epididymo- orchitis
S	- Sterility
T	- Torsion
I	- Indirect inguinal hernia
S	- Seminoma and other testicular tumour

KEY BOX 49.4	
Comparison Between Undescended Testis And Ectopic Testis	
Undescended testis	**Ectopic testis**
1. The testis is arrested in its normal path of descent	1. The testis deviates from its normal path of descent
2. Undescended testis is not fully developed.	2. The testis is fully developed
3. Scrotum is not developed on that side and empty.	3. Though empty, the scrotum is usually fully developed
4. The length of the spermatic cord may be short.	4. The length of the spermatic cord is usually normal
5. Spermatogenesis is poor after 6 years of age.	5. Spermatogenesis is perfect.
6. Undescended testis may be associated with indirect inguinal hernia.	6. This is never associated with indirect inguinal hernia.
7. Treatment - Mainly operation, though hormone therapy may be tried in selected cases. Operation is not at all successful after puberty.	7. Treatment is operation, and is usually successful.
8. Complications - List of complications have been mentioned in text (key box 49.3)	8. Complications - **The main complication is it's liability to injury.** *(NEET)*

Clinical Feature

- The condition is unilateral on the right side, in about 50% and on the left side in 30%. Arrested descent of both testes occurs in about 20%. ***[Right side > Left side : 5:3]*** *(NEET)*
- *Secondary sexual characteristics are normal* *(NEET)*, but other abnormalities of the genito-urinary tract may be present.
- Gentle palpation, with the boy recumbent and relaxed may result in identification of testis at abnormal site.
- Histological changes appear in testis at 6 months of age i.e. normal at birth.

Complication of Incomplete Descent

(AIIMS JUNE 95, PGME MANY TIMES)

- Sterility in bilateral cases.
- **Trauma:** The position of the testis within the inguinal canal or in an ectopic position makes it particularly vulnerable to trauma.
- Torsion.
- Atrophy of testis .
- Epididymo-orchitis.
- Associated Indirect inguinal hernia.
- **Tumour** : *All types of malignant testicular tumour are more common in incompletely descend testes* *(NEET)*, *even if they are brought down in scrotum surgically.* *(AI, UP 2000, AIIMS, 95, PGI, AIIMS 09)*
- *Most common carcinoma arising in undescended testes is* **seminoma.** *(NEET, MANY PGME, AIIMS 09)* {Key box 49.3}
- It has been estimated that the chance of a tumour is about 35 times more than in a normally placed testis. *(PGME)*

Surgical Treatment

Orchidopexy

Definitive treatment of the undescended testis should be ***carried out before 1 years of age*** *(NEET, AI 04, AIIMS 06, AIIMS MAY 07)*. The operation for undescended testis is **orchidopexy.** *(AI 10, AIIMS 09, 10)*

Orchidopexy consists of:- firstly the mobilization of the testis and spermatic cord down to scrotum and secondly, retaining the testis in the scrotum. The operation is performed through a short groin incision over the deep inguinal ring.

Please read key box 49.5E carefully (next page).

*****

KEY BOX 49.5E

Surgical management of undescended testis

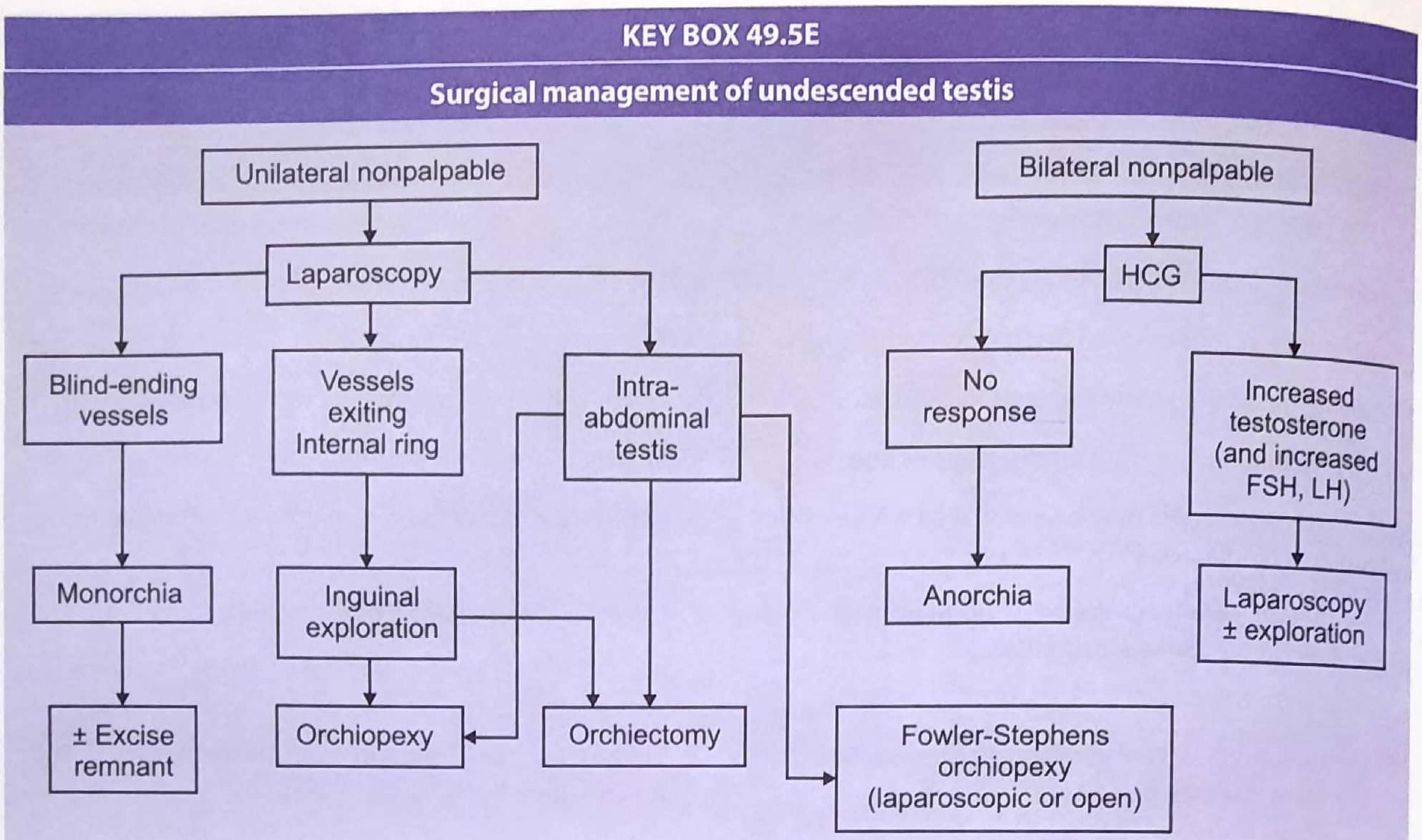

RETRACTILE TESTIS

- Retractile testis is *due to strong cremasteric retraction.* Reflex retraction occurs from a very slight stimulus, such as touching the thigh or the anterior abdominal wall.
- A retractile testis can always be brought to the bottom of the scrotum, by gently milking it from it position in the inguinal region.
- If these children are made to squat (ie; sit like in indian style toilet), the testis comes down in scrotum and becomes palpable. This will help to differentiate a retractile testis from an undescended testis.
- In infancy, 80% of inapparent testes are retractile. Such testis do not require any treatment, because in due course of time these will take up a normal position in scrotum permanently in scrotum.
- One should wait till the age of 12 years for a retractile testis to come permanently in testis, even if at 12 year it is still retractile, operative procedure (orchidopexy) should be carried out.

*****

TESTICULAR TORSION

(Torsion : Twist)

- Testicular torsion is very rare in a fully descended testis, due to its firm anchoragement. The torsion may be intravaginal or extravaginal.
- In *neonates,* torsion often occurs *extravaginal* but in *later years it is usually intravaginal* and almost always associated with a horizontally lying testis (also called as ***bell clapper testis***). (PGME)

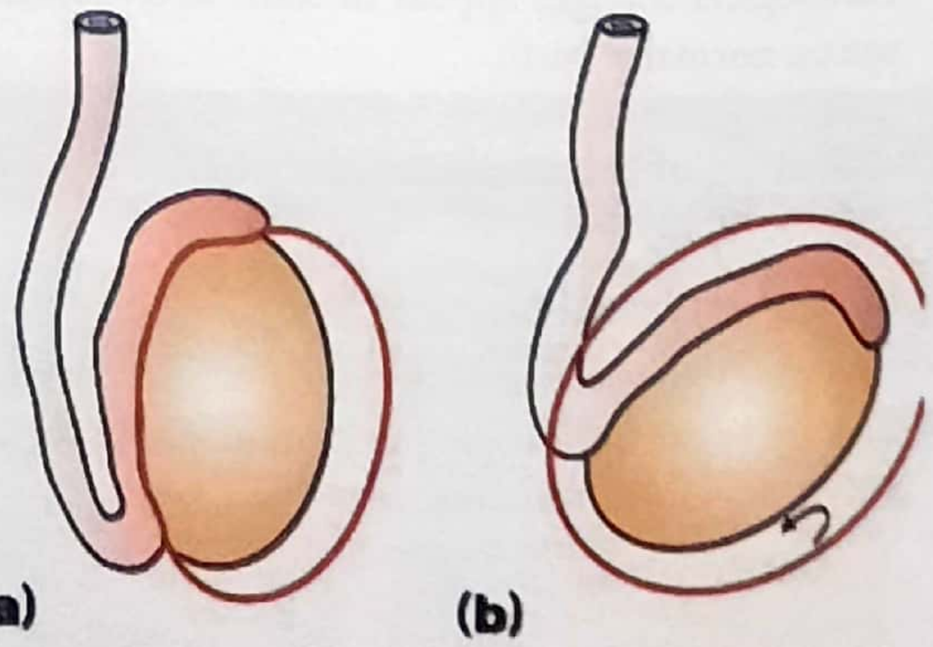

Figure 49.8(a): Testicular torsion : (a) normal attachment; (b) an abnormally high attachment of the tunica vaginalis predisposes to torsion

- Torsion may be of **two types:**

1. Intravaginal

This is common type and occurs in patients between 10-20 years. The underlying defect is high insertion of the tunica vaginalis on the cord. Testis may take up a horizontal lie (Bell- clapper testis) which is often bilateral. Please see fig. 49.8

2. Extravaginal

This occurs in incompletely descended testis, where entire testis including the tunica vaginalis twist on spermatic cord. This is more common in neonates. Please see figure 49.8a & 49.8b,c.

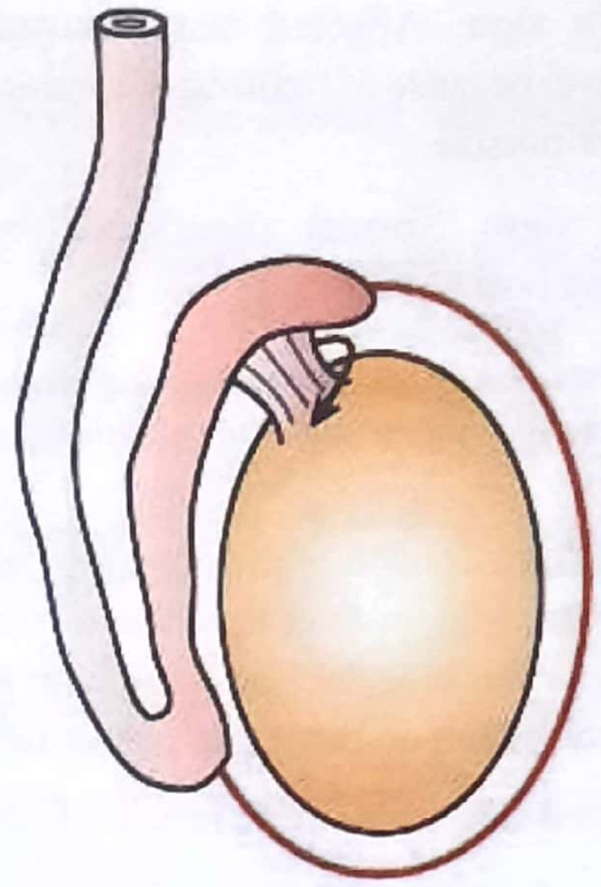

Figure 49.8(b): Testicular torsion. Separation of the testis from the epididmis - torsion about the pedicle between them

Predisposing Factors

1. High insertion of the tunica vaginalis on the spermatic cord, which allows the testis to rotate within the tunica. It is described as 'clapper bell' deformity. *(COMED 06)*
2. Undescended testes are more prone to torsion.
3. Inversion of the testis : Rotated and lies transversely or upside down.
4. Less commonly, a long mesentery may separate the epididymis and testis, allowing torsion of the testis on this long mesorchium.
5. Spasm of the cremaster muscle, following violent contraction of the abdominal muscles during over enthusiastic sexual activity.
6. Straining at stools or heavy weight lifting.

Clinical Feature

- Patient presents with sudden onset of severe scrotal pain with scrotal swelling and redness. *(AIIMS 01)*
- *Nausea and vomiting* may occur, along with the pain and mild pyrexia. *(AIIMS 99)*
- ***Prehn's Sign: The pain is not relieved by elevation of the scrotum.*** *(NEET, AIIMS 99)*.

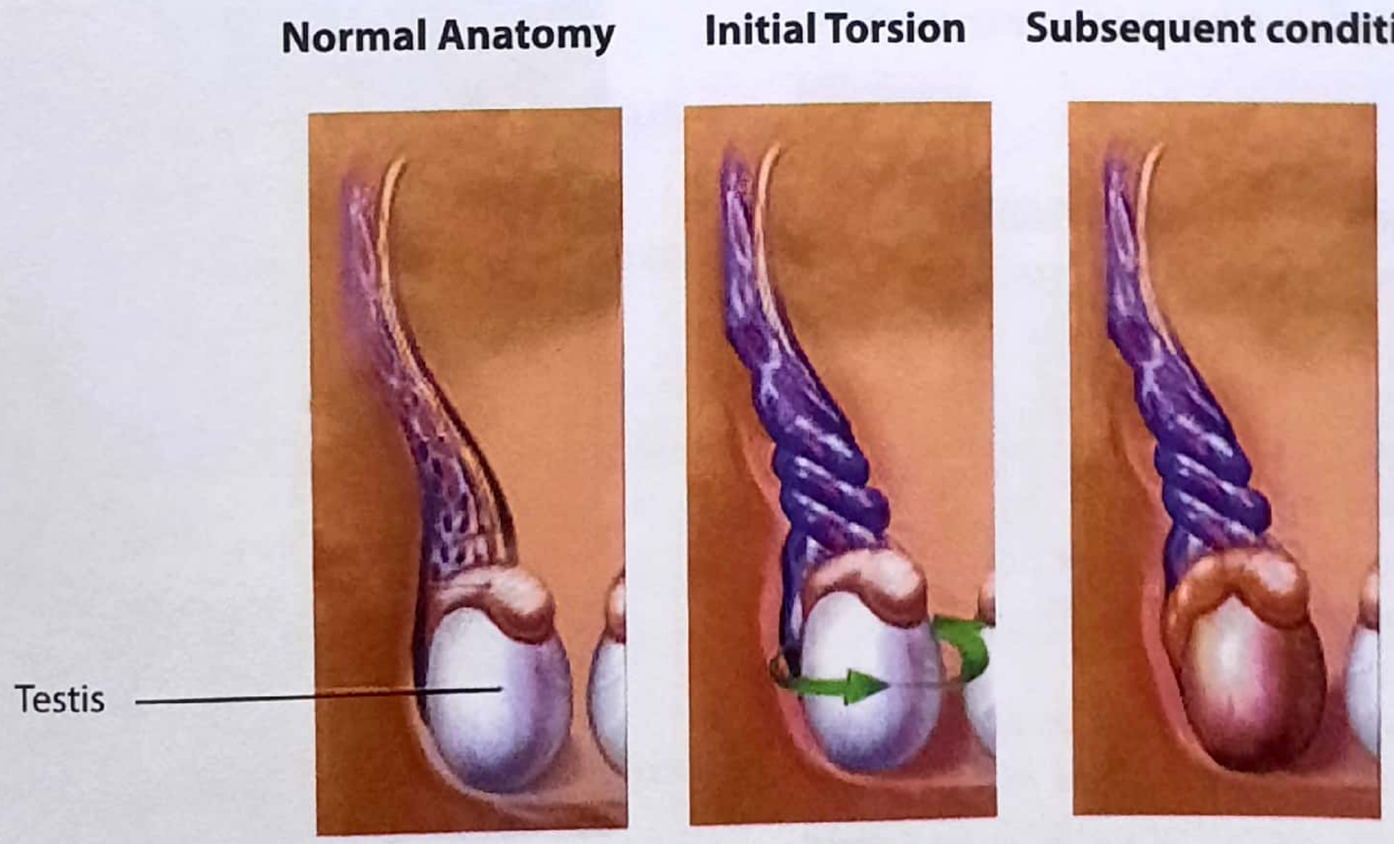

Figure 49.8(c): Testicular torsion: (A) Intravaginal (B) Extravaginal

- **Deming's sign**: Affected testis is positioned at higher level because of twisting of cord and spasm of cremaster muscle.
- **Angell's sign**: Normal (unaffected/contralateral) testis lying horizontally.

NOTE: Elevation of the scrotum usually relieves the pain in epididymo-orchitis;- an important D/D of testicular torsion *(MANY PGME)*

- **Blue dot sign:** Torsion of the appendix testis is more common in children than tisticular torsion and may be diagnosed by blue dot sign (i.e. tender nodule with blue discoloration on the upper pole of testis).
- On affected side cremasteric reflex is lost.

Diagnosis

- *The diagnosis is usually made on clinical grounds.*
- *In suspected cases.* Diagnosis can be made accurately by *coloured doppler which shows absence of blood flow in the affected testis.* *(NEET, MAY BE FUTURE PGME Q)*
- Technetium Tc^{99m} pertechnetate scan may differentiate epididymo-orchitis from testicular torsion, if performed early in the course of symptoms. *(IMP. POINT)*

Treatment *(AIIMS NOV 04, UP, AI 00)*

(a) Early cases

- It may be possible to untwist the testis by gentle manipulation in the first few hour; and if successful pain subsides. *However orchidopexy should be done at the same time to avoid recurrent torsion* *(NEET)*. *Surgery should be done with in 6 hours to save testis.* *(NEET)*

(b) Late cases

- Exploration is carried out through a midline scrotal incision, which will reveal a congested, ischemic testis with a twisted spermatic cord. The cord is untwisted and testicular viability assessed. If the testis is obviously infarcted, orchidectomy is advised. **The *opposite testis should also be fixed* (by orchidopexy)** *(AIIMS NOV 19)* because of the future possibility of torsion on the opposite side. *(AIIMS NOV 01)*

*****

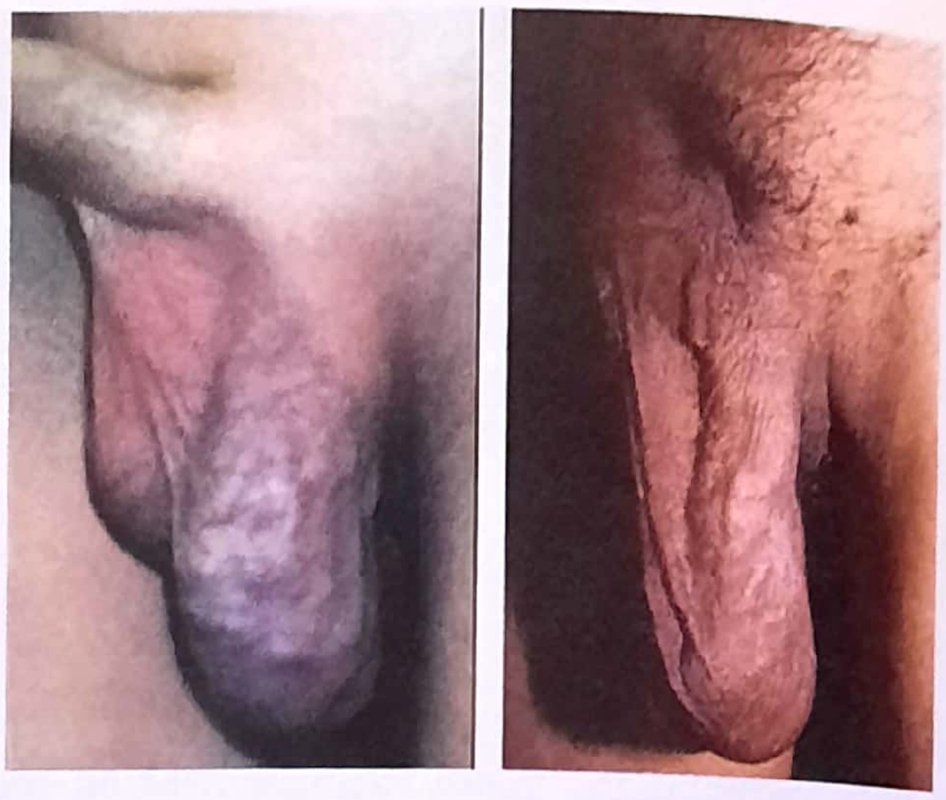

Figure 49.9(a): A patient with left Varicocele

VARICOCELE

- A varicocele is a varicose (tortuous*) dilatation of the vein draining the testis. Fig. 49.9 *(UPSC 07)*
- Most varicoceles are noticed in *adolescence or early adulthood.* *(PGME)*
- The usual sufferers are *tall, thin, adult men* often living in hot weather. *(PGME)*
- In majority of cases varicocele are left sided (95%) *(AIIMS NOV, AIM)*. [Because : The right testicular vein drains directly into the vena cava, where as the left testicular vein opens at right angle into the left renal vein, which has the high pressure] *(AI 98, UP 2000)*

Figure 49.9(b): Ultrasound of a varicocoele

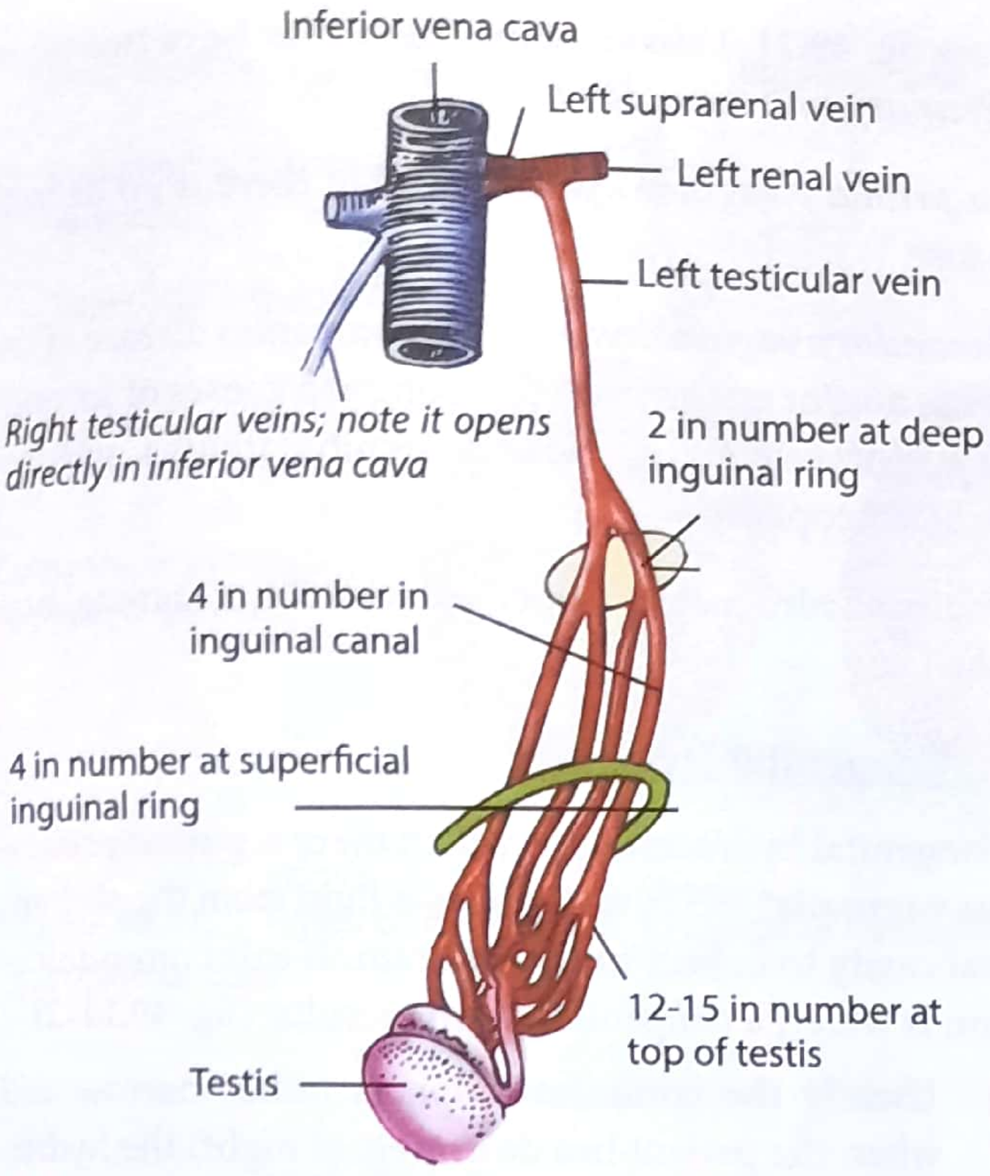

Figure 49.10: Venous return of left testis

- Please see figure 49-10 carefully, note left and right testicular vein.
- Obstruction of the left testicular vein by a *renal tumour* (CMC 98) or *after nephrectomy* are occasional causes of varicocele in middle age or there after.

Tortuous: full of twist and turn

Clinical Feature

- The patient is usually young adult and it is exclusively found **on the left side.** (MANY PGME)
- Usually; varicocele is painless and the only complaint of the patient is the swelling.
- Some patient *may present with dragging pain in the scrotum,* and the pain worsens on prolonged standing, exertion or if unsupported by underwear.
- The venous engorgement may raise the temperature in the testis and this may have an adverse effect on spermatogenesis and may result in infertility.
- **In fact varicocele is most common surgically treatable cause of male infertility.** (NEET, IMP. POINT)

On examination

- The scrotum on the affected side hangs lower than the normal.
- Impulse on coughing may some times be present.
- On palpation with patient standing the varicose plexus feels like a ***"bag of worms"*** (NEET, AIIMS NOV 01, MANY PGME).
- In chronic cases, the affected side testis is smaller and softer than the normal side.

Treatment

1. Surgery is not indicated for varicocele; unless it causes symptoms.
2. The indications for surgery: (PGI 08)
   (a) Pain interfering with daily life of patient
   (b) As a cause of infertility (oligospermia)
   (c) Makes one medically unfit for job.
3. The simplest procedure is *ligation of the testicular vein* above the inguinal ligament near deep inguinal ring. (DELHI 96)

- First line of intervention in symptomatic varicocle is embolization.

*****

HYDROCELE

A hydrocele is an abnormal collection of serous fluid within the **sac of tunica vaginalis of testis** (NEET). The fluid is often of amber colour. **Please see fig. 49.1 and locate tunica vaginalis & read key box 49.5 carefully.**

Etiology

1. Defective absorption

This is the most common cause for development of hydrocele. However, the cause of defective absorption is not well understood. It is proposed that chronic low grade infection may damage the endothelial lining and decrease absorption.

2. Excessive secretion (Secondary hydrocele)

An excessive secretion of fluid in the vaginal sac may be secondary to infection (epididymo-orchitis), trauma or neoplasm infiltrating the sac. In 5-10% of testicular tumours are associated with hydrocele. (KARN 95).

KEY BOX 49.5

IMPORTANT POINT (FUNDA)

You can not understand different types of hydrocele; if you do not know the following developmental anatomy:

Processus Vaginalis

Processus vaginalis is a pouch (process) of peritoneum which is pulled down in scrotum during descend of testis, from it original position at posterior abdominal wall during fetal development. This processus vaginalis obliterates (closes) soon at/after birth, but when it remains patent (open) it works as a preformed sac and communicates with peritoneal cavity (abdominal cavity) and increase chance of congenital hydrocele or hernia formation. When this process (patency) is narrow, it allows only fluid to come and results in congenital hydrocele and when this is wider; it allows intestine or omentum to come down in scrotum- resulting in congenital hernia.

Tunica Vaginalis

It is lower expanded part of the processes vaginalis and lies within spermatic fascia and covers the anterior, medial and lateral surfaces of each testis. (Fg 49.1)

Note: It is lower most part of processes vaginalis which extents in scrotum during fetal development and is called as tunica vaginalis and covers testis from all side except posterior. Collection of fluid in between the layers of tunica vaginalis results in vaginal hydrocele.

3. **Defective drainage due to blockage of lymphatic vessels of cord**

In filariasis; inflammation causes fibrosis, causing destruction of lymph plexus and lead to impaired absorption from the sac. Filariasis is a common cause of hydrocele.

4. **Communication between the tunica vaginalis and peritoneal cavity**

A patent processus vaginalis is the main cause behind a congenital hydrocele. (key box 49.5)

Clinical Types

1. Vaginal hydrocele

This is most common type of hydrocele; where accumulation of fluid occurs *between the layers of tunica vaginalis* (see fig. 49.11-1) in scrotum. These may be of two types: *Primary and secondary*

In ***primary vaginal hydrocele***, often there is no definite cause.

Secondary vaginal hydrocele accompanies disease of the testis and/or epididymis. The common causes of secondary hydrocele are epididymo-orchitis, trauma and testicular neoplasm.

Vaginal hydrocoele is associated with 5% of inguinal hernia.

2. Congenital Hydrocele

Congenital hydrocele, is in which there is **patent processus vaginalis*** *(NEET)*., which allows fluid from the abdominal cavity to collect in the scrotum. If this communication is wider; a congenital hernia results, (fig. 49.11-2)

- Usually the communication is rather narrow and when the patient lies down (eg. at night) the hydrocele may slowly empty itself and may again appear when the patient assumes an erect posture during day hours.
- It may also be possible, to empty the hydrocele by applying gentle pressure on hydrocele.

Friends! Must read processes vaginalis. I have given brief on it in key box 49-5.

3. Infantile hydrocele

This is uncommon type of hydrocele and **does not** necessarily appear in infants. *The tunica and processus vaginalis are distended up to the internal inguinal ring,* but there is no connection with the peritoneal cavity, like that, is present in congenital hydrocele. (fig. 49.11-3)

4. Encysted hydrocele of cord

A segment of processus vaginalis associated with the spermatic cord persist. There is a smooth ovoid swelling in the inguinal region; hence is *often mistaken for an irreducible inguinal hernia.* *(PGME, AIIMS)* (fig. 49.11-4)

It moves downward when testicle is pulled downward.

5. Funicular hydrocele

This is a rare condition, in which processus vaginalis remains patent up to the top of the testis. A swelling is felt in inguinal region up to top of testis, but testis is normal.

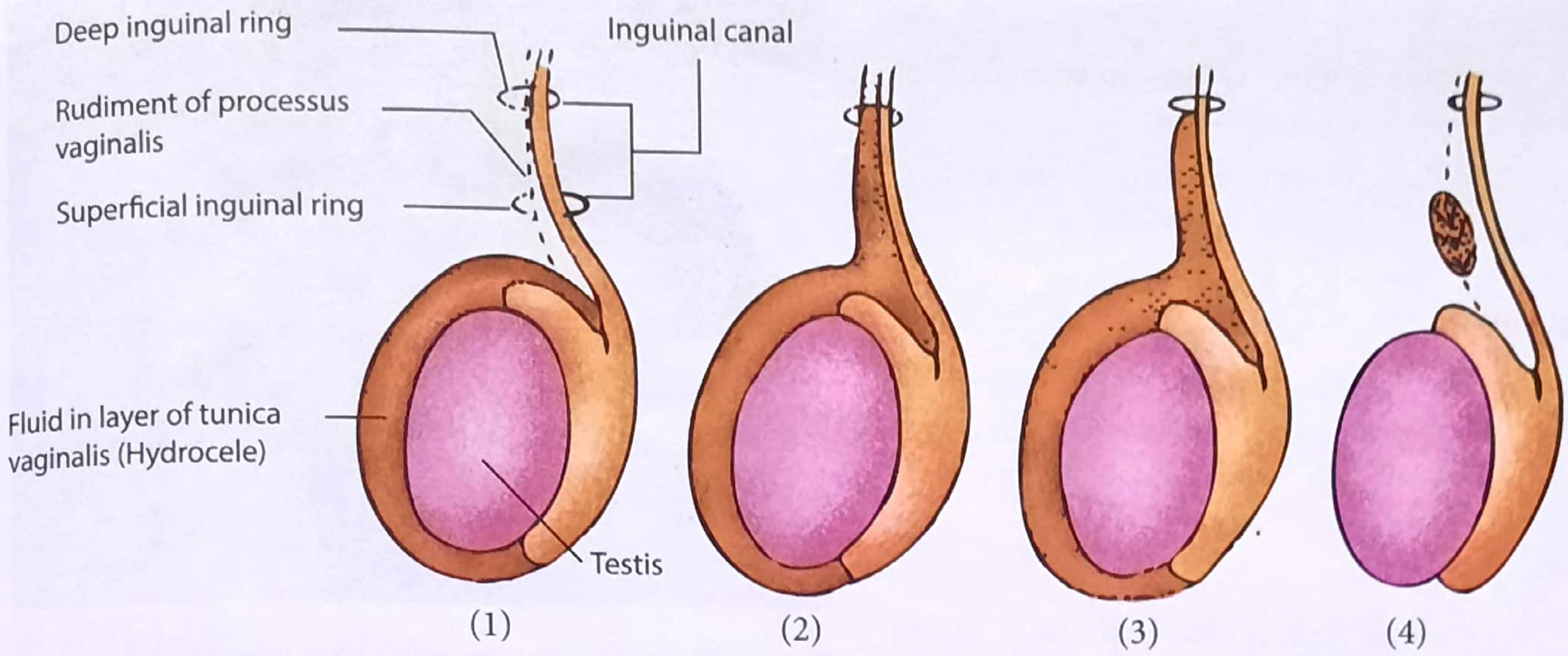

Figure 49.11: Types of hydroceles: (1).Vaginal hydrocele (2). Congenital hydrocele (3). Infantile hydrocele (4). Encysted hydrocele of cord

6. **Abdomino Scrotal Hydrocele (Hydrocele en-bissac, Bilocular hydrocele)**

This is rare condition in which two intercommunicating sacs are found; one above and one below. The upper sac has no connection with processus vaginalis and in fact it is herniated tunica vaginalis from below (testis).

Clinical Feature

IMPORTANT AS A SHORT CASE IN PROF, EXAMINATION.

- Hydrocele can be unilateral and/or bilateral.
- The skin over the swelling is shiny, with loss of normal rugosities*. rugosity: wrinkle
- It is a *purely scrotal swelling* and it is ***possible to reach above (get above) the swelling.*** *(NEET)*
- It has a *tense cystic feel and fluctuation test is positive.*
- Vaginal hydrocele is a purely scrotal swelling which is **non reducible** (a congenital hydrocele however may reduce on gentle pressure due to patent processus vaginalis, which has connection with abdominal cavity).
- **Transillumination test is positive,** however, it may be negative if the fluid is thick or chylous.
- **The testis cannot be felt separately,** because the fluid of hydrocele surrounds the body of the testis. *(AP 08)*
- Impulse on coughing is absent because. It is a purely scrotal swelling and has no connection with abdominal cavity, (cf; in hernia impulse on coughing is present)

Complications

1. Rupture may occur spontaneously or due to trauma.

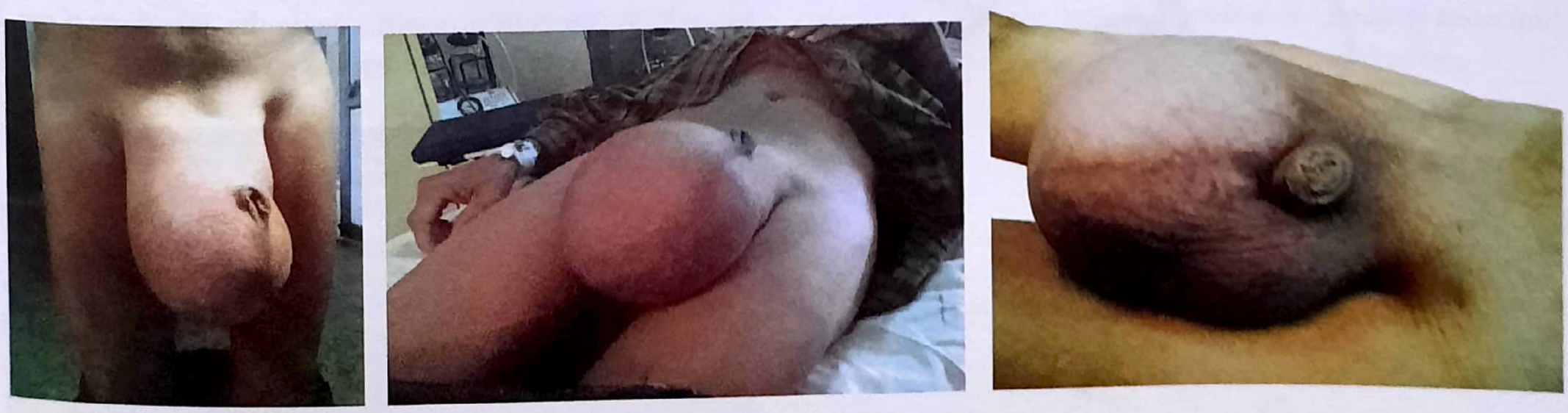

Figure 49.12: (a) A patient with huge hydrocele (b) A patient with huge hydrocele (c) A patient with moderate hydrocele

2. Pyocele.
3. Hematocele formation due to spontaneous bleeding into the sac or as a result of trauma.
4.. Herniation of the hydrocele sac through the dartos.
5. Calcification of the sac.

Investigations

Diagnosis is by clinical examination. USG; scrotum may sometimes be used to exclude a testicular tumour or **hematocele (due to testicular trauma)**. *(NEET)*

Treatment

- Treatment of a hydrocele is **always surgical.** In hydrocele; fluid present in sac should not be tapped (aspirated) because of the risk of introduction of infection through needle and subsequent pyocele formation. Tapping may also cause hemorrhage.
- Injection of sclerosing agents (tetracycline, phenol in almond oil) may be sometimes helpful but tend to be very painful and should be avoided.

Surgical Procedures

IMPORTANT FOR TABLE VIVA IN PROF EXAM

1. Eversion of Sac (EOS)-Jaboulay's operation

This is done for small and medium size hydrocele. In this, through a scrotal incision the hydrocele sac (tunica vaginalis) is opened the fluid sucked out and the **edges of sac are everted** and stitched at the back of the testis.

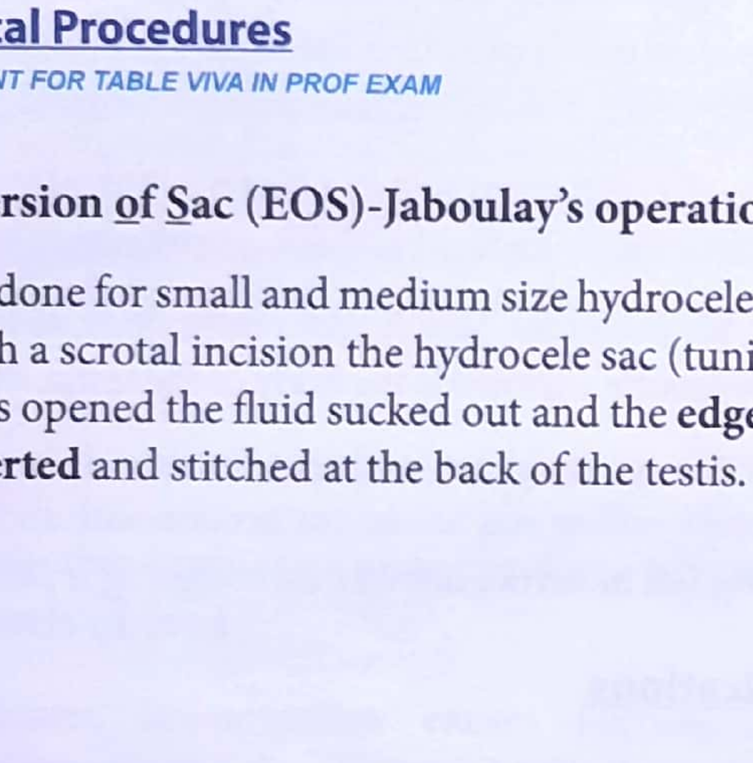

Figure 49.13(a): Lord's operation

Figure 49.13(b): Same patient after eversion of sac

2. Lord's Procedure

This operation is mainly indicated for large (huge) size hydrocele. In this operation 'plication'* of hydrocele sac is done by several catgut bites on the everted sac. When these sutured are tied, the whole tunica is bunched at the edge of the testis. (Figure 49.13a)

PLICATION the stitching of folds in an organ's wall to reduce its size. (for hindi speakers:- chunnat dalna)

3. Excision of Sac (Hydrocelectomy)

In this, whole of the sac is excised and the remaining edge is sutured by continuous catgut. This operation is indicated in thickened sac as in filariasis or in hematocele.

4. Treatment of congenital Hydrocele

In congenital hydrocele; fluid is present in layer of processus vaginalis, which communicates with peritoneal cavity (thus, it is in fact a indirect inguinal hernia with fluid content). The **treatment to this condition is herniotomy.** *(NEET, AIIMS JUNE 01, KERALA 97)*, ie; excision of hernial sac, which is patent processus vaginalis. It is done if congenital hydrocoele fails to resolve by 1 yr of age.

KEY BOX 49.6

Testicular Swelling Which are Translucent

- Chylocele
- Hematocele
- Pyocele
- Spermatocele

KEY BOX 49.7

Differentiation of Various Cystic Swellings of Tunica Vaginalis

Features	Primary Hydrocele	Secondary Hydrocele	Hematocele	Chylocele	Pyocele
1. Etiology (cause)	Unknown	Infection & malignancy	Trauma	Blockage of lymphatics	Suppuration
2. Nature of fluid	Watery straw coloured	Watery amber coloured	Blood stained or bloody	Chyle	Purulent
3. Consistency	Cystic	Cystic	Firm to hard	Cystic	Cystic
4. Transillumination	Brilliantly present	Moderately present	Absent	Absent	Absent
5. Skin signs of infection	None	Mild inflammation	Trauma, Blackening	Elephantiasis of skin	Gross inflammation, Warm & painful

Please read key box 49.6 and 49.7 very carefully before concluding this topic.

*****

OTHER SCROTAL SWELLINGS

Chylocele

The chylocele fluid is *milky white*. Filaria seems to the causative factor. The scrotal skin may be normal or thickened like in elephantiasis. Treatment is by eversion of sac followed by course of DEC treatment; and low fat diet.

Hematocele

A trauma to the scrotum may result into a hematocele. An old hematocele may feel solid due to the organization of clotted blood.

At times it may become very difficult to differentiate it from a testicular neoplasm. ***Treatment*** is evacuation of all blood then cleaning the scrotal sac by saline; followed by eversion of sac or excision of sac (hydrocelectomy) *(JIP. 81, DELHI 79, 93)*.

Pyocele

Pus in the tunica vaginalis usually occurs as a result of infection in a hydrocele or a hematocele. Treatment is immediate drainage, if an orchidectomy is to be avoided. This is a very painful condition.

*****

CYSTS RELATED WITH EPIDIDYMIS

Cysts that can occur with the epididymis can be divided into two broad groups.

1. Epididymal Cysts

These are cystic degeneration of epididymis and are filled with crystal clear fluid. Epididymal cysts are usually **multilocular** and often bilateral. (fig. 49.14 E2)

These cysts are due to cystic degeneration of remnants of the paramesonephric or Mullerian duct or wolffian duct system.

Clinical features

- Though condition is congenital, these cysts are usually found during middle life (between 40-50 years.)
- These are tense cystic swelling and fluctuation test is often difficult to be elicited.
- These cyst are situated ***behind the body*** *of testis* and gives feeling of bunch of grapes on palpation.
- On transillumination, chinese lantern pattern is seen.

Treatment

- For small cysts no treatment is required.

Figure 49.14(E1): Ultrasound of an epididymal cyst

- In case of a large cyst causing discomfort, excision of the cyst is all that is required.
- Aspiration is useless because the cysts are multilocular.

2. Spermatocele

This is a unilocular retention cyst *derived from some portion of the sperm conducting system of the epididymis.*

Clinical Features

- Patient presents with a scrotal swelling, which is usually small. *Occasionally the swelling may become big enough to make the patient think, that he has three testicles.* (IMP. POINT) (PGI 88)
- The swelling is situated in the **head of epididymis; *behind the upper pole of testis.*** (NEET) (fig. 49.14E2)
- The cyst is soft and fluctuation test is usually positive. [NOTE : Epididymal cyst are tense and fluctuation test is usually negative]

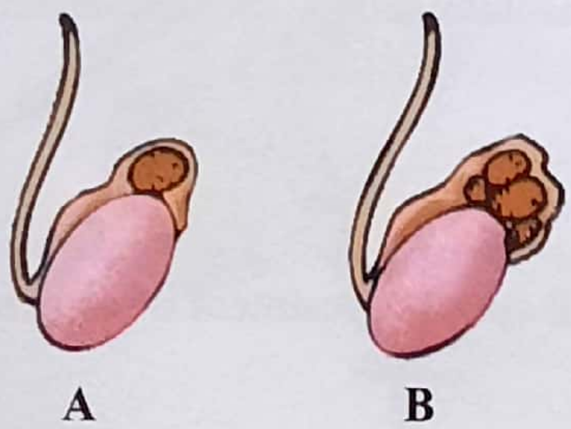

Figure 49.14(E2): (A) Spermatocele (B) Epididymal cyst

- Transillumination test is negative (because fluid is not clear in the cyst).
- The fluid within the cyst *resembles barley water,* which is revealed on aspiration.

Treatment

Small spermatocele can be ignored. Larger one should be aspirated or excised through a scrotal incision.

Other rare cyst in which may arise due to cystic degeneration of vestigial remnants are:

- The appendix of the epididymis
- The paradidymis
- Cyst of hydatid of morgagni
- The appendix of testis.

Please see figure 49.15.

Also read key box 49.8; below.

*****

KEY BOX 49.8

Difference B/W Epididymal Cyst and Spermatocele

Epididymal cyst	Spermatocele
1. Multilocular	Unilocular (Single locular)
2. Derived from degeneration of mullerian/ wolffian duct	Retention cyst, derived from some portion of sperm conducting system
3. Tense cystic swelling	Soft cystic swelling
4. Fluctuation test can not be often elicited	Fluctuation test is positive
5. Fluid in the cyst is crystal clear	Fluid in the cyst is barely water like
6. Transillumination test is positive	Trans illumination test is positive, but due to presence of sperm in the fluid most times trans illuminations test may be negative.
7. Cyst is usually situated behind the body of testis and gives feeling of small bunch of grapes (multilocular; hence bunch of grapes)	The swelling is situated in the head of epididymis behind the upper pole of testis.

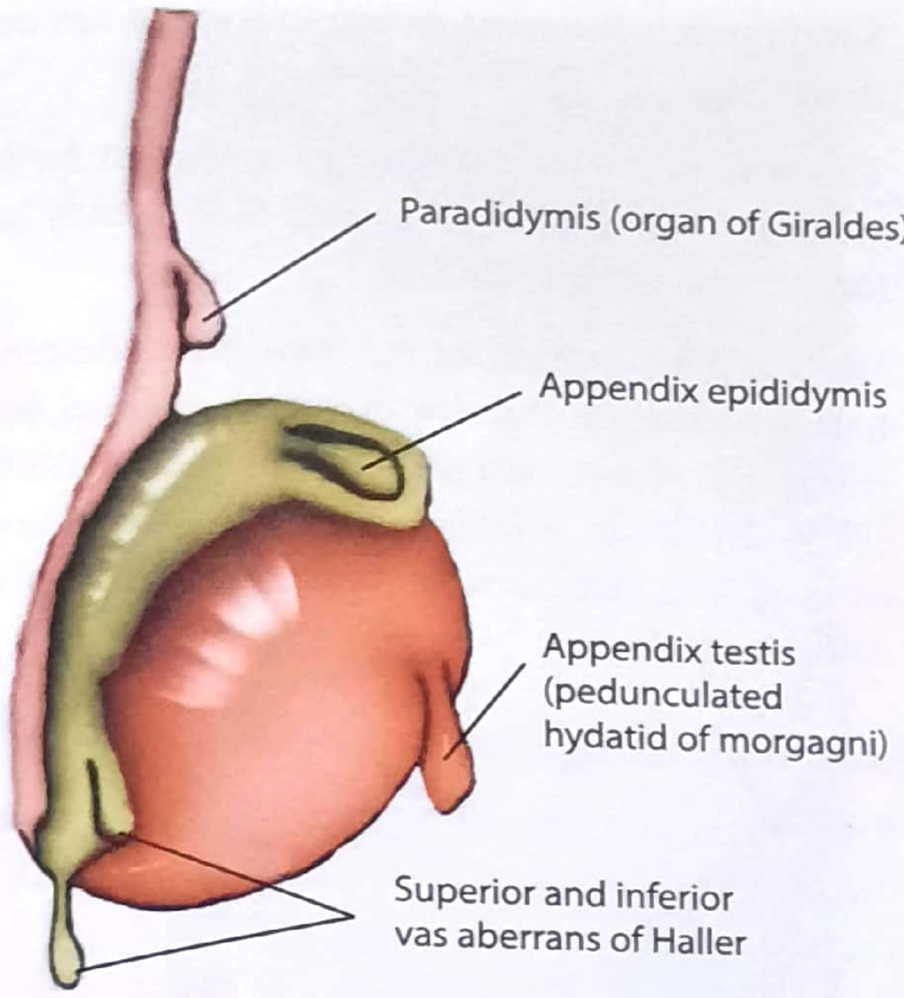

Figure 49.15: Testicular appendages

EPIDIDYMO-ORCHITIS

A. Acute Epididymo Orchitis

- Acute epididymd-orchitis is an **inflammation (increased blood flow) of the epididymis and/or testis**. This condition *usually follows* urinary tract infection such as cystitis, urethritis and prostatitis or follows instrumentation of urinary tract.
- The route of infection is usually along the vas deferens or its lymphatics. *(AIIMS FEB 97, AL 96)*

Causative Organism

The common causative organism are *E.coli, Streptococcus, Staphylococcus and Proteus.*

Clinical Feature

- Usually the patient present with an **acutely tender swelling of scrotum with pain and fever**.
- On examination, the testis is acutely tender particularly over epididymis.
- The **skin of the scrotum may be edematous**.
- Occasionally the infection may go on to abscess formation and discharge of pus may occur through the scrotal skin.
- *In acute epididymo orchitis elevation of testis relieves pain.* *(AIIMS 95, MANY PGME)*

Prehn's test is done to differentiate acute epididymo-orchitis and testicular torsion. Elevation of testis in a case of testicular torsion increases pain, while in epididymo-orchitis relieves pain (Positive prehn sign). *(VERY IMP. POINT)*

- It is infective condition, hence TLC is raised.

Treatment

- The treatment consist of bed rest, scrotal support, broad spectrum antibiotics and anti inflammatory drugs.
- Antibiotics are continued for at least 2 weeks.
- A high fluid intake is encouraged and urine is rendered alkaline by alkalizers.

B. Chronic Tuberculous Epididymo-Orchitis

- Tuberculous epididymitis is more often due to hematogenous spread, than descending infection from urinary tract. *(PGME)*
- The infection starts in the globus minor and spreads to the globus major. *(PGME)*
- Caseation may occurs and lead to a cold abscess formation, *which may burst outside and give rise to a sinus formation* on posterior surface of scrotum. *(IMP POINT)*
- There is thickening of the vas deference (beaded), because of extension of disease from the epididymis. (figure 49.16)

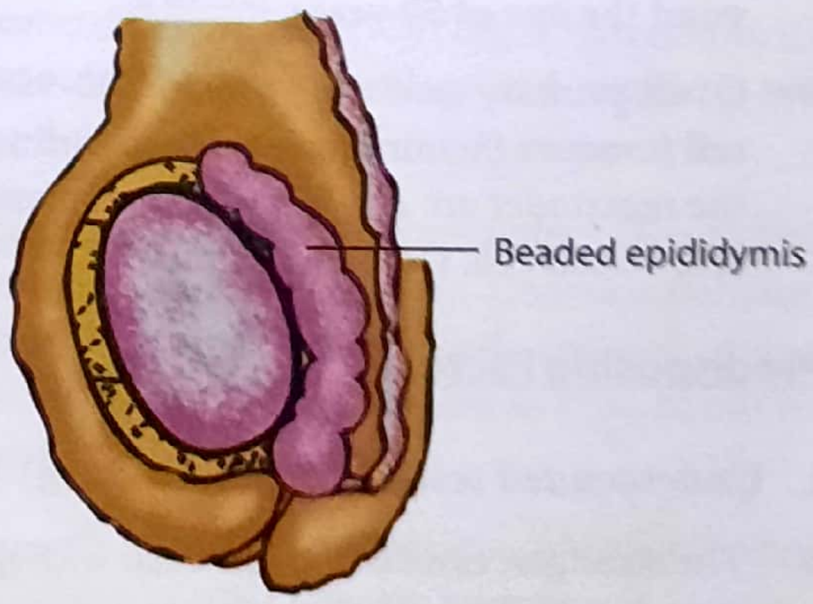

Figure 49.16: Beaded epididymis in a case of chronic epididymo-orchitis

Clinical Feature

- A slight discomfort may be present.
- The epididymis is first to be involved and feels tender and may become nodular. Later, the whole vas deferens and the seminal vesicles may become beaded. (PGI, AI). Please see fig. 49.16.
- *Testis is usually not involved or involved very late.*

Treatment

The patient is put on antitubercular drugs. If there is no response to drugs with in 2 months, epididymectomy alone or with orchidectomy is done.

C. Mumps orchitis

- It may develop in about 15-20 percent of males suffering from mumps, *usually when the parotid inflammation is subsiding.* (IMP. POINT)
- The testis becomes very painful and swollen.
- Testicular atrophy develop in *30-40% of cases.* (IMP.)
- If an release incision is made over tunica vaginalis; early in the attack; which may prevent testicular atrophy.

*****

TUMOUR OF TESTIS

- Malignant tumours of testis are rare and accounts for about 1-2 percent of malignant tumours in men.
- About *90-95% of testicular tumours are malignant.* (UP)
- Striking feature of testicular carcinoma is that, they **predominantly occur in younger age group, between 20-40 years** of age and average age being 32 years, however **testicular lymphomas are seen beyond the age of 50 years.** (ASSAM 96)
- Of all primary testicular tumour, **90-95% are germ cell tumours (Seminoma and non-seminoma)**, while the remainder are non germ cell neoplasms (leyding cell, Sertoli cell, Gonadoblastoma). (PGI 01, AIIMS 02)

Predisposing Factors

1. Undescended testis (Cryptorchidism) (NEET)

- The strongest association has been with the cryptorchid (undescended) testis. *Approximately, 7-10% of testicular tumours develop in patients who has a history of cryptorchidism* (PGI DEC 98).
- **Seminoma** is the most common form of tumour in these patients. (AIIMS NOV 02, MANY PGME)
- The relative risk of malignancy is highest for intra abdominal testis (1 in 20) and is significantly lower for inguinal testis (1 on 80).
- Surgical replacement of cryptorchid undescended testis into the scrotum (by orchidopexy) *does not alter malignant potential* of the cryptorchid testis (AIIMS NOV 99). However, it does facilitate examination and early tumour detection, hence early treatment of carcinoma if it develops; later in life.

2. Exogenous estrogen administration

- Exogenous estrogen administration to the mother during pregnancy has been associated with an increased risk of testicular tumour. (PGME)

3. **Trauma** may be contributory factor; however not proved.
4. **Atrophy:** Infection related testicular atrophy has been associated with testicular tumour, however, a causal relationship has not been established.
5. **Genetic disorders:** *Testicular feminizing syndrome, Klinefelter's syndrome.* (NEET)
6. Testicular Ca in sibling

Classification

A. WHO Classification

I- Seminoma

II - Non-seminomatous germ cell tumours

- Teratoma (NEET)
- Embryonal cell carcinoma (NEET)
- Choriocarcinoma most malignant testicular tumor
- Yolk sac tumour most common testicular tumor in infancy (NEET)

B. Histological Classification

Tumours of testis are classified according to predominant cellular type:

1. **Seminoma*** **(40 %) [M/C]** (NEET, AI 89, MANY PGME)
2. Teratoma (32%)
3. Combined seminoma and teratoma (14%)
4. Interstitial tumour (1.5%)
5. **Lymphoma (7%)** (NEET)
6. Other tumours (5.5%)

TO REMEMBER: **S**eminoma; **S**abse jyada hota hai (40%)

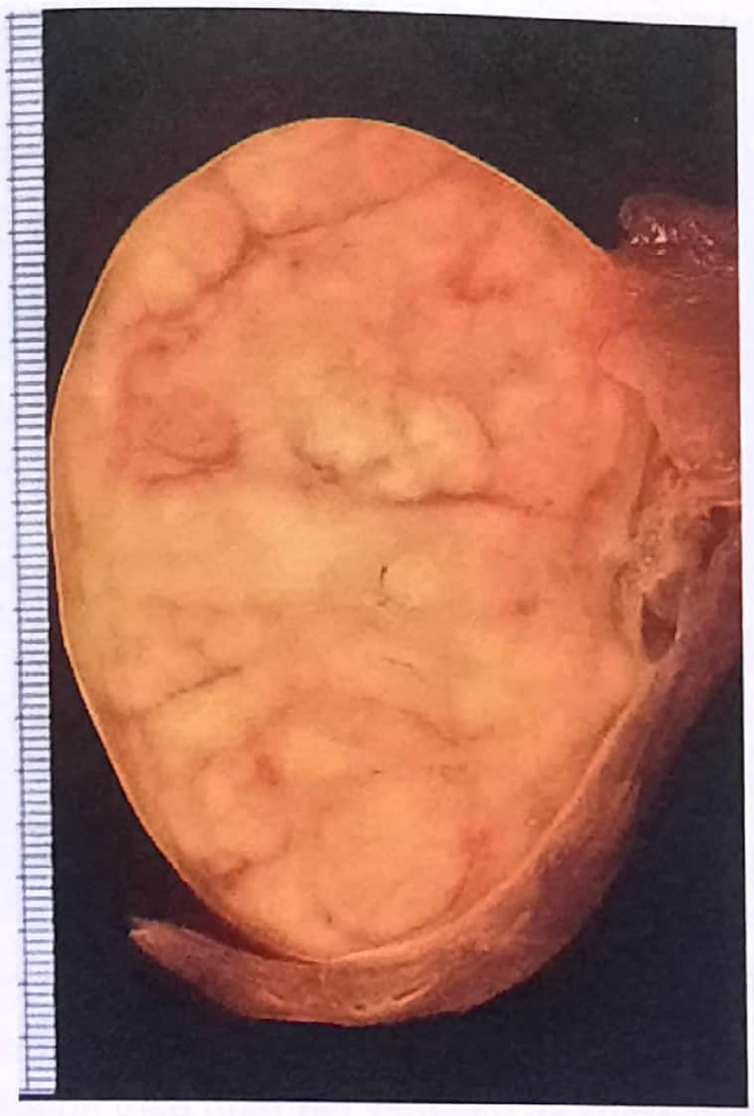

Figure 49.17: Seminoma

Figure 49.18: Teratoma

Pathological Types

1. Seminoma

This is the most common *(AI 89, MANY PGME)* form of testicular tumour in adult. The peak incidence of seminoma is between 35-45 years; and is extremely rare before puberty. Three histological subtypes of pure seminoma have been described:-

(i) *Classical seminoma:* Classical seminoma accounts for 85% of all seminomas and is most common in fourth decade of life.

(ii) *Anaplastic seminoma:* Accounts for 5-10% of all seminoma.

(iii) *Spermatocytic seminoma :* Accounts for 5-10% of all seminoma and resemble spermatocytes. More than half of the patients with spermatocytic seminoma are over the age of 50 years.

2. Teratoma

- A teratoma contain tissue derived from more than one germ cells ie; ectoderm, mesoderm or endoderm are often present.
- It is malignant in adults.
- The incidence is slightly less than seminoma (32%). The peak incidence being in age group between **19-35 years.** (To remember: **Te**ratoma occurs between 9**Te**en-35, may appear to be funny, but will help you for long time memory)
- On cut section the common type is yellow with *cystic spaces* containing gelatinous fluid with areas of hemorrhage and nodules of cartilage. *(MAY BE FUTURE PGME Q)*

Histological Classification of Teratoma

Histologically, it is subclassified into **four types.**

(i) *Teratoma differentiated (TD) (1%):* Uncommon; it is a dermoid containing cartilage and muscle as well as glandular elements.

(ii) *Malignant teratoma intermediate: [Teratocarcinoma] (MTI-A and B) (80%):* Contains definitely malignant and incompletely differentiated components, there is some mature cell in type A, but not in Type B.

(iii) *Malignant teratoma anaplastic: embryonal carcinoma (MTA) (15%)* - This is common in infants & children and contains anaplastic cells of embryonal origin in parts; these are often responsible for elevated alpha fetoprotein levels.

(iv) *Malignant teratoma trophoblastic (MIT); Choriocarcinoma (1%)* - This is highly malignant, spreads by blood stream and lymphatics in the early stages. It often produces human chorionic gonadotrophin (HCG).

3. Combined seminoma and Teratoma

- This accounts for about 14%. In most of such tumours the seminoma element is separate from teratoma.
- The peak incidence is between 25-35 years.
- The behavior and prognosis of these combined tumours tends towards that of the teratomatous component.

4. Interstitial cell tumour

- Interstitial cell tumour may occur in all age group, but peak age of incidence is between 30-50 years.
- Tumour arises either in cells of leyding or in cells of sertoli.
- *Leyding cell tumour* produce excess testosterone and may *produce Androgenic effects (sexual precocity and muscular development.* (IMP. POINT)
- *Sertoli cell tumour* may produce *feminization (Gynecomastia).* (IMP. POINT)

5. Lymphoma

- Lymphoma: is the *most common testicular tumour in a patient over the age of 50 years.* (AI 01) and is most common secondary neoplasm of testis, accounting for 5% of all testicular tumour.

Spread

1. Lymphatic spread

Testicular tumours spread most commonly via the lymphatics (AIIMS 05, MANY PGME) to the *para-aortic lymph nodes, iliac lymph nodes, mediastinal lymph nodes and supradavicular lymph nodes.* (VERY IMP. POINT)

2. Local spread

Testicular tumour may involve the epididymis and cord structures in about 10% cases. Scrotal skin is not involved until very late, because of tough tunica albuginea, which is a natural barrier to extension of growth. Involvement of scrotal skin means advanced disease (stage IV) and carry a poor prognosis. *Vas deference is almost never involved.*

3. Hematogenous spread

This is uncommon route of spread and occurs in advanced disease. *Choriocarcinoma is exception to this rule and is characterized by early hematogenous spread* (PGME).

It is for this reason, choriocarcinoma has worst prognosis among all testicular carcinoma (AIIMS 87).

Clinical Feature

- The most common symptom of testicular cancer is painless progressive enlargement of testis. (PGME)
- Testicular enlargement is gradual and patient usually complains of testicular heaviness.
- Acute testicular pain is seen in approximately 10 percent of cases and may be the result of intratesticular hemorrhage or infarction.
- On examination, normal testicular sensation is lost. {Hindi Testis ko dabaney par pain nahi hota} (IMP. POINT)
- Approximately 10% of patients presents, with symptoms related to metastatic disease, such as:-
- Back pain due to retroperitoneal metastasis, involving nerve roots.
- Other symptoms include cough or dyspnea (pulmonary metastases), anorexia, nausea or vomiting (retro-duodenal metastases), bone pain (skeletal metastases).
- A lump in the neck (due to supra-clavicular lymph node involvement) and lump in abdomen due to para-aortic lymph node enlargement may be some times first presentation. (IMP. POINT)
- About 1-5% of patient have gynecomastia (mainly with the teratomas).

Investigations

1. **Chest X-ray:** To detect
   - Pulmonary metastases cannon ball secondaries: (cannon ball ka matlab fire arm ke goley jaisa)
   - Enlargement of pulmonary, mediastinal lymph node
2. **IVP:** IVP is not essential though may be helpful in revealing deviated or obstructed ureters secondary to enlarged retroperitoneal lymph node; most commonly para-aortic lymph node (as a result of metastases).

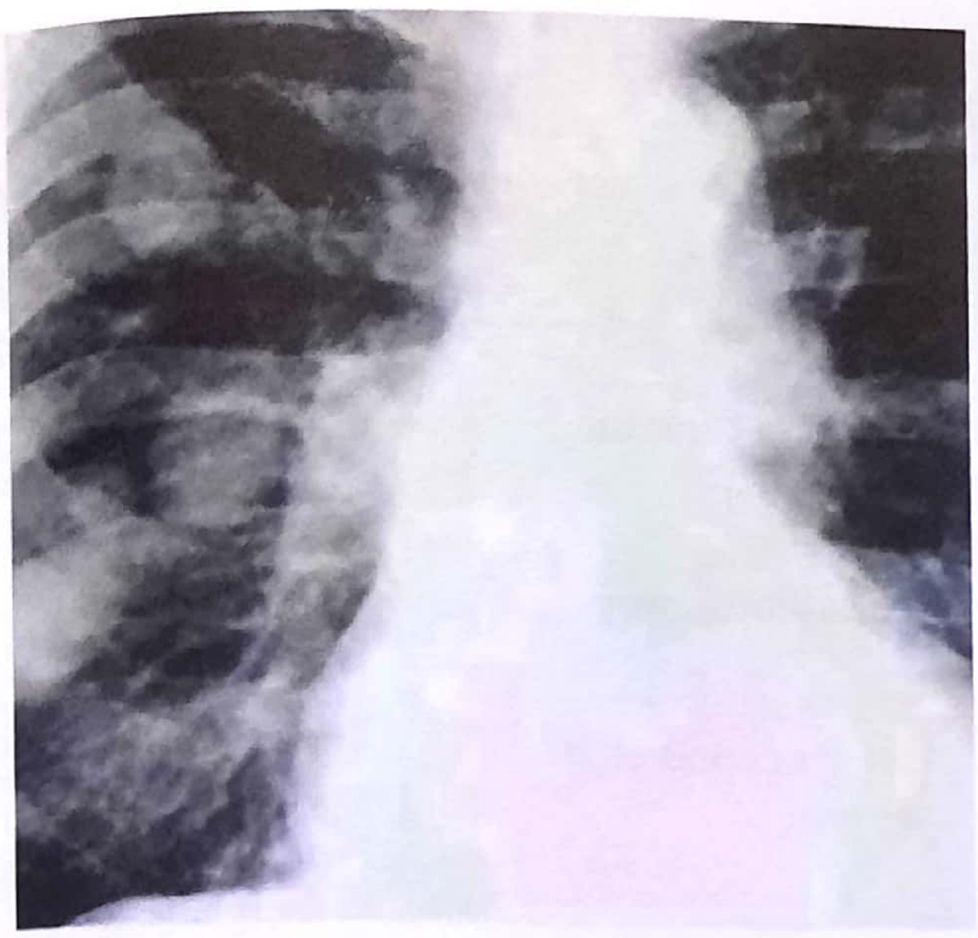

Figure 49.19: Cannon ball metastases from carcinoma of the testis.

3. **Abdominal ultrasound:** Can show enlarged lymph nodes, secondaries in the liver.
4. **Abdominal CT scan:** Abdominal CT scan in *investigation of choice for retroperitoneal lymph node metastases and for staging the tumour.*
5. **Gallium Scan:** Recently 67Ga is found to be valuable for locating seminoma deposits.
6. **Ultrasonography of scrotum:** *Scrotal ultrasound is useful for establishing the diagnosis a lesion in testis, when clinical examination is not certain, (to differentiate between hydrocele, hematocele or a tumour).* (NEET)
7. **Hormonal Study (Tumour markers)** (AIIMS MAY 03, NOV 04, PGME MANY TIMES)

   (i) **β-HCG:** β-HCG (Beta human chorionic gonadotropins) levels are elevated in about 65% patients with non-seminomatous testicular tumours (teratomas), but only in 10% cases of seminomas. (Remember with : β-HCG-elevated in Both)(*B* for Both)

   (ii) **AFP (Alpha-feto protein):** Increased levels of α-fetoprotein is found in **non seminomatous germ cell tumours** (teratomas).

   (iii) **LDH-1**: is elevated in 30-80% cases of seminoma and 60% cases of non seminoma.

   (iv) **Other tumour markers** have been described for tes-tis cancer, including placental alkaline phosphate (FLAP) (PGI DEC 99) and gamma-glutamyl transpeptidase (GGT).

AFP level is not elevated in seminomas. (PGI, AL01, UP)

AFP IS ELEVATED ONLY IN NON SEMINOMATOUS TUMOURS]

NOTE: Tumour markers are useful in not only making diagnosis of malignancy, but the rate of decline of tumour markers during chemotherapy is also used to predict; response rate in patient with advanced disease.

8. **Testicular biopsy should not be done:** (AIIMS NOV 01, AIIMS JUNE 01) *through scrotal incision, because this opens up newer lymphatic channels and increase chances of metastases.*

Staging of Testicular Tumours

Stage I:	Testicular lesion only
Stage II:	Lymphatic spread to regional lymph nodes **(below the diaphragm)**
IIa	Nodes less than 2 cm in size
IIb	Nodes between 2-5 cm (Less than 5 in number)
IIc	Nodes more than 5 cm (more than 5 in number).
Stage III:	Involvement of Mediastinal or Supra-clavicular lymph nodes. **(Nodes above diaphragm)**
Stage IV:	Extra lymphatic involvement to lung or liver.

TNM staging of tumor of testis

Tx		Cannot be assessed
T0		No evidence of primary tumor
Tis		Intratubular cancer
T1		Tumor limited to testis without lymphovascular invation
	T1a	Tumor <3 cm
	T1b	>3 cm
T2		Tumor limited to testis with lymphovascular invasion or

	Tumor invading hilar soft tissue or epodidymis or penetrating visceral mesothelial layer covering external surface of tunica abluginea with or count lymphovascular invasion.
T3	Invades spermated cord
T4	Invades scrotum
[N]	
Nx	Cannot be assessed
N0	No regional lymph node metastasis
N1	Metastasis with a lymph node mass >2cm but 5cm in greatest dimension & less than or equal to 5 nodes positive.
N2	Metastasis with Lymph node mass >2 cm but 5cm in greatest dimension or >5 nodes (+) none larger than 5cm or evidence of extranodal extension of tumor.
N3	Nodal mass > 5 cm
[M]	
Mx	Cannot be assessed
M0	No distant metastasis
M1a	Distant metastasis (+) in nonregional lymph node or lungs
M1b	Nonpulmonary visceral metastasis

Management

(AIIMS NOV 2001, AI 03, MANY PGME)

For a testicular tumour **high inguinal orchidectomy is done** and then further treatment is based on the histo-pathological report of the tumour *(AIIMS NOV 02).*

Seminomas are highly radio Sensitive, and excellent results have been obtained by irradiation of stage I & II.

Seminoma is radio Sensitive and melts like Snow by radiotherapy ie; it is a highly radio Sensitive tumour. *(UPSC 07)*

I am giving a flow chart for treatment of Seminoma and non-seminoma germ cell tumour: hope this will help you alot:

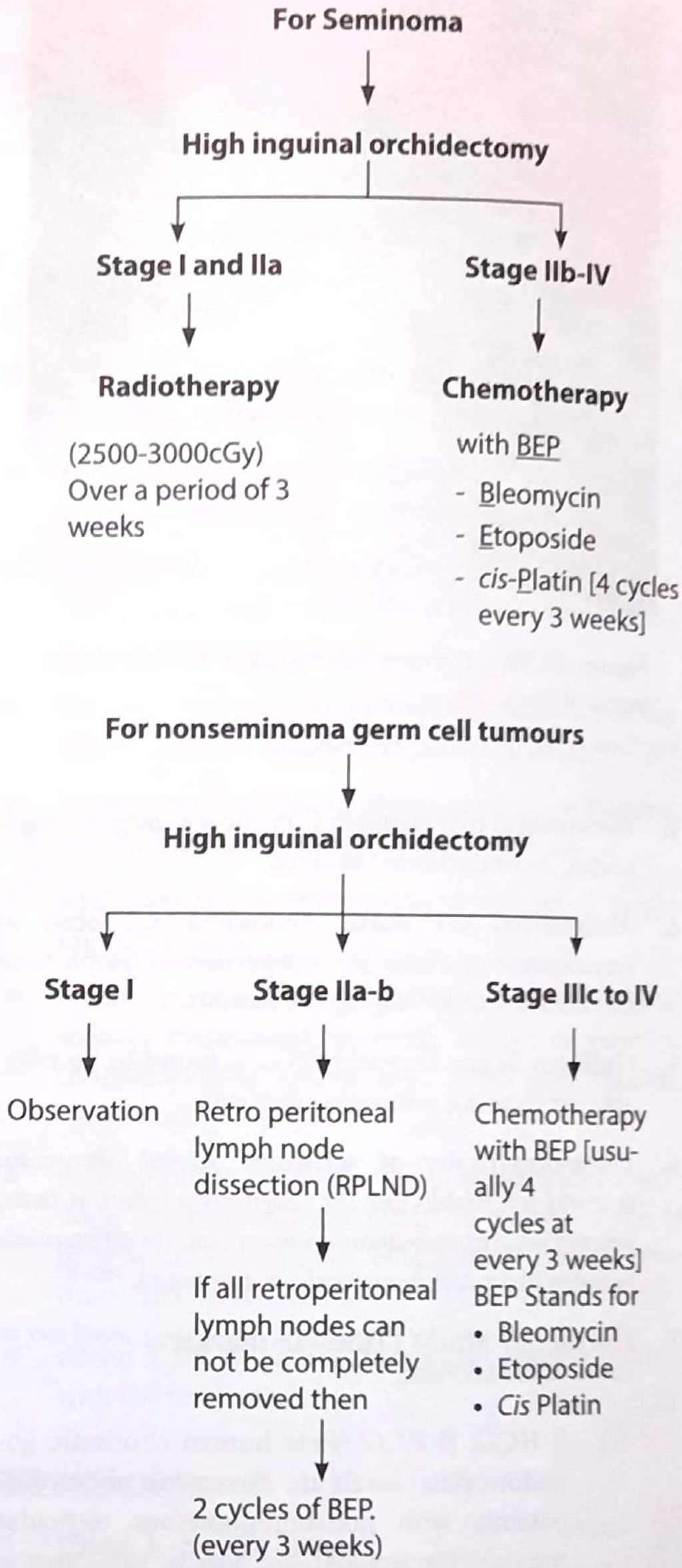

NOTE : High inguinal orchidectomy?

Orchidectomy is done through a inguinal incision made over inguinal canal as high (proximal) as possible in inguinal canal, for a testicular carcinoma]

In *high inguinal orchidectomy:* first spermatic cord is ligated near the internal ring (deep ring) and then whole cord along with the testis is excised.

KEY BOX 49.9		
Difference between Seminoma and Teratoma *(MANY PGME)*		
	Seminoma	**Teratoma**
1. Cell of origin	Seminiferous tubules	Totipotent cells of rete testis
2. Incidence	40%	32%
3. Age group	35-45 years	20-35 years
4. Shape of testis	Maintained	Distorted
5. Surface	Smooth	Initially smooth later irregular
6. Consistency	Firm	Soft to firm, may be variable
7. Spread	Lymphatic only	May be through blood
8. AFP	Not elevated	elevated
9. b-HCG	Elevated in only 10%	Elevated in 65%
10. Radio Sensitivity	Excellent - (melts like Snow)	Less radio sensitive
11. Prognosis	Good	Worse

Prognosis

Prognosis depends on the histological type and the stage of the tumour.

(a) ***Seminoma***, with no nodal metastases has 95% of five-year survival after orchidectomy and radiotherapy or chemotherapy; while with metastases the survival drops to 76%.

(b) ***Teratoma:*** For stages I&II, five-year survival rate is 85%, for stages III & IV the survival is about 60%. With improvements in chemotherapy; this rate is rising.

(c) ***Testicular tumours*** in children are usually anaplastic teratomas. They occur before the age of 3 years and are rapidly fatal.

- Overall, *seminoma has better prognosis* than teratoma. *(MANY PGME)*

Last but not the least please read key box 49.9 carefully, this is very very important.

*****

EXTRAGONADAL GERM CELL TUMOURS

- Extragonadal germ cell tumors are rare; accounting for approximately 3% of all germ cell tumors.
- Most retroperitoneal germ cell tumours have their origin from a testicular primary, whereas *medlastinal germ cell tumors are truly ectopic.*
- The **most common sites** of origin *in* ***decreasing order*** *is:-* mediastinum, retroperitoneum, sacrococygeal area and pineal gland. (Figure 49.20 next page)
- All germ cell types may be observed, however seminoma composes more than half of the retroperitoneal and mediastinal tumours.

Clinical feature

- Clinical presentation depends on the site and volume of disease.
- Mediastinal lesions may present with pulmonary complaints.
- Retroperitoneal lesions may present with abdominal or back pain and a palpable abdominal lump.

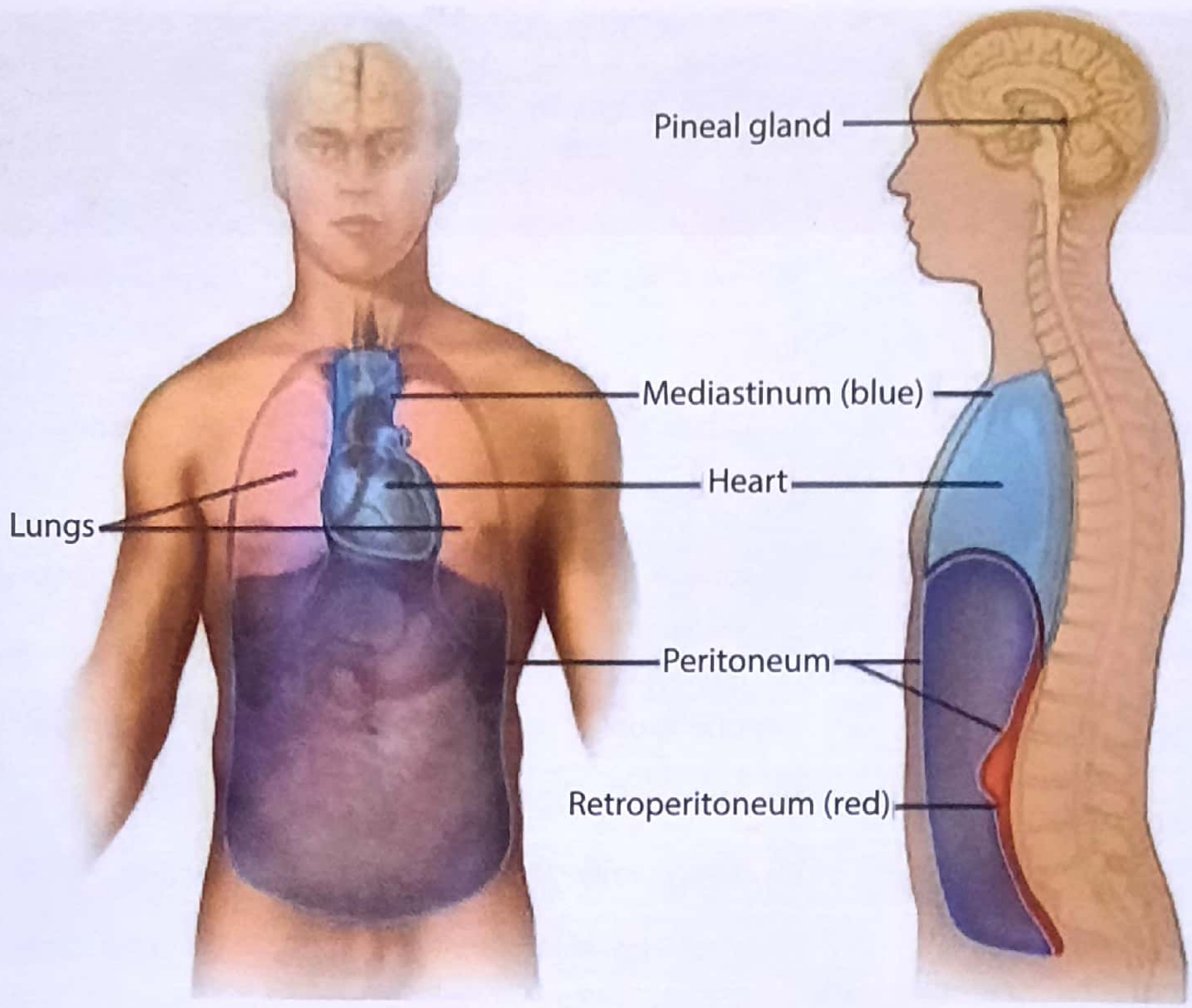

Figure 49.20: Common sites of extragonadal germ cell tumour

- Sacrococcygeal tumors are most commonly seen in neonates and may present with a palpable mass and bowel or urinary obstruction due to pressure effect.
- Pineal tumors may present with headache, visual or auditory complaints or hypopituitarism.
- Metastatic spread occurs to regional lymph nodes, lung, liver, bone and to brain.
- A careful testicular examination is must; along with USG to exclude any occult testicular primary.

Treatment

- Treatment of extragonadal germ cell tumours parallels to that of testicular tumours.
- Low-volume seminoma can be managed with radiotherapy.

  Seminoma melts like Snow by radiotherapy; highly radioSensitive
- High-volume seminoma should receive chemotherapy.
- For nonseminomatous elements; primary chemotherapy should be employed with surgical excision of residual masses. However; prognosis remains poor in these patients.

*****

MALE INFERTILITY

- Male infertility is the inability to initiate a pregnancy after one year of adequate and unprotected sexual intercourse.
- Overall one in eight marriages (about 15%) are infertile and in half of them cause lies in male partner.

Etiopathogenesis

Fertility of a couple depends on the following factor:

- Intact hypothalamopituitary gonadal axis of husband and wife.

KEY BOX 49.10	
Semen characteristic	**Lower reference limit**
Volume, mL	1.5
Sperm concentration, 10^6/mL	39
Total sperm number, 10^6	15
Total motility (PR + NP), %	40
Progressive motility (PR), %	32
Vitality (live spermatozoa), %	58
Sperm morphology (normal forms), %	4
pH	≥ 7.2
Seminal fructose, µmol/ejaculate	≥13

PR, progressive motility; **NP**, non-progressive motility

- Physical, sexual and emotional behaviour.
- Normal external and internal genitalia.
- Semen parameters and ovulation being normal in quality, quantity and timing.
- The basic causes of male infertility include defective spermatogenesis, decreased semen volume and changed seminal biochemistry, motility defect, obstruction or a capacitation* fault.

NOTE: **Capacitation** - The physiological process where by ejaculated spermatozoa; in female genital tract acquire the ability to fertilize ova, characterized by rupture of the acrosomal membrane, which releases enzymes that facilitate penetration.

Causes

Congenital	Noonan Syndrome Klinefelter's syndrome
Trauma	Traumatic injury to testis
Developmental	Absent vas deferens (vasal aplasia)
Psychogenic	Erectile and ejaculatory dysfunction.
Endocrinal defect	Pituitary insufficiency/ androgen deficiency.
Varicocele	most common surgically treatable cause

Investigation

A. Semen analysis

- A specimen is produced by masturbation, after 3 days of abstinence and should be examined with in 2 hours and at least three sample should be analyzed.
- Determination of the volume, pH, liquefaction, sperm count, viability and motility is taken in account for a complete semen analysis. **See box 49.10.**

B. Hormone Studies

Patients with no sperm in the ejaculate should have serum FSH, LH, prolactin and testosterone levels measured.

C. Testicular Biopsy: Testicular biopsies are indicated in azoospermic patients *(AI 97)* to distinguish between obstructive versus parenchymal disease.

D. Seminal fructose level: Absence of seminal fructose **indicate obstruction of the ejaculatory duct** *(AI, PGI)* and the diagnosis is confirmed by vasography.

E. Anti Sperm Antibodies: Anti-sperm antibodies can be measured in the serum of either the male or female, or in the seminal fluid. Anti-sperm antibodies decrease the motility of sperm.

F. Studies to detect a non-palpable varicocele include venous Doppler, venography, colour doppler.

Management

A. Nonoperative treatment: Primary male infertility may be caused by low levels of hormones. Spermatogenesis may be stimulated by administration of HCG followed by FSH.

B. Operative treatment: Surgical indication is indicated in following conditions and treated accordingly.

(i) Varicocele (M/C indication) *(MAHE 98)*
(ii) Epididymal obstruction
(iii) Retrograde ejaculation
(iv) Ejaculatory duct block
(v) Unilateral testicular atrophy

I have given a table in key box 49.11, for those who are interested more on this, kindly go through it.

KEY BOX 49.11	
Condition	**Treatment**
1. Varicocele	a. Microsurgical varicocelectomy b. Laparoscopic ligation c. Percutaneous occlusion of spermatic vein
2. Epididymal obstruction	Vaso Epididymal anastomosis (VEA) Macroscopic VEA Microscopic VEA
3. Vasal block	Vaso vasal anastomosis (VVA) Microsurgical '2' layer
4. Ejaculatory duct obstruction, Vas aplasia	**Cystic** - Deroofing TUR* **Fibrous** - TUR or (IVF).
5. B/L congenital Vas aplasia	Epididymal sperm aspiration and in- vitro fertilization (IVF)
6. Ejaculatory failure	**a. Retrograde ejaculation** - Bladder neck reconstruction - Sympathomimetics **b. Failure of emission** - Sympathomimetics - Electro ejaculation
7. Unilateral testicular atrophy	Orchidectomy.
***TUR: Transurethral (endoscopic) resection.**	

Sample Questions for Prof Examination

1. Describe the complications of undescended testis. How would you treat a boy of 7 years who comes with such a complaint?
2. What are the varieties of the tumours of the testis? Describe the signs, symptoms and treatment of seminoma of testis.
3. Describe the differential diagnosis of testicular enlargements. How will you investigate a case of suspected testicular tumours?
4. Write short note on
   - Congenital hydrocele
   - Encysted hydrocele
   - Vaginal hydrocele
   - Infantile hydrocele
   - Secondary hydrocele
   - Seminoma
   - Teratoma
5. Discuss the differential diagnosis of an inguinoscrotal swelling.

50 Day Surgery

Contents

- Introduction
- Definition
- Benefits of day surgery
- Day surgery units
- Suitable day surgery procedures
- Extended day surgery
- Hospital hotels

INTRODUCTION

During recent years duration of hospital stay has reduced, which is associated with an expansion in day case surgery. Today; 3 levels of day surgery can be defined

1. *Minor ambulatory surgery:* Procedures are performed with or without anesthesia.
2. *Major ambulatory surgery:* Procedures are done which require post operative observations but overnight stay is not anticipated
3. *In patient surgery* - Patients arrives one day preoperative in hospital and stays in hospital for at least one night.

Currently, in developed countries, approximately 50% of elective operations are performed as day cases. The impetus for this has been the high cost of keeping patients in patient beds, the reduction in availability of those beds and the long surgical waiting lists.

Improvements in anesthesia and pain control, minimally invasive surgery and changing attitudes to recovery after surgery have all promoted the expansion of day surgery. Day surgery is not a new concept. It dates back to 1909 when James Nicoll, a Scottish surgeon reported operating on nearly 9000 children as day cases for operations such as talipes, correction of hare lip, hernia repair and mastoid surgery.

DEFINITION

Day surgery is defined as planned investigations or procedures on patients who are admitted and discharged home on, the day of their surgery but require facilities and time for recovery. This definition excludes minor procedures, in out patient or accident and emergency departments.

Definition of terms used in ambulatory surgery

- Outpatient surgery : not admitted to a ward facility
- Procedure room surgery : surgery not requiring full sterile theatre facilities
- Day or same-day surgery : admitted and discharged within the 12-hour day
- Overnight stay : 23-hour admission with early morning discharge
- Short-stay surgery : admission of up to 72 hours

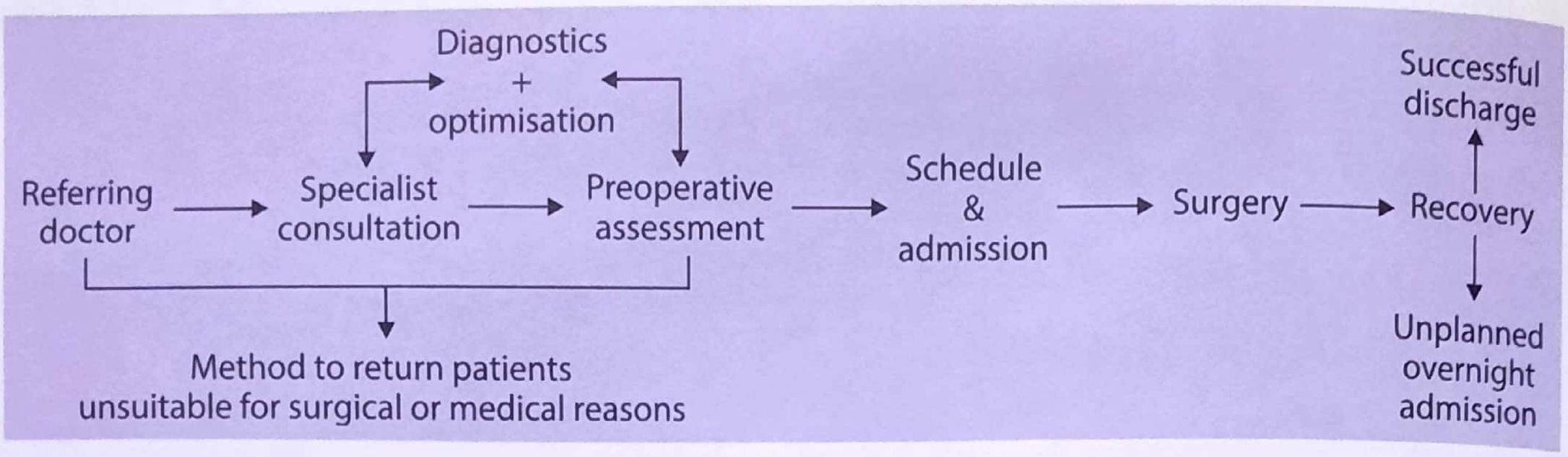

BENEFITS OF DAY CASE SURGERY

1. Reduced cost
2. More efficient
3. Reduced waiting lists for elective surgery
4. In patients beds; freed for major and emergency surgery.
5. Low incidence of serious post operative morbidity.
6. Reduced incidence of thromboembolism and hospital acquired infections
7. Minimal disruption of patients normal life and early return to work.
8. Patients, particularly children prefer it due to less psychological disturbance in children.

*****

DAY SURGERY UNIT (DSU)

There are 4 basic designs of day surgery unit.

1. Hospital integrated - Ambulatory surgical patients are managed through same surgical facility as in patient.
2. Hospital based - Separate ambulatory surgical facility located within the hospital that handles only outpatient.
3. Free standing - May be associated with hospitals but are housed in separate buildings.
4. Office based- Operating suites are managed in conjunction with physicians, for convenience of the surgeons.

The efficient organization of day surgery on which such advantages rely is dependent on a number of factors, but none more so than appropriate patient selection.

The DSU is a self contained dedicated day surgery facility, with its own reception, operating and recovery areas designed to ensure that all the essentials for good day surgeries are carried out. The day surgery unit is usually part of a general hospital.

The patient selection is normally carried out by senior day surgery unit nurses, who use medical and social questionnaires to detect problems.

KEY BOX 50.1

Age (years)	Test indicated	
	Men	Women
<40	None	Pregnancy test
40-49	ECG	Hematocrit level, pregnancy test
50-64	ECG	Hematocrit/ Hb%, ECG
65-74	• Hematocrit/Hb% • EGG • Serum area/ nitrogen • Glucose	Same
>75 yrs	Same as above + chest radiograph	Same

The American Society of Anaesthesiologists (ASA) Physical Status Classification (American Society of Anaesthesiologists 1963)	
ASA 1	A normal healthy patient
ASA 2	A patient with mild systemic disease
ASA 3	A patient with severe systemic disease
ASA 4	A patient with severe systemic disease that is a constant threat to life
ASA 5	A moribund patient who is not expected to survive without the operation

Active management of postoperative nausea and vomiting (PONV)

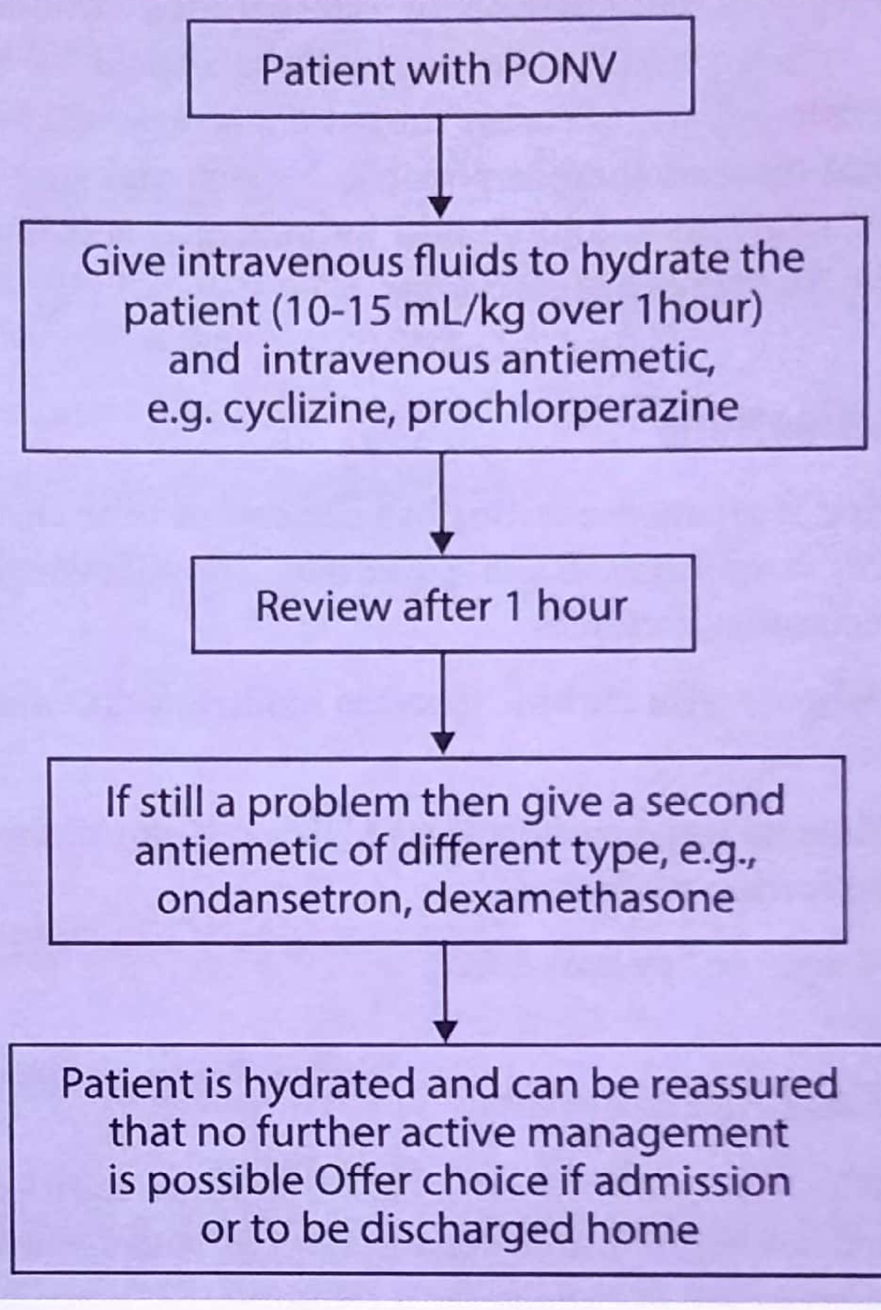

The clinical director, usually a consultant surgeon or an anesthetist should manage the DSU. Borderline cases are referred for anesthetic opinion and consultant anesthetist is involved in day surgery.

Patient Selection

A. Health criteria

(i) ASA*-1 or 2,Occasionally a stable 3 or 4.

(ii) BMI**<30

(iii) Normal airway

(iv) No recent URTI***

(v) No significant past or family history of anesthetic problems.

(vi) < 70 years of age

*AS A= American Society of Anesthesiology classification score.

BMI** = Body mass index.***

URTI*** = Upper respiratory tract infection.

B. Social criteria

(i) Responsible adult to escort home, plus supervise at home overnight.

(ii) Easy access to a telephone

(iii) Home within, maximum 1 hour drive.

Operation Selection

(i) Minimal physiological alteration.

(ii) Not associated with excessive blood loss or fluid shifts.

(iii) Very low risk of serious post operative complications (eg. bleeding or airway obstruction).

(iv) Duration of surgery up to 1 hour, maximum 2 hours

(v) Pain must be controllable with oral analgesics after discharge

(vi) Early ambulation

Postoperative complications

The patient is discharged home within a few hours of surgery requires proactive monitoring in the immediate postoperative period.

Reactionary haemorrhage is uncommon but requires careful consideration following tonsillectomy and laparoscopic procedures. Reactionary haemorrhage following tonsillectomy occurs within the first 6 hours and these patients should be monitored for this period. The danger in laparoscopic surgery is covert haemorrhage, especially in young fit patients who can lose over 15% of their blood volume before showing any cardiovascular signs of hypovolaemia (tachycardia

and hypotension). These patients require a high index of suspicion as the first signs can often be as subtle as slow recovery and mobilisation or uncontrolled abdominal pain. When problems do occur, there should be clear escalation policies to ensure the patient is reviewed by the surgical team as soon as possible. Nausea and vomiting is not uncommon and should be managed actively to maximise successful discharge.

Investigations

Routine preoperative testing of a patients prior to elective surgery is unjustified and expensive. The following are the recommendations.

- Patients with chronic diseases require additional lab studies
- Patients with an unexplained Hb% < 10 gm/dl should be further evaluated.
- Please see key box 50.1.

Day Case Anaesthesia

- The choice is between local or regional anesthesia, with or without mild sedation *or* GA with LA where appropriate PO analgesia is required.
- Local or regional anesthesia is perhaps the ideal and is excellent for elderly patients.
- Central anesthetic blocks/ epidural/spinal/ caudal may be less suitable because of time taken to carry out the block and allow it to work, the time taken for patient to mobilize and high incidence of urinary retention.
- Most popular and widely used anesthetic technique which the patients and surgeons may express a" preference for is GA. **Propofol,** a newer anesthetic agent, has established itself as agent of choice for induction and often also for maintenance, (MANY PGME)
- For inhalation induction, sevoflurane has now replaced halothane in many countries. (MANY PGME)

Discharge criteria

- Vital signs stable for at least 1 hour
- Correct orientation as to time, place and person
- Adequate pain control with supply of oral analgesia
- Understands how to use oral analgesia supplied
- Ability to dress and walk where appropriate Minimal nausea, vomiting or dizziness
- Has taken oral fluids
- Minimal bleeding or wound drainage, Has passed urine (if appropriate)
- Has a responsible adult to take them home
- Written and verbal instructions given about postoperative care
- Knows when to come back for follow-up (if appropriate)
- Emergency contact number supplied

Discharge criteria

1. Vital signs stable for at least 1 hour.
2. Correct orientation as to time, place and person.
3. Adequate pain control with supply of oral analgesia.
4. Understands how to use oral analgesia supplied.
5. Ability to dress and walk where appropriate.
6. Minimal nausea, vomiting or dizziness.
7. Has taken oral fluids.
8. Minimal bleeding or wound drainage.
9. Has passed urine (if appropriate).
10. Has a responsible adult to take them home.
11. Written and verbal instructions given about postoperative care.
12. Knows when to come back for follow-up (if appropriate).
13. Emergency contact number supplied.

*****

SUITABLE DAY SURGERY PROCEDURES

General Surgery

Sebaceous cysts, lipoma, breast lumps: excision or biopsy, subcutaneous mastectomy for gynecomastia.

Varicose veins: Ligations, avulsions, stripping

Hernia Repair: Inguinal, femoral, umbilical, epigastric, incisional, (small) toe nail avulsions

Anal Procedures: Banding or injection therapy for hemorrhoids.

Urology

Urethroscopy: Dilation and resection of stenosis.

Cystoscopy: Diagnostic, Resection/ Diathermy of bladder tumour.

Ureteroscopy: insertion of stent, stone breaking or removal procedures.

Circumcision

Varicocele surgery

Orchidectomy

Scrotal lesions: Hydrocele, Spermatocele, vasectomy,

Extracorporeal shock wave lithotripsy (ESWL).

Plastic Surgery

Skin grafting Minor Hand Surgery; Rhinoplasty; Limited liposuction

Orthopedic Surgery

Manipulation under general anesthesia,

Arthroscopy:-knee, elbow, shoulder.

Ganglionectomy,

Carpal tunnel decompression.

Ophthalmic Surgery

Cataract surgery + intraocular lens implant, strabismus correction. Eyelid and lacrimal surgery, vitreoretional surgery, corneal surgery.

Ear, Nose and throat Surgery

Myringoplasty, tympanoplasty, adenoidectomy, laryngoscopy, nasal polyps, nasal fractures.

Oral Surgery

Extraction of deciduous and wisdom teeth, orthodontic treatment.

Gynecological Surgery

Dilatation and curettage: Diagnostic, evacuation of retained products of conception

Termination of pregnancy.

Labial procedures: Bartholin's cysts.

Laparoscopy: for investigation, sterilization, endometriosis

Ovarian cysts.

*****

EXTENDING THE CONCEPT

Extended day Surgery

The principles involved in day surgery could usefully be applied to surgery involving one overnight stay. This would open up the efficiency of the day surgery system to a wider range of cases-so called *23hours surgery* or extended day surgery, those unhappy about performing laparoscopic cholecystectomies, thyroidectomies or mastectomies as day cases for example; may welcome a ward in which patients were admitted on the day of surgery as for day cases and discharged the following day, if appropriate, by day care nurses.

Hospital Hotels

Another method of extending the day case concept has been the introduction of 'Hospital Hotels'. These are typically separate buildings adjacent to the hospital, which provide accommodation for patients, who are mobile and self caring, but who require an over night stay in hospital, often for social reasons.

*****

51 Oncology Cancer Chemotherapy and Radiotherapy

Contents

- Oncogene
- Tumour suppressor genes
- Tumour markers
- Oncogenesis
- Chemotherapy
- Hormone therapy
- Immunotherapy
- Chemotherapeutic regime

Even with newer and advanced treatment for carcinoma management, general surgeon plays an important role in the cancer management, and hence the knowledge of the etiopathogenesis and options of its treatment is necessary for general surgeon.

Oncogenes and tumour suppressor genes

Oncogenes and tumour suppressor genes are defective genes, which in normal forms (proto-oncogene) are involved in control of cell division and apoptosis. When defects occur; they promote cancer genesis by attaining new functions (then called as oncogenes) or by loosing a function; when cells are release from break points (tumour suppressor genes).

RAS gene is a typical oncogene and p53 is a typical tumour suppressor gene.

p53 is a typical example of tumour suppressor gene. It is the most common genetic alteration in human cancers genesis. 70-80% of carcinoma of colon shows p53 alteration. p53 is a gene involved in apoptosis. When DNA damage occurs in a dividing cell, it is detected by p53, then p53 protein makes the cell arrest in the GI-S interphase. Only if DNA repair machinery corrects the DNA error, cells are allowed to pass to S phase. If correction is not possible, cell will be made to undergo programmed cell death. If p53 is defective, such Gl-S arrest and apoptosis will not occur. Even abnormal cells will continue to stay in the system and will divide further leading to cancer. P53 located in chromosome 17 is thus a tumour suppressor gene (ie; loss of function of the gene produce carcinoma).

In other words; tumour suppressor gene is a gene, which in healthy person suppresses the genesis of tumour.

Lie Fraumeni syndrome (abnormal predisposition to cancer) is due to germ line mutation of one allele of p53. So only one p53 allele is active which if later is inactivated by somatic mutation will lead to carcinoma.

Conversion of Proto-Oncogene To Oncogene

Conversion of proto oncogene to oncogene can occur by 4 mechanisms. They are:

1. Proviral insertion -
2. Chromosomal abnormalities
   (a) Translocation
   (b) Deletion
   (c) Insertion
   (d) Loss or gain of whole chromosome
3. Gene amplification
4. Point mutations

*****

TUMOUR MARKERS

Tumour markers are substances that can often be detected in higher than normal amount in blood, urine or body tissues of some patients with certain types of cancer.

Tumour markers are produced either by the tumour itself or by the body in response to the presence of cancer or certain benign conditions.

Uses of tumour markers

1. Diagnosis of cancer: for screening patients
2. To access the extent, stage and tumour bulk
3. To assess the prognosis
4. To assess the response to treatment
5. In follow up of a patient to detect recurrence

Methods of detection of tumour markers

1. *Radioimmunoassay (RIA):* It can detect minute quantities based on structural immunogenic characteristics.
2. *Biochemical assay:* enzymatic assay (as catalysts of reactions or binding to receptors), is less specific
3. *Molecular biologic methods:* tumour markers detected at gene level
4. *Immunohistochemistry:* staining the tumour directly for markers

Qualities of ideal tumour marker

1. Sensitivity
2. Specificity

KEY BOX 51.1

Tumour Marker	Tumour Histology	Nonmalignant condition associated with elevated level
CEA	Colorectal, Gastric, Breast (0-50%), Lung (small cell: 25-50%, non-small cell: 10-20%), Medullary carcinoma thyroid (60-80%) Paget's Disease of breast	Hepatitis, cirrhosis, jaundice, pancreatitis, peptic ulcer disease, renal failure, COPD, IBD
AFP *(AIIMS 09)*	Hepatocellular carcinoma, testicular tumours (non seminoma) Hepatoblastoma	Hepatitis, cirrhosis, pregnancy, IBD
beta HCG	Testicular & gestational trophoblastic tumour	Pregnancy
PSA	Carcinoma of prostate	BPH, biopsy, prostatic massage, instrumentation
CA153	Carcinoma of breast	Hepatitis, cirrhosis, benign breast disease
CA125 *(PGI 07)*	Carcinoma of ovary, Fallopian Tube, Cervix, endomatrium, Breast, Lung, Pancrease, Colon	Pancreatitis, pregnancy, chronic renal failure, Jaundice, PID, Fibroids
NSE	Medullary carcinoma thyroid, small cell lung cancer, neuroendocrine tumours, carcinoid	

KEY BOX 51.2	
Neoplsam	**Established marker**
1. Cataectal Carcinoma	CEA
2. Carcinoma of breast	ER/PR, CA 15-3, BRCA 1 & 2
3. Hepatocellular carcinoma	AFP
4. Non small cell lung cancer	CEA
5. Seminomatous testicular tumor	LDH, aHCG
6. Non-seminomatous testicular tumour	aHCG, AFP
7. Prostatic cancer	PSA
8. Medullary carcinoma of thyroid	Calcitonin
9. Non-mucinous epithelial carcinoma of ovary	CA 125
10. Thyroid cancer (except medullary CA)	Thyroglobulin
11. Pheochromocytoma	Norepinephrine, Epinephrine, VMA, Metanephrine, Catecholamines
12. Pancreatic carcinoma	CA 19-9, CA 242, CA 50
13. Gastrinoma(ZES)	Gastrin
14. Insulinomas	Insuling (fasting)
15. Glucagonomas	Glucagon
16. VIPomas	VIP
17. Adrenal cortex cancer	Cortisol
18. Carcinoids	Serotonin (in urine), 5 HIAA

3. Circulating levels of tumour marker should be directly proportional to amount of viable tumour present
4. Reproducible sensitivity and specificity
5. Widely available at reasonable cost

However no ideal tumour marker with all the above qualities exists.

Short coming of tumour markers

1. Tumour markers may also be elevated in benign disease
2. They are not elevated in every person with cancer, especially in early stages of disease.
3. Many are not specific to a particular type of cancer

Classification of tumour markers

1. Tumour antigens

A. *Oncofetal antigens*

- CEA
- AFP

B. *Monoclonal antibody defined cancer antigens*

(i) CA 125
(ii) CA 15-3
(iii) CA 19-9

C. *Polyclonal antibody*

- PSA
- TPA

2. Cytoskeletal filaments

- CYFRA 21-1 in non small cell carcinoma of the lung. They are circulating FRAgments of CYtokeratin 19 and measured by double antibody sandwich immunoassay.

3. Hormones (measured by RIA or Enzymatic assay)

- beta-HCG
- Calcitonin

KEY BOX 51.3	
Gene	**Tumour**
1. Erb B2	Tumours of breast, oveary, stomach
2. p53	Tumours of lung, breast, colorectal
3. Rb-1	Retinoblastoma, breast cancer
4. C myc	Carcinoma of lung
5. K-ras	Pancreas, lung, kidney, colorectal
6. Ret protoncogene	Medullary carcinoma of thyroid
7. APC	Colorectal tumours
8. N-myc	Neuroblastoma

4. **Serum proteins** (measured by serum electrophoresis)
   - Immunoglobulins (IgM) in myeloma *(PGME)*
5. **Genes that are possible tumour markers** (oncogenes) *(MANY PGME)*
   - *Erb B-2* in carcinoma of breast, colon, kidney etc.*(MANY PGME)*
   - *K- ras* in carcinoma of pancreas, lung, colon, kidney*(MANY PGME)*
   - *Ret proto-oncogene* in medullary carcinoma thyroid. *(MANY PGME)*

Please read key box 51.1, 51.2 & 51.3.

*****

CANCER CHEMOTHERAPY

Chemotherapy is one of the main modalities used in cancer treatment, the others being radiotherapy, surgery and hormonal therapy. Whereas ionizing radiation like X-rays, gamma rays and neutrons are used to treat cancers in radiotherapy; *chemotherapy means use of various anticancer drugs singly or in various combinations for the management of cancers.*

Chemotherapy or anticancer drug therapy is recent addition in cancer cure from the experience of world war-II, Nitrogen mustard (mustine) was the first chemotherapeutic agent introduced in 1941 for lymphoma. The field of medical oncology has come a long way since then and an array of agents are available today.

Modern day chemotherapy came into existence around half a century back. Presently it is being used as a systemic therapy for disseminated as well as localized disease.

The development of new anticancer drugs was started in 1950's and the process is still going on. The research in drug development and development of chemotherapy regimens is key to discipline of medical oncology.

Clinical Application of Chemotherapy

Chemotherapy is not the only modality in cancer care and is usually used in conjunction with other modalities; namely surgery and radiotherapy in a prescribed cyclic way. Chemotherapy can be used to treat cancer in following pattern:-

1. Neoadjuvant chemotherapy

When% disease is low grade, regionally advanced or if there is potential systemic spread, *chemotherapy is initiated as first line therapy to main modality of treatment,* variously termed as **induction or anterior chemotherapy.** This ensures better drug delivery and better tumour reduction along with allowance of maximum drug administration.

This helps ia ***down staging*** the tumour and helping in organ preservation in tumours like esophagus, breast, bladder, anal canal and larynx. It also enhances tumour oxygenation thus enhancing radiation effect used in radiotherapy on tumour. The drawbacks of induction chemotherapy includes:-

(a) Delay in primary mode

(b) Difficulty in administration of primary modality if toxicity is greater.

(c) The tumour can progress; if the chemotherapy is ineffective for the tumour.

2. Adjuvant chemotherapy

This is given when the disease is localized and is been controlled primarily by other therapeutic modality, namely surgery or radiotherapy. The rationale of adjuvant chemotherapy is to control the occurrence of recurrence, lymph node or distant metastasis. This reduces the low regional relapse rate. This form of therapy is given to reduce the incidence of systemic micrometastasis & thereby increases the possibility of disease free and overall survival. *Here the burden of tumour is reduced by primary modality (eg; surgery or radiotherapy) to subclinical level and the antineoplastic agents (chemotherapy) are effective in eradicating the microscopic disease.* Examples are Ca breast, Osteogenic sarcoma, Colorectal carcinoma and STS (soft tissue sarcoma) *(AIIMS 06, MANY PGMEE)*

3. Primary chemotherapy

When the goal of chemotherapy institution is curative, it is termed as primary chemotherapy. *It is used in chemosensitive tumors like lymphomas, leukemias, choriocarcinoma,and non saminomatous germ cell tumors.* Currently chemotherapy delivered as a curative approach in usually consisting of combination of several drugs and also combination of two or more regimens. Combination chemotherapy may provide greater efficacy than single agent therapy by three mechanism- (1) It provide maximum single cell kill within the range of toxicity

for each drug that can' be tolerated by the host, (2) It offers a broader range of coverage of resistant cell lines in a heterogeneous population and (3) it prevents or delays the emergence of drug resistant cell lines.

4. Concomitant chemo-radiotherapy

The main rationale *for this strategy is utilization of radiation and chemotherapy interaction.* Generally drug combination believed to have radiation enhancing properties are utilized in this approach and are term as **radiosensitizers** eg; hydroxyurea, 5FU, cisplatin, metrogyl. However some drugs while enhancing the radiation effects leads to enhanced cutaneous and increased toxicities. eg; actinomycin C, Adria, Mitomycin-C. *Simultaneous chemoradiation is given to improve local control as well as to reduce the incidence of distant metastasis.* This modality has given encouraging effects in cancers of head and neck, esophagus and anal canal and cervix (with hydroxyurea). This approach is also been as an alternative to the traditional surgery and radiotherapy combination in advanced laryngeal cancers.

5. Concomitant chemosurgery

This modality is used to check the spread of micrometastasis is peritoneum following cancers of ovary, gall bladder etc. and in tumours that are richly supplied by arterial blood.

6. Salvage chemotherapy

Here the objective of chemotherapy is salvation of recurrent disease after failure of primary modalities. This requires good performance status of patient, reasonable life expectancy and chemosensitive nature of neoplasm like germ cell tumours, lymphomas, leukemias, in specific cases of breast, colon, rectum and ovarian carcinoma. Here the final goal is to improve the quality of life by tumour reduction

Drug resistance is one of the most important hurdle in usage of chemotherapy; the other being myelosuppression, anemia and dose related toxicities, while all other problems can be overcome by selected procedures the drug resistance is hard to manage. It can be divided as:

1. *Innate:* where the tumour don't show any response from the beginning of therapy eg; as in most of solid tumours
2. *Acquired:* here initially the response is present but later on resistance is developed.

KEY BOX 51.4

Neoadjuvant chemotherapy: whenchemotherapy is given before surgery/radiotherapy.

Concomitant chemotherapy: when chemotherapry is given at the time of surgery/radiotherapy.

Adjuvant chemotherapy: when chemotherapy is given after surgery/radiotherapy

Primary Chemotherapy [Neoplasms for which chemotherapy is the primary treatment modality]
Non Hodgkin's lymphoma
Lymphoblastic lymphoma
Burkitt's lymphoma
Hodgbkin's lymphoma
Prmary central nervous system lymphoma
Wilm's tumour
Embryonal rhabdomyosarcoma
Small cell lung cancer

Primary Chemotherapy [Neoplasms for which there is an expanding role of primary chemotherapy for advanced diseaes]
Bladder cancer
Breast cancer
Cervical cancer
Esophageal cancer
Gastric cancer
Head and neck cancer
Nasopharyngeal cancer
Non small cell lung cancer
Ovarian cancer
Pancreatic cancer
Prostate cancer

Neoadjuvant chemotherapy: [Neoplasms for which Neoadjuvant chemotherapy is indicated for locally advanced disease]
Anal cance
Bladder cancer
Breast cancer
Esophageal cancer
Head and neck cancer
Gastric cancer
Osteogenic sarcoma
Rectal cancer *[AIIMS NOV 06]*
Soft tissue sarcoma

Adjuvant chemotherapy: {Neoplasms for which adjuvant therapy is indicated after surgery]
Anaplastic astrocytoma
Breast cancer
Colorectal cancer *(AIIMS NOV 06)*
Gastric cancer
Malignant melanoma
Non small cell lung cancer
Osteogenic sarcoma

FIFTY ONE

CLINICAL APPLICATION OF CHEMOTHERAPY

Chemotherapy is presently used in four main clinical settings.

- **Primary induction** treatment for advanced disease or for cancers for which there are no other effective treatment approaches.
- **Neoadjuvant treatment** for patients with localized disease for which local forms of therapy such as surgery or radiation or both are inadequate by themselves.
- **Adjuvant treatment** to local methods of treatment, including surgery or radiation therapy or both.
- **Direct instillation** into sanctuary sites or site directed perfusion of specific regions of the body directly affected by the cancer.

*****

CLASSIFICATION OF CHEMOTHERAPEUTIC AGENT

Chemotherapeutic agents can be classified according to the phase of the cell cycle at which they are effective. Nonspecific agents (eg; alkylating agents, antibiotics) have a linear dose response curve, such that the fraction of cells killed increases with dose of the drugs. In contrast, the cell cycle phase- specific drugs have a plateau with respect to cell killing ability and cell kill will not increase with further increases in drag dose. The Chemotherapeutic agents are classified as following:

A. Alkylating Agent

These compounds produce highly reactive carbonium into intermediates which transfer alkyl groups to cellular macromolecules by forming covalent bonds. Various alkylating agents are:-

Mechlorethamine

It is first nitrogen mustard and is .highly reactive. It can be given only by IV route. Main side effects are nausea, vomiting and hemodynamic changes.

Dose - 6mg/m^2 IV day I and VIII.

Cyclophosphamide

It is most popular anticancer drugs. It is inactive as such, and is not locally damaging. It is less damaging to platelet, but alopecia and cystitis (due to *acrolein metabolite}* are prominent (MANY PGME). MESNA protect this side effect.

Dose - 400-2000 mg/m^2 IV

Ifosfamide

Congener of cyclophosphamide with a longer and dose dependent t½ has found utility in bronchogenic, breast, testicular, bladder, head and neck carcinoma, osteogenic sarcoma. Hemorrhagic cystitis is common. It causes less alopecia and is less emetogenic.

Dose - 1.2g/m^2/day × 5 day.

Chlorambucil

It largely spares myeloid tissue. It is drug of choice for long term maintenance treatment for chronic lymphatic leukemia (CML), Hodgkin's disease and some solid tumours. It also has some immunosuppressant property.

Dose - l-3mg/m^2

Melphalan

It is very effective in multiple myeloma. *Bone marrow depression in most important toxicity.* Diarrhea & pancreatitis are the other complication.

Dose - 8mg/m^2 /d × 5

Busulphan

It is highly effective for myeloid elements (granulocytes precursors being most sensitive) followed by platelets, RBC. It produces little effect on lymphoid tissue. Hyperuricemia is common and *pulmonary fibrosis is specific adverse effect.* Sterility can also occur. *It is DOC for chronic myeloid leukemia.* (MANY PGME)

Nitrosourea

These are highly lipid soluble alkylating agent with a wide range of antitumour activity. *They cross blood brain barrier and are effective in meningeal leukemia and brain tumour* (MANY PGME). Visceral fibrosis and renal damage may occur. Various drugs used are:-

Carmustine - 50-200mg/m^2 every 6wk

Lomustine - 100-130mg/m^2 single oral dose every 6 weeks

Semustine - 100-200 mg/m^2 single oral dose every 6 weeks.

Dacarbazine

Primarily have inhibitory action on RNA and protein synthesis. It's most important indication is malignant myeloma.

B. Antibiotics

Practically all of them intercalate between DNA strand and interfere with the template function.

Actinomycin D (Dactinomycin)

It is highly efficacious in Wilm's tumour and rhabdomyo-sarcoma. It has also produced good result in MTX resistant choriocarcinoma.

Dose: 15mg/kg IV daily for 5 days

Daunorubicin (Rubidomycin), Doxorubicin

They are capable of causing breaks in DNA strands by activating topoisomerase II and generates quinone type free radicals. They have mutagenic and carcinogenic potentials. Maximum action in exerted at S phase.

Both these antibiotics produce ***cardiotoxicity*** as a unique adverse effect *(MANY PGME)*

Dose: Daunorubicin - 30-60mg/m^2 IV daily for 3 days; repeat weekly.

Doxorubicin - 60-75mg/m^2 slow IV every 3 wk.

Mitoxantrone

It is a recently introduced analogue of doxorubicin with lower cardiotoxicity. It has narrow range of utility in acute non hemolytic leukemia, CML, NHL, Ca breast.

Major toxicity: It causes bone marrow depression and mucosal inflammation.

Dose - 12mg/m^2 single IV dose repeat at 3 wks.

Bleomycin

This is a mixture of closely related glycopeptide antibiotics having potent antitumour activity. It chelates iron or copper & produces superoxides ions that intercalates between DNA strands; inhibiting repair. It is highly effective in testicular tumour and SCC of skin, head and neck, genitourinary track and esophageal cancer and is also useful in Hodkgin's disease.

Chief side effects are:- mucocutaneous toxicity and pulmonary fibrosis, but has little myelosuppression which is a special feature. *Dose* - 15-25mg/d × 5 days IV bolus continuous infusion.

Mitomycin C

It is highly toxic drug; which is used only in resistant cancers of stomach, cervix, colon, rectum, bladder etc. It is transformed intracellularly to a form which acts as an alkylating agent and kills cells in G_1-M phases. Bone marrow and GIT are primary targets of toxicity.

Dose -2-10 mg/m^2

Mithramycin (Plicamycin)

It is highly toxic drug and it's use is restricted to embryonal testicular tumour, disseminated cancers; specially those with bony metastasis and hypercalcaemia. *It reduces serum Ca level by direct action on bone inhibiting calcium release.* *(MANY PGME)*

Dose: 25mg/kg by slow IV infusion daily or an alternate days (8-10 doses)

Etoposide

It binds directly to topoisomerase II and causes a prominent G2 arrest. Main side effects in myelosuppression, transient hypotension related to the speed of administration of the agent but largely free from large organ toxicity.

Dose: 100-150mg/m^2 IV × 5 day.

C. Antimetabolites

Folate antagonist (Methotrexate = MTx)

They Inhibits dihydrofolate reductase by blocking the conversion of dihydrofolate to tetra hydrofolic acid; which is an essential coenzyme required for a carbon transfer reactions in denovo purine synthesis and amino acid inter conversion.

Major toxicity is on bone marrow, causing megaloblastic anemia and at higher dose pancytopenia. ***Folinic acid***; a thymidine counteract toxicity *(PGME)*. Mtx is apparently curative in choriocarcinoma -15-30mg/day for 5 day, orally or 20-40mg/m^2 BSA IM or IV twice weekly.

It is highly effective in maintaining remission in children with acute leukemia. It is also useful in other malignancy, psoriasis and as immunosuppressant.

Purine antagonist

Mercatopurine (6MP) and Thioguanine (6TG) are highly effective anticancer drugs.

They are useful in childhood acute leukemia, choricarcinoma and in some solid tumours.

Azathioprine has marked effect on T-lymphocytes, presses cell mediated immunity and is used primarily as immunosuppressant in organ transplantation, rheumatoid arthritis. All antipurine are absorbed orally. Main toxic effect is bone marrow depression.

Dose: 6MP - 75mg/m^2 PO

6TG - 2-3mg/kg/day for upto 3-4 wks

Azathioprine - l-5mg/kg/day

Pyrimidine antagonists

5-Fluro-uracil (5 FU)

It is converted in body to the corresponding nucleotide 5-fluro-2 deoxyuridine monophosphate which inhibits thymidylate synthetase and blocks the conversion of deoxyuridilic to doxythymidylate acid. Selective failure of DNA synthesis occur due to non availability of thymidylite. Thymidase can partially reverse its toxicity. It is particularly used for solid tumours of breast, colon, urinary bladder, liver etc. Topical application is useful in cutaneous basal cell carcinoma.

Dose: 375 mg/m^2 IVgd × 5 day

Cytosine arabinoside

It is phosphorylated in body to corresponding nucleotide which inhibits DNA synthesis. Triphosphate of cytarabine in an inhibitor of DNA polymerase and block generation of cytidilic acid. It also interfere with DNA repair. It is cell cycle specific and acts primarily during S phase. Main use in to induce remission in acute leukemia in children. Other use is in Hodgkin's and non Hodgkin's lymphoma.

Dose: 100mg/m^2 9d × 7

Fludarabine phosphate

Fludarabine phosphate is a pro drug of F-ara A, which in turn was designed to diminish the susceptibility of ara A to adenosine deaminase. Ara A is incorporated into DNA and can cause delayed cytotoxicity even in cell with low growth fraction including chronic lymphocytic leukemia and folli-cular B cell lymphoma.

D. Vinca alkaloids

Vincristine

It is very useful in childhood acute leukemia. Other indications are lymphosarcoma, Hodgkin's disease, Wilm's tumour, Ewing's sarcoma, Carcinoma lung. Main adverse effects are peripheral neuropathy and alopecia. Bone marrow depression is minimal.

Dose - l-1.4mg/m^2/wk

Vinblastin

Primarily employed with other drugs in Hodgkin's disease and testicular carcinoma. Bone marrow depression is more prominent while neurotoxicity and alopecia are less.

Dose: 6-8mg/m^2/wk

E. Taxanes

Paclitaxel

It exerts cytotoxic action by enhancing polymerization of tubulin. Microtubule are stabilized and depolymerization is prevented. This stability results in inhibition of normal dynamic recognization of microtubule network; that is essential for vital interphase and mitotic function.

It is mainly used in metastatic ovarian and breast carcinoma after failure of first line chemotherapy and has also shown efficacy in advance malignancy of head and neck, small cell lung cancer, esophageal adenocarcinoma, hormone refractory prostatic cancer.

Major toxicity is reverssible myelosuppression and stocking and glove type neuropathy.

Dose - 135-175 mg/m^2/day

F. Miscellaneous Cytotoxic Drugs

Hydroxyurea

It blocks the conversion of ribonucleotides to deoxyribo-nucleotides by *inhibiting the enzyme ribonudeoside diphosphate reductase* thus interfere with DNA synthesis. It's primary therapeutic value is in CML, PCV and in some solid tumours. Myelosuppression is major toxicity.

Dose - 20-30mg/kg daily or 80 mg/kg twice weeks

Procabazine

After activation procarbazine, depolymerizes DNA and causes chromosomal damage. Inhibition of nucleic acid synthesis also occurs. Procarbazine is a component of popular MOPP regimen for Hodgkin's disease. It is also useful in NHL and oat cell carcinoma of lung.

Dose - 100-300mg oral daily

L-Asperginase

Many typical adverse effects of anticancer drugs are not seen with L-Aspargine, however it produces liver damage, **pancreatitis** and CNS symptoms. *(MANY PGME)*

Dose - 25000IV/m^2 every 3-4 wks

Cisplatin

Cisplatin is very effective in metastatic testicular and ovarian carcinoma. It is highly reactive drug. The most important toxicity in renal impairment which is dependent on total dose administered. This can be reduced by maintaining good hydration.

Tinnitus, deafness, neuropathy and hyperuricemia are other problem.

Dose - 50-100 mg/m^2 BSA every 3-4 wks

Carboplatine

Mainly indicated in ovarian carcinoma of epithelial origin and has shown promise in squamous carcinoma of head and neck, squamous cell carcinoma of lung and as second line drug in seminomas. Nephrotoxicity, ototoxicity and neurotoxicity are low. Nausea and vomiting in milder and delayed dose limiting toxicity is thrombocytopenia and less often leucopenia

Dose - 400mg/m^2 IV infusion over 15-60 min every 4 weeks.

Newer Chemotherapeutic Agents

Imp. topic; you may get questions from this section in *(AIIMS/AI & PGI)*

1. **Nab paclitaxel:** It is novel taxane that combines paclitaxel with albumin into a nano particle 1/100 of the size of RBC. It is in phase III trial in treatment of metastasis breast cancer.
2. **Gemcitabine:** It is a pyrimidine analogue for IV use. It has been approved to treat pancreatic and nonsmall cell lung cancer. *(AIIMS, AI)*
3. **Oxaliplatin:** It is a platinum based compound and in randomized control trial has show efficacy in treating metastatic colorectal caner in combination with fluorouracil and leucovorin.
4. **Tamzolemide:** It is an oral alkylating agent with the very unusual property of excellent CNS penetration. It is useful in treating primary brain tumour, and is also being tested in metastatic brain tumours with encouraging results.
5. **Pemetrexed and Raltitrexed:** Novel inhibitors of thymidylate synthetase are under study for treatment of advanced colorectal carcinoma. Pemetrexed show improved results in malignant mesothelioma in combination with cisplatin.
6. **Antibodies linked to cytotoxic agents or radiation**
   (a) *Ibritumonab tiuxetan:* is an Yttrium 90 labelled antibody to CD20 that is approved by FDA for treatment of low grade non Hodgkin's lymphoma refractory to rituximab, or transformed B cell non Hodgkin's lymphoma.
   (b) *Tositumonab:* Linked to I^{131}; recently approved for the treatment of low grade non Hodgkin's lymphoma refractory to rituxan.
   (c) *Denileukin diftitox* (ONTAK): a recombinant DNA derived cytotoxic protein composed of amino acid sequences from diphtheria toxin fragment followed by sequence for IL-2. It has been approved for the treatment of cutaneous T cell lymphoma.
   (d) *Gemtuzumab ozoyamicin:* antibody to CD 33 linked to a potent antitumour antibiotic. Calicheamicin is approved for treatment of patient over the age of 60 years with relapsed or refractory acute myelocytic leukemia.
7. **Thalidomide** has been found to induce significant responses in advanced and relapsed multiple myeloma.
8. **Revlimid:** a lead compound, effect multiple pathway within cell and inhibit TNF-oc. Preliminary data indicates effectiveness in multiple myeloma and myelodysplastic syndromes.
9. **Bortezomib (velcade):** is a first of new class of agents, termed proteosome inhibitors. It is approved for treatment of multiple myeloma that progresses despite at least two prior therapies.

10. **Bexarotane:** It is a retinoid; which selectively activates retinoid X receptor (RXR) and is now FDA approved to treat cutaneous T cell lymphoma; such as mycosis fungoides.
11. **Oral small molecule tyrosine kinase inhibitors**

    (a) **Imitinib mesylate**: approved for clinical use in both early and late stage CML. Also being tested in conditions like myelofibrosis, chronic myelomonocytic leukemia, prostatic cancer and glioblastoma.

    (b) **Geftinib:** It is recently approved to treat advanced lung cancer that progress after at least two prior chemotherapy regimen.

*****

HORMONAL THERAPY

They are not cytotoxic but modify the growth of hormone dependent tumours.

Glucocorticoids

- They have lympholytic action and are primarily used in acute childhood leukemia and lymphomas. They induce remission rapidly but relapses inevitably occur after variable intervals and gradually responsiveness is lost.
- Considerable palliative effects are obtained in Hodgkin's disease and they have a secondary role in some hormone responsive breast cancers.
- They are also valuable for control of complications like hypercalcemia, hemolysis, bleeding due to thrombocy-topenia and increase ICT, mediastinal edema after radiotherapy.
- Moreover they afford symptomatic relief by; antipyretic and mood elevating action and potentiate antiemetic action of ondensetron/metochlopramide.

Estrogens

They produce highly gratifying results in Ca prostate; which is an androgen dependent tumour. However relapses eventually occur, an hormone dependence is gradually lost, but life is prolonged.

Some breast cancers have estrogen receptors on their cells. These respond to estrogen /anti-estrogen regimens. Estrogens should be employed only in women who are >5 years postmenopausal and have become nonresponsive to tamoxifen (anti-estrogen).

Antiestrogen (Tamoxifen)

It is effective in estrogen receptor containing breast cancer in both pre as well as postmenopausal women, response is better in the older age group. It is first line drug for palliative treatment of Ca breast.

Androgen

Used as a secondary palliative measure in perimenopausal women with Ca breast generally after using tamoxifen.

Progestin

They bring about temporary remission in some cases of advanced/recurrent metastatic endometrial carcinoma. High doses are needed.

They have also been used in palliative treatment of metastatic breast carcinoma; that has been become unresponsive to tamoxifen.

Luteinizing Hormones Releasing Hormones Agonist

In prostatic carcinoma; when orchidectomy (which provides surgical hormone ablation) is not accepted by patient; then testicular androgen suppression can achieved by LHRH agonist such as:- **leuprolide and goserelin** *(PGME)*. These agents cause tonic stimulation of CHRH receptor, with the loss of its normal pulsatile activation resulting in its desensi-tization and decreased output by the anterior pituitary. Therefore, as primary hormonal manipulation in prostate cancer one can choose orchidectomy or leuprolide; but not both.

Aminoglutathemide & Ketoconazol

It can be used to block adrenal synthesis by interfering with enzymes of steroid metabolism. It is most commonly used in refractory breast and prostatic carcinoma.

Anastrazol and Letrozol: act by inhibition of aromatase enzymes used in tumours having steroid inducing aromatase activity.

Mitotane: Adrenocorticoid carcinoma can cause Gushing syndrome as well as syndromes of androgen and estrogen excess. Mitotane can counteract these by decreasing synthesis of steroid hormone.

***Octreotide*:** Islet cell neoplasm can cause debilitating diarrhea, treated with somatostatin analogue octreotide.

***Bromocriptine*:** Prolactin secretary tumours can be effectively managed by dopaminergic agonist; like bromocriptine (IMP. POINT).

Monoclonal antibodies: Monoclonal antibodies work by targeting tumour specific antigens, thus enhancing the host's immune response to tumour cells to which the agent attaches itself. *Examples are trastuzumab (Herceptin), Cetuximab, Bevacizumab and Rituximab (Rituxan).* (IMP)

*****

IMMUNOTHERAPY

The aim of immunotherapy is to induce or potentiate inherent antitumour immunity that can destroy cancer cells. Central to the process of antitumour immunity is the ability of the immune system to recognize tumour associated antigens present on human cancers and to direct cytotoxic responses through humoral or T cell mediated immunity. Overall, T-cell mediated immunity appears to have the greater potential among the two for eradicating tumour cells. T cells recognize antigens on the surfaces of target cells as small peptides presented by class I and class II major histo-compatibility complex (MHC) molecules.

Routes of Administration

The chemotherapeutic agents can be given by following routes.

1. **Intravenous:** Most commonly and largely used in most of the cases.
2. **Oral:** Drugs like etoposide, methotrexate, ondensetron, hormonal drugs, eg; Temozolamide, procarbazine and steroids are available in oral formulation also. Xeloda is an oral 5Fu, now available in market.
3. **Intrathecal** - Methotrexate is used for leukemic conditions.
4. **Intraperitoneal** - Drugs like cisplatin, adria, thiotepa and paclitaxel are used by this route.
5. **Intravesicle** - Drugs like BCG are used in cases of urinary bladder malignancies.

*****

Newer and Experimental Approaches

Hematopoietic stem cell transplant approach

Stem cell harvesting and autologous or allogeneic stem cell transplant has been used to allow for higher doses of chemotherapeutic agents, where dosages are primarily limited by hematopoietic damage. Years of research in treating solid tumours, particularly breast cancer with hematopoietic stem cell transplants has yielded little proof of efficacy. Hemato-logical malignancies such as myeloma, lymphoma and leukemia remain the main indications for stem cell transplants.

Isolated infusion approaches

Isolated limb perfusion (often used in melanoma) or isolated infusion of chemotherapy into the liver or the lung have been used to treat some tumours. The main purpose of these approaches is to deliver a very high dose of chemotherapy to tumour sites; without causing overwhelming systemic damage. (Unfortunately, while these approaches can be useful against solitary or limited metastases, they are - by definition - not systemic and therefore do not treat metastases or micrometastases).

Specially targeted delivery mechanisms toward higher effective doses and reduced toxicity

This means specially targeted delivery vehicles aim to increase effective levels of chemotherapy for tumour cells while reducing effective levels for other cells. This should result in an increased tumour kill and/or reduced toxicity.

Specially targeted delivery vehicles have a differentially higher affinity for tumour cells by interacting with tumour specific or tumour associated antigens.

Specially targeted delivery vehicles vary in their stability, selectivity and choice of target, but in essence they all aim to increase the maximum effective dose that can be delivered to the tumour cells. Reduced systemic toxicity means that they can also be used in sicker patients, and that they can carry new chemotherapeutic agents that would have been far too toxic to deliver via traditional systemic approaches. Few examples of specially targeted delivery mechanisms are:

Nanoparticles

Nanoparticles have emerged as a useful vehicle for poorly-soluble agents such as paclitaxel. Abraxane; also

known as nab-paclitaxel, was approved by the US FDA in January 2005 for the treatment of refractory breast cancer, and allows reduced use of the cremophor vehicle usually found in paclitaxel.

Minicells

Bacterially-derived minicells are a new approach to selectively-delivering chemotherapy to target tumour cells, awaiting research trials in human subjects.

*****

RADIOTHERAPY

Radiation therapy (or radiotherapy) is the medical use of ionizing radiation as part of cancer treatment to control malignant cells. (It should not to be confused with radiology, the use of radiation in medical imaging and diagnosis).

Radiotherapy is the use of X-rays and similar rays to treat disease.

Since the discovery of X-rays over one hundred years ago, radiation has been used more in medicine, both to help with diagnosis (by taking pictures with X-rays) and as a treatment (radiotherapy). While radiation obviously has to be used very carefully.

Many people with cancer will have radiotherapy as part of their treatment. This can be given either as external radiotherapy from outside the body using x-rays; called as **teletherapy** or from within the body as internal radiotherapy; also called as **brachytherapy**. Radiotherapy works by destroying the cancer cells in the treated area. Although normal cells are also sometimes damaged by the radiotherapy, they can repair themselves.

Radiotherapy may be used for curative or adjuvant cancer treatment. It is used as palliative treatment (where cure is not possible and the aim is for local disease control for symptomatic *relief)* or as therapeutic treatment (where the therapy has survival benefit but is not curative).

Radiotherapy is commonly used for the treatment of malignant tumours and may be used as the primary therapy. It is also common to combine radiotherapy with surgery, chemotherapy, hormone therapy or some mixture of the three. Most common cancer types can be treated with radiotherapy in some way. The precise treatment intent (curative, adjuvant, neoadjuvant, therapeutic, or palliative) will depend on the tumour type, location and stage, as well as the general health of the patient.

Radiation therapy is commonly applied to the tumour. The radiation fields may also include the draining lymph nodes if they are clinically or radiologically involved with tumour, or if there is malignant spread. It is necessary to include a margin of normal tissue around the tumour.

To spare normal tissues (such as skin or organs which radiation must pass through in order to treat the tumour), shaped radiation beams are aimed from several angles of exposure to intersect at the tumour, providing a much larger absorbed dose there than in the surrounding

Radiotherapy has a few applications in nonmalignant conditions, such as the treatment of trigeminal neuralgia, severe thyroid eye disease, pterygium, prevention of keloid scar growth and prevention of heterotopic ossification. The use of radiotherapy in nonmalignant conditions is limited partly by worries about the risk of radiation- induced cancers.

Type of Radiation Therapy

Historically, the two main divisions of radiotherapy are:

(i) External beam radiotherapy (EBRT or XBRT) or Tele-therapy

(ii) Brachytherapy or Internal radiotherapy

The differences between these depends on the position of the radiation source, viz; external is outside the body, while in brachytherapy the source is placed in the body itself or is very close to body.

Radiation therapy is the use of a type of energy, called ionizing radiation and kill cancer cells and shrink tumour. Unlike external beam radiotherapy (teletherapy), in which high energy X-ray beams generated by a machine are directed at the tumour from outside the body, brachytherapy involves placement of radioactive material in side the body. Common tumours treated by brachytherapy are:-Prostate, Cervix, Head & neck, Ovary, Breast, Gallbladder, Uterus, Vagina.

Brachytherapy may be either temporary or permanent.

In temporary brachytherapy, the radioactive material is placed inside or near a tumour for a specific amount of time and then withdrawn. Permanent brachytherapy, also called as seed implantation, involves placing a radioactive seed or pellets (about the size of a rice grain) in

or near the tumour and leaving them there permanently. After several weeks or months, the radioactivity level of implants eventually diminishes to nothing. The seeds then remain in the body; with no lasting effects on the patient.

Side Effects

Radiation Therapy is in itself painless. Many low-dose palliative treatments (for example, radiotherapy to bony metastases) cause minimal or no side effects. Treatment at higher doses causes varying side effects during treatment called as acute side effects. In the months or years following treatment, long- term side effects develop or after re-treatment; cumulative side effects develop. The nature, severity and longevity of side effects depends on the organs that receive the radiation, the treatment itself ie; type of radiation dose, fractionation, concurrent chemotherapy and the patient.

Most side effects are predictable and expected. One of the aims of modern radiotherapy is to reduce side effects to a minimum, and to help the patient to understand and to deal with those side effects which are unavoidable.

A. Acute side effects

- Epithelial damage
- Edema
- Infertility
- Generalized fatigue

B. Medium and long-term side effects

These depend on the tissue that received the treatment; they may be minimal. Some of them are:-

- Fibrosis
- Hair loss
- Dryness
- Cancer

C. Cumulative side effects

Cumulative effects from this process should not be confused with long-term effects- When short-term effects have disappeared and long-term effects are subclinical, re-irradiation can still be problematic.

Dose

The choice of total dose and dose fractionation is a complex process and involves consideration of tumour size, histological type, anatomical site, conditions of the normal surrounding tissues, presence of diseased processes associated with radiation sensitivity and to determine the fact of administering radiotherapy alone or in combination with surgery and chemotherapy.

The biological effect of radiation is principally due to the ionization produced in critical molecules, particularly DNA. DNA is essential for cell survival and the impact of radiation induced changes in degree of damage inflicted. The unit of radiation is Gray [Gy]. 1 Gy is define as absorption of 10,000 ergs/gm of the irradiated material. In other words, 1 Gray = 100 rads [rad = Radiation Absorption dose].

Tumours, which are sensitive to radiation are known as radiosensitive and where radiotherapy does not provide effective tumour ablation (destruction); these tumours are named as radioresistant. The radiation sensitivity can be modified by improving the oxygen tension and by combination of radiation with chemotherapy.

*****

Radioisotope Therapy (RIT)

Radiotherapy can also be delivered through infusion (into the bloodstream) or ingestion. Examples are the infusion of metaiodobenzylguanidine (MIBG) to treat neuroblastoma, of oral iodine-131 to treat thyroid cancer or thyrotoxicosis, and of hormone-bound lutetium-177 and yttrium-90 to treat neuroendocrine tumours (peptide receptor radionuclide therapy). Another example is the injection of radioactive glass or resin microspheres into the hepatic artery to radioembolize liver tumours or liver metastases.

In 2002 the united states Food and drug administration (FDA) approved **Ibritumomab tiuxetan** (zevalin), which is a monoclonal antibody, anti-CD20 conjugated to a molecule of Yttrium-90. In 2003, the FDA approved Tositumomab Iodine-131 (Boxxar), which conjugates a molecule of Iodine- 131 to the monoclonal antibody anti-CD20. These medications were the first agents of what is known as **radiommunotherapy,** and they were approved for the treatment of refractory non- Hodgkins lymphoma. Uranium-235 is also used in radiotherapy recently to treat some diseases.

COMMONLY USED CHEMOTHERAPY SCHEDULES IN ONCOLOGY

LYMPHOMAS

HODGKIN'S DISEASE

1. MOPP/COPP

Mustine	- 6 mg/m^2	I/V D1 & D8	At every 4 weeks × 6 cycles
Vincristine (Oncovorin)	-1.4mg/m^2	I/V D1 & D8	
Procarbazine	-100 mg/m^2	Oral D1-D14	
Prednisolone	-40 mg/m^2	Oral D1-D14	

In COPP- Cyclophosphamide (Endoxan in place of Mustine) -300 mg/m^2 I/V D1 & D8 is used instead of Mustine

2. ABVD

Adriamycin	- 25 mg/m^2	I/V D1 & D15	At every 4 weeks × 6 cycles
Bleomycin	-10 units/m^2	I/V D1 & D15	
Vinblastin	- 6 mg/m^2	I/V D1 & D15	
Decarbazine	- 375 mg/m^2	I/V D1 & D15	

NONHODGKIN'S LYMPHOMA (NHL)

1. CHOP (For High grade NHL)

Cyclophosphamide (CTX)	-750 mg/m^2	I/V D1	At every × 6 cycles
Doxorubicn (ADR)	-50 mg/m^2	I/V D1	
Oncovorine (Vincristine)	-1.4 mg/m^2	I/V D1	
Prednisolone (PDN)	-50 mg/m^2	Oral D1-D5	

2. COP (For low grade NHL)

Cyclophosphamide	-750 mg/m^2	I/V D1-D8	At every 4 weeks × 6 cycles
Oncovorine (Vincristine)	-1.4 mg/m^2	I/V D1-D8	
Prednisolone (PDN)	- 40 mg/m^2	Oral D1, D8	

D = on day, eg; DI = on day 1, D8 = on day 8.

CARCINOMA BREAST

1. CMF

Cyclophosphamide (CTX)	- 600 mg/m^2	I/V D1-D8	Every 3 weeks × 6 cycles
Methotrexate (MIX)	- 40 mg/m^2	I/V D1 & D8	
5 FluoroUracil (5 Fu)	- 600 mg/m^2	I/V D1 & D8	

2. FAC

5 Fluorouracil (5 Fu)	- 600 mg/m^2	I/V D1, D8	Every 21 days × 6 cycles
Doxorubicin (Adriamycin ADR)	- 50 mg/m^2	I/V D1	
Cyclophosphamide	- 600 mg/m^2	I/V D1	

TESTICULAR TUMOURS

1. BEP

Bleomycin	- 30 units	I/V, D2, D9 & D16	Every 3 week × 6 cycles
Etoposide(VP-16)	- 100 mg/m^2	I/V-D1-D5	
Cisplatin	-20 mg/m^2	I/V D1-D5	

2nd line chemotherapy

2. V.I.P

Etoposide (VP-16)	-100 mg/m^2	I/V/day D1-D5	
Ifosphamide (holoxan with mesna)	-1.2 mg/m^2	I/V/day D1-D5	Every 3 weeks
Cisplatin	-20 mg/m^2	I/V/day D1-D5	

NOTE: Mesna is not an antitumour drug, it is added to check, hemorrhage cystic caused by Ifosphamide.

Ca. Ovary

Epithelial Tumours

Cisplatin and Endoxan

Cisplatin	- 70 or 100 mg/m^2	as divided doses in 2-3 days	
Cyclophosphamide (Endoxan)	- 650 mg/m^2/	I/V on D1	

2nd line chemotherapy

Taxol & Carboplatin

Taxol	- 135mg/m^2	I/VD1	Every 21 days × 6 cycles
Carboplatin	- 450-600mg/m^2		

GIT TUMOURS

Carcinoma esophagus

(Cisplatin + 5 Fu)

Cisplatin	- 70 mg/m^2 in 2 divided dose	Every 3 weeks
5Fu	- 650 mg/m^2 in 2 divided doses	

CA Stomach

(Options)

1. 5 Fu and Calcium Leucovorin

5 Flurouracil (5 Fu)	- 400 mg/m^2 I/V	Every 4 week D1-D5 6 months
Leucovorin	- 20mg/m^2 I/VDI-D5	

2. F.A.M

5 Flurouracil (5 Fu)	- 750 mg/$m^2$1/V DI, D8, D29, D36	Repeated every 21 days × 6 months
Adriamycin	- 30mg/m^2I/VDI	
Mitomycin	- 10mg/m^2I/VDI	

3. E.A.P

Etoposide(VP16)	- 100 mg/m^2 D1,D3	} Every 21 days × 6 cycles
Adriamycin	- 50 mg/m^2 DI	
Cis Platin	- 70 mg/m^2 DI	

Ca Colon

1. 5 Fu and Levamisole

(Total duration of treatment 1 year)

5Fu	- 375 mg/m^2/day	} I/V × 5 days (D1-D5)
Then from D28 onwards	- 5 Fu 400 mg/m2	I/V weekly × 48 weeks
Tab Levamisole	- 150 mg daily	3 days every weeks × 48 weeks

2. 5 Fu and Calcium Leucovorin

(duration of treatment 6 months)

5Fu	- 375 mg/m^2/day	} I/V × 5 days (D1-D5)
Calcium Leucovorin	- 20 mg/m^2/day	Every 4 weeks × 6 months

Carcinoma of lung

Non small cell

1. MVP

Mitomicin	- 10 mg/m^2	} IV D1
Vinblastin	- 6 mg/m^2	IV D1 Every 21 days 6 cycles
Cisplatin	- 100 mg/m^2	IV D1

2. CAP

Cyclophosphamide	- 400 mg/m^2	IV D1
Adriamycin	- 40 mg/m^2	IV D1 } Every 21 days × 6 cycles
Cisplatin	- 40 mg/m^2	IV D1

Small cell carcinoma

1. Cisplatin & Etoposide

Cisplatin	- 100 mg/m^2 IV in 3 divided dose on DI-3	} Every 21 days × 6 cycles
Etoposide	- 100 mg/m^2 DI-3	

52 Principles of Laser Surgery

Contents

- Introduction
- Laser Light
- Pulsed laser
- Continuous wave laser
- Laser/atom connection
- Types of LASER
- LASER surgery
- Advantage of LASER surgery
- LASIK LASER

INTRODUCTION

The Basics of an Atom

Electrons are constantly in motion in its orbit. They continuously vibrate, move and rotate. Atoms can be in different states of excitation. In other words, they can have different energies. If we apply a lot of energy to an atom, it can leave what is called the **ground-state energy level** and go to an **excited level.** The level of excitation depends on the amount of energy that is applied to the atom via heat, light or electricity.

Absorbing Energy

It can be useful to think of these orbits as the different energy levels of the atom. If we apply some heat energy to an atom, we might expect that some of the electrons in the lower-energy orbitals would shift to higher energy orbitals farther away from the nucleus*.

Basic funda, we were taught in Physics in class XII.

Emission of Energy

Once an electron moves to a higher-energy orbit, it eventually wants to return to the ground state. When it does, it releases its energy as a photon:- "a particle of light".

LASER LIGHT

Laser light is very different from normal light. Laser light has the following properties:

- The light released is **monochromatic.** It contains **one specific wavelength** of light **(one specific colour).** The wavelength of light is determined by the amount of energy released; when the electron drops to a lower orbit.
- The light released is **coherent.** It is "organized", ie; each photon moves in step with the others. This means that all of the photons have wave fronts that launch in unison.

- The light is **unidirectional.** A laser light has a very tight beam and is very strong and concentrated. A flashlight, on the other hand, releases light in many directions, and the light is very weak and diffuse.

To make these *three properties occur takes something called stimulated emission.* This does not occur in ordinary flashlight, where all of the atoms release their photons randomly.

The **photon** that any atom releases **has a certain wavelength** that is dependent on the energy difference between the excited state and the ground state. If this photon (possessing a certain energy and phase) encounter another atom that has an electron in the same excited state, stimulated emission can occur. The *first photon can stimulate or induce atomic emission such that the subsequent emitted photon (from the second atom) vibrates with the same frequency and direction as the incoming photon.*

Power Density

- Power density is the measure of power contained in a unit beam area.
- The importance of increasing the power density by altering the power or the size of spot cannot be overstated.

  PD = power(watts)/focal spot area=watts/cm^2
- PD is the most important adjustable parameter used in laser.
- *It signifies laser's ability to vaporize, excise and coagulate.*

Laser Energy

- It is the power delivered per second. **1 Joule = 1 watt × 1 sec.**
- Laser energy is the principle parameter defining the volume of tissue removed. *(IMP. POINT)*

The time and duration of exposure of the tissue to the laser emission is typically controlled by a shutter system.

Relationship Between Power and Duration of Exposure

Pulsed laser - It generates high peaked power for only brief time, ie; in pulses

- It has relatively few applications in medicine. Most notable application is of use of a Q-switched neodymium-YAG laser in ophthalmology.
- Q switched laser generates power as great as millions or hundred of millions of watt with extremely short duration (often as brief as 10^{-12} sec).

Continuous wave laser: It generates a continuous power for a relatively longer duration.

Most medical LASER equipment utilize continuous laser.

TYPES OF LASER DEPENDING ON MEDIA

There are many different types of lasers. The laser medium can be a solid, gas, liquid or semiconductor.

Lasers are commonly designated by the type of lasing material employed:

- **Solid-state lasers** have **lasing material distributed in a solid matrix** (such as the ruby or neodymium: Yttrium-Aluminum Garnet=Nd-YAG lasers). The neodymium-Yag laser emits infrared light at 1064 nanometers (nm).

A nanometer is 1×10^{-9} meters.

- **Gas lasers:** Helium and Helium-Neon (HeNe) are the most common gas lasers. They have a primary output of visible red light. An other gas; CO2 lasers emit energy in the far-infrared and are used for cutting hard materials.
- **Excimer lasers** (the name is derived from the terms **excited and dimers**) use reactive gases, such as chlorine & fluorine, mixed with inert gases such as Argon, Krypton or Xenon. When electrically stimulated, a pseudo molecule (dimer) is produced. When lased the dimer produces light in the ultraviolet range.
- **Dye lasers** use complex organic dyes, such as rhodamine in liquid solution or suspension as lasing media. They are tunable over a broad range of wavelengths.
- **Semiconductor lasers** sometimes called **diode lasers** are not solid-state lasers. These electronic devices are generally very small and **use low power.** They may be built into larger arrays, such as the writing source in some laser printers or CD players.

The first working laser was demonstrated in May 1960 by Theodore Maiman.

LASER SURGERY

Definition

LASER (Light Amplification by Stimulated Emission of Radiation) surgery uses an intensely hot, precisely focused beam of light to excise, vaporize, coagulate tissue and control bleeding in a wide variety of non-invasive and minimally invasive procedures.

Laser surgery is used to

- **Cut or destroy tissue** that is abnormal or diseased without harming healthy & normal tissue.
- **Shrink or destroy** tumours and lesions.
- **Cauterize** (seal) **blood vessels** to prevent bleeding.
- **Photocoagulation** ie; coagulating the tissue by denaturation of protein by laser light.
- **Photoradiation therapy:** Photodynamic therapy is a new form of anticancer therapy, which has gained popularity because of its selectivity to cancer cells. This technique consists of injecting a photosensitizing agent intravenously; which gets selectively concentrated in malignant cells. When illuminated by LASER beam of an appropriate wave length; the tumour cells are destroyed selectively with minimal damage to normal tissue. The only photosensitizer used clinically is *Photofrin,* which is a hematoporphyrin derivative. The light source provided is by a tunable dye laser or a diode laser.

TYPES OF LASERS

Carbon dioxide (CO_2) laser.

- Wave length 10.6mm.
- Rapidly absorbed by water in the tissues.
- Penetrates the tissues very poorly. *(IMP. POINT)*
- Useful for vaporizing the surface tissues. Requires a visible guiding beam (Red helium/neon beam).

Neodymium - Yttrium - Aluminum - Garnet (Nd:YAG) laser (invisible)

- Wave length 1.06mm.
- Absorbed easily by the tissues.
- Penetrates more deeply (3-5mm).
- Vaporizes the tissues easily and effectively.
- Useful for destroying larger tissue volume.
- Requires a visible guiding beam (Red Helium/Neon Beam)
- Nd: YAG laser is used through an endoscope to treat internal organs, such as the uterus, esophagus and colon.
- Nd: YAG laser light can also travel through optical fibers into specific areas of the body during LITT. (Laser induced Interstitial ThermoTherapy)

Argon laser {visible green light}

- The two dominant wavelengths of 514nm **"Green"** and 488nm **"Blue"** make up about 67% of the total beam output power.
- Absorbed by red pigment (hemoglobin and also by melanin molecules)
- Vaporizes the tissues very poorly.
- This laser provides the limited penetration needed for **eye surgery and superficial skin disorders.**
- In a special procedure known as **photodynamic therapy (PDT),** this laser uses light-sensitive dyes to shrink or dissolve tumours. Tissue absorption is less than CO_2 but more than Nd: Yag

*****

KEY BOX 52-1

Laser type	Wave length (nm)
Argon fluoride (UV)	193
Krypton fluoride (UV)	248
Xenon chloride (UV)	308
Nitrogen (UV)	337
Argon (blue)	488
Argon (green)	514
Helium neon (green)	543
Helium neon (red)	633
Ruby(CrAlO3)(red)	694
Nd: Yag (MIR)	1064
Carbon di oxide (FIR*)	10600

* NIR = near infra red, FAR= far infrared

LASER APPLICATIONS IN SURGERY

LASERS are used alone or with conventional surgical instruments in a diverse array of procedures, such as:-

(I) Gastroenterology

1. Hemorrhoidectomy
2. Vaporizing and debulking; recurrent (or) untreated advanced esophageal cancer.
3. To arrest the GI bleeding from the esophagus, stomach and duodenum.
4. To ablate small ampullary tumours in the duodenum.
5. Palliative resection of rectal carcinoma.
6. To destroy angiodysplastic lesions in the small gut/colon.

(II) Urology

To remove low grade, early cases of transitional cell carcinoma of the urinary bladder, where Nd-Yag laser is used. It can be used in conjuction with photosensitizing agent such as hematoporphyrin.

(III) Ophthalmology

1. Glaucoma:- Trabeculoplasty to decrease the intraocular pressure in open angle glaucoma (argon laser is used)
2. Laser photocoagulation in diabetic retinopathy
3. Retinal detachment
4. To destroy an opaque posterior capsule during extracapsular cataract extraction (Nd-YAG is used).

(IV) ENT

1. For hemostasis:- CO_2 Laser
2. For removal of small benign tumours and premalignant lesions:- CO_2 laser
3. Bronchoscopic debulking of inoperable intra bronchial cancers

(V) Dermatology

1. Port wine stains removal in children where Argon laser/Tuneable dye laser is used. The resultant scar is minimal and provides good cosmetic result.
2. To remove tattoos (pulsed ruby lasers)

KEY BOX 52.2

Comparison/Characteristics Between CO_2, Argon and Nedodymium : Yaglaser

	CO_2 laser	Argon laser	Neodymium : YAG laser
Wavelength	10600 nm	458-515nm	1060nm
Visibility	Invisible	Green light	Invisible
Spectrum	Middle infrared	Visible	Near infrared
Medium	Gas	Gas	Solid state
Significant characteristics	• Absorption in tissue • Scattering negligible, light energy converted into heat at tissue surface • Suitable for removal of tissue and for cutting at shallow depths • Rapidly absorbed by water in the tgissues Penetrates the tissues very poorly	• Tissue absorption less than CO_2 but stonger than ND : Yag • Thermal action shallower than Nd : YAG • Has application to indications when removal of tissue with sismjultaneous localized coaglation is desired. • Also used in photodynamic therapy.	• Optical scazttering in tissue considerable-promotes uniform distribution of radiation in tissues • Suitable for deep thermal work, with destruction of tissue without removal • Slight mechanical damage to tissue surface • Can be used through flexible fiber-optic source • Can be used in water

3. Keloid removal.
4. Skin discolouration and skin changes due to aging.

(VI) Vascular surgery

1. Laser angioplasty (CO_2 & Nd-YAG) to vapourize atheromatous plaques in peripheral arteries.

(VII) Gynecology

1. To remove precancerous conditions in the vulva/ cervix (CO_2 laser)
2. Endometrial ablation (Nd-YAG)
3. Vapourization of endometriosis
4. Adhesiolysis
5. Linear salphingostomy
6. Utero sacral ligament transaction
7. Hysteroscopic submucous myoma resection
8. Ovarian wedge resection in polycystic ovarian disease
9. Microsurgery- Co_2 laser is used in adhesiolysis, fimbrioplasty, salpingostomy, tubal reanastomosis.
10. Infertility

(VIII) Orthopaedics

Carpal Tunnel Syndrome (CTS): Low Level Laser Therapy (LLLT) is highly effective in eliminating wrist pain completely.

Advantageous actions of low level laser therapy (LLLT) take place in all organs and tissues of the body for the creation of good cellular functioning once again. They include:

- Reduction of pain by the body's production of endorphins.
- In diminishing of inflammation.
- In stoppage of a tissue's influx of fluids.
- In disappearance of swelling, redness and heat.
- In elimination of pain.
- In elevation of lymphatic drainage.
- In increase of blood circulation;
- In flow of healing enzymes into a traumatized area;
- In spasm release of tight muscles
- In speeding up of bone repair from the stimulation offered by fibroblastic and osteoblastic proliferation;

Advantages of Laser Surgery

1. Bloodless surgery
2. Heat generated by the laser keeps the surgical site free of germs and reduces the risk of infection.
3. Smaller incision is required
4. Take less time & costs less money than traditional surgery
5. Sealing off blood vessels and nerves reduces bleeding, swelling, scarring, pain and the length of the recovery period.

Hazards of Laser

I. Patient hazard

1. Burning of normal tissues
2. Perforation of hollow viscus esophagus /trachea
3. Perforation of a vessel

II. Operator hazard

1. Eye /Skin burns
2. Retinal damage - due to more penetrating laser
3. Corneal burns and
4. Cataract; due to less penetrating laser.

Precautions and Safety Measures

1. Laser safety officer (LSO) a senior nurse -should have the laser key. The laser instrument should be in the safe custody of LSO.
2. Laser should be labelled as per hazard risk (Low/ Medium/High risk)
3. Only trained persons should handle
4. LASER area should be marked in the OT
5. Adequate eye protection with dark goggles
6. Audible signal during laser firing
7. Shutter devices and emergency automatic shut off switches
8. Avoid dry materials to prevent fire (use always wet drapes and swabs).

*****

LASER IN ONCOLOGY

How is it used in Cancer Treatment?

Laser therapy uses high-intensity light to treat cancer & other illnesses. It can be used to shrink or destroy tumours.

1. Lasers are most commonly used to treat superficial cancers (cancers on the surface of the body or the lining of internal organs) such as basal cell skin cancer.
2. Very early stages of some cancers, such as cervical, penile, vaginal, vulvar and non-small cell lung cancer are benefited most by laser surgery.
3. Lasers also may be used to relieve certain symptoms of cancer, such as bleeding or obstruction. For example, lasers can be used to shrink or destroy a tumour that is blocking a patient's trachea or esophagus. Lasers can also be used to remove colon polyps or tumours that are blocking the colon or stomach.
4. Laser therapy can be used alone, but most often it is combined with other treatments, such as surgery, chemotherapy or radiation therapy. In addition, lasers can seal nerve endings to reduce pain after surgery and seal lymph vessels to reduce swelling and limit the spread of tumour cells.

How is Laser Therapy Given To The Patient?

- Laser therapy is often given **through a flexible endoscope.** The endoscope is fitted with optical fibers (thin fibers that transmit light). It is inserted through an opening in the body; such as the mouth, nose, anus or vagina. Laser light is then precisely aimed to cut or destroy a tumour.
- **Laser-induced Interstitial ThermoTherapy (LITT)** (or interstitial laser photocoagulation) also uses lasers to treat some cancers. LITT is similar to a cancer treatment called hyperthermia, which uses heat to shrink tumours by damaging or, killing cancer cells. During LITT, an optical fiber is inserted into a tumour. Laser light at the tip of the fiber raises the temperature of the tumour cells and damages or destroys them.
- **Photodynamic therapy** (PDT) is another type of cancer treatment that uses lasers. In PDT, a certain **drug**, called a **photosensitizer** or photosensitizing agent, is injected into a patient and absorbed by cells all over the patient's body. After a couple of days, the agent is concentrated mostly in cancer cells. Laser light is then used to **activate** the agent and destroy cancer cells. Because the photosensitizer makes the skin and eyes sensitive to light for approximately 6 weeks, patients are advised to avoid direct sunlight and bright indoor light during that time.

*****

What is Lasik?

Though it is a purely opthalmology topic, I am providing a brief notes on it, because of curiosity of many about it. You may not get enough text on this in a UG books.

The basis for all laser eye surgery is to reshape the cornea so that it changes the focal point of the eye. Ideally, the focal point is changed so that; it focuses perfectly on the retina, just like a normal eye.

Myopia (nearsightedness) usually results from the eye being too long. The cornea has a more pronounced curve than a normal eye. Laser eye surgery is great for myopia; because it is relatively easy to remove a little of the cornea to flatten out the curve.

Hyperopia (farsightedness) normally means the eye is too short, which means that the cornea needs to curve more properly to focus the light on the retina. Although more intensive than correcting myopia, laser eye surgery can treat hyperopia by reshaping the cornea to make it rounder.

Principle: Laser eye surgery works by pulsing (throwing) a tightly-focused beam of light (laser) onto the surface of the eye. Upon contact with the surface of the cornea, the laser vaporizes a microscopic (thin) portion of the cornea. By controlling the size, position and number of laser pulses, the surgeon can precisely control how much of the cornea is to be removed.

Like ALK, LASIK uses a microkeratome to create a "flap" of the outer corneal tissue that can be folded out of the way and then replaced. Once the flap is folded out of the way, LASIK uses the same Excimer laser used in PRK to reshape the underlying corneal tissue. Then the flap is replaced over the reshaped area and confers new shape of cornea.

LASIK combines the best features of ALK* and PRK**. (read below).

The great thing about the cornea is how quickly it heals. As soon as that flap is replaced, it begins to naturally seal itself to the rest of the cornea. This approach greatly speeds the overall healing process when compared to PRK, which leaves the reshaped area open.

* ALK= Automated lamellar keratoplasty

**PRK= Photo Refractive Keratotomy

Problems with LASIK

Undercorrection: When not enough tissue is removed during the procedure.

Overcorrection: When too much tissue is removed during the procedure.

Wrinkling: The corneal flap has a small fold or wrinkle in it when it is replaced, causing a small blurry area in your vision. **Blurred vision, halos** around lights, **photophobia** and even **double vision.**

Scarring can happen to the cornea, resulting in a partial or complete **loss of vision.**

Other Types of Eye Surgery

Radial keratotomy (RK): It is the original surgical procedure for vision correction, RK dates back to the 1960s. Tiny incisions are made in the cornea, radiating out from the center. These incisions cause the cornea to flatten slightly. RK is useful in correcting fairly mild cases of myopia.

Automated lamellar keratoplasty (ALK) - A microkeratome* is used to create a corneal flap that is folded out of the way. The microkeratome is then used to remove a tiny slice of the cornea. The corneal flap is placed back into position, where it flattens to fill the space left by the removed slice. ALK can only correct myopia.

(*Microtome = Instrument for preparing thin sections of tissue, similar to that used in histopathology for making thin sciles)

PhotoRefractive keratotomy (PRK) - The precursor to LASIK, PRK first appeared in 1987. Like LASIK, PRK uses an Excimer laser to reshape the cornea. However, PRK works directly on the outer surface of the cornea. PRK can correct myopia, astigmatism and to a lesser degree hyperopia.

*****

53 Surgical Conditions in Neonates, Infants and Children

Contents

- Gastrointestinal condition
  - Duodenal atresia
  - Jejunoileal atresia
  - Malrotation and volvulus neonatorum
  - Meconium ileus
  - Meconium plug syndrome
  - Anorectal malformation
  - Hirschsprung's disease
  - Colonic atresia
  - Intussusception
  - Infantile pyloric stenosis
  - Appendicitis
  - Mesenteric adenitis
  - Exomphalos
  - Gastroschisis
  - Prune belly syndrome
  - Congenital hernia/hydrocele

Contents

- Head & neck disorders
  - Neural tube defect
  - Sacrococcygeal teratoma
- Skin lesions
  - Capillary hemangioma
  - Strawberry angioma
  - Portwine angioma
  - Portwine stain
  - Salmon patch
  - Venous/Cavernous hemangioma
  - Arterial/Plexiform hemangioma
- Other common conditions
  - Umbilical hernia
  - Diaphragmatic hernia
  - Acute scrotum
  - Testicular torsion
  - Undescended testis
  - Acute scrotum
  - Torsion
- Tumours
  - Neuroblastoma
  - Rhabdomyosarcoma
  - Wilm's tumour
- Fetal surgery

Pediatric surgery has emerged as a super speciality for several reasons. First; infants and children differ from adults; both physiologically and anatomically. The nutritional requirements and fluid & electrolyte management for infants and children are very much different from adults. It is because of this reason, specialized knowledge is required for care of pediatric surgical patient. The full discussion of specialized pediatric considerations is too much extensive to be covered in this chapter and of course will become bit boring at UG level; therefore only certain common diseases are discussed here below:

GASTROINTESTINAL CONDITIONS

NEONATAL INTESTINAL OBSTRUCTION:

This is further divided as:

(Depending upon site of obstruction)

1. **Disorder of the small intestine**
   - (a) Duodenal atresia
   - (b) Jejunoileal atresia
   - (c) Malrotation and Volvulus neonatorum
   - (d) Meconium ileus
2. **Disorders of the large intestine**
   - (a) Meconium Plug syndrome
   - (b) Anorectal malformation/Imperforate anus
   - (c) Hirschsprung's disease
   - (d) Colonic atresia
3. **Other causes**
   - (a) Narcotics
   - (b) Electrolyte abnormalities; hypermagnesemia, hypokalemia, hypercalcemia
   - (c) Neonatal hypothyroidism
   - (d) Sepsis

Some of the common causes of neonatal intestinal obstruction are described below:-

Duodenal Atresia

- Duodenal atresia or web affects as many as 1 in 10,000 infants.
- History of polyhydramnios is present in about 50% of mothers.

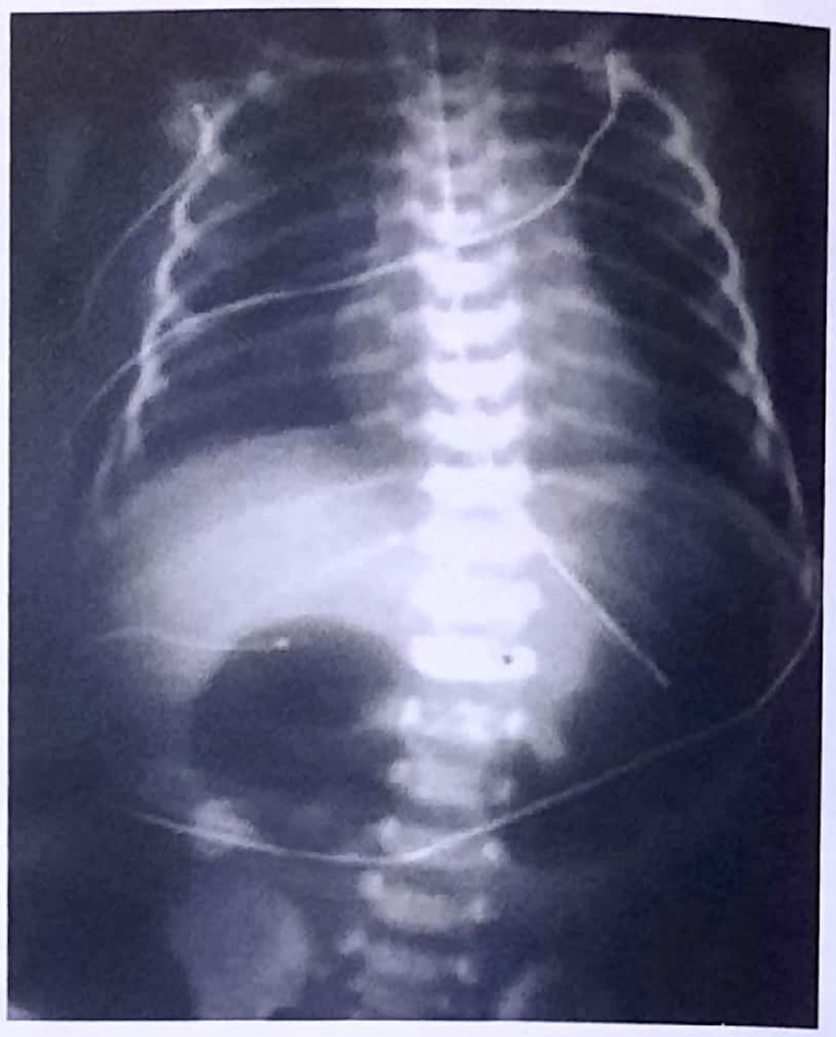

Figure 53.1: Duodenal Atresia (Double bubble sign)

- Unlike jejunoileal atresia, which is believed due to a mesenteric accident the mesentery of the duodenum is intact in duodenal atresia.
- Duodenal atresia is associated with other congenital anomalies in as many as 50% of new born, which include trisomy (of chromosome 21) in 40%, imperforated anus and congenital cardiac disease.
- In more than 85% cases, the atresia is distal to ampulla of vater-hence vomitus is bilious. (IMP. POINT)
- Annular pancreas is almost always associated with hypoplasia at the level of duodenum.

Diagnosis

- X-ray of the abdomen shows distended stomach and distended proximal duodenum *Double bubble sign* (PGI 97). Distended stomach and distended duodenum gives a picture resembling two bubbles. (Figure 53.1)

Treatment

- *Duodeno-duodenostomy is operation of choice.* (PGME)
- Duodeno-jejunostomy can also be done.
- If *annular pancreas* is present it should be left as such and a bypass procedure such as duodeno-duodenostomy is done. (PGME, IMP. POINT)

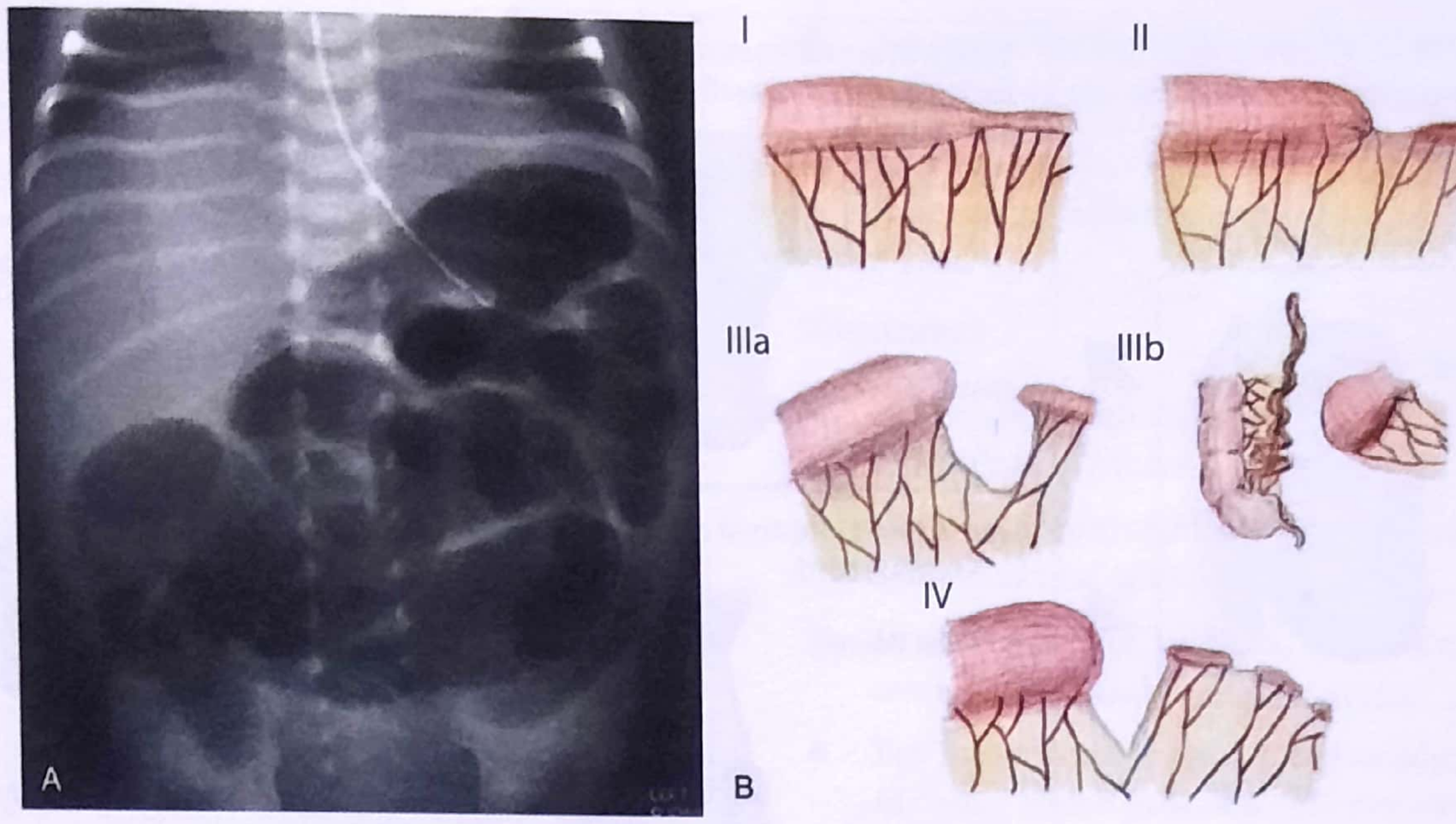

Figure 53.2(a): (A) Plain abdominal radiograph shows multiple dilated bowel loops indicating congenital bowel obstruciton. (B) Jejunoileal atresia Types I to IV are depicted. In particular, IIIb demonstrates an apple peel type of atresia with a large mesenteric gap.

? Duodeno-duodenostomy

It is surgical creation of passage, *between* the first part of duodenum and third (or fourth) part of duodenum, *bypassing the second part,* where in most of the atresia or stenosis is present. After creation of this; food will enter directly into third (or fourth part) of duodenum bypassing the second part, hence intestinal continuity is maintained.

? Duodeno-jejunostomy

It is surgical creation of passage between the duodenum and jejunum.

Jejunoileal Atresia

- Atresia of jejunum or ileum is more common than duodenal atresia; and occurs in 1 in 1500 newborn and one third of newborn born with jejunoileal atresia are premature.
- In contrast of duodenal atresia; jejunoileal atresia is widely considered to be a condition acquired during development, rather than a preprogrammed anomaly.
- Intrauterine mesenteric vascular accidents occur in segment of intestine, rendering it devascularized. Please see figure 53.2a and 53.2b.
- Interruption of the main superior mesenteric artery may result in atresia of most jejunum and ileum.
- Infants present with distension and bilious vomiting.
- Preoperative nasogastric suction to decompress the bowel is vital to limit the distention of the intestine proximal to atresia.
- Surgery for jejunal atresia involves resection of atretic segment and primary anastomosis between healthy (normal) bowel loop.
- Long term outcomes are generally excellent if sufficient bowel is present for absorption and growth.

Malrotation and Volvulus Neonatorum

- Malrotation and volvulus are perhaps the most feared cause for proximal small bowel obstruction.
- Midgut volvulus from malrotation is a life- threatening surgical emergency in the newborn and occur in approximately 1 in 6000 newborns.
- Rotational abnormalities of bowel may be present in as many as 1% of the population.
- Volvulus represents the acute twisting of the intestines upon their mesentery and can occur in a patient with malrotation due to the lack of normal fixa-

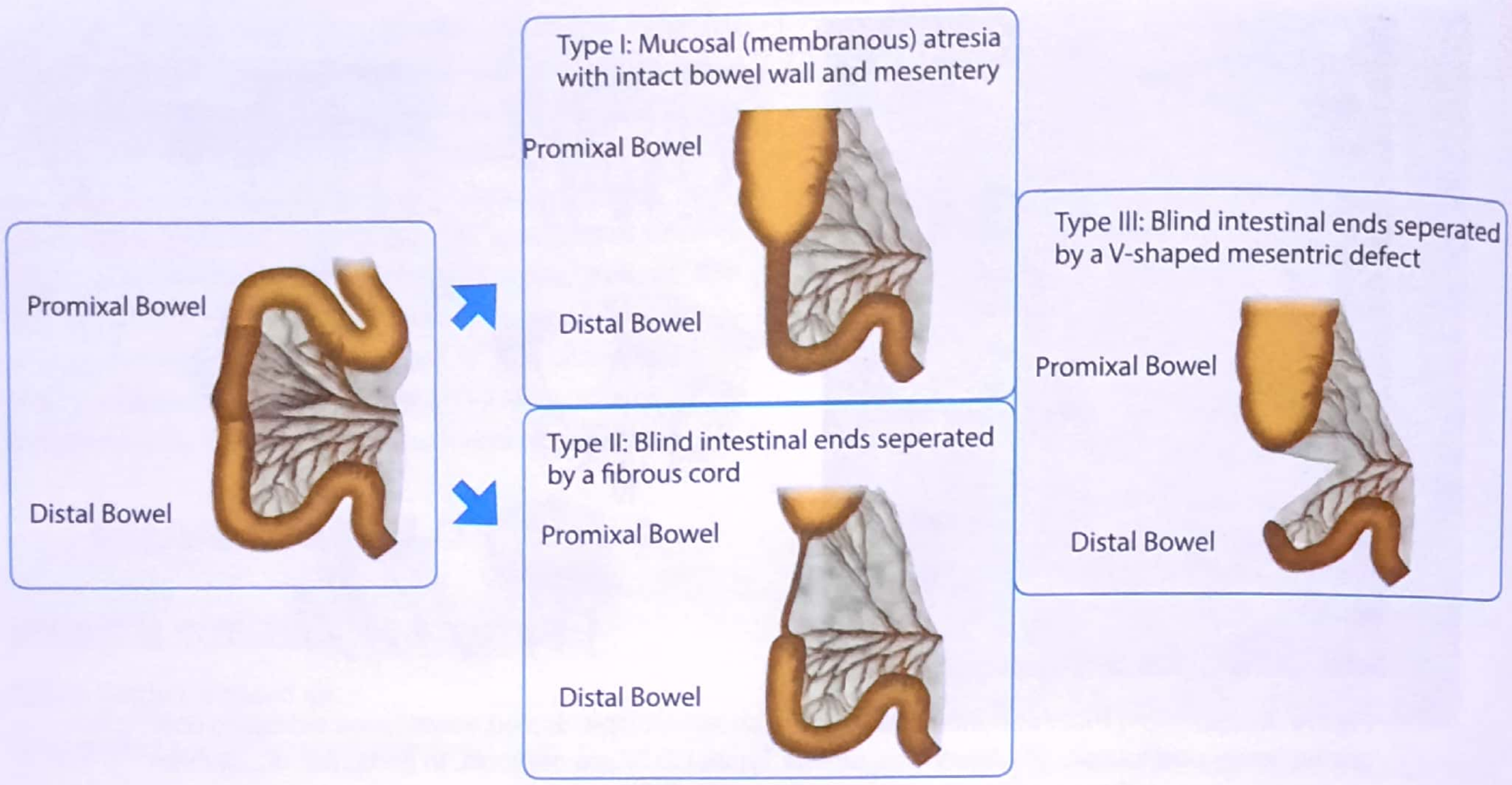

Figure 53.2(b): Intestinal atresia

tion of the bowel to the retroperitoneum during fetal development.

- Patients usually presents in the first month of life.

Pathogenesis

- The bowel develops outside of the abdominal cavity as a single long loop of bowel; based on the pedicle of the superior mesenteric vessels.
- As the bowel returns to the abdomen, the proximal small bowel returns first and the duodenum rotates underneath the superior mesenteric vessels to assume a retroperitoneal position.
- Rotation continues as the large bowel returns to the peritoneal cavity, rotating over the vascular pedicle occurs to place the ileocecal valve in the right lower quadrant and establishing the hepatic and splenic flexures.

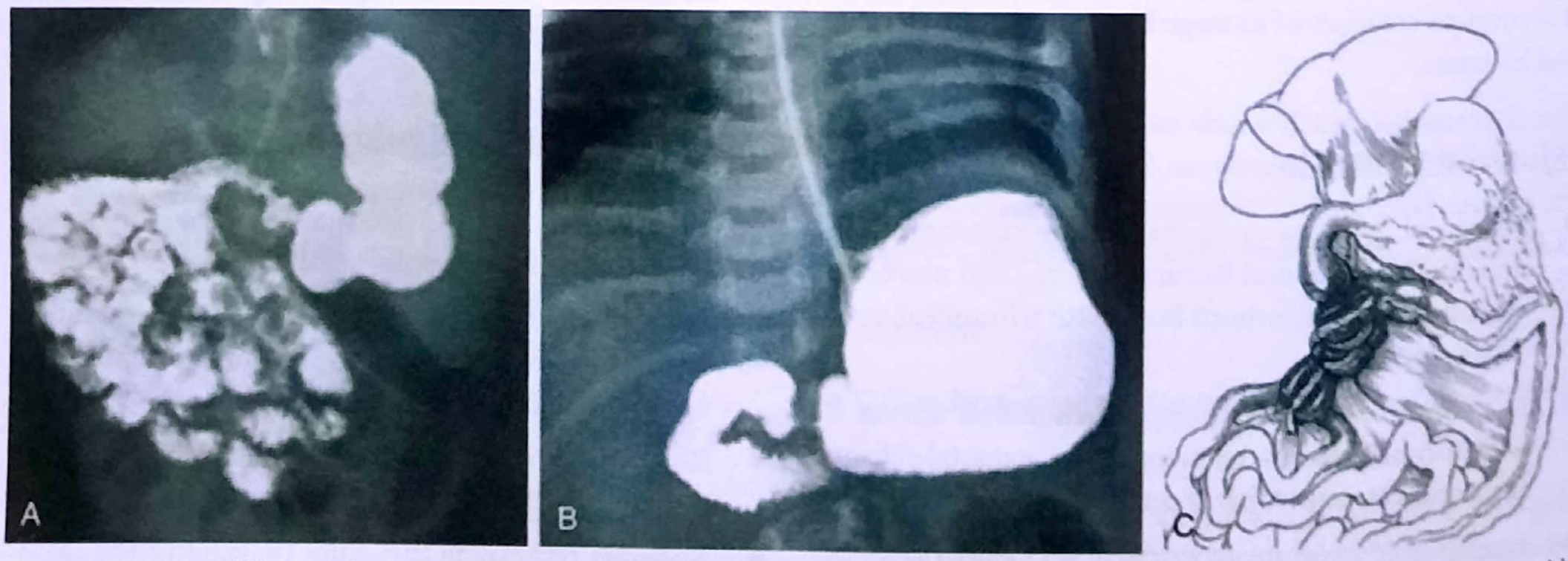

Figure 53.3(a): (A) Intestinal malrotation. The duodenal C-loop does not cross the midline and the proximal small bowel is on the right side of the abdomen. (B) Midgut vovulus as demonstrated by a corkscrew appearance of contrast abruptly tapering off in the duodenum. (C) Diagram depicting midgtu volvulus from intestinal malrotation.

Figure 53.3(b): Volvulus Neonatorum

- Fixation points develop in the peritoneum at the duodenum by ligament of Treit'z, Ileocecal valve and right and left paracolic gutters. This arrangement results in a broad fixed base of the small -bowel mesentery by 10 weeks gestation.
- Malrotation result from a failure of the GI tract to complete it's normal rotation as it returns to the abdominal cavity at 8-10 week gestation.
- If the rotation is incomplete or does not occur, normal mesenteric attachments are absent and abnormal peritoneal bands may develop.
- These bands may obstruct the duodenum and are known as Ladd's bands.
- The unfixed bowel may twist around itself and compromise the blood supply of the superior mesenteric pedicle, resulting in obstruction and ischemic of bowel. Please see figure 53.3a & 53.3b.

Clinical feature

Initially patient present with bilious vomiting. The abdomen is initially soft and scaphoid. As the obstruction progresses, the volvulus compromises flow in the superior mesenteric pedicle and the ischemic bowel becomes dilated, distended and firm. The child may become hypotensive from sequestration of fluid within the obstructed bowel. Later perforation of bowel occurs due to ischemia; resulting in peritonitis and shock.

Investigations

Ultrasonography is helpful in confirming the diagnosis.

- Normally, the superior mesenteric artery (SMA) lies to the left of the superior mesenteric vein (SMV)
- An SMA that lies to the right or anterior to the SMV suggests malrotation.

Treatment

- Malrotation with midgut volvulus is a true surgical emergency in the newborn.
- Delay in operation may result in catastrophic loss of a large portion of the small bowel.
- In severe midgut volvulus, the entire midgut is necrotic and the child can not survive.
- For malrotation is the Ladd procedure is operation of choice which includes; evisceration of the midgut and immediate counterclockwise derotation of the gut to release the volvulus and reestablish flow of blood to the bowel.
- Obstructing Ladd bands from the colon to the duodenum are released (divided).
- The bowel is returned to the abdomen in a manner that spreads out the mesentery as much as possible.
- The duodenum and small bowel are placed on the right side of the abdominal cavity.
- The colon is placed on the left, with the cecum in the left lower quadrant.
- Because the ileocecal value now is on the left side of the abdomen, the appendix is removed to minimize future problem in diagnosis.
- Morbidity and mortality is directly related to the extent of bowel ischemia.
- The mortality rate may be as high as 65% if more than 75% of the small bowel is necrotic at the time of laparotomy.
- Survivors may develop short bowel syndrome with its associated complications of malabsorption and malnutrition.

Meconium Ileus

The meconium is kept in fluid (ie; in liquid form) by the action of pancreatic enzymes. In *cystic fibrosis*, where pancreatic enzyme secretion is reduced/absent, meconium could not be kept in fluid *(AJ 2000, 96, 98)*. Meconium ileus is the earliest manifestation of cystic fibrosis in new born period. Incidence of cystic fibrosis is 1 case per 3000 live

birth. Of new born with cystic fibrosis disease, 10-20% will present with meconium ileus.

In this situation the meconium becomes inspissated and fills the terminal ileum. Because it is very dry and relatively hard and hence, could not be passed out and results in progressive neonatal obstruction.

The condition is due to an *autosomal recessive* genetic defect. The gene is located at chromosome 7. A family history may be present. (PGME)

Clinical feature

- Abdominal distension is usually absent at birth, it develops rapidly with failure of passage of meconium.
- Vomiting soon follows and it is usually bilious.

Any small bowel obstruction distal to 2nd part of duodenum, where in CBD opens, results in bilious (bile) vomiting. (AI 94)

For example

In pyloric stenosis where the obstruction is above (proximal) 2nd part of duodenum (ie; at pylorus) the vomitus does not contain bile, where as Heal obstruction, jejunal obstruction, duodenal atresia result in bilious vomiting.

Investigation

Straight abdominal x-ray

- Will show enormously distended small bowel *without air-fluid levels* because meconium is viscid. (PGI JUNE 98, MANY PGME)
- Small bubbles of gas are trapped in the inspissated meconium and thus produces "ground *glass appearance*". (PGME)
- Air mixed with meconium produces a typical "*soap bubble*" sign. (PGME)
- A gastrografin enema will show a microcolon and terminal ileum filled with pellets of meconium.

Ground glass pattern = Homogenous translucency

Treatment

Conservative

Gastrografin contrast enema is the first line of treatment of meconium ileus (IMP. POINT). Dilute gastrografin is introduced into colon as enema and it reaches to ileum and fills it. Gastrografin absorbs fluid from the interstitial space into lumen of the ileum, as gastrografin is hyper-osmolar, (which absorbs water) and make meconium soft. Now the soft meconium is passed naturally. Large volumes of intravenous fluid are needed to correct fluid losses from intestinal tract, resulting from absorption of water by Gastrografin. Hyperosmolar enemas may increase the risk of perforation. The risk of perforation is 3-10%.

Surgical treatment

If the conservative treatment fails; ***Bishop - Koop operation*** is done. [I am not discussing Bishop - koop operation, because it will be boring and "too much for a UG"]

Meconium-plug Syndrome

Occasionally, a meconium plug in the rectum may cause intraluminal intestinal obstruction. Conditions that predispose to dysmotility of the neonatal bowel; such as maternal preeclampsia, maternal diabetes, hypothyroidism, prematurity, maternal administration of magnesium sulfate, sepsis may be responsible for formation of a meconium plug in rectum. The colon distal to the obstruction is narrowed and small in caliber. Because of the frequent association between maternal diabetes mellitus and colonic obstruction with a small left colon; this association is termed as small left colon syndrome. This readily resolves after enema. A rectal wash will stimulate the newborn to pass tenacious meconium and relieves the obstruction immediately.

Anorectal Malformation/Imperforated Anus

Anorectal malformation occurs in approximately 1 in 5000 live births and affect males and females in equal frequency. This is due to failure of descent of the urorectal septum. In patient with imperforated anus, the rectum fails to descend through the external sphincter complex; but the rectal pouch end blindly in pelvis, above or below the levator ani muscle. In most of the patients; this blind rectal pouch communicates distally with genitourinary system or with perineum through a fistulous tract.

In 40-50% of the cases, there are other associated anomaly- **VACTERAL** anomaly:-

V - **V**ertebral defect
A - **A**nal atresia (imperforate anus)
C - **C**ardiovascular abnormality (M/C-TOF)
TE - **T**racheo **E**sophageal Fistula

KEY BOX 53.1

Classification of congenital anomalies of the anorectum

Female

- Cutaneous (perineal fistula)
- Vestibular fistula
- Imperforate anus without fistula
- Rectal atresia
- Cloaca
- Complex malformation

Male

- Cutaneous (perineal fistula)
- Rectourethral fistula
- Bulbar
- Prostatic
- Recto-bladder neck fistula
- Imperforate anus without fistula
- Rectal atresia

RA - Renal Agenesis

L - Limb hypoplasia

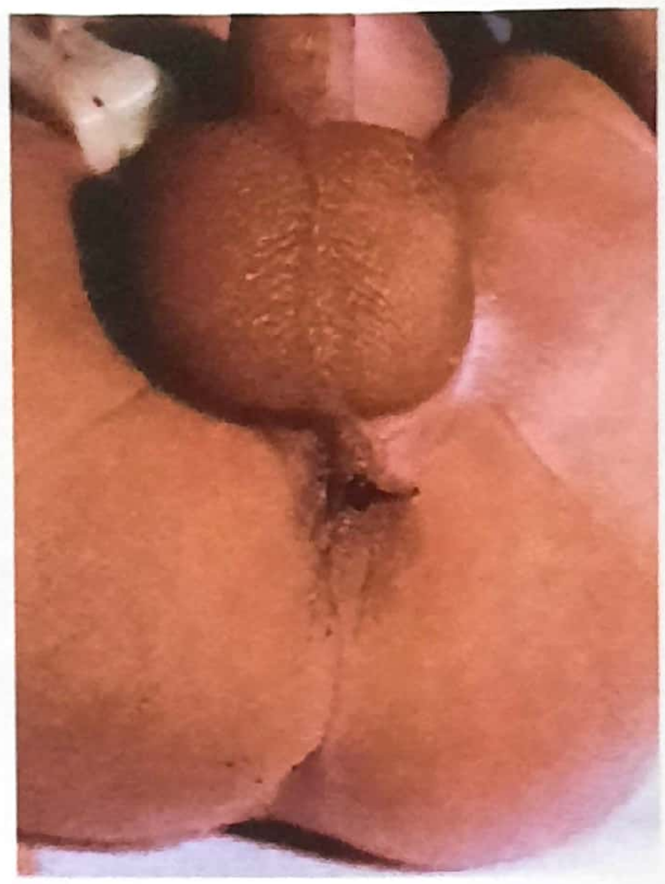

Figure 53.4(a): Imperforate anus with perineal fistula opening demonstrating meconium.

A new born with imperforate anus should undergo plain radiography 12-24 hours after birth to assess the distal extent of bowel gas. Lateral X ray with child in a inverted position (***invertogm***) may be helpful in classifying the imperforate anus.

KEY BOX 53.2

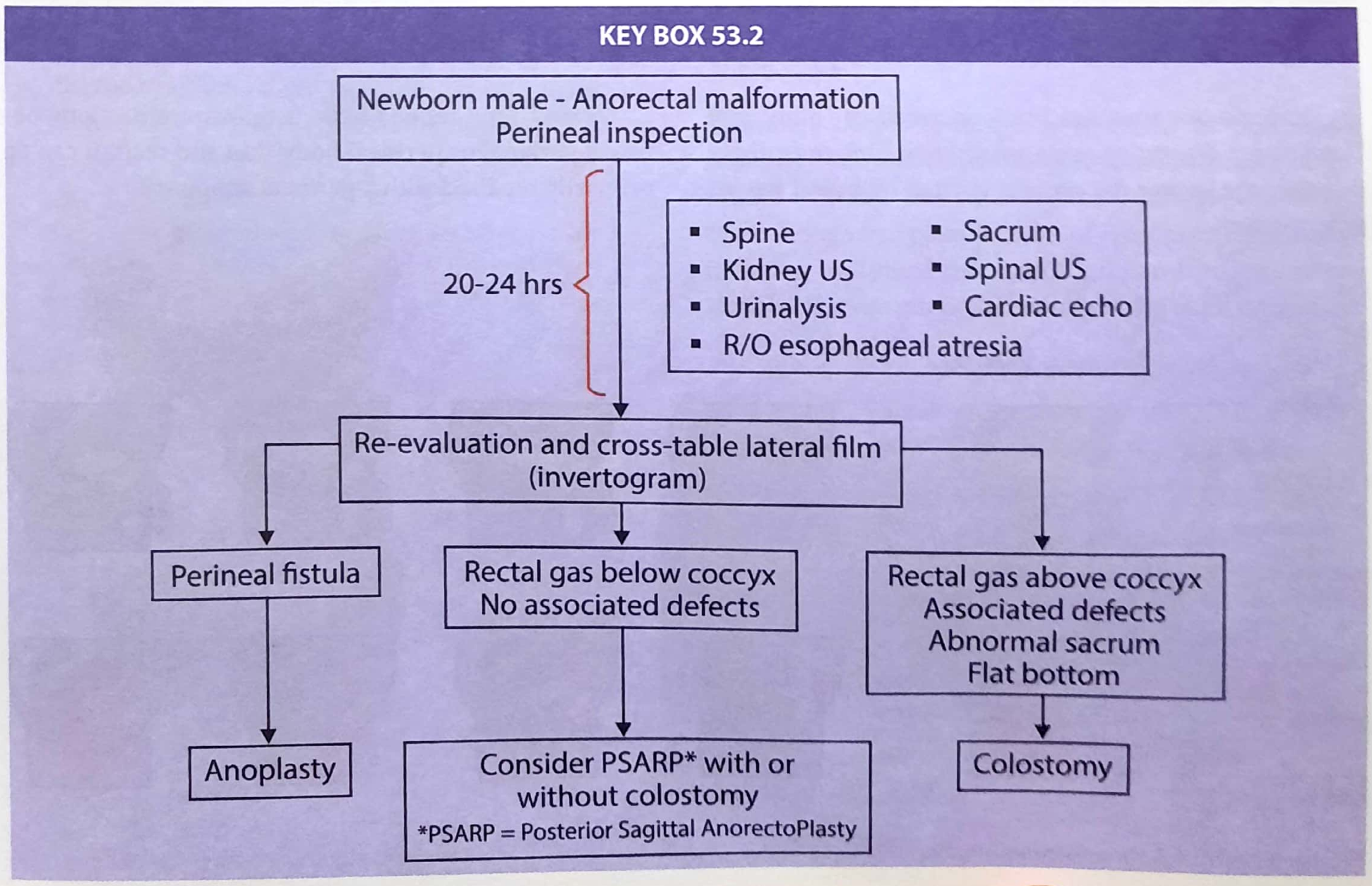

KEY BOX 53.3

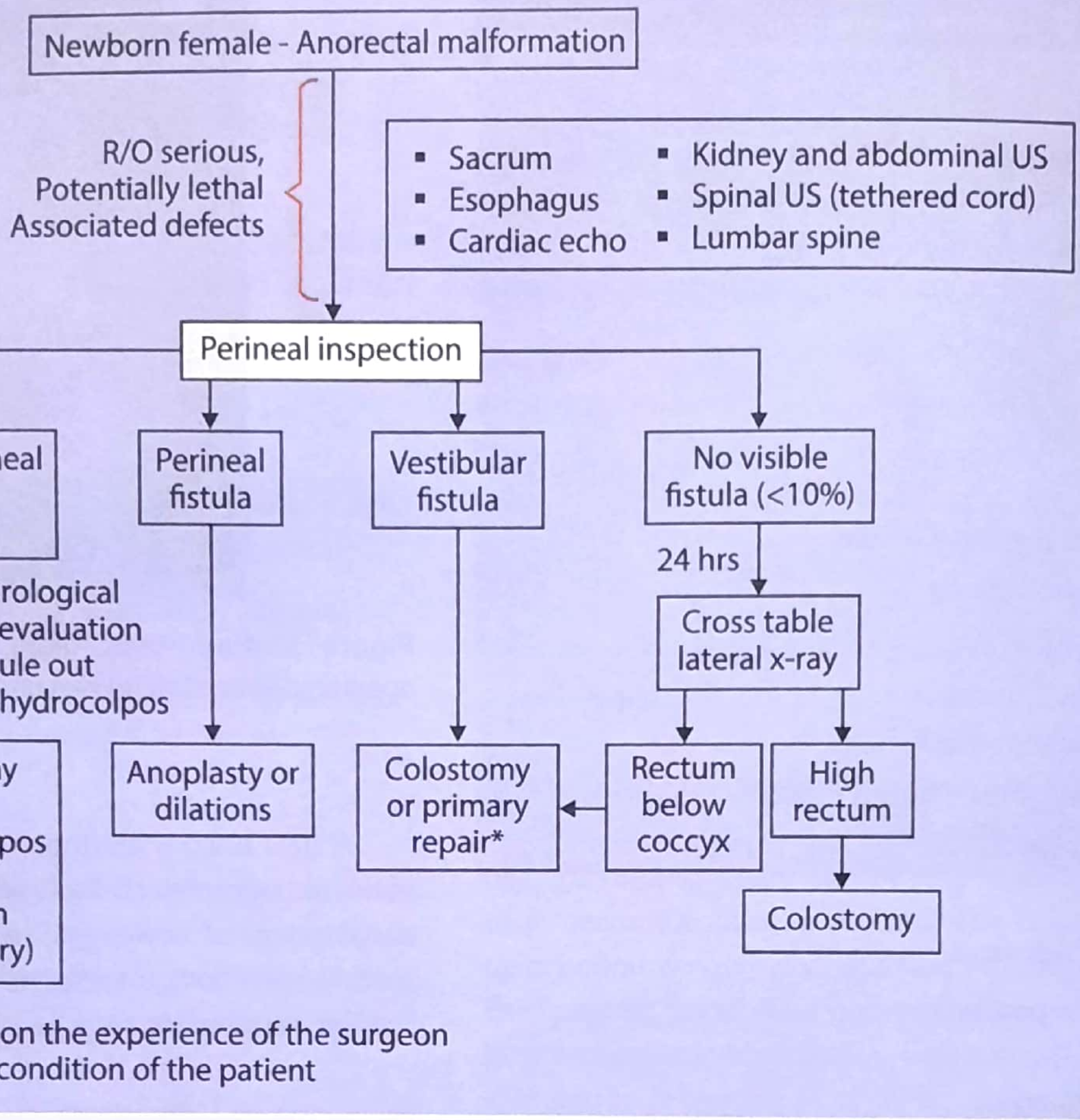

*Depending on the experience of the surgeon and general condition of the patient

Imperforate anus has been classified as "high" and "low" type; *depending upon whether rectum ends above or below the levator ani muscle:* elicited by bowel gas on invertogram.

"Low" type lesions have fistulous connections between perianal or perineal body skin and rectum can be primarily repaired with a perineal anoplasty.

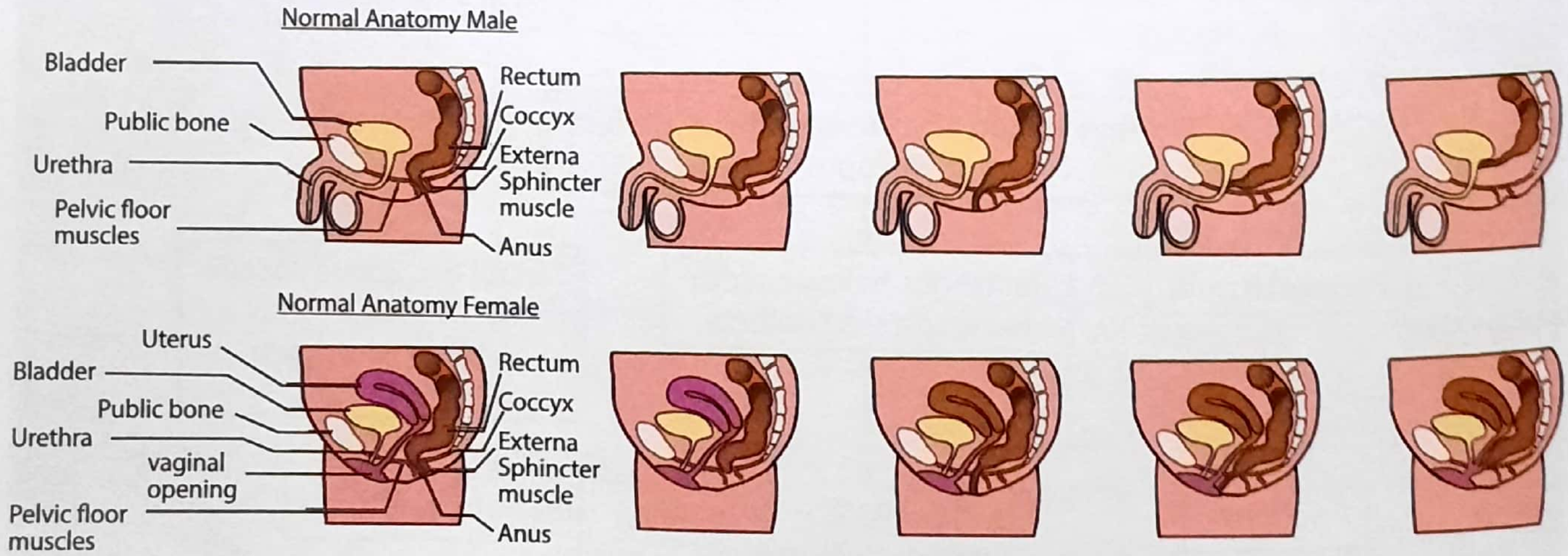

Figure 53.4(b): Anorectal malformation

In "High" type where distal end of rectum is several centimeters (>2.5cms) above the anal skin or has a fistula to vagina or urinary bladder; colostomy is performed in neonatal period followed by a pull-through procedure at approximately 2 months of age.

The type of pull through procedure favoured is **P**osterior **S**agittal **A**no**R**ecto**P**lasty (**PSARP**). *(IMP. POINT)*

Hirschsprung's Disease

- Hirschsprung's disease is a disorder of the neuroenteric pathway with in distal large bowel that prevents bowel relaxation, resulting in functional distal bowel obstruction that affects 1 in 1500 newborn.
- Hirschsprung's disease is caused by *failure in* migration of *ganlionic cell in the myenteric plexus* of the colon from the neural crest. *(AIIMS 97, UP 05, PGI 06)*.
- The aganglionic segment usually starts at anorectal junction and extends proximally (upwards) for a variable distance. *(IMP. POINT)*
- In approximately 95% cases aganglionosis is restricted to rectum, however rarely aganglionic segment may be longer and in exceptional cases the entire colon and small intestine may be affected.
- The disease is more common in male child than in female child and male to female ratio in 4:1.
- The genetic defect responsible for Hirschsprung's disease has been linked to the *rat protooncogene,* located on the *long arm of chromosome 10.* *(IMP. POINT)*

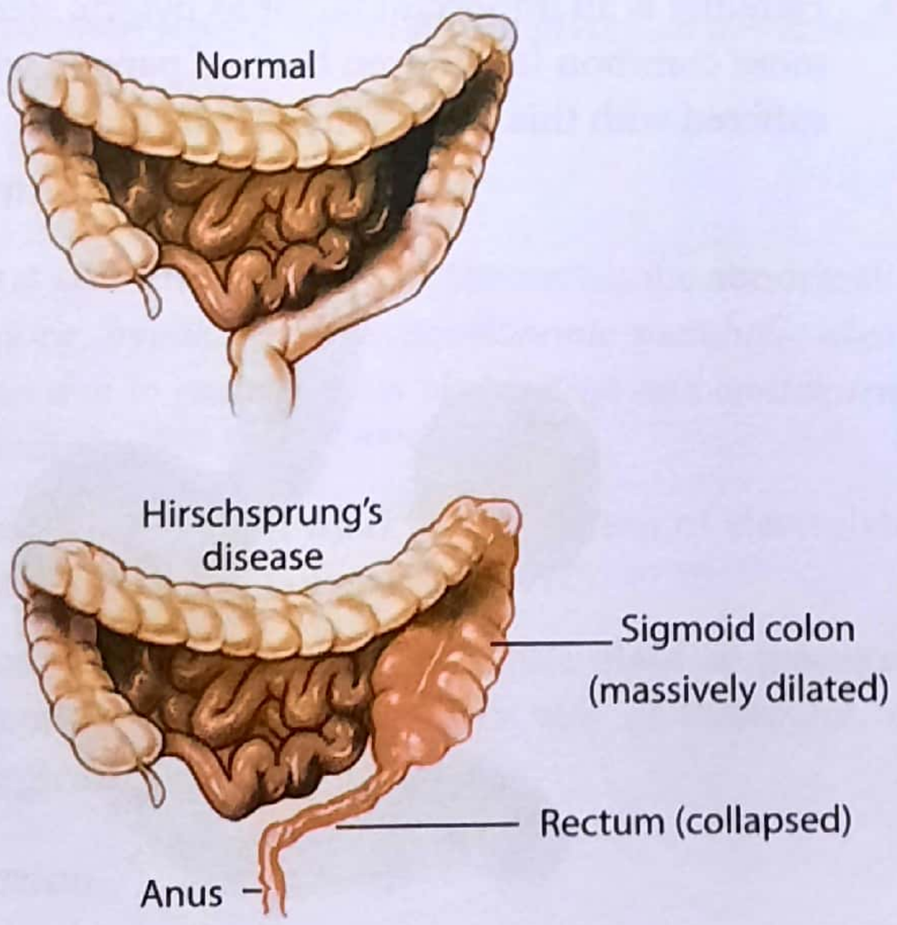

Figure 53.5(a): Hirschsprung's disease

- The *absence of ganglion cells in the myenteric plexus results in failure-of peristalsis in affected segment.* This segment remains narrow and spastic and represents a zone *of functional intestinal obstruction.*
- As a result of narrowing & obstruction the colon **proximal** to the aganglionic segment **dilates** enormously (hence called as megacolon) leading to abdominal distension *(AIIMS NOV 99)*. Please see figure 53.5 (a & b).

Clinical feature *(VERY IMPORTANT FOR PGME)*

- Most affected children present soon after birth with *failure to pass meconium* in 24 hours, followed by abdominal distention and bilious (bile containing) vomiting (MANY PGME)*. Persistent vomiting lead to loss of fluid and electrolytes; resulting in fluid and electrolyte imbalance. *(PGME, AIIMS, PGI)*
- Stasis of abdominal content leads to growth of bacteria resulting in enterocolitis; which may subsequently result in intestinal perforation and subsequent septicemia.
- In a few cases; the onset is delayed and presents with chronic constipation starting in first few weeks of life.
- Perianal soiling is **not** a feature of Hirschsprung's disease, which is often a feature of idiopathic megacolon.
- Rectal examination reveals empty (no stool in) rectum.

Treatment

Treatment of this condition is primarily surgical. More recently, a minimal invasive pull-through transanal approach without formal laparotomy has gained acceptance. Long term complication of Hirschsprung's disease include a continued risk for chronic constipation and enterocolitis, even after successful pull-through operation.

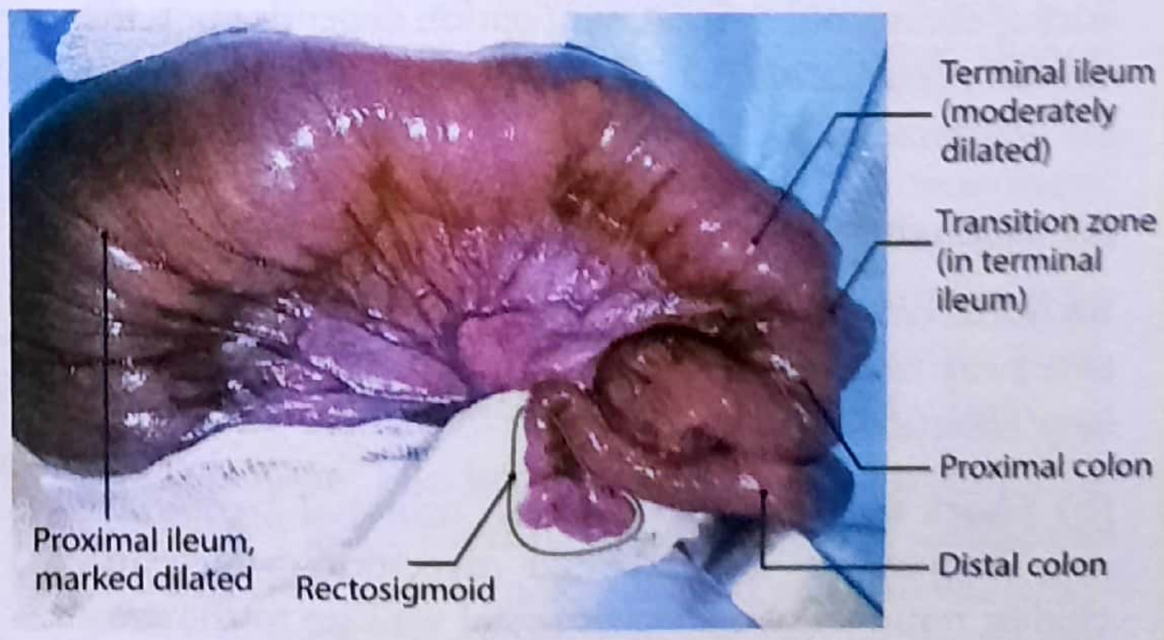

Figure 53.5(b): Hirschsprung's disease

Figure 53.5(c): Barium enema

Diagnosis

(A) Radiology

Barium enema: It is done by injecting the radio-opaque Barium (Ba) into the rectum and descending colon and then obtaining a X-ray of abdomen. This will show the dilated proximal segment and the length and site of involved segment of intestine. (Please read Ba enema in chapter 55) (Figure 53.5c)

(B) Rectal Biopsy

- *Confirmation of diagnosis depends upon absence of ganglion cells in the biopsy specimen* (MANY PGME)

The biopsy specimen is usually taken from just above the anorectal junction. (MANY PGME)

Treatment

This depends upon the age of the patient, the length of the involved segment, the severity of symptoms and the presence of enterocolitis. Treatment option depends upon the clinical presentation. Child may present with any one of the below mentioned situations and treated accordingly.

(a) Neonates with enterocolitis and obstruction

An initial colostomy is performed to divert the fecal content away from the diseased segment (this will also relieve obstruction).

(b) Short segment disease with minimal symptoms may respond to an extended myectomy which includes; removal of a strip of rectal wall up to the area where normal ganglion cell start.

(c) Long segment disease

In a neonate definitive operation is postponed till 10-12 months of life until the child weighs approximately 10 kg (PGI 79, TN 89).

Till then a temporary colostomy is performed. When the child becomes of one year; then the definitive procedures can be performed. The definitive operative procedures are:

- Duhamel operation (UP 01)
- Swenson's procedure
- Soave's operation (coloanal anastomosis)

Colonic Atresia

Colonic atresia is a rare condition and is usually associated with genitourinary anomalies or abdominal wall defect. Pathophysiology is similar to that of jejunoileal atresia; that is result from an intrauterine mesenteric vascular accident. Diagnosis of colonic atresia may be made by contrast enema. Diverting colostomy may be necessary; if the proximal colon is extremely dilated.

Infantile Hypertrophic Pyloric Stenosis

Etiology

- The incidence of this condition is approximately three per 1000 birth.
- *Male, female ratio is 4:1 and the patient is generally first born male child.* (MANY PGME)
- The etiology is not well understood.
- Heredity is an important factor as pyloric stenosis is more common in children born of parents who had suffered with this condition in their infancy.

Figure 53.6(a): Infantile pyloric stenosis

Pathology

- There is gross *hypertrophy* of musculature of pylorus and adjacent antrum.

Clinical feature

- The *condition is most commonly seen 4 weeks after birth, ranging from third week,* (MANY PGME)
- One to two weeks after birth *projectile vomiting start.* As obstruction is at pylorus, *there is no bile in vomitus.* (PGI 89, UP 93, 01, MANY PGME)

NOTE: If obstruction is distal to 2nd part of duodenum (where in bile duct opens) the vomitus will contain bile, but in this case obstruction is at pylorus; hence vomitus does not contain bile (non-bilious vomiting)

- Often a *hard lump is palpable in right hypochondrium.*
- When the infant is fed a peristaltic wave may be seen ***from left to right*** in epigastric region. (IMP. POINT) (Figure 28.11 page 408)
- Weight loss is a striking feature and the infant rapidly becomes emaciated and dehydrated.

Diagnosis

- Can usually be made by a test meal, *and observing the peristaltic wave moving across the abdomen from left to right.*
- Imaging: *Ultrasonography is the investigation of choice* (AIIMS 99), which detects the classical feature of the pyloric canal.
- *Gastrografin study* will give **shouldering sign**.
- ***String sign*** *on barium meal* (NEET) *where in thin stripes of contrast is seen within lumen giving an appearance of string.*

Treatment

- First concern is to correct the metabolic abnormalities eg; *hypokalemic, hypochloremic metabolic alkalosis due to gastric outlet obstruction and consequent vomiting.* (PGI 89, UP 95, MANY PGME)
- Ideal replacement fluid for correction of electrolyte abnormalities is normal saline (NS) (UP 98)
- Conservative treatment has little place in management of condition. The main stay of treatment, is surgical.

Operation

Ramstedt's pyloromyotomy
(AIIMS 87, TN 04, PGI 97, UP 2000)

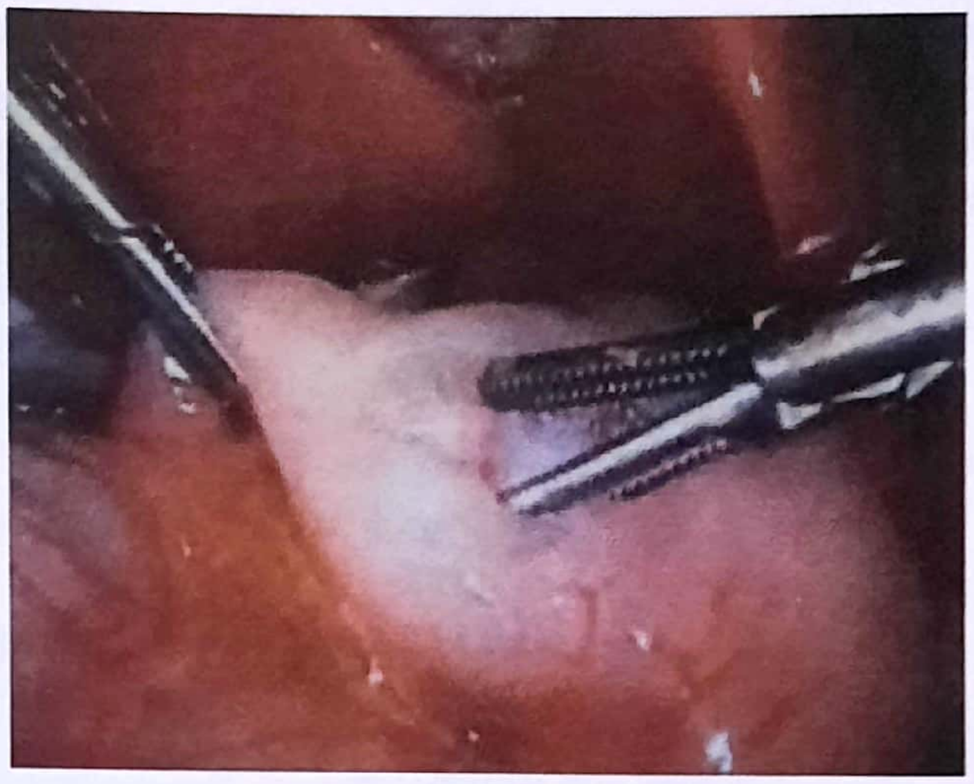

Figure 53.6(b): Ramstedt's pyloromyotomy

- Pyloromyotomy : Pyloro + myo + otomy = Pylorus + Muscle + cutting (incision)
- Pylorus muscle in incised and mucous membrane of pyloric canal comes out bulging.
- Results of surgery are excellent and most infants are discharged with in 3rd postoperative day.

Intussusception

Please read this topic on page number 648.

Acute Appendicitis

The incidence of appendicitis is equal among males and female before puberty. In teenagers and young adult, male-female ratio increases to 3:2 at 25; there after the greater incidence in male declines.

Etiology

1. **Diet**: Decreased dietary fibre and increased consumption of refined carbohydrate increases chances of appendicitis.
2. **Family tendency**: It has been seen that many members of the same family sometimes suffer from appendicitis. This may suggest familial tendency for this condition. This is common with retrocecal appendix. This could be due to poor blood supply.
3. **Infection:** Infection by direct invasion from the lumen or blood stream. A mixed growth of aerobic and anaerobic organism is usual and *most common* bacteria are *E.coli, Streptococcus fecalis and Bacteroids.* (MANY PGME)

4. **Obstruction of appendix lumen:** The causes could be:
   (a) Hyperplasia of submucosal lymphoid follicles (60%): This is the most common cause in children and young adults.
   (b) Fecolith* (35%): This is the most common cause in adults.
   (c) Foreign bodies (4%)
   (d) Stricture and tumours (1%)
   (e) Worms (< 1 %) such as pin worm *(Oxyuris-vermicularis)*
   (f) Acute kinking of appendix by a band of old adhesion or a congenital band.
   (e) Vegetable and fruit seeds.
   (g) Contraction of base of appendix in a sphincteric manner.

Clinical feature

Symptoms

1. *Pain*

- Initially vague pain is experienced around umbilicus.
- Pain is constant in nonobstructive type, where as colicy in obstructive type. (IMP. POINT)
- Later on when the parietal peritoneum is affected; the pain shifts to right iliac fossa and becomes well localized constant.

2. *Gastric upset*

Anorexia, nausea and vomiting follows the onset of pain.

Gastric upsets never precede pain but always follow pain (important point to remember)

3. *Low grade fever*
4. *Many patient* may feel constipated, however diarrhea may be associated with a *pelvic appendicitis due to irritation of rectum by inflamed appendix.* (PGME)

Signs

1. Brown furred tongue and foul breath.
2. Pulse rate: There is no changes initially but after 6 hours; pulse rate rises with rise in temperature.
3. Temperature-The temperature is only slightly elevated (37.8°C) in the absence of perforation of appendix.

Abdominal examination (VERY IMPORTANT)

(i) *Localized tenderness at Me Burney's point:* McBurney's point lies at the junction of lateral 1/3 and medial 2/3 of line joining the anterior superior iliac spine and the umbilicus. (UP 93, MANY PGME)

(ii) *Pointing sign:* Patients point out the exact site of pain by a finger; which is towards right iliac fossa.

(a) Infants

(i) It is rare in infants below 3 years of age.

(ii) Incidence of perforation (about 99%) & postoperative morbidity is highest in infants among all age group

(iii) Diffuse peritonitis may develop rapidly, due to under developed greater omentum in infants.

(b) Children

(i) Vomiting is a common feature.

(ii) Bowel sounds are usually absent in the early stages.

Treatment

The treatment of acute appendicitis is **appendicectomy,** which is carried out as soon as diagnosis is made. Intravenous fluids, and appropriate antibiotics should be given.

1. When peritonitis is suspected, therapeutic IV antibiotics should be started.
2. Appendicectomy may be performed by conventional open operation or by using laparoscopic techniques.
3. The **incisions** for **appendicectomy are:**
   (a) ***Gridiron incision*** (McBurney's) is the standard approach. (MANY PGME)
   (b) ***Rutherford Morrison incision*** is used if better access is required. This is a *muscle cutting incision.* (KAR94)
   (c) A *transverse skin crease* ***(lanz)*** incision has gained popularity in recent years as the exposure is better and extension of incision; if required is easier.
   (d) Right lower paramedian incision is made, if the diagnosis is in doubt or perforation peritonitis is suspected.

Please see various incision on page 751-752.

4. ***Laparoscopic appendicectomy*** is particularly useful in early stage of appendicitis and in women of child-bearing age.

Esophageal Atresia and Tracheoesophageal Fistula

Please read this topic on page no 371.

Mesenteric Lymphadenitis

- This condition is one of the common cause of acute abdominal pain in children. Nonspecific mesenteric lymph adenitis was so named to distinguish it from specific (Tuberculous) mesenteric lymphadenitis.
- It is now very much more common than the tuberculous variety.

Etiopathogenesis

- The etiology often remains unknowns, although some cases are associated with ***Yersinia*** infection of the ileum. In some cases, an unidentified virus is blamed. In about 25% of cases, a respiratory infection precedes an attack of NSMLA.
- Some time appendicitis has been incriminated to cause this condition, though at laparotomy appendix in found to be absolutely normal. However; appendicectomy reduces the incidence of further attacks.
- This condition may be as a result of hypersensitivity reaction to a foreign protein in food.
- There are small sized enlarged firm lymph nodes in ileocecal mesentery. In very acute cases the nodes are distinctly red and very large. There may be small increase in peritoneal fluid.

Clinical feature

- Non specific mesenteric lymph adenitis (NSMLA) is a common cause of acute abdominal pain during childhood. The condition is unusual after puberty.
- The condition more commonly occurs, when child is tired after playing.
- Early in the attack the temperature may be elevated.
- There is a history of short attack of central abdominal pain lasting for 10-30 minutes and associated with circumoral pallor.
- Vomiting occurs in about 1/3 or cases.
- **Shifting tenderness** is a valuable sign, which clearly differentiate this condition from acute appendicitis. If the child is turned to left side in lying posture for 5 minutes, the site of maximal tenderness will move towards the left than the original site, while in a case of acute appendicitis tenderness remains at the same spot (McBurney's point).
- **On rectal examination** - there may be tenderness on right side of pelvic.
- **Leukocytes count:** There is often a leucocytosis of 10,000 - 12,000 /ml or more.

Treatment

As the prognosis is excellent and complete recovery almost always occurs without specific treatment, no specific treatment is required except assurance and bed rest. Only when it becomes difficult to exclude acute appendicitis, appendicectomy is performed.

Meckel's diverticulitis

Kindly read this topic on page no 598.

Rectal polyp

Kindly read this topic on page no. 624.

Exomphalos

An exomphalos is a variety of *congenital hernia* in which, a part of mid gut fails to return to the abdominal cavity during early fetal life due to normal developmental

Figure 53.7(a): Exomplalos; Note the intestine is covered by a membrane

failure. The basic defect is in the failure of fusion of the anterior abdominal wall Abdominal organs remains protruded out side the abdominal cavity, **being covered by a membrane,** a middle layer of wharton's jelly and an inner layer of peritoneum. Exomphalos may be divided in *exomphalos minor* and *exomphalos major* depending upon the size of defect of anterior abdominal wall. Generally; **if the defect is less than 4 cm it is called as exomphalos minor and if the defect is more than 4 cm it is called as exomphalos major.** (Fig. 53.7a)

For further details please read this topic on page 782.

Gastroschisis

Gastroschisis is an congenital abnormality where the bowel loops (intestine) is seen protruding out through abdominal wall, usually to the right of the umbilicus. Unlike exomphalos where- the protruding viscera are covered by a membrane, in Gastroschisis the protruding intestinal loops floats freely naked on anterior abdominal wall. The bowel loops are prone to direct injury. (Figure 53.7b).

Prune Belly Syndrome

Prune belly syndrome occurs almost exclusively in males. In addition to a lax abdominal wall, these babies show bilateral abdominal testes and dilatation of ureters and urinary bladder. However, renal parenchymal function is preserved until late and does not require operative intervention unless there is specific obstructive lesion. Despite orchidopexy, done at 6-12 months when lax abdominal wall is reconstructed, fertility is unlikely. (figure 53.7c), next page.

Choledochal Cyst

Choledochal cyst is a rare congenital dilatation of extrahepatic and/or intra hepatic biliary tract. Though *it is a congenital condition,* most patients frequently present in infancy/childhood, the disease is more commonly diagnosed in adult. The incidence of choledochal cyst is 1 in 100,000. Choledochal cysts are three to eight time more common in women than men. For further details please read more on page no. 501.

Omphalocele	Gastroschisis
Bowel and solid viscera are **covered by peritoneum** and amniotic membrane.	No overlying sac.
Umbilical cord inserts into the sac.	Umbilical cord lies to the left of the defect.
Higher incidence of **congenital anomalies** and pulmonary hypoplasia.	Associated anomalies are rare except for a 10-15% rate of intestinal atresia.
Higher morbidity and mortality.	Lower morbidity and mortality.
Omphalocele can be repaired **electively.**	Require urgent surgical treatment to protect the exposed intestine.
Poor prognosis.	Good prognosis.

Figure 53.7(b): Omphalocele (left), Gastroschisis (right); Note the intestine is lying naked in Gastroschisis

*****

Absent abdominal muscles
(Lax abdominal wall)

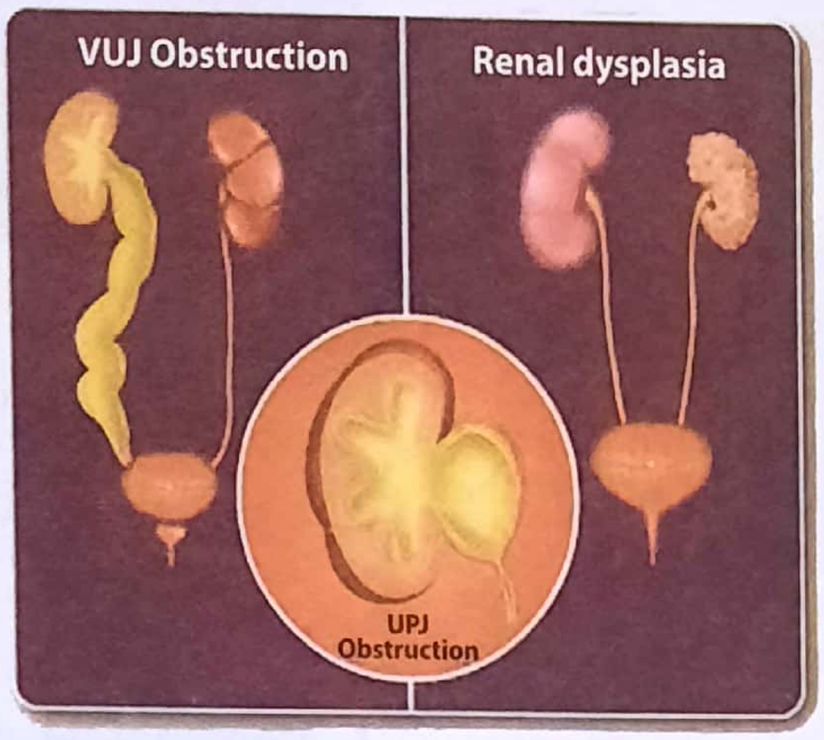

Severe urinary tract malformations

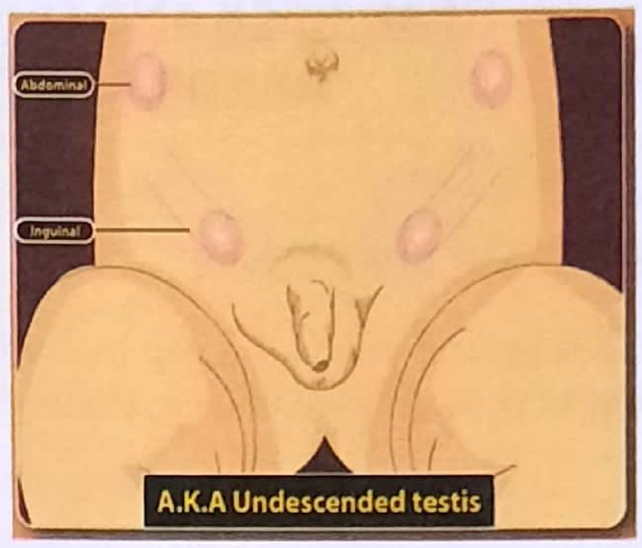

Bilateral cryptorchidism

Figure 53.7(c): Prune Belly Syndrome (triad of abnormalitis)

Congenital Hernia/Hydrocele

Congenital hydrocele, is in which there is patent processus vaginalis*, which allows fluid from the abdominal cavity to collect in the scrotum. If this communication is wider; it will allow intestine to come out through this opening and a congenital hernia results. Usually the communication is rather narrow and when the patient lies down (eg. at night) the hydrocele may slowly empty itself and may again appear when the patient assumes an erect posture during day hours. (figure 53.8)

Processus vaginalis is an outpouching of peritoneum attached to the testicle that trails behind as testis descends retroperitoneally into scrotum. When obliteration of the processus vaginalis fails to occur, inguinal hernia results.

It may also be possible, to empty the hydrocele by applying gentle pressure on hydrocele. In complete congenital hernias the contents in the sac extend down to scrotum; whereas in incomplete hernias the contents extend only up to some part of the canal.

Diagnosis is by clinical examination. Ultrasonography of scrotum may sometimes be used to exclude a testicular tumour or hematocele.

Treatment of a congenital hydrocele and congenital hernia is **always surgical. The** fundamental principle on which surgical treatment is based is the elimination of vestigial structure, the patent processus vaginalis. Cure of such conditions can be achieved by closure of the abnormal opening in the peritoneum and removal of the portion the persistent processus vaginalis; which nature has failed to obliterate.

In congenital hydrocele; fluid is present in layer of processus vaginalis, which communicates with peritoneal cavity (thus, it is in fact, a indirect inguinal hernia with fluid content). The **treatment to this condition is herniotomy.** *(AIIMS JUNE 01, KERALA 97)*, ie; excision of hernial sac, which is patent processus vaginalis. The treatment of congenital hernia is also herniotomy.

*****

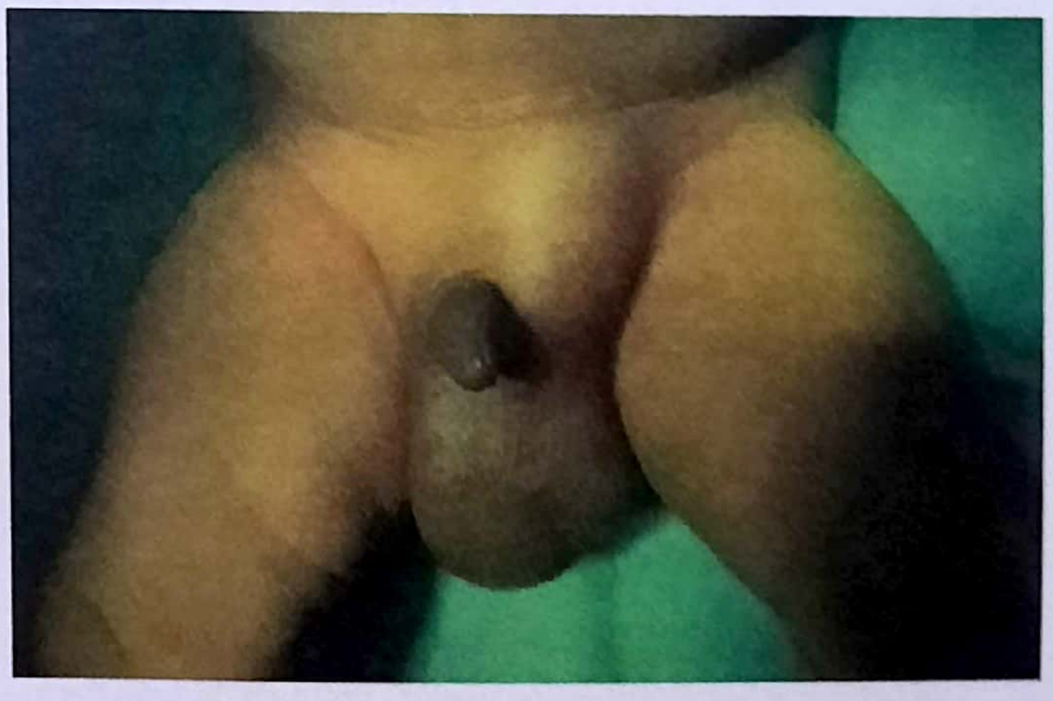

Figure 53.8: Congenital hernia (Right side)

HEAD NECK AND SPINAL CORD ABNORMALITIES

Cleft Lip and Palate

Cleft lip and palate is a gap in the lip; mostly congenital but may be acquired due to trauma.

The **cleft (hare) lip** occurs *due to failure of fusion* between the maxillary process of one side (forming the lateral parts of lip) and medial nasal process (forming the central area or 'Philtrum'). The nasal deformity usually accompanies the cleft lip in form of a broadened and depressed nostril.

The **cleft palate** occurs *due to failure of* palatal processes of maxilla to fuse with each other and with the pre-maxilla (developed from the medial nasal process) *(PGME)*.

For further details please read this on page 180-182.

NEURAL TUBE DEFECTS

The central nervous system develops from dorsal ectoderm known as the neural plate, which in early fetal life folds along its length to form the neural tube. The surrounding mesoderm forms the skull and vertebral column and is covered over by skin. Defective closure of neural tube may occur through out its extent but is most common on lower end than upper end. Please see key box 53.4.

KEYBOX 53.4	
Neural Tube Defect	
(A) Defective closure the caudal end	**(B) Defective closure of cranial end.**
• Spina bifida occulta	• Occipital meningocele
• Meningocele	• Anencephaly
• Meningomyelocele	
• Spina bifida	

A. Defective Closure of The Caudal End

Spine bifida is a disorder, in which the vertebral arches of lower vertebrae are not fused posteriorly. There are several degrees of severity. It has been discussed below in *order of increasing severity.*

1. Spina bifida occulta

It is the mildest form and is characterized by failure of vertebral fusion only. The overlying skin often shows a dimple or a tuft of hair. In few cases a sinus can be seen connecting the skin and the spinal canal. All these patients have increased incidence of meningitis, hydrocephalus and Arnold Chiary malformation*.

Arnold Chiary malformation: Condition in which the inferior poles of cerebellar hemispheres and medulla protrude through the foramen magnum into spinal cord.

2. Meningocele

This is more severe degrees of anomaly than occulta. In meningocele there is associated protrusion of a meningeal sac filled with C.S.F. through the vertebral defect. It is **most common in Lumbo sacral spine. There** is usually ***no features*** of nerve paralysis affecting the lower limbs and or bladder or bowel involvement. It is a *brilliantly trans-illuminant swelling and transmitted pulsation* may be present. *(MANY PGME)*

3. Meningomyelocele

It is more serious form than meningocele, and is **commonest variety** of spine bifida. *(MANY PGME) The* **commonest site** is **lumbosacral region** *(MANY PGME)*. There occurs failure of development of normal skin at the summit of the swelling, and at this point meninges, the spinal cord, and the nerve are attached and swelling may burst through this potentially weak point. Associated paralysis of the lower limb, bladder incontinence and rectal incontinence are common features of meningomyelocele. Transillumination test shows neural tissue as a dark shadow.

4. Spina bifida aperta

It is most severe and fortunately very rare form of spina bifida, which results from complete failure of fusion of caudal end of neural plate. The neural plate open on the skin surface. Severe neurologic defects in the legs, bladder, and rectum are present.

B. Defective Closure on The Cranial End

Neural tube abnormalities at the cranial end are less common. Complete failure of development of the cranial end of the neural tube results in **anencephaly;** which is incompatible with life.

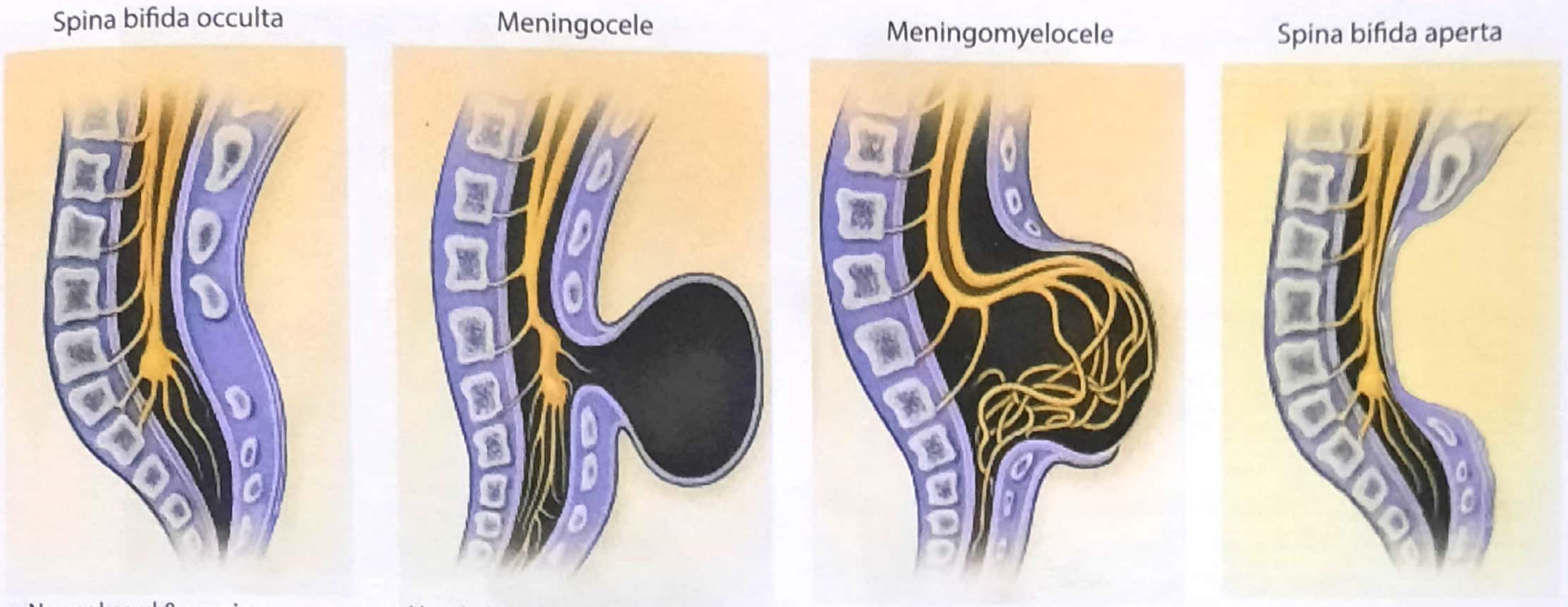

Figure 53.9: Neural tube defects (caudal end)

Occipital meningocele is protrusion of a CSF filled sac of meninges through the skull in the occipital region. An **encephalocele** is similar but contains brain matter in the meningeal sac.

Clinical presentation

Spina bifida occulta

This is a common abnormality that is usually asymptomatic and discovered when a radiograph of the lumbosacral spine is obtained. Rarely, these patients have an associated fistulous communication between the skin and the spinal canal that predisposes to recurrent meningitis in childhood. Also rarely, there may be a keratin filled epidermal cyst in the spinal canal that may leak; causing chemical meningitis.

Meningocele, meningomyelocele, and spina bifida aperta present at birth with a detectable lesion in the lumbosacral region.

Meningocele

This is cystic and transilluminant, fluctuant, compressible swelling and is not associated with severe neurologic deficit.

When child cries, an expansile impulse is present. On palpation the swelling, a bony defect in spinal cord is usually found.

Meningomyelocele

This shows neural structures on transillumination of the cyst and is associated with lower limb weakness and with bladder and rectal dysfunction.

Spina bifida aperta

It appears as a flat lesion in which the open spinal cord is visible and produces a profound neurologic deficit.

All of these patients have an increased risk of meningitis and hydrocephalus from the frequently associated Arnold Chiary malformation.

Anencephaly

It is incompatible with life after birth. Occipital meningocele and encephalocele are similar to their spinal counterparts. The most common location of the cystic mass is the nape of the neck. When very large, an occipital meningocele may obstruct normal delivery of the baby.

Treatment

- Spina bifida occulta usually do not require treatment but surgical treatment is indicated when neurological, urological or orthopaedic symptoms progress or appear after infancy.
- The treatment of meningocele is by excision of sac. Majority of patients with meningocele recover after operation. Later on, a few may develop hydrocephalus.

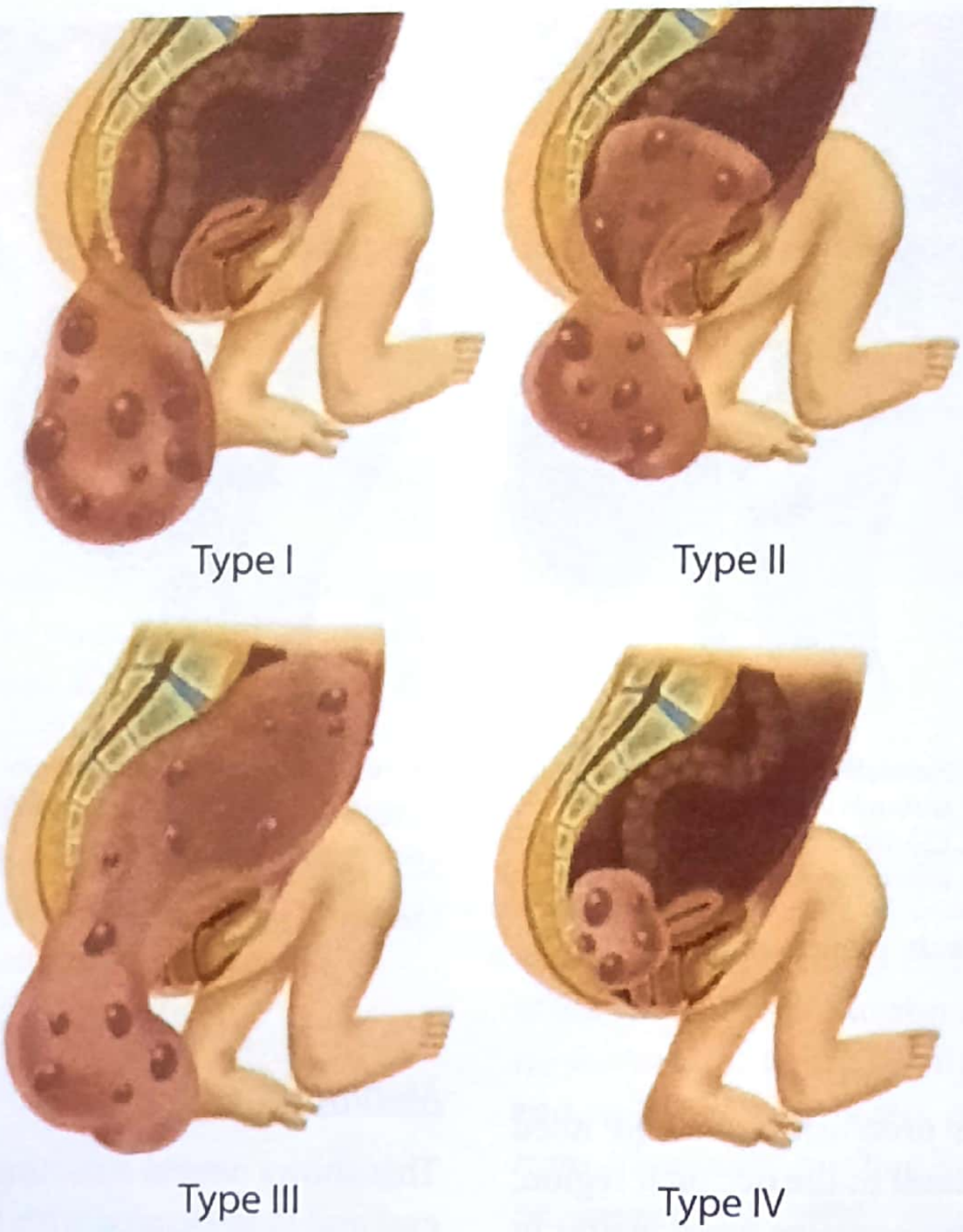

Figure 53.9(Extra): Sacrococcygeal Teratoma

- Meningomyelocele is treated by excision of sac, sparing and replacing spinal cord and nerves in the spinal canal.

****

Sacrococcygeal Teratoma

It is an uncommon tumour of infancy/childhood. Teratomas are tumours composed of tissue from all three embryonal layers. A sacrococcygeal teratoma usually presents as a large mass extending from sacrum. Though uncommon; it is one of the most common large tumour in infancy. Females are more affected than males. The tumour arises between the sacrum and rectum and is firmly attached to the coccyx and occasionally to last piece of sacrum. They are broadly classified into two types:-

(i) Tumours growing outwards from the region of the coccyx with little or no pelvic extension.

(ii) Tumour growing inward from the region of the coccyx with large pelvic extension.

Most tumours are benign but with advancing age; malignant potential increases. (Figure 53.9 Extra)

Treatment

The treatment consists of excision of tumour soon after birth. A delay in treatment may result in ulceration and malignant changes. Cure rate is excellent after resection. Most tumours can be excised by perineal route; however for large retrorectal tumours an abdominoperineal operation is recommended. The coccyx must always be excised.

*****

Cystic Hygroma

It is a multilocular cystic swelling of clear lymph and considered as a benign lymphatic tumour. Cystic hygroma develops as a result of sequestration of a portion of the jugular lymph sac in the neck from the lymphatic system. *Cystic hygroma has been found in association with Turner's syndrome.* The lesion consists of *multilocular cysts,*

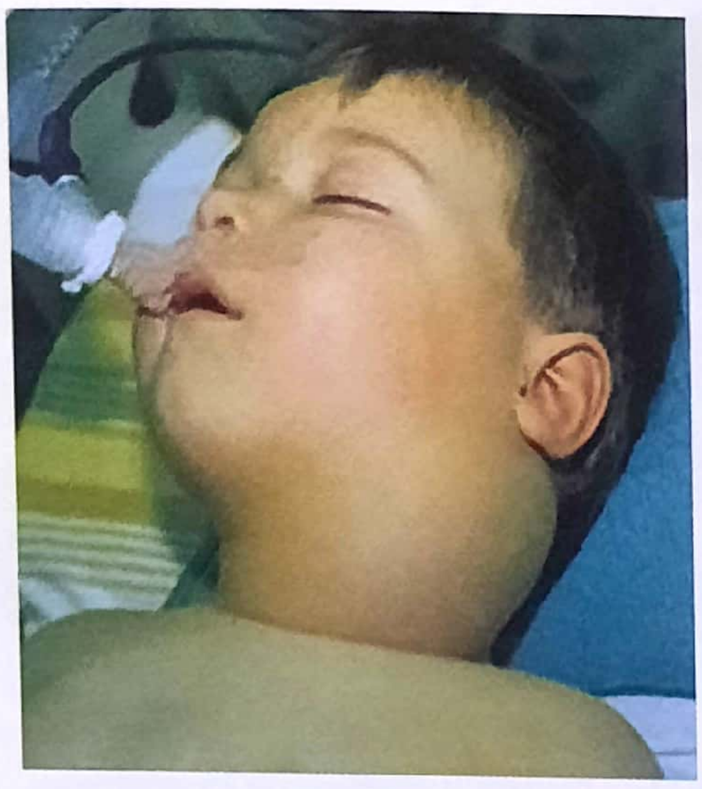

Figure 53.10: A patient with cystic hygroma

deeper the cysts smaller is their size, and if it presents as a single swelling, it is called as ***hydrocele of neck.***

Please read this topic on page no. 181-182 for details.

Cogenital torticollis: Please read this on page no.183

*****

SKIN LESIONS

Hamartoma

The term hamartoma was first given by albrecht in 1904. The term hamartoma is derived from a Greek word which means 'fault' or 'misfire' its original meaning was 'missing the mark in spear throwing'.

A hamartoma is a developmental malformation consisting of a tumour like overgrowth in which the tissues of a particular part of the body are arranged haphazardly, usually with an excess of one or more of its components. A large number of common lesions fall into the general category of hamartoma.

Common lesions included in this group are benign pigmented moles, majority of angiomas and neurofibromas.

Characteristic Features

(i) Most hamartomata are present at birth or in early years of childhood. But usually only those on exposed areas like the skin and mouth will be recognized early. Other tumours will be recognized late, though no doubt the original nidus was present at birth.

(ii) Its growth is coordinated with that of the surrounding tissues and growth stops after adolescence.

(iii) It may regress, which is typically seen in strawberry hemangioma.

(iv) It may be multiple, eg; typical example being neurofibroma.

(v) There is no capsule around a hamartoma. It grows along with its surroundings, so there is no question of any connective tissue condensation.

(vi) Hamartoma is not a tumour, but it is quite possible for a tumour to develop in a hamartoma.

(vii) For all practical purposes the lesion is benign and it very rarely changes into malignancy.

(viii) Hamartoma may be associated with an obvious chromosomal abnormality.

Examples of hamartoma are:

(a) Vascular hamartoma-known as hemangiomas.

(b) Benign nevus.

(c) Angiomatous syndromes (often multiple)

  (i) Hereditary hemorrhagic telangiectasia.

  (ii) *Sturge weber syndrome*- in which there is combined hemangioma over one-half of the face with hemangioma of the ipsilateral cerebral hemisphere.

(d) Glomus tumour.

(e) Lymphangioma.

(f) Neurofibroma (Von Recklinghausen's disease)

(g) Skeletal hamartoma-solitary exostosis and diaphyseal aclasis.

(h) Adenoma sebaceum.

HEMANGIOMA

A hemangioma is a developmental malformation of blood vessels and is not a typical tumour; so it should be considered to be an example of hamartoma. Such theory can be explained by the facts that:

(i) Hemangioma is often present since birth and

(ii) It never turns malignant.

Types of hemangioma

There are mainly three types of hemangiomas.

1. Capillary hemangioma- arising from capillaries.
2. Venous or cavernous hemangioma- arising from the veins.
3. Arterial or plexiform hemangioma-arising from arteries.

Hemangioma may occur anywhere in the body though it is more common in the skin and subcutaneous tissues.

Now lets discuss them one by one:-

1. Capillary hemangioma

Mainly three varieties of capillary hemangiomas are seen:

(a) Strawberry angioma (strawberry nevus)

(b) Portwine stain

(c) Salmon patch

(a) Strawberry angioma

Characteristic features are:

(i) The typical history is that the red mark is noticed after 1 to 3 weeks of birth. This red mark gradually increases in size for a few months till it takes a typical strawberry or raspberry like swelling.

(ii) The subcutaneous tissue as well as the skin is often involved. Sometimes muscles may be affected.

(iii) Clinically the swelling is compressible.

(iv) After the first birthday the angioma gradually regresses in size and involution may be complete by the age of 7 to 8 years, *(MANY PGMEE)*

(v) On examination- This is bright or dark red in colour. This slightly protrudes from the skin surface and appears as a sessile hemisphere. The surface is irregular and there may be small areas of ulceration covered with scabs. Strawberry angioma is soft. It is compressible but not pulsatile. Sustained pressure will squeeze most of the blood out of the hemangioma leaving it collapsed. As soon as the pressure is released refilling occurs quickly.

(b) Portwine stain *(NEET)*

Characteristic features are:-

Figure 53.11: Portwine stain

(i) It is **usually present since birth and does not show any change for the rest of the life.** The size gradually varies in proportion to the whole body. *(MANY PGMEE)*

(ii) It is common on the face and at the shoulders, neck and buttock. (figure 53.11)

(iii) This is deep purple-red in colour which may become paler in later life.

(iv) There is no definite swelling; but a diffuse vascular deformity.

(v) With pressure the colour diminishes in intensity, but when the pressure is released the colour of the lesion takes time to reappear as the feeding vessels are also abnormal.

Sturge-weber syndrome-A facial port-wine stain may be associated with hemangioma of the ipsilateral cerebral hemispheres which may lead to jacksonian epilepsy.

(c) Salmon patch

Characteristic features are:

(i) This is present since birth

(ii) It is usually disappears before the first birthday

(iii) It is mostly seen over the forehead or occiput or anywhere in the midline of the body.

Treatment

(i) Wait and watch policy should be adopted, as majority the capillary hemangiomas disappear on their own.

(ii) If the lesion exists even after 8 years and the patient and the parents insist on cosmetic treatment, the following may be tried.

(a) Excision of the lesion with skin grafting.

(b) Carbondioxide snow application.

(c) Injection of hot water or hypertonic saline or sclerosing agent may be tried if strawberry angioma persists.

(d) X-ray therapy has not proved very successful yet may be considered in failure cases. It causes disturbance of growth, necrosis of skin, pigmentation and ulceration.

(e) Injection of steroids.

2. Cavernous/Venous hemangioma

It consists of multiple dilated venous channels. It is a spongy swelling.

Characteristic features are:

(i) It is usually present since birth.

(ii) It does not show any tendency to involute. On the contrary it may become larger and more troublesome as the time goes on.

(iii) These are always raised from the surface and are localized swellings.

(iv) These are bluish in colour as the content is venous blood.

(v) These are non-pulsatile.

(vi) Compressibility can be seen. Continued pressure and squeezing will drive the blood out of the lesion and the swelling crumbles. As soon as the pressure is removed swelling reappears with refilling

(vii) Common sites are

(a) Face, cheek, ears.

(b) In the mucous membrane of lips, mouth and tongue.

(c) In the organs like liver, kidney and brain.

Treatment

(i) Conservative treatment is more often required in either of the following form:-

(a) Injection of sclerosing agent in to the lesion. In this respect 3% sodium morrhuate is quite effective otherwise boiling water or hypertonic saline may be tried. The injection is given once a week; upto 6 weeks if necessary.

(b) Cautery treatment may be applied to the hemangioma. A needle is pushed into the hemangioma and its end is touched with a diathermy.

(ii) Surgery is a better treatment if the swelling is small and localized. The feeding vessels are ligated and the whole skin is excised. Diathermy may be required to control hemorrhage.

3. Arterial or Plexiform hemangioma

It is a type of congenital arteriovenous fistula. There is a pulsatile swelling of arteries and the veins become arterialized i.e; tortuous and the thick walled and pulsatile, feeling like a bag of pulsating earthworms. This is often called **cirsoid aneurysm.** Such cirsoid aneurysm is commonly seen on the forehead or in the scalp over the temporal region.

Treatment

1. Ligation of feeding vessels.
2. Therapeutic embolism of the feeding artery.
3. After ligation of feeding vessels excision on the lesion with diathermy.

*****

LYMPHANGIOMA

Like hemangioma, it is congenital in origin. It is localized cluster of dilated lymph sac in the skin and subcutaneous tissues; which can not connect into the normal lymph system grows into lymphangioma.

Types: Mainly there are 2 types of lymphangioma:

(a) superficial variant presents as circumscribed lesion which appears as small blisters and slightly elevated skin patches. These lesions are called lymphangioma circumscriptum.

(b) Deep lesions are large, cystic, translucent and may be seen in the neck, mediastinum or axilla. These are called cystic hygroma.

Clinical features

- Lymphangioma are present since birth.

- Usually the disfigurement is noticed by the child's parents. Sometimes small vesicles may leak clear fluid. Occasionally the vesicles may be rubbed with the clothes and get infected and become painful, otherwise this lesion is painless.

  (i) *Site-* Lymphangioma circumscriptum are found at the junction of the limbs and at the junction of the neck with the trunk, i.e. around the shoulder, axilla, buttock and groin. Cystic hygroma are commonly seen in the neck, axilla, mediastinum etc.

  (ii) *Colour-* Skin vesicles contain clear fluid and looks yellow or watery. When such vesicle contains blood they turn brown and even black.

  (iii) *Size-* Lymphangioma circumscriptum are small lesions, whereas cystic hygromata are big lesions.

  (iv) *Consistency-* is soft and spongy. These ar translucent swellings fluctuation and fluid thrill is present.

  (v) *Regional lymph* nodes usually do not enlarge until and unless the lesion gets infected.

Treatment

Surgical excision is the treatment of choice. Radiotherapy has no place. When excision is complete there is no chance of recurrence and cure is complete and permanent; however sometimes complete excision becomes difficult and excision remains incomplete. Even then this condition is rarely associated with recurrence.

*****

OTHER COMMON CONDITIONS

Umbilical Hernia

This is a hernia through a weak umbilicus and is due to a defect in development of abdominal muscle. The hernia is often symptomless; but increases in size on crying and assumes a classical conical shape. Strangulation in this hernia is extremely rare; because the neck is wide.

Treatment

No treatment is required in about 95% cases with umbilical hernia *(MANY PGME)*, reassurance to the parents is all that is required. Most of them are spontaneously cured (closed) by the age of 12-18 months. To hasten the disappearance of umbilical hernia, 3-4 coins covered by cotton is placed over the hernia and is strapped with leucoplast. This strapping is maintained for three weeks. If the hernia does not disappear by itself at 2 years of age or older-then hemiorrhaphy is indicated.

Diaphragmatic Hernia

1. Hernia through the foramen of Morgagni (Parasternal hernia)

This is due to congenital defect in fusion of sternal (ventral) and costal (lateral) part of diaphragm. Through present since birth, majority of defects are detected in adulthood, and 90% of them are on right anterior side. *(AI 07, AIIMS NOV 06)*. Omentum or transverse colon are two most common structure that usually herniate through this defect.

Treatment

When a definitive diagnosis is established repair of the hernial defect is advocated, even if there are minimal symptoms.

2. Hernia through the foramen of Bochdalek (Pleuro-peritoneal hernia)

This may result due to failure of fusion, between the dorsal and ventrolateral parts of developing diaphragm. It is the most common type of all congenital diaphragmatic hernia, it is more common on left side. Because major part of the thorax is filled with herniated abdominal organs (stomach, small intestine, transverse colon) there occurs hypo-plasia of respiratory system ie; decrease in size and number of bronchi and alveoli resulting in respiratory distress.

Clinical feature

Triad

- Cyanosis
- Dyspnea
- Cardia dextroposition

Physical examination reveals scaphoid abdomen, *decreased breath sound and presence of bowel sound in the chest.*

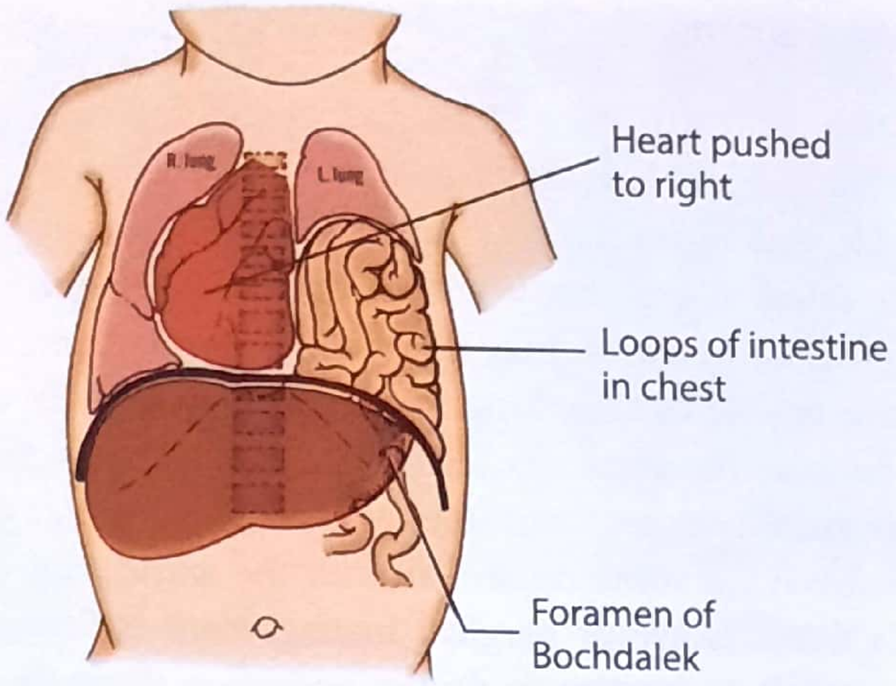

Figure 53.12: Hernia through foramen Bochdalek

Diagnosis

Plain X-ray chest: An AP view shows *mediastinal shift and air filled intestinal loops in chest,* (MANY PGME)

Treatment

Only surgical treatment will be beneficial. Laparotomy (Opening of the abdominal cavity) is done and hernial defect is identified and reduced. Abdominal contents are brought back in abdominal cavity and hernial defect is repaired. There is high mortality even after satisfactory repair, because of existing congenital pulmonary hypoplasia.

Undescended Testis

Kindly read this topic on page no. 893.

Phimosis

Kindly read this topic on page no. 882.

Acute Scrotum In Pediatric Age Group

Acute scrotum refers to the common clinical setting of a boy first seen with pain in the hemiscrotum, which may or may not be accompanied by swelling and redness of the overlying skin of the same hemiscrotum.

Such a scenario always has a degree of urgency attached to it because (1) the possibility may exist that the underlying testis on that side may be in risk of permanent ischemic damage, and (2) the condition can be excruciatingly painful and require urgent relief for the comfort of the child. A number of possibilities exist for the cause of the acute scrotum, and in most instances symptoms and signs are such that the clinical diagnosis can be reached and a rapid course of intervention planned without the need for additional diagnostic tests. Please see figure 53.13.

Causes of Acute Scrotum

- Torsion of the appendix testis
- Torsion of the testis
- Epididymitis
- Idiopathic scrotal edema
- Trauma
- Other possible conditions
  - Incarcerated inguinal hernia
  - Acute hydrocele
  - Vascular orchitis
  - Rare infections

1. Torsion of the appendix testis

Incidence

The incidence of torsion of the appendix testis, or one of the other appendages is the commonest cause of the acute scrotum by far. The torsion of the appendix testis is 4 times more common than true torsion of the testis.

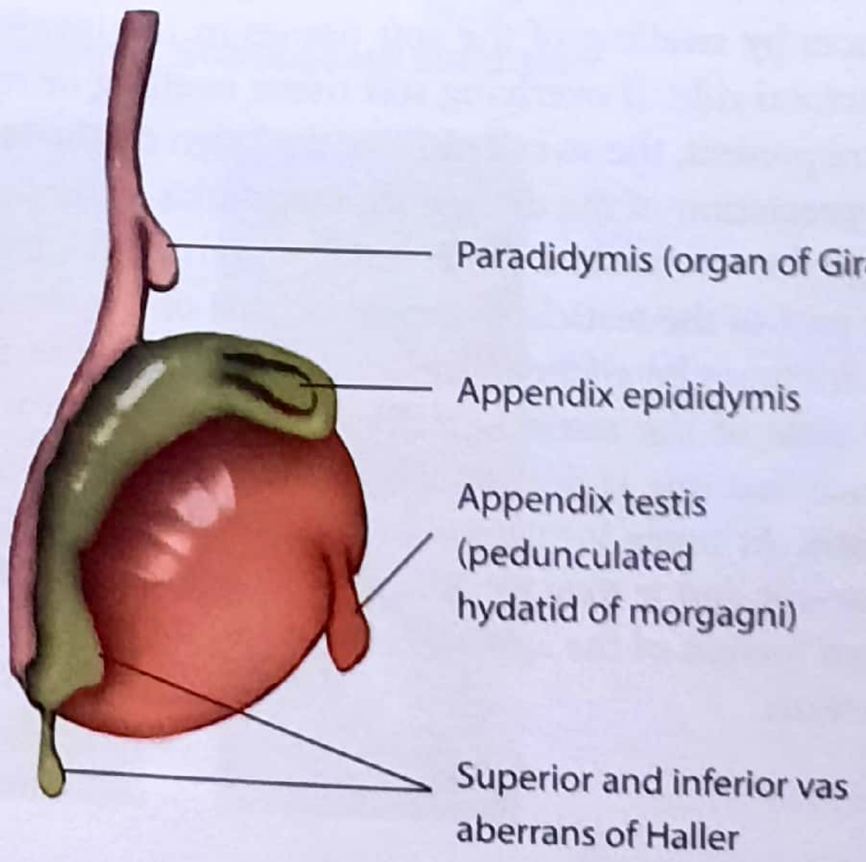

Figure 53.13: Testicular appendages

Etiology

The exciting factor in torsion of the appendix testis is not known. Studies demonstrated that the appendix testis has both estrogen and testosterone receptors. The appendix testis represents a vestigial remnant of the Mullerian duct, so the presence of estrogen receptors is predictable, but the presence of testosterone receptors as well is somewhat surprising. Therefore it is possible that elevation of either of these hormones in the bloodstream may produce swelling of the appendage, which may in turn predispose the structure to twisting on its narrow stalk.

Presentation

Torsion of the appendix testis occurs mostly in 7 to 10 year- old boys but can occur in younger patients and also can occur in postpubertal boys. Onset of pain is usually gradual but can on occasion be sudden and may even be accompanied by nausea and vomiting.

Characteristically boys tolerate the pain and be reluctant to tell their parents. Eventually the pain starts to interfere with walking, playing, sports or the ability to attend school. As the pain gets worse, the boys often walk with a wide-based gait. What is not readily explainable is that in some of these boys the torsion is accompanied by redness and swelling of the associated hemiscrotal skin and soft tissues. However other boys can have complete gangrene of the appendix testis without any accompanying scrotal signs.

Examination of Scrotum

Examination of the scrotum in these boys often reveals redness in the overlying skin, accompanied in some instances by swelling of the soft tissues in the involved hemiscrotal side. If overlying soft tissue swelling or redness are present, the so called "blue dot" sign can be seen the appreciation of the discoloured testicular appendage through the scrotal skin. Differential tenderness from the upper part of the testicle to the lower part of the testicle can sometimes be elicited. The tenderness related to the upper pole of the testis is really conclusive diagnostic evidence that one is dealing with torsion of the appendix testis. At times localization of the tenderness is not so clear-cut and it may be difficult to tell the difference between torsion of the appendix testis and torsion of the entire testis.

Management

The natural history of torsion of the appendix testis is that the acute onset of pain will subside as the appendix undergoes ischemic involution. It will then become a calcified free body within the tunica vaginalis. This process, however, may take many days and many boys are unable or unwilling to put up with the discomfort. Because the appendix testis has no known function; the possibility exists that these cases could be treated conservatively. In some centers around the world; this is what is done. However surgical management is favoured by most. It is practice to do the operation through a midline scrotal incision and to explore both side and remove the necrotic appendix testis and the testicular appendage on the opposite side. Fixation of both testes via window orchidopexy is also recommended to prevent the future complication of torsion of the testis.

2. Torsion of testis

Incidence

Torsion of the testis occurs less frequently than torsion of one of the appendix testes, in about 1:4 ratio. However, the exact incidence is not known. The relative rarity of the condition is probably responsible for its often missed diagnosis, and the general ignorance in the medical community about the consequences of torsion of the testis makes its misdiagnosis even more potentially tragic. Torsion of the testis may lead to reduced or complete infertility, and that the time taken for the testis to become irreversibly damaged can be as short as 3 hours. Thus urgency of detorsion is to be emphasized. Delay can result in permanent testicular damage.

Etiology

The exact etiology of torsion of the testis is unknown. Many theories have been advocated including twisting by the cremasteric muscles or an abnormal high "lie" of the testis. Neither of these theories has ever been proven. A long mesorchium is the only anatomic variant that predisposes to torsion of the testis, but how the testis twist on this mesorchium is not really understood.

Presentation

Testicular torsion can occur at any time during childhood or early adolescent life and indeed even into adult life. However, the peak periods for torsion of the testis

KEY BOX 53.5	
Effects of Torsion	
Duration of Torsion (hrs)	**Testicular salvage (%)**
<6	85-97
6-12	55-85
12-24	20-80
>24	<10

occur before age 3 years and then after the onset of puberty. It is rare for torsion of the testis to occur between age 3 years and puberty and even rare for it to occur after about age 25 years.

Torsion of the testis is usually heralded by the sudden onset of severe lower abdominal pain, accompanied by vomiting, followed by localization of the pain to either the right of left testis. Boy who have had both trauma and torsion will describe the sickening feeling of being hit in the testis as the same as that felt in the early stages of torsion. With torsion of the testis, the* testis retracts up toward the groin.

If prompt treatment is not sought, then swelling and redness of the hemiscrotum will soon occur. The pain of torsion is usually described as sudden and excruciating but can at times be of dull and has less dramatic onset.

Torsion of the testis in those younger than the infant and toddler age group often is discovered late and in most of these cases the testis is already beyond salvage at exploration. The first signs may be a wide- based gait or redness and swelling of the hemiscrotum noticed by parents at change of diaper time and bath time.

Examination

Examination of the affected patient will often reveal a tender, swollen testis accompanied by varying degrees of redness and soft tissue swelling. Usually no differential tenderness is found between the upper and lower poles of the involved testicle. If any doubt exists in the diagnosis from a clinical point of view, then Doppler ultrasonography (US) can be used to demonstrate reduced blood flow to the involved testis. However, this test is not completely reliable and must not be used to exclude torsion.

Prehn's Sign: *The pain is not relieved by elevation of the scrotum.* ***(AIIMS 99)***

NOTE: Elevation of the scrotum usually relieves the pain in epididymo-orchitis

An important D/D of testicular torsion ***(MANY PGME)***

Treatment

The aim of management is to restore the blood supply to the testis as soon as possible. This can be done only by open exploration. Once the testis has been untwisted, then its co-

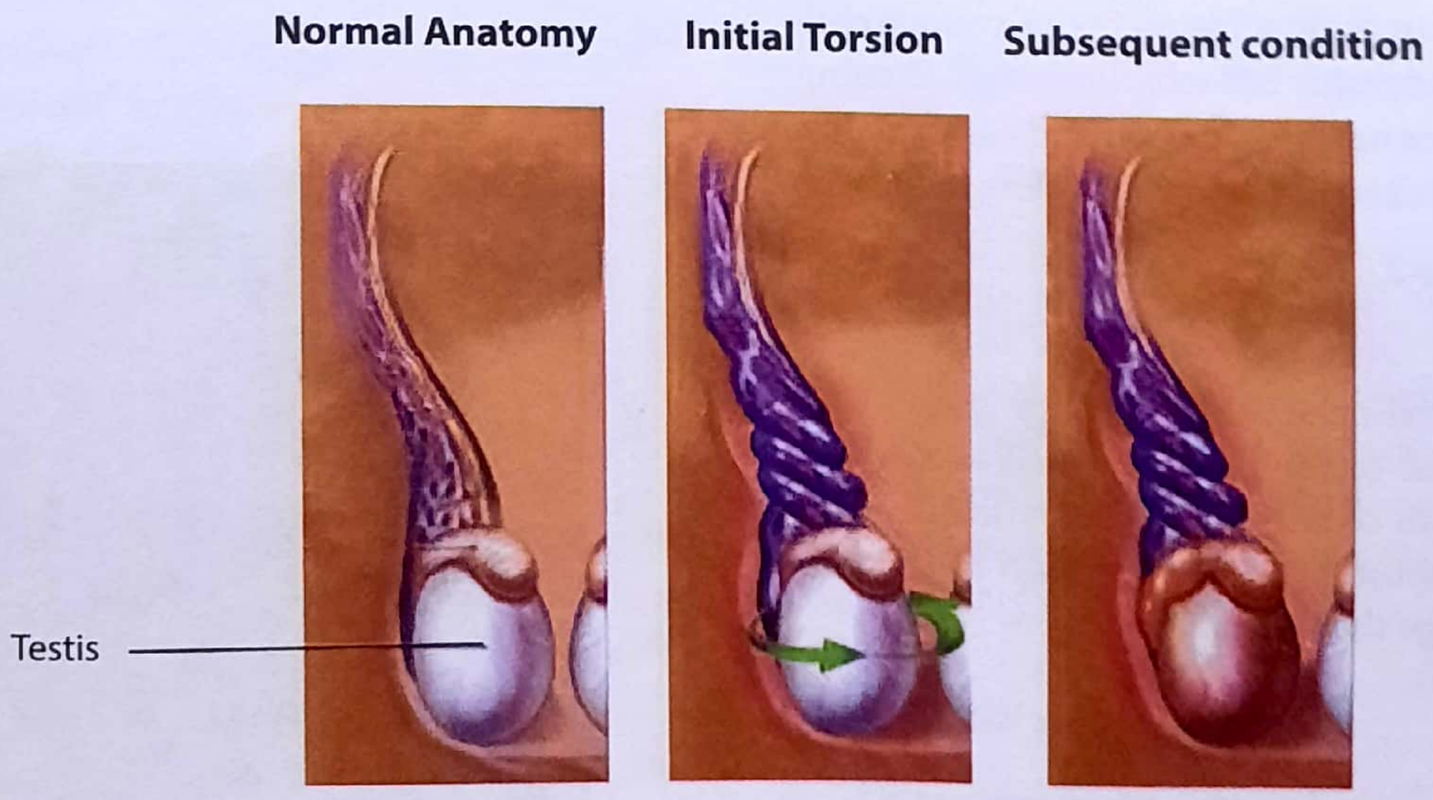

Figure 53.14: Testicular torsion

lour must be observed to see whether any recovery is likely. If no return of colour is noted, then orchidectomy must be undertaken, as retention of the testis may result in further damage to the normal remaining testis. Conversely, if the testis colour improves as arterial flow is reestablished , then fixation of the testis to prevent a recurrence of the torsion must be undertaken, usually in the from of a window orchidopexy/dartos pouch. *It is very important then to explore the contralateral side and also fix other testis also* (MANY PGME). Recovery is usually rapid, but these patients need to be followed up for at least 12 to 24 months to ensure that atrophy of the affected testis does not occur and that testicular growth is maintained.

Prognosis

If the testis is significantly damaged by ischemia or is completely infarcted, or both then an incidence of infertility occurs in between 40% and 50% of cases.

Although a wide range of success has been reported in detorsion of testis, it has been shown that testicular torsion of longer that 6 hours is unlikely to be accompanied by testicular recovery. Please see key box 53.5 on page no 967. The observations support the concept that after 6 hours of ischemia, recognizable changes are seen in the contralateral testis, the exact mechanism of how this occurs is unknown. It is thought to be perhaps the result of an autoimmune -mediated injury of the contralateral testis.

3. Acute epididymoorchitis

Acute epididymitis is an infrequent finding in the pediatric population and accounts for approximately 10% to 15% of patients with an acute scrotum in the average children's hospital. Epididymitis has a biphasic age distribution, with a peak in the newborn period and early infancy & a second much smaller peak during adolescence.

Presentation

Epididymitis in the neonatal and infant age group usually is first seen as the onset of redness and swelling of the hemiscrotum, with or without fever. Irritability may bring the reddened scrotum to the attention of the parents when they change the diaper.

Examination

Examination in cases of epididymitis usually reveals induration and swelling in the hemiscrotum, which is extremely tender. The edema in the surrounding soft tissue often will make palpation of the testis itself very difficult.

Management

Although urine culture provides a bacterial etiology in a small percentage of cases, it should still always be included as a routine study. Because of torsion of the testis in the same age group, scrotal exploration is mandatory. If exploration of the scrotum reveals acute epididymitis, cultures of the epididymis should be taken in an attempt to determine the causative organism. If acute epididymitis is seen, the contralateral side should not be explored.

Antibiotics should be commenced immediately, with the recommendation that these be broad spectrum and aimed at urinary pathogens. Obviously on a successful culture result the antibiotic regimen may have to be altered.

Also read this topic on page no. 905.

4. Idiopathic scrotal edema

In the differential diagnosis of the acute scrotum in childhood, idiopathic scrotal edema is probably the fourth most common condition encountered. It begins as redness and swelling in either the perineum or inguinal region; which seems to spread into the hemiscrotum. The hemiscrotum then becomes uncomfortable and sometimes painful and considerable soft tissue swelling is noted in the wall of the scrotum.

Figure 53.15: Idiopathic scrotal edema

Etiology

The etiology of idiopathic scrotum edema is unknown. Speculation about some kind of allergy, possibly to insect bite or to a sudden change in temperature, such as plunging into cold water has been proposed. The concept of an allergic etiology is further strengthened by the fact that if often responds to a single dose of antihistaminics. Scrotal edema is a self- limiting condition and recurrence is rare.

Presentation

Idiopathic scrotal edema usually has an insidious onset with pain, redness and swelling in the scrotum and also in the surrounding adjacent perineum and sometimes into the groin. It usually affects boys between the ages of 5 and 9 years. (Figure 53.15)

Examination

Examination usually reveals a nontender testis but some discomfort in the scrotum, some edema in the scrotal wall and also spreading edema into the perineum or inguinal region.

Treatment is usually conservative.

5. Testicular trauma

Testicular trauma in children is rare. Usually an antecedent history of the trauma is found and so by taking a careful history the diagnosis can usually be made clinically.

Presentation

Boys affected by testicular trauma usually have an acutely painful and swollen testis together with swelling and bruising of the scrotum. It may or may not be more pronounced on the one side. The most common injury is a hematoma of the testis. USG must be undertaken to exclude rupture of the tunica albuginea. Disruption of the tunica albuginea, as seen by USG is an indication for operative repair. It is particularly important with post pubertal boys because of the possibility of initiating some sort of autoimmune orchitis in the opposing testis. It is also important to evacuate any large hematoma that may occur in the space between the tunica vaginalis and the tunica albuginea because if it occurs, it may produce pressure necrosis of the testis.

Epididymal injuries also can occur with testicular trauma. Disruption of the epididymis from the testis has actually been described at exploration for testicular trauma. Satisfactory repair is extremely unlikely and the long-term outcome for these boys, in terms of sperm production from the involved testis must be doubtful.

Other conditions that may present as an acute scrotum:

6. Incarcerated and strangulated inguinal hernia
7. Acute tubercular epididymitis
8. Acute epididymoorchitis of mumps

*****

TUMOURS

Neuroblastoma

Neuroblastoma is a neoplasm of adrenal gland origin. It occurs in 1 of every 10,000 live births and is most common extracranial solid tumour of childhood. They tend to occur more commonly in boys than in girls.

Clinical feature

Most patients present with a complaints of abdominal lump which is irregular on palpation and is nodular, (cf. Wilm's tumour is smooth).

Neurological symptoms can occur from compression of nerve trunk or due to extension of tumour into extradural space. Horner's syndrome has been reported. Pelvic extension may result in urinary dysfunction. Metastatic spread can involve lung, liver- bone marrow and skin.

Investigation

- USG and CT scan will confirm the lump.
- Bone marrow aspirates may reveal typical neuroblastoma cells.
- **Urinalysis:** The tumour synthesizes various catechocholamines. The excretion products include vanillylmandelic acid (VMA) and homovanilic acid. These acids are checked in a 24 hours urine collection. *(IMP. POINT)*

Radiological study

- Ultrasonography acts as a screening tool to define organ and rule out Wilm's tumour.

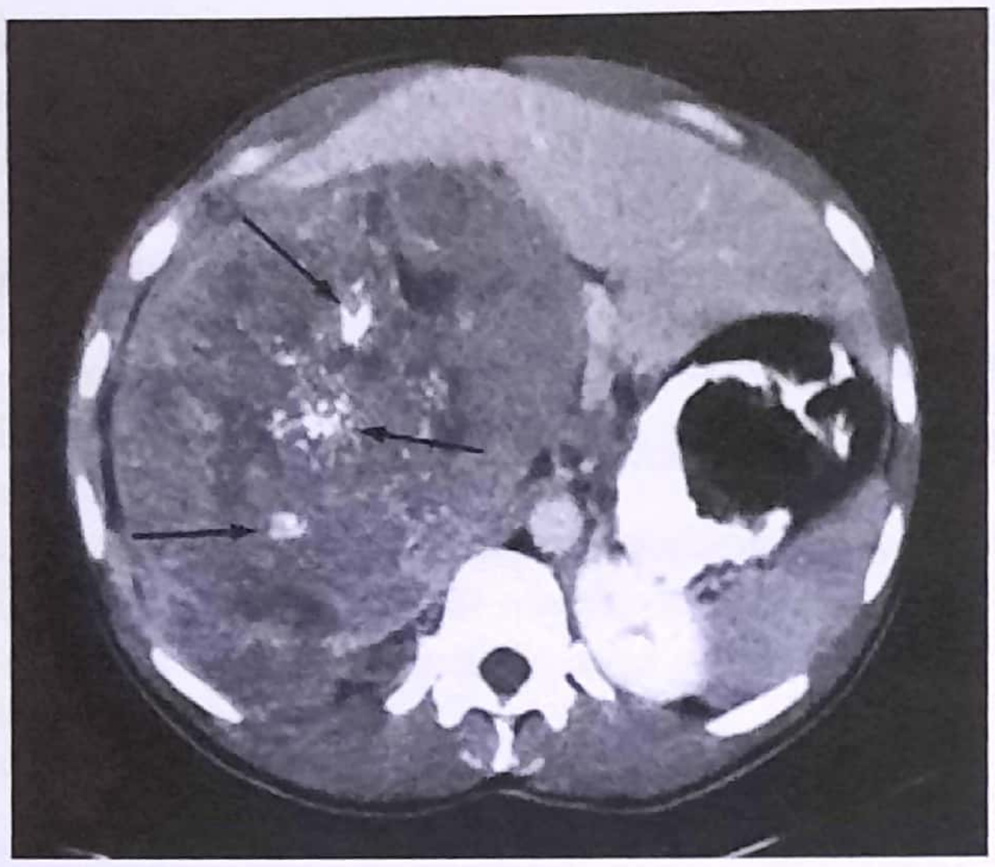

Figure 53.16: Computed tomography scan of neuroblastoma demonstrating areas of calcification (*arrows*)

- Chest X-ray chest will confirm or rule out pulmonary metastasis, (stippled calcification+)
- A CT scan gives details of the tumour as well as metastasis; if present.

Staging (Evan's)

Stage I: Confined to organ of origin+ totally excisable.

Stage II: Extended beyond the origin but does not cross midline; ipsilateral lymph node may be involved.

Stage III: Extended beyond midline

Stage IV: Distant metastasis

Stage IVs: Small primary lesion with metastasis limited to one or more of the following organs:- liver, skin, bone marrow with out evidence of cortex involvement.

Treatment

A rational approach to manage neuroblastoma requires a combined approach; which include surgeon, radiation oncologist, chemotherapist and a pediatrician.

Treatment of choice for stage I, II and IVs is surgery (total excision).

Treatment of choice for advanced disseminated disease is chemotherapy. Radiation therapy is used as an adjuvant for resected or incompletely resected primary tumour or as palliative therapy for symptomatic metastases; with pain.

Rhabdomyosarcoma

Rhabdomyosarcoma is most common primitive soft tissue tumour. Lesion may occur anywhere in the body, but over one third of the lesion develop in head and neck. Most common site is orbit, followed by urinary bladder in a male child. However most common site in female is vagina. Various *histological types* of rhabdomyosarcoma occurs: these are; embryonal, alveolar, botryoid, pleomorphic and undifferentiated.

Tumours with embryonal pathology has a better prognosis than with alveolar variety. Local invasion to surrounding tissue is common and metastasis occurs through blood to liver, brain, lung, bone marrow and to the regional lymph node.

Treatment: Operative excision for any rhabdomyosarcoma is combined with radiation therapy and multidrug chemotherapy (actinomycin D, Vincristine, and Cyclophosphamide).

Staging for rhabdomyosarcoma

Group I : Localized disease that is completely resected with no regional node involvement

Group II :

- **A.** Localized, grossly resected tumor with microscopic residual disease but no regional nodal involvement
- **B.** Locoregional disease with tumor-involved lymph nodes with complete resection and no residual disease
- **C.** Locoregional disease with involved nodes, grossly resected, but with evidence of microscopic residual tumor at the primary site and/or histologic involvement of the most distal regional node (from the primary site)

Group III : Localized, gross residual disease including incomplete resection or biopsy only of the primary site

Group IV : Distant metastatic disease present at time of diagnosis

Wilm's Tumour

Kindly read this topic on page no 822.

*****

FETAL SURGERY

Fetal surgery is the surgical treatment of a fetus in uterus with certain life- threatening congenital abnormalities. Surgical intervention during pregnancy on the fetus is meant to correct problems that would be too advanced to correct after birth. During fetal surgery the uterus is opened by cesarian or through tiny, single or multiple port incisions, the malformation is surgically corrected and the fetus remains in the uterus to complete gestation. A wide range of surgical techniques can be used to treat the fetus. Generally the techniques are divided into two categories.

1. **Open fetal surgery**
2. **Fetoscopic surgery**

Open Fetal Surgery

A hysterotomy (cesarean section) is performed and the fetus is partially removed so that the area that needs surgery is exposed. After corrective surgery is performed, the fetus is returned back in uterus and the uterus is closed. In some cases, surgery on the fetus is scheduled to coincide with delivery. Surgery would be done on the fetus after cesarean section, but before the cord is cut, so that the fetus is sustained by the mother's placenta and doesn't have to breath on his or her own. This method, known as EXIT (ex utero intrapartum treatment) and is usually employed for the fetus suffering from a congenital defects that block the airway, such as a cervical teratoma. EXIT gives surgeons time to perform multiple procedures to secure the baby's airway, so that the by the time the cord is cut and the baby has to breath, he or she has an unblocked airway.

Fetoscopic Surgery

This type of surgery, which employs minimally invasive techniques is used more often than open surgery. Surgeons can use fiber-optic telescopes; an specially designed instruments to enter the uterus through small surgical openings to correct congenital malformations without major incisions or removing the fetus from the uterus. This technique is less traumatic and reduces changes of pre-term labor.

This technique has been successfully applied for decompression of the obstructed urinary tract, creation and repair of fetal cleft lip, fetal endoscopic tracheal occlusion in congenital diaphragmatic hernia, division of placental vessels or ligation of the umbilical cord in twin-twin transfusion syndrome.

Indication

Fetal surgery becomes an option when it is predicted that the fetus will not live long to make it to delivery or live long after birth.

Fetal surgery is being done and might be considered to correct the following prenatally diagnosed fetal malformations.

1. Urinary tract obstruction
2. Congenital diaphragmatic Hernia.
3. Congenital cystic adenomatoid malformation (CCAM)
4. Sacrococcygeal teratoma
5. Twin-Twin transfusion syndrome
6. Hydrocephalus
7. Myelomeningocele
8. Cleft lip and Palate
9. Inherited defects correctable by fetal stem cell transplantation.

Risk

The risk associated with open fetal surgery includes:

1. Pre-term labor
2. Infection
3. Bleeding
4. Pain
5. Anesthetic complications
6. Uterus scar disruption in subsequent pregnancy.

*****

54 Organ Transplantation

Contents

- Types of donor
- Immunology
- Rejection
- Immunosuppression
- Principles of transplantation
- Donor
- Kidney Transplantation
- Liver transplantation
- Pancreas transplantation
- Small bowel transplantation
- Heart transplantation
- Lung transplantation
- Tumours

Transplantation, the removal or partial detachment of a part of the body and it's implantation in the body of the same or a different individual has fascinated human being for long time. .

In 1902; first experimental transplantation was done. In 1951, human kidney transplants were started in Paris, Chicago and Boston. 10 years later, massive progression in the development of transplantation of extra-renal organs was started. Thomas Starzl started performing human liver transplantation in 1963. The first pancreas was performed in 1966 at University of Minnesota. In 1967; *Christiaan Barnard performed first Cardiac transplantation, in CapeTown, South Africa.* (PGME) Transplantation of human organs act was passed in india in 1994.

*****

DEFINITIONS

(a) **Autograft** describes tissue transfer within the same individual (e.g. skin graft).

(b) **Isograft** describes tissue transfer between genetically identical individuals (e.g. **identical twins**) (NEET)

(c) **Allograft** describes tissue transfer between genetically nonidentical members of the same species (NEET) (includes living related donor and cadaver donor human transplants).

(d) **Xenograft** describe tissue transfer between different species. Immunosuppressant is must.

Physician should remember that allografts and xenografts require immunosuppression or they will fail because of rejection.

Further the placement of the graft is described as **orthotropic or heterotropic.**

Orthotopic transplantation is described as a graft that is place in its normal anatomical position, as for clinical liver or heart transplants. In these instance, the native or-

gan is removed and replaced with an allograft at the same anatomical place.

Heterotopic transplantation (NEET) describes surgical placement of the graft in a non anatomic location, as in renal transplantation wherein tranplanted kidney is placed inferior to the native kidneys in iliac fossa.

*****

IMMUNOLOGY

The compatibility between a donor organ and the immune system of the recipient remains the most important barrier to the field of transplant science. The cellular recognition of self by immunological components of the recipient allows for the assault on tissues that possess foreign antigens.

This process of recognition of cells as either self or foreign starts with cell-surface antigens, such as the ABO blood antigen system. In humans, A and B antigens protrude from erythrocyte membranes. In other words, patients who do not express either A or B antigen are therefore unable to tolerate tissues that do express that antigen.

More specific antigen recognition exists in the major histocompatibility (MHC) antigens.

As they were first discovered on leukocytes, they were termed human leukocyte antigens (HLA). These transmembrane glycoproteins are divided into two major classes, class I and class II. class I antigens, labeled A, B and C are expressed on the surface of all nucleated cells and platelets. This class of molecules is recognized by $CD8^+$ cytotoxic T cells, initiating lysis of the target cells. Class II antigens are found on specific immunological active cells such as macrophages, monocytes, B lymphocytes, dendritic cells, kupffer cells and activated T cells. They are labeled D-related (Dr) antigens and are thought to be the most important for cross-matching purposes because of there vital role in immune attacks. This class is recognized by $CD4^+$helper cells, which leads to T-cell activation and the mounting of a full immune response. Both CD^4 and CDS complexes on T cells are associated with CDS. (Figure 54.1)

REJECTION

Graft (transplanted organ) damage due to attack by the recipient immune system is termed rejection. The general types, differentiated by both timing and mechanism are hyperacute, acute and chronic rejection.

1. Hyperacute Rejection

It occurs immediately upon reperfusion because preformed antibodies exist in the serum of the recipient

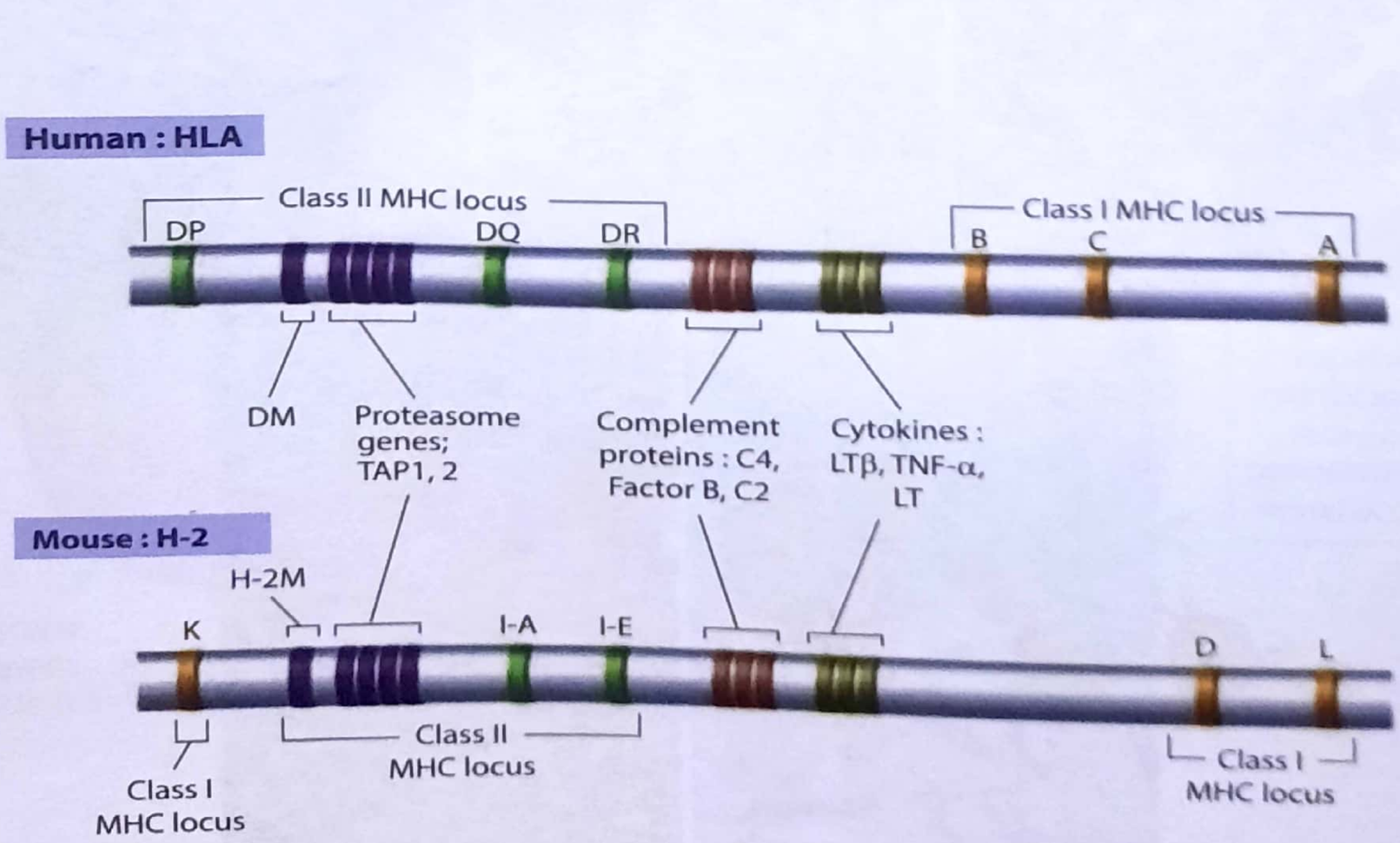

Figure 54.1: Location and organization of the HLA complex on human chromosome 6 and H-2 complex on murine chromosome 17. The complex is conventionally divided into regions I and II.

against antigens expressed on the donor organ. This is usually due to ABO incompatibility and results in an immediate and massive inflammatory response against-the vascular endothe-lium of the donor organ. Hyperacute rejection is not reversible and should be treated by graft/ organ removal.

2. Acute Rejection

It is a cell-mediated response; whereby antigen-presenting cell recognize the donor organ as foreign and present those antigens to T cells. This results in T- cell activation and immune attacks against the organ. The purpose of immu-nosuppressive regimens is to avoid this physiological response and even after acute rejection has begun, it can be treated medically by increasing the does of immunosup-pression and/or the use of additional agents.

3. Chronic rejection

It occurs over the course of months to years. It is the product of antibody response, cell mediated response or a combination of two. This type of rejection is characterized by vascular obliteration with replacement by fibrotic tissue and is not reversed by immunosuppressive drugs.

*****

IMMUNOSUPPRESSION

The immune system of the recipient needs to be pharmacologically manipulated for the remainder of the recipient's life to prevent the immune system from recognizing the graft as foreign and triggering a destructive attack. There are many different regimens used; but listed below are some of the most common immunosuppressive agents currently used clinically. These agents are:

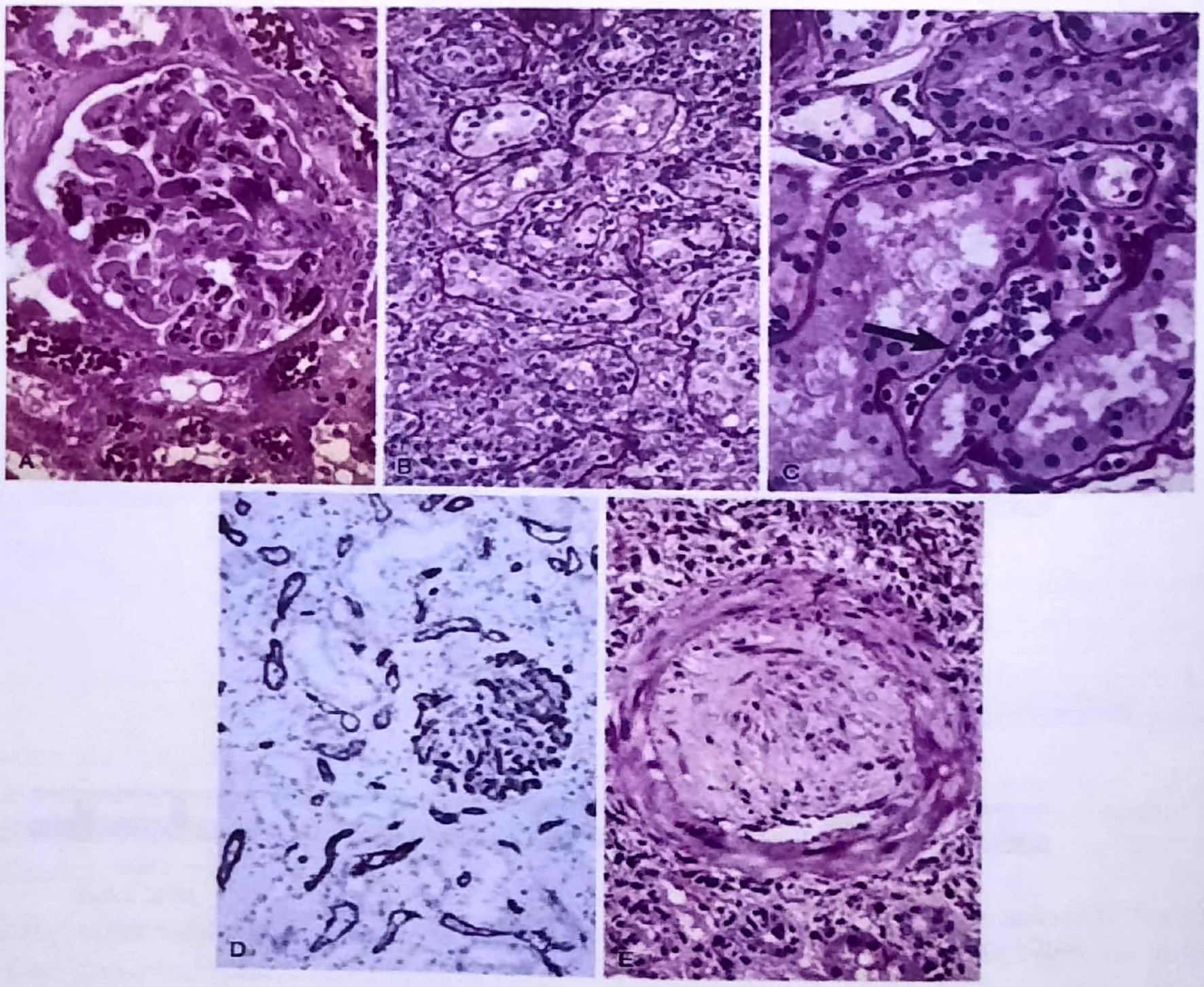

Figure 54.2: Histology of Rejection

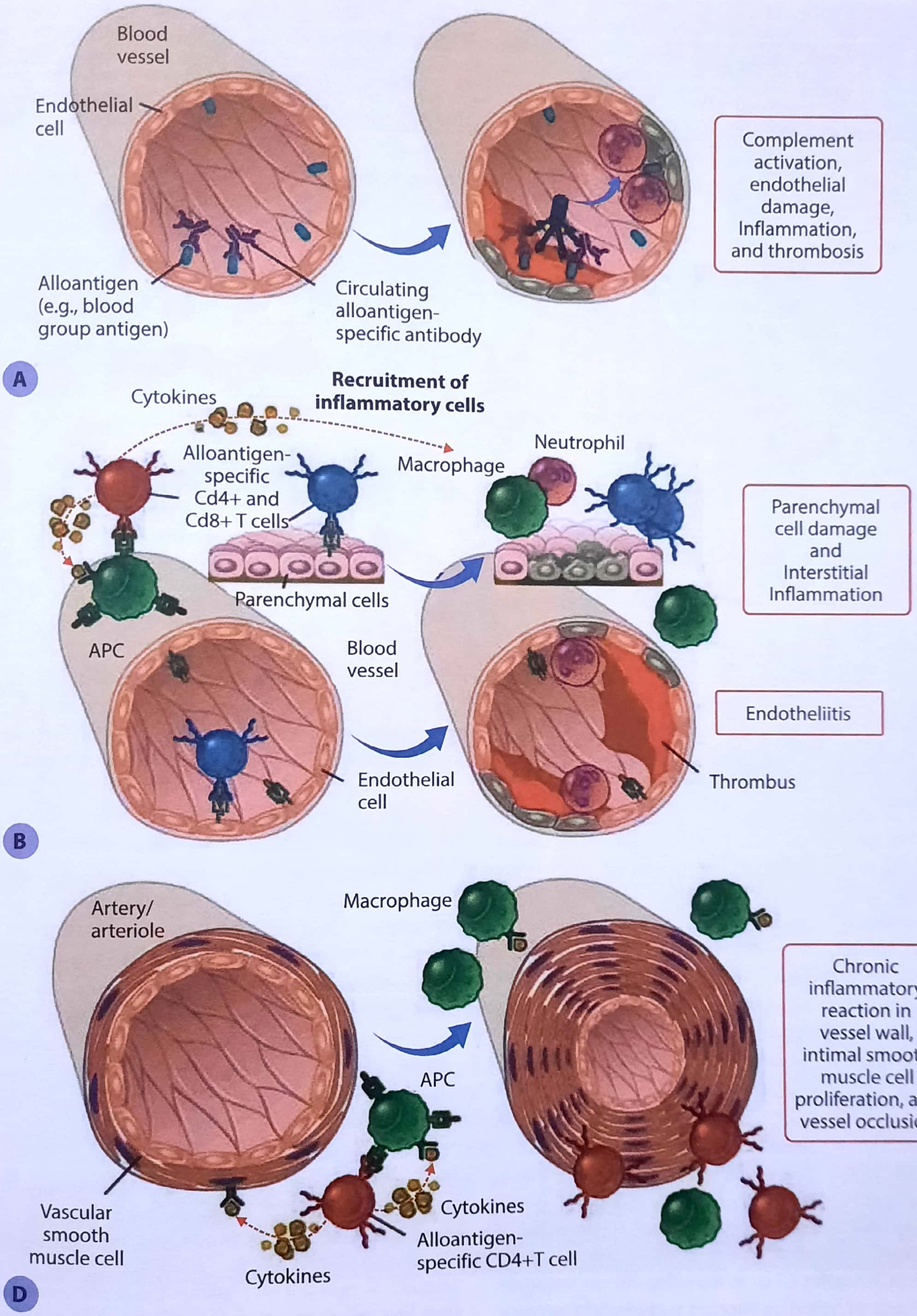

Figure 54.3: Mechanisms of rejection

KEY BOX 54.1

Summary of Immunosuppressive Drugs

Drug	Description	Mechanism	Nonimmune toxicity and comments
Prednisone	Corticosteroid	Binds nuclear receptor and enhances transcription of IκB, which inhibits NF-κB and T-cell activation	Diabetes, weight gain, psychological disturbances, osteoporosis, ulcers, wound healing, adrenal suppression
CsA	11-Amino acid cyclic peptide from *Tolypocladium inflatum*	Binds to cyclophilin; complex inhibits calcineurin phosphatase and T-cell activation	Nephrotoxicity, hemolytic uremic syndrome, hypertension, neurotoxicity, gingival hyperplasia, skin changes, hirsutism, posttransplantation diabetes, hyperlipidemia
Tacrolimus (Prograf)	Macrolide antibiotic from *Streptomyces tsukubaensis*	Binds to FK-BP12; complex inhibits calcineurin phosphatase and T-cell activation	Effects similar to CsA but with lower incidence of hypertension, hyperlipidemia, skin changes, hirsutism, and gingival hyperplasia but higher incidence of posttransplantation diabetes and neurotoxicity
Sirolimus (Rapamycin)	Triene macrotide antibiotic from *Streptomyces hygroscopicus* from Easter Island (Rapa Nui)	Binds to FK-BP12, complex inhibits target of rapamycin and IL-2-dependent T-cell proliferation	Hyperlipidemia, increased toxicity of calcineurin inhibitors, thrombocytopenia, delayed wound healing, delayed graft function, mouth ulcers, pneumonitis, interstitial lung disease
Everolimus (Zortress) Mycophenolate mofetil (CellCept)	Derivative of sirolimus, similar mechanism and toxicities Mycophenolic acid from *Penicillium stoloniferum*	Inhibits synthesis of guanosine monophosphate nucleotides; blocks purine synthesis, preventing proliferation of T and B cells	Gastrointestinal symptoms (mainly diarrhea) neutropenia, mild anemia
Azathioprine (Imuran)	Prodrug that undergoes hepatic metabolism to form 6-mercaptopurine	Converts 6-mercaptopurine to 6-thioinosine-5-monophosphate, which is converted to thioguanine nucleotides that interfere with DNA and purine synthesis	Leukopenia, bone marrow depression, liver toxicity (uncommon)
Antithymocyte globulin	Polyclonal IgG from rabbits or horses immunized with human thymocytes	Blocks T-cell membrane proteins (CD2, CD3, CD45), causing altered function, lysis, and prolonged T-cell depletion	Cytokine release syndrome, thrombocytopenia, leukopenia, serum sickness

OKT3 (muromonab-CD3)	Anti-CD3 murine monoclonal antibody	Binds CD3 associated with the TCR, leading to initial activation and cytokine release, followed by blockade of function, lysis, and T-cell depletion	Severe cytokine release syndrome, pulmonary edema, acute renal failure, central nervous system changes
Basiliximab	Anti-CD25 chimeric monoclonal antibody	Binds to high-affinity chain of IL-2R (CD25) on activated T cells, causing depletion and preventing IL-2-mediated activation	Hypersensitivity reaction, uncommon
Daclizumab Rituximab	Anti-CD25 humanized monoclonal antibody Anti-CD20 chimeric monoclonal antibody	Similar to that of basiliximab Binds to CD20 on B cells and causes depletion	Hypersensitivity reaction, uncommon Infusion and hypersensitivity reactions, uncommon
Alemtuzumab	Anti-CD52 humanized monoclonal antibody	Binds to CD52 expressed on most T and B cells, monocytes, macrophages, and NK cells, causing lysis and prolonged depletion	Mild cytokine release syndrome, neutropenia, anemia, autoimmune thrombocytopenia, thyroid disease
FTY720	Sphingosine-like derivative of myricin from the fungus *Isaria sinclairii*	Functions as an antagonist for sphingosine-1-phosphate receptors on lymphocytes, enhancing homing to lymphoid tissues and preventing egress, causing lymphopenia	Reversible first-dose bradycardia, potentiated by general anesthetics and beta blockers, nausea, vomiting, diarrhea, increased liver enzyme levels
Belatacept (LEA29Y)	High-affinity homologue of CTLA-4-Ig	Binds to CD80/CD86 and prevents costimulation through CD28	In clinical trials, results show improved glomerular filtration rate and improved outcomes to CsA

1. Corticosteroids

These drugs block membrane phospholipase, preventing the production of arachidonic acid, which is the substrate for the creation of prostaglandins, kinins, leukotrienes and thromboxanes. This is not a specific mechanism of immunosuppression; however this class of medication is currently parts of most immunosuppressive regimens.

2. Metabolic Inhibitors

These cytotoxic agents are antiproliferative, preventing efficient mitosis, a process upon which the immune response is highly dependent.

Azathioprine is metabolized by the liver to become 6-mercaptopurine, which is a purine analogue and thus a competitive inhibitor of DNA and RNA synthesis. In addition to being hepatotoxic, all cell lines are affected by azathioprine, leading to anemia, leukopenia and thrombocytopenia.

Mycophenolate mofetil, a new agent, selectively agents inhibits the production of leukocytes. It has been shown to effectively reduce rejection rates and is not associated with the toxicities of azathioprine. It's a adverse effects are mainly gastrointestinal.

3. Calcineurin Inhibitors

This very important class of immunosuppressive agents which inhibit the production of interleukin -2. IL -2 is a key messenger that is released by T cells after recognition of an antigen and the complete cell-mediated immune response occurs subsequent to its release. Calcineurin is a serine phosphatase enzyme activated by the secondary messenger calcium; which leads to cytokine gene transcription .

Cyclosporine and tacrolimus are the two main calcineurin inhibitors. Cyclosporine an 11 amino acid peptide has the adverse effects of hyperglycemia, hyperuricemia, hyperkalemia, hypertrichosis, tremors an gingival hyperplasia. However the most significant disadvantage of Cyclosporine is nephrotoxicity, which can be confused with acute rejection.

Tacrolimus, a macrolide antibiotic is also nephrotoxic but is more neurotoxic and diabetogenic than Cyclosporine. Most immunosuppressive regimens utilize a calcineurin inhibitor.

Sirolimus is structurally very similar to tacrolimus, even binding the same cytoplasm proteins, but mechanistically distinct. Sirolimus is not calcineurin dependent in its action. It causes substantial dislipidemia; but is not as nephrotoxic or diabetogenic as Cyclosporine.

4. Polyclonal antibodies

This class is composed of a heterogeneous population of antibodies directed against multiple sites on the surface of T cells, leading to depletion of circulating T cells by complement mediated lysis and reticuloendothelial trapping. Antithymocyte globulin (ATG) is most commonly used polyclonal antibody. Fever and chills typically occur with infusion, necessitating pretreatment with antihistamines and steroids. Other adverse effects include:- leucopenia, thrombocytopenia, serum sickness, skin rashes and phlebitis. Directed antibody medication, both monoclonal and polyclonal are used for the treatment of acute rejection. Antibody medications are effective in this task because they transiently destroy leukocyte colonies.

5. Monoclonal Antibodies

As the name implies, these drugs are a *homogeneous mixture of antibodies* directed against a single target. OKT3, a commonly used monoclonal antibody; which binds to the CD3 receptor present on all leukocytes. The adverse effect is massive release of inflammatory cytokines resulting in nausea, vomiting, diarrhea, fever, chills, myalgia and in severe cases; bronchospasm and hypotension. Pretreatment with antihistamines, steroids and non-steroidal anti-inflammatory medications is important. Monitoring of CDS lymphocytes during treatment is recommended.

Other monoclonal antibodies include **basiliximab** and **daclizumab.** Both agents bind alpha chain of IL-2, causing selective inhibition of this important cytokines.

DONORS

1. Cadaver Donors

They are individuals with severe brain injury resulting in brain death, which is defined as "complete irreversible cessation of all brain function including the brain stem."

Two types :

1. **Brain dead donors:** This is most common category. Brain death is defined as irreversible cesation of brain function, including brainstem.
2. **Cardiac deceased donors:**

Maastricht classification

Category 1	→	Dead on arrival at hospital
Category 2	→	Resuscitation attempted without success.
Category 3	→	Awaiting cardiac arrest after withdrawl of support (most donor)
Category 4	→	Cardiac arrest while brain dead.
Category 5	→	Cardiac arrest & unsuccessful resuscitation in hospital.

2. Living donors

Living donors are individuals motivated by altruism.

Types of living donors

1. **Living unrelated donors** share no genetic relationship with a recipient. An example is the patient's wife.
2. **Living related donors** share a substantial portion of their genomes with the recipient, eg; mother, father, sister.

Living donors must be in almost perfect health, have normal function of the organ under consideration, and be good candidates for anesthesia and the operative procedure. The work-up includes:-

- ABO typing, tissue typing and cross-matching.
- Complete history and physical examination, chest radiography, ECG, complete blood count, sequential multiple analysis (SMA), 24-hour creatinine clearance and protein, serology for hepatitis B and C, CMV and HIV etc.
- For renal donors, arteriography and intravenous pyelogram [now combined as a helical computed tomography (CT) scan].

Risks to Donor

Perioperative mortality for living kidney donors is 0.03% (3 per 1000). A living donor provides one kidney and the other kidney hypertrophies and achieves 80% of creatinine clearance.

Newer procedures include donation of the left lateral segment or a lobe of the liver and segment (s) or lobe(s) of the lung. In these procedures, the safety of the donor is not assured.

Although traditionally most living kidney donations are performed as an open surgical procedure, there is increasing experience with laparoscopically performed nephrectomy. This method potentially offers the advantage of minimally invasive surgery; while still producing an excellent kidney.

Removal Of The Donor Organ

The donor organ is removed in a formal surgical procedure, wherein the blood supply of the organ is controlled and then the organ is rapidly flushed with a cold (4°C) solution to render it cold and ischemic. All organs are more tolerant of cold ischemia than warm (normothermic) ischemia.

The **practical** limit of cold ischemia with current preservation methods is 4 hours for the heart, 6 hours for a lung, 12 hours for the liver, 36 hours for the pancreas and 40 to 48 hours for a kidney. As the limit is approached or passed the risk increase for delayed function, damage or non function of the organ.

KIDNEY TRANSPLANTATION

Indications

The indications for kidney transplantation are end-stage renal disease (ESRD) regardless of the primary cause. Common diseases in adults leading to ESRD include diabetes mellitus (85%), hypertension, infections and glomerulonephritis. In children the important causes are congenital dysplasia, post urethral valves and reflux with chronic pyelonephritis.

Contraindication

Absolute contraindication are presence of infection or malignancy that cannot be eradicated, recent cancer (<2 yrs), active substance abuse or failure to adhere to prescribed medical regimens, end stage renal disease due to hyperoxaluria. Relative contraindications are old age, severe cardiovascular disease.

Sources of Kidneys

About half of kidney transplants are from living donors. Long term complication live donor are HTN, CVA, ESRD, proteinuria. Since medication to prevent rejection is so effective, donors do not need to be genetically similar to their recipient. The other half are from deceased* donors.

Deceased donors can be divided in two groups:

- Brain dead (BD) donors
- Non-heart beating (NHB) donors El Deceased= recently dead person

Deceased = recently dead person

Although the brain death (or 'heart beating') donors are considered dead. The donor's heart continues to pump and maintain the circulation. This makes it possible for surgeons to start operating while the organs are still being perfused. Kidneys from brain dead donors are generally of a superior quality for transplantation.

Immediately after donation, creatinine level & clearance increases in donor.

KEY BOX 54.2

Contraindications to renal transplantation

Absolute

- Active malignant disease
- Active infection
- Unreconstructable peripheral vascular disease
- Severe cardiac or pulmonary disease
- Active intravenous drug abuse
- Significant psychosocial barriers that interfere with the patient's ability to comply with a complex medical regimen

Relative

- Limited life expectancy
- History of nonadherence to medication regimen
- History of noncompliance with dialysis
- Financial barriers
- Psychiatric issues
- Renal disease with high recurrence rate
- Morbid obesity (BMI is center dependent)
- Frailty

Expanded criteria donors for kidney transplantation

- ECD kidneys are those from either a brain dead donor older than 60 years or
- A donor older than 50 years with at least two of following - Diabetes, HTN, S.Cr > 1.5mg/dL or cerebrovascular cause of death.

Surgical method

Living donor nephrectomy can be performed either through a flank incision (open nephrectomy) or by laparoscopic techniques.

Donor nephrectomy

Living donor nephrectomy can be performed either through a flank incision or by laparoscopic technique.

(i) **Open nephrectomy:** A flank or subcostal incision may be used for kidney exploration. The ***left kidney is commonly used because it's longer renal vein* facilitates operation** (NEET, MANY PGME). However if arteriogram shows multiple renal artery on one side then the kidney with a single artery is usually selected.

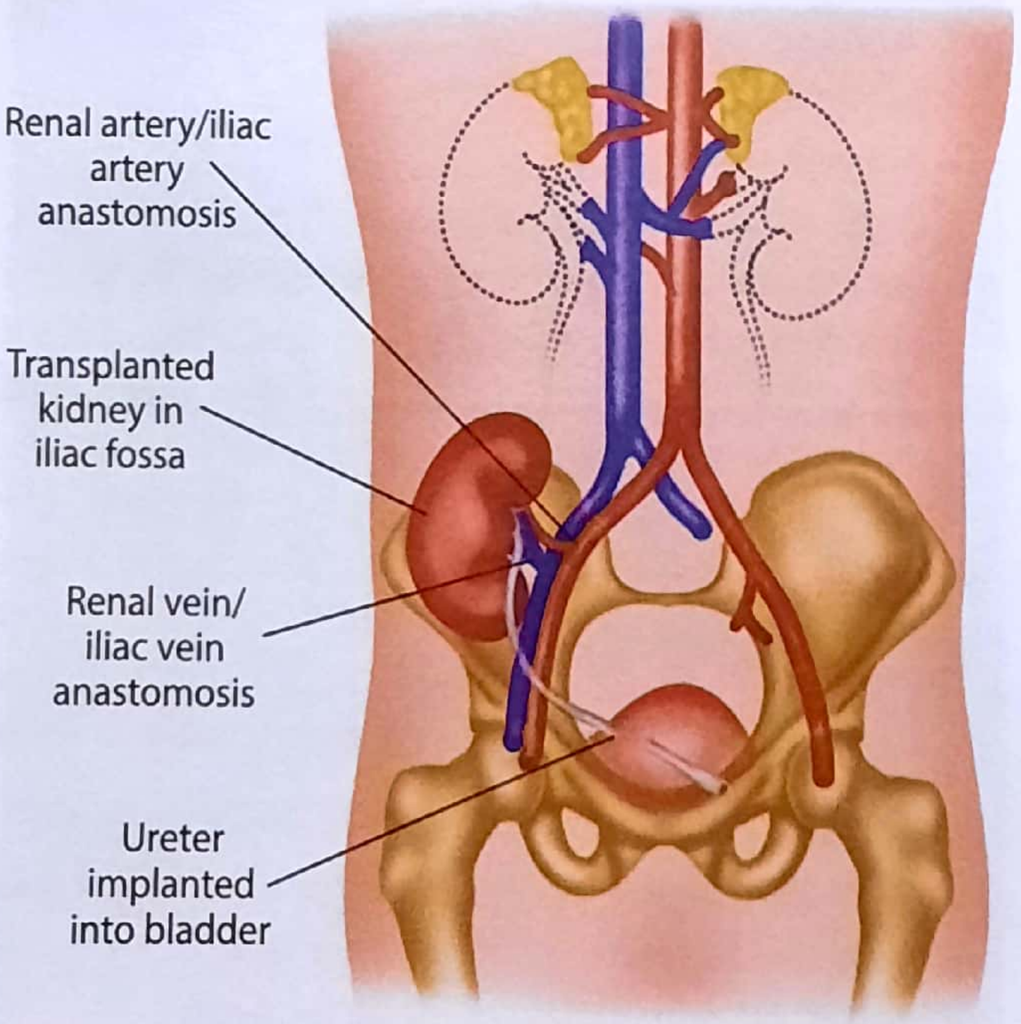

Figure 54.4: Renal transplantation

KEY BOX 54.3

Contraindications to living kidney donation

- BMI >40
- Diabetes
- Active malignant disease
- GFR <70 mL/min/1.72 m^2 (center dependent)
- Significant albuminuria
- Hypertension requiring multiple medications
- Pelvic or horseshoe kidney
- Significant psychiatric impairment
- Nephrolithiasis with a high chance of recurrence (cystine, struvite)

(ii) **Laparoscopic nephrectomy:** Advantage of laparoscopic nephrectomy is short hospital stay and less operative morbidity in comparison to that of open nephrectomy. Where as some early graft dysfunction was evident in kidneys removed laparoscopically, the long term function of these grafts is equal to those obtained by the conventional open approach. The shorter and thinner walled right vein complicates the procedure; especially because the stapling device used to transect vessels, hence laparoscopic nephrectomy is seldom used to remove right kidney.

Placement of Graft (Kidney)

The kidney is usually placed in a location different from the original kidney (**often in the iliac fossa** (NEET)) and as a result; it is often necessary to use a different blood supply. This is called as Heterotopic transplantation

- *The renal artery of the kidney, previously branching from the abdominal aorta in the donor, is often connected to the external iliac artery in the recipient.* (IMP. POINT). Please see fig. 54.4.
- *The renal vein of the grafted kidney, previously draining to the inferior vena cava in the donor, is often connected to the external iliac vein in the recipient.* (IMP. POINT)

Immunosuppression

Medicines are used to suppress the immune system from rejecting the donor kidney. These medicines must be taken for rest of the patient's life. The most common medication regimen today is: tacrolimus, mycophenolate and prednisone. Some patients may instead take cyclosporine, rapamycin or azathioprine.

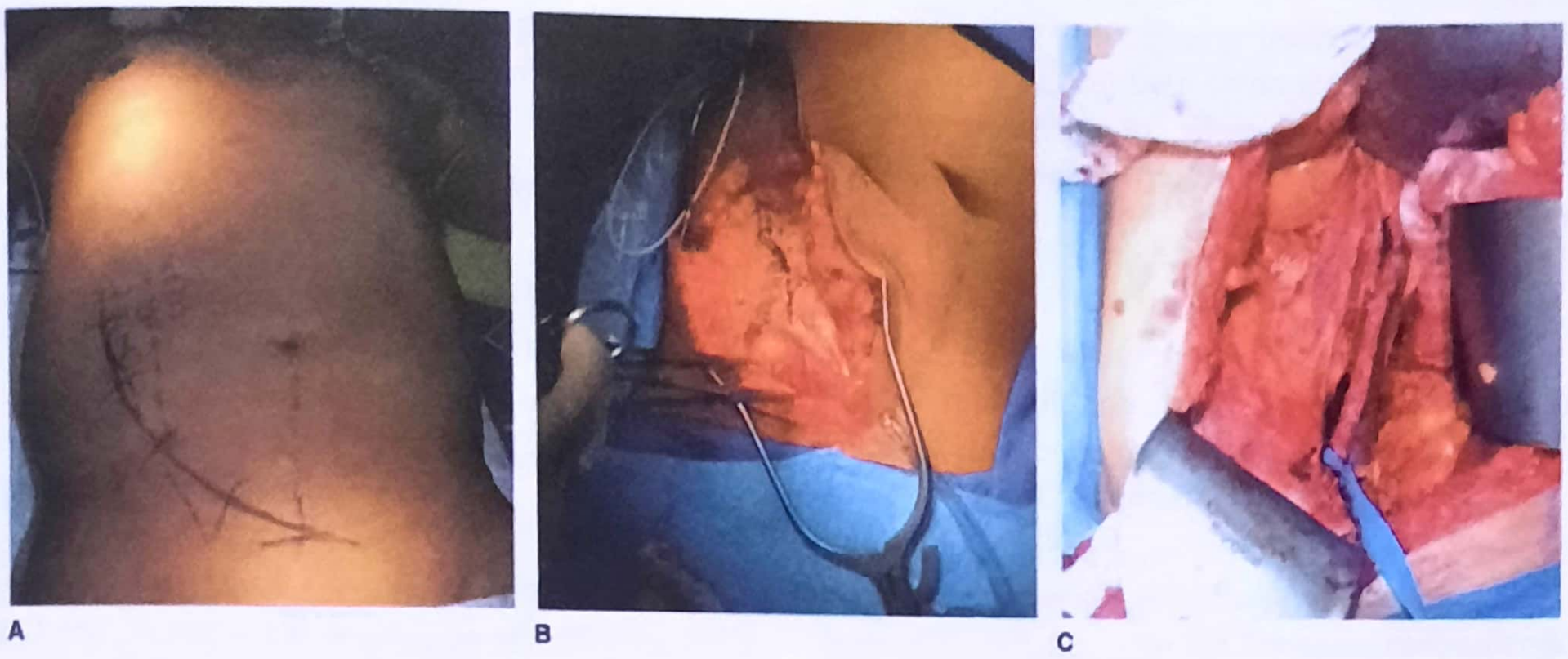

Figure 54.5: Incision and exposure for kidney transplant

Currently used immunosuppressive agents are generally much more specific in their mechanism of action and has significantly reduce the incidence of rejection. These drugs can be classified into 4 groups: corticosteroids, antimetabolites, macrolides, and antibodies. Immunosuppressive agents used are as follows:

(i) Corticosteroids

Methylprednisolone is used intravenously for induction or antirejection therapy. Prednisolone is given orally as maintenance therapy. Corticosteroids acts by inhibiting the production and release of IL-1.

(ii) Antimetabolites

Names- Mycophenolate mofetil, azathioprine Method of action - Inhibition of cell proliferation.

Mycophenolate mofitil blocks inosine monophosphate dehydrogenase, an enzyme necessary for purine synthesis specifically in lymphocytes. This provides more specific immunosuppression for transplantation than azathioprine.

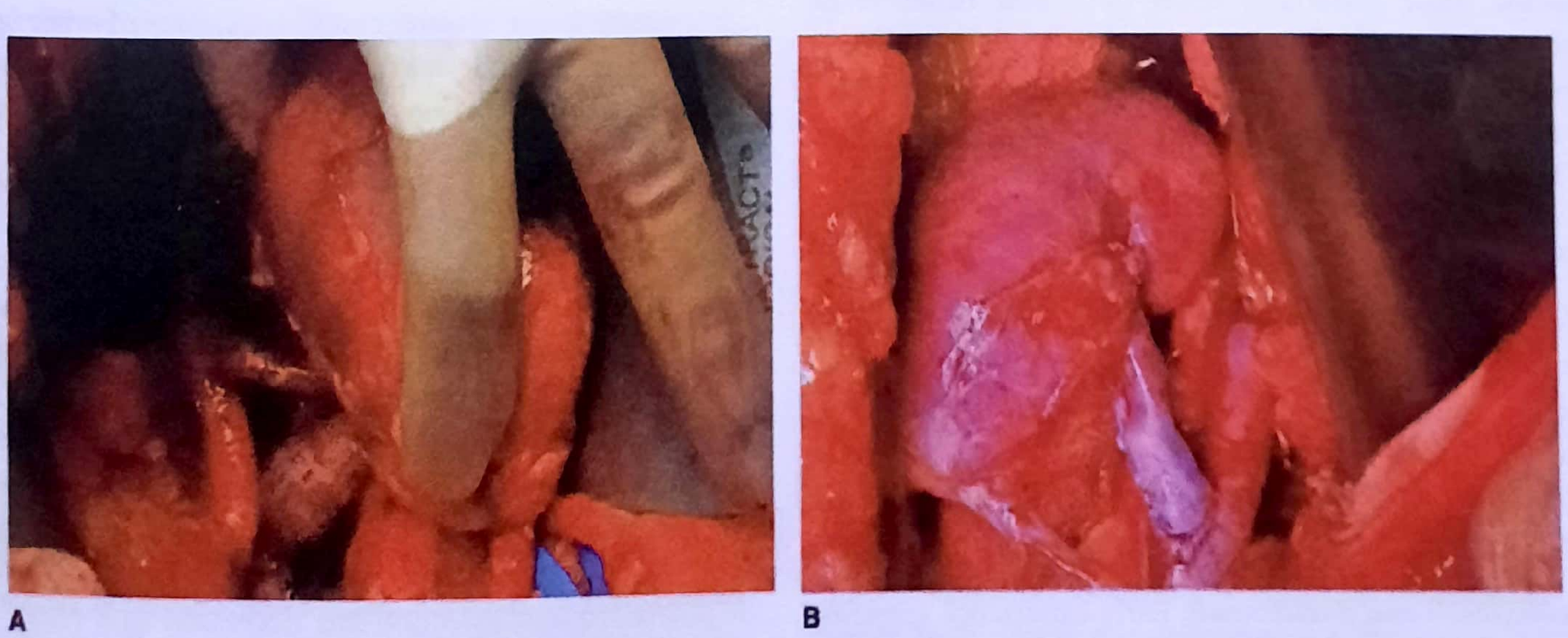

Figure 54.6: Vascular anastomoses of kidney transplant.

Because of the increased specificity of mycophenolate mofetil, azathioprine is rarely used in current transplant immunosuppression regimens. However, many long-term recipients who received transplants in childhood remain on azathioprine.

(iii) Macrolides

Names- Cyclosporine, tacrolimus, sirolimus (Rapamycin) *Method of action* - Blocks production of or action of IL -2 or other cytokines. Tacrolimus is 100 times more potent than cyclosporine

(iv) Antibodies

Many antilymphocyte antibodies have been used in transplantation. Polyclonal antibodies provides a relatively less specific impairment of lymphocyte activity.

Monoclonal antibodies (i.e., muromonab-CD3, daclizumab, basiliximab) provide more specific inhibition of lymphocyte function. Antibodies are used for induction (temporary use immediately following transplantation, while other immunosuppressive agents are adjusted) and for treatment of acute rejection.

Names

Antithymocyte globulin (ATG), muromonab-CD3 (Orthoclone OKT3), daclizumab (Zenapax), basiliximab (Simulect)

Method of action

In general, antibodies used in immunosuppression interfere with the function of T lymphocytes; lysis of lymphocytes with a resulting lymphopenia caused by some agents; some antibodies cover or impair function of cell surface markers necessary for recognition and processing of foreign antigens in the cascade of the immune response; others may result in an increase of suppressor T lymphocytes.

Adverse effects:

Muromonab- CDS (OKT3) - Fever, myalgia, lymphopenia, thrombocytopenia, increased susceptibility to viral infections or reactivation of latent viral infections. Increased susceptibility to post transplant lymphoproliferative disorder (varies in severity from a premalignant lymphoproliferation to a frankly malignant lymphoma)

Basiliximab and daclizumab: Early experience suggests relatively few adverse effects directly attributable to use of these antibodies; however, concern remains regarding potential to increase risk of infection and malignancy.

Complications

(a) Surgical complications

(i) *Lymphocele*

(ii) *Wound infection*

(iii) *Thrombosis*

(iv) *Renal artery stenosis*

Renal artery stenosis can result from a surgical technical error causing constriction at the point of anastomosis from kinking of the renal artery, or from segmental hypertrophy of the intima of the renal artery or a branch thereof. Although ultrasonography may demonstrate a narrowing in the renal artery or increased velocity of arterial flow, it is not sufficiently sensitive to confirm the diagnosis. Digital subtraction angiography (DSA) is the most sensitive diagnostic test. Three dimensional CT scanning has also been used in making the diagnosis. Treatment options include balloon angioplasty (highest success rate with the lowest risk of complications) or open surgical revascularization.

(b) Urologic complications

Urologic problems are the most common surgical complications following pediatric kidney transplantation.

(i) **Obstruction:** Obstruction of urine drainage occurs in 2-4% of recipient of kidney transplants. Obstruction may be caused by faulty surgical technique or ischemia of the distal ureter.

(ii) **Urine leak:** A breakdown in the anastomosis of the ureter to the bladder results in leakage of urine into the perinephric space. This can result from a technical failure or from ischemia of the distal ureter.

(c) Medical complications

Infection

Infection is one of the most important and common complications of renal transplantation, secondary to use of immunosuppressive drugs. It can occur at any time after the transplant and can vary considerably in severity. Infections add significantly to the morbidity and mortality of transplantation. The incidence and severity of posttransplant infection has decreased as a result of more judicious use of immunosuppressive medications

and the availability of better therapeutic options. In early era of kidney transplantation, infection occurred in as many as 70% of transplant recipients. More recently, the incidence of infection has decreased to 15-44%. Mortality rates from infection have decreased from 11-40% in the 1960s to less than 5%. Post-transplant infections can be caused by bacteria, viruses, fungi, mycobacteria and other opportunistic microbes. Infections are most common in the first 6 months after transplantation when immunosuppression is relatively high; however, infections can occur at any time.

Urinary tract infection (UTI) remains the most common posttransplant infection, especially in children, occurring in as many as 30% of patients. Other bacterial infections that may occur, especially in the first 6 months after transplant include listeriosis, legionellosis, nocardiosis, and pneumococcal infections. Tuberculosis and atypical mycobacterial infection can occur at any time as a primary infection or a reinfection. Many may develop disseminated disease.

Viral infections are a source of significant morbidity as well as mortality in children. *CMV is the most common viral infection in pediatric recipients of transplants.* Other important viral infections in these children also belong to the herpes group, including EBV and HSV. Sever infection with CMV has been associated with acute rejection and organ dysfunction. CMV infection occurs in as many as 90% of pediatric recipients in the first 3-6 months following transplantation.

Pneumonia caused by ***Pneumocystis carinii*** has been reported in 5-10% of renal transplantation recipients who did not take prophylaxis. It is associated with increased immunosuppression, which can occur with CMV infection and during treatment of acute rejection episodes. Low-dose trimethoxazole is commonly employed prophylactically for the first 6-12 months following transplantation.

Immunizations

All potential pediatric recipients of transplants should receive standard immunizations at least 6 weeks prior to transplantation.

Malignancy

Immunosuppression increase the risk of malignancy in children as well as adults. The common malignancies reported are **cutaneous cancers (m/c)** (NEET), lymphoma, carcinoma of the vulva and/or perineum, liver tumors and sarcomas.

Rejection

Immunologic reactions against kidney transplants are becoming less common as more specific immunosuppressive agents are used. However, rejection remains the most common cause of allograft loss in children and adults. Rejection can be classified into 3 types.

Hyperacute rejection

The occurrence of hyperacute rejection is rejection within minutes of revascularisation, as evidenced by the bluish discolouration of the kidney, deterioration of perfusion and cessation of function. It is refractory to immunosuppressive and anticoagulant therapy and requires removal of transplanted kidney.

Acute rejection

Acute rejection is an immunologic reaction against an allograft resulting in a rapid decline in renal function. Acute rejection typically manifests as a rapid rise in serum creatinine without other signs or symptoms. Severs acute rejection episodes can cause fever, myalgia, pain over the allograft or a decrease in urine output. Evaluate all patients with a rise in serum creatinine.

Chronic rejection

Chronic rejection is defined as an immunologic reaction against an allograft resulting in a gradual (but persisting) decline in renal function. Chronic rejection typically manifests as a gradual rise in serum creatinine. Patients are asymptomatic. The risk of chronic rejection is significantly higher in patients who have experienced an acute rejection episode.

Figure 54.7: Acute rejection causing kidney parenchymal disruption and hemorrhage

Etiology of patient death

The NAPRTCS report from 1997 lists cardiopulmonary event as the most common cause of death among children with kidney transplants. Infection (bacterial more common than viral) was the second most common cause of mortality. In adults CVA is the most common cause of death in patients.

Prognosis

Recent studies have indicated that kidney transplantation in a life-extending procedure. The typical patient will live 10-15 years longer with a kidney transplant than if they stay on dialysis. The years of life gained is greater for younger patients. But even 75 year-olds (the oldest group for which there is data) gain an average of 4 Years of life with a kidney transplant. People generally have more energy, a less restricted diet and fewer complication with a kidney transplant than if they stay on dialysis. Some studies seem to suggest that the longer a patient is on dialysis before the transplant the less time the kidney will last. It is not clear why this occurs, but it underscores the need for rapid referral to a transplants program.

*****

LIVER TRANSPLANTATION

First Liver transplant was done in **1963 by Thomas Starzl** *(NEET)*.

First successful liver transplant was done in 1967 by Thomas Starzl.

Liver after transplant enlarges by hyperplasia.

Indications For Liver Transplantation

Approximately 95% of candidates have chronic disease; the remaining 5% have **fulminant hepatic failure** *(NEET)*, which is a disorder that progress rapidly.

1. Adults

Indicated for Acute or Chronic Liver Failure In adults; the common chronic diseases that require liver transplantation include **cirrhosis** *(NEET)* from chronic hepatitis C (40%), alcoholic cirrhosis (15%), chronic hepatitis B (<10%) primary biliary cirrhosis (<10%) and primary sclerosing cholangitis (<10%).

2. Children

In children who require liver transplantation, **more than 50% have biliary atresia as the cause of liver failure.** *(NEET, PGME)*

Types

I. **(A). Cadaver Donar transplantation**
   (B). Living donar transplantation

II. **(A). Orthotropic Liver transplantation**: recipient's liver is removed and replaced with donor liver in same anatomic location.

King's college criteria for orthotopic liver transplantation in acute liver failure.

PCM induced (Paracetamol induced)

pH <7.30 irrespective of grade of encephalopathy.

PT >100 sec + S.creatinine >300 μmol/L (with grade 3 or 4 encephalopathy)

PT = Prothrombin time

Non-paracetamol induced (irrespective of encephalopathy)

PT >100 or any three of the following:

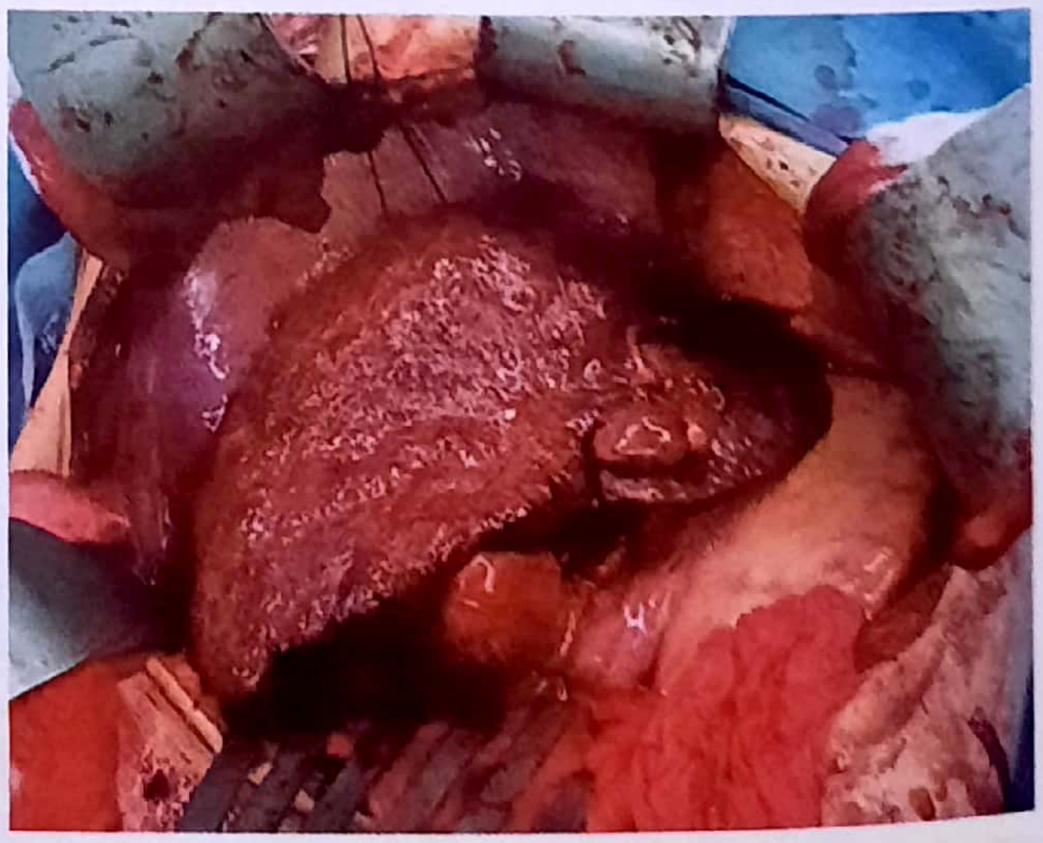

Figure 54.8: Cirrhotic liver immobilized in preparation for complete hepatectomy

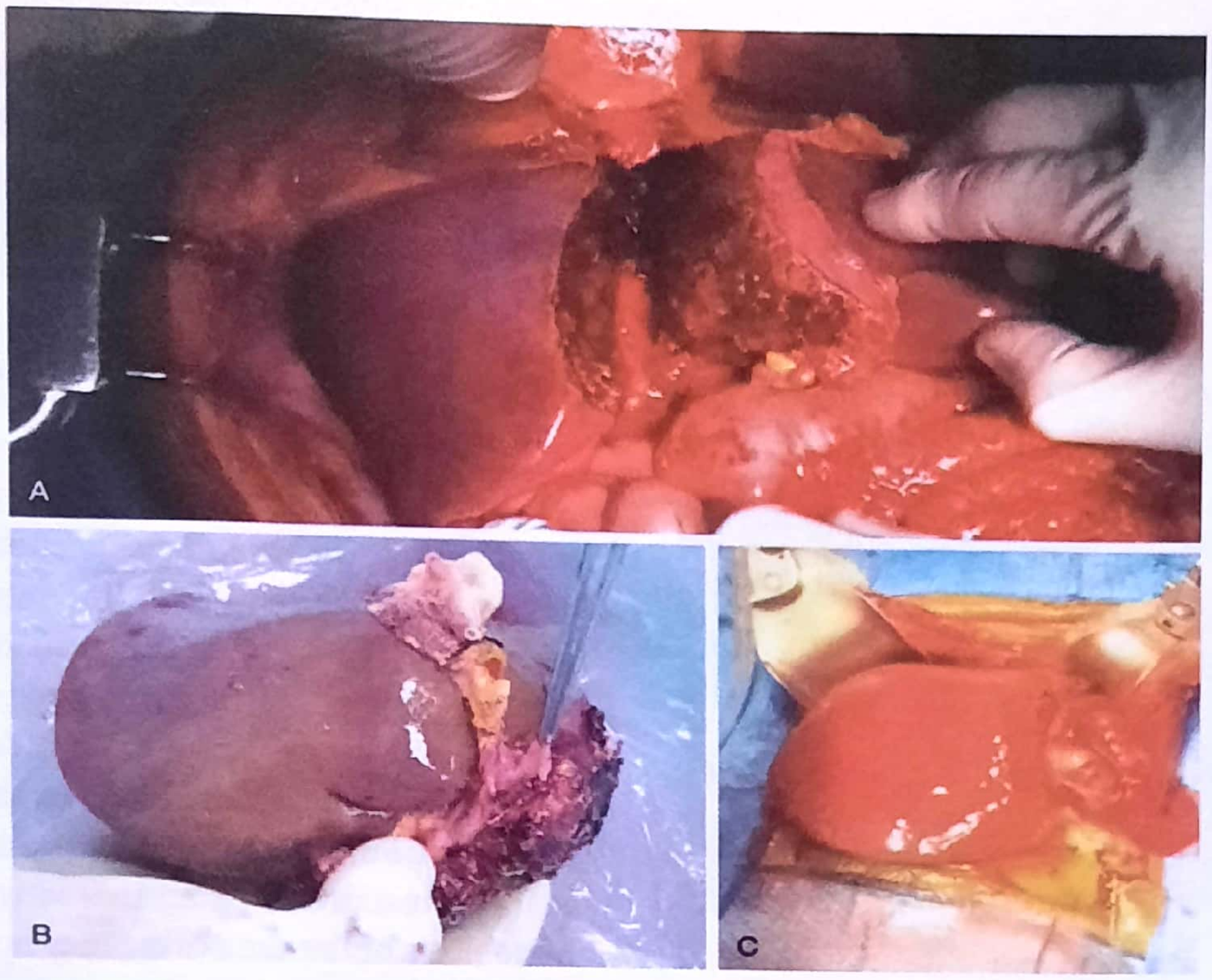

Figure 54.9: Split liver transplant for a child

- Age <10 yr or >40 yr
- Aetiology non-A, non-B, halothane or idiosynoratic drug reaction.
- More than 7 days jaundice before encephalopathy
- PT >50s
- Bilirubin >300 μmol/L

(B). **Auxillary Liver Transplant:** part of healthy liver is transplanted into the recipient, alongside part of recipient's liver. Indicated for:

- Reversible fulminant hepatic failure
- Non cirhotic metabolic liver disease
- Small for size graft
- ABO imcompatibility

III. **Split Liver Transplant:** Liver from a deceased donor is split in two parts — a small left lateral segment and a larger extended right lobe graft. Larger graft is transplanted to an adult recipient and smaller graft is for pediatric recipient.

Technique of Liver Transplantation

Donor operation

The round ligament is ligated and divided, the falciform ligament is incised and the left lateral segment is freed from the diaphragm. Inspection of the gastrohepatic ligament will reveal a replaced left hepatic artery. The attention is turned to the hepatoduodenal ligament, where a variable order of dissection is performed with the aim to identify one or more of the structures, including the common hepatic artery, common bile duct and portal vein. The liver is then removed with the entire length of the celiac artery and/or any other accessory or replaced arteries, a significant length of the portal vein, the common bile duct and the entire retrohepatic vena cava. Further preparation of the graft before transplantation is done on the bench while the liver is kept immersed in ice. In theory, preservation in University of *Wisconsin* solution may extend cold ischemia time up to 24 hours before revascularization.

Recipient hepatectomy

Bilateral subcostal incision is made with midline extension towards the xiphoid. The round ligament is clamped,

KEY BOX 54.4
Disease states causing liver failure that may be successfully treated with transplant
Noncholestatic Cirrhosis
Alcoholic
Nonalcoholic fatty liver disease
Hepatitis C
Cryptogenic cirrhosis
Autoimmune cirrhosis
Hepatitis B
Drug or exposure induced
Cholestatic Cirrhosis
Primary biliary cirrhosis (PBC)
Primary sclerosing cholangitis (PSC)
Caroli disease
Choledochol cyst

divided and ligated. The falciform ligament is divided down to the suprahepatie vena cava. At this stage, the left lateral segment is separated from diaphragm and the hepatogastric ligament is divided. The right and left branches of the hepatic artery are then ligated and divided at hilum. Similarly, the common bile duct and cystic ducts are ligated and divided. At this stage clamps are placed on the portal vein and suprahepatie vena cava and liver is removed.

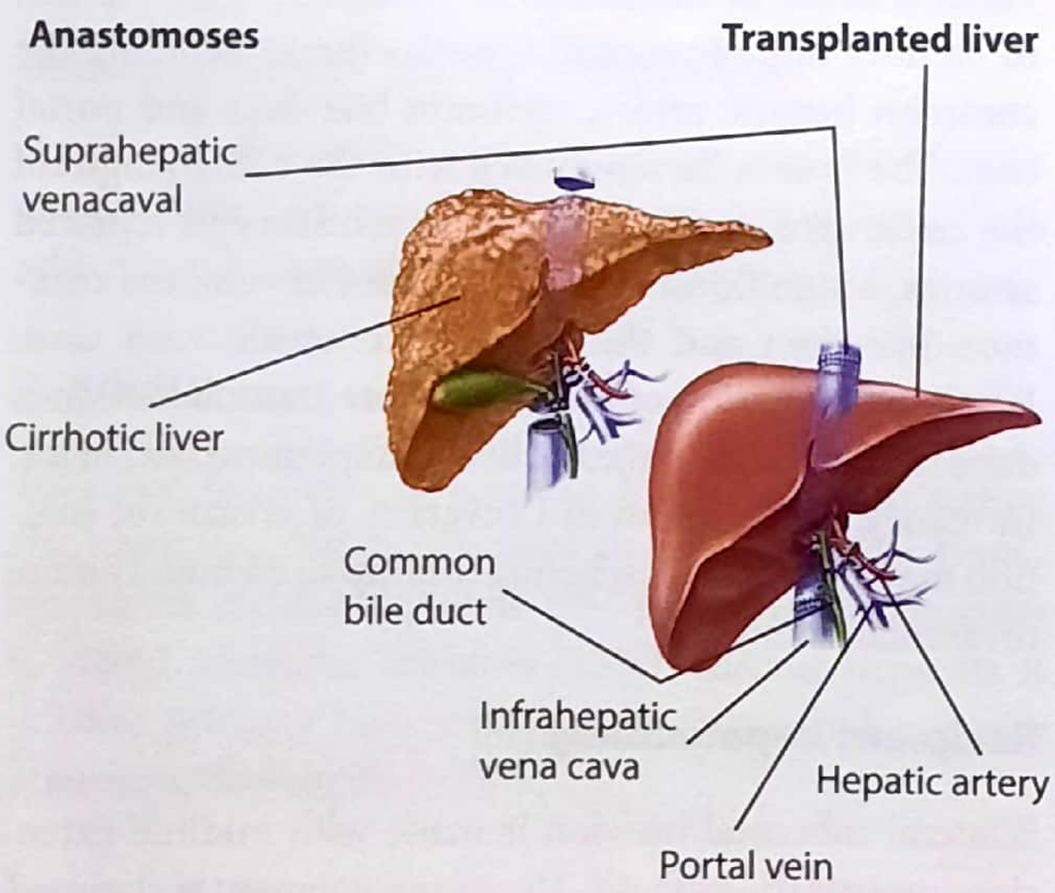

Figure 54.10: Liver transplantation

Milan criteria

Used for selecting patients for liver transplantation:

1. 1 lesion <5cm
2. Upto 3 lesion <3cm
3. No vascular invasion
4. No extrapathmanifestation

Anhepatic phase

After hemostasis, the retroperitoneum may be reapproximated to cover the bare area. The suprahepatie vena caval cuff is prepared by opening the orifice of the right, middle and left hepatic veins and oversewing of the phrenic branches transplantation is done by end-to-end anastomosis of the donors to the recipients suprahepatie vena cava, followed by similar end-to-end anastomosis of the intrahepatic vena cava. Alternatively an end-to-side anastomosis of the vena cavae may be utilized in a "piggyback" fashion in which the recipients entire vena cava is left intact.

The preservation solution is next flushed out with lactated ringers solution, the portal bypass cannula is removed, and portal vein anastomosis is carried out using a continuous suture, utilizing a "growth factor" to prevent stenosis at this anastomosis. The clamps are then released and the liver is reperfused with portal blood. This part of the procedure is critical and is characterized by varying degrees of "reperfusion syndrome, " which is manifested by hypotension, bradycardia, arrhythmia and rarely cardiac arrest.

Arterial revascularization and biliary reconstruction

End-to-end anastomosis using an aortic patch of the donor celiac artery and a branch patch of the recipient artery at the level of the gastro duodenal bifurcation. In most cases, biliary drainage can be achieved using a duct-to-duct anastomosis with or without placement of a T-tube. Alternatively, pathology of the bile duct such as in the presence of PSC or biliary atresia requires biliary drainage via a choledochojejunostomy.

Hepatic Arterial Reconstruction

The surgeon is faced with arterial complexities more often than venous abnormalities. Intimal dissection or other pathology of the hepatic artery may require the placement of on allogenic vascular graft to the recipients supraceliac or infrarenal aorta. The potential need for venous or arterial grafts for revascularization mandates

that the procuring team always obtains adequate donor blood vessels for potential extension grafts. In addition any unused blood vessel grafts must be kept refrigerated under sterile conditions for a few days after transplantation in case of emergent need for subsequent vascular reconstruction.

Immunological aspects of liver transplantation

The relatively low immunogenicity of liver allografts and the unique ability of the liver to generate are probably the main reasons for the excellent long-term outcome. Good results are achieved when graft and recipient are ABO blood group compatible. *Preoperative human leukocyte antigen (HLA) matching does not appear to be necessary* (MANY PGME). Most recipients are treated with combination therapy, which includes a calcineurin inhibitor (cyclosporine or tacrolimus), along with prednisolone with or without azathioprine or mycophenolate mofetil.

Acute rejection

T -cell-mediated acute rejection is seen at a rate of 30% to 50% within the first 6 months after transplantation, most often within the first 10 days. It's clinical presentation is variable and may include the development of fever, abdominal pain, elevated liver enzymes and bilirubin. Patients with a T-tube may manifest a decrease in quantity and change in character of the bile. The diagnosis is confirmed by a liver biopsy that will demonstrate the presence of lymphocytic infiltrate that extends into the liver parenchyma, as well as the invasion of inflammatory cells into the vascular endothelium.

Chronic rejection

It is usually characterized histologically by paucity of the bile ducts, thus often described as **"vanishing bile duct syndrome"**.

MELD score (Model for End stage Liver Disease)

Known as model for end stage liver disease.

MELD score is chronic liver disease severity scoring system to predict survival of the patient:

MELD score based on

↓

Creatinin

Bilirubin

INR

Score ranges from 6 to 40.

It is used for proritizing patients on the waitlist for decreased done liver transplantation.

Common complications

1. **Primary nonfunction** is a problem which is encountered in 2% to 5% of liver grafts. It is characterized by clinical and laboratory findings indicating poor synthetic function and severe hepatocytes injury. Laboratory findings demonstrate worsening acidosis coagulopathy and extremely elevated liver enzymes.
2. Hepatic artery thrombosis: is especially common in children (5-10%) and often requires retransplantation.
3. Intra-abdominal bleeding
4. Vascular thrombosis
5. Biliary leak
6. Infections

*****

HEART TRANSPLANTATION

Indications

1. Cardiomyopathy (40%) and coronary artery disease (40%) are most common. Congenital heart disease, valvular disease and retransplantation comprise the remaining 20%.
2. The age of recipients ranges from newborns to adults in their mid-60s.

Contraindications include severe **pulmonary hypertension** (NEET), tobacco use within 6 months and poor renal or pulmonary function, malignancy, active peptic ulcer disease.

Procedure

The heart transplant is both orthotopic & heterotopic (NEET)**. The orthotopic procedure requires institution of cardiopulmonary bypass** (heart-lung machine) followed by partial excision of the heart, preserving the posterior half of the atria and the interatrial septum. The donor heart is then implanted with two atrial suture lines, the pulmonary artery anastomosis and the aortic anastomosis.

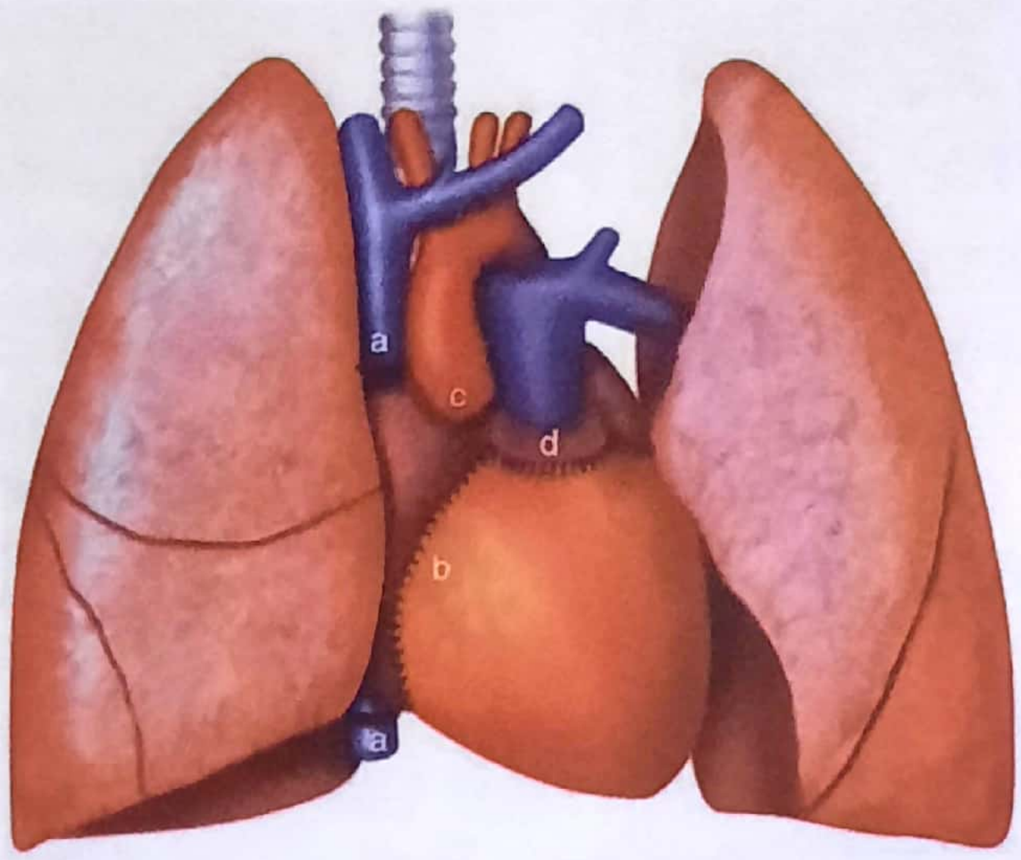

Figure 54.11: Suture lines for bicaval anastomosis

Postoperatively the heart provides normal cardiac output. As the heart is denervated, bradycardia is treated with pacing via temporary pacing wires implanted at surgery or via chronotropic drugs (e.g; isoproterenol). Initial immunosuppression is usually with corticosteroids, a calcineurin inhibitor and an antimetabolite, which are continued as maintenance therapy. Immunosuppression is started preoperatively.

Complications and results

1. Acute rejection is common.
2. Chronic rejection manifests as graft coronary artery disease.
3. Hypertension and renal insufficiency from cyclosporine or tacrolimus can be difficult to manage.
4. Mortality: Almost 10% of recipients die in the first month after transplantation. These deaths are often related to multiple organ failure or initial graft failure. Another 5% die during the next 11 months. Patient survival at 1 year is 85%.
5. Long-term patient survival is 70% at 5 years.

*****

LUNG TRANSPLANTATION

Indications

Emphysema, either smoking induced or secondary to alpha antitrypsin deficiency, has been the single largest indication for the lung transplantation. (IMP. POINT)

Other major indications for unilateral lung transplants include idiopathic pulmonary fibrosis (21%) and primary pulmonary hypertension (5%). The major diagnosis among heart-lung recipients are primary and secondary pulmonary hypertension (54%) and cystic fibrosis (16%).

Procedure

Single-lung transplantation is performed through a posterolateral thoracotomy and double-lung transplantation through a bilateral thoracotomy or median sternotomy. During lung transplantation; the donor pulmonary veins (on a left atrial cuff) are anastomosed to the recipient left atrium. Next, the bronchial anastomosis and the pulmonary arterial anastomosis are completed. Cardiopulmonary bypass is usually required if pulmonary hypertension is present. Dehiscence of the airway anastomosis is common after heart-lung transplantation, but improvements in organ preservation and surgical technique have dramatically reduced the incidence of this often fatal complication to <5%. Late airway stenosis at the bronchial anastomosis due to ischemia occurs in around 10% of bronchial anastomoses and is treated by dilatation.

*****

KEY BOX 54.5	
Effect of immunological compatibility	
Organ	**HLA matching**
Heart	Not important
Liver	Not important
Kidney	Important for both living & cadaver donor
Pancreas	Important for pancreatic transplant done alone

PANCREAS TRANSPLANTATION

The first clinical pancreatic transplant was performed by William in 1970. Lillehei published the first case in the Minnesota series of clinical pancreatic allotranaplants that began in 1966.

Indications

The indications for transplanting the pancreas remains controversial. It can be performed in three settings.

1. Alone in a preuremic patient.
2. After successful kidney grafting
3. And simultaneously with a kidney transplantation

Pancreas transplant is indicated for type I Diabetics and not for type II

Contraindication

1. Type II Diabetics
2. Intra-abdominal contamination
3. Acute pancreatitis
4. Pancreatic injury
5. History of diabetes in the donor

Combined pancreatic - renal transplantation

Immunosuppression and its inherent risk is the price the patient has to pay for getting insulin free following a successful pancreatic transplantation. About 75% of diabetics could still remain free of complication after 20 years of well maintained insulin therapy. Therefore 95% of pancreas transplantation have been performed in those, who needed immunosuppression for kidney. 87% of pancreatic transplantation have been performed as simultaneous pancreatico-renal transplants in those with actual or impending renal failure, 7% as pancreas after kidney, 5% as pancreas transplant alone and 1% as a part of multiorgan transplantation.

Transplantation of isolated pancreatic islets

Treatment of diabetes by transplantation of isolated islets of Langerhans is a more attractive concept than vascularized pancreas transplantation because major surgery and the potential complications of transplantation exocrine pancreas are avoided. Pancreatic islets for transplantation are obtained by mechanically disrupting the pancreas after injection of collagenase into the pancreatic duct.

Figure 54.12: Photograph of the "ideal pancreas"

The islets are then purified from the dispersed tissue by density gradient centrifugation and can be delivered into the recipient liver (the optimal, site for transplantation) by injection into the portal vein. The renal subcapsular space is an another excellent islets transplantation site.

A major attraction of this approach is that islets isolated from animals can be used and bioartificial pancreas grafts containing xenogeneic islets are currently under evaluation.

Complication (of pancreas transplantation)

1. Vascular thrombosis
2. Allograft pancreatitis
3. Fistula and abscess
4. Urologic complications

Results

One year survival rate of patient and graft survival in pancreatic transplantation is 90% and 75% respectively.

*****

SMALL BOWEL TRANSPLANTATION

Indications

I. Infants and children

1. Gastroschisis
2. Visceral myopathy and neuropathy

KEY BOX 54.6

Underlying conditions necessitating intestinal transplantation

Pediatric	Incidence (%)	Adult	Incidence (%)
Short bowel syndrome	63	Short bowel syndrome	64
- Gastroschisis	22	- Ischemia	24
- Volvulus	16	- Crohn disease	11
- Necrotizing enterocolitis	14	- Other	10
- Atresia	4	- Volvulus	8
- Ischemia	1	- Trauma	7
- Trauma	1		
- Unspecified	3		
Motility disorders	18	Tumor	13
Malabsorption syndromes	8	Motility disorders	11
Retransplantation	8	Other	9
Other	5	Retransplantaiotn	7

3. Jejuno-ileal atresia
4. Malrotation and mid gut rotation

II. In Adults

1. Trauma
2. Radiation injury
3. Desmoid tumour, Garden syndrome
4. Mesenteric infarction due to vascular occlusion
5. Idiopathic pseudo-obstruction
6. Crohn's disease

Results

In 1980's 20 patients after Bowel transplantation only 2 patients were able to resume oral diet. Introduction of tacrolimus (FK 506) based immunosuppression has provided a new hope to those involved in small bowel transplantation. One year survival rate is 60%. 3 year survival rate is 35% Despite dramatic improvements in clinical out come, the contraindication of bowel transplantation will always be more than other solid organ transplantation. In the treatment of intestinal failure small bowel transplant can become standard only when it can offer greater safety and better quality of life than long term total parenteral nutrition.

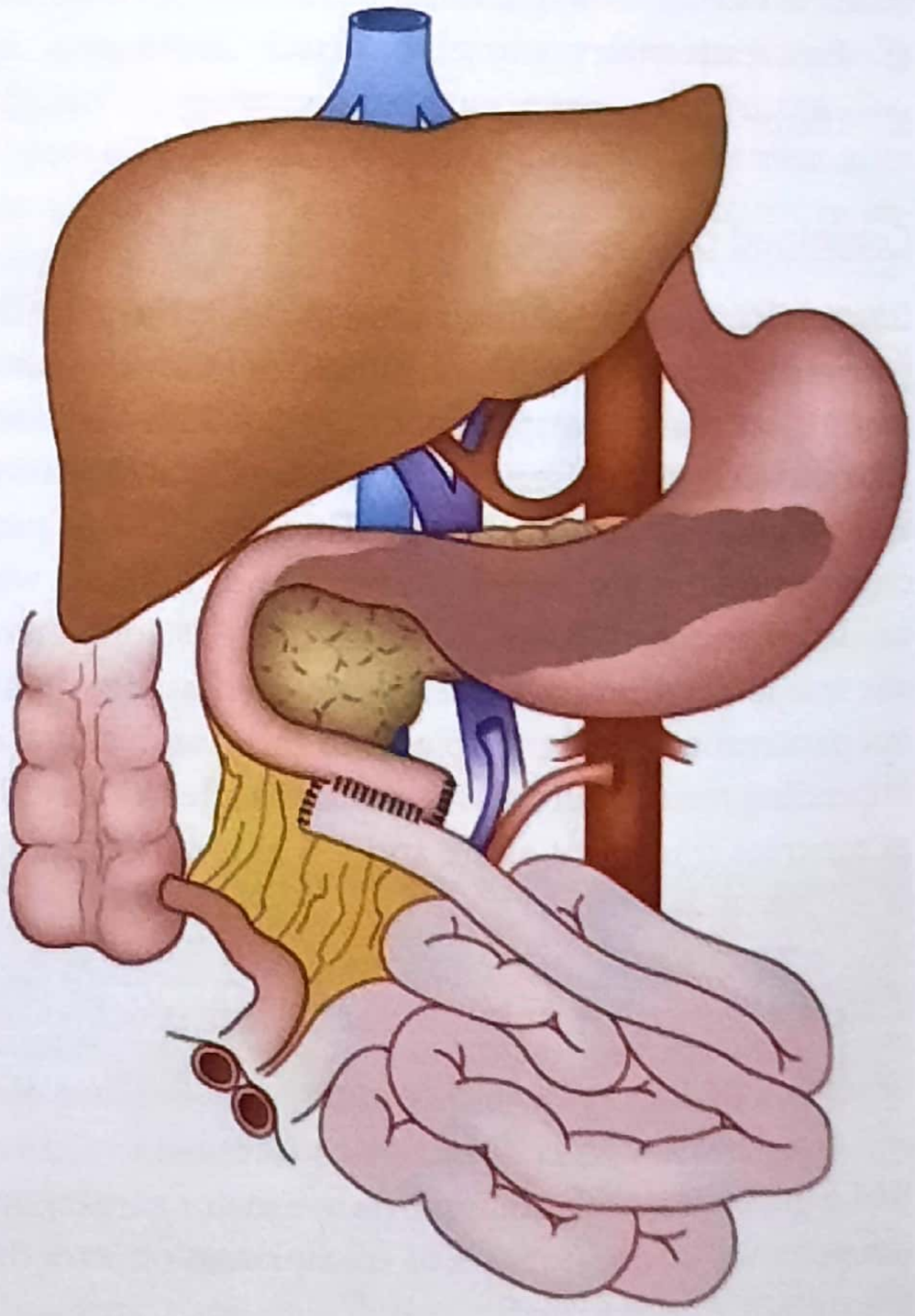

Figure 54.13: Isolated intestine transplant

KEY BOX 54.7 Diagnostic studies for evaluation of the intestine transplant candidate	
Diagnostic studies	**Tests and procedures**
Laboratory evaluation	Serum chemistries, liver function tests, complete blood count, prothrombin time-international normalized ratio, partial thromboplastin time, platelet count, albumin
Immunologic evaluation	HLA typing, HLA antibody, panel reactive antibody (PRA)
Serologic tests for infectious diseases	CMV immunoglobulin G/immunoglobulin M, EBV antibodies, hepatitis B virus, hepatitis C virus, HIV
Endoscopy	Upper gastrointestinal endoscopy, colonoscopy with biopsy
Pathology	Percutaneous liver biopsy
Radiographic evaluation	Upper gastrointestinal series with small bowel follow-through, barium enema Computed tomography of abdomen and pelvis, liver ultrasound Doppler ultrasonography of jugular and subclavian veins (or magnetic resonance venography) to assess patency Gastric emptying study, motility testing Two-dimensional echocardiography
Other	Nutrition, psychosocial, cardiopulmonary, and anesthesia assessment

History of Successful Transplants

1905: First successful cornea transplant by Eduard Zim

1954: First successful kidney transplant by Joseph Murray (Boston)

1970: First successful pancreas transplant by Richard Lillehei and William Kelly (Minnesota)

1967: First successful liver transplant by Thomas Starzl

1967: First successful heart transplant by Christiaan Barnard

1981: First successful heart/lung transplant by Bruce Reitz

1983: First successful lung lobe transplant by Joel Cooper

1986: First successful double-lung transplant by Joel Cooper (Toronto)

1987: First successful whole lung transplant by Joel Cooper

1995: First successful laparoscopic live-donor nephrectomy by Lloyd Ratner and Louis Kavoussi

2005: First successful partial face transplant

2006: First successful penis transplant in China

*****

55 Diagnostic Modalities

Contents

- X-ray
- Contrast enhance X-ray
  - Ba swallow
  - Ba meal
  - Ba meal follow through (BMFT)
  - Ba enema
- Ultrasonography
- CT Scan
- MRI Scan
- Magnetic resonance spectrography
- Radionuclide scanning (Isotope scintigraphy)
- PET scan

X-RAY

Definition

X-rays are a form of electromagnetic radiation, just like visible light. In a health care setting, a machines sends X-ray particles, called photons. These particles pass through the body. A special film is used to record the images that are created.

Structures that are dense (Such as bone) will block most of the x-ay particles and will appear white. Metal and contrast media (special dye used to highlight areas of the body) will also appear white. Structures containing air will be black and muscle, fat and fluid will appear as shades of gray. The test is performed in a hospital radiology department or in the health care provider's office by an x-ray technologist. The positioning of the patient, x-ray machine, and film depends on the type of study and area of interest. Multiple individual views may be requested. Much like conventional photography, motion causes blurry images on radiographs and thus, patients may be asked to hold their breath or not move during the brief exposure (about 1 second).

Patient is asked to remove all jewelry and wear a hospital gown during the X-ray examination because metal and certain clothing can obscure the images & require repeat studies.

Medical Uses

Since Rontgen's discovery that X-rays can identify bony structures, X-ray have been developed for their use in medical imaging. Radiology is a specialized field of medicine. Radiographer employ radiography and other techniques for diagnostic imaging. Indeed, this is probably the most common use of X-ray technology.

X-ray are especially useful in the detection of pathology of the skeletal system, but are also useful for detecting some disease processes in soft tissue. Some notable examples are the very common chest X-ray, which can

be used to identify lung diseases such as pneumonia, lung cancer or pulmonary edema, and the abdominal X-ray, which can detect ileus, free air (from visceral perforations) and free fluid (in ascites). In some cases, the use of X-rays is debatable, such as gallstones (which are rarely radiopaque; about 10%) or kidney stones (which are often visible, in about -90%). Traditional plain X-ray pose very little use in the imaging of soft tissues such as the brain or muscle. Imaging alternatives for soft tissue are computed axial tomography (CAT or CT scanning), magnetic resonance imaging (MRI) or ultrasound.

Radiotherapy a curative medical intervention used almost exclusively for cancer, employs higher energies of radiation.

Risks

During a single radiograph, a small fraction of the X-rays pass right through the body. The photons are absorbed by tissues in the body, The energy of the absorbed photons can break apart (ionize) compounds, and this may cause cell damage. Most cell damage is soon repaired. However, some damage is permanent.

For the exposures encountered in conventional radiography, the risk of cancer or heritable defects (due to damaged ovarian cells or sperm cells) is very low. Most experts feel that this low risk is largely outweighed by the benefits of information gained from appropriate imaging. X-ray are monitored and regulated to provide the minimum amount of radiation exposure needed to produce the image.

Young children and developing fetuses are more sensitive to the risks of x-rays. Women should always tell health care providers/X-ray technition about suspected pregnancy.

*****

CONTRAST ENHANCE X-RAY

An X- ray test where patient drinks a liquid that contains some barium sulphate can be used to obtain pictures of patient intestine. Barium is a soft, white metal. Barium sulphate is used for X-ray of digestive system. It is given as a white liquid drink (known as a **barium meal**) or into the anus (as **barium enema**). X-rays cannot pass through Barium, so when the X-ray pictures are taken, the outline of the stomach wall or bowel wall shows up on the X-ray.

Why is barium used during some X-ray tests?

The gut does not show up very well on ordinary X-ray pictures. However, if patient drink a white liquid that contains a chemical called barium sulphate, the outline of the gut (esophagus, stomach, small intestines and large intestine) shows up clearly on X-ray pictures. This is because *X-rays; do not pass through barium*.

Depending on what part of your gut is being looked at, patient may have one or more of the tests listed below. ***In each test, the barium coats the lining of the gut being tested. Therefore, abnormalities in the lining of gut wall or structure of the gut can be seen on the X-ray pictures.***

In each of the following tests, several X-ray pictures are taken using low dose X-rays. The total amount of radiation for each test is quite small and thought to be safe.

1. Barium swallow

In this test patient drinks some barium liquid. The barium liquid is often fruit flavoured. Patient stands in front of a X-ray machine; and X-ray pictures are taken as patient swallows. This test aims to look for problems in the esophagus such as a stricture (narrowing), hiatus hernias, tumours in esophagus, reflux from the stomach, disorders of swallowing, etc. Patient is asked not to eat or drink for a few hours before this test.

2. Barium Meal (Upper Gastrointestinal series)

This is similar to a barium swallow (read above) but aims to look for problems in the stomach and duodenum such as ulcers, polyps, tumours etc. patient drinks some barium liquid, and then patient lies on a table and then X-ray pictures are taken of stomach and duodenum.

3. Barium meal follow through (BMFT)

This test is similar to a barium meal but aims to look for problems in the small intestine. Therefore, patient drinks the barium liquid; but' than need to wait for 30-90 minutes, before any X-rays are taken. This allows time for the barium to reach the small intestine. Patient may then have an X-ray every 30 minutes or so until the barium is seen to have gone through all the small intestine and reached the large intestine (colon).

4. Barium enema (Lower Gastrointestinal series)

Barium enema is a special X-ray of the large intestine, which includes the colon and rectum. Before X-rays are

taken, a liquid called barium sulfate is placed into the rectal area. The liquid is a type of contrast. Contrast material (Barium) used can highlight specific areas inside the body, which creates a clearer image. The contrast eventually passes out of your body through your stools.

Procedure

The patient lies on the X-ray table and a preliminary X-ray is taken. Then gently a well lubricated tube is insert into rectum. The tube is connected to a bag that contains the Barium. The barium is allowed to flows into rectum & colon.

A small balloon at the tip of-the enema tube may be inflated to help keep the barium inside the colon. The flow of the barium is monitored on an X-ray fluoroscope screen, which is like a TV monitor. (Figure # 55.1)

There are two type of barium enemas:-

- Single contrast barium enema uses only barium to highlight your large intestine
- Double contrast barium enema uses the barium, but also delivers air into the colon to expand it. This allows for even better images.

At certain times when the X-ray pictures are taken, patient is asked to hold his breath and remain still for a few seconds so the images won't be blurry. The enema tube is removed after the pictures are taken.

One other contrast medium which can be used is Gastrografin.

*****

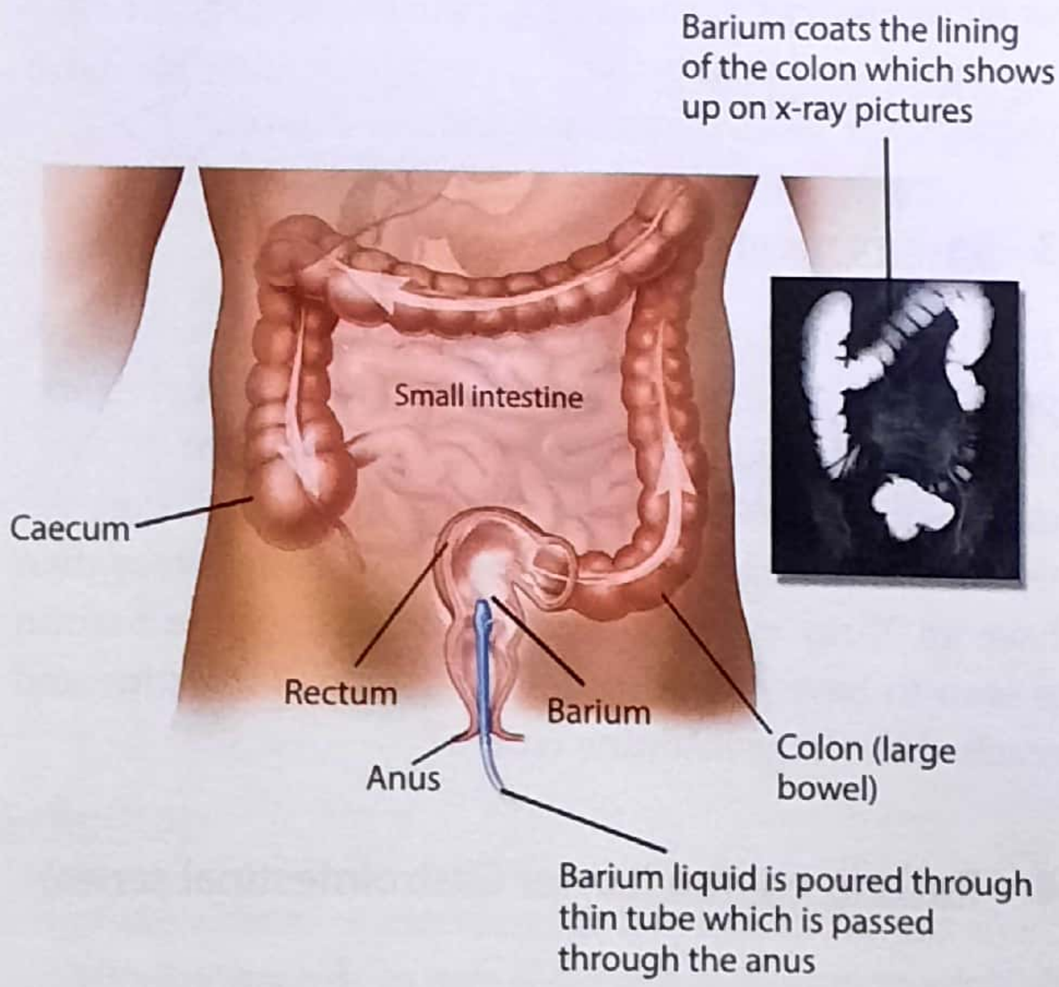

Figure 55.1: Barium enema

ULTRASONOGRAPHY

Medical sonography (ultrasonography) is an ultrasound-based diagnostic imaging technique used to visualized muscles and internal organs, their size, structures and possible pathologies or lesion. Obstetric sonography is commonly used during pregnancy and is widely recognized by the public.

In physics the term "ultrasound" applies to all acoustic energy with a frequency above human hearing (20,000 hertz or 20 kilohertz). *Typical diagnostic sonographic scanners operate in the frequency range of 2 to 8 megahertz*, hundreds of times greater than the limit of human hearing. The choice of frequency is a trade-off between spatial resolution of the image and imaging depth: lower frequencies produce less resolution but image deeper into the body and vice-versa. Ultrasound imaging, also called ultrasound scanning or sonography, involves exposing part of the body to high-frequency sound waves to produce pictures of the inside of the body. Ultrasound exams do not use ionizing radiation like x-ray/CT scan. Because ultrasound images are captured in real-time, they can show the structure and movement of the body's internal organs, as well as blood flowing through blood vessels.

A general-purpose sonographic machine may be able to be used for most imaging purposes. Usually specialty applications may be served only by use of a specialty transducer. The dynamic nature of many studies generally requires specialized features in a sonographic machine for it to be effective; such as endovaginal, endorectal, or transesophageal transducers.

Figure 55.2: Ultrasound Machine

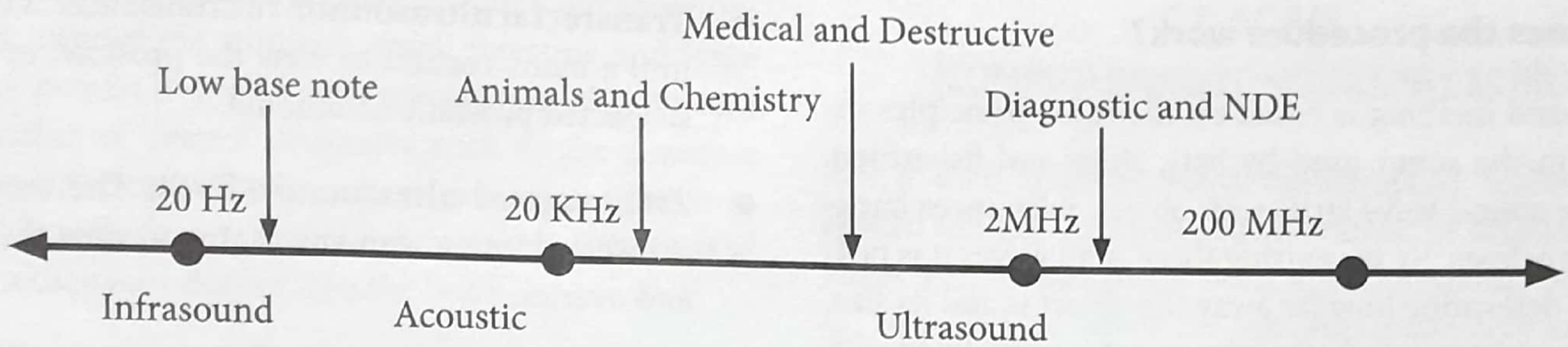

Obstetrical ultrasound is commonly used during pregnancy to check the development of the fetus.

Various Types of Ultrasound

Conventional ultrasound displays the images in thin, flat sections of the body, advancements in ultrasound technology include three-dimensional (3-D) **ultrasound** that formats the sound wave data into 3-D images. Four dimensional (4-**D**) **ultrasound** is 3-D ultrasound in motion.

Doppler Ultrasound

Doppler ultrasound is a *special ultrasound technique that evaluates blood as it flows through a blood vessel,* including the body's major arteries and veins in the abdomen, arms, legs and neck.

Types of Doppler Ultrasound

(i) *Colour Doppler* uses a computer to convert Doppler measurements into an array of colours to visualize speed and direction of blood flow through a blood vessel.

(ii) *Power Doppler* is a newer technique that is more sensitive than color Doppler and capable of providing greater detail of blood flow, especially in vessels that are located inside organs. Power Doppler, however, does not help the radiologist determine the direction of flow, which may be important in some situations.

(iii) *Spectral Doppler,* instead of displaying Doppler measurements visually, spectral Doppler displays blood flow measurements graphically, in terms of the distance traveled per unit of time.

Modes of Sonography

A-mode: A-mode is the simplest type of ultrasound. A single transducer scans a line through the body with the echoes plotted on screen as a function of depth. Therapeutic ultrasound aimed at a specific tumour or calculus is also A-mode, to allow for pinpoint accurate focus of the destructive wave energy.

B-mode: In B-mode ultrasound, a linear array of transducers simultaneously scans a plane through the body that can be viewed as a two-dimensional image on screen.

M-mode: M stands for motion. In M-mode a rapid sequence of B-mode scans whose images follow each other in sequence on screen enables doctors to see and measure range of motion, as the organ boundaries that produce reflections move relative to the probe.

Doppler mode: This mode makes use of the Doppler effect.

*****

ULTRASOUND SCANNER

Ultrasound scanners consist of a console containing a computer and electronics, a video display screen and a transducer (probe); which is a small hand-held device that resembles a microphone, attached to the scanner by a cord. The transducer sends out a high frequency sound wave and then listens for a returning sound wave or "echo".

The ultrasound image is immediately visible on a nearby screen that looks much like a computer or television monitor. The image is created based on the amplitude (strength), frequency and time it takes for the sound signal (organ) to return from the patient to the transducer.

How does the procedure work?

Ultrasound imaging is based on the same principles involved in the sonar used by bats, ships and fishermen. When a sound wave strikes an object, it bounces backward or echoes. By measuring these echo waves it is possible to determine how far away the object is and its size, shape, consistency (whether the object is solid, filled with fluid, or both) and uniformity.

The probe (transducer) sending the sound waves; also picks up the reflected waves (echoes) and a converts them into an image, which is visible on a screen.

In an ultrasound examination, a transducer both sends the sound waves and records the echoing waves. When the transducer is pressed against the skin, it directs a stream of inaudible, high-frequency sound waves into the body. As the sound waves bounce off of internal organs, fluids and tissues, the sensitive microphone in the transducer records tiny changes in the sound's pitch and direction. These signature waves are instantly measured and displayed by a computer, which in turn creates a real-time picture on the monitor. These live images are usually recorded on videotape and one or more frames of the moving pictures are typically captured as still images.

Depending upon the consistency of the various tissues the waves may be reflected abundantly {hyperechoic}, may not be reflected at all {anechoic}, may have the same reflection as the surrounding tissues {isoechoic} or a solid tumour or blood clot of organizing abscess may cause less echoes reflection than the surrounding structures {hypo echoic}.

In clinical practice; ultrasound is used to detect changes in appearance and function of organs, tissues or abnormal masses, such as tumours.

Doppler ultrasound, a special application of ultrasound, measures the direction and speed of blood cells as they move through vessels. The movement of blood cells causes a change in pitch of the reflected sound waves (Doppler effect). A computer collects and processes the sounds and creates graphs or pictures that represent the flow of blood through the blood vessels.

In some ultrasound studies, the transducer is attached to a probe and inserted into a natural opening in the body. These examinations include:

- **Transesophageal echocardiogram:** The transducer is inserted into the esophagus to obtain images of the heart.
- **Transrectal ultrasound:** The transducer is inserted into a man's rectum to view the prostate; in case of suspected prostatic carcinoma.
- **Transvaginal ultrasound (TVS):** The transducer is inserted into a woman's vagina to view the uterus and ovaries.
- **Laparoscopic ultrasound:** The transducer is mounted on a laparoscope, and passed in peritoneal cavity during laparoscopy, which provides clinician clear images of internal organs. Most ultrasound examinations are completed within 30 minutes to an hour.

Benefits

- Ultrasound scanning is noninvasive (no needles or injections) and is usually painless.
- Ultrasound is widely available, easy-to-use and less expensive than other imaging methods.

(USG= 600-800 rupees, CT= 4000-8000 rupees, while MRI 8500-10,000 rupees)

- Ultrasound imaging uses no ionizing radiation.
- Ultrasound scanning gives a clear picture of soft tissues that do not show up well on X-ray images.
- Ultrasound causes no health problems and may be repeated as often as is necessary, if indicated.
- Ultrasound is the preferred imaging modality for the diagnosis and monitoring of pregnant women and their unborn infants.
- Ultrasound provides real-time imaging, making it a good tool for guiding minimally invasive procedures such as needle biopsies (USG guided biopsy) and needle aspiration (USG guided aspiration) of fluid in joints, abdominal cavity or elsewhere.

Risks

For standard diagnostic ultrasound there are no known harmful effects on humans.

Limitation

Ultrasound waves are reflected by air or gas; therefore ultrasound is not an ideal imaging technique for the bowel. Barium study and CT scanning are the methods of choice for bowel-related problems.

Ultrasound waves do not pass through air; therefore an evaluation of the stomach, small intestine and large intestine may be limited. Intestinal gas may also prevent visualization of deeper structures such as the pancreas and aorta. Patients who are obese are more difficult to image because tissues attenuates (weakens) the sound waves as they pass deeper into the body.

Ultrasound has difficulty in penetrating bone and therefore can only see the outer surface of bony structures and not what lies within. For visualizing internal structure of bones such as spinal cord/brain or certain joints, other imaging modalities such as MRI are typically used.

Here I would like to explain on more diagnostic test usually carried out especially in a case with blunt abdominal trauma.

Focussed abdominal sonography for trauma (FAST)

This is a modification of the conventional USG abdomen to identify intra-peritoneal free fluid.

It can rapidly identify any source of hemorrhage in the peritoneal cavity in trauma patients, who are too unstable to undergo CT scan. It is useful to evaluate those patients without major risk factors for abdominal injury, who do not require more extensive evaluation of abdominal cavity.

It is 90% sensitive 99% specific and 98% accurate for intraabdominal injury. It is portable, non invasive, rapid and easy. It can detect as little as 100 ml fluid in the peritoneal cavity. It uses a 3.5 MHz transducer and one can complete the abdominal examination in 2 *m* minutes. It detects free fluid in pericardial sac, hepatorenal (morrison's) pouch, splenorenal recess and pelvis.

Standard practice is to keep the transducer at 4 different positions. *(IMP. POINT)*

1. Sub xiphoid region to check; heart and pericardial cavity
2. Right mid axillary line between 11th and 12th ribs
3. Left posterior axillary line between 9th and 10th ribs
4. 4 cm above the pubic symphysis

FAST is helpful diagnostic test in assessing abdominal trauma; particularly blunt abdominal trauma.

*****

CT SCAN

(COMPUTERIZED TOMOGRAPHY SCAN)

A CT scan (computerized tomography) scanner is a special kind of X-ray machine. Instead of sending out a single X-ray through the body as with ordinary X-ray, in CT scan several beams are sent simultaneously at different angles.

CT scan is some times called a CAT scan which is acronym of computerized axial tomography.

How does a CT scanner work

In many ways CT scanning works very much like other X-ray examinations. X-rays are a form of radiation like light or radio waves-that can be directed at the body. Different body parts absorb the X-rays in varying degrees. In a conventional X-ray examination, a small burst of radiation is aimed at and passes through the body, recording an image on photographic (a special image recording plate). Bones appear white on the X-ray; soft tissue shows up in shades of gray and air appears black.

With CT scanning, numerous X-ray .beams and a set of electronic X-ray detectors rotate around patient, *measuring the amount of radiation being absorbed throughout patients body.* At the same time, the examination table is moving through the scanner, so that the X-ray beams follow a spiral path. A special computer software program processes this series of pictures, or slices of your body to create two-dimensional cross-sectional images, which are then displayed on a monitor.

CT imaging is sometimes compared to looking into a loaf of bread by cutting the loaf into thin slices. When the image slices are reassembled by computer software, the results is a very detailed multidimensional view of the body's interior. Refinements in detector technology allow new CT scanners to obtain multiple slices in a single rotation. These scanners, called "multislice CT" or "multidetector CT" allow thinner slices to be obtained in a shorter period of time, resulting in more detail and additional view capability.

Modern CT scanners are so fast that they can scan through large sections of the body in just few seconds.

The technique of CT scanning was developed by British inventor ***Godfrey Hounsfield,*** who was awarded the noble prize for this work.



Figure 55.3 A CT Scan unit

How is a CT scan carried out

The CT scanner is typically a large machine with a hole/ or tunnel in the center. A moveable examination table slides into and out of this tunnel. In the center of the machine, the X-ray tube and electronic X-ray detectors are located opposite each other on a ring, called a gantry, which rotates around patient. The computer that processes the imaging information and monitor are located in a separate room. The length of the test depends on the members of pictures and the different angle taken.

As there is little room inside the tunnel people who suffer from sever claustrophobia sometimes has problems with CT scan.

Contrast CT

For some CT exams, a contrast material (usually a dye) is used to enhance visibility in the area of the body being studied.

If the patient is receiving an abdomen scan, for example, they will be asked not to eat for six hours before the test. They will be given a drink containing gastrografin, an flavoured X-ray dye, 45 minutes before the procedure. This makes the intestines easier to be visualized on the pictures. Sometimes a liquid X-ray dye is injected into the veins during the test. This also makes it easier to see the organs, blood vessels or for example, a tumour. The injection might be a little uncomfortable and some people also experience a feeling of warmth in their arm.

Spiral CT scan (Helical CT scan)

This is a newer type of CT scan, also known as a 'helical' CT scan. It is faster than a standard CT scan and gives an even more detailed picture of organs and tissues, including blood vessels. This can make it useful for picking up very small tumours. It is called as spiral scan because the X-ray beam rotates around the patient during the scan in a spiral fashion. This gives the radiographer a continuous picture, with no possible gaps between die 'slices' of the scan.

Benefits of CT scan

- CT scanning is painless, noninvasive and accurate.
- A major advantage of CT is that it is able to image bone, soft tissue and blood vessels all at the same time.
- Unlike conventional X-ray, CT scanning provides very detailed images of many types of tissue as well as the lungs, bones and blood vessels.
- CT examinations are fast and simple; in emergency cases, they can reveal internal injuries and bleeding quickly enough to help save lives.
- CT may be less expensive than MRI.
- CT imaging provides real-time imaging, making it a good tool for guiding minimally invasive procedures such as needle biopsies and needle aspirations of many areas of the body, particularly the lungs, abdomen, pelvis and bones.
- CT is for retroperitoneal tumors & trauma.

- A diagnosis determined by CT scanning may eliminate the need for exploratory surgery and surgical biopsy.

Risk of CT scan

- There is always a slight chance of cancer from radiation. However; the benefit of an accurate diagnosis far outweighs the risk.
- CT scanning is, in general, not recommended for pregnant women because of potential risk to the baby.
- Nursing mothers should wait for 24 hours after contrast material injection before resuming breast-feeding.
- The risk of serious allergic reaction to contrast materials that contain iodine though rare but is definitely present.
- Children should have a CT study only if it is essential for making a diagnosis and should not have repeated CT studies unless absolutely necessary.

Limitations of CT scan

Very fine soft-tissue details in areas such as the knee or shoulder can be more readily and clearly seen with magnetic resonance imaging (MRI). The CT examination is generally not indicated for pregnant women due to irradiation exposure and subsequent cancer development in fetus. A person who is very obese may not fit in CT scanner.

*****

MRI
(MAGNETIC RESONANCE IMAGING)

MRI (magnetic resonance imaging) is a fairly new technique that has been used since the beginning of the 1980s. The MRI scan *uses magnetic and radio waves,* meaning that there is no exposure to X-rays or any other damaging forms of radiation.

Magnetic resonance imaging (MRI) is primarily used in medical imaging to visualize the structure and function of body. **MRI has much greater soft tissue contrast than CT scan making it especially useful in neurological, muscles skeletal, cardiovascular and oncological disease.** Unlike CT; it does not use ionization radiation. The scanner creates a powerful magnetic field which aligns the magnetization of hydrogen atoms to emit a weak radio signals, which is amplified by the scanner. This signal can be manipulated by additional magnetic fields to build up enough information to reconstruct an image of the body.

The scanners used in clinical practice has a typical magnetic field strength of 0.2 to 3 teslas (2,000-30,000 gauss).

NOTE: magnetic field of earth which causes compass needle to point towards north; typically ranges between 0.2 gauss and 0.6 gauss. Note how strong magnetic field is produced durinh a MRI procedure.

How does an MRI scanner work?

The patients lies inside a large, cylinder-shaped magnet. Waves 10,000 to 30,000 times stronger than the magnetic field of the earth are then sent through the body. This affects the body's atoms, forcing the nuclei into a different position. As they move back into place they send out radio waves of their own. The scanner picks up these signals and a computer turns them into a picture. These pictures are based on the location and strength of the incoming signals. Our body consists mainly of water which contains hydrogen atoms. For this reason, the nucleus of the hydrogen atom is often used to create an MRI scan in the manner described above.

Interpretation

Using an MRI scanner, it is possible to make picture of almost all the tissue in the body. The tissue that has the least hydrogen atoms (such as bones) turns out dark, while the tissue that has many hydrogen atoms (such as fatty tissue) looks much brighter. By changing the timing of the radio wave pulses; it is possible to gain information about the different types of tissue that are present.

An MRI scan is also able to provide clear pictures of parts of the body that are surrounded by bone tissue, so the technique is useful when examining the brain and spinal cord.

Because the MRI scan gives very detailed pictures; it is the best technique when it comes to finding tumours (benign or malignant) in the brain. If a tumour is present, the scan can also be used to find out; the degree of spread into nearby brain tissue.



Figure 55.4: A MRI Unit

MRI versus CT scan

With an MRI scan it is possible to take pictures from almost at every angle, where as a CTscan only shows pictures horizontally. There is no ionizing radiation (X-rays) involved in producing an MRI scan. MRI scans are generally more detailed too. The difference between normal and abnormal tissue is often clearer on the MRI scan than on the CT scan.

Since patient is exposed to a powerful magnetic field during the MRI scan, it is important not to wear jewelry or any other metal objects.

It is also important for the patient to inform medical staff if they use electrical appliances, such as a hearing aid or pacemaker or have any metal in their body such as surgical clips, but orthopaedic metal ware such as artificial hips or bone screws is not normally a problem.

Risk of MRI

There are no known dangers or side effects of MRI scan, the test is not painful; and patient cannot feel it. Since radiation is not used, the procedure can be repeated without problems. There is a small theoretical risk to the foetus in the first 12 weeks of pregnancy, and therefore scans are not performed on pregnant women during this time. Because patients have to lie inside a large cylinder while the scans are being made. Some people get claustrophobic during the test. The machine also makes a banging noise while it is working, which might be unpleasant.

Magnetic Resonance Angiography

Magnetic resonance angiography (MRA) is used to generate pictures of the arteries in order to evaluate them for stenosis (abnormal narrowing) or aneurysm (vessel wall dilatation). Gadolium is a paramagnetic contrast agent used in MRA. Magnetic resource venography (MRV) is a similar procedure that is used to image vein.

Magnetic Resonance Spectrography

It is used to measure the levels of different metabolites in body tissue. The MR signal produces spectrum of difference resonance that correspond to different molecular arrangements of the isotopes being 'excited'. This signature is used to diagnose certain metabolic disorder, especially those affecting the brain, as well as to provide information on tumour metabolism.

*****

RADIONUCLIDE SCANNING
(ISOTOPE SCINTIGRAPHY)

How does a radionuclide scan work?

A radionuclide (sometimes called a radioisotope or isotope) is a chemical which emits a type of radioactivity called gamma rays. A tiny amount of radionuclide is put into the body, usually by a injection into a vein. (Sometimes it is breathed in or swallowed, depending on the test). There are different types of radionuclides. Different ones tend to collect or concentrate in different organs or tissues. The radionuclide used depends on which part of the body is to be scanned. For example, if radioactive iodine is injected into a vein; it is quickly taken up into the tissues of the thyroid gland, hence it is used to scan the thyroid. Cells which are most 'active' in the target tissue of organ will take up more of the radionuclide. So active parts of the tissue will emit more gamma

rays than less active or inactive parts. Gamma rays are similar to X-rays and are detected by a device called as gamma camera. Gamma rays which are emitted from inside the body are detected by the gamma camera & are converted into an electrical signal & sent to a computer. The computer builds a picture by converting the different intensities of radioactivity emitted into different colours or shades of grey. For example, areas of the target organ or tissue which emit lots of gamma rays may be shown as red sports ('hot spots') on the picture on the computer monitor. Areas which emit low levels of gamma rays may be shown as blue ('cold spots'). Various other colours may be used for 'in between' levels of gamma rays emitted.

Procedure

Depending on the type of scan required, patient swallows a small quantity of radionuclide, or it is injected into a vein in arm. It then takes some time, sometimes several hours (depending on what is being scanned) for the radionuclide to travel to the target organ or tissue, and to be 'taken' into the active cells. So, after receiving the radionuclide patient has to wait for few hours.

When it is time to do the scanning, patient lies on a couch while the gamma camera detects the gamma rays coming from patients body, and the computer turns the information into a picture.

Indication

- A bone scan is perhaps the commonest indication. A radionuclide is used which collects in areas where there is a lot of bone activity (where bone cells are breaking down or repairing parts of the bone). So a bone scan is used to detect areas of bone where there is cancer, infection or damage. These areas of activity are seen as 'hot spots' on the scan picture.
- A kidney scan can assess how well a kidney is working (as the radionuclide chosen is taken up by kidney cells and passes into the urine). So, the scan can detect scars on the kidney and how well urine drains from the kidney to the bladder.
- Lung perfusion Scan (or 'VQ scan') can detect blood clots in the lungs (pulmonary embolus).
- A heart scan can assess blood flow to the heart muscle. Areas of poor blood flow do not 'take up' the radionuclide very well and this will be shown in the picture.
- Thyroid scan may be done to assess cases of overactive thyroid (hyperthyroidism). For example; some nodules are sometimes a focus of over activity and will show as 'hot spots' on the picture.

Risks

The term 'radioactivity' may sound alarming, but the radioactive chemicals used in radionuclide scans are considered to be safe; because they leave the body quickly in the urine. The dose of radiation that your body receives is very small. However, as with any other types of radiation (such as X-rays) there is a small risk that the gamma rays may affect an unborn child.

*****

PET SCAN

A positron emission tomography (PET) scan is a unique type of *imaging test that helps clinician in detecting how the organs and tissues inside the body are actually functioning.*

Positron emission tomography, also called PET imaging or a PET scan; is a diagnostic examination that involves the acquisition of **physiologic images** based on the detection of radiation from the **emission of positrons.** Positrons are tiny particles emitted from a radioactive substance administered to the patient. The subsequent images of the human body developed with this technique on a computer monitor evaluate a variety of diseases.

Procedure

Before the examination begins, a radioactive substance is produced in a machine called a cyclotron and attached, or tagged to a natural body compound, most commonly glucose; and sometimes to water or ammonia. Once this substance is administered to the patient, the radioactivity localizes in the appropriate areas of the body and is detected by the PET scanner.

Different colours or degrees of brightness on a PET image represent different levels of tissue or organ function.

For example: Because healthy tissue uses' glucose for energy, it accumulates some of the tagged glucose, which uses more glucose than normal tissue will accumulate more of the substance and appear brighter than normal tissue on the PET images.

A technologist will take patient into a special injection room, where the radioactive substance is administered as an intravenous injection (although in some cases, it will be given through an existing intravenous line or inhaled as a gas). It will then take approximately 30 to 90 minutes for the substance to travel through your body and accumulate in the tissue under study. During this time, patient is asked to rest quietly and avoid significant movement or talking, which may alter the localization of the administered substance. After that time, scanning begins. Patient is asked to lie down on a flat examination table that is moved into the center of a PET scanner: (a doughnut like shaped machine). This machine detects and records the energy given off by the tracer substance with the aid of a computer, then this energy is converted into three-dimensional pictures. A physician can then look at cross-sectional images of the body organ from any angle in order to detect any functional problems. This take 30 to 45 minutes.

PET scan Versus CT/MRI scan

One of the main differences between PET scans and other imaging tests like CT scan or magnetic resonance imaging (MRI) is that the **PET scan reveals the cellular level metabolic changes occurring in an organ or tissue.** This is important and unique because disease processes often begin with functional changes at the cellular level. A PET scan can often detect these very early changes whereas a CT or MRI detect changes a later; when as the disease has produced changes in the structure of organs or tissues.

Indications of PET scan

A PET scan can measure; vital functions, such as blood flow, oxygen use by the tissue and glucose metabolism of the tissue, which helps clinician in identifying abnormal from normal functioning organs and tissues. The scan can also be used to evaluate the effectiveness of a patients. treatment plan, allowing the course of care to be adjusted if necessary.

Currently; PET scans are most commonly used to detect cancer, heart problems (such as coronary artery disease and damage to the heart followings a heart attack), brain disorders (including brain tumors, memory disorders, seizures) and other central nervous system disorders.

*****

INDEX

A

Abbe flap 172

Abdominal compartment syndrome 744

Abdominal incisions 751

Abdominal paracentesis 732

Abdominal wall 746

Abdominal wall dehiscence 746-748

Abdomino-perineal resection 687

Abdomino-scrotal hydrocele 900

ABI 291

Abnormal wound healing 12

Abrasion 2

Abscess 53

Acalculus cholecystitis 505

Accessory pancreatic tissue 530

Accessory spleen 558

Achalasia cardia 375-377

Acoustic Neuroma 163

Acquired auto-immune hemolytic anemia 567

Acquired diverticula 597

Acrocyanosis 301

Actinic keratosis 131

Actinomycin D 926

Acute rejection 974

Acute retention of urine 852

Acute cholecystitis 505

Acute acalculus cholecystitis 511

Acute anal fissure 698

Acute appendicitis 664, 953

Acute breast abscess 344

Acute cholecystitis 509

Acute crohn's disease 610

Acute epididymoorchitis 905, 968

Acute erosive gastropathy 411

Acute gastric dilatation 452

Acute intestinal obstruction 640

Acute ITP 565

Acute mesenteric ischemia 658-670

Acute pancreatitis 533, 534

Acute paronychia 110

Acute parotitis 195

Acute prostatitis 852-853, 865

Acute pyelonephritis 816-817

Acute scrotum 965

Acute suppurative parotitis 196

Acute suppurative tenosynovitis 111

Acute thromboembolism 297

Acute thyroiditis 244

Acute tubercular peritonitis 578

Acute wound 5
Adamantinoma 189
Adenoearcinoma lung – 281
Adenocarcinoma of colon 625
Adeno lymphoma 201
Adenoid cystic Carcinoma 202
Adenoma - carcinoma sequence 684
Adenomatous polyp 624-625
Adhesive intestinal obstruction 652
Adiposa dolorosa 124
Adjuvant chemotherapy 923
Administration of nutrition 44
Adrenal Incidentaloma 267
Adson's test 215, 311
Adult polycystic kidney disease 797
Advanced gastric cancer 442
Advanced trauma life support approach 721
Adynamic obstruction 656-658
Afferent loop syndrome 431
Ainhum 126
Air reduction 651
Alagilla syndrome 522
Albumin 30
Alfa adrenergic blocker 856
Alfa reductase inhibitor 856
Alkaline reflux gastritis 430
Alkylating agents 925
Allograft 972
Alveolar Abscess-185
Altmeir's operation 682
ALTS 721
Alvardo scoring 669
Alveolar abscess 185
Amastia 331
Amebic liver abscess 470-471
Ameloblastic fibrosarcoma 190
Ameloblastoma 189
Ammonium urate stone 809
Ampulla of Vater 495
Amputation 303
Anal advancement flap 700
Anal column of Morgagni 692
Anal dilatation 699
Anal fissure 698
Anal sphincter 693
Anal stricture; non malignant 713
Anal valve 692
Anaphylactic shock 19
Anaplastic Carcinoma of thyroid 249
Anaplastic seminoma 907
Anatomy of Ulcer 60
Anchovy sauce 470
Anderson-Hynes operation 806
ANDI 343
Aneurysmal bone Cyst 191
Anencephaly 160
Angiodysplasia 596
Angioscopy 292
Angiogenesis 8
Angiosarcoma-Skin 142
Ankle brachial index (ABI) 291
Annular pancreas 530
Anorectal malformation 984
Anorectal abscess 710
Anorectal ring 691
Anterior urethera 875
Antegrade urogram 791
Anterior abdominal wall 746
Anterior gastrojejunostomy 449
Anterior triangle of neck 205
Antibioma 54
Antibioma of breast 345
Antimetabolite 926-929
APACHE II score 538
Apical abscess 111
Apical Cyst 186
APKD 797

Appendicectomy 671-672
Appendices epiploicae 590
Appendicular artery 663
Appendicular lump 673
Appendicular mass 673
Appendix testis 904
Apple core lesion 626
Apthous ulcer 167
Areola 333
Argon laser 938
Arnold-chiary malformation 158
Aromatase inhibitor 856
Aortic dissection 307
Arterial aneurism 304
Arterial hemangioma 128-129, 963
Arterial hemorrhage 33
Arterial occlusion 285
Arterial ulcer 62-63
Arterio-venous fistula 309
Artificial blood 39
Ascending urethrography 791
Asepsis wound score 4
Asiatic cholangiohepatitis 522
Astrocytoma 161
Asymptomatic gall stone 505
Athelia 331
Atherosclerotic obstruction 286
Atrophic gastritis 412
Auchincloss mastectomy 361
Auerbach's plexus 592
Autograft 972
Automated lamellar keratotomy 942
Autosplenectomy 569
Avulsion 3
Axial hiatus hernia 386
Axillary tail of spence 332

B

Back wash ileitis 604
Bacteremia 58
Bag of worm 899
Balthazar grading 538
Balanitis 884
Balanitis xerotica obliterans 885
Balanoposthitis 884
Balkan's nephropathy 829
Balloon tamponade 486
Band causing intestinal obstruction 654
Band of ladd 654
Bariatric surgery 455
Barber's Pilonidal sinus-113
Barium enema 993-994
Barium meal 993
Barium meal follow through 993
Barium swallow 993
Barrett's esophagus 385
Barrett's ulcer 385
Barron's banding 705
Basal cell carcinoma 133
Basal skull fracture 147
Basaloid carcinoma 714
Basement membrane 353
Battle's sign 147, 724
BCT 360-361
Bed sore 64
Bell-clapper testis 896
Belsey's mark IV operation 385
Benign esophageal stricture 374
Benign juvenile melanoma 131
Benign prostatic hyperplasia 849
Berry's sign 257
Bexarotane 929
Bezin's ulcer 65
Bilateral renal agenesis 795
Bile duct stricture 520
Bilharzial cystitis 837
Biliary ascariasis 522
Biliary enteric fistulae 573

Biliary peritonitis 578
Billroth I gastrectomy 425-426
Billroth II gastrectomy 425-426
Bilocular hydrocele 899-900
Biopsy 341
Birt-Hogg-Dube syndrome 825
BIRADS 342
Bismuth classification 521
Bishop koop operation 656
Bismuth classification 521
Bladder out flow obstruction 845
Black pigment stone 505
Bladder cancer 839
Bladder stone 837
Bleeding per rectum 690
Bleomycin 926
Blood Product 38
Blood transfusion 35
Blue nevus 130
Blummer shelf 444
Blunt abdominal trauma 731
Blunt gastric injury 734
Blunt liver injury 736
BMFT 993
Boas's sign 506
Bochdalek hernia 400, 964
BOO 865
Boerhaave's syndrome 373
Boil 53
Bolus obstruction 638
Bortezomib 928
Borchardt's triad 453
Bormann's classification 442
Boundaries of inguinal canal 768
Bouveret's syndrome 514
Bowen's disease 132, 714
Boyd's grading 289
Brain dead donor 978
Brachytherapy 753
Brain injury 147, 725
Branchial cyst 209
Branchial fistula 210
Breast conservative therapy 360
Breast lump 335
Breast mass 335
Bread and butter adhesion 652
Breast conservative therapy (BCT) 360
Breast mouse 347
Breast reconstruction 367-368
Breslow modification 140
Bridge flap 97
Bronchoalveolar Carcinoma 281
Brodie trendelenburg test 319
Brown pigment stone 503
Bruise 1
Bubonocele 769
Budd-Chiary syndrome 491
Buerger's angle 290
Buerger's disease 293-296
Buerger' s postural test 290
Bulb of penis 881
Bulbourethral gland 870
Burn 78
Burn Severity 80
Burrhole 152
Burst abdomen 747-748
Buschke-Lowenstein tumour 885
Busulphan 925

C

Calcineurin inhibitors 977
Callosity 125
Callus ulcer 61
Calot's triangle 496
Campher's fascia 468; Fig: 33. l
Canal of nuck 760
Cancer chemotherapy 923
Cancer in cuirasse 339

Cancrum oris 167
Capillary hemangioma 127, 962
Capillary hemorrhage 33
Capsule of prostate 849
Cardiac decased donor 978
Carbon di oxide laser 938
Carboplatine 928
Carbuncle 54
Carbuncle of hand 110
Carcinoma of stomach 439
Carcinoid of appendix 675
Carcinoid syndrome 621
Carcinoid tumour 620
Carcinoma-ex pleomorphic 198-199
Carcinoma of anal canal 713-715
Carcinoma of breast 351-367
Carcinoma of cheek 170
Carcinoma of esophagus 389-391
Carcinoma of gall bladder 522-524
Carcinoma of lip 171
Carcinoma of male breast 367
Carcinoma of Pancreas 549
Carcinoma of Prostate 859
Carcinoma of rectum 684
Carcinoma of scrotum 893
Carcinoma of tongue 175
Carcinoma of urinary bladder 839
Carcinoma penis 885
Carcinoma peritonei 584
Carcinoma of Thyroid 208-210
Carcinomatous epulis 185
Cardiogenic shock 18
Caroli's disease 502-503
Carotid body tumour 212
Carotid triangle 205, 206
Carr's theory 807
Casoni's test 475
Caterpillar turn 495
Caudate lobe of liver 457-458
Cavernous hemangioma 128, 963
CEAP Classification 313
Cecal volvulus 644
Cellular edema 155
Cellulitis 54-55
Cement kidney 821
Central expanding jaw tumours 186
Cephalic tetanus 101
Cerebral ischemia 155
Cervical lymph node dissection 220
Cervical lymphadenopathy 215
Cervical rib 214
Chain of lakes 542
Charcot's foot 116
Charcot's triad 516
Chemical burn 90-91
Chemodectoma 212
Chemoradiation 577
Chest trauma 282
Chest tube drainage 276
Chilaiditi syndrome 582
Chilblains 301
Chimney sweeper cancer 893
Chronic rejection 974
Chronic tuberculous epididymo orchitis 905
Chronic pelvic pain syndrome 866
Cholesterol gall stone 504
Cholelithiasis 503
Choledochocele 502
Chondroma 192
Choroid plexus papilloma 162
Cholangiocarcinoma 525
Cholangitis 516
Cholecystectomy 510-511
Cholecystojejunostomy 552
Choledochal cyst 501, 956
Choledochojejunostomy 552
Choledocholithiasis 514
Cholesterol polyp 417

Cholesterol stone 504
Cholesterosis 513
Chronic rectension of urine 853
Chronic subareolar mastitis 345
Chronic anal fissure 698
Chronic appendicitis 673
Chronic breast abscess 345
Chronic cholecystitis 509
Chronic crohn's disease 610
Chronic epididymoorchitis 905
Chronic functional constipation 595
Chronic gastritis 412
Chronic ITP 565
Chronic mesenteric ischemia 660
Chronic pancreatitis 541
Chronic paronychia 110
Chronic prostatitis 866
Chronic pyelonephritis 817
Chronic tubercular peritonitis 578
Chronic ulcer
Chronic wound 5
Chylocele 903
Chylolymphatic cyst 585
Chylous ascites 582
Cibal syndrome 430
Cibal syndrome 430
Circle of death 768
Circoid aneurysm 310
Circumcision 833
Circle of death 774
Cis-Platin 928
Clean Contaminated wound 4
Clark's level 139-140
Classification of hernia 762
Classification of Ulcer 61
Claudication 288
Claw sign 650
Clean wound 4
Cleft lip 180-181
Cleft palate 181-182
Clonorchiasis 522
Cloquet's hernia 781
Close wound 1
Closed hemorrhoidectomy 705
Closed loop obstruction 642
Closed pneumothorax 271
CO2 laser 938
Cockett and Dodd operation 321
Cock's peculiar tumour 124
Coffee bean appearance 642
Cold abscess 54, 217, 218
Cold thyroid nodule 228-229
Collar-stud abscess 217
Colloid carcinoma of breast 355
Colloid solution 30
Coll's - Nissen's operation 388
Colonic atresia 952
Colon cut off sign 537
Colonic adenoma 624
Colonic diverticula 602
Colonic diverticulitis 602
Colonic injury 35, 742
Colostomy 633,634
Colour coding in triage 720
Colovesical fistula 627
Combined hemorrhoids 701
Comedo carcinoma 354
Cammando operation 178
Common bile duct stone 514
Complete hernia 769
Complete rectal prolapse 681
Complex wound 3
Complication of blood transfusion 36
Complication of burn 89
Composite graft 94
Compound nevus 130
Compound palmar ganglion 113
Compound volvulus 647

Concomitant chemoradiotherapy 924
Concomitant chemosurgery 924
Concealed hemorrhage 34
Concomitant chemoradiotherapy 924
Concomitant chemosurgery 924
Concussion 148
Condyloma acuminata 885
Congenital diverticula 597
Congenital duodenal atresia 654
Congenital Duodenal stenosis 654
Congenital hernia 957
Congenital hydrocele 900
Congenital megacolon 593
Congenital phimosis 882
Congenital torticolis 213
Conjoint tendon 767
Conn's syndrome 264
Constriction of esophagus 370
Contaminated wound 4
Content of hernia 761
Continuous laser 937
Contrast urography 790
Contre coup injury 148
Contusion, wound 1
Contusion; cerebral 148
Cooley's trait 564
Cooley's anemia 564
Corkscrew esophagus 380
Corn 125
Corona mortis 774
Coronal hypospadias 874
Corpus cavernosum 881
Corpus spongiosum 881
Coup injury 148
Courvoisier's law 518
Covering of hernia 760-761
Cowper's gland 870
Craniotomy 152
Cremastric fascia 890
Cremastric reflex 890
Cretinism 239
Crile's method 255
Crohn's disease 607
Crossed dystopia 796
Crush injury 3
Cryopathic ulcer 66
Cryoprecipitate 39
Cryosurgery 705
Crypt abscess 604
Crypt atrophy 604
Cryptorchidism 906
CT Scan 997-999
  Contrast enhanced 998
  Helical CT 998
  Sprial CT 998
Cullen's sign 540
Cushing's syndrome 263
Cushing's reflex 151
Cyclosporine 978
Cyclical mastalgia 342
Cyclophosphamide 925
Cylindroma 145
Cystic duct 495
Cystic fibrosis 530
Cystic hygroma 210
Cystine stone 809, 838
Cystitis 836
Cystitis cystica 837
Cystitis glandularis 837
Cystogastrostomy 546
Cystojejunostomy 546
Cystosarcoma phyllodes 349
Cystoscopy 793
Cytosine arabinoside 927
Cytotoxic edema 155

D

Dacron graft 307

Dartos 889
Daunorubicin 926
Day surgery unit 916
Day or same day surgery 915
Day care anesthesia 918
Day surgery 916
De Bakey classification 309
Decarbazine 925
Decerebrate rigidity 149
Decortication 278
Deep extravasation of urine 877
Deep inguinal ring 766
Deep palmar abscess 112
Deep vein thrombosis 322
Degloving injury 2
Delayed Closer 7
Delhi boil 66
Delorme's operation 681
Denileukin diftitox 928
Dental cyst 186
Dentigerous cyst 188
Depth of burn 78
De-Quervains's thyroiditis 243
Dercum's disease 124
Dermoid cyst (Epidermal cyst) 121-122
Desmoid tumour 750
Detrusor 831
Dextran 31
Dextrose 5% 24
Diabetic foot 115
Diabetic ulcer 65
Diagnostic laparoscopy 71
Diagnostic peritoneal lavage 727
Diaphragmatic hernia 399, 964
Dielt's crisis 805
Dieulafoy's disease 454
Diffused axonal injury 149
Diffused esophageal spasm 380
Diffused toxic goiter 240
Digital substraction angiography 792
Digital substraction arteriography 792
Direct inguinal hernia 770
Dirty wound 4
Distal pancreticojejunostomy 544
Divarication of recti 750
Diverticular disease 597
DMSA 792
Donor 978
  Cadever donor 978
  Living donor 978
Dormia basket 815
Dorsal fissurectomy 700
Dorsal slit 884
Dorsal spaces 106
Double barrel colostomy 634
Double bubble sign 944
Doxorubicin 926
DPL 732
Dry gangrene 301
DTPA 792
Duct ectasia 335
Duct of Rivinus 195
Duct of santorini 529
Duct of stensen 194
Duct of wirsung 529
Duct papilloma 335, 348
Ductal carcinoma in-situ 354
Ductal carcinoma 355, 354
Duhamel operation 595
Dukes staging 685
Dumping syndrome 430
Duodenal adenocarcinoma 452
Duodenal atresia 410, 944
Duodenal diverticula 597
Duodenal hematoma 734
Duodenal injury 734
Duodenal obstruction 452
Duodenal point 421

Duodenal tumour 452
Duodenal ulcer 421
Duodeno-duodenostomy 945
Duodeno-jejunostomy 945
Duplication of renal pelvis 799
Duplication of ureter 799
DVT 322
DNS .45% 26-27
Dye laser 937
Dynamic intestinal obstruction 637
Dyspepsia 412
Dyspeptic oral ulcer 167
Dysphagia lusoria 379
Dystrophic calcification 287
Dysuria 838

E

Early dumping syndrome 430
Early gastric cancer 442
Ectopia vesicae 833
Ectopic kidney 736
Ectopic pancreas 530
Ectopic spleen 559
Ectopic testis 893
Edematous pancreatitis 533
Efferent loop syndrome 431
Elastic band ligation 705
Electric burn 88
Elephant man disease 129-130
Elephantiasis chirurgens 366
Embolectomy 299
Emphysematous cholecystitis 512
Emphysematous Pyelonephritis 817
Empyema necessitans 270
Empyema of gall bladder 508, 511
Empyema thorax 272
Encysted hydrocele of cord 900
End colostomy 634
Endocrine tumour of pancreas 553
Enteral nutrition 44
Enterocele 761
Enterocutaneous fistula 631
Enterogenous cyst 585
EOS 902
Eosinophil gastritis 414
Ependymoma 162
Epiphrenic diverticulum 396
Epidermoid carcinoma 135
Epidermoid cyst 123
Epididymal cyst 903
Epididymis 891
Epididymo-orchitis 905
Epidural hematoma 150
Epigastric hernia 783
Epiphrenic diverticula 396
Epiploic foramen 572
Epispadias 874
Epulis 184
ERCP 462
Erosive gastritis 411
Erysipelas 55
Erythema pernio 301
Erytheroplakia 174
Erythromelalgia 301
Erythroplasia of Queyrat 132, 885
Esophageal atresia 371
Esophageal diverticula 394
Esophageal perforation 373
Esophageal sphincter 371
Esophageal varices 485-486
Esophageal web 378
ESWL 812-813
Etoposide 926
European hernia society classification of hernia 764
Eusol 66
Evan's staging 970
Eventration of diaphragm 401

Eversion of sac 902
Eve's disease 189
Examination of thyroid 255
Excimer LASER 937
Excision of sae 903
Excisional biopsy 341
Excretory urography 790
Exophthalmos 241
Exomphalos 782, 955
Exomphalos major 782
Exomphalos minor 782
Exstrophy of bladder 833
Extended day surgery 919
Extended radical mastectomy 361
Extended simple mastectomy 381
Extended day surgery 919
Extended neck dissection 222
Extended pyelolithotomy 811
External anal sphincter 695
External beam radiotherapy 931
External hemorrhage 34
External hemorrhoids 700
External inguinal ring 767
External spermatic fascia 890
Extra gonadal germ cell tumour 911
Extra sphincteric fistula 707
Extracellular matrix 9
Extradural hematoma 150
Extrahepatic biliary atresia 495, 501
Extraperitoneal rupture of bladder 834
Extravasation of urine 875-876

F

Factors affecting wound healing 9
Falciform ligament 457
False capsule of prostate 849
False diverticula 597
Familial adenomatous polyposis 624
Familial polyposis coli 624
FAP syndrome 624
FAST 732, 997
Fatty hernia of linea alba 783
FBOC 39
Fecal elastase 544
Fecal fistula 631
Fecolith 665
Feeding tubes 44
Feline esophagus 380
Felon 110
Felty's syndrome 565
Femoral canal 778
Femoral hernia 778
Fetal surgery 971
Fetoscopic surgery 971
Fibrinous adhesion 653
Fibro lamellar carcinoma 480
Fibroadenoma 347
Fibroadenosis 343
Fibrocystic disease 343
Fibrolipoma 125
Fibrous adhesion 653
Fibrous dysplasia 192
Fibrous epulis 184
Filarial lymphedema 328
Filarial scrotum 892
Finney's pyloroplasty 426
Fistula 68
Fistula in ano 706
Fistulectomy 708
Fistulotomy 709
Flaps 96
Fleischner sign 615
Flial chest 282
Floating gall bladder 500
Floating prostate 877
Fludarabine phosphate 927
Fluid therapy 23

Fluosol DA 39
FNH 477
FNAC 232, 341
Focal nodular hyperplasia 477
Focussed
abdominal sonography for trauma (FAST) 732, 997
Folate antagonist 926
Foley's catheter 880
Follicular adenoma of thyroid 244
Follicular Carcinoma of thyroid 248
Forrest classification 435
Foramen cecum 225
Foramen of winslow 571
Foreign body in bladder 837
Fournier's gangrene 891
Frenulum 881
Fresh frozen plasma 39
Freyer's prostatectomy 858
Frey's syndrome 203
Frost bite 301
Frykman goldberg procedure 681
Full thickness burn 78
Full thickness skin graft 93
Fulminant colitis 604
Fundoplication 383-384
Funicular hernia 769
Funicular hydrocele 900

G

Galactocele 347
Galactorrhea 348
Gall stone disease 503
Gall bladder perforation 506
Gall stone ileus 513
Ganglioglioma 163
Ganglion 113
Gangrene 301
Gangrenous cholecystitis 506
Gardner's syndrome 624
Gas gangrene 104
Gas laser 937
Gastoesophageal reflux disease 380
Gastointestinal stromal tumour 415
Gastric carcinoid 451
Gastric diverticula 454
Gastric injury 734
Gastric lymphoma 451
Gastric outlet obstruction 419, 437
Gastric stromal tumour 450
Gastric ulcer 419
Gastrinoma 554
Gastrinoma triangle 554
Gastritis 411-415
Gastro-jejuno-colic fistula 429
Gastrojejunostomy 427, 449
Gastroschisis 956
Gastroscopy 406-407
Gastrosplenic ligament 558
GCS 156
GCS - P score 156
Geftinib 929
Gelatin Polymer 31
Gemcitabine 928
Gemtuzumab ozoyamicin 928
Genunine stress inconinenss (GSI) 845
Generalized neurofibromatosis 129
Generalized tetanus 101
Gerstmann syndrome 160
Giant cell reparative granuloma 191
Giant cell (myeloid) epulis 185
Giant cell tumour 191
Giant condyloma accuminata 714, 885
Giant fibroadenoma 348
Giant pigmented hairy nevus 131
Gillie's flap 97
GIST 450
Glasgow criteria 538
Glandular hypospadias 874

Glans of penis 880
Glasgow coma scale 720
GOO 419, 437
Gleason's classification 863
Glomangioma 144
Glomus tumour 144
Glial tumour 161
Glucagonoma 556
Gluteal hernia 785
Goiter 232
Golf hole ureter 821
Golf-hole ureteric orifice 821, 837
Gonococcal urethritis 879
Goodsall's rule 708
GORD 380
Grave's disease 240
Grade of internal hemorrhoids 701
Grading of prostatic enlargement 853
Grading of severity of tetanus 101
Graham-cole's test 497
Graham's patch repair 433
Granulation tissue 59
Granulomatous epulis 185
Grawitz tumour 825
Greater omenta 572-573
Greater sac 571
Grey turner sign 540
Gritti strokes acuputation 304
Grid iron incision 671, 752
Guillotine amputation 304
Gun Shot injury 4
Gynecomastia 368

H

Haagensen's criteria 362
Hadfield operation 337
Hairy leukoplakia 174
Hairy mole 130
Halsted mastectomy 361
Hamartoma 961
Hare lip 181
Hartmann's operation 689
Hartmann's pouch 495
Hartmann's solution 27
Hashimoto's thyroiditis 242
Hashitoxicosis 243
Hasson's cannula 70
HBOC 39
Heart transplantation 987
Healing Ulcer 61
Heinke-Mikulicz pyloroplasty 426
Heller's myotomy 377, 378
Hemangioblastoma 163
Hemangioma 126, 961
Hemangioma of liver 478
Hematemesis 433
Hematocele 903
Hematochezia 433
Hematoma 1
Hematuria 839, 842
Hemobilia 466
Hemoptysis 433
Hemorrhoid 700-703
Hemorrhoidal cushions 700
Hemorrhoidectomy 705-706
Hemothorax 272
Hepatic encephalopathy 483
Hepatic lobule 458
Hepatocellular carcinoma 478
Hepatorenal pouch 580
Hereditary elliptocytosis 564
Hereditary non-polyposis colon cancer 624
Hereditary spherocytosis 563
Hernia 758
Hernia truss 771, 772
Hernia-en-glissade 777
Hernia-en-W 778
Hernioplasty 773

Herniorrhaphy 773
Herniotomy 773, 903
Herpes ulcer 167
Hessel bach's triangle 770
Heterotopic transplantation 973
Hetastarch 32
Hiatus hernia 385
Hidradenitis suppurativa 56
High anal fistula 706
High anterior resection 686-687
High fistula in ano 706, 707
High inguinal orchidectomy 910
High output fistula 631
Highly selective vagotomy 429
Hill's repair 385
Hill-feurguson operation 705
Hippocratic facies 576
Hirschsprung's disease 593
Hollandar's insulin test 423
Homan's Opration 329-330
Homan's sign 324
Home parenteral nutrition 50
Honeymoon cystitis 836
Honeymoon pyelitis 816
Hooded prepuce 873
Horner's syndrome 252, 257
Horse shoe fistula 707-708
Horseshoe kidney 796
Hospital hotels 919
Hot thyroid nodule 228-229
Hour glass stomach 439
Hunner's interstitial cystitis 837
Hydatid cyst of liver 475, 522
Hydatid fluid 475
Hydatid sand 475
Hydrocele 899
Hydrocele en bissac 900
Hydrocele of neck 210
Hydrocelectomy 902
Hydrohepatosis 518
Hydronephrosis 804
Hydrops of gall bladder 511
Hydrostatic reduction 652
Hydroxyurea 927
Hyperacute rejection 973
Hyper trophic scar 8-9
Hyperkeratosis 173
Hypernephroma 825
Hyperparathyroidism 259
Hyperplastic polyp 622
Hyperplastic tuberculosis 614
Hypersplenism 566
Hypertensive ulcer 65
Hyperthyroidism 238
Hypertrophic Pyloric Stenosis of adult 454
Hypertrophic pyloric stenosis of infancy 408, 952
Hypertropic gastritis 414
Hypertrophic Scar 13
Hypo volemic shock 17
Hypoadrenal shock 19
Hypoparathyroidism 262
Hypospadias 873
Hypothyroidism 236

I

Ibritumonab tiuxetan 928
Idiopathic detrusor overactivity 845
Idiopathic megacolon 595
Idiopathic pelviureteric junction obstruction 804
Idiopathic scrotal edema 968
Idiopathic scrotal gangrene 891
Idiopathic thrombocytopenic purpura 565
Ifosfamide 925
Ileal-pouch anal anastomosis 607
Ileo-anal anastomosis 607
Ileocecal angle 615
Ileo-sigmoid knotting 647
Ileostomy 632

Ileostomy dysfunction 632
Imitinib mesylate 929
Immuno suppression 974
Immersion foot 301
Immunotherapy 930
Imperforated anus 984
Imperfect descent of testis 893
Incarcerated hernia 763
Incised wound 2
Incisional biopsy 341
Incisional hernia 748
Incomplete descent of testis 893
Indirect inguinal hernia 769
Induction chemotherapy 923
Infantite hyper trophic pyloric stenosis 952, 408
Infantile hydrocele 900
Infantile polycystic kidney disease 798
Infected hydronephrosis 819
Infantile hypothyroidism 239
Infiltrative ductal carcinoma 355
Infiltrative lobular carcinoma 356
Inflamed hernia 763
Inflammatory carcinoma 367
Ingrowing toe nail 115
Inguinal hernia 766-767
Injection sclerotherapy 705
Injury to kidney 740, 800
Injury to pancreas 531-532
Injury to rectum 741
Immunosuppression 974
Implantation dermoid 122
Insulinoma 553
Internal inguinal Ring 766
Inter costal drainage 276
Inter digital pilonidal sinus 696
Internal anal sphincter 693
Internal drainage of pancreatic- pseudocyst 546
Internal hemorrhage 34
Internal hemorrhoids 701
Internal inguinal ring 766
Internal radiotherapy 931
Intersphincteric fistula 707
Interstitial cell tumour 908
Interstitial emphysema 284
Interstitial hernia 778
Intestinal bands 654
Intestinal hamartoma 622
Intestinal obstruction 637, 654
Intra hepatic cholangiocarcinoma 481
Intracranial hematoma 150
Intralingual thyroid 234
Intraperitoneal abscess 579
Intraperitoneal organ 572
Intraperitoneal rupture of bladder 834
Intrapleural fibrinolytic agents 277
Intrathoracic thyroid 234
Intravenous pyelography 790
Intravenous urography 790
Intussusception 648
Intussusceptum 648-650
Intussuscipiens 648-650
Invasive bladder cancr 840
Invagination test 780
Invertogram 949
Irreducible hernia 762
Irritative symptoms 852
Ischemia colitis 617
Ischeorectal abscess 711
Isograft 972
Isolyte E 29
Isolyte G 28
Isolyte H 29
Isolyte P 29
Isotope Scanning 1000
Isotope Scintigraphy 1000
ITP 565
Ivor- Lewis operation 393

J

Jaboulay's operation 902
Jackson's staging 888
Japanese classification of Ca stomach 442
Jaw swellings 184
Jaw tumours 186
Jeep bottom 696
Jejunal atresia 945
Jejunal diverticula 597
Jejunal tubes 44-45
Jejuno-ileal obstruction 654
Junctional nevus 130
Juvenile retention polyp 623

K

Kalan's modification for appendicitis 671
Kanavels sign 112
Kaposi's sarcoma 143
KASAI operation 501
Kehr's sign 561
Keloid 14
Keratoacanthoma 132
Kernohan's phenomenon 151
Kidney transplantation 979
Kidney infection 816
Killian's dehiscence 395
Klatskin tumour 527
Klippel trenaunay syndrome 318
Kocher's incisions 752
Kocher's test 257
Kock's pouch 607
Kondoleon operation 330
Krukenberg tumour 444
Kwashiorkor 42

L

Laceration 2
LAHSAL System 183
Lahaut's operation 683
Lahey's method 256
Lanz incision 671, 752
Laparoscopic appendectomy 671- 672
Laparoscope 70-71
Laparoscopic appendicectomy 671-672
Laparoscopic hernia repair 773
Laser energy 937
Laser light 936
LASER surgery 938
LASIK LASER 941
L-Asperginase 928
Late dumping syndrome 430
Late dumping syndrome 430
Lateral aberrant thyroid 247
Lateral anal sphincterectomy 699
Lateral Pancreaticojejunostomy 599
Lateral swelling of neck 209
Laugier's hernia 781
Lauren's classification 441
Lead pipe deformity 608
Left sided appendicitis 602
Leriche's syndrome 288
Lesser omenta 571-572
Lesser sac 571-572
Leukoplakia 132, 173
Lie Fraumeni syndrome 920
Lienorenal ligament 598
Ligament; definition 598-599
Ligament of berry 225
Ligament of cooper 333
Limey bile 513
Lingual thyroid 234
Linitis plastica 443
Lipoma 124
Liposarcoma 143
Litholapaxy 839
Lithotripsy 812
Littre's gland 886

Littre's hernia 761, 778
Liver transplantation 984
Liver abscess 467
Liver Biopsy 464
Liver cell adenoma 477
Liver secondaries 481
Liver trauma 464, 742
Lobular carcinoma in-situ 354
Lobular carcinoma 354, 356
Local flaps 96
Local gigantism 129-130
Local tetanus 101
Lockwood operation 781
Loop ileostomy 633
Lord's procedure 902
Lotheissen's operation 781
Lower GI bleed 619
Low anal fistula 706
Low anterior resection 687
Low fistula in ano 706, 708
Low operation 781
Low output fistula 631
Lund and Browder chart 81
Lumbar hernia 785
Lumbar sympathectomy 295
Lumpectomy 361
Lung Tumour 280
Lundh's test 543
Lung abscess 278
LUTS 852
Lymphoma 163
Lymph node of gerota 678
Lymph node of lund 496
Lymphangioma 210, 963
Lymphangiosarcoma 366
Lymphedema congenita 327
Lymphedema 327-328
Lymphedema praecox 327
Lymphedema tarda 327
Lymphocytic gastritis 414
Lymphoma of testis 908
Lymphovenous shunt 330
Lynch syndrome 625, 627

M

Macroglossia 172
Madura foot 117
Major hemothorax 272
Male infertility 912
Male urethral carcinoma 880
Malignant tumours of bile duct 525
Malignant ameloblastoma 190
Malignant lymphoma of thyroid 251
Malignant melanoma 137
Malignant tumour of breast 350
Malignant tumour of skin 113
Malignant tumour of Thyroid 244
Malignant tumours of parotid gland 201
Malignant ulcer 66
Mallory-Weiss syndrome 379
Mammary duct ectasia 346
Mammary fistula 346
Mammography 339
Manchester classification 359
MANTRELS score 669, 670
Marasmus 42
Marion's disease 865
Marjolin's ulcer 137
Markel cell carcinoma 142
Martorell's ulcer 65
Massive blood transfusion 37
Massive hemothorax 272
Mastectomy 361
Mastalgia 338, 342
Mastitis carcinomatosa 367
Maydl's hernia 761, 778
Mayo's repair 783
Mc Keown approach 393

McBurney's point 666-667
McEvedy operation 781
Meatal dilatation 872
Meatal stenosis 871
Meatoplasty 872
Meatotomy 872
Mechanical intestinal obstruction 637
Mechlorethamine 925
Meckel's diverticula 598
Meconium 655
Meconium ileus 655, 947
Meconium peritonitis 577
Meconium plug syndrome 656, 948
Medulloblastomna 163
Mediastinum testis 891
Medical jaundice 518
Medullary Carcinoma of breast 355
Medullary Carcinoma of thyroid 250
Medullary cystic disease 798
Medullary sponge kidney 798
Megacolon 593
Meige's disease 327
Meissner's plexus 592-593
MELD syndrome 987
Melena 433
Meleney's gangrene 57
Melphalam 925
Membranous urethra 870
Meningioma 163
MEN syndrome 266
Menetrier's disease 414
Meningocele 158
Meningomyelocele 158
MESS 721
Mesenteric cysts 585
Mesenteric lymphadenitis 955
Mesenteric tear 584
Mesenteric venous thrombosis 658, 661
Mesh 773
Mesh rectopexy 683
Metabolic inhibitor 977
Methotrexate – MTX 926
Metastasic tumour of liver 481
Meteorism 802-803
Miami Criteria 261
Microdochectomy 337, 349
Micturating cystourethrography 791
Middle volar pulp space infection 111
Mid-esophageal diverticula 397
Midline incision 751
Midline swelling of neck 208
Mile's operation 687
Milk fistula 346
Milk ridge 332
Milligan Morgan operation 705
Millin's prostatectomy 858
Milroy's disease 327
Minimal papillary carcinoma 246
Minor burn 81
Mirizzi syndrome 514
Mitomycin C 926
Mitotane 930
Mitoxantrone 926
Mitramycin 926
Mixed hiatus 388
Mixed parotid tumour 198
Modified lund and Browder chart 81
Modified Hinchey's classification 603
Moderate burn 81
Modified Johnson classification 420
Modified Lucas classification 532
Modified radical mastectomy 361
Modified radical neck dissection 221
Modified Whipple's operation 551
MODS 22
Modified shock index 20
Moles 130
Moh's micrographic surgery 134

Monoclonal antabodies 978
Mondor's disease 346
Mongolian spot 130
Monoclonal antibodies 930
Morgagian hernia 400
Morrison's pouch 581
Morrissey cough impulse 319
Mortorell's operation 330
Moses sign 324
Moynihan's hump 495
Magnetic resonance angiography 1000
MRA 1000
MRI 999
MRV 1000
Magnetic resonance venography 1000
Mucinous carcinoma of breast 355
Mucocele of appendix 673
Mucocele of gall bladder 511
Muco epidermoid Carcinoma 202
Mucoepidermoid carcinoma 714
Mucous retention cyst 168
Mucoviscidosis 530
Multiple lipoma 125
Mumps orchitis 906
Mumps Parotitis 196
Murphy sign 666
Muscle flap 98
Muscular triangle 205
Mycosis fungoides 144
Myo phenolate mofetil 977
Myopectineal orifice 774
Myeloid (giant) cell epulis 185
Myenteric plexus 592

N

Nab-paclitaxel 928
Nanoparticles 930
Napkin ring lesion 626
Narath's hernia 781
Navicular fossa 870
NBT-PABA test 543
Nd:YAG laser 938
Necrotizing pancreatitis 533
Necrotizing fascitis 57
Nagative Pressure wound therapy 10
Neoadjuvant chemotherapy 923
Neobladder 882
Neonatal intestinal obstruction 654
Neonatal tetanus 101
Neoplasm of breast 347
Neoplasm of esophagus 389
Neoplasm of liver 477
Neoplasm of exocrine pancreas 548
Nephroblastoma 882
Nephrolithotomy 812
Nephroscope 813
Nesbitt's operation 884
Neuroblastoma 969
Neurogenic ulcer 63
Neurolipoma 125
Neural tube defect 157
Neuroblastoma 266
Neurofibroma 129
Neurofibromatosis 129
Neurogenic shock 19
Neurolipoma 125
Nevin staging 524
Nevin's staging 523
NICE guideline for CT-151
Nicolandi Branham's sign 310
Nigro's protocal 715
Nipple discharge 335
Nissen's fundoplication 383-384
Nitrosourea 925
Noble plication operation 653
Nocturnal enuresis 846
Nonbacterial prostatitis 866
Non chromophin paraganglioma 212

Non gonococcal urethritis 879
Nonhealing ulcer 61
Non Hemolytic reaction 36
Non specification ulcer 66
Noncyclical mastalgia 343
Nonspecific cystitis 837
Nonspecific mesenteric lymph adenitis 587
Normal saline 25
NPWT 10
NSMLA 586
Nutritional assessment 42
Nutritional indices 43
Nutritional support in special situation 50
Nyhus classification 765

O

Oblique inguinal hernia 769
Obstructed hernia 763, 776
Obstruction by adhesion 652
Obstructive jaundice 417
Obstructive shock 19
Obturator hernia 785
Obturator test 667
Occult papillary carcinoma 246
Octreotid 930
Odontogenic cyst 186
Ogilvie's hernia 778
Ogilvie's syndrome 657
Oligodendroglioma 162
Omega sing 642
Omental patch 433
Omentocele 761
Omphalitis 752
Omphalocele 781-783
Oncofetal gene 922
Oncogenes 920
Open fetal surgery 971
Open hemorrhoidectomy 705
Open pneumothorax 271
Open wound 2
OPSI 569
Opsonin 589
Opsonization 559
Oral candidiasis 166
Oral cholecystography 497
Oral submucous fibrosis 174
Oral ulceration 167
Orchidopexy 895
Orf 113
Organ transplantation 972
Orphan Annie–nucclie 246
Oriental cholangiohepatitis 522
Oriental sore 66
Ormand's disease 587
Orthotopic transplantation 972
Oshner-sherren's regimen 673
Osteoma 165 osteomyelitis of jaw 185
Outpatient surgery 915
Overnight stay surgery 915
Over active bladder 845
Overwhelming post splenectomy syndrome 569
Oxalate stone 808, 838
Oxaliplatin 928

P

Packed red cell 35
Packed red blood cells 35
Paclitaxel 927
Paget's disease of nipple 366
Paget's disease of penis 885
PAIR 476
Palmar space 106
Pancreatic injury 739
Pancreatic pseudocyst 545
Pancreas divisum 529
Pancreatic abscess 540
Pancreatic ascites 541
Pancreatic cholera 556

Pancreatic fistula 533
Pancreatic hypoplasia 530
Pancreatic lymphoma 553
Pancreatic necrosis 540
Pancreatic pleural fistula 544
Pancreaticoduodenectomy 551
Pancreatogenic diabetes 543
Pancreatic pseudocyst 545
Pantaloon hernia 778
Papillary adenoma of thyroid 244
Papillary carcinoma of breast 356
Papillary Carcinoma of Thyroid 245
Papillary dermis 121
Papillary transitional cell tumour 829
Parabronchial diverticulum 397
Parabronchial diverticula 397
Paracentesis 465
Para-esophageal hernia 387
Paralytic ileus 656
Paramedian incisions 751
Paraphimosis 883
Parasternal hernia 399
Parathormone 258
Parathyroid Carcinoma 262
Para-umbilical hernia of adult 783
Parenteral nutritional therapy 46
Parkland formula 83
Park's classification of fistula in ano 707
Parona's space infection 113
Parotid gland 194
Partial rectal prolapse 678-679
Partial thickness burn 78
Parts of hernia 761
Passaro's triangle 554-555
Pattarson – Kelly syhdrome 377
Patent urachus 756
Patey's mastectomy 361
Patterson- Brown- Kelly syndrome 377
Paul-mikulicz operation 647
PCNL 813
Peau d' orange 2338, 339, 366
Pectinate line 692
Pectus carinatus 269
Pectus excavatum 269
Pedicle flaps 97-98
Pelvi rectal abscess 712-713
Pelvic abscess 579
Pelvic hydronephrosis 805
Pender's syndrome 239
Penetrating abdominal trauma 741
Penetrating duodenal injury 741
Penetrating small bowel injury 741
Penile hypospadias 874
Penile urethra 870
Penis 382
Penoscrotal hypospadias 874
Pentastarch 32
Peptic ulcer 415
Persistant vitello intestinal duct 754
Percutaneous nephrostomy 820
Perianal paget disease 715
Perforated peptic ulcer 431
Perforating ulcer 63
Perforating veins 314-315
Perfusion 16
Periampullary carcinoma 553
Perianal abscess 711
Perianal hematoma 701
Periapical cyst 186
Pericolic abscess 579, 603
Perineal hernia 785
Perineal hypospadias 874
Perineal prostatectomy 859
Perinephric abscess 820
Periodontal cyst 186
Peripheral arterial occlusion 287
Peripheral heart 315
Peripheral parenteral nutrition 46

Peritoneal ligament 572
Peritoneal mesothelioma 584
Peritoneum 571-573
Peritonism 546
Peritonitis 573
Permanent colostomy 634
Permanent ileostomy 633
Perthe's test 319
Peterson hernia 785
PET scan 1001
Peud d'orange 338
Peutz-jeghers syndrome 624
Peyronie's disease 884
Pfannenstiel's incision 751, 752
Pharyngeal pouch 394
Phase of wound healing 7
Pheochromocytoma 265
Phimosis 882
Phlegmesia alba dolens 325
Phlegmesia cerulea dolens 325
Phosphate calculus 808
Photo coagulation 705
Photodynamic therapy 941
Photofrin 941
Photoradiation therapy 938
Photorefractive keratotomy 942
Photosensitizer 941
Phrenicocolic ligament 558
Phrygian cap deformity 500, 501
Phylloid tumour 349
Physiological phimosis 882
Phytobezoar 453
Pigmented bill stone 505
Pigment stone 505
Pile 700
Pilomatrixoma 145
Pilonidal sinus 696
Pilosebaceous unit 121
Pistol shot perforation 643
Plantar fascitis 175
Platelet concentrates 38
Pleomorphic adenoma 198
Pleural drainage 275
Pleuro-peritoneal hernia 400
Plexiform hemangioma 128, 963
Plummer-Vinson's syndrome 377
Plunging ranula 169
Pneumoperitoneum 582
Pneumothorax 271
Pointing sign 666
Polyclonal antibodies 978
Polyclonal antibodies 978
Polycystic liver disease 473
Polymastia 331
Polypoid adenoma 623
Polythelia 331
Pons-Duret hemorrhage 150
Popcorn calcification 340
Porcelain gall bladder 523
Porta hepatis 459
Portal circulation 482-483
Portal hypertension 482
Portal vein 482
Portwine stain 127, 962
Porto-systemic shunt 487
Posterior urethera 875
Post anal dermoid 122
Post burn contracture 89
Post vagotomy syndrome 431
Posterior gastrojejunostomy 426, 449
Posterior triangle 205
Posterior urethral valve 872
Posthitis 884
Postoperative hernia 748
Potato tumour 212
Power density 937
PP-oma 557
Pratt's sign 324

Pratt's test 319
Pregnancy epulis 185
Prehn's sign 897
Preprostatic urethra 869
Prepucial gland 882
Prepucial sae 881
Pressure/Decubitus ulcer 11
Priapism 884
Primary bladder stone 837
Primary brain injury 148
Primary brain stem injury 149
Primary chemotherapy 923
Primary closure 734
Primary hemorrhage 34
Primary hemorrhoid 702
Primary hyperaldosteronism 264
Primary hyperparathyroidism 260
Primary intension closer 7
Primary megacolon 593
Primary peritonitis 574
Primary repair 734
Primary sclerosing cholangitis 605
Primary thyrotoxicosis 236, 237
Primary toxic goiter 240
Primary vaginal hydrocele 900
Primary volvulus 643
Primordial cyst 188
Pringle's maneuver 465
Procedure room surgery 915
Procarbazine 928
Processus vaginalis 760
Proctalgia fugax 713
Proctitis 678
Proctocolectomy 607
Proctocolitis 678
Prolapse of rectum 678
Prostatic abscess 866
Prostatic calculi 866
Prostatic carcinoma 859
Prostatic pouch 851
Prostatic urethra 869
Prostatic utricle 869
Prostatic venous plexus 849
Prostatism 852
Prostatectomy 856
Proto-oncogenes 921
Prune belly syndrome 956
Pruritus ani 713
Psammans body 246
PSARP 951
PSA 862
PSA density 862
PSA form 862
PSA velocity 862
Pseudo pancreatic cyst 545
Pseudolipoma 125
Pseudomyxoma peritonei 584
Pseudo-obstruction 657
Psoas test 666
PTC 463
Puestow's procedure 544
Pulsion diverticula 394
Pulled up cecum 615
Pulmonary embolism 326
Pulp space infection 110
Pulsed laser 937
Punctured wound 2
Purine antagonist 927
Push bangs 815
Putty kidney 821
Pyelolithotomy 811
Pyemia 58
Pyemic abscess 54
Pyloric stenosis 437
Pyloromyotomy 409
Pyloroplasty 426
Pyocele 903
Pyoderma gangrenosum 605

Pyogenic abscess 54
Pyogenic granuloma 56
Pyogenic liver abscess 467
Pyonephrosis 819
Pyrimidine antagonist 927

Q

Quadrate lobe 456

R

Rabson staging 826
Raccoon's eye 147
Radical keratotomy 942
Radical mastectomy 361
Radical neck dissection 220
Radical nephrectomy 824
Radical prostatectomy 865
Radicular cyst 186
Radionuclide scanning 1000
Radiotherapy 931
Ramstedt's operation 409, 953
Randall's plaque theory 807
Ranson's criteria 538
Ranula 168
Raspberry tumour 756
Ray amputation 304
Raynaud's disease 300
Raynaud's phenomenon 300
Reactionary hemorrhage 33
Rebound tenderness 666
Rectal prolapse 678
Rectouterine pouch 581
Recurrent appendicitis 673
Red blood cell substitute 39
Reducible hernia 762
Reflux nephropathy 816-817
Rejection 973
  Acute 974
  Chronic 974
  Hyper-acute 973
Renal transplantation 979
Renal abscess 817
Renal agenesis 795
Renal angle 809
Renal biopsy 792
Renal carbuncle 817
Renal cell carcinoma 825
Renal hydronephrosis 805
Renal hypoplasia 795
Renal infection 816
Renal stone 806
Renal trauma 800-803
Renal tuberculosis 820
Resection and anastomosis 736
Resection rectopexy 682
Residual volume 851
Retention of urine 868
Retropubic prostectomy 858
Retroperitoneal trauma 589
Rete testis 891
Retention of urine 835
Reticular layer of dermis 121
Retractile testis 896
Retrograde urogram 791
Retromammary abscess 345
Retroperitoneal fibrosis 587
Retroperitoneal organ 587
Retroperitoneum 587
Retro sternal goitre 233
Retropubic prostectomy 858
Retrosternal thyroid 233, 234
Revised trauma score 720
Revealed hemorrhage 34
Reversed 3 sign 551
Revised trauma score (RTS) 720
Revlimid 928
Reynold's pentad 516-517
Rhabdomyosarcoma 970

Rib tracture 282
Rib fracture 282
Richter's hernia 761, 778
Riedel's thyroiditis 242
Right hemicolectomy 616
Rim sign 805
Ring occlusion test 780
Ringer lactate 27
Ripstein's operation 681
RL 27
Robson's staging 826
Rocker bottom foot 116
Rockey Davis incision 752
Rodent ulcer 133
Rolling hernia 387
Roos test 312
Root of mesentery 586
Root of penis 881
Rovsing's operation 798
Rovsing's sign 666
Rule of "10" 294
Rule of "2" 599
Rule of nine 80-81
Rupture of bladder 834
Rupture of bulbar urethra 875
Rupture of membranous urethra 876
Rupture of spleen 560
Rutherford Morrison incision 671, 752
Ryle's tube 432, 436

S

Sac of hernia 761
Saccular aneurysm 305
Sacculation 851
Sacrococcygeal teratoma 960
Saddle bag's hernia 770
Saint's triad 601
Salvage chemotherapy 923
Salivary gland calculi 197
Salivary gland neoplasm 198
Salivary gland 193
Salvage chemotherapy 924
Saphena varix 319
Saphenous venous system 314
Salman's patch 128, 962
Saw tooth appearance 601
Scanlon's mastectomy 361
Scalene syndrome 214
Scalp 129
Scalp contusion 147
Schatzki's ring 379
Sciatic hernia 785
Scirrhous carcinoma of breast 355
Sclerosing cholangitis 519
Sebaceous cyst 123
Sebaceous cyst of scrotum 892
Sebaceous horn 123
Secondary megacolon 595
Secondary bladder 882
Secondary bladder stone 837
Secondary brain damage 150
Secondary hemorrhage 33
Secondary hemorrhoids 702
Secondary hyperparathyroidism 259
Secondary hypothyroidism 238
Secondary intension closure 7
Secondary megacolon 595
Secondary peritonitis 575
Secondary phimosis 882
Secondary pneumothorax 271
Secondary sclerosing cholangitis 519
Secondary thyrotoxicosis 236, 238
Secondary vaginal hydrocele 900
Secondary volvulus 644
Selective neck dissection 222
Selective nonoperative management 563, 738
Seminoma 907
Sengstaken Blakemore tube 488

Sentinal loop 537
Sentinal node 334
Sentinal pile 698
Septic blister 110
Septicemia 58
Sequestration dermoid 121
Serocystic disease of Brodie 349
Serosanguinous discharge 749
Serpiginous ulcer 609
Serum PSA 862
Seton 710
Sezery's syndrome 144
Sherren's triangle 667
Shifting tenderness 587
Shock 16
Shock index 20
Short stay surgery 915
Short bowel syndrome 617
Shwachman-diamond syndrome 530
Sialolithiasis 197
Sideropenic dysphagia 377
Side to side pancreatico jejunostomy 544
Sigmoid volvulus 645-646
Sigmoidopexy 647
Simple mastectomy 361
Simple cyst of kidney 799
Simple mastectomy 361
Simple ranula 168
Simplified nodal classification 219
Simson's classification of gynecomastia 368
Sinus 68
SIRS 22
Sister mary joseph node 496
Sister joseph nodule 444
Sistrunk operation 209
Sitz bath 697
Skin graft 92
Skin tag 698
Skip lesions 608
Skull fracture 147
Sliding hernia 774
Sliding hiatus hernia 386
Slip sign 124
Slough 59
Small cell Carcinoma – lung 280
Small bowel transplantation 989
Small intestinal diverticula 597
Small stomach syndrome 429
Smegma 882
Smooth mole 130
SNOM 563, 738
SOFA 58
SOFA Score 58
Soft sore 66
Solar keratosis 131
Solitary bone cyst 191
Solitary rectal ulcer 683
Solitary renal cyst 799
Solitary thyroid nodule 254
Somatostatinoma 556
Southampton wound grading system 4
Spogy urethera 870
Sporotrichosis-113
Spontaneous (Secondary) intension closure 6-7
Spermatic cord 851
Special TPN Solution 49
Speckled leukoplakia 174
Spermatocele 904
Spermocytic seminoma 907
Sphincter of Oddi 495
Sphincter vesicae 831
Spigelian hernia 785
Spina bifida aperta 159
Spina bifida occulta 158, 159
Spiral valve of Heister 494, 495
Spitz nervus 131
Splenectomy 568
Splenic abscess 570

Splenic rupture 560
Splenic vein thrombosis 544
Splenomegaly 566
Splenorrhaphy 563
Splenosis 563
Splenunculi 558
Split thickness skin graft 93
Spontaneous intension closure 7
Spontaneous pneumothorax 271
Spreading Ulcer 61
Spurious diarrhea 686
Squamous cell Carcinoma – lung 280
Squamous cell cancer 135
Squamous cell carcinoma of renal pelvis 829
Squamous cell carcinoma of urinary bladder 840
Stan ford classification 309
Stab wound 2
Stag horn calculus 808
Stage of ulcer 59
Stages of shock 17
Staging of breast cancer 358
Standard classification of fistula in ano 707
Stangury 809
Stapled hemorrhoidectomy 706
Steerhorn stomach 403
Stem cell transplant 930
Sterile pyuria 821
Sternomastoid tumour 213
Stewart treves syndrome 143
Stoma 632
Stomatitis 165
Stove in chest 282
Strowbarry angioma 127, 962
Stress incontinence 845
Strangulated hernia 763
Strasberg classification 520
Strangulated hernia 776
Strangulated intestinal obstruction 641
Strawberry angioma 127
Stratum corneum 120
Stratum granulosum 120
Stratum lucidium 120
Strawberry gall bladder 513
Stress factor 43
Stricture urethra 879
Stricturoplasty 616
String sign of kantor 610
Stripping 321
Struvite stone 838
Sub cutaneous mastectomy 3614
Sub mucous abscess 712
Sub-acute thyroiditis 243
Subarachnoid hemorrhage 153-154
Subareolar abscess 345
Sub-clavian steal syndrome 310
Subcutaneous mastectomy 361
Subdural hematoma 152
Subhyoid bursal cyst 209
Subhyoid bursitis 209
Sublingual dermoid 169
Sublingual gland 195
Submandibular salivary gland 194
Submandibular triangle 205
Submental triangle 205
Submucous fibrosis 174
Subphrenic abscess 580
Succession splash 437
Superficial bladder cancer 840
Superior mesenteric artery syndrome 618
Super radical mastectomy 361
Superficial extravasation of urine 875-876
Superficial inguinal ring 767
Superficial thrombophlebitis 321
Suppurative cholangitis 517
Supra sphincteric fistula 707
Suprapubic cystolithotomy 839
Surgical emphysema 284
Surgical Jaundice 517, 518

Swenson's operation 595
Symes amputation 304
Syme's amputation 304
Syphilitic ulcer 66, 167

T

Taenia coli 590, 596
Tamzolemide 928
TAO 290
TAPP repair 773
TaTME 688, 689
Tea pot stomach 439
Tear cancer 133
Temporary colostomy 634
Tendon sheath infection 111
Tenesmus 686
Tension pneumothorax 271
TEP repair 773
Teratoma 709
Teratomatous dermoid 123
Terminal hematuria 853
Tertiary hyperparathyroidism 260
Tertiary hypothyroidism 238
Tertiary intension closure 7
Tertiary peritonitis 577
Testicular appendages 965
Testicular descent 893-894
Testicular torsion 896, 966
Testicular trauma 969
Testis 889
Tetanolysin 99
Tetanospasmin 99
Thalassemia major 564
Thalassemia minor 564
Thalidomide 928
Thenar space infection 112
Thiersch's operation 681
Thiersch graft 93
Thimble bladder 821
Thoracic outlet syndrome 311
Thoracentesis 276
Thoracotomy 278
Three tourniquet test 319
Thromboangitis obliterans 290
Thrombolytic therapy 299
Thrombophilia 323
Thumb printing sign 618
Thyroid adenoma 244
Thyrotoxicosis 238, 241
Thyroglossal cyst 208, 235
Thyroglossal fistula 208, 236
Thyroid storm 238, 253
Thyroidectomy 251
Tietze's disease 269, 343
TIPSS 487
Toxemia 58
Tongue cancer 171
Tongue tie 172
Tertiary intention closure 5-6
Torsion of appendix testis 965
Torticollis 213
Torus 192
Tositumonab 928
Total mastectomy 361
Total parenteral nutrition 47
Toupel fundoplication 385
Toxic edema 236
Toxic megacolon 604
TPN 46
Transanal total mesorectal excision–Ta TME 688, 689
Traction diverticula 394
Tracheoesophageal fistula 371
Traction 3
Tractotomy 737
TRAM flap 367-368
Traumatic brain edema 154
Traumatic shock 17
Traumatic ulcer 62

Trans rectal ultrasonography 792
Trans sphincteric fistula 707
Transfusion reaction 36
Transitional cell carcinoma of bladder 839
Transmission of Infection 37
Transurethral prostectomy 857
Transverse incisions 752
Transvesical prostectomy 858
Traumatic brain edema 154
Traumatic hemothorax 284
Traumatic ulcer (oral cavity) 167
Trendelenburg operation 320
Trench foot 301
Triple phosphate stone 838
Triage 720
Triangle of doom 768, 773
Triangle of pain 768, 774
Triangular ligament 456
Trichobezoar 453
Trigone 831
Triple assessment 341
Trismus 101
Troisier's sign 322
Trophic ulcer 63
Tropical splenomegaly 570
Tropical ulcer 64
Trousseau's sign 322
Trousseau's syndrome 322
True diverticula 597
Truncal vagotomy 428, 430
Tuberculosis of breast 346
Tuberculous ulcer 66
Tubercle of montgomery 333
Tubercular ulcer 66, 167
Tuberculosis of intestine 614
Tuberculosis of mesenteric lymph node 587
Tuberculous lymphadenitis 216
Tuberculous peritonitis 578
Tubular adenoma 623
Tubular Carcinoma of breast 355
Tubulo dermoid 122
Tumour marker's 232, 921
Tumour of appendix 675
Tumour suppressor genes 920
Tumours of cheek 170
Tumours of large intestine 622
Tumours of rectum 684
Tumours of small intestine 620
Tumours of testis 966
Tumours of Thyroid 244
Tunica albuginea 891
Tunica vaginalis 891
TUR syndrome 859
Turban tumour 133
Turcot's syndrome 624
Type A gastritis 412, 413
Type B gastritis 412, 413
Type of shock 17
Types of LASER 937-938
Tyson's gland 832
Tylectomy 361

U

Ubiquitous tumour 124
Ulcerative colitis 603
Ulcer 59
Ulcer crater 423
Ulcer niche 423
Ulcerative tuberculosis 616
Ultrasonography 994-997
3D ultrasonography 995
4D ultrasonography 995
A mode 995
B mode 995
Doppler mode 995
M mode 995
Transesophageal 996
Transrectal 996

Laproscopic ultrasound 996
Umbilectomy 757
Umbilical abscess 753
Umbilical adenoma 756
Umbilical calculus 754
Umbilical dermatitis 754
Umbilical fistula 754
Umbilical granuloma 753
Umbilical hernia 781-783, 964
Umbilical hernia of infants 782
Umbilical sinus 753-754
Umbilicus 752
Umbolith 754
Undescended testis 906
Unilateral fusion of kidney 796
Unilateral renal agenesis 795
Universal tumour 124
Urachal cyst 756
Urachus 754
Urate stone 808, 838
Ureterolithotomy 816
Uremic medullary cystic disease 798
Ureteric calculus 814
Ureteric colic 814
Ureteric meatotomy 815
Ureterocele 800
Ureterosigmoidostomy 833-834
Urethral carcinoma 880
Urethral stricture 879
Urethritis 879
Urinary incontinence 845
Uric acid calculus 808, 838
Urinary diversion 833-834
Uroflowmetry 854
Utrasensitive TSH 230
Uvula vesicae 831

V

Vaginal hydrocele 900
VACTERAL anomaly 948
Vaccume assisted closure 70
Vanishing bile duct syndrome 987
Variceal banding 486
Varioliform gastritis 414
Varicocele 898
Varicose veins 317
Vasodilatory shock 18
Vasogenic edema 154
Vasospastic disorders 300
Vasovagal shock 19
VATS 277
Velcade 928
Vena caval filter 327
Venous Hemangioma 128, 963
Venous hemorrhage 33
Venous stasis ulcer 10
Venous thrombosis 321
Venous ulcer 10, 63
Verner Morrison syndrome 556
Ventral cordee 873
Ventral hernia 748
Verres needle 70
Verrucous carcinoma 714
Verumontanum 869
Vesical pile 851
Vesico-ureteric reflux 817
Villous adlnoma 623
Vinblastine 927
Vinca alkaloids 927
Vincent stomatitis 166
Vincristine 927
VIPoma 556
Virchow nodes 496
Viral Parotitis 196
Virchow's triad 322
Vitelline cyst 567
Vitello-intestinal duct 754

Voiding symptoms 852
Volvulus 643
Volvulus neonatorum 644, 945
Volvulus of sigmoid colon 645
Volvulus of small intestine 644
Volvulus of stomach 453
Vonreckling hausen's disease 129

W

WAGR syndrome 822
Wandering spleen 559
Warm thyroid nodule 228, 229
Warthin's tumour 201
Wart 126
WDHA syndrome 556
Web space infection 111
Well's operation 681
Wen 123
Wet gangrene 302
Wharton's duct 194
Whipple's operation 551-552
Whipple's triad 554
White bile 519
White line of Hilton 693
Whitehead deformity 706
Whitehead's hemorrhoidectomy 706
Whitlow 113
Wilkie's syndrome 618
WILM'S tumour 822
Wolfe graft 93
Woody thyroiditis 243
Wound 1
Wound Closure 7
Wound healing 7
Wright test-312

X

Xanthine stone 809
Xanthogranulomatous pyelonephritis 818
X ray 992

Y

Young's operation 859

Z

Z-E syndrome 554
Zenker's diverticula 394
Ziemann's technique 780
Zollinger-Ellison's syndrome 554
Zonal anatomy of prostate 848